

INFECTION

Pathophysiology.....	185	Management.....	190
Select Organisms.....	186	Antibiotics.....	190
<i>Staphylococcus aureus</i>	187	Pyarthrits.....	190
<i>Staphylococcus epidermidis</i>	187	Osteomyelitis.....	191
<i>Kingella kingæ</i>	187	Complications.....	192
<i>Propionibacterium acnes</i>	187	Other Infection.....	193
<i>Pseudomonas æruginosa</i>	187	Chronic Recurrent Multifocal Osteomyelitis.....	193
<i>Salmonella</i>	187	Pelvis.....	193
<i>Borrelia burgdorferi</i>	187	Pyomyositis.....	194
Evaluation.....	188	Necrotizing Fasciitis.....	194
History.....	188	Tuberculosis.....	195
Physical Examination.....	188	Surgical Site Infection.....	196
Imaging.....	188		
Laboratory Studies.....	189		

Musculoskeletal infections risk life, deformity, and disability. Infections and their treatment are evolving. Pyarthrits due to *Hæmophilus influenzae* has declined due to vaccination. Antibiotic resistance is rising, for example, methicillin-resistant *Staphylococcus aureus* (MRSA) is the causative pathogen in up to 1/3 of cases, is more invasive, and leads to more complications. Diagnosis is improving with new modalities, for example, polymerase chain reaction. Duration of intravenous administration of antibiotics and total duration of therapy have been shortened significantly.

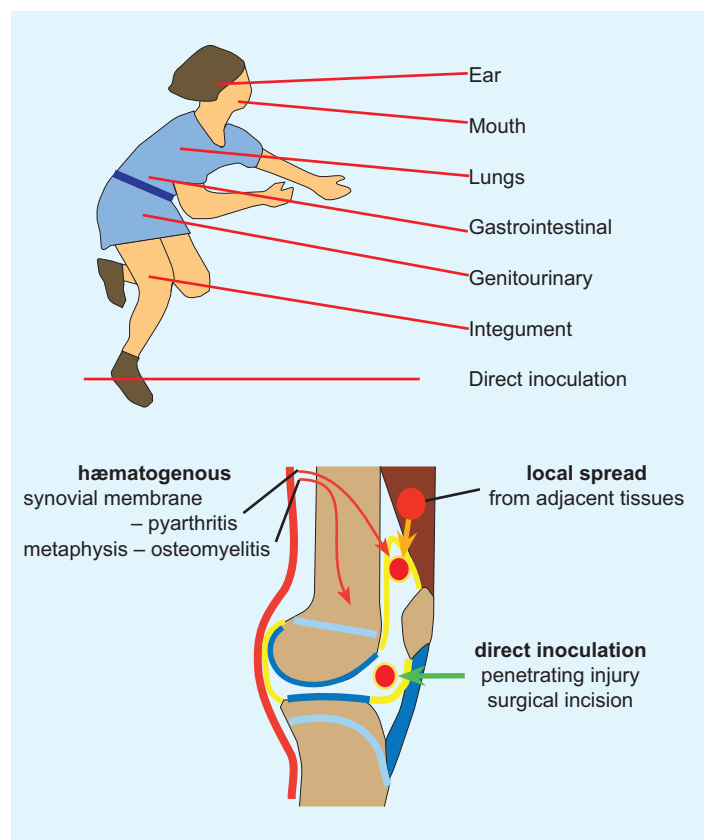
Osteomyelitis is twice as frequent as pyarthrits. This increased rate may be due to MRI detection of bone infection before radiographic change. Musculoskeletal infections show no gender predilection. Presentation skews to the middle of the first decade (6.6 years).

PATHOPHYSIOLOGY

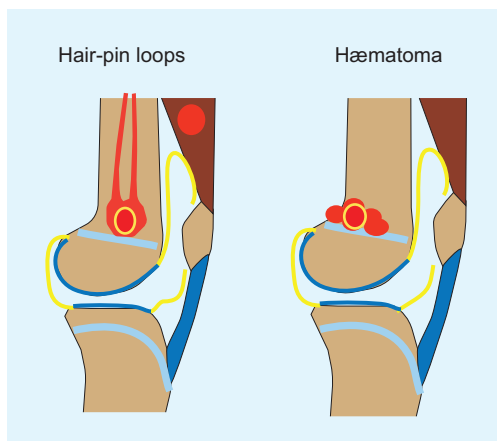
Most infections are hæmatogenous [A]. Joints may be seeded through the vascular network of the synovial membrane and by local extension from infection of intra-articular bone (neck of femur, neck of radius, distal fibula, proximal humerus). Direct inoculation is an occupational hazard of childhood (scrapes and falls) and has particular relevance to the surgical incision.

Bacteræmia occurs daily and, often, as does trauma in a child. The metaphysis of bone is vulnerable to infection because of normal vascular stasis in hairpin capillary loops turned back by an impervious physis [B]. Hæmatoma results in a similarly favorable environment. Bacteria may gain access to epiphysial bone and a joint from metaphysial bone via transphysial vessels, which remain patent in infancy and account for a high rate of hip pyarthrits [C].

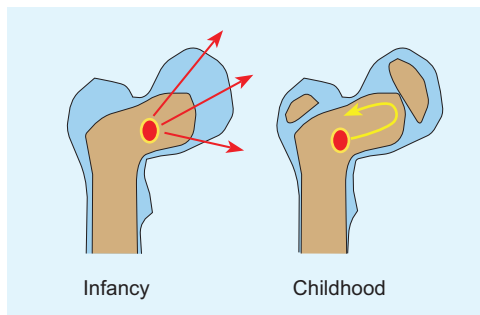
Bacteria secrete a glycocalyx (Greek γλυκος: “sugar” and καλύξ: “coat”), a viscous polysaccharide slime that coats their surface. The glycocalyx protects against drying, traps nutrients, allows adherence to surfaces to aid colonization and resist flushing, and prevents engulfment by phagocytes. Bacteria gain advantage by formation of a community within an adhesive matrix known as a biofilm, which impedes diffusion of antibiotics and where the bacteria communicate by quorum sensing and adapt to their environment (e.g., reduce metabolism) as a population, akin to a multicellular organism, rather than as individuals.



A Portals of entry Most common is hæmatogenous.



B Vascular anatomy Stasis in hairpin loops or a hæmatoma provides a favorable environment for bacterial proliferation.



C Transphyseal extension Transphyseal vessels allow spread of infection from metaphysis into joint (red) in infancy. The physis becomes impervious (yellow) with growth.

Most exposures do not amount to infection, because the immune system clears the infectious organisms [D]. When organism virulence overcomes host defense, an acute infection follows, which may escape local confines to threaten the child systemically, including life. A stalemate between organism and host results in chronic infection, including abscess, posing a local threat to the limb. This is defined as > 6 weeks but may last for years. Impaired hosts include the malnourished, those with chronic disease or tumor, those receiving immunosuppressive medication, and the premature. They may become infected even by low-virulence organisms, which can penetrate porous defenses.

SELECT ORGANISMS

Bacteria may be distinguished morphologically as coccus (Greek *κοκκος*; “grain, seed”), rod or bacillus (Latin *bacillus* = Greek *βακτηρία*: “staff, cane”), vibrio (comma shaped), spirilla (spiral), and spirochete (tightly coiled). The organisms may occur in pairs (diplococcus), for example, *Neisseria*; in chains, for example, *Streptococcus*; in bunches, for example, *Staphylococcus* (Greek *σταφυλη*: “grape”); in filaments, for example, *Actinobacter*; and in complex structures resembling fungi, for example, *Nocardia*.

Gram-positive bacteria are characterized by a thick cell wall containing many layers of peptidoglycan and teichoic acids, which retain crystal violet in the Gram stain technique (Danish scientist Hans Christian Gram, 1853–1938). Gram-positive cocci are the most common pathogens in musculoskeletal infections. By contrast, Gram-negative bacteria have a relatively thin cell wall consisting of a peptidoglycan layer surrounded by a second lipid membrane containing lipopolysaccharides, the endotoxin responsible for much of their toxicity. Acid-fast bacteria, like *Mycobacterium*, are resistant to decolorization by acids during staining procedures (e.g., Gram stain), on account of the high lipid content of its wall (mycolic acid), which also contributes to virulence and resistance. L-form bacteria are strains of bacteria that lack cell walls. The main pathogenic bacteria in this class is *Mycoplasma*.

Certain genera of Gram-positive bacteria, such as *Clostridium tetani* (puncture wounds), form resistant endospores that may lie dormant for millions of years. Aerobic organisms use oxygen as the electron acceptor, while anaerobic organisms use other inorganic compounds (e.g., nitrate, sulfate, carbon dioxide) as electron acceptors, in a redox reaction that releases energy to synthesize ATP and drive metabolism.

Type of pathogen depends upon several factors:

- Age. While *Staphylococcus aureus* is most common overall, Gram-negative bacteria and in particular *Kingella kingae* account for more than half of infections in children under 4.
- Vaccination history. Vaccination against *Haemophilus influenzae B* in the last decade of the 20th century has essentially eliminated pyarthrititis due to this organism compared with a prevaccination rate of 1/3 of pyarthrititis.
- Host environment. Because of its ability to rapidly develop a biofilm, *Staphylococcus epidermidis* is of particular concern to patients with implants.

- Socioeconomics. *Haemophilus influenzae* remains relevant in developing countries lacking vaccination programs.
- Geography. Tuberculous spondylitis, rare in North American children, remains a significant burden in Africa.

Staphylococcus Aureus

New strains of this Gram-positive bacterium may be methicillin (MRSA) or vancomycin resistant. MRSA secretion of the necrotizing toxin Panton-Valentine leukocidin results in more invasive infection, longer hospitalization, more surgery, and higher complication rates.

Staphylococcus Epidermidis

This Gram-positive bacterium is responsible for nosocomial infection. It is a threat to patients who are immune compromised. The ability to form biofilms on implants is a major virulence factor. It is a frequent contaminant in laboratory analysis.

Kingella Kingae

Infections by this Gram-negative coccobacillus are rising, in particular in infants. Presentation is benign, including fever in less than 1/5 of children and a normal C-reactive protein (CRP) in more than 1/3.

Propionibacterium Acnes

This aerotolerant anaerobic Gram-positive bacterium is a commensal colonist of the sebaceous glands of the skin around puberty. The indolent nature of this organism explains the delayed presentation of postoperative infection (including revision), in particular in spine surgery, where it requires implant removal for eradication.

Pseudomonas aeruginosa

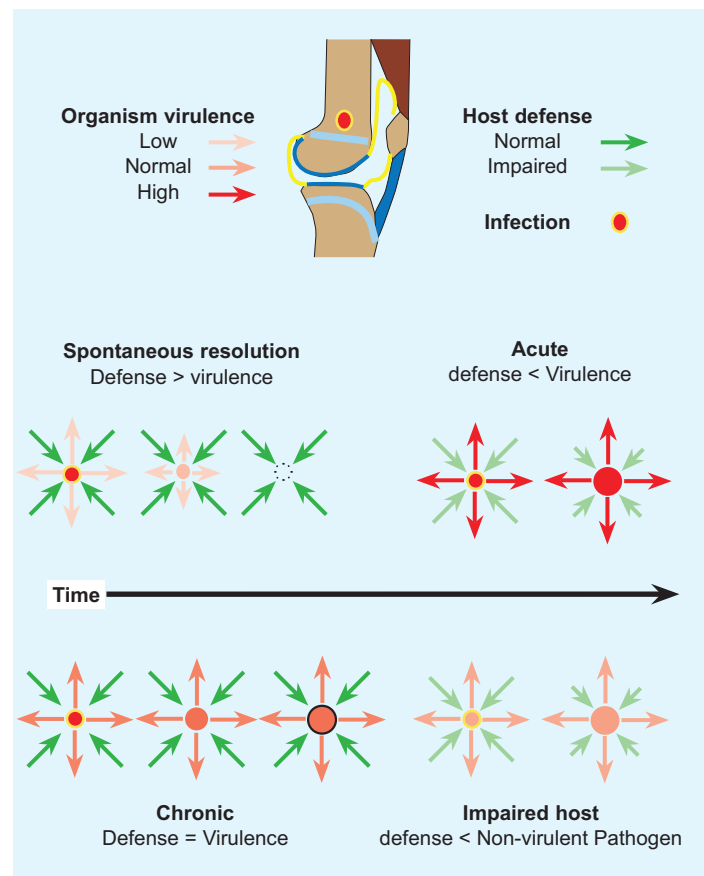
Opportunistic Gram-negative rod that rarely causes disease in the healthy, except when a physical barrier is breached, such as after a puncture wound to the sole of the foot in a shoe. It also is found in the setting of immune compromise, such as in the gastrointestinal tract of a child with leukæmia and the lungs in cystic fibrosis.

Salmonella

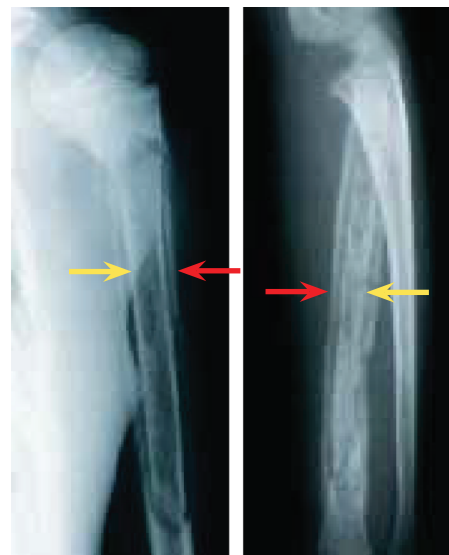This Gram-negative enterobacterium is of particular concern in children with sickle cell disease. Capillary occlusion secondary to sickling may infarct the gut, permitting *Salmonella* invasion. Reticuloendothelial dysfunction and expanded marrow with sluggish flow leads to osteonecrosis with *Salmonella* infection. The infection is distinguished by diaphysal involvement [A], multiple sites, and a high rate of complications due to vasculopathy and immune compromise.

Borrelia Burgdorferi

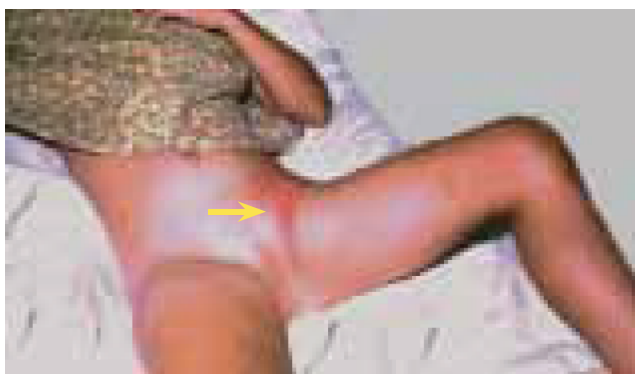This spirochete causes Lyme disease (Old Lyme, Connecticut, USA), a zoonosis transmitted from rodents by the *Ixodes* tick. Lyme disease is characterized by a delayed, warm though not itchy, target rash, termed erythema chronicum migrans, and pyarthrititis. The disease also may affect the heart and central nervous system. Be alert to travel and exposure history: due to the relative indolence of pyarthrititis, delay in diagnosis is typical.



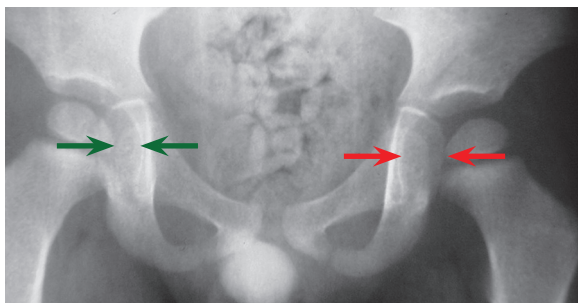
D Organism versus host The balance of virulence versus defense influences outcome.



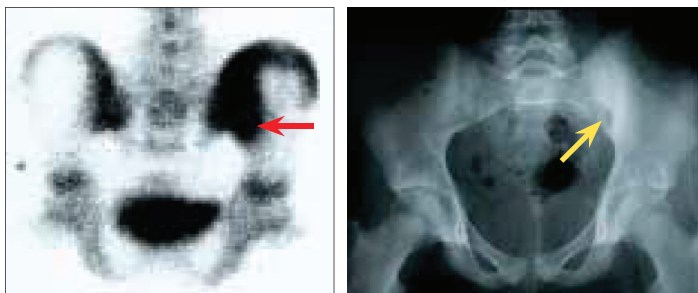A Salmonella osteomyelitis in sickle cell disease This polyostotic infection elicits extensive subperiosteal osteogenesis (red) that completely surrounds the native diaphysis (yellow).



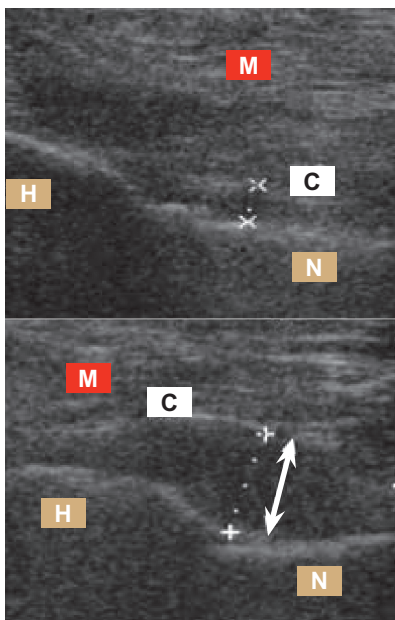
A Hip infection Presentation was delayed until swelling, redness, and warmth appeared externally. The hip is held in flexion, lateral rotation, and abduction.



B Röntgenogramme of hip infection The left hip has an effusion based upon increased medial joint width.



C Scintigraphy for osteomyelitis Increased uptake in the left ilium (red) despite negative röntgenogrammes, which showed a lesion 3 weeks later (yellow).



D Ultrasonography for hip effusion The joint capsule is elevated (*white*) off the femur by fluid. H, head of femur; N, neck of femur; C, capsule; M, muscle.

EVALUATION

History

Determine if there is comorbidity. What is the vaccination status? Have there been any significant exposures or travel? Was the child injured? Duration of symptoms in pyarthrititis is of prognostic value: while there is biochemical evidence of cartilage within several hours of exposure to pus, clinical outcomes, including postinfectious arthritis and growth disturbance, deteriorate after 3 days. Did the patient already receive antibiotics? If so, this will reduce culture yields from blood and other tissue specimens.

Physical Examination

Take the temperature. Perform a screening examination first. Is the child in distress? This suggests an overwhelmed host worthy of expeditious attention. It argues against more benign confounding conditions such as transient synovitis. Similarly, lack of movement of, or bearing weight on, a limb, known as “pseudoparalysis,” is a sign of such extreme pain that the child will not use the affected part. Even if the examiner tries, the child will splint to present joint rigidity. In children, infected joints do not move; by contrast, only half of adjacent joints show reduction of motion in osteomyelitis. Look for inflammatory signs in the soft tissues, including swelling, redness, and warmth [A]. In order to relax these inflamed soft tissues, joints are flexed and at the hip rotated lateralward [A]. Percuss the bone to determine tenderness: this transmits force effectively to the bone while manipulating surrounding soft tissues less than palpation. Check the skin for stigmata that may predispose to infection, such as a pock or a laceration.

Imaging

Röntgenogrammes Signs of infection include the following:

- Soft tissue swelling. This includes alteration of cutaneous contour, distortion of intermuscular planes, and contrasting densities.
- Joint diastasis. At the hip, measure the distance between proximal femoral epiphysis and medial wall of acetabulum [B]. An effusion may be sufficiently large to dislocate a joint.
- Periosteal elevation. This represents repair of osseous destruction.
- Bone loss. A reduction of bone density of >30% is necessary before there are radiographic changes.

Röntgenogrammes are significant only if positive; negative images are inconclusive.

Scintigraphy This is indicated for clinical suspicion of osteomyelitis with normal röntgenogrammes. Technetium (^{99m}Tc) medronic acid is taken up preferentially by bone, concentrating (hot) where bone is inflamed. The immediate or flow phase (seconds after injection) assesses bone perfusion. The second or blood pool phase (minutes) is a measure of surrounding vascularity, as capillary dilatation slows the flow of blood. The third or delayed phase (hours) is a reflection of bone turnover. Reduced uptake (“cold” scan) is concerning for infarction and osteonecrosis, which limit antibiotic access. The scintigramme is unaffected by bone or joint aspiration.

Ultrasonound This is indicated for evaluation of the joint (in particular axial), such as effusion [D], and soft tissue, such as abscess. It is noninvasive, nonradiating, dynamic, portable, versatile, and cheap. However, it is user dependent, both for technique and for interpretation. Both quantitative and qualitative assessment of joint effusion is possible. At the hip, >2 mm elevation of the capsule off the neck of femur at the anterior joint recess defines distension. Echogenicity of the fluid suggests pus. Synovial membrane hypertrophy distinguishes transient synovitis (absent) from infection or other inflammatory process (present). Joint aspiration may be facilitated by ultrasonogramme, which confirms articular location of the needle. False negatives may occur early in disease, before sufficient fluid has accumulated to be detectable.

MRI This shows soft tissue best [E]. It also shows bone and its reaction. The modality allows for early identification with high sensitivity, before röntgenogrammes change, and provides anatomic detail for surgical planning. Gadolinium enhancement enables identification of infection of nonossified cartilage, including the epiphysis. This is a tissue target for MRSA and *Kingella kingae*. Thus, treatment may be instituted earlier to mitigate damage from these pathogens.

Exercise sobriety and correlate MRI findings with the entire evaluation of the child. Because it reveals everything in such detail, it may raise alarm and promote zealous intervention. Remember that it requires sedation for the young child who will not lie still.

CT/PET This may be superior to MRI in monitoring response to treatment for osteomyelitis and in distinguishing ongoing infection from repair. However, the radiation dose limits the use of this modality.

Laboratory Studies

Blood Only half of children will have an elevated white blood cell count (WBC) > 12,000/mm³ at presentation. Most patients will have erythrocyte sedimentation rate (ESR) > 20 mm/h and C-reactive protein (CRP) > 20 mg/L; in combination, these markers approach 100% sensitivity for infection. Isolated musculoskeletal infection is characterized by a range of CRP 20 to 90 mg/L; CRP > 90 mg/L suggests disseminated infection. With successful treatment, ESR rises by 3 to 4 days and normalizes by 4 to 6 weeks, while CRP rises by 1 to 2 days and normalizes within 2 weeks [F]. ESR is useful for long-term follow-up and CRP for the acute treatment period.

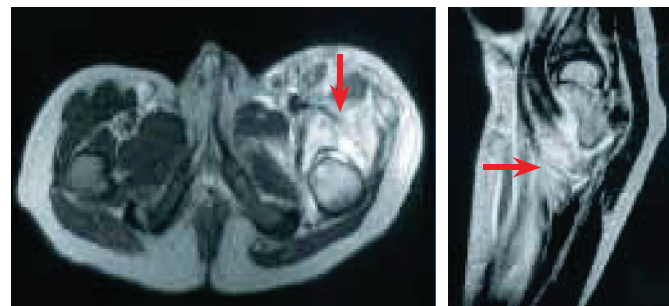
Bone and joint This may be fluid from arthrocentesis or blood from bone or surgical specimen. The emergency setting, where the child may be sedated and before antibiotics are administered, is an opportunity to obtain fluid directly from the site of infection, rather than peripherally from a vein. If an appendicular joint is swollen, stick a needle in it. Decompression in this case may be therapeutic, by decreasing bacterial load, in addition to diagnostic. Infected metaphyseal bone is soft. Insert a needle while aspirating in the event that there is a periosteal abscess. Once bone is encountered, advance the needle while rotating through a small arc to burrow into the bone, from where a blood specimen may be aspirated. At operation, physical deep and superficial tissue is preferable to swabs.

Gram stain may show bacteria. WBC > 50,000/mm³ with predominance of polymorphonuclear leukocytes in joint fluid is consistent with infection, although there may be overlap with juvenile idiopathic arthritis.

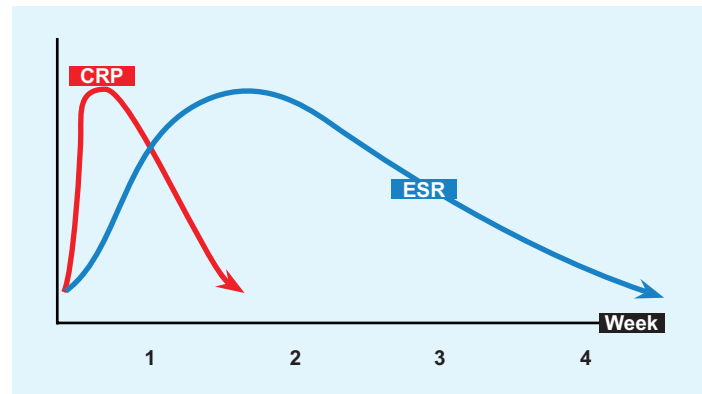
Culture Only half of blood, joint, and bone specimens will yield an organism. The rate is reduced by antibiotics, of which administration should be delayed in the stable child until all specimens are obtained. For *Kingella kingae*, nasopharyngeal cultures (due to colonization) are significantly more positive than joint fluid.

Polymerase chain reaction Heat-stable polymerase selectively amplifies, using complementary primers, a specific region, or target of DNA after melting the double helix into independent strands. It provides results within 3 hours. It identifies fastidious organisms difficult to grow in culture, such as *Kingella kingae*. It accelerates identification of virulent pathogens, such as MRSA, allowing earlier treatment to limit their morbidity. Early identification also promises more targeted antibiotic regimens, reducing iatrogenic bacterial resistance.

Due to diagnostic dilemma, burden of disease, and gravity of negative outcomes, diagnostic criteria have been developed for pyarthrits of the hip [G]. Added to this has been repeat presentation, suggesting deterioration during a period of observation. Remember that these are guidelines and not rules.



E MRI showing a thigh abscess Osteomyelitis of the proximal femur was associated with an abscess of the upper thigh (red). This guided the approach to drainage.



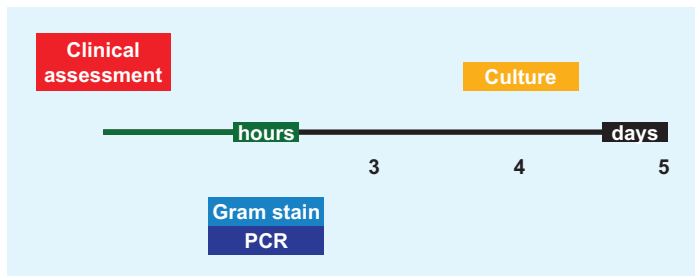
F Temporal pattern of CRP and ESR CRP is a better acute measure, ESR better as a chronic measure.

Predictor	#: Likelihood of infection
	0: Not infection.
Refusal to bear weight	1: Unlikely.
Fever (> 38.5 degrees)	2: Unlikely, observe.
Leukocytosis (> 12,000/mm ³)	3: Likely, act.
Erythrocyte sedimentation rate (ESR)	4: Highly likely, act.
C-reactive protein (CRP)	Negative predictive value: > 80%
	Positive predictive value: 50%

G Prediction of pyarthrits of the hip Do not rely on these guidelines at the expense of judgment. Normal value of ESR is <20 mm/h. Normal value of CRP is <10 mg/L.

Antibiotic	Comment
First generation cephalosporin (e.g., cephalexin)	Standard empirical therapy MSSA, <i>Kingella kingae</i>
Clindamycin	For cephalosporin hypersensitivity <i>Kingella kingae</i> resistant Covers Gram positive cocci + anaerobic Gram negative rods + some MRSA
Vancomycin	MRSA Concerns about iatrogenic resistance
Third generation cephalosporin (e.g., ceftriaxone)	Gram negative coverage in neonates

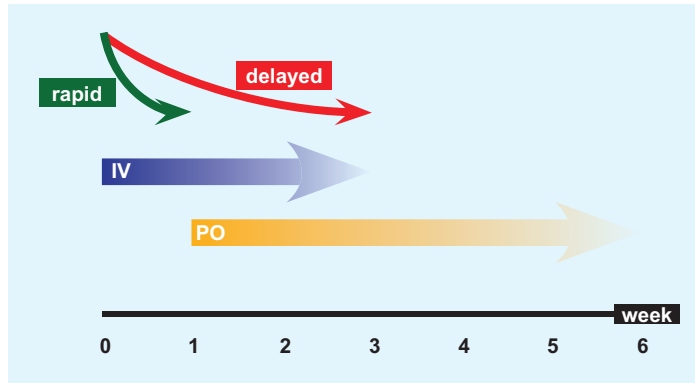
A Initial antibiotic therapy Clinical assessment guides treatment.



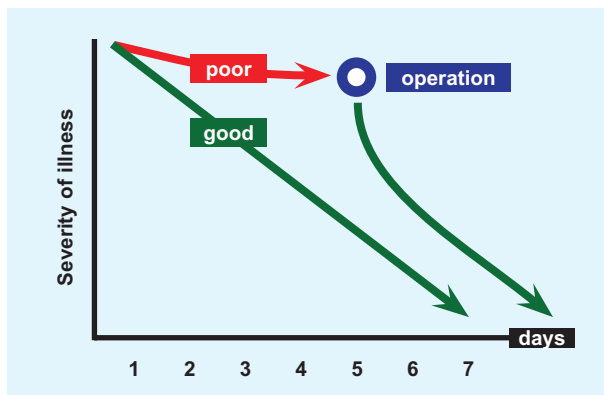
B Timing of antibiotic therapy Selection of antibiotics is influenced by sequence of evaluation.

Indication	Timing of treatment
Active infection	<ul style="list-style-type: none"> • Days <i>per venam</i> • Weeks <i>per orem</i>
Surgical prophylaxis	Single dose <i>per venam</i> : <ul style="list-style-type: none"> • prior to surgical incision • at emergency presentation

C Timing of antibiotic therapy This varies according to indication.



D Timing of antibiotic therapy Duration and route are determined in part by clinical response (rapid or delayed), and overall are contracting. IV, intravenous; PO, *per orem*.



E Variability in the course of treatment Several factors impact treatment approach, such as operation for drainage and débridement when intravenous antibiotics alone do not elicit a good response.

MANAGEMENT

Established principles stand in a setting of changing practice that admits variability.

Antibiotics

The potential for healing paediatric musculoskeletal infection is remarkable. For example, diskitis may resolve without antibiotics, of which the effect is limited to shortening the duration of symptoms. Balancing this is the vulnerability of children. For example, physial involvement may disturb growth, leading to malangulation or arrest. Empirical therapy commences after specimens have been obtained. Clinical assessment [A], in particular age and history, Gram stain, PCR, and culture, guides treatment. Time is an essential factor:

- Selection and focusing of type of antibiotic [B].
- Active treatment *versus* prophylaxis [C]:

There is clear evidence to support a single dose of preoperative intravenous antibiotics within 6 hours of incision as surgical prophylaxis. Further administration is moot and if prolonged >48 hours may increase infection by selection for resistant organisms.

- Duration and route of antibiotic therapy [D]:

The advantage of the intravenous route is rapidity of delivery, due to 100% bioavailability. The oral route is affected by compliance and bioavailability, which in turn is determined by gastrointestinal disease (absorption) and metabolism. Initial hospital treatment allows close observation for response. The traditional 6 weeks of intravenous route and treatment has undergone fundamental revision. The following is an idealized approach.

- Begin intravenous antibiotics:

Ensure that the child does not develop cephalosporin-induced neutropenia. Calculate antibiotic blood levels and modify dosing as indicated.

- Observe for clinical and laboratory response:

The former includes fever, pain, swelling, warmth (Celsius), function, and surgical incision. Pain includes that to palpation and with joint motion. Function includes gait assessment, for example, will the child who refused to bear weight at presentation now attempt this? A good response to the operation is a dry wound for 24 hours after drain removal. The latter may be limited to CRP, due to the rapidity of its response to infection and treatment. Observe the trend: a steady decline to <20 mg/L is deemed a success.

- Convert to oral antibiotics:

This is done once a good response has been realized. Observe in hospital for 24 hours to ensure no relapse and to educate family on regimen and follow-up.

- Stop oral antibiotics when ESR normalizes to <20 mm/h:

This may be followed weekly in the ambulatory setting.

Most (>80%) primary infections can be treated successfully with antibiotics *per venam* < 1 week and *per orem* for 3 weeks. However, this idealized approach will be modified according to patient. Specimen analysis may reveal that initial antibiotic selection was ineffective, requiring a change that prolongs intravenous duration. Persistent or worsening clinical (e.g., fever, pain, wound drainage) and laboratory (e.g., elevated CRP) response should prompt further investigation, such as with imaging, a broadening of antibiotic spectrum for occult organism, and possible repeat operation [E]. The socioeconomic status of the patient and family has implication on compliance and follow-up.

Pyarthrititis

Pus in a joint causes damage of hyaline and physial cartilage by inflammatory mediators and of bone by ischæmia due to vascular thrombosis

and pressure occlusion. Consequences include arthritis, growth disturbance, and osteonecrosis. Susceptibility to injury is determined principally by time: cartilage degradation is detectable microscopically after hours, though macroscopic, clinical injury becomes significant after 3 days. Anatomy also is a determinant. Swelling is more apparent in an appendicular joint, whereas for an axial joint, ultrasonogram may be necessary to diagnose a joint effusion. Tenuity of blood supply limits tolerance to pressure and collateral compensation. The hip is the quintessential example of anatomic vulnerability. Thus, even though the knee represents the highest burden numerically, the hip is the greatest source of consternation [A].

While osteomyelitis may resolve without surgical intervention, or even with no treatment at all (e.g., diskitis), pyarthritides requires treatment, and invasion, at least with a needle.

Infected joints may be divided into axial (hip and shoulder) and appendicular [B]. Appendicular pyarthritides may be treated with aspiration and antibiotics. Aspiration may be combined with irrigation *via* two large-bore angiocatheters until clear. Confirm by physical examination that the joint has no more fluid, in case loculations prevent complete decompression. This approach decreases the bacterial load sufficiently in a child that antibiotics will be able to eradicate the rest of the infection. It is diagnostic and therapeutic. Despite a success rate > 80% with aspiration, many surgeons prefer arthroscopic or open lavage, influenced in large measure by the grave consequences of delayed evacuation of pus from the joint: the child may be able to tolerate serial aspirations but the cartilage will not. A hybrid approach consists of aspiration and lavage at presentation in the emergency setting, where a child may be adequately sedated, followed by a more open approach if there is repeat accumulation of fluid or other evidence of poor response.

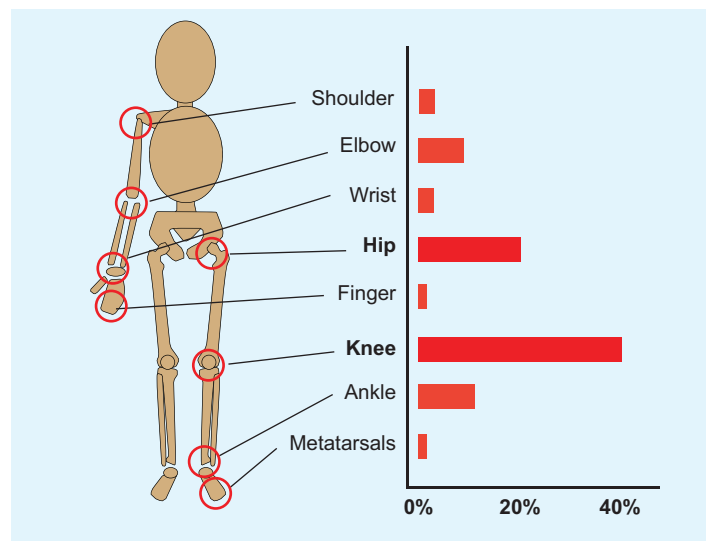
Because axial joints are deep and fluid accumulation cannot be assessed as a response to treatment, open irrigation and drainage is the first choice:

- Approach the hip *via* a Smith-Petersen approach and the shoulder *via* a deltopectoral approach.
- Perform a 1-cm² capsulectomy to allow egress of fluid after operation.
- Place a drain of sufficient caliber not to occlude. Remove the drain once there has been a good response and output is “minimal,” although there is no consensus on amount. The drain offers a path of lesser resistance to decompress the joint in order to allow healing of the wound, which must be observed to remain dry for 24 hours after drain removal before discharge is considered.
- Fenestration and curettage of intra-articular bone are indicated if röntgenogrammes show osseous change. Drilling of radionegative bone is controversial. If osteomyelitis has extended to infect the joint, it has achieved a spontaneous decompression. If the bone is uninvolved, drilling provides a direct and deep path for extension of infection into the bone.
- Repair the wound loosely and with interrupted monofilament suture.

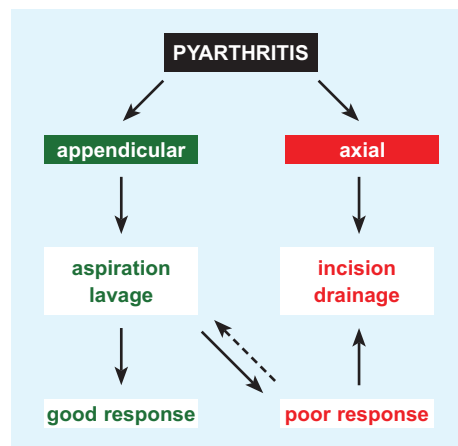
Suppressing the immune response to infection by adding intravenous dexamethasone to intravenous antibiotic therapy may reduce fever, pain, and other inflammatory signs, lower acute-phase reactants, and thereby accelerate clinical response as well as shorten duration of intravenous treatment and hospitalization.

Osteomyelitis

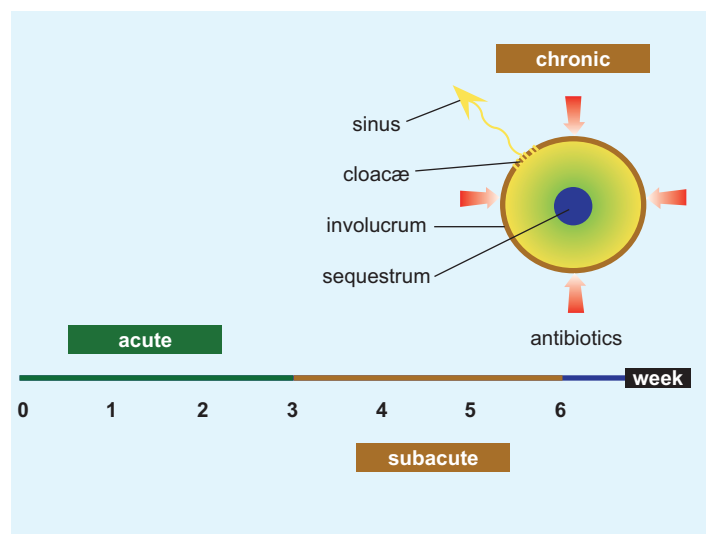
Osteomyelitis is an infection of the bone. This is classified temporally as acute (<3 weeks), subacute (3 to 6 weeks), and chronic (>6 weeks). Acute is radionegative, subacute has röntgenographic change, and chronic is characterized by abscess formation with osteonecrosis [A]. The femur is most affected [B]. Infection typically begins in the metaphysis, from where it expands toward the diaphysis and through the cortex, where it may be contained by the periosteum or it may escape to form a soft tissue abscess [C]. Long bones are more susceptible, due to a thick and relatively hypovascular cortex, compared with flat bones, such as the pelvis, which have thin cortices and rich medullæ.



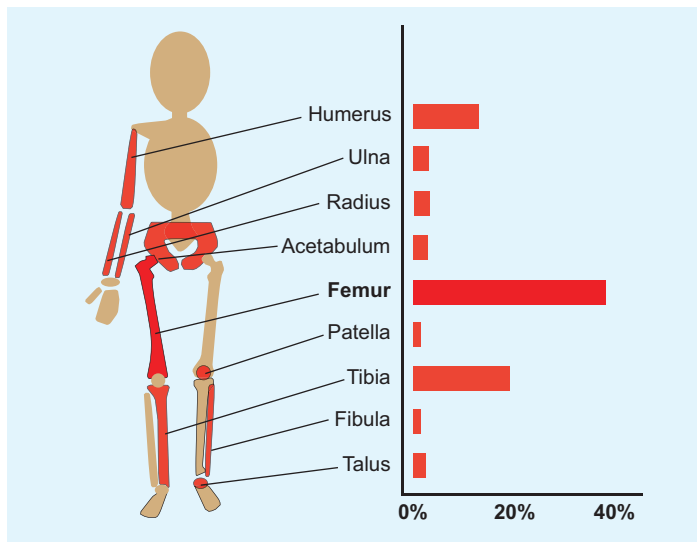
A Geographic distribution of pyarthritides.



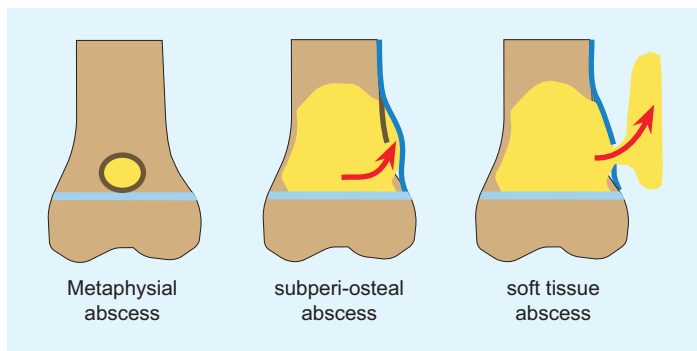
B Treatment of pyarthritides The approach differs according to type of joint and response to initial intervention.



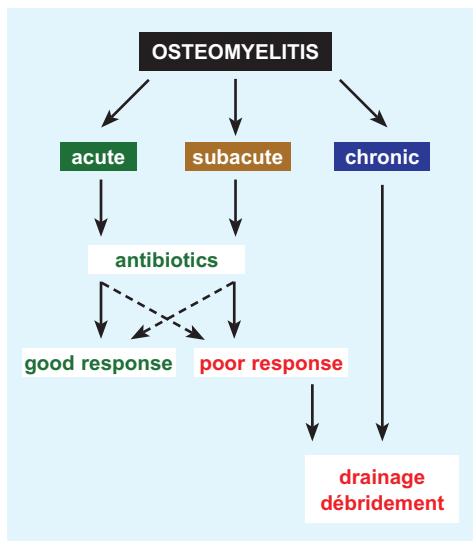
A Classification of osteomyelitis Chronicity is defined as >6 weeks. Chronic osteomyelitis is characterized classically by a sequestrum, dead piece of bone “isolated” from the surroundings in a pool of pus; an involucrum, “a wrapper” of sclerotic bone that forms as a barrier around the infection; and cloacæ, “drains” that eventually perforate the involucrum to allow flow of pus out toward the skin via a sinus, “tract.” Antibiotics cannot penetrate the involucrum, hence the indication for operative drainage.



B Geographic distribution of osteomyelitis.



C Subacute progression of osteomyelitis Metaphyseal abscess (Brodie) may erode the cortex, where it may be contained as an abscess by a repeatedly reactive periosteum that gives an "onion-skin" appearance, or from where it escapes into surrounding soft tissues.



D Treatment of osteomyelitis The approach differs according to type of joint and response to initial intervention.

The child presents with signs of inflammation, such as fever, tenderness, swelling, and erythema. There may be a history of trauma forming a haematoma that creates a favorable environment for bacterial growth. Percussion amplifies force in bone. While the patient may limit use of a limb, such as limp, individual joints will not be stiff as they are in pyarthrititis.

If röntgenogrammes are negative, scintigramme may show a locus of increased uptake. It focuses the clinical examination in a child with a vague presentation, such as refusal to walk. It also casts a wide net to evaluate remote sites, such as the spine in diskitis, and multiple sites, as may be affected in a generalized process such as leukæmia. Ultrasonogramme rules out a joint effusion in when there is a diagnostic dilemma between pyarthrititis and osteomyelitis. The imaging modality also evaluates soft tissues, including for periosteal abscess, which may be aspirated. MRI gives greater detail of extent of bone involvement and of soft tissue extension. MRI does not influence management in primary or otherwise uncomplicated cases, except to raise anxiety.

For radionegative osteomyelitis, which is typical of an acute presentation, antibiotics are the initial treatment of choice [D]. If there is a good response, a full recovery without sequelæ is expected. If there is a poor response, investigate further, including more detailed imaging such as MRI. Consider operative intervention to decrease bacterial load if there is a defined site of disease, such as a soft tissue abscess that was not visible on röntgenogrammes.

Subacute osteomyelitis may be managed initially with antibiotics. Unlike pyarthrititis, where pus damages articular cartilage if not evacuated, bone will recover fully from injury even if surgical treatment is delayed, so long as the child is stable. If there is a poor response over 2 to 3 days, surgical drainage and débridement are indicated. There has been significant bone destruction, suggesting that the balance has tipped away from host toward organism.

In the chronic setting, antibiotic access may be blocked by an involucrum, which must be physically disrupted [E]:

- Preoperative imaging will aid in surgical planning, including incision and need for consultants.
- Explore and drain the soft tissues.
- Débride all tissue that is not viable.
- If there is cortical softening, excise this to make a wide window.
- If the cortex is robust, outline an ovoid window with a drill like a postage stamp and remove with an osteotome.
- Débride until bleeding bone, manually or with a motorized burr.
- Do not injure an adjacent physis.
- Preserve periosteum to promote bone healing.
- Lay adjacent healthy muscle into the osseous bed, a process known as "saucerization." The muscle will bring the blood supply that was absent in the abscess, thereby bringing antibiotics to the infected site.
- Extensive sinus may require plastic closure, including flap coverage, after complete excision.

Complications

Generalized Infection that escapes the confines of bone, joint, or soft tissue may threaten the child systemically. Accelerate evaluation and make management more aggressive if a child is in distress.

Localized Pyarthrititis may result in the following:

- Postinfectious arthritis, due to irreversible articular cartilage injury. There is no good solution for this.
- Growth disturbance, malangulation, or arrest, due to physal cartilage injury. Excise a discreet bridge once diagnosis is made and before deformity sets in. Add osteotomy for established deformity. Perform distraction osteogenesis for shortening, without or with correction as indicated.
- Osteonecrosis, due to vascular thrombosis and pressure occlusion [A]. Observe for recovery.

These complications are the result of delayed or incomplete treatment, virulence of pathogen, and host immunity, in particular the neonate.

Osteomyelitis may result in the following:

- Advance of acute to chronic infection, an evolution from simple infection to abscess, from radionegative to radiopositive, and from nonoperative to operative treatment.
- Morbid fracture. Deossification lags the activity of infection by 2 to 3 weeks. Fracture is a risk of operative débridement.
- Growth disturbance due to adjacent physal injury. This may be infectious or iatrogenic.

OTHER INFECTION

Chronic Recurrent Multifocal Osteomyelitis

The name is descriptive, except that this is “inflammation” of the bone in a general sense: pathologic analysis shows bone that is reactive as if infected, yet no organism is isolatable. Because of this, and because solitary lesions are possible, the disorder also is known as chronic non-bacterial osteomyelitis (CNO).

The patient complains of pain without other systemic or local inflammatory symptoms or signs. The pain comes and goes in different sites of the body. Duration is months to years. Laboratory analysis is normal. Röntgenogrammes show a sclerotic heterogeneous lesion typically in metaphysis of a long bone abutting physis, although any bone may be affected. Scintigramme shows increased uptake in the lesion and identifies other skeletal sites. The unusual presentation often leads to MRI (T2-weighted and enhanced with gadolinium-diethylene triamine penta-acetic acid), which may be difficult to differentiate from a neoplastic process. Biopsy often is inconclusive, leading to more invasive and extensive surgical intervention. Lesions abutting a physis are at risk of iatrogenic growth disturbance.

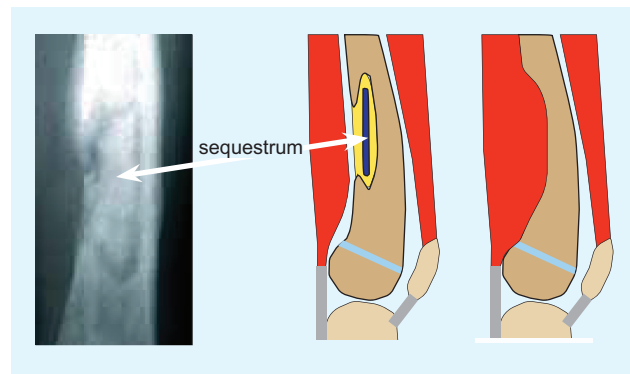
Autoinflammation, immune dysregulation without autoantibodies, error of metabolism, and postinfectious reaction have been posited as causes. There may be overlap with enthesitis-related arthritis. CRMO has been associated with chronic inflammatory bowel disease and hypophosphatasia. CRMO is equivalent in the adult to SAPHO syndrome (synovitis, acne, pustulosis, hyperostosis, and osteitis), which is managed in a similar manner.

Based upon a high haplotype relative risk, a gene has been identified in the region of a rare allele of marker D18S60 that may contribute to the cause of CRMO. In an animal model, restriction fragment length polymorphism analysis indicates that a CRMO gene may reside on murine chromosome 18.

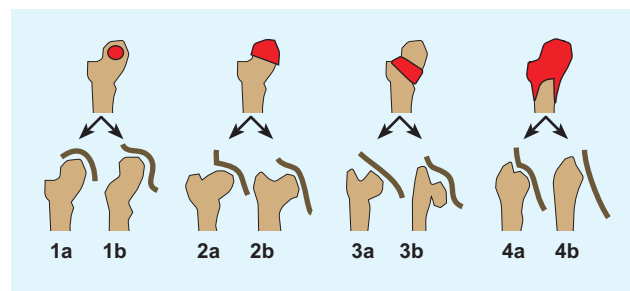
Recognize the entity and exercise restraint. Spend the time to educate patient and family, who often require considerable assurance given chronicity, appearance on imaging, and the inevitable previous opinion. The patient is not ill. Pain is frustrating but manageable symptomatically, including nonsteroidal anti-inflammatory drugs. Other agents, indicated for severe pain, include immunosuppressants (corticosteroids, methotrexate, and tumor necrosis factor blockers), immunomodulators (intravenous immunoglobulins, interferon, colchicine, and dapsone), calcitonins, and bisphosphonates. Observe clinically. Alter laboratory analysis, röntgenogrammes, and other imaging if presentation changes significantly. There is debate about whether a good prognosis with spontaneous resolution is universal.

Pelvis

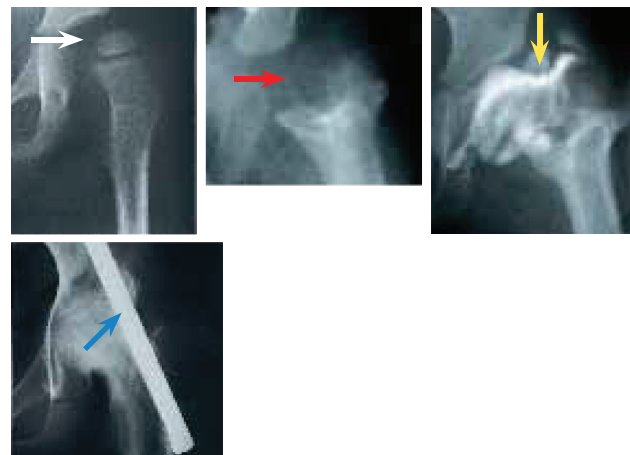The pelvis is complex [A]. Its cavitory nature makes evaluation indirect. The patient may complain of flank, back, hip, or groin pain. Examine the abdomen for rebound tenderness associated with appendicitis. Diskitis may present as refusal to walk or abdominal pain in the first decade; only in the second decade does a child reliably localize this to the back. Palpate and move the spine. The sacroiliac joint may be stressed by flexion–abduction–external rotation manoeuvre (FABER, Patrick). A rectal examination may reveal a deep pelvic abscess. Prone hip extension stretches the iliopsoa.



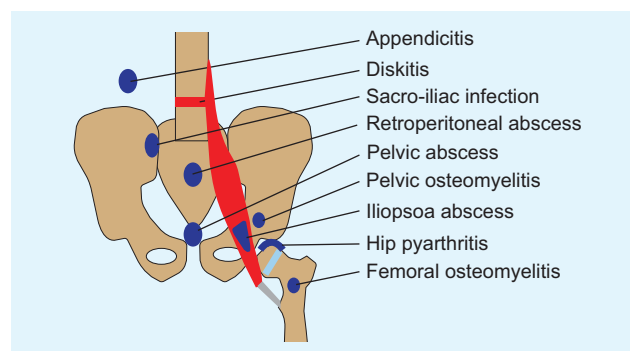
E Operative treatment of chronic osteomyelitis The approach differs according to type of joint and response to initial intervention.



A Classification of sequelae of hip pyarthrits Initial necrosis (red) determines severity of final deformity.



B Sequelae of hip pyarthrits Unrecognized infection (white) resulted in delayed treatment, which was complicated by osteonecrosis (red). Arthrogram showed hinged deformity of the proximal femoral epiphysis (yellow). Because of unacceptable pain and stiffness, the patient underwent hip arthrodesis with an anterior plate at age 14 years (blue).



A Sites of infections about the pelvis.

Due to the overlap between multiple organ systems, imaging for pelvic infection prioritizes soft tissue. While screening with ultrasonogramme or scintigramme may focus the evaluation, CT and MRI are the modalities of choice.

Management of infections of the pelvis (and spine) is exceptional. Because of the morbidity of access, and because of rich vascularity, principles of treatment are skewed toward antibiotics without and with image-guided aspiration and drainage and away from operation initially, because most will resolve without the latter.

Pyomyositis

This represents a hæmatogenous bacterial infection of skeletal muscle. It is seen in healthy children in tropical regions; by contrast, in temperate zones, it most often involves immunocompromised children, including with diabetes mellitus, viral infection (e.g., HIV), and poor nutrition. Most affected are quadriceps femoris, gluteal, and iliopsoa muscles. In the majority of cases (>75%), the pathogen is *Staphylococcus aureus*. Three clinical stages are distinguished:

- Stage 1 (first week) is characterized by localized muscle ache, pain, and low-grade fever. Physical examination reveals induration of muscle with mild pain but without cutaneous manifestation. This accounts for delay in diagnosis. T2-weighted MRI shows nongeographic hyperintense signal and muscle enlargement. Have a high index of suspicion and obtain this test early. Treatment is intravenous antibiotics and close observation.
- Stage 2 (2 to 3 weeks). Suppuration makes the child appear ill and the muscle exquisitely tender. Abscess presents rim enhancement on MRI. Perform urgent drainage and débridement.
- In stage 3, the child has become septic. Supplement drainage and débridement with supportive measures as indicated.

Necrotizing Fasciitis

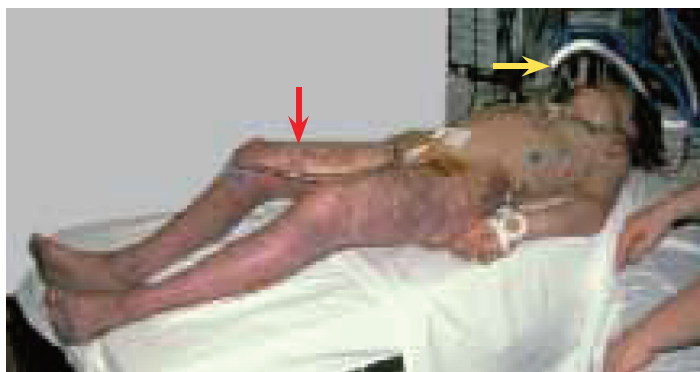The condition is described in the Corpus Hippocraticum in association with erysipelas. The name emphasizes disproportionate destruction of superficial fascia with relative sparing of subjacent muscles (Wilson). Spread is rapid along deep fascial planes. Two types are distinguished, based upon pathogens:

- Type I is polymicrobial, including ærobes *Streptococcus pyogenes*, *MSSA*, and *MRSA* and anærobes *Clostridium perfringens*, *Bacteroides fragilis*, and *Aeromonas hydrophila*. This represents the majority of cases.
- Type II is monomicrobial.

It also may be classified based upon fulminance. Immune compromise is a risk factor. Skin is the richest source of pathogens, where infection reflects anatomic distribution, for example, perineal infection (Fournier gangrene) by anærobes. One source of MRSA is nosocomial. Bacterial exotoxins and superantigens set up a vicious cycle of thrombosis followed by necrosis followed by bacterial growth and invasion. The limbs are more affected than the trunk, which is associated with a higher mortality rate due to proximity of vital viscera and lack of amputation as an option.

The condition resembles an infected compartmental syndrome. The inciting event is a breach of skin, including a surgical incision. Appearance is one of acute distress, often panic. Pain is the first sign and is out of proportion with the remainder of the early presentation. Within hours, other inflammatory signs manifest: fever, swelling, compartmental tension, cutaneous crepitus, violaceous discoloration, and bullæ, which leak gray “dishwater” pus [A]. Systemic signs develop, such as tachycardia, hypotension, diarrhæa, and vomiting. No matter the external manifestation, the internal ones are much worse. Tissues are devitalized, black, œdematous, indurated yet friable, unstable due to loss of normal anchoring architecture, liquefied, and foul.

Inflammatory markers are very elevated, for example, CRP > 100 mg/L and WBC > 20,000/mm³, whereas hæmoglobin is reduced <10 g/dL.



A Necrotizing fasciitis There are severe changes in the lower limbs (red) in a child who requires ventilatory support (yellow).

Do not let laboratory analysis distract from the fact that this is a clinical diagnosis. And it is a surgical emergency. Administer broad spectrum and multiple intravenous antibiotics. Imaging such as MRI may be too much of a delay, as are fine needle aspiration or biopsy. Operation requires courage, both on the side of the patient and family—who must be counseled on how much will be removed and that there will be many stages and risks including death—as well as the side of the surgeon. Make a big incision and débride widely: leaving dead tissue will threaten life for the misplaced concern about saving function. Explore everywhere and follow every tract. Amputation may be necessary. Reserve the ICU, plan for a return to the operating room, and assemble an interdisciplinary team (e.g., soft tissue reconstructive surgeons).

Hyperbaric oxygen therapy is not readily available and controversial. Intravenous immunoglobulins show efficacy as an adjunctive treatment.

Mortality rate increases with time to diagnosis and with age.

Tuberculosis

The disease is caused by *Mycobacterium tuberculosis*. It is highly aerobic (lung) and very slow growing, replicating over several hours compared with minutes for most bacteria. The German scientist Robert Koch (1843 to 1910) presented four postulates that proved this bacillus as the cause of consumption.

Less than 10% of tuberculosis is extrapulmonary, and skeletal involvement accounts for 2% of the total burden of the disease. Half of skeletal cases are spinal [A]. The disease is heavily weighted toward the developing world: 1/3 cases are in Asia and 1/3 in Africa. After socioeconomic status, immune compromise is the most frequent causative factor. The portal of entry is the lung, with h ematogenous spread to the skeleton. Less than 10% of healthy children will contract tuberculosis after infection with *Mycobacterium tuberculosis*.

Evaluation Rarity in the developed world results in lack of clinical suspicion. This, together with slow progression of disease, results in delayed diagnosis (months). Inflammatory markers are only mildly elevated, including ESR, but often, CRP is normal. Ask about travel and exposure, as well as BCG (Bacille Calmette-Gu erin) vaccination. Obtain a chest r ontgenogramme. Place a tuberculin skin test. Because the disease is globally erosive of both sides of a joint and elicits a robust osseous reaction, tumor may be suspected on r ontgenogrammes. MRI aids visualization of soft tissue abscess.

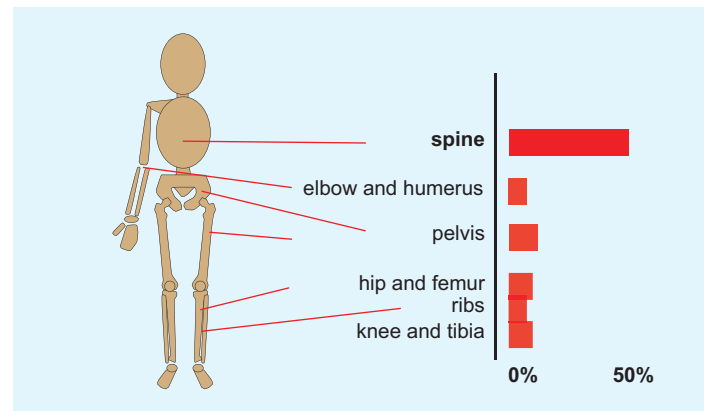
Management Despite or because of the slowness of progression, the disease is destructive. This results in significant postinfectious arthritis and deformity. It also necessitates a prolonged (12 months) and multiple (four drug: isoniazid, rifampin, ethambutol, pyrazinamide) antibiotic regimen. Drug resistance is a worldwide concern. Surgical débridement may require bone grafting of subchondral erosions. Osteotomy corrects malangulation. Arthrodesis may be necessary for end-stage arthritis.

Tuberculous spondylitis (Pott disease) starts in the metaphysis of the vertebral body (adjacent to intervertebral disk), where it produces a short sharp kyphosis [B]. Ten percent of cases are cervical, with thoracic slightly more frequent than lumbar. Cervical involvement may lead to atlantoaxial instability. Lumbar infection may extend along the psoa to the groin. Pott disease is the most dangerous manifestation of skeletal tuberculosis. Pain is universal. Neural involvement occurs in half of cases. R ontgenogrammes measure deformity. MRI shows the abscess and neural elements. CT is useful for operative planning.

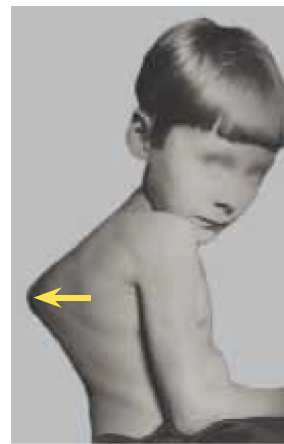
In addition to antibiotic treatment, surgical reconstruction is indicated for the following:

- Neural compromise. This may be due to abscess or to severe deformity.
- Progression of deformity.

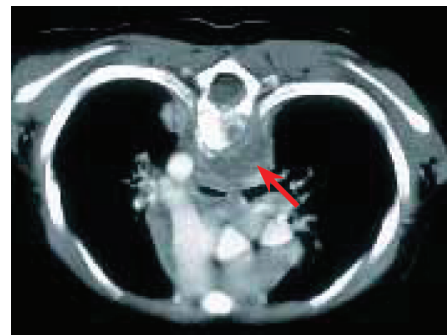Operation is circumferential, because abscess compromises the integrity of the anterior column of the spine [C] and rigidity requires vertebral column resection for correction. Hence the high surgical risk.



A Geographic distribution of musculoskeletal tuberculosis.



B Tuberculosis of the spine This may produce a short sharp kyphosis (yellow).



C Tuberculous paravertebral abscess The abscess (red) infiltrates all columns of the spine, eroding the vertebral body leading to anterior collapse into kyphosis.

Measure	Intervention
Host	Maximize health, e.g., improve nutrition Minimize risk, e.g., treat pre-existing infection such as urinary tract
Skin	Clean: chlorhexidine, bleach Remove hair with depilatory agent (not razor)
Nose	Topical mupirocin
Antibiotics	Intravenous administration within 1 hr. before operation Redose during operation Antibiotic powder in wound Stop within 24 h after operation
Operating room	Heat to maintain patient normothermia Limit traffic to essential personnel Dedicated attire Close doors
Skin	Chlorhexidine preparation Do not use adhesive drapes
Instruments	Wipe and keep dry
Suction	Clamp when not in use Change the tip
Gloves	Change regularly
Dressing	Impervious Careful technique for postoperative change
Drain	Remove within 24 h
Dental prophylaxis	No consensus

A Measures influencing surgical site infection These may be divided into before (*gray*), at (*blue*), and after (*green*) operation.

Surgical Site Infection

Surgical site infection (SSI) represents nearly 1/5 of all hospital-acquired infections, second to urinary tract infection. It increases morbidity and mortality: national data show a 3% increase in death due to SSI. It deteriorates outcomes: for example, nonunion hurts and impedes function, threatens implant stability, and ultimately requires revision and reconstruction. It increases cost, including further testing, antibiotics, repeat operation, and prolonged length of stay in hospital (mean 1 week).

Sources of SSI include the physical environment, such as personnel, operating room, and equipment. The host brings normal cutaneous flora (nearly half of cases are due to *Staphylococcus aureus*) and may be compromised and colonized, such as in neuromuscular disease.

Several measures may be taken to reduce SSI [A]. Neuromuscular patients undergo preoperative assessment for health status and risk of infection, including laboratory analysis such as serum transferrin and urinalysis. They are managed accordingly, such as referral to a general surgeon for gastrostomy tube placement, before undergoing major operation. A bleach bath (1/2 cup, 20 minutes) is an effective chemical decontaminant, in particular to reduce MRSA, and does not risk iatrogenic resistance.

Antibiotics are most effective around the time of operation: practices that prolong postoperative use, for example, for the duration of wound drainage, may increase infection by selecting for resistant organisms. Consider earlier administration of antibiotics when a tourniquet is planned. Readminister in operation according to the half-life of the antibiotic.

The room where an operation takes place no longer can be regarded as a “theater,” but as a place with strict and consistent controls. Wear clothing dedicated to the operating room: change scrubs between cases, and keep civilian clothes, bags, and other paraphernalia out. Warm the operating room: patient hypothermia is associated with increased infection. The most effective skin preparation is chlorhexidine: it has the same bactericidal properties as alcohol (both better than iodine) but lasts longer. Adhesive drapes may trap blood and other contaminants as they inevitably lift off the skin during long procedures, thereby increasing SSI. The instrument bath is a culture broth: dilute in a chemical bacteriocidal agent such as hydrogen peroxide or bleach, or wipe and keep instruments dry. Do not suck continually: minimize how much of the room air is circulated into the wound. Consider simple measures such as regularly changing sucker tip and outer pair of gloves, which are breached more frequently than realized. Irrigate the wound multiple times during long procedures, and use irrigant that is opened only when needed for this indication.

Apply an impervious dressing. Change it after 48 hours methodically: wear a gown and sterile gloves, replace soiled gauze and adhesive strips, clean the skin with an antiseptic solution, do not touch the wound edges. Avoid prolonged wound drainage: colonization provides a route for exogenous bacteria to access the wound. Administration of prophylactic antibiotics for dental care or other invasive procedures lacks consensus or consistent national treatment recommendations.

- Abernethy LJ, Lee YC, Cole WG. Ultrasound localization of subperiosteal abscesses in children with late-acute osteomyelitis. *J. Pediatr. Orthop.* 13(6):766–768, 1993.
- Appel M, Pauleto AC, Cunha LA. Osteochondral sequelae of meningococemia: radiographic aspects. *J. Pediatr. Orthop.* 22(4):511–516, 2002.
- Aroojis AJ, Johari AN. Epiphyseal separations after neonatal osteomyelitis and septic arthritis. *J. Pediatr. Orthop.* 20(4):544–549, 2000.
- Belthur MV, Birchansky SB, Verdugo AA, Mason EO Jr, Hulten KG, Kaplan SL, Smith EO, Phillips WA, Weinberg J. Pathologic fractures in children with acute *Staphylococcus aureus* osteomyelitis. *J. Bone Joint Surg.* 94(1)-A:34–42, 2012.
- Berger E, Saunders N, Wang L, Friedman JN. Sickle cell disease in children: differentiating osteomyelitis from vaso-occlusive crisis. *Arch. Pediatr. Adolesc. Med.* 163(3):251–255, 2009.
- Bickels J, Ben-Sira L, Kessler A, Weintraub S. Primary pyomyositis. *J. Bone Joint Surg.* 84(12)-A:2277–2286, 2002.
- Bos CF, Mol LJ, Obermann WR, Tjin a Ton ER. Late sequelae of neonatal septic arthritis of the shoulder. *J. Bone Joint Surg.* 80(4)-B:645–650, 1998.
- Brodie BC. An account of some cases of chronic abscess of the tibia. *Med. Chir. Trans.* 17:239–249, 1832.
- Brook I. Microbiology and management of infectious gangrene in children. *J. Pediatr. Orthop.* 24(5):587–592, 2004.
- Canavese F, Krajchich JJ, LaFleur BJ. Orthopaedic sequelae of childhood meningococemia: management considerations and outcome. *J. Bone Joint Surg.* 92(12)-A:2196–2203, 2010.
- Cavalier R, Herman MJ, Pizzutillo PD, Geller E. Ultrasound-guided aspiration of the hip in children: a new technique. *Clin. Orthop.* 415:244–247, 2003.
- Ceroni D, Cherkaoui A, Combescure C, François P, Kaelin A, Schrenzel J. Differentiating osteoarticular infections caused by *Kingella kingae* from those due to typical pathogens in young children. *Pediatr. Infect. Dis. J.* 30:906–909, 2011.
- Chambers JB, Forsythe DA, Bertrand SL, Iwinski HJ, Steflik DE. Retrospective review of osteoarticular infections in a pediatric sickle cell age group. *J. Pediatr. Orthop.* 20(5):682–685, 2000.
- Choi IH, Pizzutillo PD, Bowen JR, Dragann R, Malhis T. Sequelae and reconstruction after septic arthritis of the hip in infants. *J. Bone Joint Surg.* 72(8)-A:1150–1165, 1990.
- Dartnell J, Ramachandran M, Katchburian M. Haematogenous acute and subacute paediatric osteomyelitis: a systematic review of the literature. *J. Bone Joint Surg.* 94(5)-B:584–595, 2012.
- Duffy CM, Lam PY, Ditchfield M, Allen R, Graham HK. Chronic recurrent multifocal osteomyelitis: review of orthopaedic complications at maturity. *J. Pediatr. Orthop.* 22(4):501–505, 2002.
- Ezra E, Cohen N, Segev E, Hayek S, Lokiec F, Keret D, Wientroub S. Primary subacute epiphyseal osteomyelitis: role of conservative treatment. *J. Pediatr. Orthop.* 22(3):333–337, 2002.
- Garron E, Viehweger E, Launay F, Guillaume JM, Jouve JL, Bollini G. Nontuberculous spondylodiscitis in children. *J. Pediatr. Orthop.* 22(3):321–328, 2002.
- Giedion A, Holthusen W, Masel LF, Vischer D. Subacute and chronic ‘symmetrical’ osteomyelitis. *Ann. Radiol.* 15(3):329–342, 1972.
- Girschick HJ, Zimmer C, Klaus G, Darge K, Dick A, Morbach H. Chronic recurrent multifocal osteomyelitis: what is it and how should it be treated? *Nat. Clin. Pract. Rheum.* 3(12):733–738, 2007.
- Gram HC. Über die isolierte Färbung der Schizomyceten in Schnitt- und Trockenpräparaten. *Fortschr. Med.* 2: 185–189, 1884.
- Grimes J, Carpenter C, Reinker K. Toxic shock syndrome as a complication of orthopedic surgery. *J. Pediatr. Orthop.* 15(5):666–671, 1995.
- Gristina AG, Shibata Y, Giridhar G, Kreger A, Myrvik QN. The glycocalyx, biofilm, microbes, and resistant infection. *Semin. Arthroplasty* 5(4):160–170, 1994.
- Grogan DP, Love SM, Ogden JA, Millar EA, Johnson LO. Chondro-osseous growth abnormalities after meningococemia. A clinical and histopathological study. *J. Bone Joint Surg.* 71(6)-A:920–928, 1989.
- Hammond PJ, Macnicol MF. Osteomyelitis of the pelvis and proximal femur: diagnostic difficulties. *J. Pediatr. Orthop.* 10(2)-B:113–119, 2001.
- Harris NH, Kirkaldy-Willis WH. Primary subacute pyogenic osteomyelitis. *J. Bone Joint Surg.* 47-B:526–532, 1965.
- Hodgson AR, Stock FE, Fang HS, Ong GB. Anterior spinal fusion. The operative approach and pathological findings in 412 patients with Pott’s disease of the spine. *Br. J. Surg.* 48:172–178, 1960.
- Jaberi FM, Shahcheraghi GH, Ahadzadeh M. Short-term intravenous antibiotic treatment of acute hematogenous bone and joint infection in children: a prospective randomized trial. *J. Pediatr. Orthop.* 22(3):317–320, 2002.
- Jaramillo D. Infection: musculoskeletal. *Pediatr. Radiol.* 41(Suppl 1):S127–134, 2011.
- Jones HW, Beckles VL, Akinola B, Stevenson AJ, Harrison WJ. Chronic haematogenous osteomyelitis in children: an unsolved problem. *J. Bone Joint Surg.* 93(8)-B: 1005–1010, 2011.
- Jung ST, Rowe SM, Moon ES, Song EK, Yoon TR, Seo HY. Significance of laboratory and radiologic findings for differentiating between septic arthritis and transient synovitis of the hip. *J. Pediatr. Orthop.* 23(3):368–372, 2003.
- Khachatourians AG, Patzakis MJ, Roidis N, Holtom PD. Laboratory monitoring in pediatric acute osteomyelitis and septic arthritis. *Clin. Orthop.* 409:186–194, 2003.
- Kim HK, Alman B, Cole WG. A shortened course of parenteral antibiotic therapy in the management of acute septic arthritis of the hip. *J. Pediatr. Orthop.* 20(1):44–47, 2000.
- Kocher MS, Mandiga R, Zurakowski D, Barnewolt C, Kasser JR. Validation of a clinical prediction rule for the differentiation between septic arthritis and transient synovitis of the hip in children. *J. Bone Joint Surg.* 86(8)-A:1629–1635, 2004.
- Konyves A, Deo SD, Murray JR, Mandalia VI, Von Arx OA, Troughton AH. Septic arthritis of the elbow after chickenpox. *J. Pediatr. Orthop.* 13(2):114–117, 2004.
- Kucukkaya M, Kabukuoglu Y, Tezer M, Kuzgun U. Management of childhood chronic tibial osteomyelitis with the Ilizarov method. *J. Pediatr. Orthop.* 22(5):632–637, 2002.
- Lowden CM, Walsh SJ. Acute staphylococcal osteomyelitis of the clavicle. *J. Pediatr. Orthop.* 17(4):467–469, 1997.
- Luhmann SJ, Jones A, Schootman M, Gordon JE, Schoenecker PL, Luhmann JD. Differentiation between septic arthritis and transient synovitis of the hip in children with clinical prediction algorithms. *J. Bone Joint Surg.* 86(5)-A:956–962, 2004.
- Lundy DW, Kehl DK. Increasing prevalence of *Kingella kingae* in osteoarticular infections in young children. *J. Pediatr. Orthop.* 18(2):262–267, 1998.
- Mantadakis E, Plessa E, Vouloumanou EK, Michailidis L, Chatzimichael A, Falagas ME. Deep venous thrombosis in children with musculoskeletal infections: the clinical evidence. *Int. J. Infect. Dis.* 16(4):e236–243, 2012.
- Maraq NF, Gomez MM, Rathore MH. Outpatient parenteral antimicrobial therapy in osteoarticular infections in children. *J. Pediatr. Orthop.* 22(4):506–510, 2002.
- Morrison MJ, Herman MJ. Hip septic arthritis and other pediatric musculoskeletal infections in the era of methicillin-resistant *Staphylococcus aureus*. *Instr. Course Lect.* 62:405–414, 2013.
- Odio CM, Ramirez T, Arias G, AbdelNour A, Hidalgo I, Herrera ML, Bolan W, Alpizar J, Alvarez P. Double blind, randomized, placebo-controlled study of dexamethasone therapy for hematogenous septic arthritis in children. *Pediatr. Infect. Dis. J.* 22(10):883–888, 2003.
- Orlicek SL, Abramson JS, Woods CR, Givner LB. Obturator internus muscle abscess in children. *J. Pediatr. Orthop.* 21(6):744–748, 2001.
- Peltola H, Unkila-Kallio L, Kallio MJ. Simplified treatment of acute staphylococcal osteomyelitis of childhood. The Finnish Study Group. *Pediatrics* 99(6):846–850, 1997.
- Perlman MH, Patzakis MJ, Kumar PJ, Holtom P. The incidence of joint involvement with adjacent osteomyelitis in pediatric patients. *J. Pediatr. Orthop.* 20(1):40–43, 2000.
- Piehl FC, Davis RJ, Prugh SI. Osteomyelitis in sickle cell disease. *J. Pediatr. Orthop.* 13(2):225–227, 1993.
- Pott P. The chirurgical works of Percivall Pott, F.R.S., surgeon to St. Bartholomew’s Hospital, a new edition, with his last corrections. 1808. *Clin. Orthop.* 4–10, 2002.
- Rasool MN. Osseous manifestations of tuberculosis in children. *J. Pediatr. Orthop.* 21(6):749–755, 2001.
- Riise ØR, Kirkhus E, Handeland KS, Flato B, Reiseter T, Cvancarova M, Nakstad B, Watne KO. Childhood osteomyelitis-incidence and differentiation from other acute onset musculoskeletal features in a population-based study. *BMC Pediatr.* 8(45):2431–2438, 2008.
- Roderick MR, Ramanan AV. Chronic recurrent multifocal osteomyelitis. *Adv. Exp. Med. Biol.* 764:99–107, 2013.
- Rose CD, Fawcett PT, Eppes SC, Klein JD, Gibney K, Doughty RA. Pediatric Lyme arthritis: clinical spectrum and outcome. *J. Pediatr. Orthop.* 14(2):238–241, 1994.
- Segev E, Hayek S, Lokiec F, Ezra E, Issakov J, Wientroub S. Primary chronic sclerosing (Garre’s) osteomyelitis in children. *J. Pediatr. Orthop.* 10(4)-B:360–364, 2001.
- Shallcross LJ, Fragaszy E, Johnson AM, Hayward AC. The role of the Panton-Valentine leucocidin toxin in staphylococcal disease: a systematic review and meta-analysis. *Lancet Infect. Dis.* 13(1):43–54, 2013.
- Song J, Letts M, Monson R. Differentiation of psoas muscle abscess from septic arthritis of the hip in children. *Clin. Orthop.* 391:258–265, 2001.
- Spiegel DA, Meyer JS, Dormans JP, Flynn JM, Drummond DS. Pyomyositis in children and adolescents: report of 12 cases and review of the literature. *J. Pediatr. Orthop.* 19(2):143–150, 1999.
- Stumpe KD, Strobel K. Osteomyelitis and arthritis. *Semin. Nucl. Med.* 39(1):27–35, 2009.
- Tong CW, Griffith JF, Lam TP, Cheng JC. The conservative management of acute pyogenic iliopsoas abscess in children. *J. Bone Joint Surg.* 80(1)-B:83–85, 1998.
- Tudisco C, Farsetti P, Gatti S, Ippolito E. Influence of chronic osteomyelitis on skeletal growth: analysis at maturity of 26 cases affected during childhood. *J. Pediatr. Orthop.* 11:358–363, 1991.
- Unkila-Kallio L, Kallio MJ, Peltola H. The usefulness of C-reactive protein levels in the identification of concurrent septic arthritis in children who have acute hematogenous osteomyelitis. A comparison with the usefulness of the erythrocyte sedimentation rate and the white blood-cell count. *J. Bone Joint Surg.* 76(6)-A:848–853, 1994.
- Willis AA, Widmann RF, Flynn JM, Green DW, Onel KB. Lyme arthritis presenting as acute septic arthritis in children. *J. Pediatr. Orthop.* 23(1):114–118, 2003.
- Wilson B. Necrotising fasciitis. *Am. Surg.* 18(4): 416–431, 1952.
- Yokoe DS, Mermel LA, Anderson DJ, Arias KM, Burstin H, Calfee DP, Coffin SE, Dubberke ER, Fraser V, Gerding DN, Griffin FA, Gross P, Kaye KS, Klompas M, Lo E, Marshall J, Nicolle L, Pegues DA, Perl TM, Podgorny K, Saint S, Salgado CD, Weinstein RA, Wise R, Classen D. A compendium of strategies to prevent healthcare-associated infections in acute care hospital. *Infect. Control Hosp. Epidemiol.* 29:S12–S21, 2008.

