

UPPER LIMB

Development	7	Constriction	13
Evaluation	8	Amniotic Band Syndrome	13
Observation	8	Generalized Syndromes	13
Physical Examination	8	Arthrogryposis	13
Deficiency	8	Cerebral Palsy	14
Symbrachydactyly	8	Wrist	15
Preaxial Deficiency	9	Kienböck Disease	15
Postaxial Deficiency	10	Madelung Deformity	15
Phocomelia	10	Forearm	16
Failure of Differentiation	10	Congenital Dislocation of the Head of the Radius	16
Syndactyly	10	Congenital Radioulnar Synostosis	16
Symphalangism	10	Shoulder	17
Camptodactyly	10	Sprengel Anomaly	17
Trigger Thumb	11	Congenital Pseudarthrosis of the Clavicle	18
Clinodactyly	11	Brachial Plexus Birth Injury	18
Delta Phalanx	11	Hand Infection	20
Kirner Deformity	11	Cellulitis	20
Duplication	12	Paronychia	20
Polydactyly	12	Felon	20
Overgrowth	12	Herpetic Whitlow	20
Macroductyly	12	Flexor Tenosynovitis	20
Undergrowth	12	Deep Space Infection	20
Thumb Hypo-/a-plasia	12		
Poland Syndrome	13		

The upper limb positions the hand for bimanual activity within the field of vision. For many anomalies of the upper limb, normal function and appearance are unattainable. Management focuses on the preservation or enhancement of motion to meet activities of daily living, at a minimum access to the face and perineum. Goals for the dominant hand include pinch and fine motor function. Goals for the nondominant hand include grasp and release to stabilize objects for the dominant hand. The critical nature of sensibility and mobility in the hand influences surgical incisions and dissection.

DEVELOPMENT

Morphologic description of the embryo provides a gross understanding of development [A]. Lodged within this is an orderly, sequential expression of genes known as a developmental cascade, which is under the control of HOXD genes expressed in successive overlapping fields. The apical ectodermal ridge releases fibroblast growth factors that induce the zone of polarizing activity, located in the posterior mesenchyme of the bud, to secrete sonic hedgehog to establish anteroposterior (radioulnar) polarity in the developing limb. Dorsal ectodermal expression of the WNT7A, which induces mesodermal LMX1B, and suppression of WNT7A in the ventral ectoderm by EN1 determine the dorsoventral axis of the limb.

Anomalies may be classified according to abnormality of development [B]. Upper limb anomalies are features of several syndromes [C].

Week	Development
3	The upper limb bud originates as a core of mesenchyme draped by ectoderm from Wolff crest opposite the 5 lowest cervical vertebrae on the ventrolateral surface of the embryo. The leading edge is thickened into apical ectodermal ridge, which directs longitudinal limb growth. The limb bud at this stage is perfused by the marginal sinus.
4	The hand plate is visible.
5	Mesenchymal cells condense into blastemas, which form the cartilage models of the bones of the limb. Nerves enter from the spinal cord.
6	The ulnar artery branches from the central brachial artery to reach the hand.
7	The upper limb rotates 90 degrees around a longitudinal axis, "before" which are the thumb and radius (Latin <i>pre-</i>), to turn the apex of the elbow posterior and determine its dermatomal pattern. Endochondral ossification and joint cavitation begin. The mesenchyme differentiates into dorsal and ventral muscles, which represent the extensors and flexors.
8	The apical ectodermal ridge fragments as the digits begin to separate by apoptosis.

A Embryonic development of the upper limb Most anomalies of the upper limb form during the embryonic period.

8 Upper Limb / Deficiency

Type	Example
Failure of formation	Limb deficiency
Failure of differentiation	Syndactyly, camptodactyly, trigger thumb, clinodactyly, delta phalanx
Duplication	Polydactyly
Overgrowth	Macroductyly
Undergrowth	Thumb hypoplasia, Poland
Constriction	Amniotic band syndrome
Generalized skeletal abnormalities	Syndromes

B Classification of anomalies This may be used as an organizing framework. One-third of hand anomalies are bilateral. One-fourth of children with hand anomalies have a nonhand anomaly, most often in the lower limb. One-sixth of children have an affected relative.

Deficiency
Cornelia de Lange Holt-Oram Poland Split hand/split foot Thrombocytopenia-absent radius VACTERL
Failure of Differentiation
Apert Arthrogryposis Oculodigital Pfeiffer
Duplication
Orofacial digital syndrome Ellis-van Creveld Rubinstein-Taybi
Undergrowth
Brachydactyly A-E Hand-Foot-Genital Oto-palato-digital

C Syndromes characterized by upper limb anomalies Cf. Syndromes chapter.

EVALUATION

Observation

Hand function progresses in an orderly fashion [D]. The function of each upper limb is more independent than that of the lower limbs; thus, a short arm causes less functional difficulty than a short leg. Look for deformity, asymmetry, anomaly. What is the resting position? Watch how the child uses the upper limb—toys are helpful. Does the child have bimanual function? Does the child guard? Does the child express hand dominance? Determine functional limitations, such as bringing the hand to the mouth. What is the muscular tone? Are there contractures or spasticity? Ask about medical comorbidities that may be features of a generalized condition.

Physical Examination

A detailed motor and sensory assessment may not be possible in a young child. Ask the parents. Perform gross tests, such as distinguishing textures. Check passive and active motion. Look for signs of laxity, including elbow and metacarpophalangeal hyperextension, and thumb on volar forearm. Examine the entire child for other anomalies that may suggest a syndrome. Bring the child back for a second evaluation.

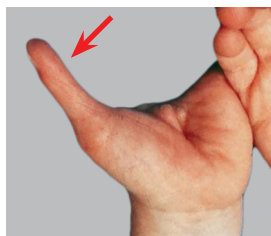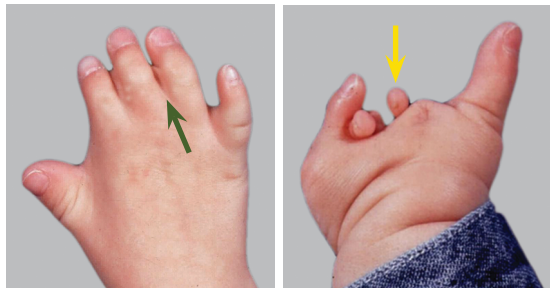DEFICIENCY

Distinguish congenital from acquired deficiency [E]. Failure of formation may be transverse or longitudinal [F]. Symbrachydactyly is a transverse deficiency. Examples of longitudinal deficiency is radial clubhand, of central is split hand, and of postaxial is ulnar clubhand, and of intercalary is phocomelia.

Symbrachydactyly

Cause may be disruption of vascular ingrowth during limb development. Digits are “short” (Greek βραχυς) and webbed “together” (Greek συν-). Mildest is short, webbed but well-formed fingers. Cleft hand is characterized by absence of central digits [G]. Monodactyly refers to loss of fingers, marked by remnants or “nubbins,” with preservation of the thumb. Digital remnants lack a nail remnant, distinguishing this from constriction deficit. Peromelia (Greek πηρος: “disabled, incapacitated”) is most severe, with absence of all digits.

Treatment depends upon what remains. Metacarpal spaces may be created for basic pinch. A hand plate may be fitted to a mobile wrist. Free vascularized toe transfer has variable success.



G Types of symbrachydactyly Digits may be short, webbed, and functional (*green*). Central deficiency, with digital remnants, characterizes cleft hand (*yellow*). The thumb is normal in monodactyly (*red*).

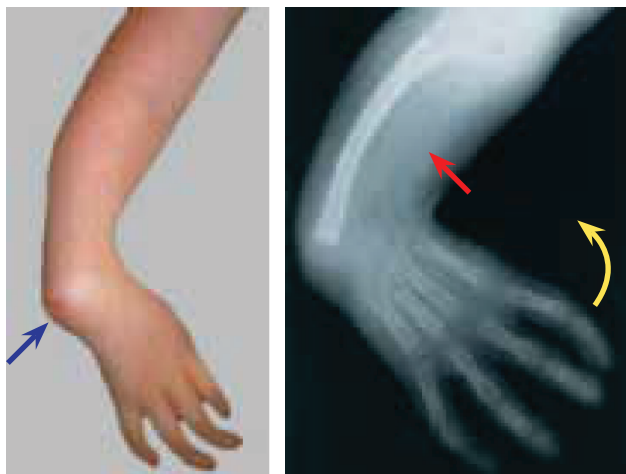Preaxial Deficiency

There are six types.

- N. Hypoplasia or absence of thumb. Wrist and radius are normal.
- 0. Hypoplasia or absence of thumb. Carpal anomaly. Normal distal radius. Proximal radius may be normal, dislocated, or synostosed with the ulna.
- 1. As 0, except distal radius shortening >2 mm.
- 2. Hypoplasia or absence of thumb. Carpal anomaly. Distal and proximal radial hypoplasia.
- 3. As 2, except absence of distal epiphysis of radius.
- 4. Hypoplasia or absence of thumb. Carpal anomaly. Absent radius [H].

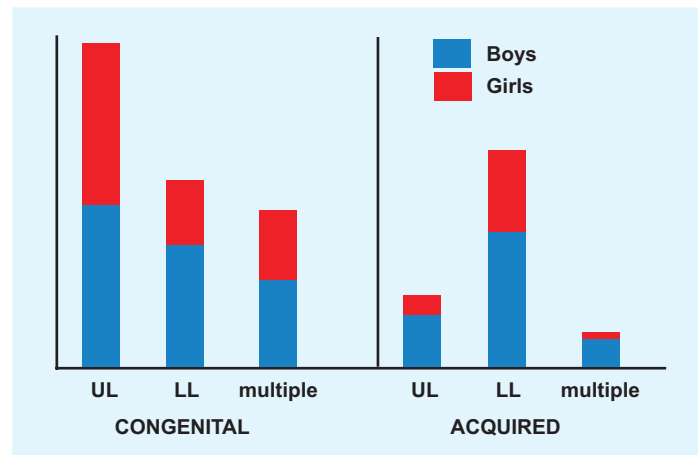
The radial nerve and artery follow bone deficiency. Tethering by the radial anlage may dislocate the ulna. Half of cases are bilateral, most of which are associated with a syndrome, for example, Holt-Oram, thrombocytopenia-absent radius, and VACTERL.

Soft tissue stretching may be achieved by serial splinting or casting. Pollicization of the index substitutes for nonfunctional thumb. Centralization or radialization of the ulna supports the hand when there is significant radial hypoplasia. This is contraindicated in elbow stiffness, which may prevent accessing the mouth by a straightened hand and wrist, which previously were more functional in the deviated and shortened position.

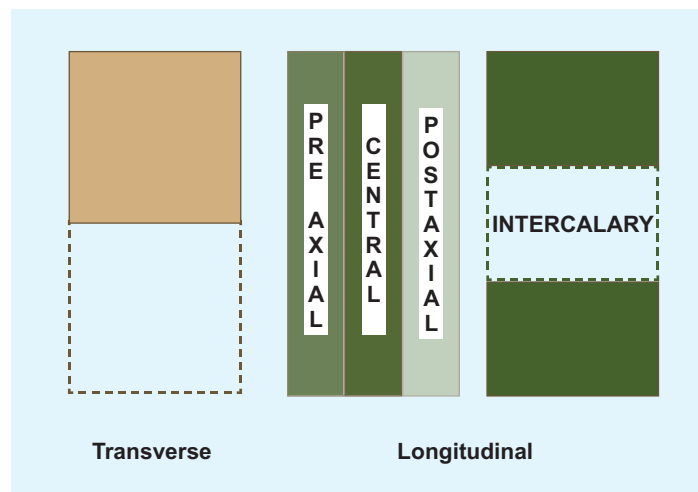


Age		Function
1	M	Clenches hand
2	O	Opens hand
3	N	Holds objects
6	T	Independent sitting Bimanual function
9	H	Early finger pinch
12	S	Prehension
1.5	Y	Piles blocks
2	E	Fine motor function, e.g., buttons clothing
3	A	Hand dominance
4	R	Throw a ball
5	S	Catch a ball

D Developmental milestones for the upper limb.



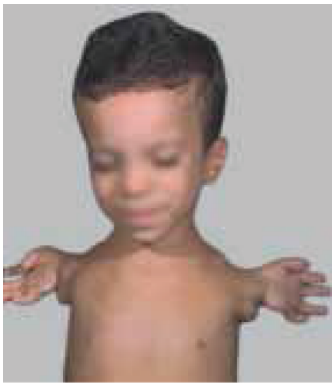E Distribution of paediatric amputees Upper limb-acquired deficiency is rarer than congenital. UL: upper limb; LL: lower limb.



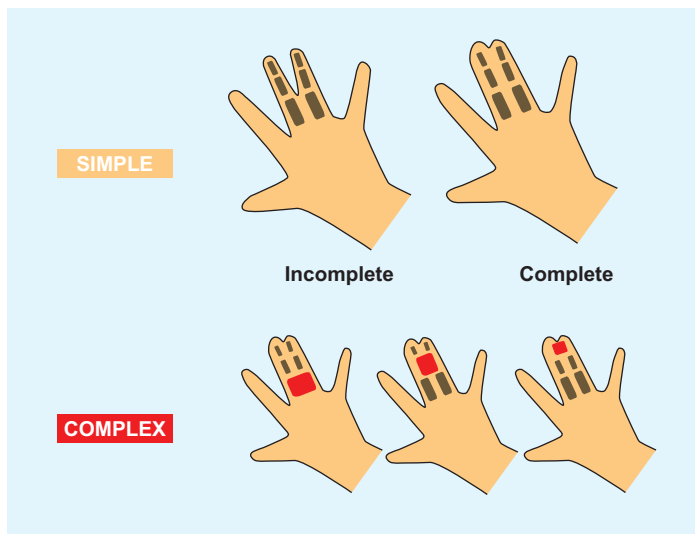
F Classification of failure of formation.

H Radial dysplasia Absence of radius (*red*) produces a radial clubhand (*yellow*) and a prominent end of ulna (*blue*).

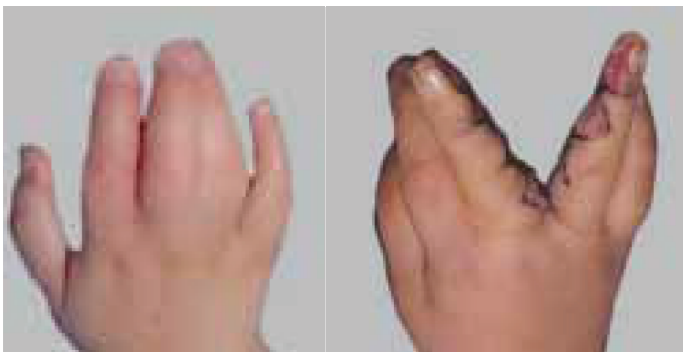10 Upper Limb / Failure of Differentiation



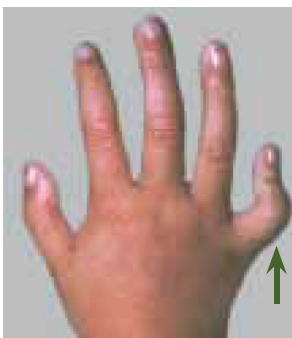I Phocomelia Severe longitudinal humeral and ulnar deficiency makes the upper limbs resemble the flippers of a seal.



A Classification of syndactyly This is an anatomic classification. Simple involves only skin. This fusion may be incomplete, leaving variable parts of the digits free, or complete. Complex involves bone, which may be fused at different levels.



B Separation of syndactyly The completely joined middle and ring fingers were separated by zigzag incisions.



C Camptodactyly Flexion of the proximal interphalangeal joint of the smallest finger (*green*) is a sagittal plane deformity (Greek *καμπτος*: “bent, crooked”).

Postaxial Deficiency

Ulnar deficiency differs from radial deficiency in being 1/10 as common, in showing autosomal dominant inheritance, in rarely being associated with a syndrome, and in being typically unilateral. In addition, the consequences to the hand are milder, whereas the elbow is more severely affected. There are four types.

- I. Hypoplasia of the ulna, with preservation of proximal distal physis and minimal deformity.
- II. Absent distal ulna, with radial bowing. This is most common.
- III. Complete absence of ulna.
- IV. Absent ulna with humeroradial synostosis.

Thumb and carpal anomalies occur variably. Excise the ulnar anlage and perform a corrective radial osteotomy for ulnar deviation of the wrist. Fuse the proximal ulna to radius to create a single bone forearm: this stabilizes the head of the radius, thereby improving elbow function, and reduces bowing of the forearm.

Phocomelia

The appellation describes resemblance of the severely shortened limb to that of a “seal” (Greek *φοκη*). An epidemic in Europe developed after thalidomide became an over-the-counter drug in Germany (1957) for nausea in pregnancy. It is rare today and may be due to true intercalary deficiency or severe axial deficiency [1].

FAILURE OF DIFFERENTIATION

Syndactyly

The upper limb develops as a zeugopod (arm), then stylopod (forearm), and then autopod (hand). This is associated with sequential expression of HOXD9 and HOXD10 (zeugopod) followed by HOXD11 and HOXD12 (stylopod), which in turn give way to HOXD13 (autopod). Mutation in HOXD13 on 2q31.1 results in failure of programmed interdigital apoptosis and syndactyly.

Syndactyly has been classified according to affected tissue and extent of joining [A]. When osseous abnormalities are more than side-to-side fusion, such as accessory bones, it is referred to as “complicated.” Syndactyly is most common in the third web, by contrast with the second web in the foot. It may be associated with syndromes such as Apert.

There are several principles of surgical separation [B].

- Full-thickness, local, dorsal, or volar skin flaps to avoid contracture and “web creep.”
- Zigzag incisions to avoid longitudinal contracture.
- Operate on only one side of a digit, to avoid vascular insufficiency.
- Correct underlying osseous deformity.
- Relaxed closure to avoid vascular constriction.

Symphalangism

This refers to failure of cavitation of the interphalangeal joints, usually of the ulnar digits. Three types have been distinguished:

- Affected digits is normal in length.
- Brachysymphalangism, in which the digit is “short” (Greek *βραχυς*).
- Symphalangism associated with syndromes.

Digits are gracile and lack cutaneous creases. There is loss of motion and narrowing of the joint on röntgenogramme, to which the cartilaginous bridge is invisible. Release, for example, by capsulectomy, has limited success. Arthrodesis is unnecessary. Children adapt to the stiffness.

Camptodactyly

This refers to contracture of the finger in the sagittal plane [C]. Smallest finger and proximal interphalangeal joint are most affected. In a subset of patients, the condition is genetic, linked to 3q11.2-q13.12. This also is known as streblomicrodactyly (Greek *στρεβλος*: “bent, crooked”). There are three types of camptodactyly.

- I. Congenital
- II. Progressive, presenting in the second decade
- III. Affecting multiple digits and associated with other conditions, in particular arthrogryposis

Intrinsic imbalance due to muscle anomaly, for example, errant lumbrical insertion or hypoplastic tight flexor digitorum superficialis, produces secondary soft tissue contracture and osseous deformity, such as condylar blunting.

Initial management is stretching and splinting. If this is unsuccessful, release anomalous muscle insertion or transfer flexor digitorum superficialis to the extensor retinaculum when the deformity is flexible. For rigid deformity, add wide capsular release and consider osteotomy.

Trigger Thumb

The flexor pollicis longus develops a nodular swelling (Notta) that restricts and ultimately obstructs excursion at the entrance of the tendon sheath. This is not congenital. Cause is unknown. One-fourth are bilateral.

The thumb may click and hurt with forcible interphalangeal extension, as the nodule squeezes abruptly past the first annular pulley, or it may be held in fixed flexion. The mobile nodule is palpable as the interphalangeal joint is manipulated. To compensate for lack of interphalangeal extension, the metacarpophalangeal joint may become hypermobile, extending abnormally to better position the pulp of the thumb during opening of the hand.

Observe trigger thumb during the 1st year of life, as most resolve spontaneously. Resolution is unlikely after the 2nd year, which is an indication for operative section of the first annular pulley. Demonstrate full interphalangeal extension to confirm acceptable release. The surgical site may be traversed by the radial digital nerve [D], which may be endangered by a percutaneous method. By 3 years of age, development of diffuse contracture at a flexed interphalangeal may limit surgical result. For patients with hyperextension of the metacarpophalangeal > 60 degrees, some advocate concomitant advancement of the volar plate.

Clinodactyly

In contrast with camptodactyly, the finger in clinodactyly (Greek κλινη: “that upon which one *reclines*, a couch,” whence “*clinic*”) is deformed in the coronal plane [E]. Most affected is the smallest finger. This deformity tends to be bilateral and associated with syndromes, for example, 80% of children with trisomy 21. It is classified.

- Simple, due to osseous deformity, or complex, which has associated soft tissue contracture.
- Uncomplicated, when the deformity is < 45 degrees, or complicated when > 45 degrees associated with rotation.

Because of the plane of deformity, this leads to dysfunction when severe. For significant digital overlap, perform an opening wedge osteotomy rather than closing, which may relax the extensor to produce a mallet finger.

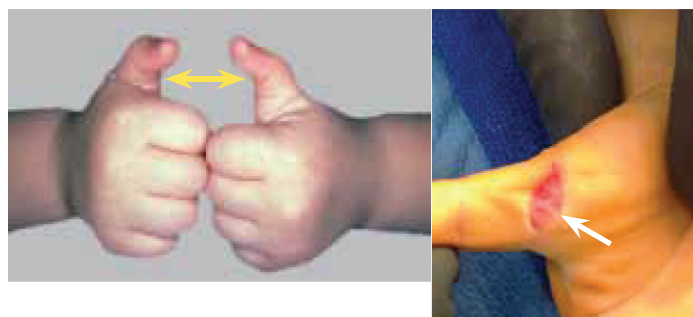Delta Phalanx

The name describes the shape of a triangular bone, like the Greek letter delta (Δ), which on its short side is flanked by a C-shaped bracket epiphysis (*cf.* Foot chapter). Most affected are the middle phalanx of the longest finger [F] and the thumb, where it may form a triphalangeal thumb. The bone produces a coronal plane deformity.

Excise an accessory delta phalanx in triphalangeal thumb early, before secondary deformity sets in. Physiolysis with fat interposition is an effective detethering in the child who has enough growth remaining to overcome a deformity that is not severe. For severe deformity in the older child, opening osteotomy with bone graft is indicated.

Kirner Deformity

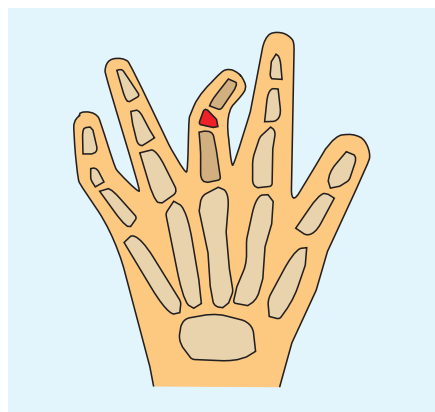
Progressive volad and radiad curving of the distal phalanx of the smallest finger [G]. Cause of this growth disturbance is unknown. It tends to be bilateral and affects girls more than boys toward the end of the first decade. It is characteristic in appearance, which is the principal problem it poses because it causes no disability. Phalangeal osteotomy at the end of growth is indicated rarely.



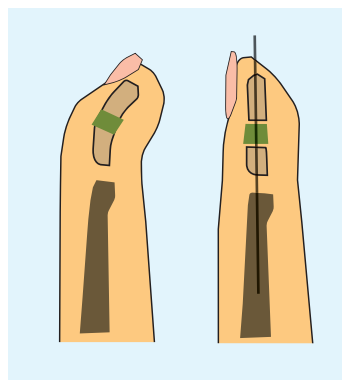
D Trigger thumb Both thumbs are stuck in interphalangeal flexion (yellow). A transverse incision in the metacarpophalangeal flexion crease becomes invisible after healing. The radial digital nerve may traverse the surgical site (white).



E Clinodactyly Coronal plane deformation of the smallest fingers (blue) is distinguished from camptodactyly, which occurs in the sagittal plane.



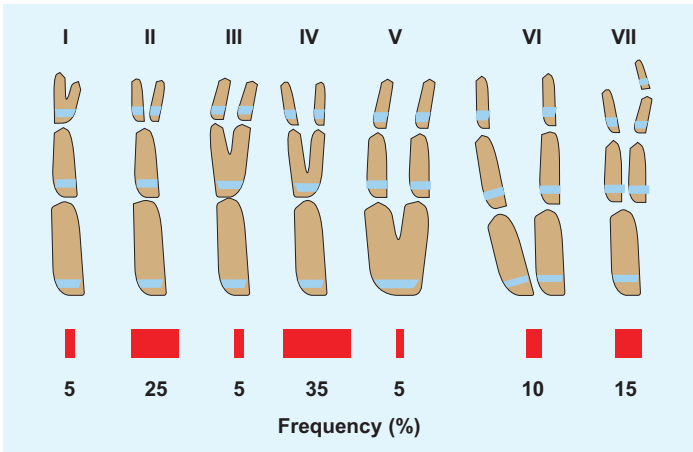
F Delta phalanx The triangular middle phalanx of the longest finger (red) is an osseous cause for digital deformity.



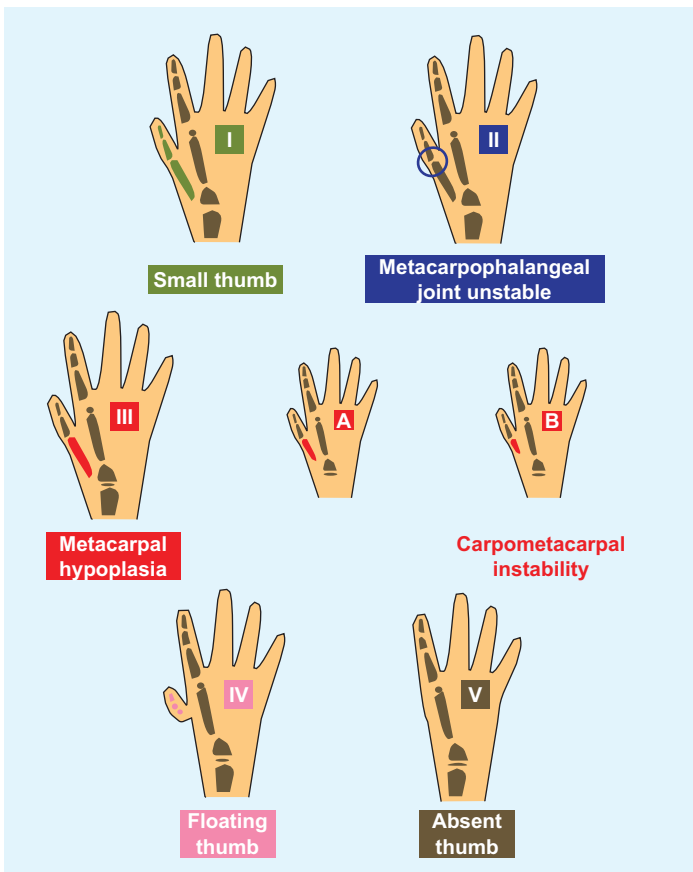
G Kirner deformity Correction by osteotomy.

	Preaxial	Central	Postaxial
Prevalence	Common	Rare	Common
Inheritance	Variable	Variable	Autosomal dominant
Ethnicity	Whites		Blacks 10 × Whites
Associated condition	Often	Syndactyly Foot anomaly	Rare
Surgical repair	Difficult	Complex	Simple

A Polydactyly Distinguishing features.



B Thumb polydactyly Classification according to osseous duplication. Type VII represents a triphalangeal thumb with or without duplication.



C Classification of thumb hypo-/a-plasia.

DUPLICATION

Polydactyly

This is the most common anomaly of the upper limb. It may be preaxial, central, or postaxial [A]. It may be subtyped as A: full digital development, and B: rudimentary or pedunculated digit. Central lesions often are polysyndactylies.

Thumb polydactyly has been classified according to osseous involvement [B]. While most are sporadic, type VII may be syndromic. A subset of triphalangeal thumb is caused by an autosomal dominant heterozygous mutation in a sonic hedgehog regulatory element (ZRS) that resides in intron 5 of the LMBR1 gene on 7q36.3.

For postaxial polydactyly, type B may be suture ligated or excised. Counsel family that the former, which is performed simply in the neonatal nursery, may be followed by a residual bump that does not interfere with function. For type A, reconstruct collateral ligament and hypothenar muscle attachments as indicated.

Principles of thumb polydactyly reconstruction include the following:

- Timing is influenced by the development of pinch, toward the end of the 1st year.
- Reconstruct the collateral ligament connected to the excised thumb.
- Transfer thenar muscles, for example, in type IV, opponens and abductor insert on radial digit while adductor inserts on ulnar digit.
- Perform chondroplasty of a widened metacarpal of metatarsal.
- Recognize pollex abductus, and release the abnormal connexion between flexor pollicis longus and extensor pollicis longus. This is one cause of postoperative angulation, which is the most common complication of excision of thumb polydactyly.

OVERGROWTH

Macroductyly

Overgrowth may be static, which remains proportionate as the child grows, or progressive, which is more common and characterized by growth acceleration. The longest finger is most affected. Half of cases involve more than one finger. There are four types.

- Associated with nerve territory-oriented lipofibromatosis. This is most common. Overgrowth is driven by a digital (single finger affected) or peripheral (more than one finger affected) nerve, which is enlarged, is tortuous, and has fibrofatty infiltration.
- Associated with neurofibromatosis. Overgrowth is neurotrophic.
- Associated with hyperostosis. There is no neural abnormality. The driver is primary bone overgrowth.
- Associated with hemihypertrophy.

Surgical management may be divided into three categories.

- Growth modulation. Timing of physiodesis is difficult. This addresses only length.
- Reduction. This may be of bone, by segmental excision, or of soft tissue, which risks neurovascular structures and stiffness.
- Amputation. This may be partial or of the ray. It may be performed in conjunction with digit or toe transfer.

Counsel the patient and family that multiple procedures may be necessary and that normal function is unrealistic.

UNDERGROWTH

Thumb Hypo-/a-plasia

This also may be considered within the spectrum of preaxial deficiency. It is classified according to severity [C].

- I. The thumb is small but otherwise muscles and joints are normal.
- II. Metacarpophalangeal joint is unstable. Thumb is adducted. The thenar muscles are underdeveloped.
- III. This is subtyped according to degree of metacarpophalangeal hypoplasia and presence of carpometacarpal instability (B and C).

Thenar muscles are absent. There is dysplasia of trapezium and scaphoid, as well as styloid process of radius.

- IV. The thumb, consisting of rudimentary phalanges, floats at the side of the hand, connected by its neurovascular pedicle. Thenar muscles are absent. There is dysplasia of trapezium and scaphoid, as well as styloid process of radius.
- V. Thumb is absent. This is most common.

Type I needs no treatment. Central to surgical decision making is the metacarpophalangeal joint. Reconstruction is possible when the joint is stable. An unstable joint is an indication for pollicization.

Poland Syndrome

This autosomal dominant disorder is characterized by unilateral chest hypoplasia, including unilateral hypoplasia or absence of pectoralis major muscle, most commonly the sternocostal head [D], as well as digital anomalies, including brachydactyly, oligodactyly, and syndactyly.

Other features include costal and vertebral anomalies, as well as absence of hypoplasia of shoulder muscles, including latissimus dorsi, serratus anterior muscle, and rotator cuff. It occurs on the right side in three-fourths of cases. Boys are affected thrice as often as girls. Most are sporadic, with a small subset demonstrating autosomal dominant inheritance.

The disorder may be regarded as part of the subclavian artery dysplasia complex, as evidenced by reports of dextrocardia in left-side cases (*cf.* Pseudarthrosis of the Clavicle).

A lower limb counterpart includes gluteal hypoplasia with brachysyndactyly of the toes.

Orthopaedic management resides in the hand. Plastic reconstruction of the chest may be necessary, in particular for breast asymmetry and nipple absence.

CONSTRICTION

Amniotic Band Syndrome

This is sporadic and may be associated with other anomalies, for example, clubfoot. Amniotic bands encircle the member perpendicular to the longitudinal axis, presenting as an anular soft tissue constriction [E]. Anatomy is normal proximal. More than 80% occur distal to the wrist. There are four types.

- I. Simple constriction ring without distal anomaly. Consider release of constriction ring.
- II. Distal swelling and hypoplasia. Excise constriction ring with local flaps.
- III. Distal syndactyly. Separate syndactyly.
- IV. Amputation. Reconstruction should be individualized, including bone lengthening, web deepening, and free vascularized toe transfer.

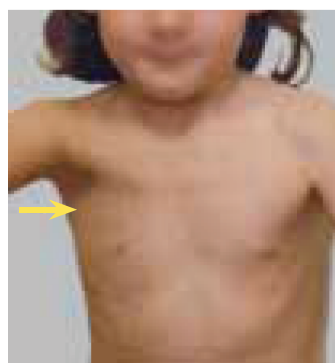
GENERALIZED SYNDROMES

Arthrogryposis

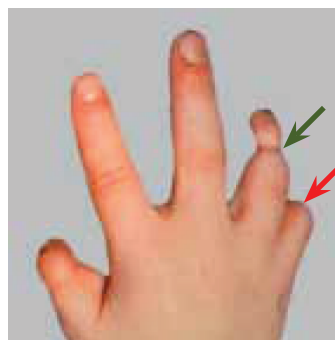Hypokinesia *in utero* results in muscle hypoplasia, joint stiffness, and deformity (*cf.* Syndromes chapter).

Evaluation The upper limb assumes a classic posture [A]. In the distal form of the disorder, the hand is principally affected, with relative sparing of the elbow and shoulder. There is minimal muscle action. Intelligence and sensation are normal. These factors significantly improve hand adaptation and surgical outcomes.

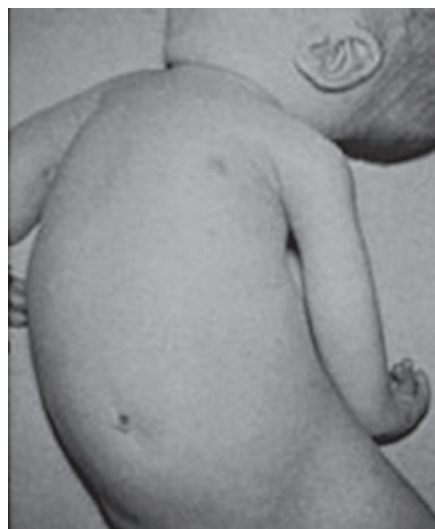Management Physical therapy for stretching and occupational therapy for adaptive training. Consider realignment, by soft tissue release or osteotomy, to improve functional position and not motion, of which any gain may be lost in the absence of muscle action. Lengthen biceps or triceps, but this will add to weakness. Consider supracondylar humeral osteotomy. If there is sufficient passive elbow motion, unilateral pectoralis major transfer may facilitate one hand reaching the mouth, while the other remains in extension to reach the perineum for independent care and to use an assistive ambulatory device.



D Poland syndrome The sternocostal head of right pectoralis major is absent.



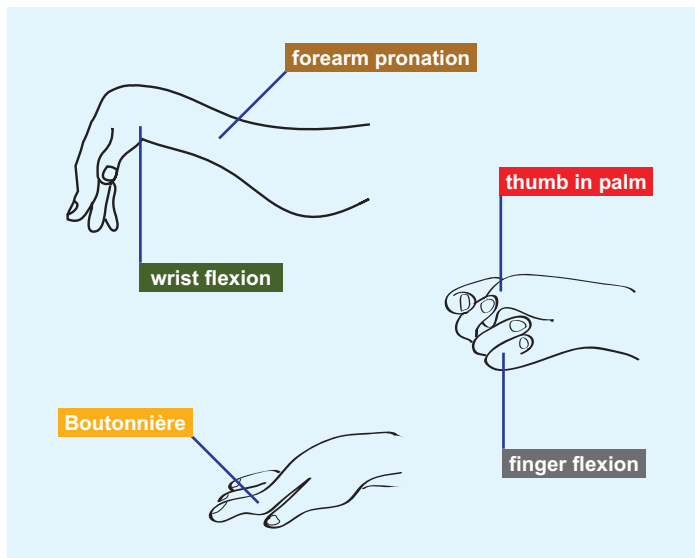
E Amniotic band syndrome There is distal hypoplasia (green) and amputation (red).



A Arthrogryposis The upper limb is held in a typical posture, including shoulder adduction and internal rotation, elbow extension, wrist flexion, and digital mild camptodactyly.

Level	Classification	Ability
0	No use	Not used
1	Passive help—poor	Uses limb to stabilize weight
2	Passive help—fair	Holds onto object placed in hand
3	Passive—good	Hold and stabilize object for use by other hand
4	Active help—poor	Weak grip
5	Active help—fair	Good grip
6	Active help—good	Manipulates object
7	Spontaneous use—limited	Performs bimanual function
8	Spontaneous use—complete	Use of hand independent of other hand

A House classification This is a functional assessment of hand use in cerebral palsy.



B Common hand deformities in cerebral palsy Deformities may be combined and vary in severity.

Level	Spasticity	Ability
1	Minimal	Full active extension of the fingers with wrist 0- to 20 degree flexion
2	Moderate	Full active extension of the fingers only with wrist at >20 degree flexion
2A		Active wrist extension with fingers flexed
2B		No wrist extension due to extensor paralysis
3	Severe	No finger extension

C Zancolli classification of spasticity This assesses active finger and wrist extension.

Cerebral Palsy

About half of children with cerebral palsy have a problem with hand function. Impairment correlates with disease severity; for example, most affected are those with tetraplegia. Disability results from limited voluntary control, including spasticity, sensory, and cognitive impairment, contractures, and deformity, to which contribute soft tissue and bone. The classic classification systems was developed by House and colleagues [A].

Evaluation Ask the family and therapists, who know the patient more broadly and for longer. Determine cognitive status, which is essential to outcome, in particular as pertains to postoperative rehabilitation. The classic posture of the upper limb is shoulder internal rotation, elbow flexion, forearm pronation, wrist flexion, finger flexion or boutonnière deformity, and thumb-in-palm [B]. Since examination may be difficult, focus on stereognosis, that is, tactile discrimination of size, shape, and texture, which is the most common sensory deficit. Level of function may be assessed by several instruments [C].

Management Passive range of motion, splinting (including night and day), and casting prevent and may correct contracture. Pharmacologic treatment may be central, for example, baclofen administered intrathecally or *per orem*, or peripheral, including botulinum toxin and phenol injection into muscle. The two approaches may be used synergistically, for example, botulinum toxin potentiates casting and splinting.

Operative treatment may be divided into muscle reconstruction or ablation. Reconstruction, including muscle lengthening and transfer, restores function to a cognitively spared child with flexible deformity. Ablation includes neurotomy, to permanently disable a spastic muscle without significant underlying contracture in a child with low functional demand, or fusion, which is an end treatment when soft tissue release and muscle balancing cannot control severe, rigid deformity.

For reconstruction, the child must be cooperative and compliant with evaluation and postoperative rehabilitation. As a result, intervention is delayed until after 5 years of age, when the child is old enough to comprehend and be motivated.

ELBOW Chronic flexion contracture may require plastic reconstruction for antecubital closure. Z-lengthen biceps brachii, fractionally lengthen brachialis, and release brachioradialis. Protect radial nerve and lateral antebrachial cutaneous nerve, although the latter may be cut if it resists elbow extension.

FOREARM No operative treatment is indicated for supination beyond neutral. For active supination, perform a pronator quadratus and flexor-pronator aponeurotic release. For no active supination but an active pronator teres, transfer the muscle through the interosseous membrane to the dorsolateral radius.

WRIST AND FINGERS Wrist flexion may be caused by weak wrist extensors, spastic wrist flexors, or spastic digital flexors. For active wrist extension but spastic wrist flexors, lengthen flexor carpi ulnaris, and radialis, and release palmaris longus. Transfer a deforming extensor carpi ulnaris to extensor carpi radialis brevis to enhance wrist extension. For finger flexor spasticity, fractionally lengthen these if the fingers may be extended with <45 degrees of wrist extension, or release the flexor pronator origin if wrist flexion > 45 degrees is necessary for digital extension. Rigid deformity is addressed by carpal fusion.

For flexible boutonnière deformity without dynamic metacarpophalangeal flexion deformity, perform a central slip tenotomy.

THUMB Sequential release includes thenar muscles, first dorsal interosseous, flexor pollicis longus lengthening, and soft tissue stabilization or fusion of the metacarpophalangeal joint. Weak thumb abduction may be addressed by extensor pollicis longus or brachioradialis transfer.

WRIST

Kienböck Disease

Osteochondritis of the lunate, also known as lunatomalacia (Greek μαλακος: “soft”), is rare in children. Microtrauma conspires with force concentration at the distal corner of radius brought about by a negative ulnar variance to injure the bone. The condition may be associated with dermatomyositis and athetoid cerebral palsy, which is characterized by increased motion under high tone.

Evaluation Presentation includes insidious onset pain and tenderness over lunate, with wrist swelling and stiffness.

IMAGING Röntgenogrammes show sclerosis, collapse, and irregularity of contour of lunate and allow measurement of ulnar variance [A].

Management Most children may be treated symptomatically, with resolution without sequela over months to a few years. Radial shortening osteotomy to address negative ulnar variance and reduce stress on the lunate is indicated for persistent or unacceptable pain, or for carpal deformity.

Madelung Deformity

Growth disturbance of the volar–ulnar part of the distal radial physis leads to volar translation of the hand and wrist associated with dorsal prominence of the distal ulna. Prepubescent girls are primarily affected. More than half of cases are bilateral and of asymmetric severity. Madelung deformity may be primary or secondary; for example, it is a feature of Léri-Weill dyschondrosteosis and Turner syndrome (*cf.* Syndromes chapter).

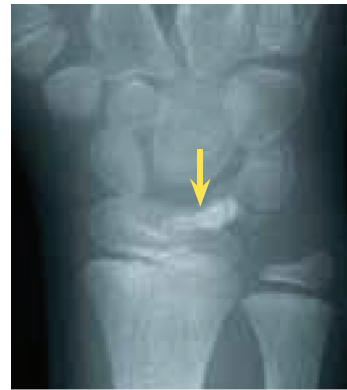Evaluation Ask about family history, as one-third of cases show an autosomal dominant pattern of inheritance, with variable expression and penetrance. Wrist pain, stiffness, and deformity are accompanied by the characteristic hand displacement.

IMAGING Obtain bilateral röntgenogrammes on the same image to allow comparison. Posteroanterior projection shows increased radial inclination (normal 20 to 25 degrees) and ulnar variance [B]. Lateral projection shows increased volar tilt of distal radius (normal 10 to 15 degrees) and relative subluxation of the distal ulna dorsal to the proximal carpal row. CT may provide a clearer understanding of the three-dimensional nature of the deformity.

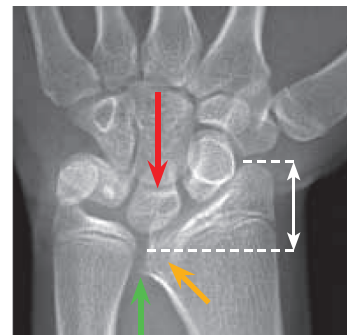
Management Release of Vickers ligament, *via* a volar approach, reduces tension that is implicated in the genesis of pain. In addition, early release combined with bridge resection may remove a retardant force to growth, thereby altering the natural history of progressive deformation by allowing the volar–ulnar physis to grow again.

Osteotomy of the distal radius corrects orientation of the articular surface [C], when insufficient growth remains for release and physiolysis. Distraction osteogenesis with an external fixator may facilitate multiplanar correction and enables restoration of radial length.

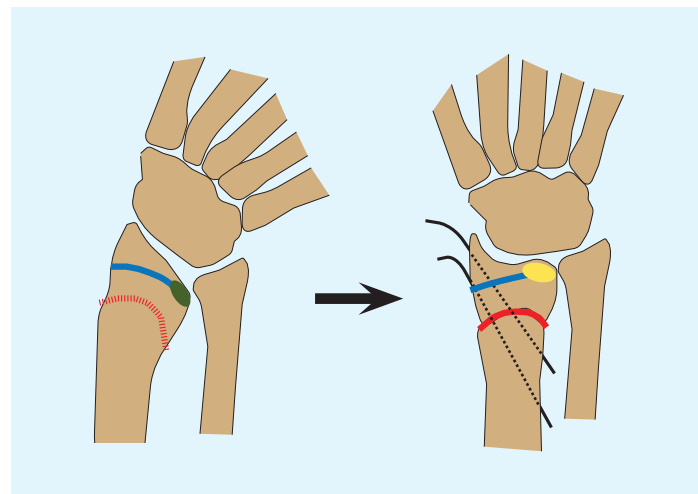
For severe deformity that prevents restoration of a congruent wrist, radioscapocapitate arthrodesis is indicated. Deformity of the distal radioulnar joint may be addressed by distal radioulnar fusion (Lauenstein); avoid resection of the distal ulna (Darach), which may be followed by gradual ulnar migration of the wrist.



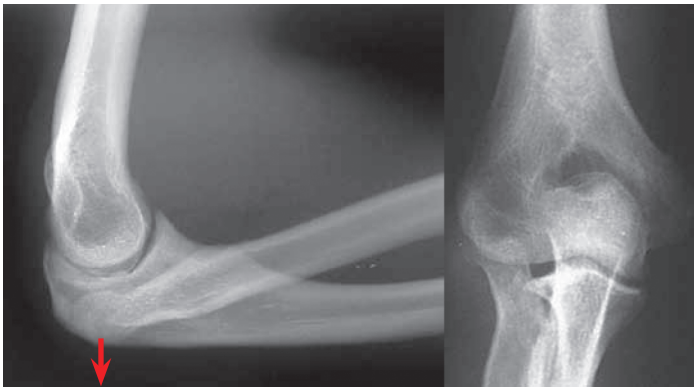
A Kienböck disease. This 9 year old gymnast with dermatomyositis developed wrist pain. There is sclerosis, collapse and irregular contour of lunate is obvious (*yellow*).



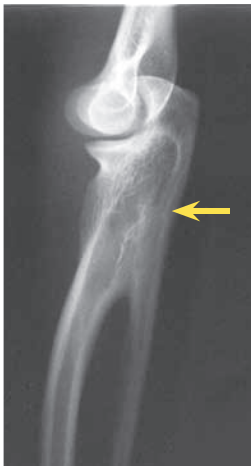B Madelung deformity There is lucency and premature fusion (*orange*) at the locus of growth disturbance, triangular distortion of the distal epiphysis, and pyramidalization (*red*) of the wrist as it sink into the defect, with apex at the lunate. Distal radial height is increased (*white*) by retardation of ulnar growth (normal 12 to 15 mm). Interosseous space is widened, into which lunate may be displaced. Vickers ligament attaches immediately distal to the osteophyte arising from the ulnar aspect of the distal metaphysis of radius (*green*).



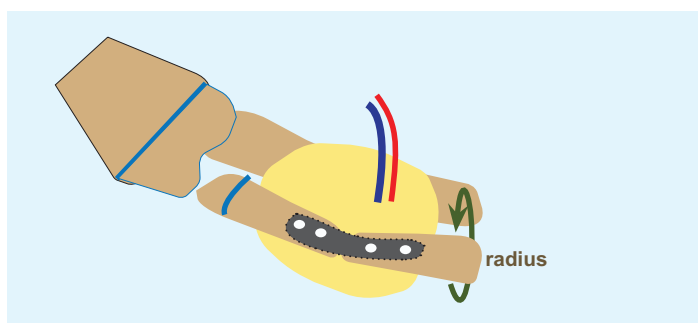
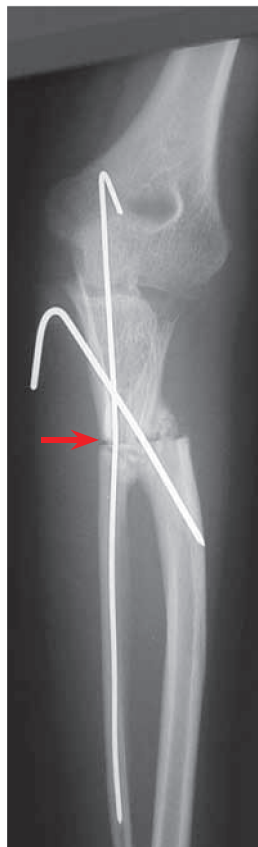C Correction of Madelung deformity This correction is performed through a volar approach. Vickers ligament and physal bridge (*green*) are excised with fat interposition (*yellow*). The dome shape of osteotomy (*red*) allows simultaneous correction of radial inclination as well as radial and dorsal translation, which improves articular support of lunate. Fixation is with divergent wires, due to the inherent stability of the wide surface area of the osteotomy.



A Atraumatic dislocation of radial head The proximal radius is thin and deformed; capitulum is blunted. Posterior direction is most common.



B Congenital radioulnar synostosis Proximal radius and ulna fail to differentiate (yellow). Perform a rotational osteotomy (red) through the synostosis. Incision is along subcutaneous border of ulna. Subperiosteal interval is safe, including away from posterior interosseous nerve. Nail the ulna antegrade with a wire, around which osteotomy is rotated to 45 degrees of pronation or supination and cross-fixed with a wire into the radius. Monitor after operation for compartment syndrome, which is a risk of acute forearm rotation. If signs develop, remove the cross wire and relax the forearm. Rerotate the forearm after bleeding, swelling, and risk subside.



C Mobilization of radioulnar synostosis Through a subacromial approach, synostosis is excised. Proximal radius is cut: it is shortened to reduce its dislocated head to capitulum, the distal fragment is supinated (green) to take its synostosis surface away from the ulna's, and fixed with a plate. Profunda humeri vessels of the fasciofat graft are anastomosed to radial recurrent vessels. The fasciofat graft, like a lateral arm flap, includes a skin bridge to monitor viability.

FOREARM

Congenital Dislocation of the Head of the Radius

This may be isolated or associated with other anomalies, such as nail–patella syndrome, hereditary multiple exostosis, and osteogenesis imperfecta (*cf.* Syndromes chapter). Most are bilateral.

Evaluation Limited forearm rotation and a palpable prominence over the displaced radial head bring the child to medical attention, typically around 5 years of age. Posterior dislocation is most common and limits extension of the elbow; anterior dislocation limits elbow flexion. The dislocated radial head becomes progressively more prominent with growth. Shortening of the radial side of the forearm makes the ulna more prominent at the wrist. Bilateral involvement and a family history distinguish this from traumatic dislocation, for example, as part of Monteggia fracture (*cf.* Trauma chapter).

IMAGING Röntgenogrammes show relative lengthening of ulna associated with a hypoplastic capitulum and proximal radius, of which the epiphysis is underdeveloped and deformed in childhood and which becomes tapered like “sucked candy” by maturity [A]. Differentiate traumatic dislocation, which is characterized by normal development of capitulum and proximal radius, including epiphysis, without shortening of radius.

Management Most presentations are so mild that education and symptom control *pro re nata* suffice. Reduction of atraumatic dislocation of the radial head is unsuccessful due to radiocapitular dysplasia: incongruence leads to persistent instability. Rarely, excision of the radial head is indicated, to alleviate pain and reduce prominence more than to improve motion. Delay this until maturity, to reduce heterotopic ossification that may require repeat excision. Cubitus valgus, ulnar neuritis, and weakness are theoretical concerns that have eluded demonstration.

Congenital Radioulnar Synostosis

This may be categorized as a failure of differentiation of proximal radius and ulna. Longitudinal segmentation of radius and ulna proceeds from distal to proximal. Radioulnar synostosis is detectable at neonatal examination. Alternatively, like congenital dislocation of the radial head presentation may be delayed due to absence of pain and adaptation of the child: radioulnar synostosis comes to light when forearm rotation becomes noticed by third parties, such as when drawing at school. Half are bilateral.

Distinguish traumatic synostosis. This follows and correlates with the energy of fracture, or it may be iatrogenic from surgical dissection. It may occur at any level of the forearm. It is more common in the setting of head injury.

Evaluation There is no forearm rotation. Hand position may be stuck in any degree of pronation or supination. Wrist may be hypermobile to compensate. Another compensatory mechanism is shoulder abduction for loss of pronation.

IMAGING Röntgenogrammes show fusion of proximal radius and ulna that extends beyond the bicipital tuberosity [B].

Management In a patient with unilateral synostosis, the unaffected forearm may compensate for loss of motion on the synostosed side.

OSTEOTOMY Surgical correction is indicated for a patient with bilateral synostosis who is unable to compensate for physical demand [B]. Perform a rotational osteotomy through the synostosis to achieve the goals of pronation of the dominant side to write and use a keyboard, and supination of the nondominant side to receive, for example when accepting change, and for support, for example when carrying objects.

EXCISION This promises restoration of motion. Interposition of synthetic material, for example silicone, or biologic material, for example autograft fat, or allograft or autograft fascia wrapped around the radius, has not been durable. Interposition of a vascularized fasciofat flap, obtained from lateral aspect of the same arm, has shown success in limited series [C]. The problem and solution resemble tarsal coalition (*cf.* Foot chapter).

SHOULDER

Sprengel Anomaly

During the 2nd to 3rd fetal months, the scapula migrates from adjacent to the fourth to sixth cervical vertebrae caudad. Failure of descent (not elevation) strands the scapula between the neck and shoulder. The scapula is small; its inferior angle is rotated medialward such that the glenoidal cavity is directed downward. One-third of cases are associated with an omovertebral bone (Greek *ομοος*: “shoulder”), which connects superomedial border of scapula with lower cervical vertebrae, and which is a homolog of the suprascapular bone in lower vertebrates, in particular Amphibia [A]. Boys are thrice as affected as girls. It is sporadic, with rare subsets of autosomal dominant inheritance.

Evaluation This is detectable at neonatal examination. The patient has a firm fullness in the neck. Shoulder abduction is limited: downward projection of the glenoidal cavity shifts the glenohumeral arc inferior, while hypoplasia and contracture of spinoscapular muscles reduces scapulothoracic motion. An omovertebral bone further restricts motion. Serratus anterior weakness results in winging, which worsens the appearance. Bilateral presentation is less disfiguring due to symmetric neck contour, but more disabling due to difficulty raising a hand above the horizon.

IMAGING Röntgenogrammes show relative elevation of a dysplastic scapula. A lateral or oblique view of the cervical spine screens for vertebral anomalies and may show the omovertebral bone, which is confirmed by CT. An MRI visualizes the spinal cord for neural lesion, and a fibrous connexion with the cervical spine.

Management Physiotherapy preserves and maximizes shoulder motion. Unacceptable appearance and limited shoulder motion are indications for operation. Optimal age is the first decade, when contractures are less unyielding and when nerves, including brachial plexus, are more tolerant of stretch. Muscle release is extraperiosteal to avoid osseous regrowth. Cutting the clavicle decompresses the brachial plexus when the scapula is mobilized significantly.

SCAPULOPLASTY (M^BBURNEY, SANDS) This is indicated for mild deformity, in which neck fullness is more significant than displacement of the body and winging of the scapula and than shoulder abduction above the horizon. Release levator scapulæ and rhomboid minor, protecting transverse cervical artery and dorsal scapular nerve. Identify scapular attachment of omovertebral bone: release this and draw it distal to liberate it for extraperiosteal excision. Reflect supraspinatus to the greater scapular notch, protecting the transverse scapular artery and suprascapular neurovascular bundle. Reflect subscapularis off deep surface of the scapula. Excise the superior angle of scapula. Reattach supraspinatus to the spine of the scapula.

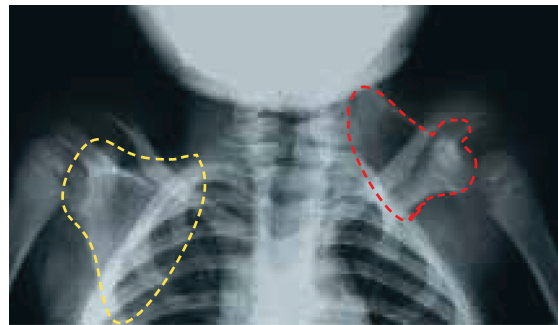
REPOSITIONING (GREEN, WOODWARD) This is indicated for more severe deformity. Division of the clavicle, with preservation of its periosteal sleeve, reduces the risk of brachial plexus compression with scapular distalization. This is performed supine, after which the patient is turned prone.

Release trapezius, protecting spinal accessory nerve. Release adhesions tethering scapula to the thorax. Release latissimus dorsi. Reposition scapula, including suture of superomedial corner to spinous processes of T11-T12 to rotate glenoid out of varus, thereby shifting the glenohumeral arc toward more abduction. The scapula may be held in place by a pocket fashioned in latissimus dorsi and by suture to adjacent ribs. Reattach muscles to new sites based upon the distalization [C].

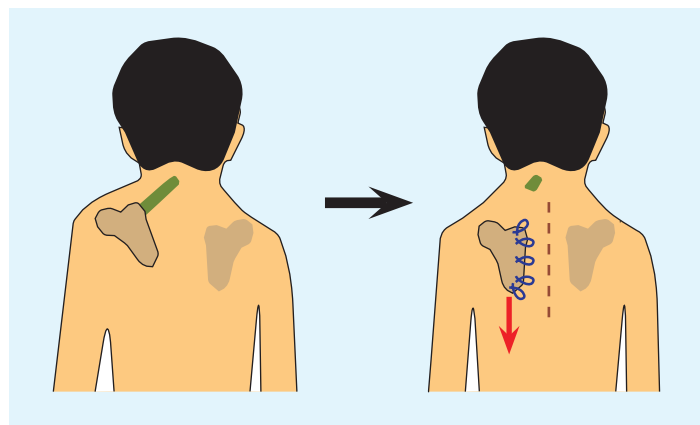
OSTEOTOMY (KÖNIG) Because of a return of the scapula toward its original position with time as the soft tissue reconstruction gives way, osteotomy has been advocated to provide more secure healing [D]. The scapula is divided 1 cm lateral to vertebral border, leaving its muscular attachments undisturbed. The medial half is tensioned distalward to deliver an omovertebral bone, which is excised. Subscapularis and adhesions are freed from the lateral half, which is distalized and secured to the medial half by sutures or wire through offset drill holes. Excise the superomedial angle, leaving levator scapulæ free.

Anomaly
Omovertebral bone
Congenital scoliosis
Cervical spina bifida
Diastematomyelia
Costal fusion
Syndromes, e.g., Klippel-Feil, Poland

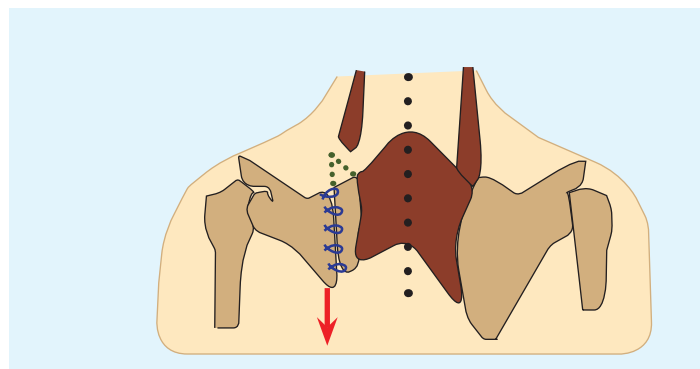
A Anomalies associated with Sprengel anomaly. These are seen in half of cases.



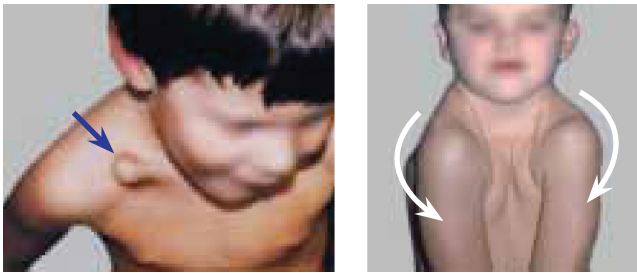
B Sprengel anomaly. The left scapula is dysplastic, rotated, and elevated.



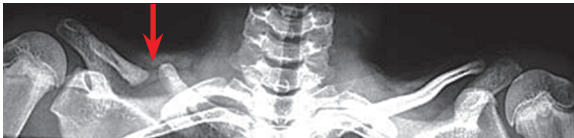C Soft tissue repositioning. A midline linear incision is used (brown). Omovertebral bone (green) is resected. Muscular attachments are released extraperiosteally and reattached (blue) in the new scapular position (red).



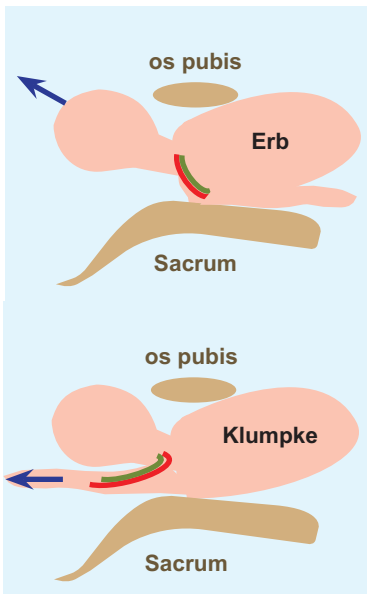
D Vertical osteotomy. Osseous union may be more reliable than soft tissue reconstruction. The lateral half of the scapula is distalized (red) and fixed in the new position to the medial half by suture or wire (blue). The superior angle of the medial fragment is excised (green), leaving levator scapulæ free.



E Congenital pseudarthrosis of the clavicle. This presents as a painless prominence at the midclavicle (blue). Absent clavicles in cleidocranial dysplasia result in shoulder hypermobility (white).



F Congenital pseudarthrosis of the clavicle. Medial and lateral ossification centers of right clavicle failed to coalesce (red). Medial end is displaced superior, where it is prominent under skin.



G Dystocia. When a child obstructed in the birth canal at the shoulders is pulled by the head, the upper brachial plexus may be stretched and injured (red). This disproportionately affects the proximal upper limb. Pulling the child by the arm, by contrast, will put tension on the lower brachial plexus (red). The focus of disability is the hand.

Risk Factor
Birth weight >5 kg
Maternal diabetes
Multiparity
Breech
Second stage of labor >60 minutes
Assisted delivery
Manual traction during delivery
<i>In utero</i> torticollis
Shoulder dystocia

H Risk factors for brachial plexus birth injury. Injury may occur during delivery, during descent into the canal or *in utero*. This explains injury in small babies and absent dystocia, and the fact that only 1/2 of cases have an identifiable risk factor.

Poor prognostic sign
Preganglionic injury
Total plexus involvement
2 weeks: no sign of early recovery
6 months: no recovery of elbow flexion, wrist and digital extension

I Poor prognostic signs. These aid counseling of family and decision making.

Congenital Pseudarthrosis of the Clavicle

The clavicle is the first bone to ossify and the last to fuse into one. Medial and lateral primary centers of ossification appear by the 6th fetal week. A third, secondary ossification center appears toward the end of the second decade at the sternal end and unites with the rest of the bone by the middle of the third decade.

Failure of coalescence of the two primary ossification centers of the clavicle leaves a central defect. Contributing to this failure may be pulsation of the subclavian artery, whence the concept of subclavian artery dysplasia syndrome. The lesion is predominantly right sided (95%). The right subclavian artery arises from the innominate artery, and its third portion is intimately apposed to the clavicle. By contrast, the left subclavian artery arises from the arch of aorta at a lower level and is more remote from the clavicle on its way to the upper limb. Left-sided lesions have been reported in association with dextrocardia.

Evaluation The pseudarthrosis produces a painless prominence over the clavicle [E], associated with narrowing of the shoulder. Fatigue and pain may develop in the older child as the demands of sports heighten. Distinguish cleidocranial dysplasia, in which bilateral failure of coalescence of the primary ossification centers or aplasia of the clavicle is associated with hypermobility of the shoulders, such that they may be brought together anteriorly in the midline, as well as other stigmata absent from congenital pseudarthrosis of the clavicle (*cf.* Syndromes chapter) [F].

IMAGING Röntgenogrammes show a midclavicular defect with anterior and superior angulation. Occasionally, osseous irregularity may raise the specter of infection or tumor.

Management The indication to treat is unacceptable appearance and pain with activity. Explain to the patient and family that a bump will be traded for a scar and a slightly narrower shoulder. Resect the sclerotic ends of each fragment, compress with a plate, and augment with autogenous iliac crest bone graft. Stay within and preserve the periosteal sleeve: this will improve union rate and reduce the risk of brachial plexus injury due to anatomic distortion.

Brachial Plexus Birth Injury

Traction during dystocia may stretch and thereby injure the brachial plexus [G]. Several risk factors have been identified [H]. Injury may affect part of the brachial plexus or the entire brachial plexus. Partial injury may affect the upper trunk (C5-C6; Erb), which is most common; the lower trunk (C8-T1; Klumpke); or it may be mixed.

There are three types of neural injury.

- Apraxia is characterized by temporary loss of function that is followed by spontaneous resolution without sequela.
- In axonotmesis, the axon and myelin sheath are disrupted but the nerve remains in continuity: there is Wallerian degeneration and recovery over several months.
- Neurotmesis refers to complete nerve discontinuity, which makes spontaneous recovery unlikely.

Natural history Eighty percent show spontaneous recovery during the first year. Return of partial antigravity upper trunk muscle strength in the first 2 months indicates complete recovery by 2 years. There are several signs indicative of a poor prognosis [I]. Recovery of elbow flexion and shoulder abduction are better than of shoulder external rotation.

Evaluation The upper limb hangs by the side of the body or has an abnormal posture. There is reduced or no spontaneous movement of the upper limb. Moro reflex is asymmetric. Deep tendon reflexes are absent.

Determine if the lesion is pre- or postganglionic, because this is prognostic. The dorsal root ganglion contains the sensory cell body. The motor cell body is in the spinal cord. Preganglionic lesions represent avulsions from the spinal cord, which will not spontaneously recover. Signs include Horner syndrome (miosis, ptosis, anhidrosis, enophthalmos), elevation of the hemidiaphragm (phrenic nerve), and winging of the scapula (long thoracic nerve).

Upper brachial plexus injury produces a “waiter tip” posture of the upper limb: shoulder adduction and internal rotation, elbow extension, forearm pronation, wrist and digital flexion reflect loss of antagonists, for example, supraspinatus, deltoid, biceps, supinator, long extensors. Lower trunk injury manifests as elbow flexion, wrist extension, and clawing of the hand.

Measure motion. Palpate the posterior shoulder for a dislocation. Check for scapular winging. There may be associated fracture of the clavicle or humerus, as a sign of dystocia. At 3 to 6 months, a child in the supine position who cannot remove a towel from the face (“towel test”), lacking sufficient flexion and abduction, is a microsurgical candidate.

Sensation and strength may be graded systematically [J, K].

IMAGING Röntgenogrammes are unrevealing. MRI visualizes neural elements, for example, presence of roots in the neural foramina or meningocœles (root avulsion), and allows study of the glenohumeral joint for dysplasia without or with dislocation [L].

TESTS Electromyography and nerve conduction studies early may be used to measure injury and track recovery, both of which may be achieved by physical examination.

Management During observation for recovery, passive range of motion exercises are essential to prevent contracture and secondary osseous deformity. Passive stretch also reduces muscle hypoplasia and atrophy. Isolate glenohumeral motion to stretch the shoulder joint capsule by stabilizing the scapula. Enlist a physical therapist. Botulinum toxin facilitates stretching.

Nerve surgery This is indicated after 3 months in total plexus injury or in the presence of Horner syndrome, and after 6 months in postganglionic injury if there is no clinical sign of recovery [M].

AVULSIONS Perform a nerve transfer [N].

RUPTURES Nerve transfer may offer better outcomes than use of an autogenous peripheral nerve graft, for example, sural, to bridge the defect.

NEUROMA This is the most common lesion. Excision and grafting with autogenous sural nerve has superior results to neurolysis. The rôle of collagen matrix tubes has not been defined.

Soft tissue surgery This assumes no significant osseous deformity, which soft tissue reconstruction cannot overcome [O].

RELEASE Consider contracture release after 1 year of age, in order to preserve motion for later muscle transfer and to prevent secondary osseous deformity. Slide subscapularis off its origin on scapula *via* a posterior vertebral border approach. Indications for open reduction, as well as glenoid osteotomy for early dysplasia and dislocation, are in flux.

MUSCLE TRANSFER After 2 years of age, combine internal rotation release, including pectoralis major and subscapularis (Sever) as well as joint capsule, with transfer of latissimus dorsi and teres major to the rotator cuff at the greater tubercle (L’Episcopo) in order to restore shoulder abduction. Identify and protect the axillary nerve, which is at risk during this procedure. An alternative transfer for is lower trapezius augmented by tendo Achilles allograft to infraspinatus. Durability of muscle transfer is a concern.

Bone surgery This is indicated in the older child (>5 years) in whom improved positioning of the hand is the goal when shoulder motion is limited by advanced glenohumeral dysplasia.

HUMERAL OSTEOTOMY Perform a humeral osteotomy proximal to deltoid eminence, *via* a direct anterior approach and fixed with a plate, to recover external rotation. Adjust this to maintain sufficient internal rotation for perineal access.

FOREARM ROTATIONAL DEFORMITY A child with upper recovery but persistent C8-T1 palsy will present with supination contracture of the forearm. If there is >60 degrees of passive pronation, reroute the biceps brachii around the neck of radius to covert the muscle from supinator to pronator.

If passive motion is limited due to extensive contracture, place medullary wires in radius and ulna, which are cut and rotated into 25 degrees of pronation, where they are held by a cast until union.

Type	Sensation
S0	No reaction to pain
S1	Reaction to pain, none to touch
S2	Reaction to heavy touch, none to light touch
S3	Normal

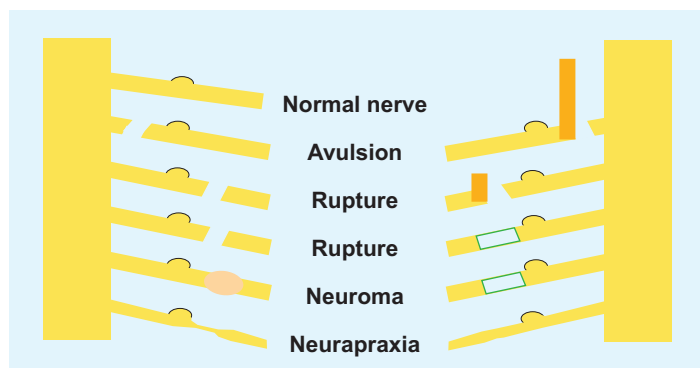
J Sensory grading system (Narakas).

Grade	1	2	3	4	5
Abduction	0	0–30 degrees	30–60 degrees	>60 degrees	Full
External Rotation	0	0 degrees	0–20 degrees	>20 degrees	Full
Hand to Neck	0	0 degrees	Difficult	Easy	Normal
Hand to Spine	0	0 degrees	to S-1	to T-12	Normal
Hand to Mouth	0	Trumpet	Partial trumpet	<40 degree abduction	Normal

K Grading of motor function (Mallet).

Type	Finding (MRI)
I	Normal
II	>5 degree glenoid retroversion
III	Posterior subluxation of humeral head
IV	Pseudoglenoid
V	Deformity of humeral head
VI	Dislocation
VI	Growth arrest of proximal humerus

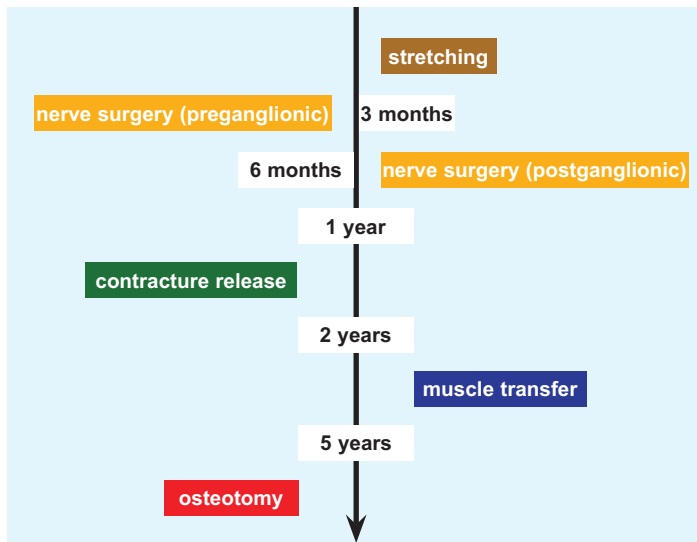
L Glenohumeral dysplasia (Waters) This develops secondary to muscle imbalance and chronic contracture. Recognition of this approaches hip dysplasia.



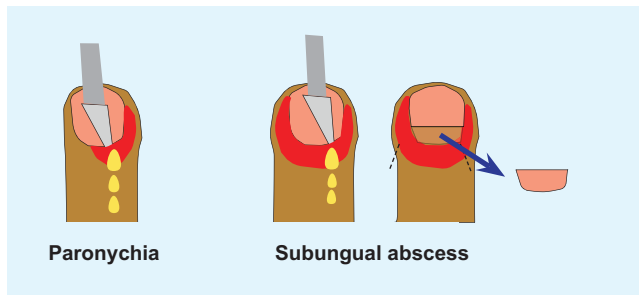
M Nerve surgery for obstetric brachial plexus injury Rupture may be treated by nerve transfer (*orange*) or grafting (*green*). The former has the advantage of a single microsurgical interface. Neurapraxia recovers without operation.

Nerve	Recipient	Function
Ulnar flexor carpi ulnaris motor branch	Musculocutaneous	Biceps brachii
Medial pectoral nerve	Musculocutaneous	Biceps brachii
Spinal accessory nerve	Suprascapular	Supraspinatus
Radial motor branch to long head of triceps	Axillary	Deltoid

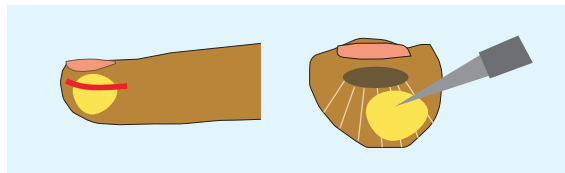
N Nerve transfer for upper brachial plexus birth injury Spinal accessory nerve is transferred distal to innervation of trapezius.



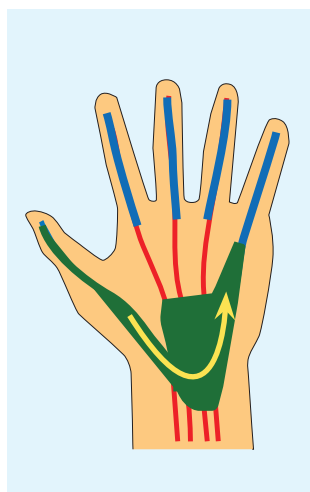
O Algorithm for treatment of brachial plexus birth injury.



A Nail infections Incising the nail wall for paronychia. If puss extends subjacent to the nail plate, remove part of this to complete drainage.



B Felon Lateral incision dorsal to neurovascular bundle (red). Follow with a blunt instrument to evacuate the abscess. Do not cut the septa with scalpel. Do not advance scalpel deep in order not to contaminate flexor tendon sheath or interphalangeal joint. Leave gauze to wick pus.



C Flexor tenosynovitis Infection spreads rapidly along tendon sheaths (blue). Radial and ulnar bursae (green) communicate to spread infection from the thumb to smallest finger (yellow).

HAND INFECTION

The most common pathogens are *Staphylococcus aureus* and *Streptococcus pyogenes*.

Cellulitis

Inspect the skin for breach. Rule out deep infection, for example, there should be painless motion of the digits and wrist. Draw the perimeter on the skin to aid follow-up. Treat with intravenous followed by oral antibiotics. Reduction of pain, recession of erythema, and return of cutaneous wrinkling indicated recovery.

Paronychia

This represents an infection lodges between nail plate and nail wall. Most are caused by *Staphylococcus aureus*; however, nail biting and thumb sucking introduce anaerobes. Treatment begins with warm soaks in dilute soap solution, a cotton wisp between nail wall and plate, to allow it to lift away with growth, and oral antibiotics if necessary. Severe infection is incised and drained [A].

Felon

This represents a closed space infection of the digital pulp, which is divided into compartments by vertical septa that stabilize the pad. Abscess in a confined space may lead to a mini-compartment syndrome, which may lead to necrosis of the skin and pulp, and spread to bone, joint, and flexor tendon. The infection develops spontaneously in 1/2 of patients, with no history of penetrating or other injury. Treatment consists of incision and drainage [B].

Herpetic Whitlow

Type I or II herpes simplex is the most common viral infection of the hand, caused typically by direct inoculation from gingivostomatitis. Clear vesicles are surrounded by erythema with tenderness but no swelling or distortion of the finger tip. A Tzanck test shows multinucleated giant cells in a smear taken from an unroofed vesicle. Do not incise and drain; this may lead to bacterial superinfection, or to systemic viral spread, for example, herpetic encephalitis. Protect the area, and observe for resolution over 3 to 4 weeks.

Flexor Tenosynovitis

Deep infections are introduced by a penetrating injury, they may be contiguous, for example, from a felon, or rarely they may be haematogenous. The infection travels rapidly through the tendon sheath, making this a surgical emergency. There are four cardinal signs (Kanavel):

- Flexed posture of the digit.
- Fusiform swelling along the volar digit.
- Tenderness along flexor tendon.
- Pain on passive extension.

In 80% of people, the thumb and smallest finger tendon sheaths communicate *via* radial and ulnar bursae [C], which may produce a horseshoe abscess. Second to fourth tendon sheaths are independent. In children, and for a presentation within the first 24 hours, intravenous antibiotics alone may suffice. Incise and drain an unresponsive infection.

Deep Space Infection

There are four deep spaces in the hand.

- Dorsal subaponeurotic
- Subfascial web
- Thenar
- Midpalmar

Dorsal subaponeurotic and subfascial web spaces communicate: tracking of infection between them may form a “collar-button” abscess. Because of dorsal location of the lymphatics of the hand, and because of the thickness and unyielding nature of palmar skin, deep palmar infection may manifest as dorsal erythema and swelling. This may be distinguished from cellulitis by pain with passive extension of inflamed flexor tendons. Ultrasonogramme also aids diagnosis and is easy on the child. Treatment is incision and drainage.

GENERAL

- Eklblom AG, Laurell T, Arner M. Epidemiology of congenital upper limb anomalies in 562 children born in 1997 to 2007: a total population study from Stockholm, Sweden. *J. Hand Surg. Am.* 35(11):1742–1754, 2010.
- Manske PR, Oberg KC. Classification and developmental biology of congenital anomalies of the hand and upper extremity. *J. Bone Joint Surg. Am.* 91(Suppl 4):3–18, 2009.
- Swanson AB, Swanson GD, Tada K. A classification for congenital limb malformation. *J. Hand Surg. Am.* 8(5 Pt 2): 693–702, 1983.

DEFICIENCY

- Bayne LG, Klug MS. Long term review of the surgical treatment of radial deficiencies. *J. Hand Surg. Am.* 12(2):169–179, 1987.
- Bayne LG. Congenital hand deformities: ulnar club hand (ulnar deficiency). In: Green DG, ed. *Operative Hand Surgery*. New York: Churchill Livingstone; 1982.
- Eaton CJ, Lister GD. Toe transfer for congenital hand defects. *Microsurgery* 12(3):186–195, 1991.
- Goldfarb CA, Manske PR, Busa R, Mills J, Carter P, Ezaki M. Upper-extremity phocomelia reexamined: a longitudinal dysplasia. *J. Bone Joint Surg. Am.* 87(12):2639–2648, 2005.
- James MA, McCarroll HR Jr, Manske PR. The spectrum of radial longitudinal deficiency: a modified classification. *J. Hand Surg. Am.* 24(6):1145–1155, 1999.
- Miura T, Nakamura R, Horii E. The position of symbrachydactyly in the classification of congenital hand anomalies. *J. Hand Surg. Br.* 19(3):350–354, 1994.
- O’Rahilly R. Morphological patterns in limb deficiencies and duplications. *Am. J. Anat.* 89(2):135–193, 1951.

FAILURE OF DIFFERENTIATION

- Baek GH, Kim JH, Chung MS, Kang SB, Lee YH, Gong HS. The natural history of pediatric trigger thumb. *J. Bone Joint Surg. Am.* 90(5):980–985, 2008.
- Hefner RA. Inheritance of crooked little fingers. *J. Hered.* 20(8):395–398, 1929.
- Kemp T, Ravn J. Über erbliche hand-und fussdeformitäten in einem 140-koepfigen geschlecht, nebst einigen bemerkungen ueber poly-und syndaktylie beim menschen. *Acta Psychiat. Neurol. Scand.* 7:275–296, 1932.
- Kjaer KW, Hansen L, Eiberg H, Utkus A, Skovgaard LT, Leicht P, Opitz JM, Tommerup NA. 72-year-old Danish puzzle resolved—comparative analysis of phenotypes in families with different-sized HOXD13 polyaniline expansions. *Am. J. Med. Genet.* 138(4):328–339, 2005.
- Kirner J. Doppelseitige verkrümmungen des kleinfingerendglieders als selbständiges krankheitsbild. *Fortschritte auf dem Gehiete der Rönigenstrahlen.* 36:804–806, 1927.
- Larner AJ. Camptodactyly: a 10-year series. *Eur. J. Dermatol.* 21(5):771–775, 2011.

DUPLICATION

- Frazier TM. A note on race-specific congenital malformation rates. *Am. J. Obstet. Gynecol.* 80:184–185, 1960.
- Furniss D, Lettice LA, Taylor IB, Critchley PS, Giele H, Hill RE, Wilkie AOM. A variant in the sonic hedgehog regulatory sequence (ZRS) is associated with triphalangeal thumb and deregulates expression in the developing limb. *Hum. Mol. Genet.* 17(16):2417–2423, 2008.

- Tupper JW. Pollex abductus due to congenital malposition of the flexor pollicis longus. *J. Bone Joint Surg. Am.* 51(7):1285–1290, 1969.
- Wassel HD. The results of surgery for polydactyly of the thumb. A review. *Clin. Orthop.* 64:175–193, 1969.

OVERGROWTH

- Cerrato F, Eberlin KR, Waters P, Upton J, Taghinia A, Labow BI. Presentation and treatment of macrodactyly in children. *J. Hand Surg. Am.* 38(11):2112–2123, 2013.
- Tsuge K, Ikuta Y. Macrodactyly and fibro-fatty proliferation of the median nerve. *Hiroshima J. Med. Sci.* 22(1):83–101, 1973.

UNDERGROWTH

- Blauth W. The hypoplastic thumb. *Arch. Orthop. Unfallchir.* 62(3):225–246, 1967.
- Buck-Gramcko D. *Congenital Malformations of the Hand and Forearm*. London, UK: Churchill Livingstone; 1998.
- Poland A. Deficiency of the pectoral muscle. *Guys Hosp. Rep.* 6:191, 1841.

CONSTRICTION

- Patterson TJ. Congenital ring-constrictions. *Br. J. Plast. Surg.* 14:1–31, 1961.

GENERALIZED SKELETAL ABNORMALITIES

- Gschwind C, Tonkin M. Surgery for cerebral palsy: Part 1. Classification and operative procedures for pronation deformity. *J. Hand Surg. Br.* 17(4):391–395, 1992.
- House JH, Gwathmey FW, Fidler MO. A dynamic approach to the thumb-in palm deformity in cerebral palsy. *J. Bone Joint Surg. Am.* 63(2):216–225, 1981.
- Tonkin M, Freitas A, Koman A, Leclercq C, Van Heest A. The surgical management of thumb deformity in cerebral palsy. *J. Hand Surg. Br.* 33(1):77–80, 2008.
- Tonkin M, Gschwind C. Surgery for cerebral palsy: Part 2. Flexion deformity of the wrist and fingers. *J. Hand Surg. Br.* 17(4):396–400, 1992.
- Zancolli EA, Zancolli ER Jr. Surgical management of the hemiplegic spastic hand in cerebral palsy. *Surg. Clin. North Am.* 61(2):395–406, 1981.

WRIST

- Carter PR, Ezaki M. Madelung’s deformity. Surgical correction through the anterior approach. *Hand Clin.* 16(4):713–721, 2000.
- Dannenberg M, Anton JI, Spiegel MB. Madelung’s deformity. *Am. J. Roentgen. Radium. Ther. Nucl. Med.* 42(5):671–676, 1939.
- Laffosse JM, Abid A, Accadbled F, Knör G, Sales de Gauzy J, Cahuzac JP. Surgical correction of Madelung’s deformity by combined corrective radioulnar osteotomy: 14 cases with four-year minimum follow-up. *Int. Orthop.* 33(6):1655–1661, 2009.
- Vickers D, Nielsen G. Madelung deformity: surgical prophylaxis (physiolysis) during the late growth period by resection of the dyschondrosteosis lesion. *J. Hand Surg. Br.* 17(4):401–407, 1992.

ELBOW

- Almqvist EE, Gordon CH, Blue AI. Congenital dislocation of the head of the radius. *J. Bone Joint Surg. Am.* 51(6):1118–1127, 1969.

- Blodgett WE. Congenital luxation of the head of the radius. Report of two cases. Analysis of fifty-one cases. *Am. J. Orthop. Surg.* 3:253–270, 1905.
- Green WT, Mital MA. Congenital radio-ulnar synostosis: surgical treatment. *J. Bone Joint Surg. Am.* 61(5):738–743, 1979.
- Kanaya F, Ibaraki K. Mobilization of a congenital proximal radioulnar synostosis with use of a free vascularized fascio-fat graft. *J. Bone Joint Surg. Am.* 80(8):1186–1192, 1998.

SHOULDER

- Cavendish ME. Congenital elevation of the scapula. *J. Bone Joint Surg.* 54(3)-B:395–408, 1972.
- Eulenberg M. Casuistische mittelheilungen aus dem gembeite der orthopadie. *Arch. Klin. Chir.* 4:301–311, 1863.
- Fawcett J. The development and ossification of the human clavicle. *J. Anat. Physiol.* 47:225–234, 1913.
- Gilbert A, Tassin JL. Surgical repair of the brachial plexus in obstetric paralysis. *Chirurgie* 110:70–75, 1984.
- Green WT. The surgical correction of congenital elevation of the scapula (Sprengel’s deformity). *J. Bone Joint Surg. Am.* 39-A:1439–1448, 1957.
- Haerle M, Gilbert A. Management of complete obstetric brachial plexus lesions. *J. Pediatr. Orthop.* 24(2):194–200, 2004.
- Hale HB, Bae DS, Waters PM. Current concepts in the management of brachial plexus birth palsy. *J. Hand Surg. Am.* 35(2):322–331.
- König F. Eine neue operation des angeborenen schulterblatthochstandes. *Beitr. Klin. Chir.* 94:530–537, 1914.
- L’Episcopo JB. Tendon transplantation in obstetrical paralysis. *Am. J. Surg.* 25:122–125, 1934.
- Lloyd-Roberts GC, Apley AG, Owen R. Reflections upon the aetiology of congenital pseudarthrosis of the clavicle. With a note on cranio-cleido dysostosis. *J. Bone Joint Surg. Br.* 57(1):24–29, 1975.
- Mallet J. Obstetrical paralysis of the brachial plexus. *Rev. Chir. Orthop. Reparatrice Appar. Mot.* 58(Suppl 1):166–168, 1972.
- Matsuoka T, Ahlberg PE, Kassaris N, Iannarelli P, Dennehy U, Richardson WD, McMahon AP, Koentges G. Neural crest origins of the neck and shoulder. *Nature* 436(7049):347–355, 2005.
- McBurney CH, Sands A. Congenital deformity due to malposition of the scapula. *N Y Med. J.* 47:582–583, 1888.
- McMurtry I, Bennet GC, Bradish C. Osteotomy for congenital elevation of the scapula (Sprengel’s deformity). *J. Bone Joint Surg. Br.* 87(7):986–989, 2005.
- Narakas AO. Brachial plexus surgery. *Orthop. Clin. North Am.* 12(2):303–323, 1981.
- Sever JW. Obstetric paralysis: report of eleven hundred cases. *JAMA* 85:1862–1865, 1925.
- Sprengel RD. Die angeborene verschiebung des schulterblattes nach oben. *Arch. Klin. Chir.* 42:545–549, 1891.
- Woodward JW. Congenital elevation of the scapula: correction by release and transplantation of muscle origins. *J. Bone Joint Surg. Am.* 43(2):219–228, 1961.

INFECTION

- Doyle JR. Anatomy of the finger flexor tendon sheath and pulley system. *J. Hand Surg. Am.* 13(4):473–484, 1988.
- Kanavel AB. *Infections of the Hand. A Guide to the Surgical Treatment of Acute and Chronic Suppurative Processes in the Fingers, Hand, and Forearm*. Philadelphia, PA/New York: Lea & Febiger; 1912.

