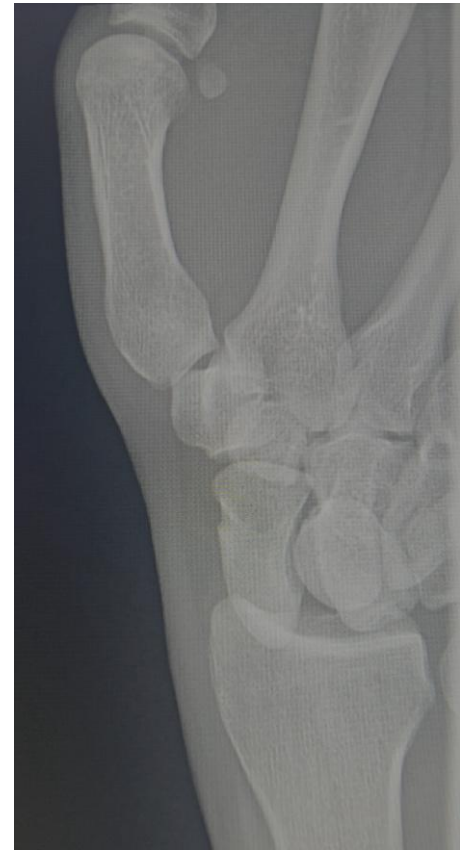
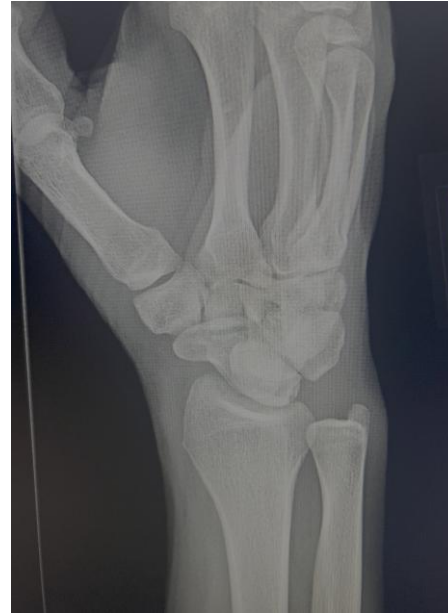
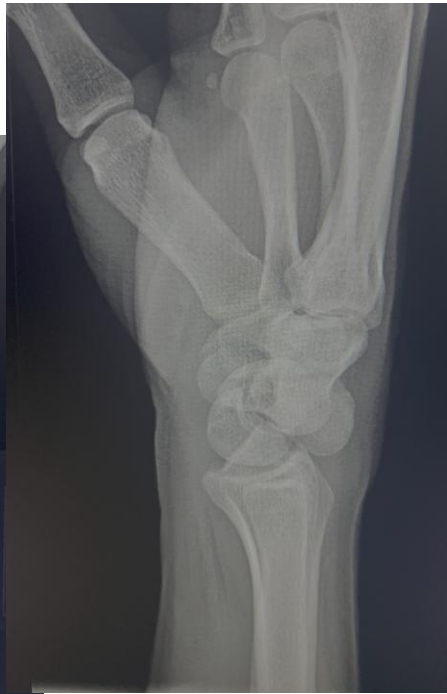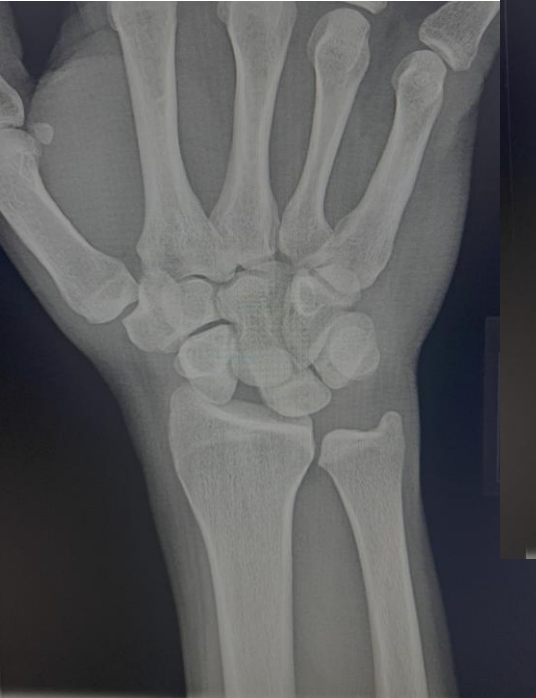Hand and Wrist Cases

Scott L. Hansen, M.D.

Case 1

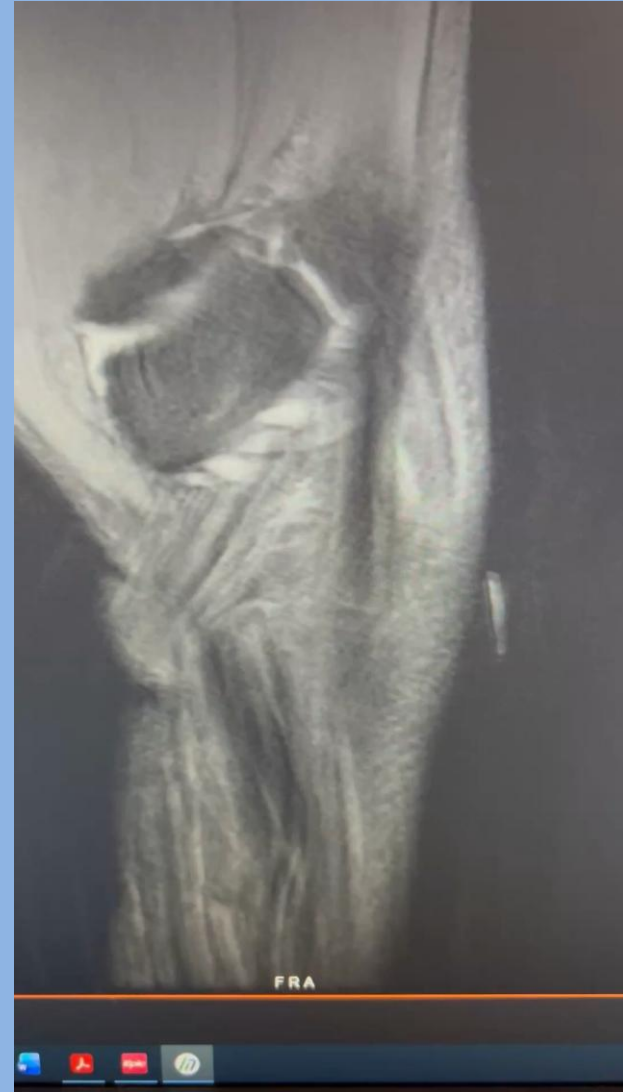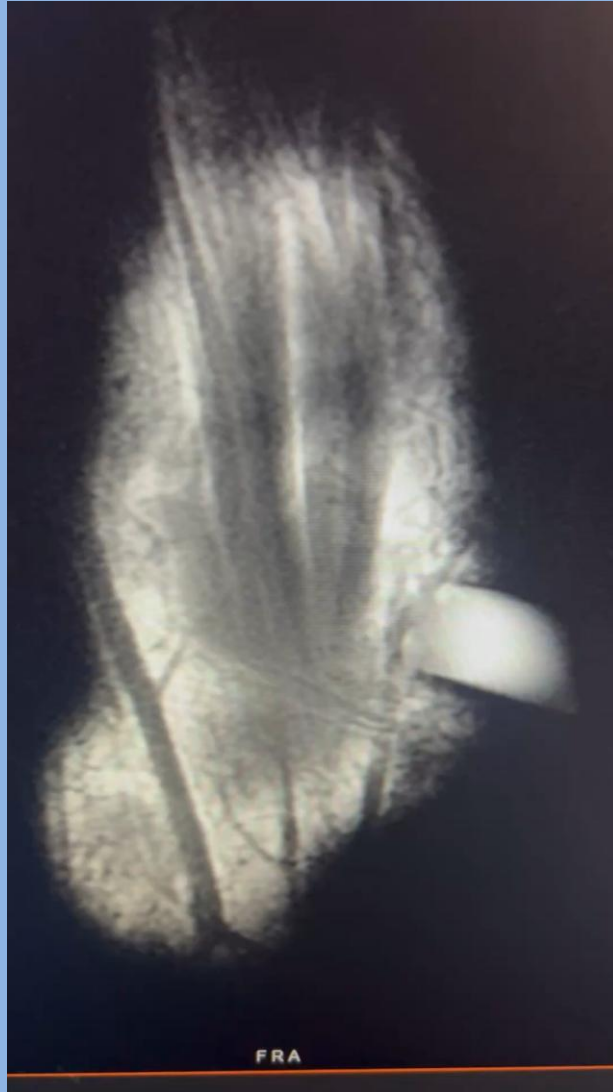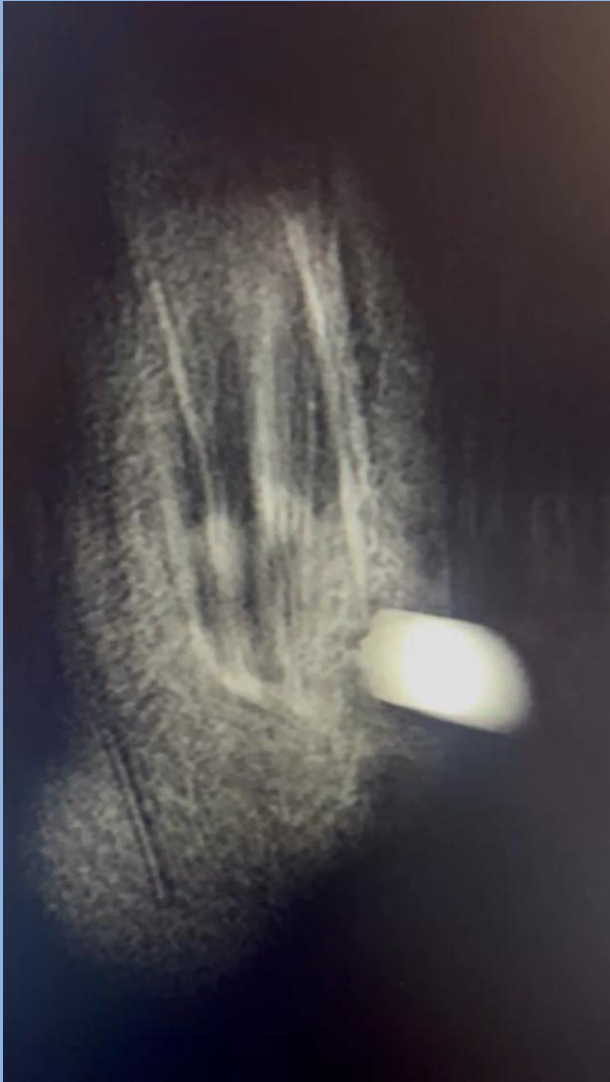
- 42 yo RHD man presents with right wrist pain
- Fell from standing 4 months prior, delayed presentation
- Healthy and active (Mountain biker)



Case 1

Management?

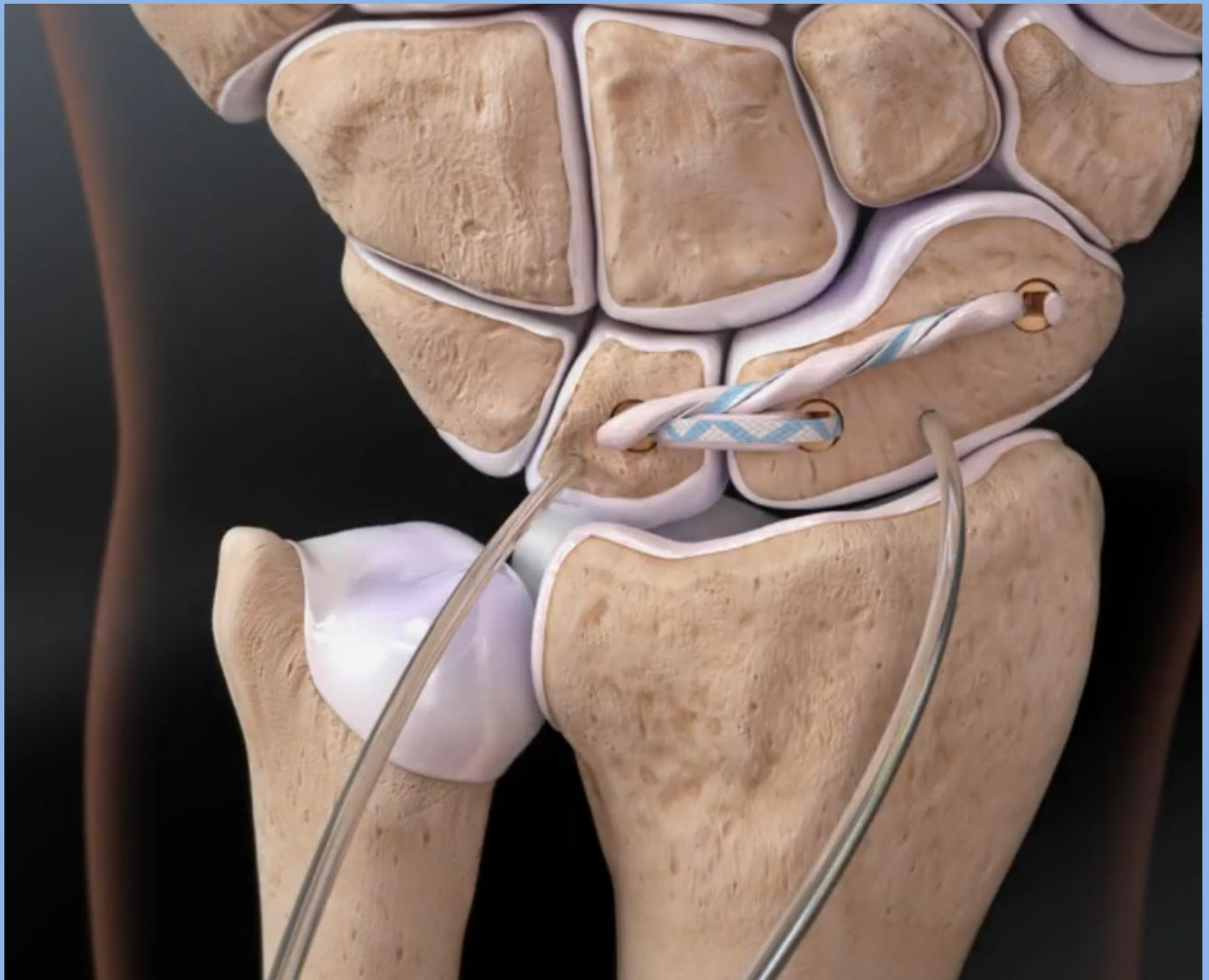
MRI

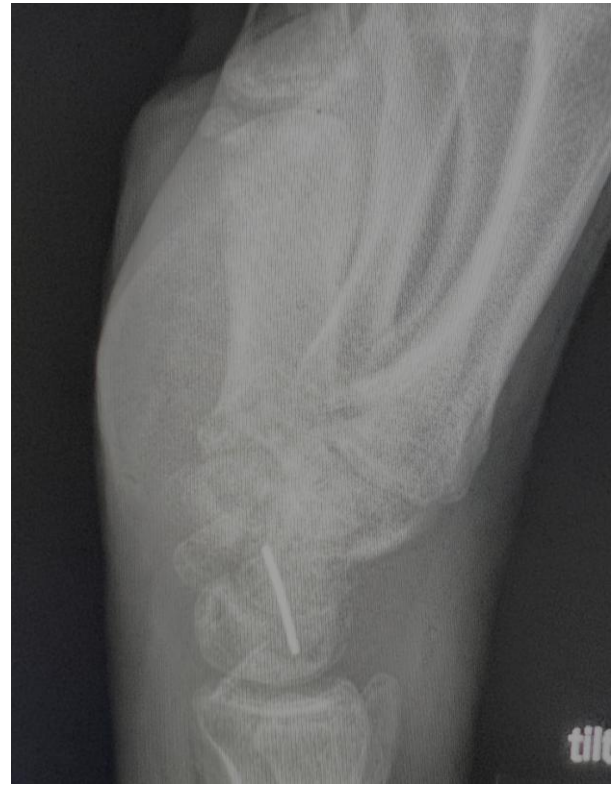
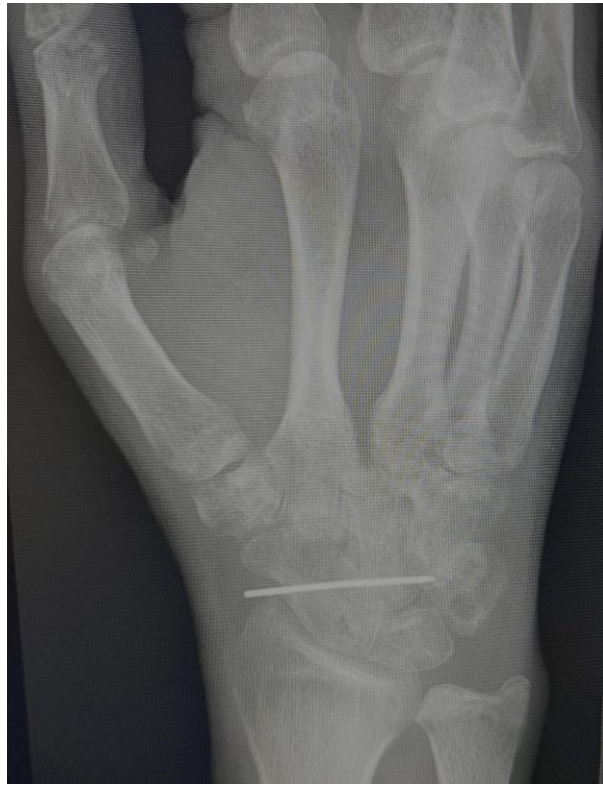
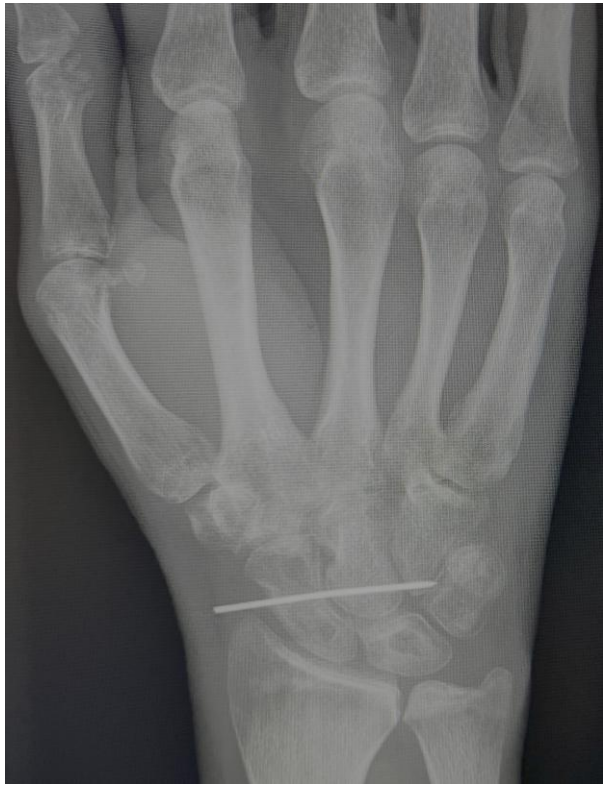Surgical Approach

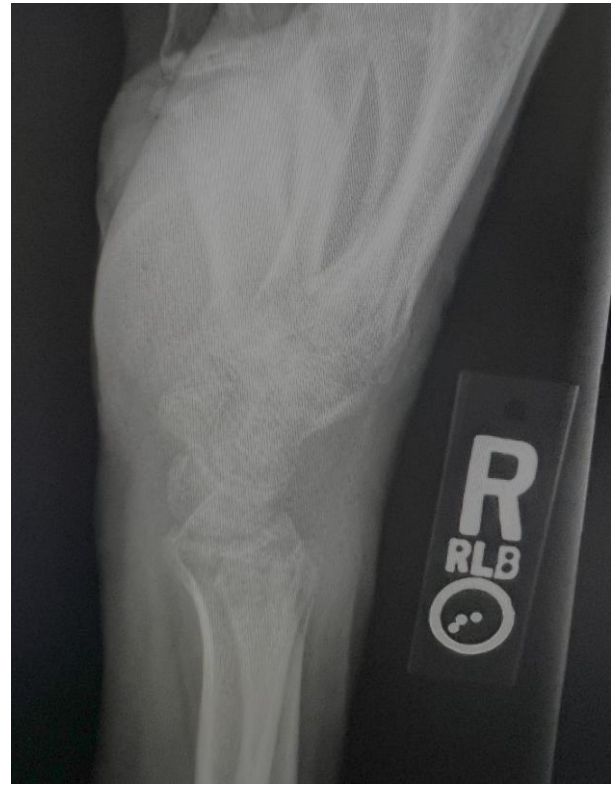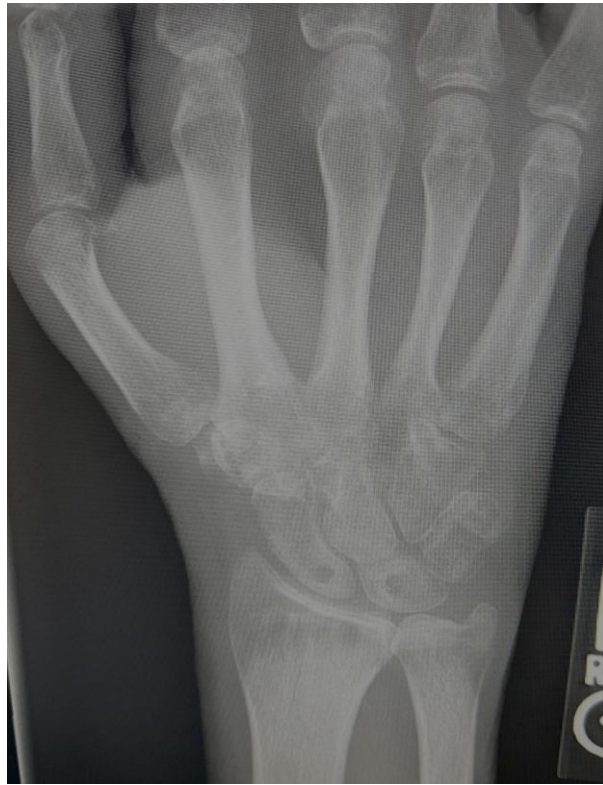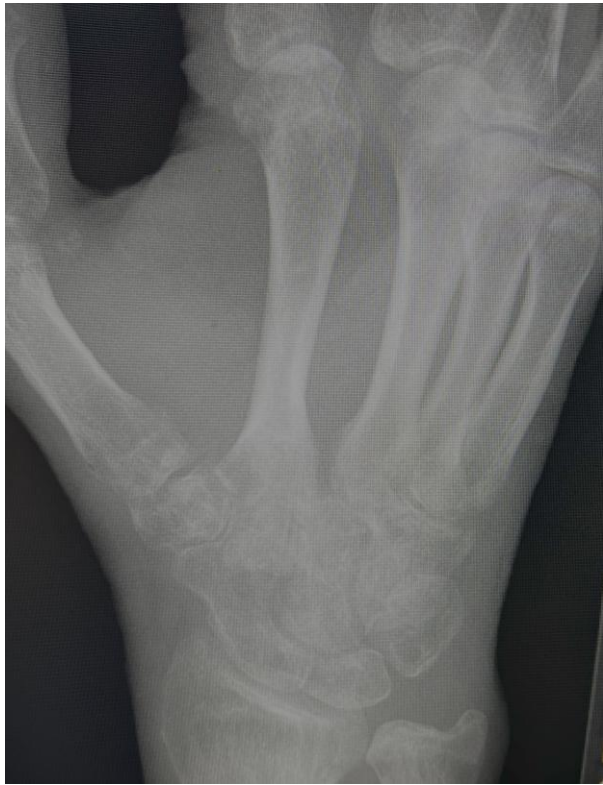Procedure

- R wrist SL ligament reconstruction + internal brace
 - Arthrex 3.5mm swivelock anchors and allograft tendon
 - Dorsal approach
- R CTR

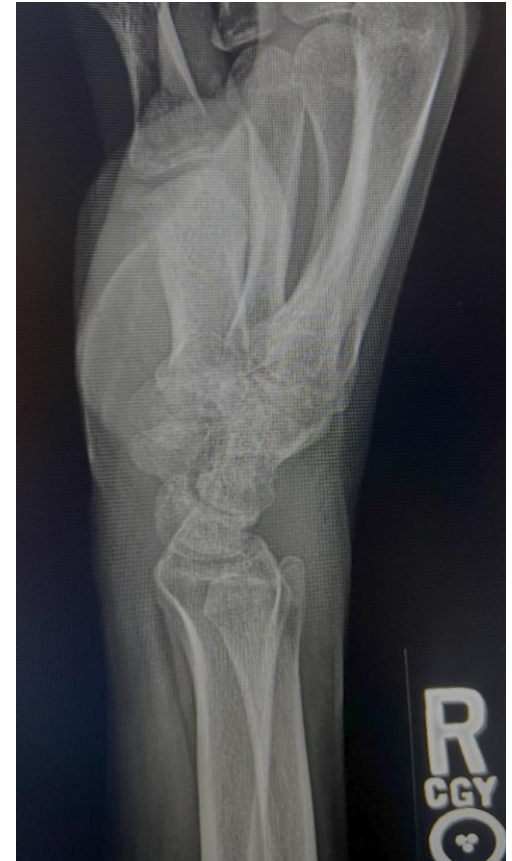
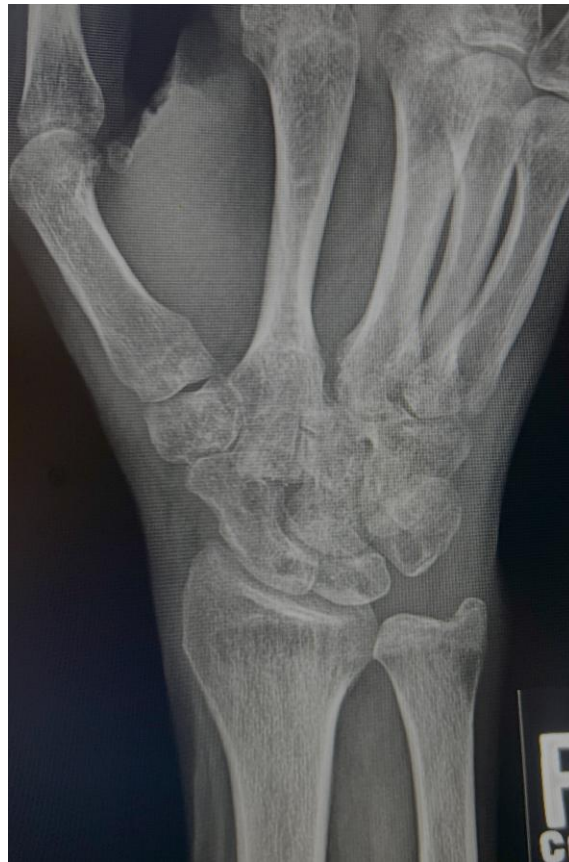
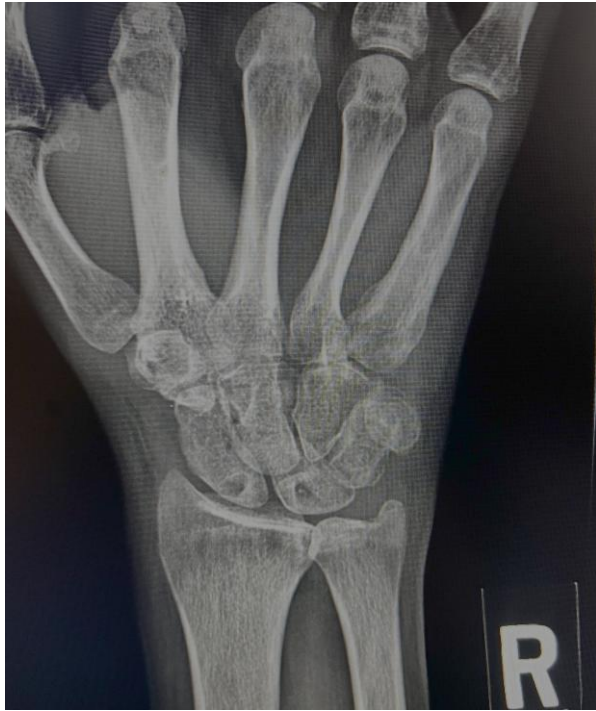

4 Weeks



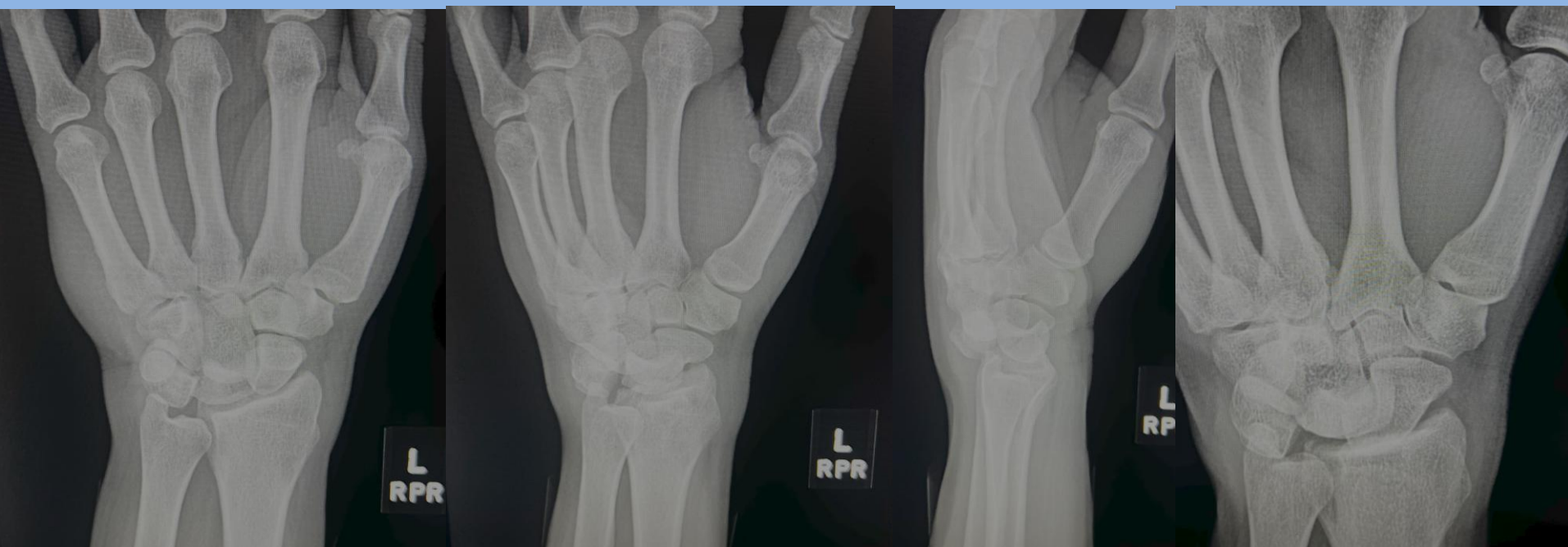6 weeks



4 months

Case 2

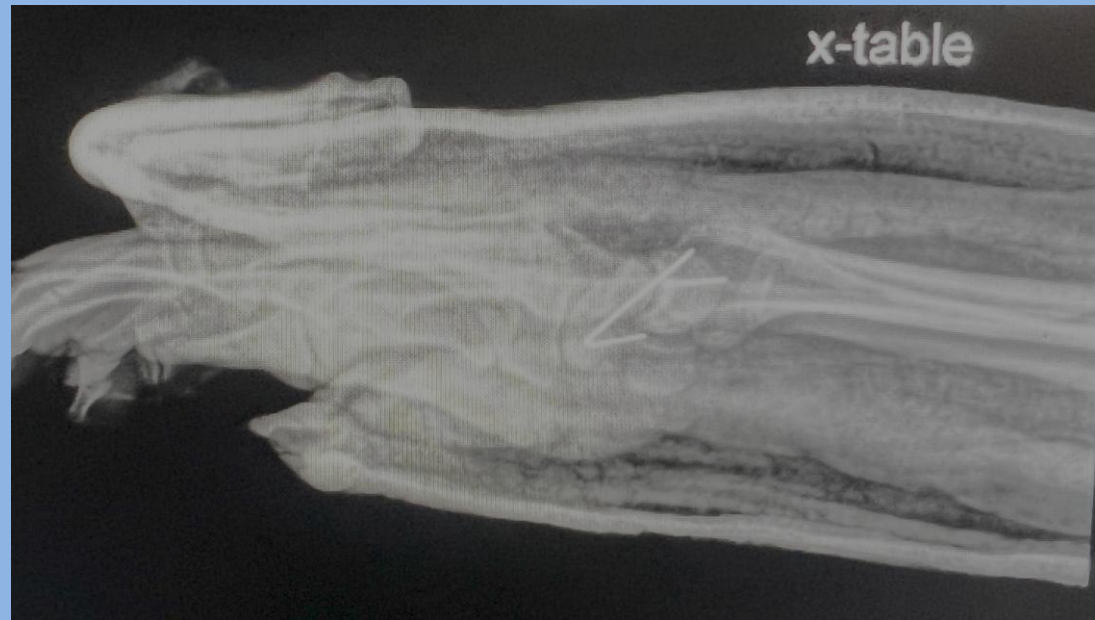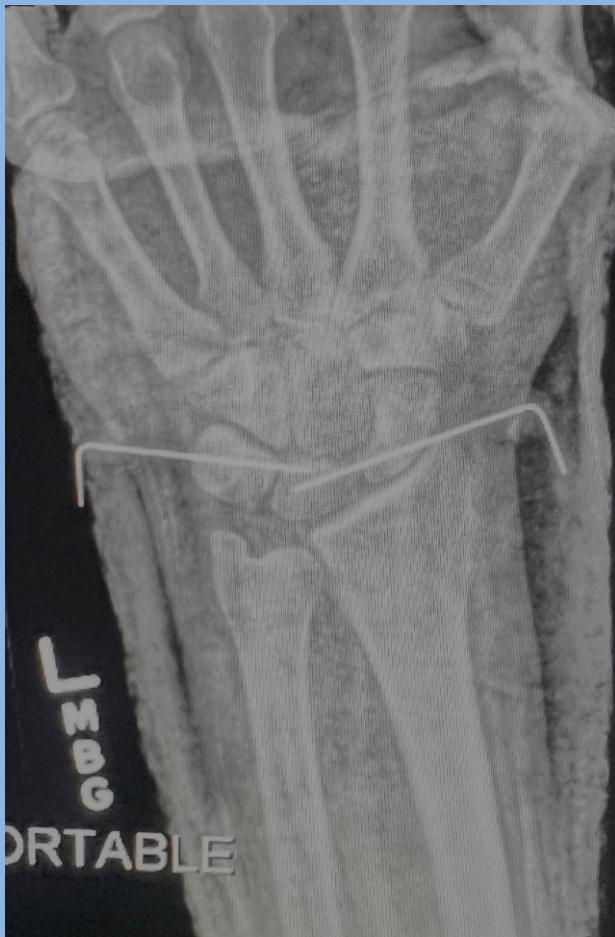- 47-year-old RHD man s/p fall down several stairs



Management?

Management

- Taken to OR for reduction and emergent CTR

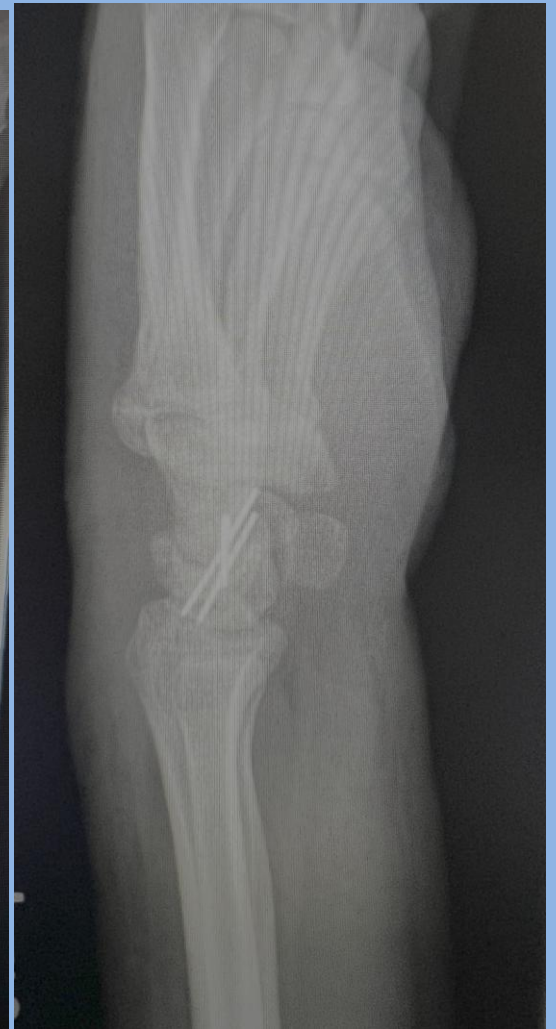
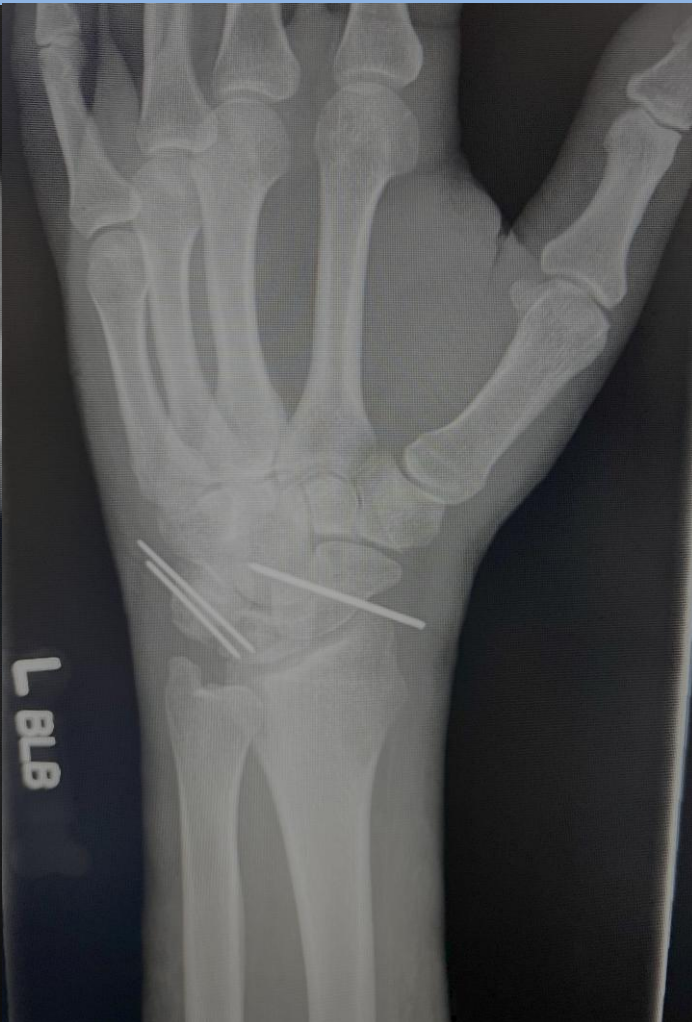
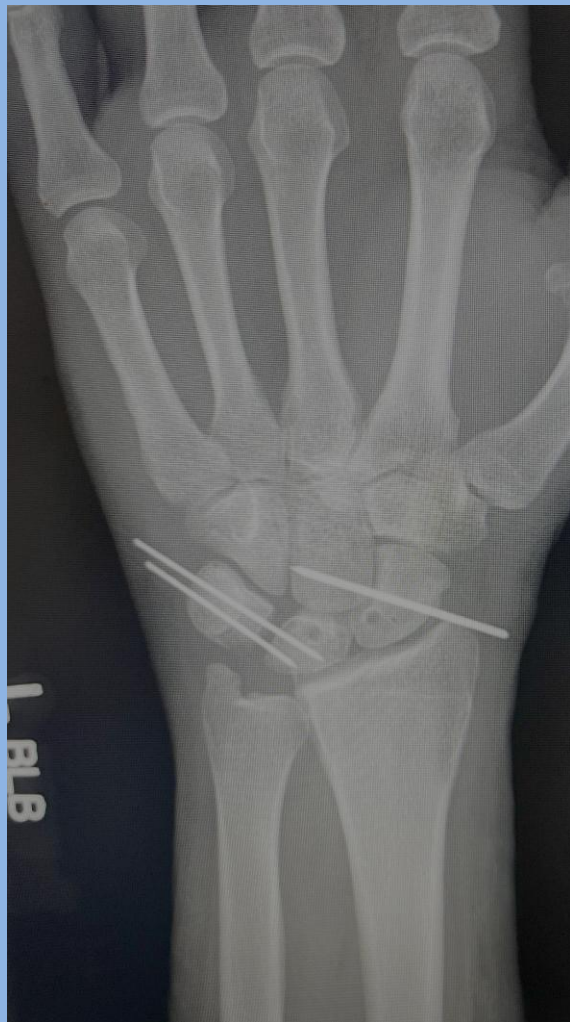Is this enough?

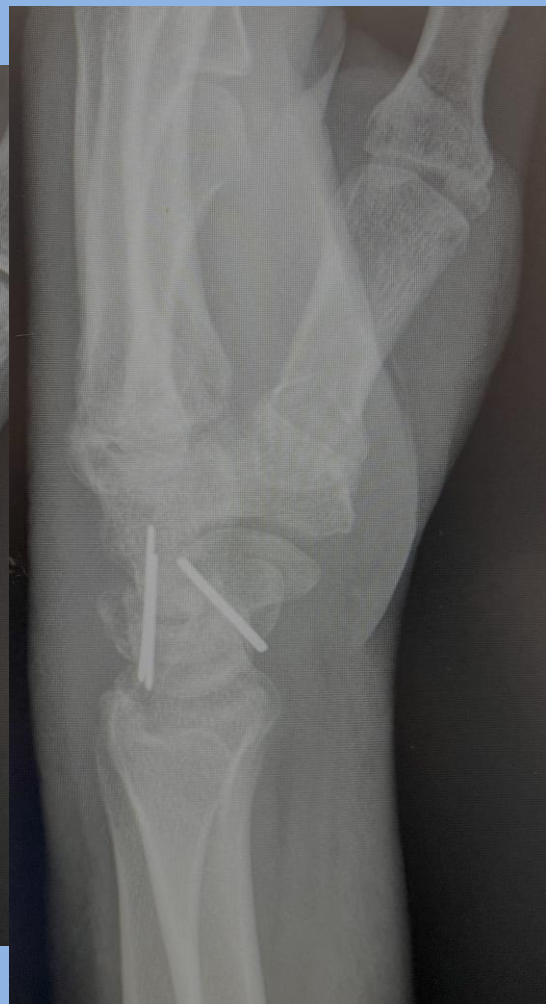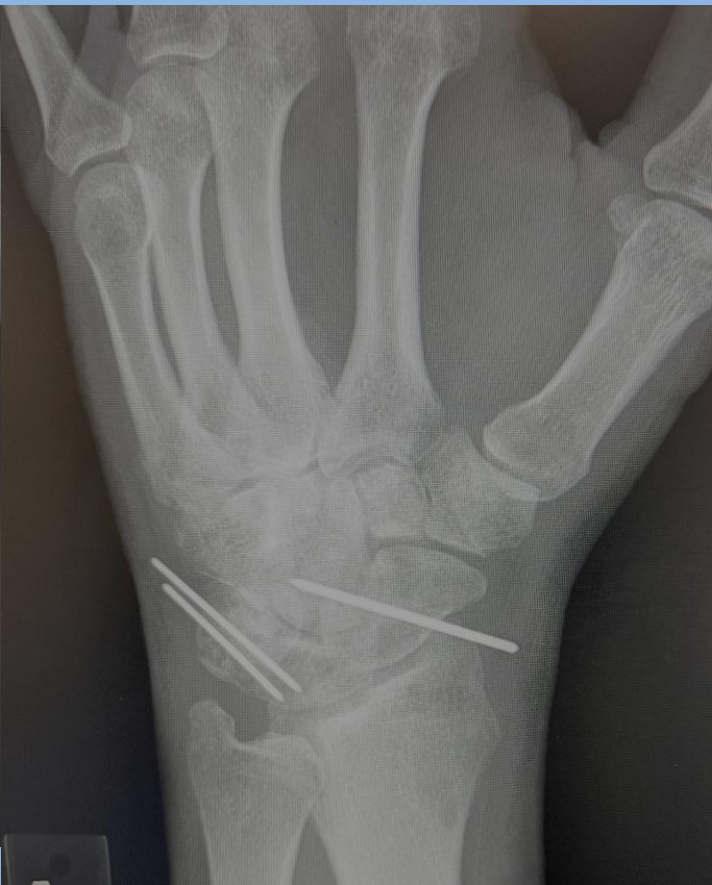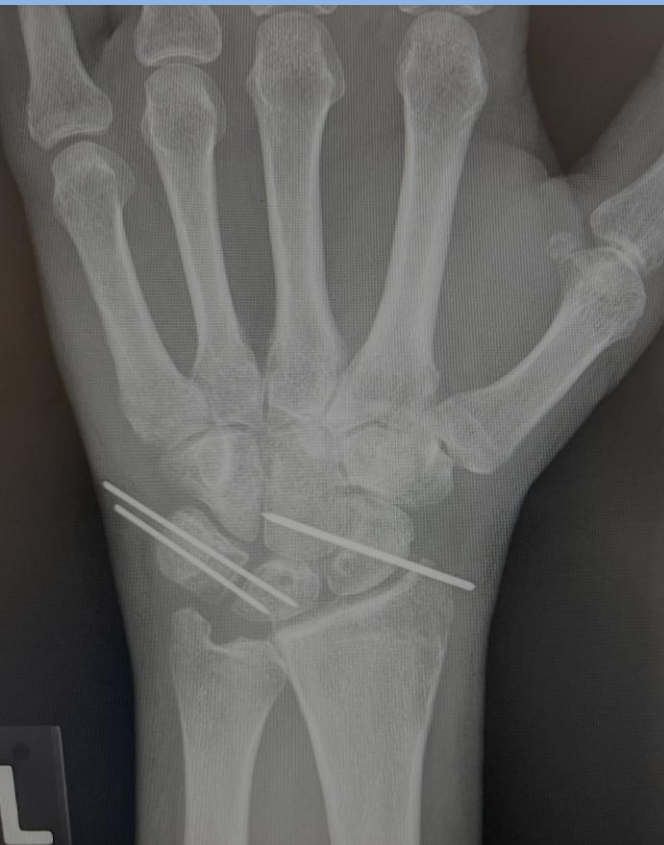Procedure #2

- Findings: Complete tear of LT and nearly complete SL ligament tear
 - Open reconstruction of SL ligament
 - Arthrex fiber tape (no graft)
- Pinning of LT joint for LT instability

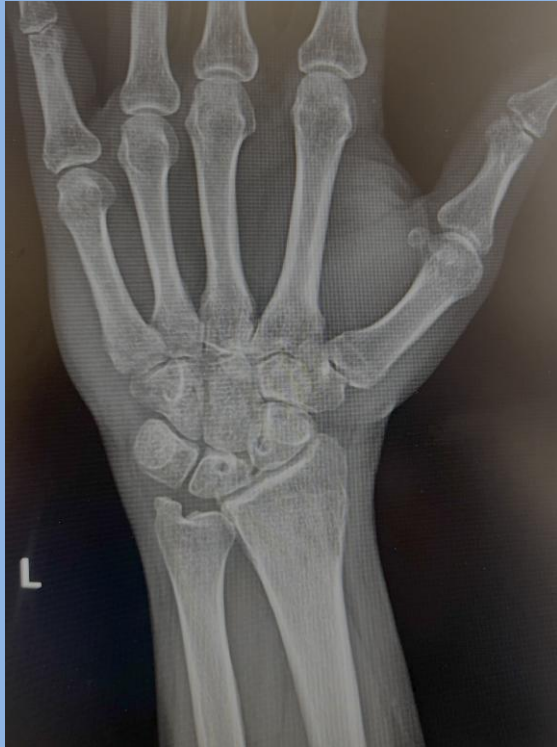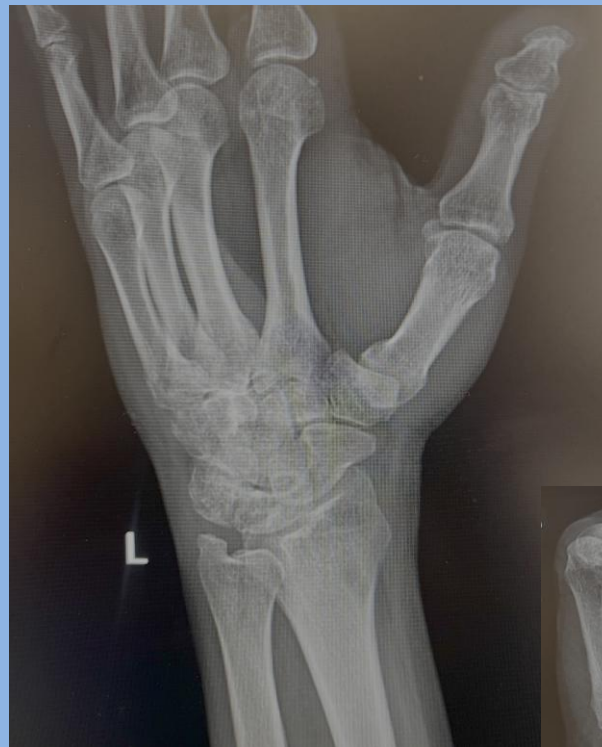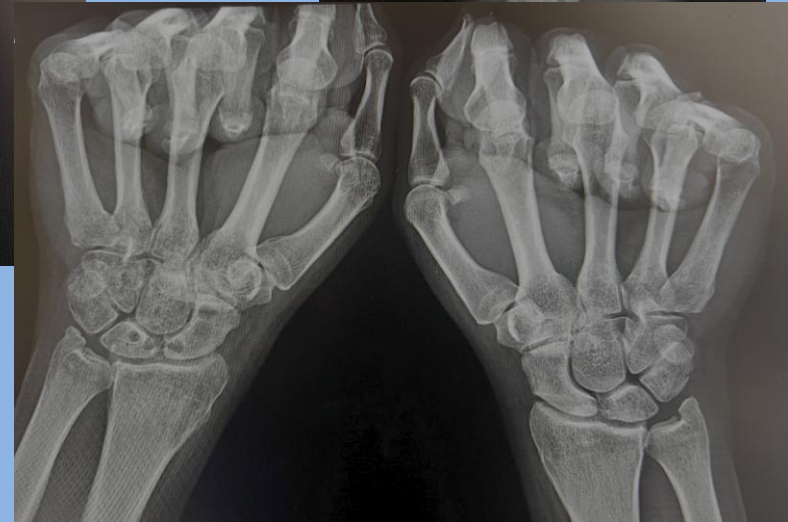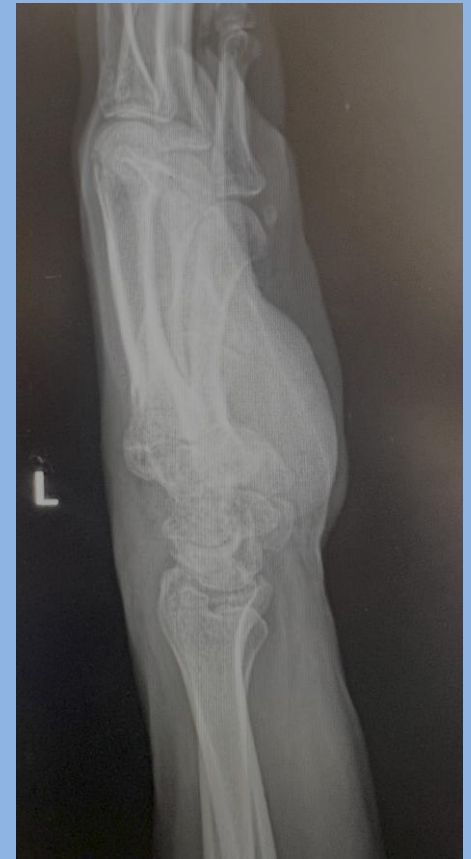2 weeks



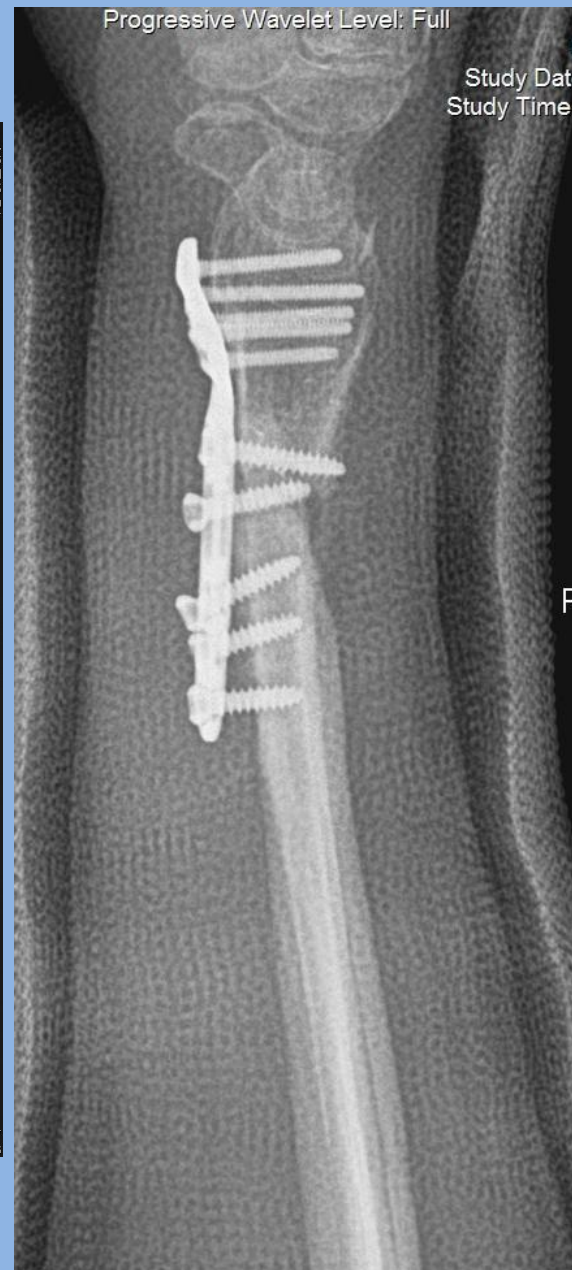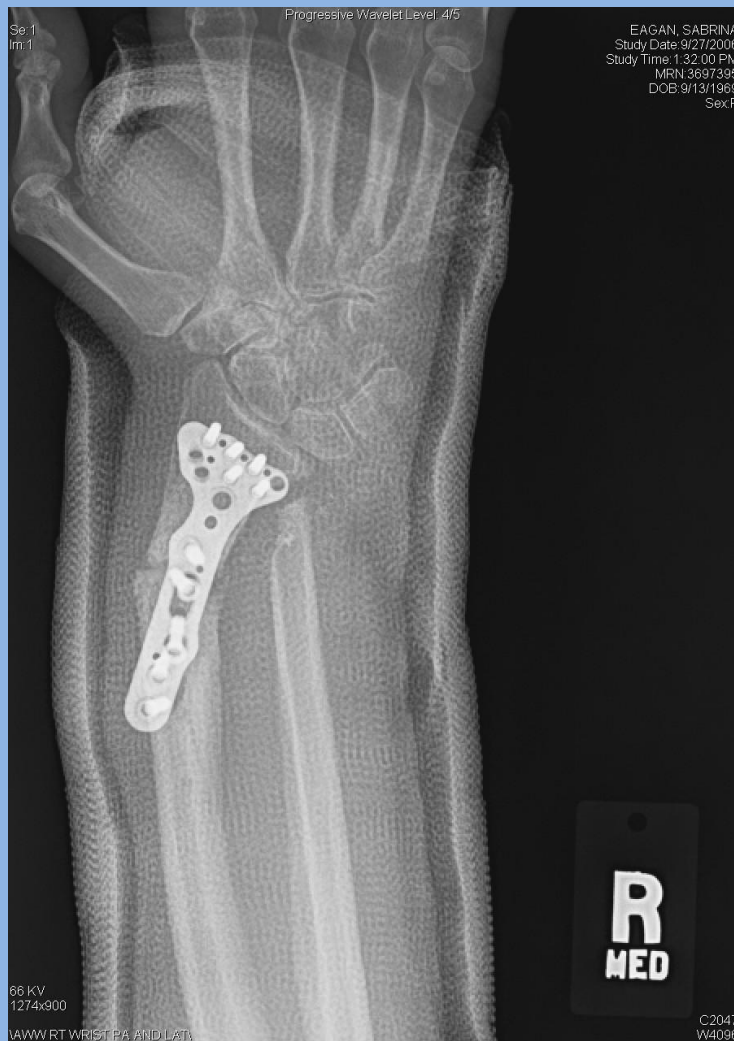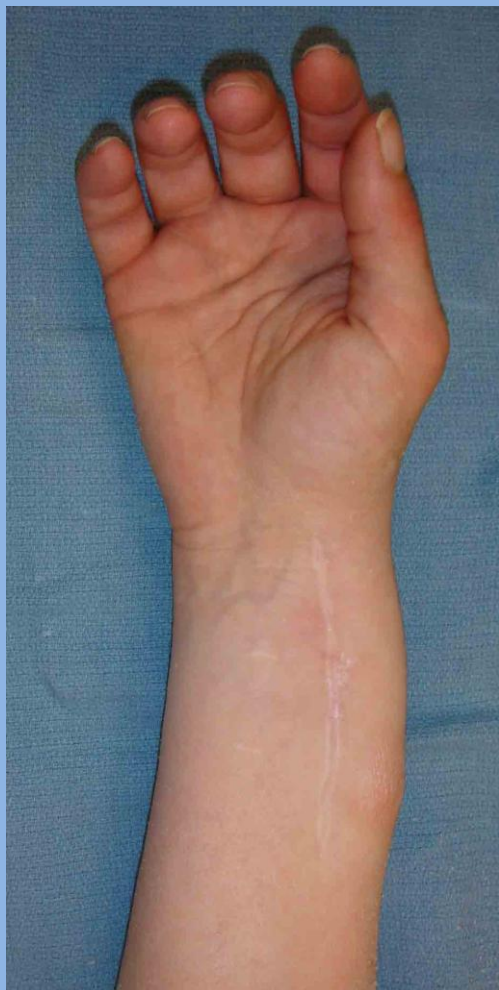
2 months



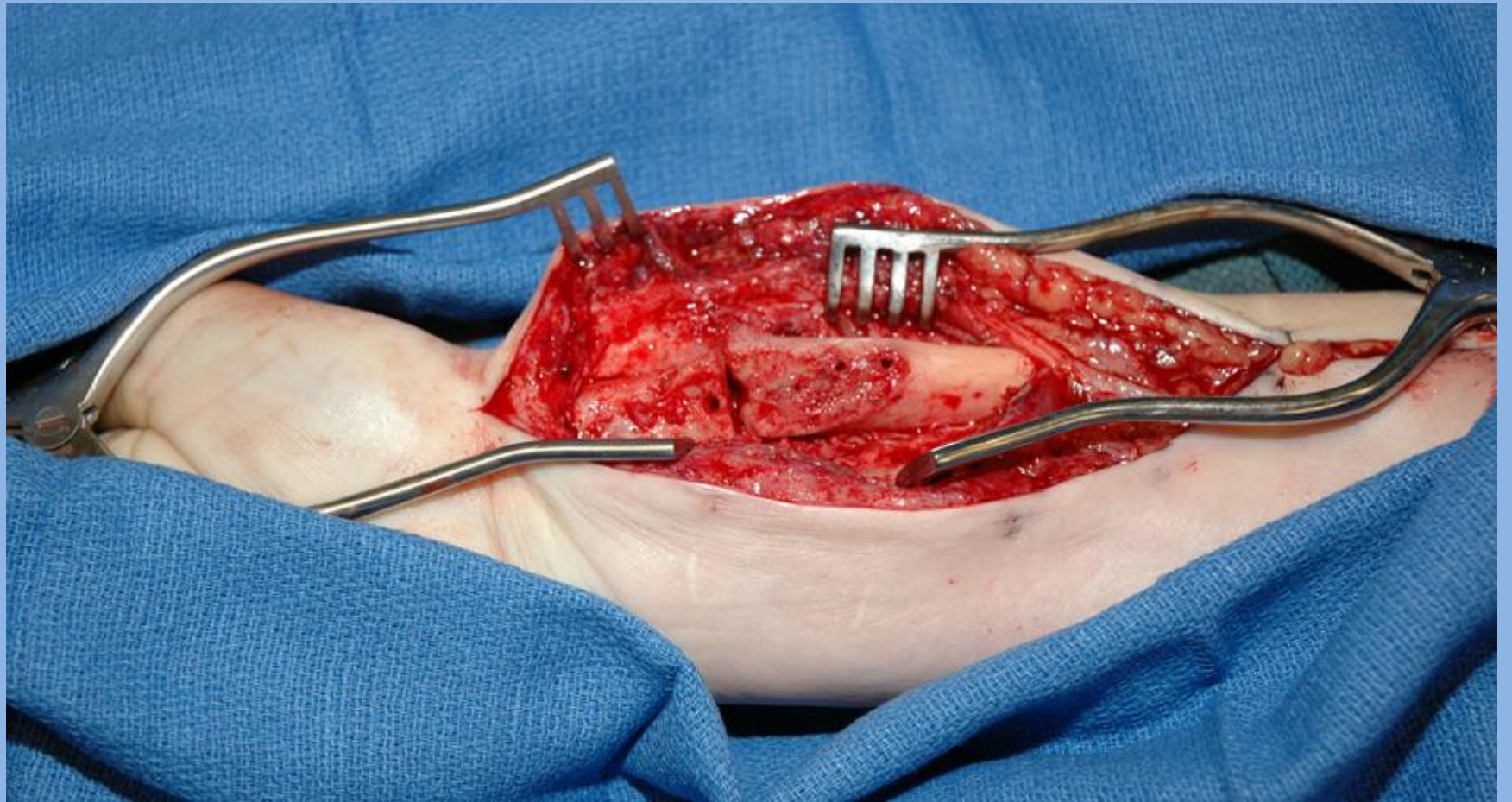
14 months



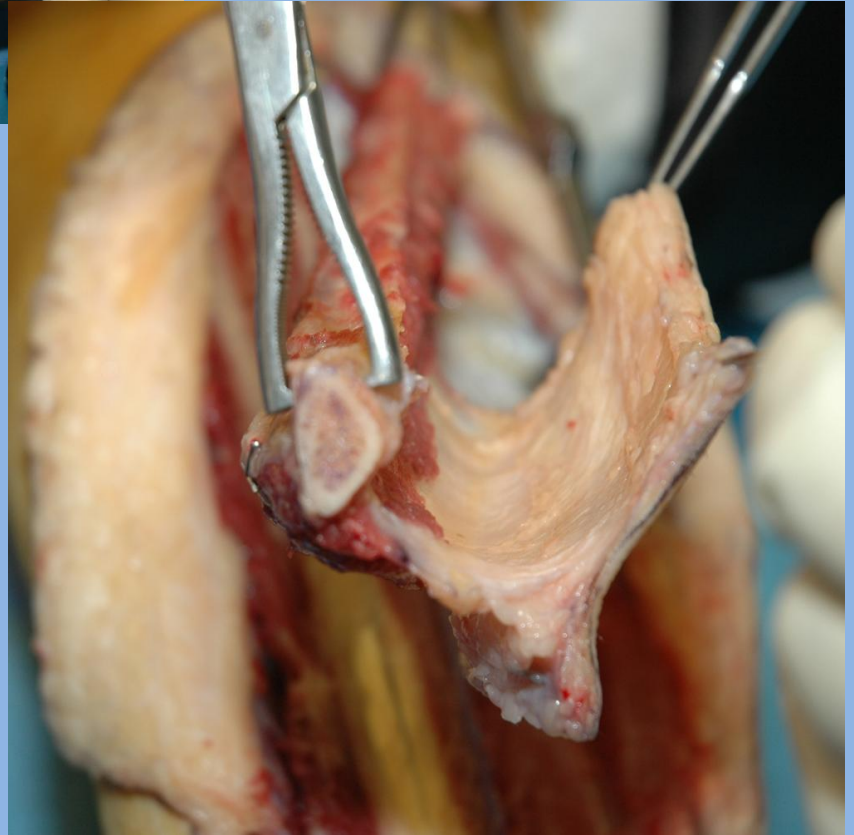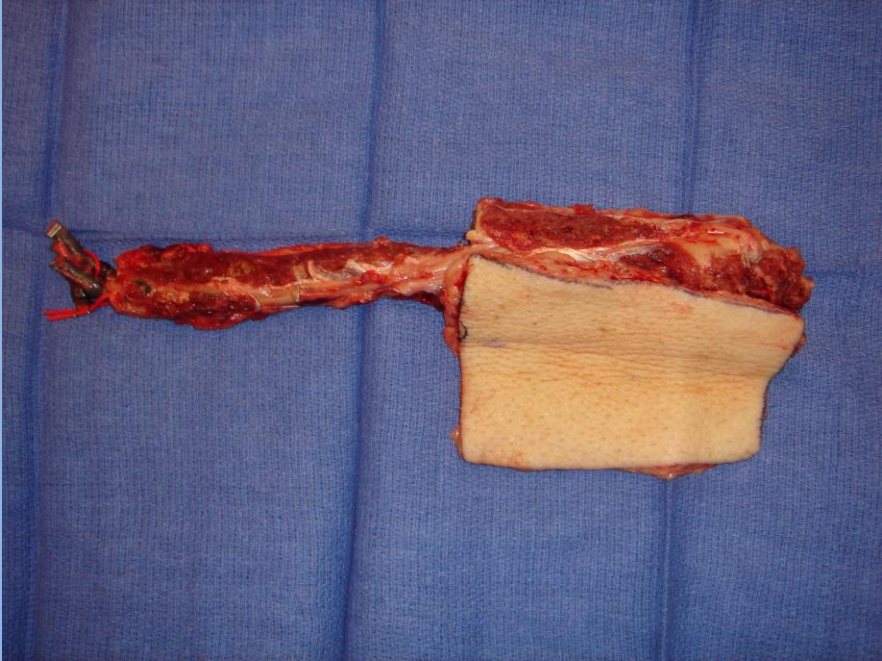
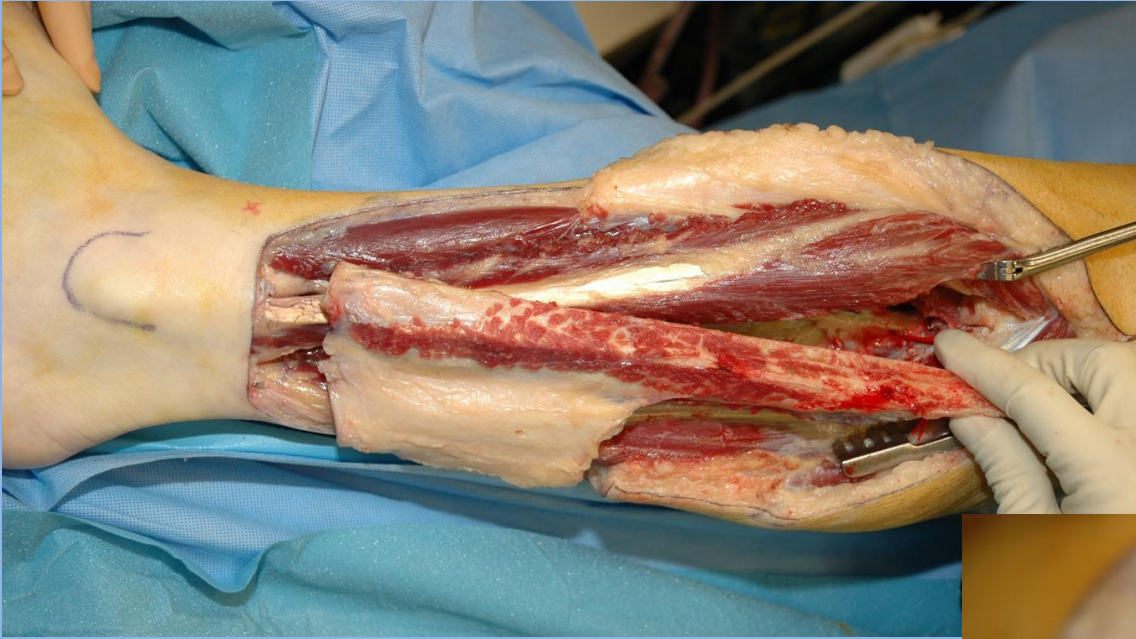- 38 y.o. RHD female
- R wrist pain

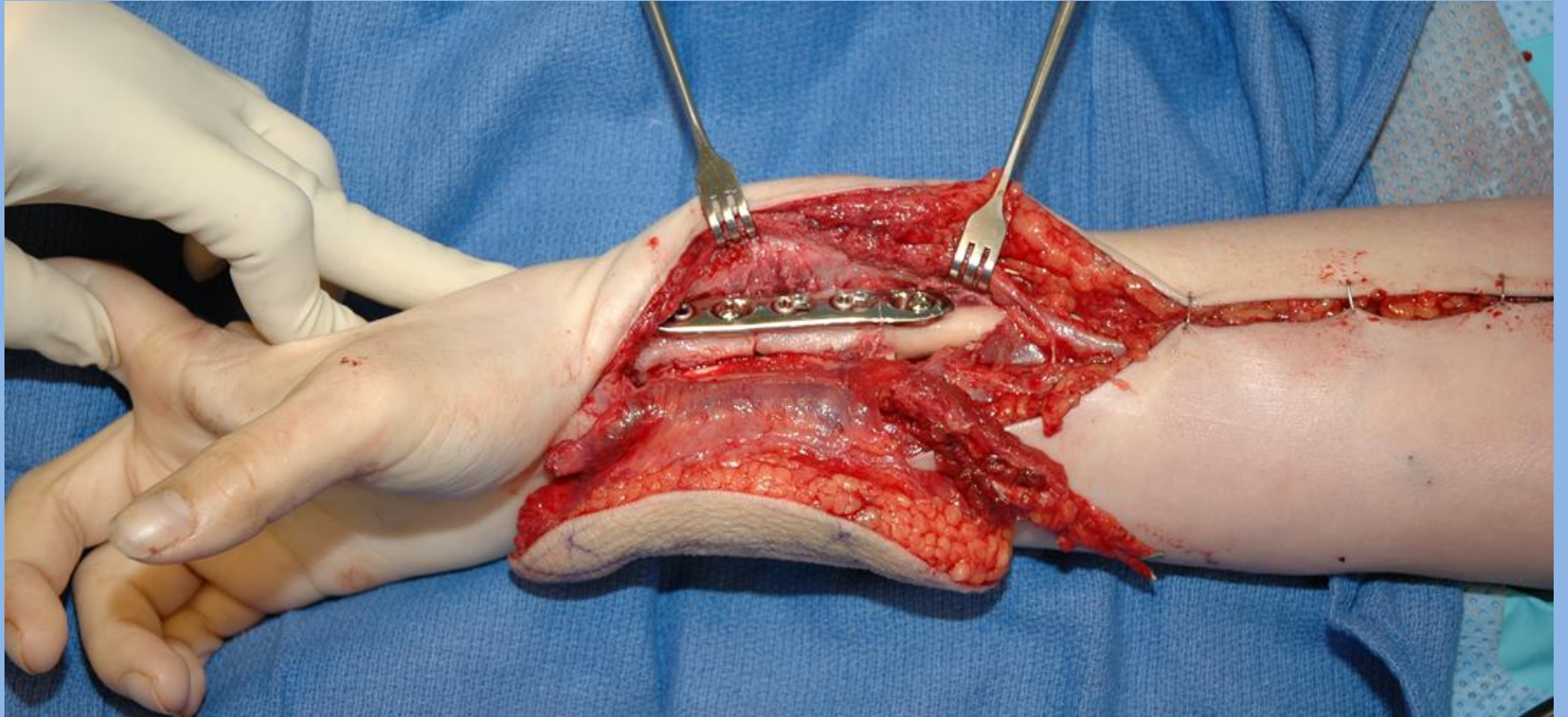


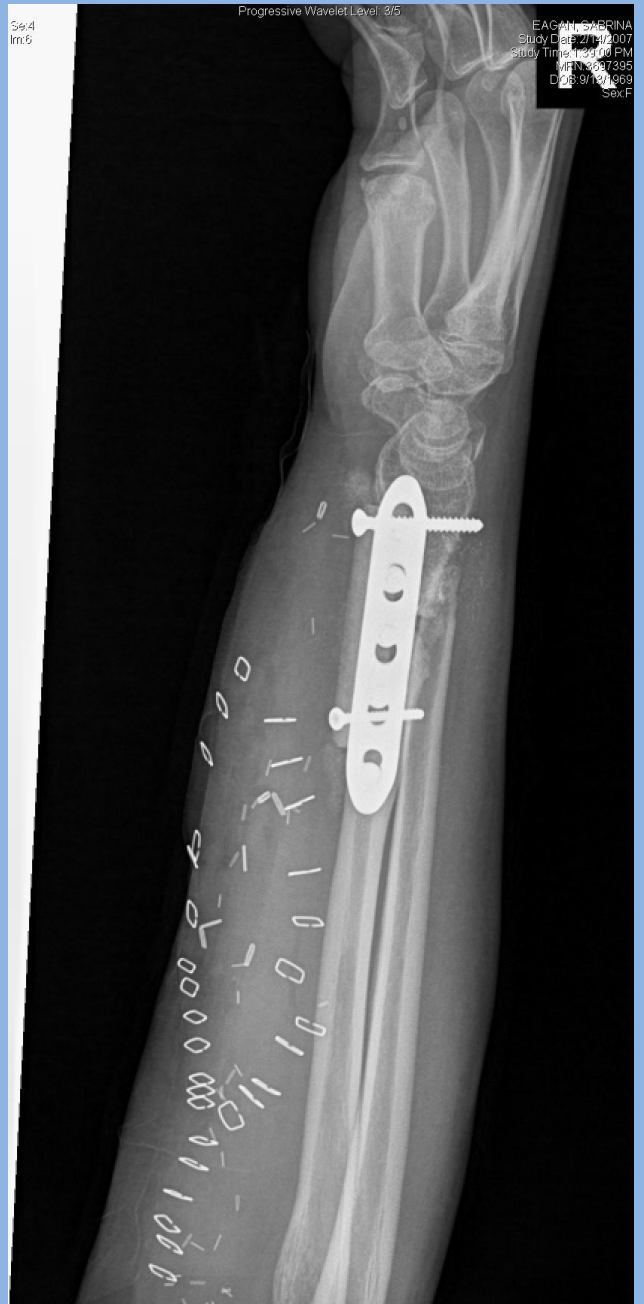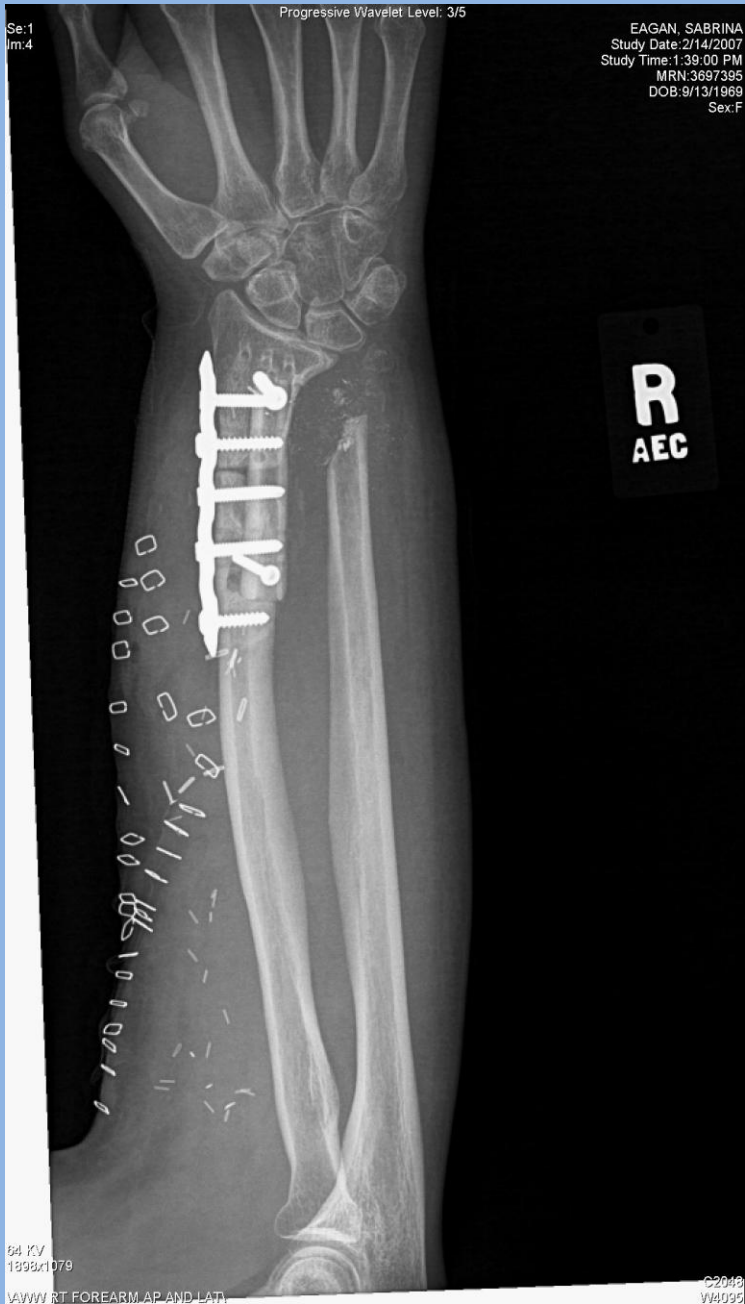Management?

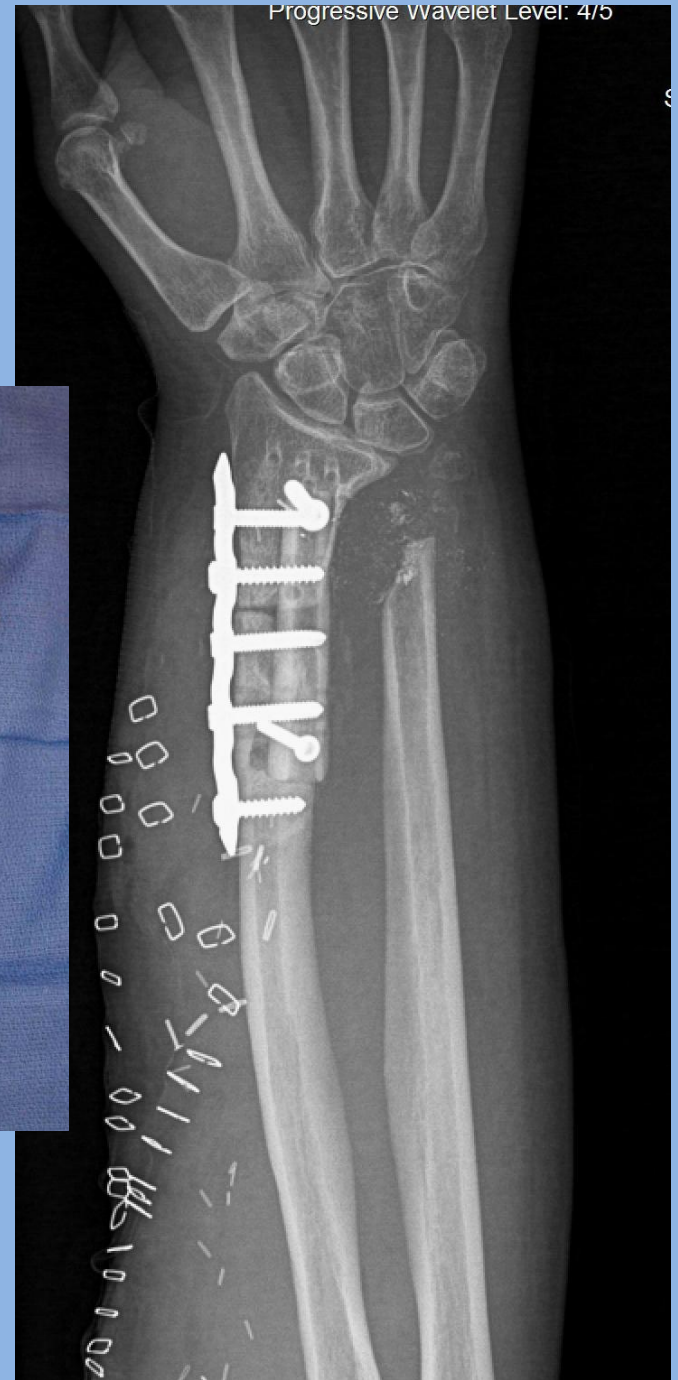
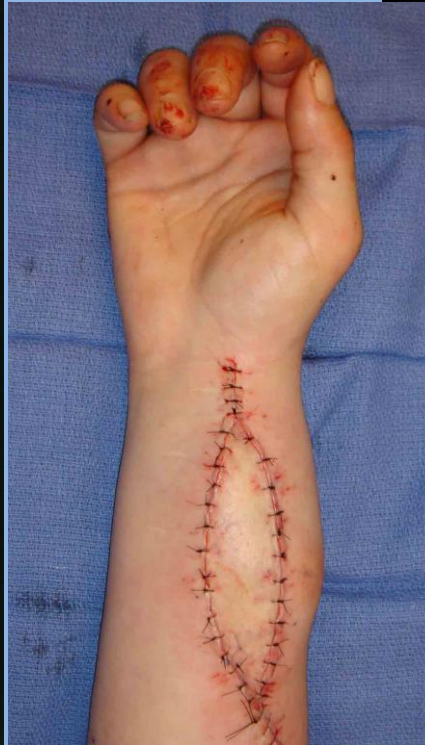
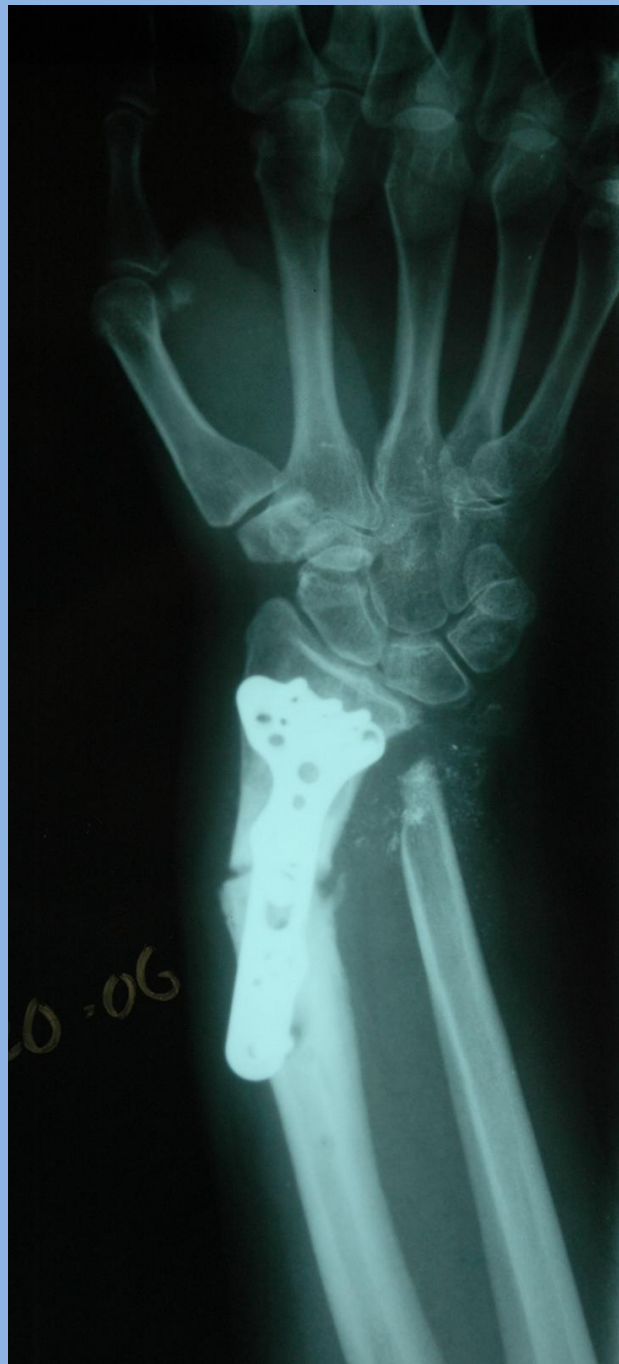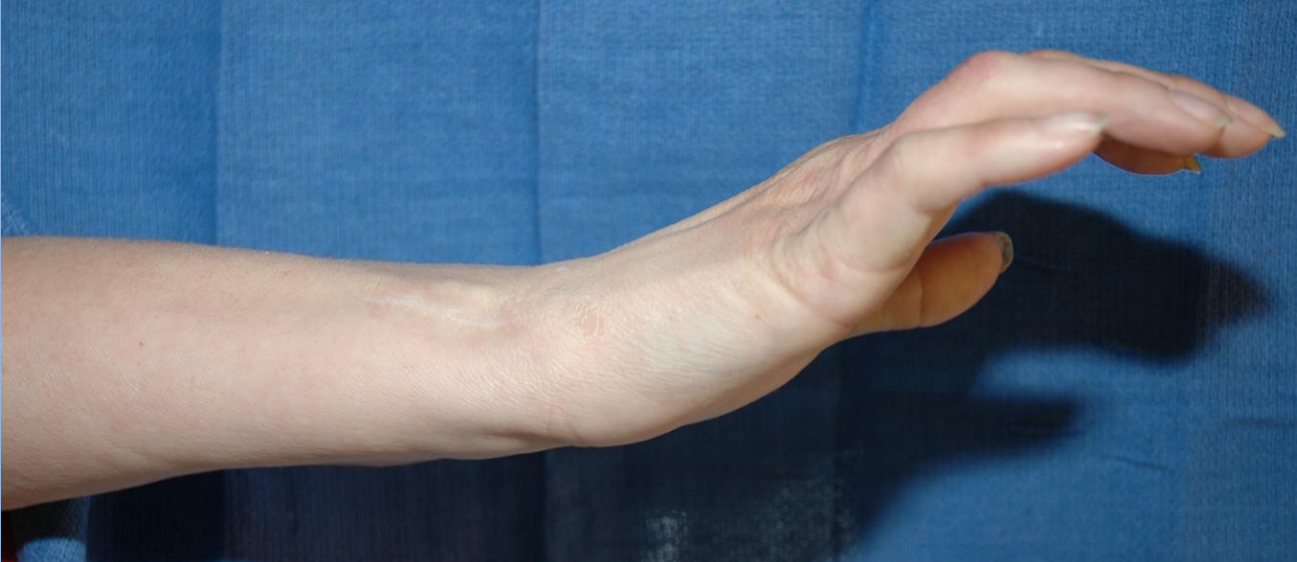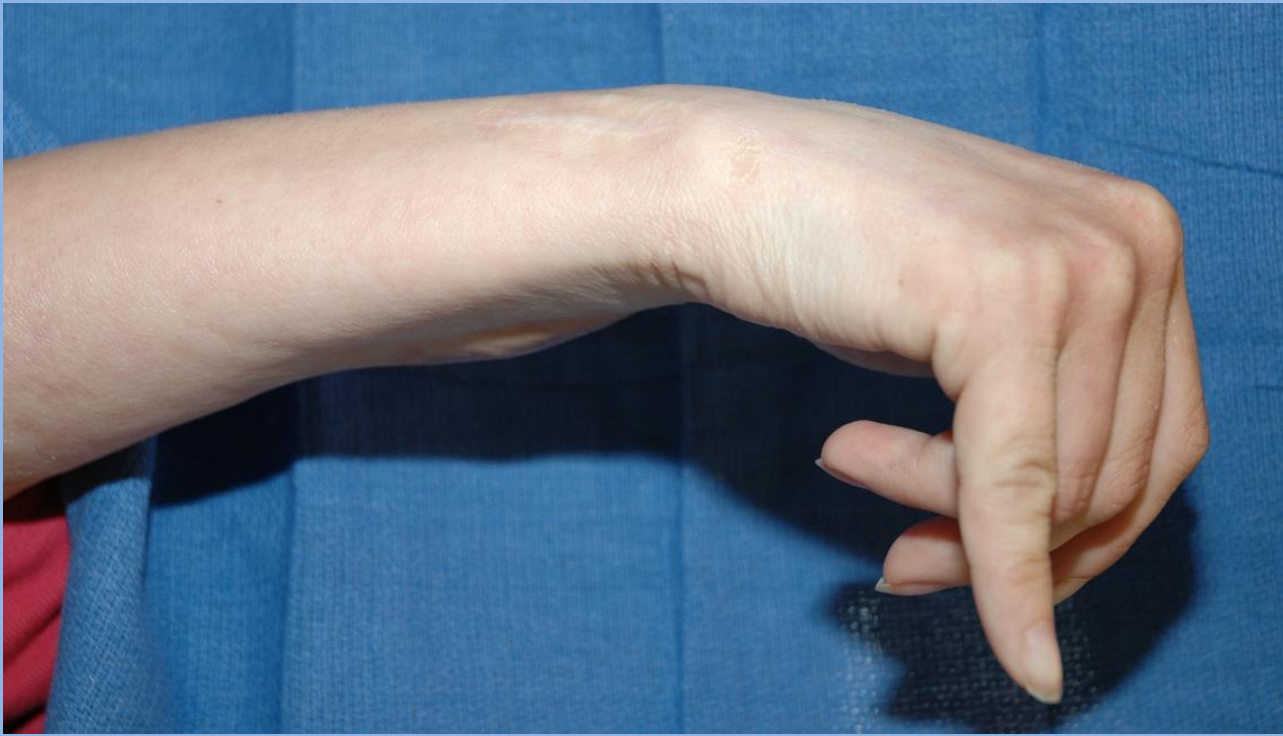
Options?





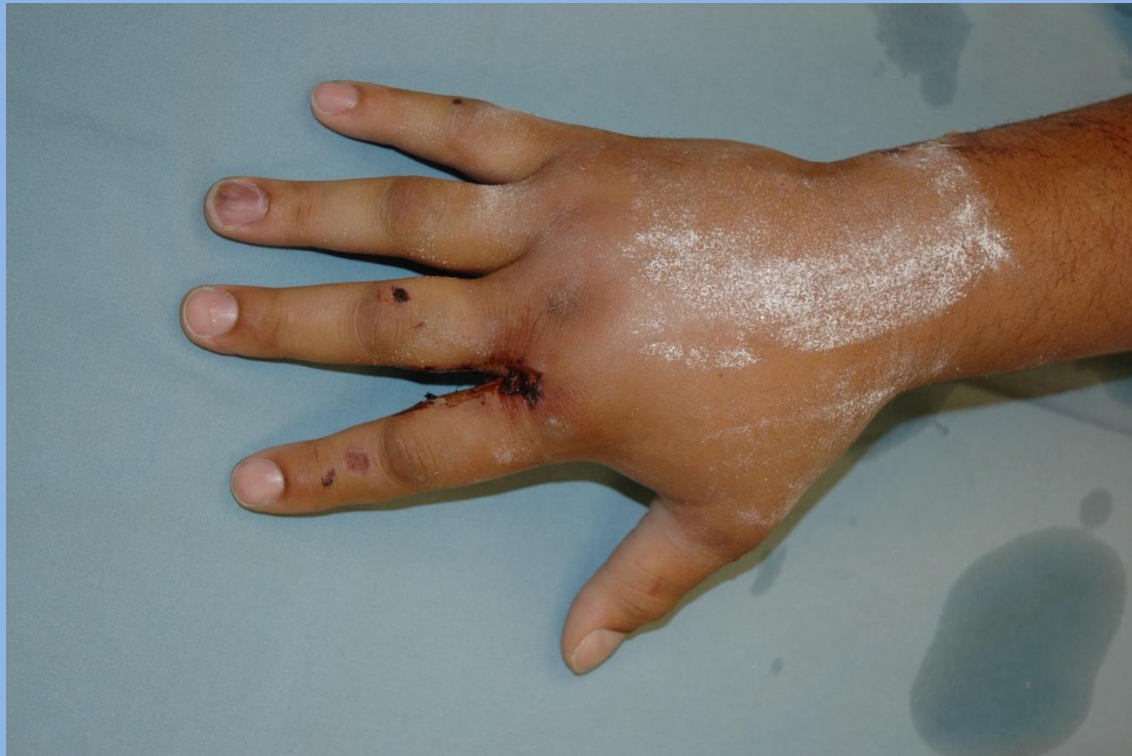


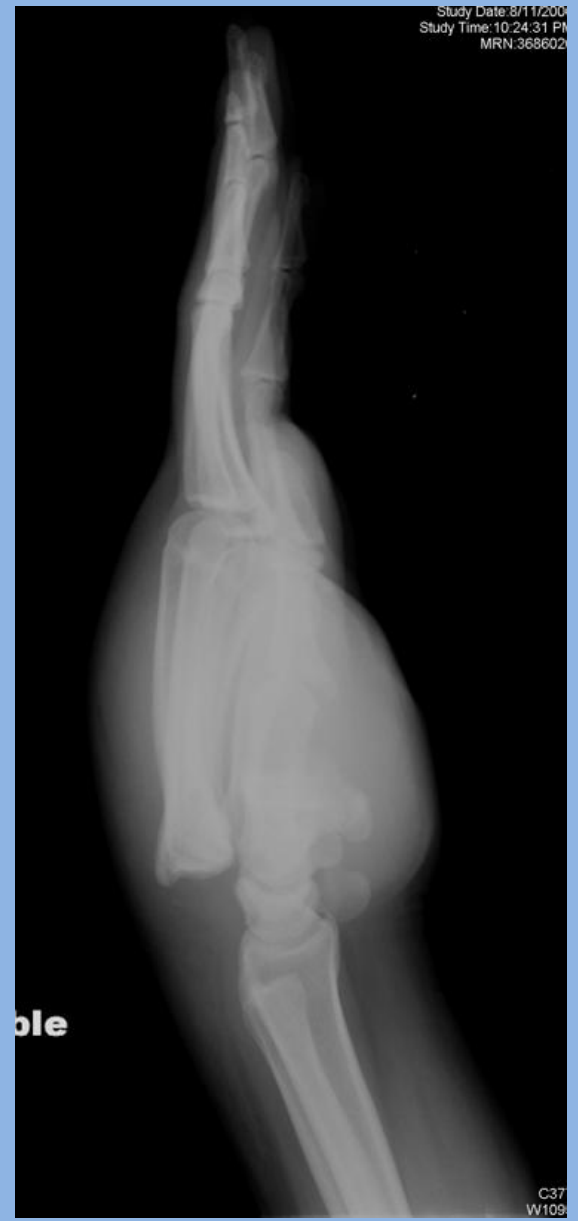
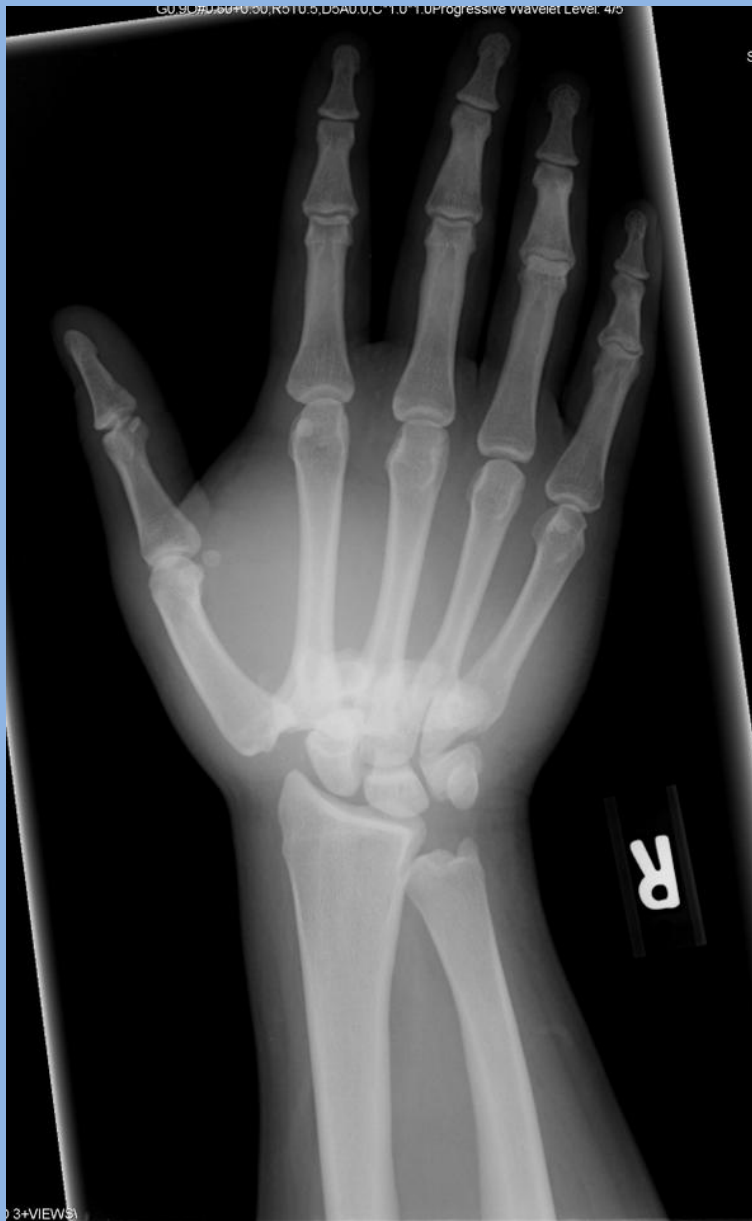

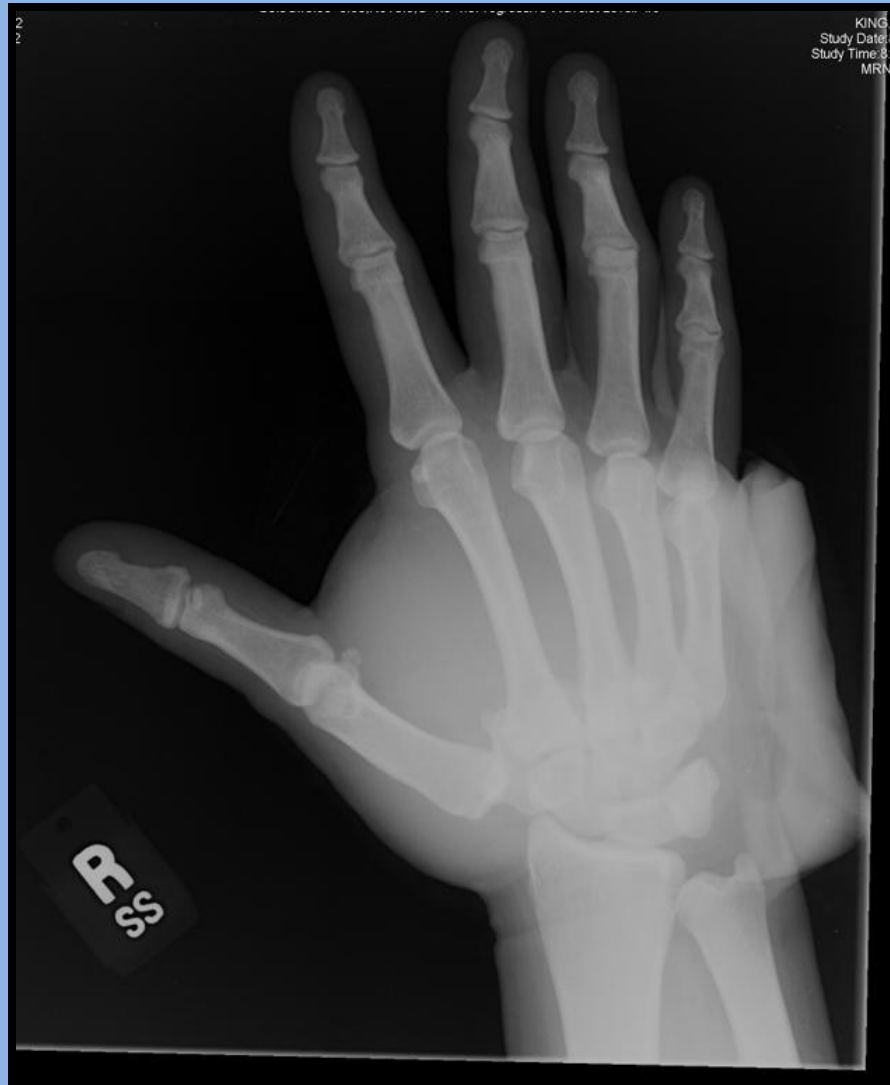Case

- 29 year old male s/p MCA presents to ER with R hand pain

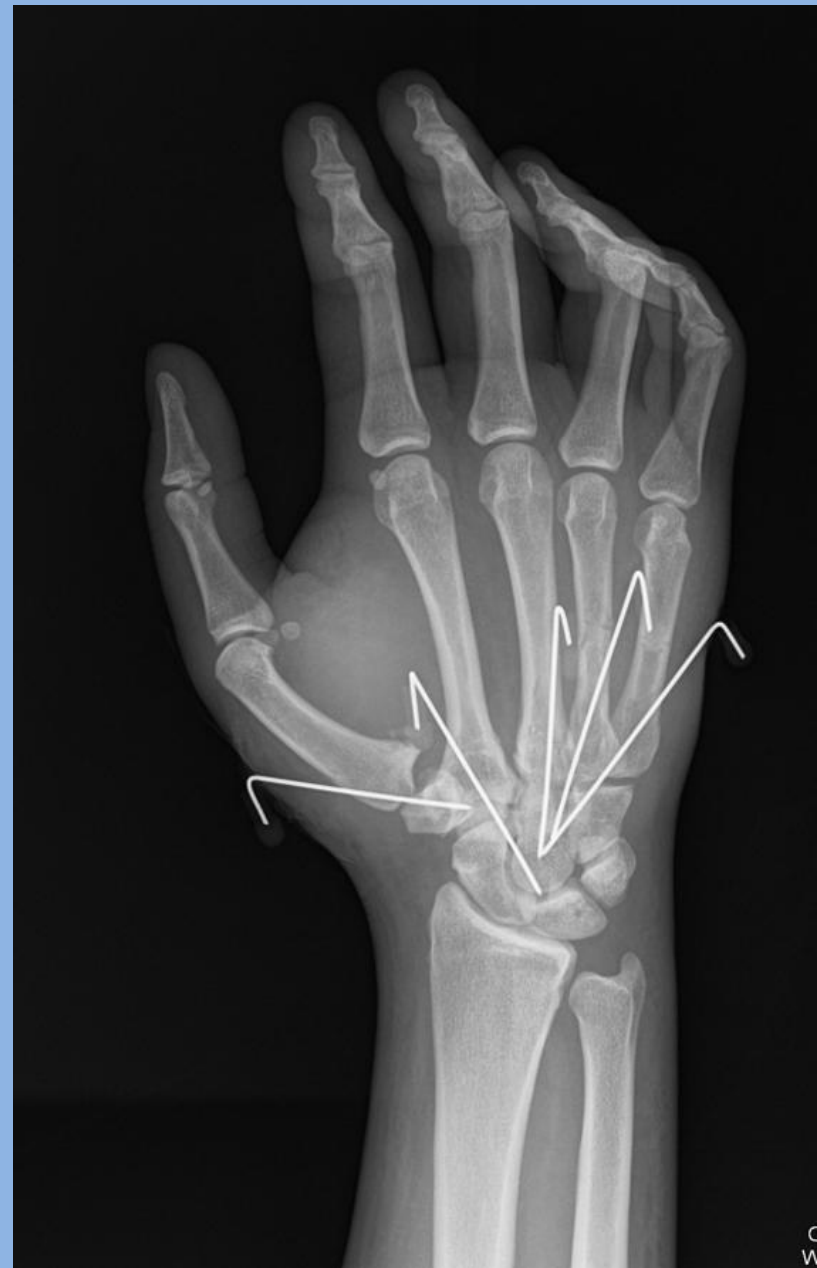
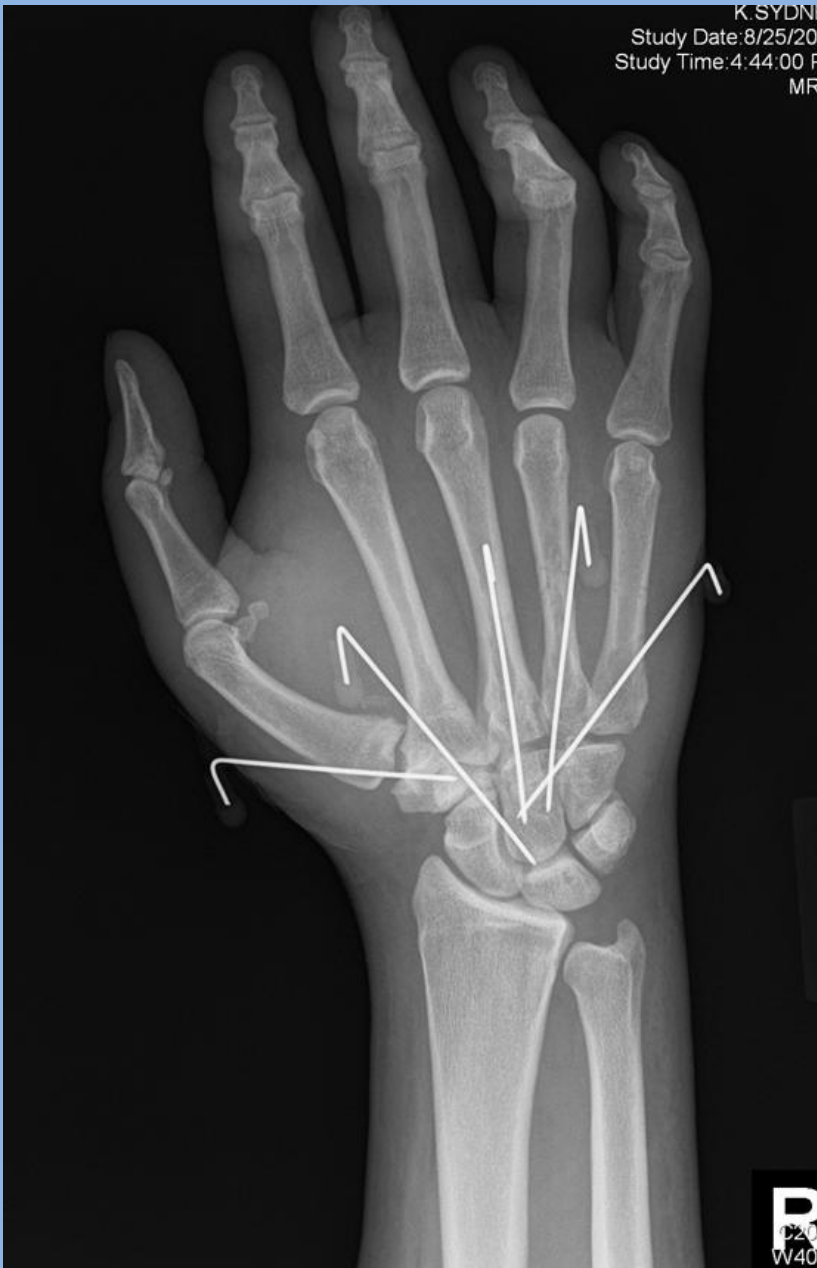


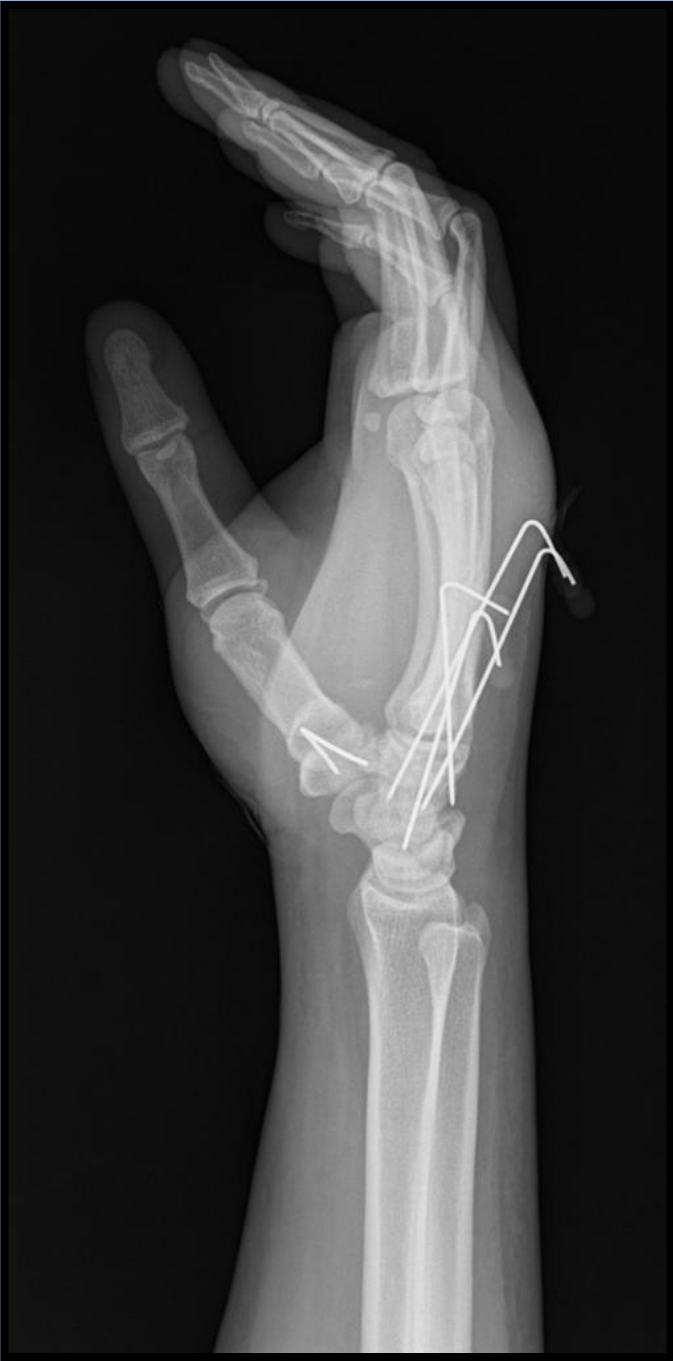Management?



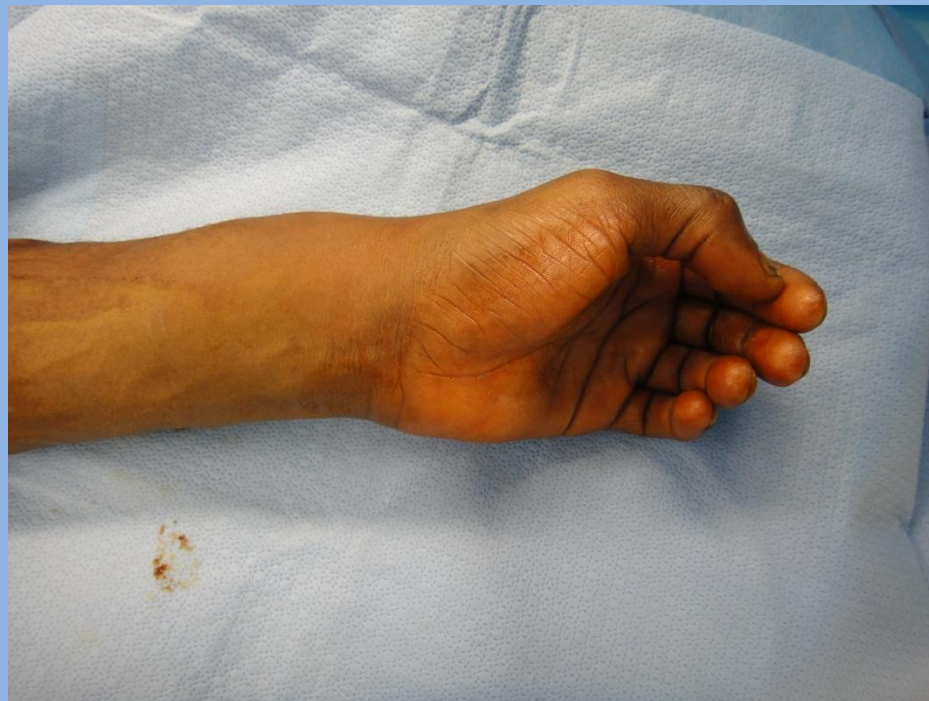K. SYDNI
Study Date: 8/25/20
Study Time: 4:44:00 P
MR

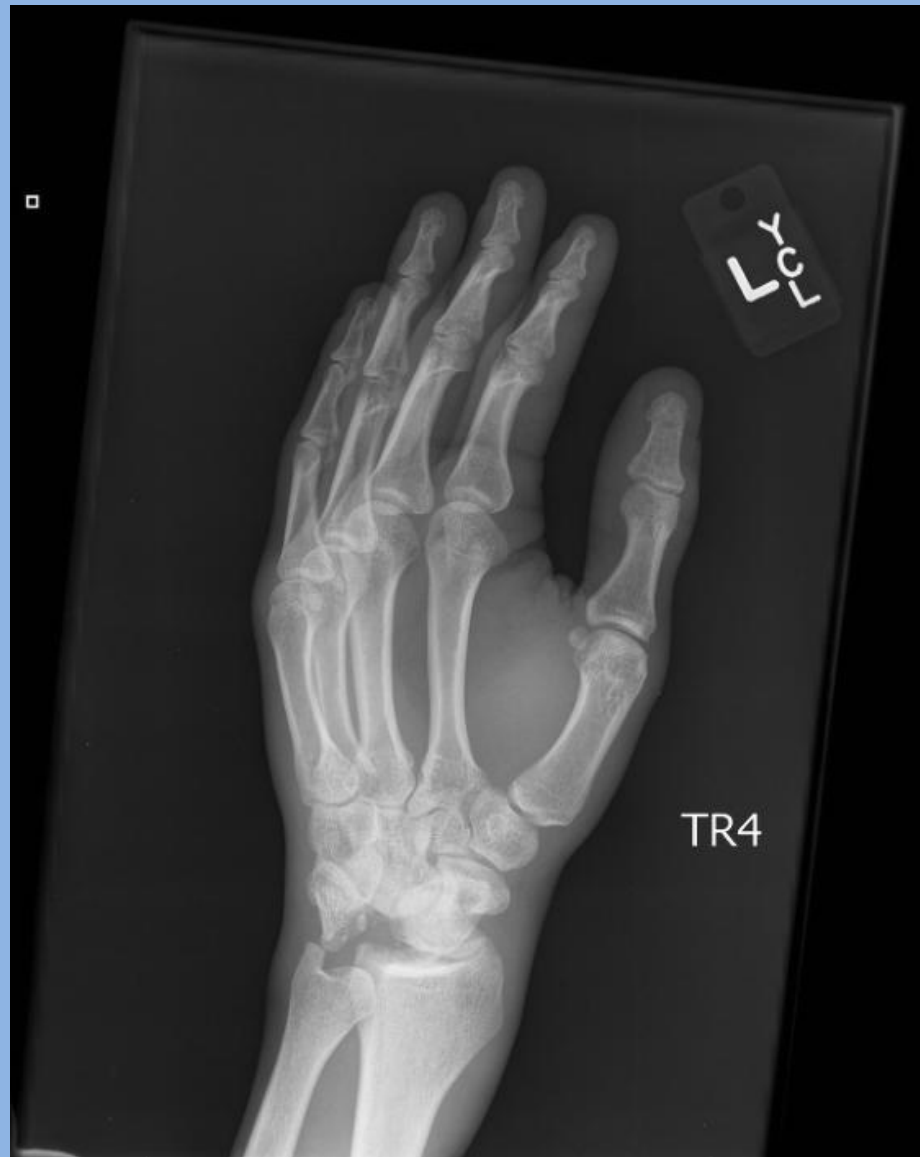
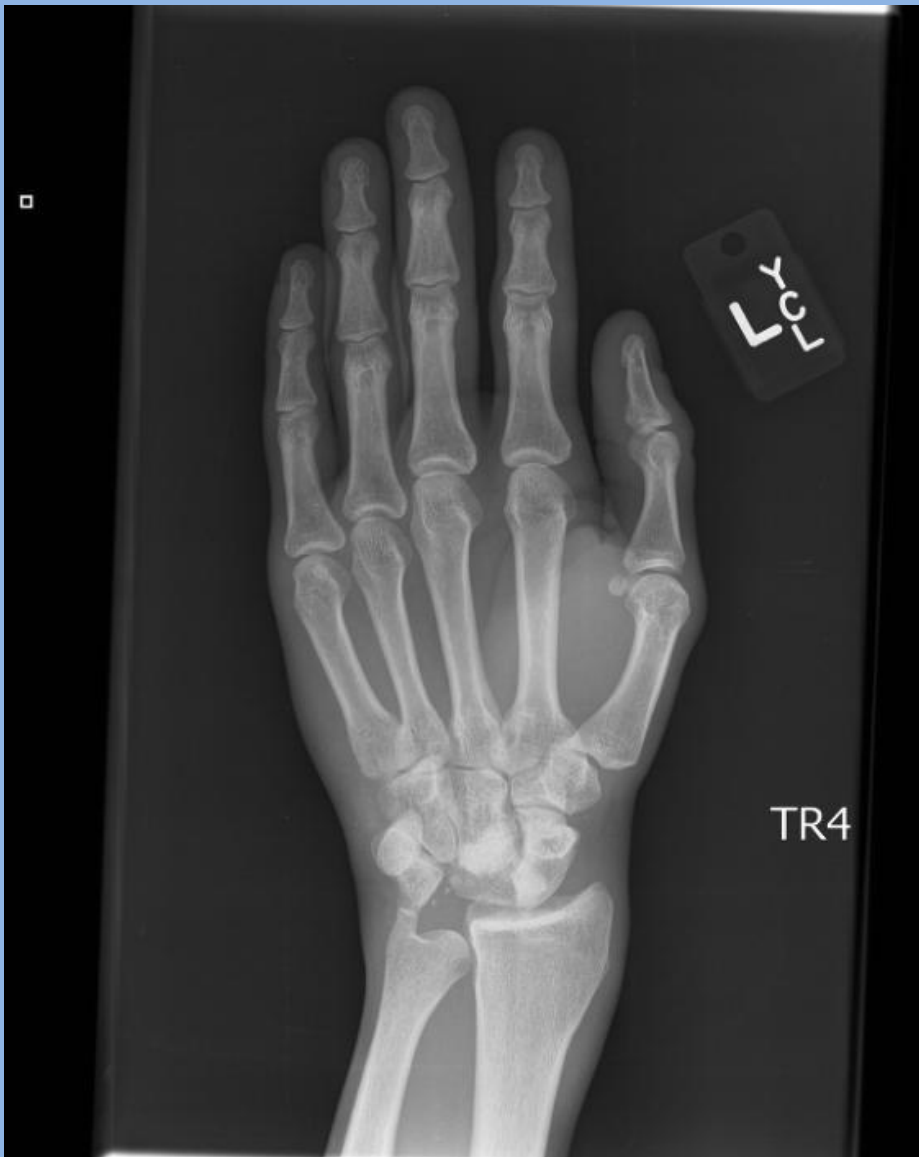


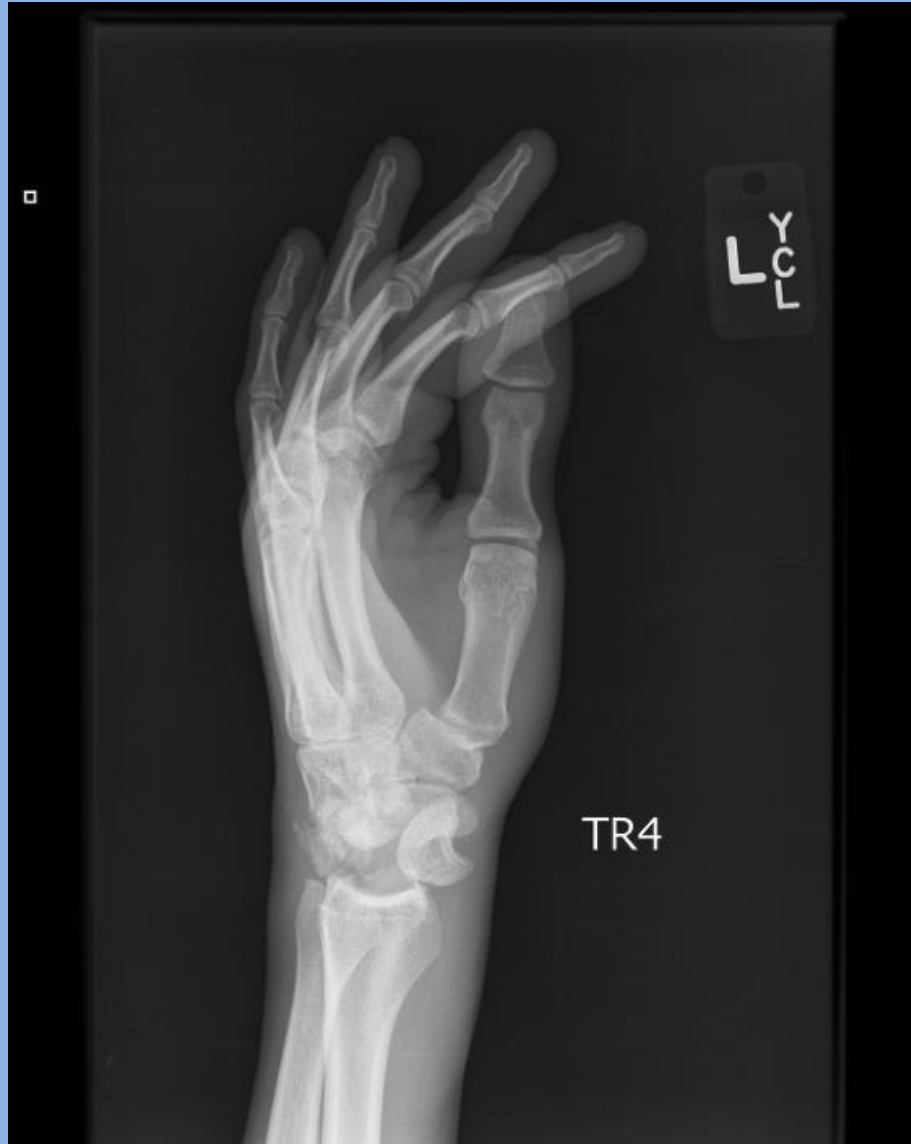Case

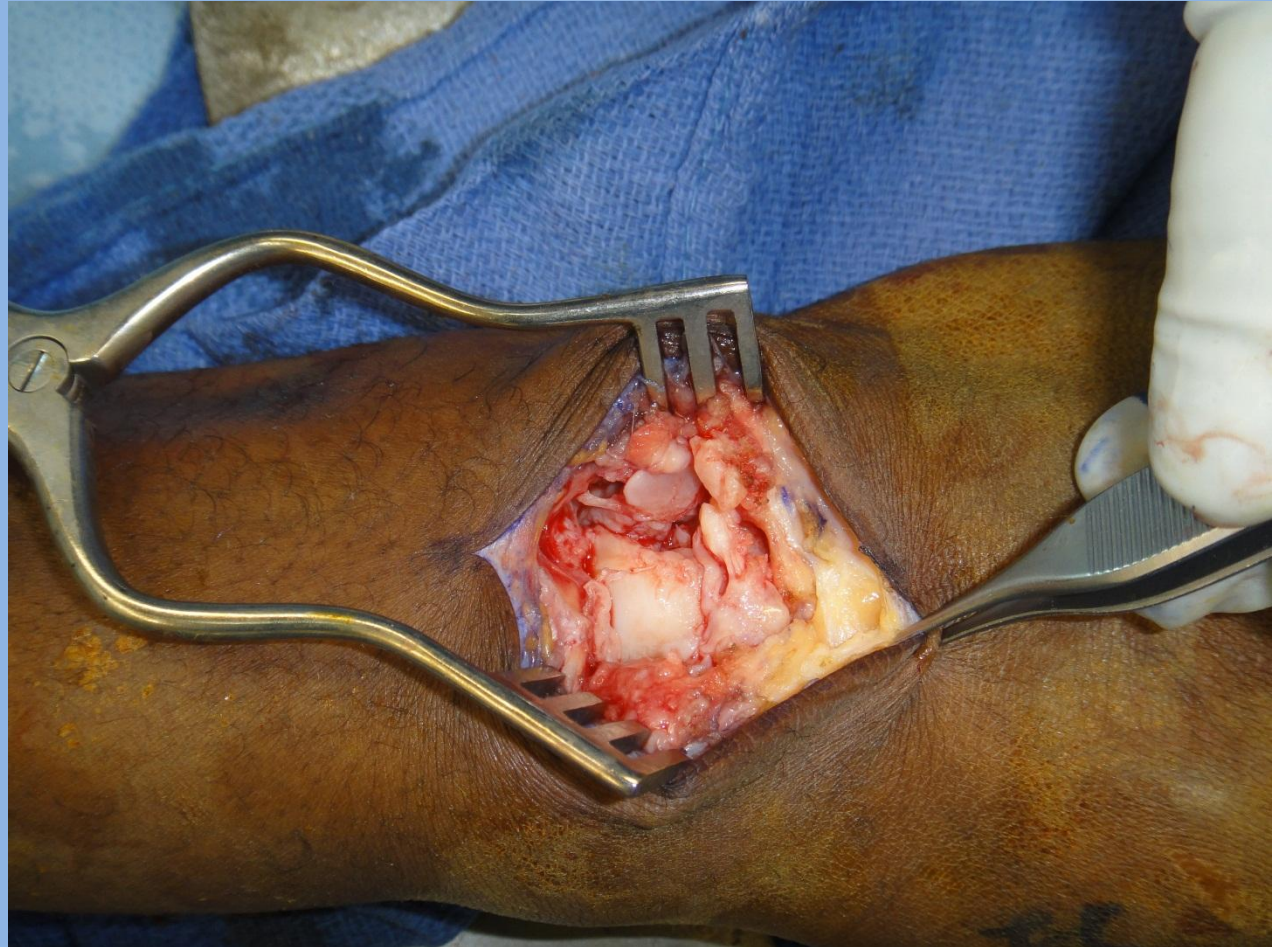- 32 y.o. RHD man s/p fall from skateboard to Left hand
- Severe Left wrist pain, acute CTS

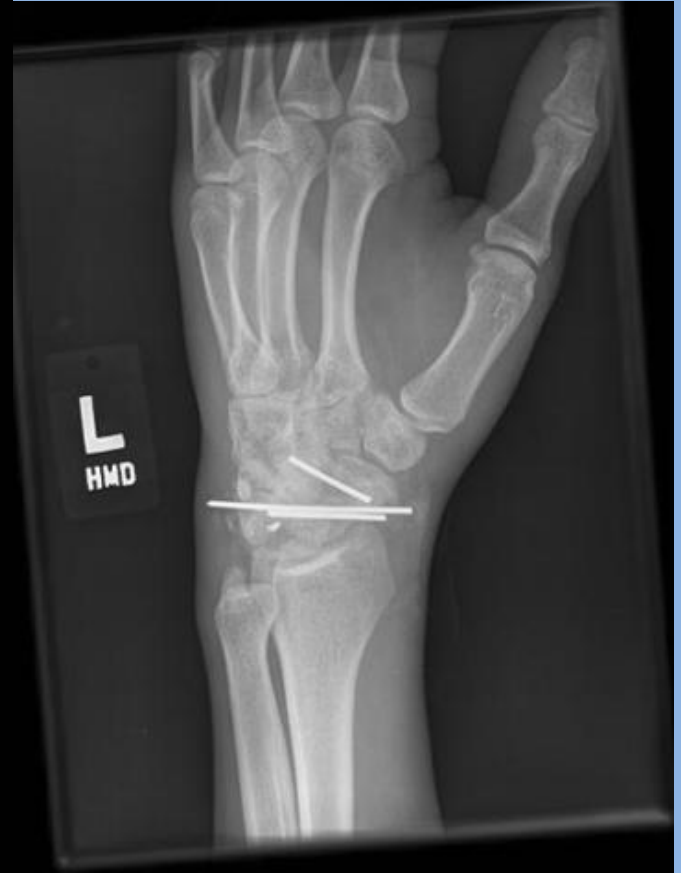
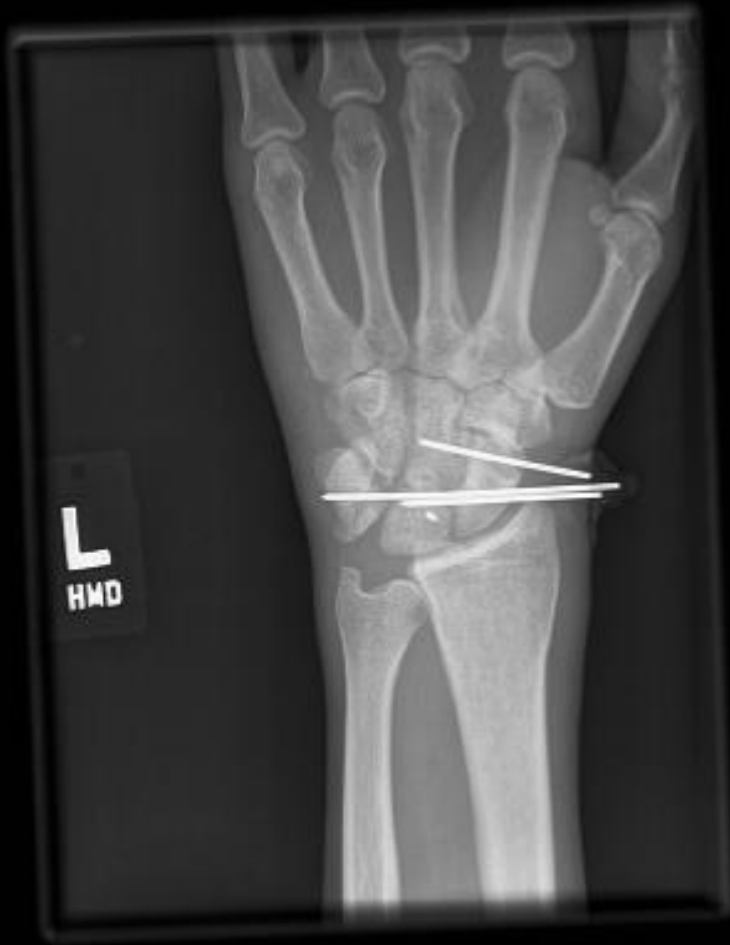


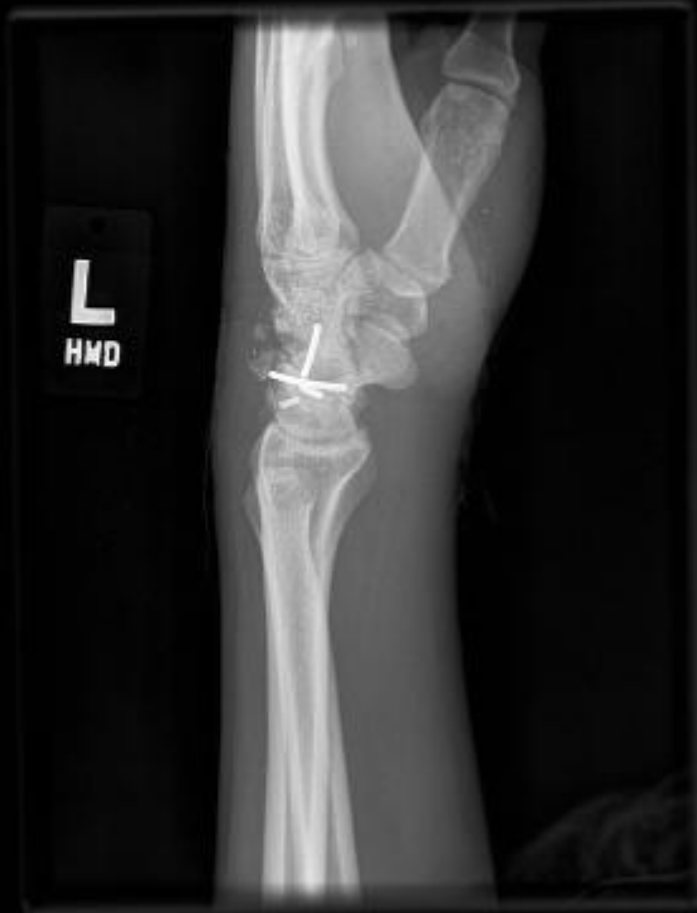

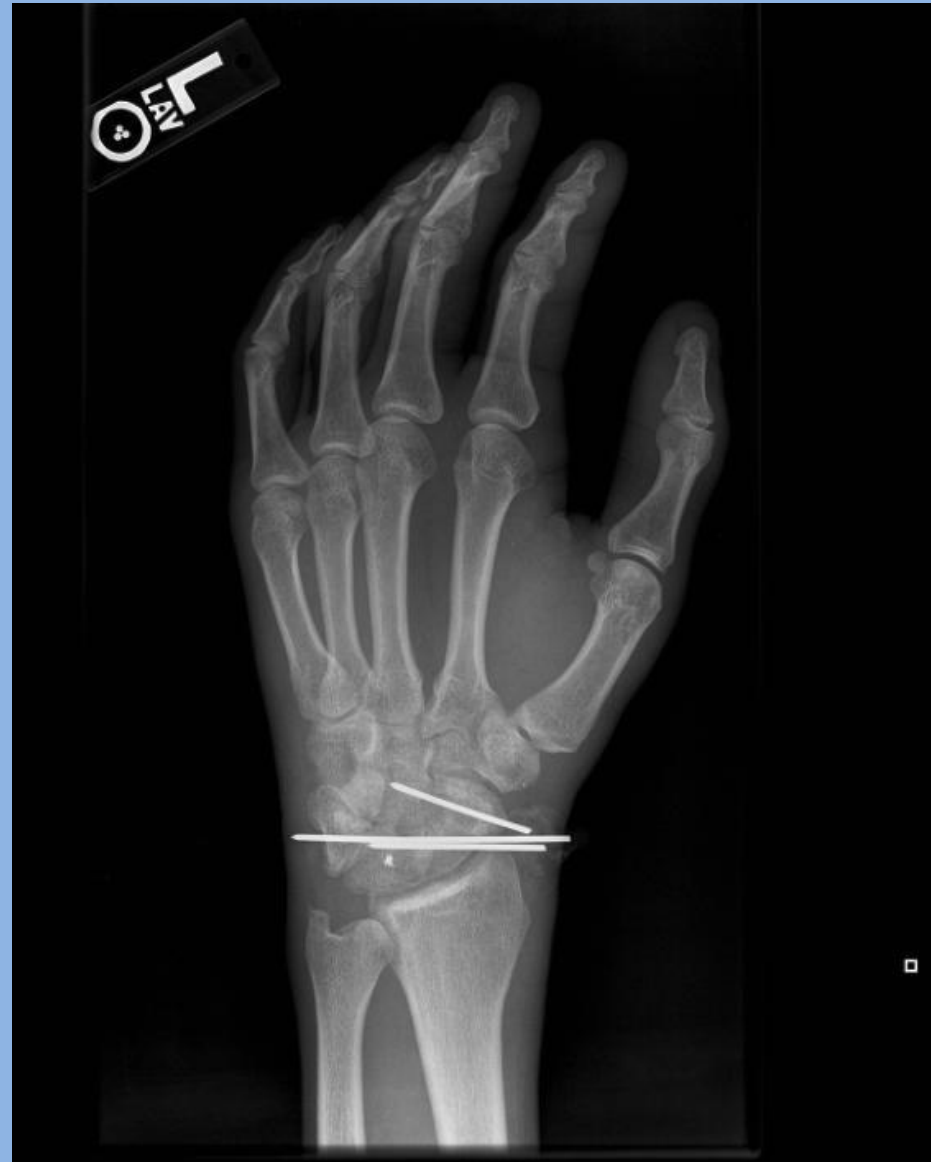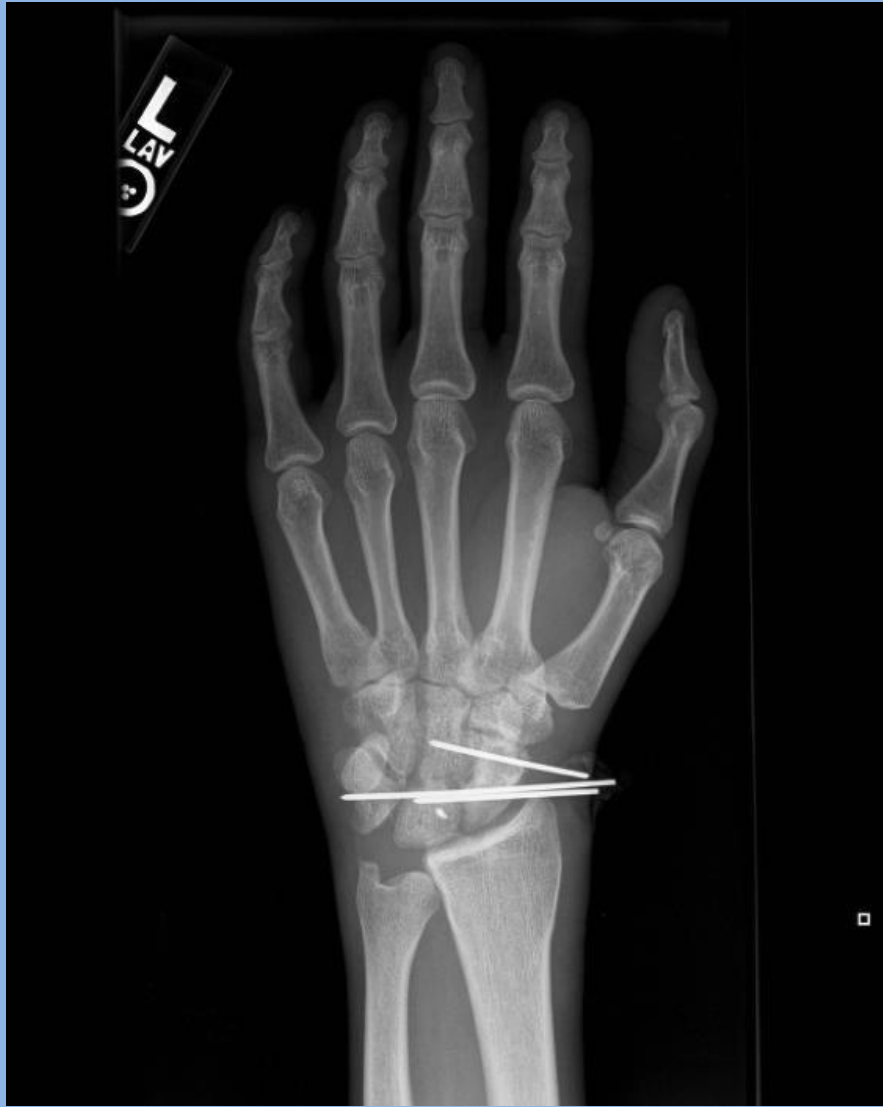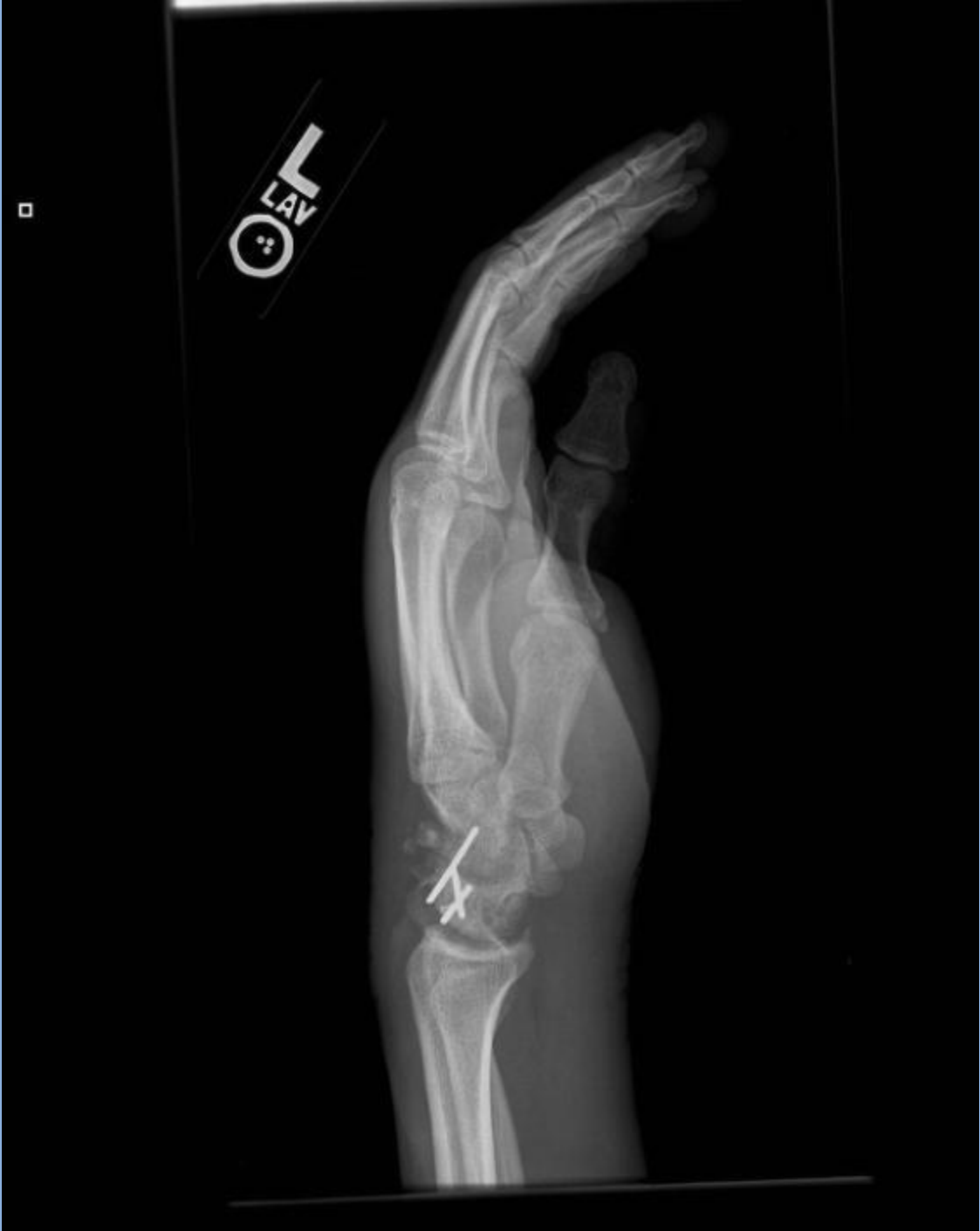Management?

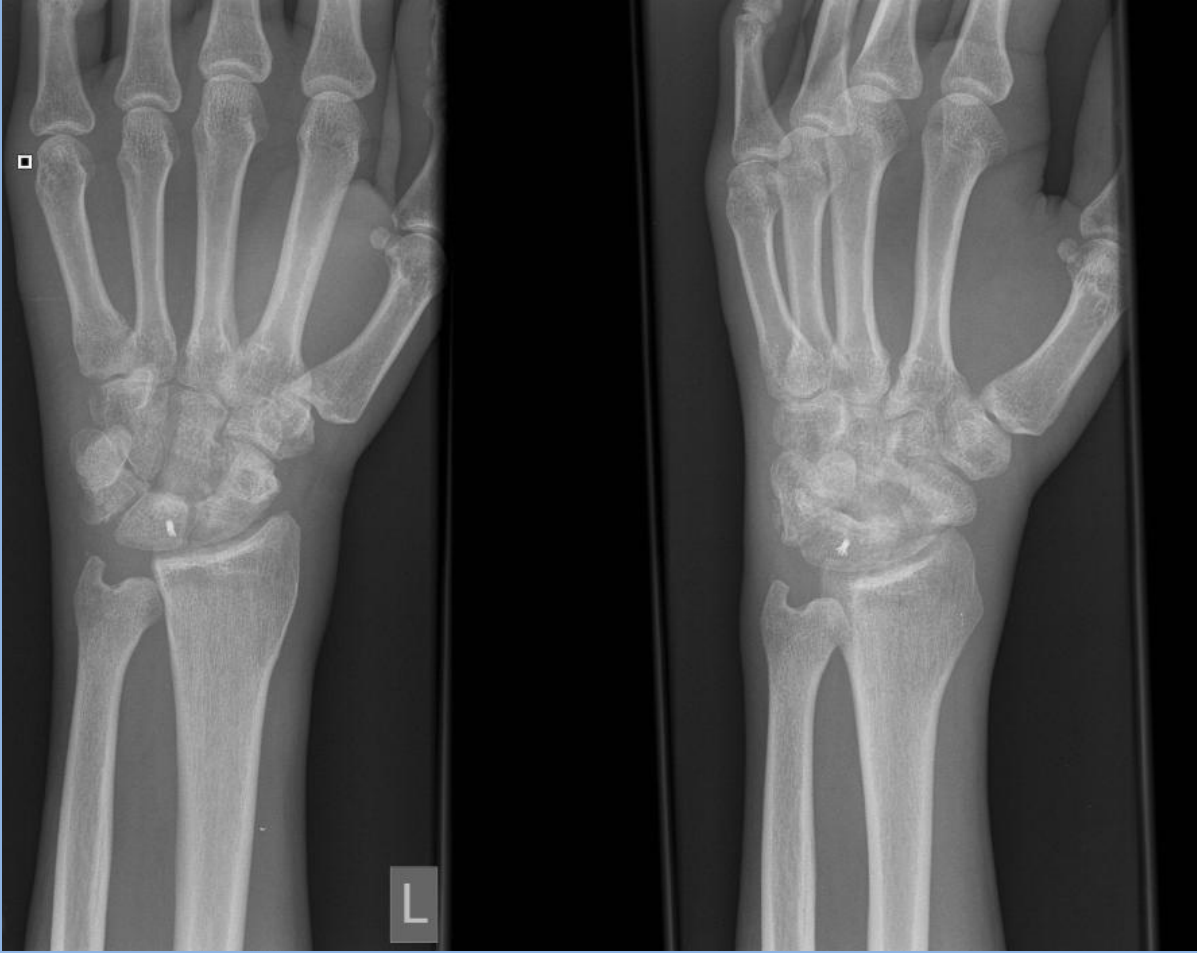


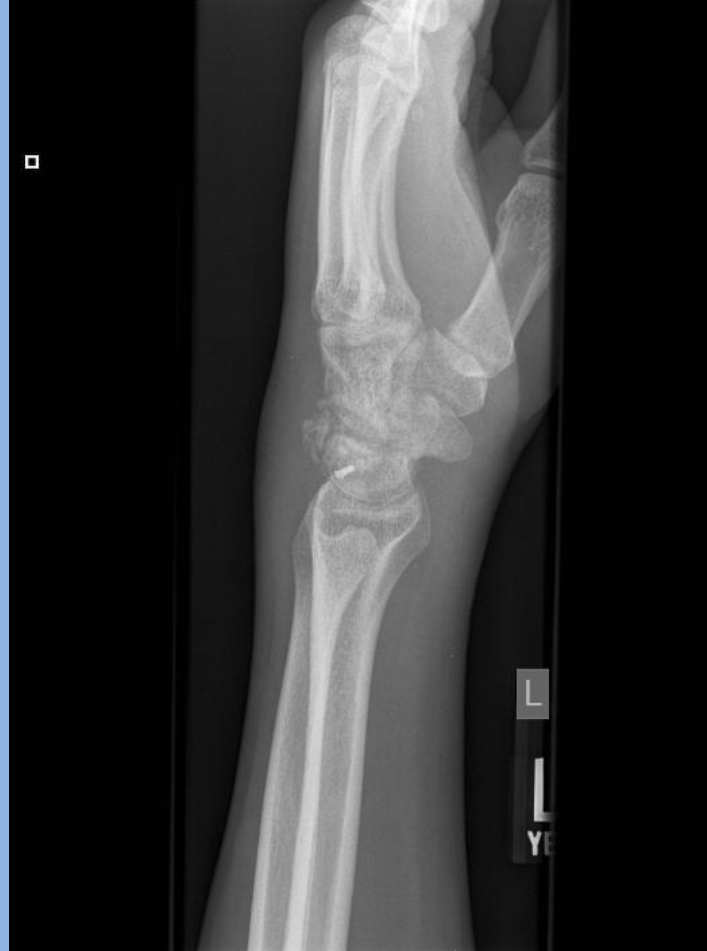






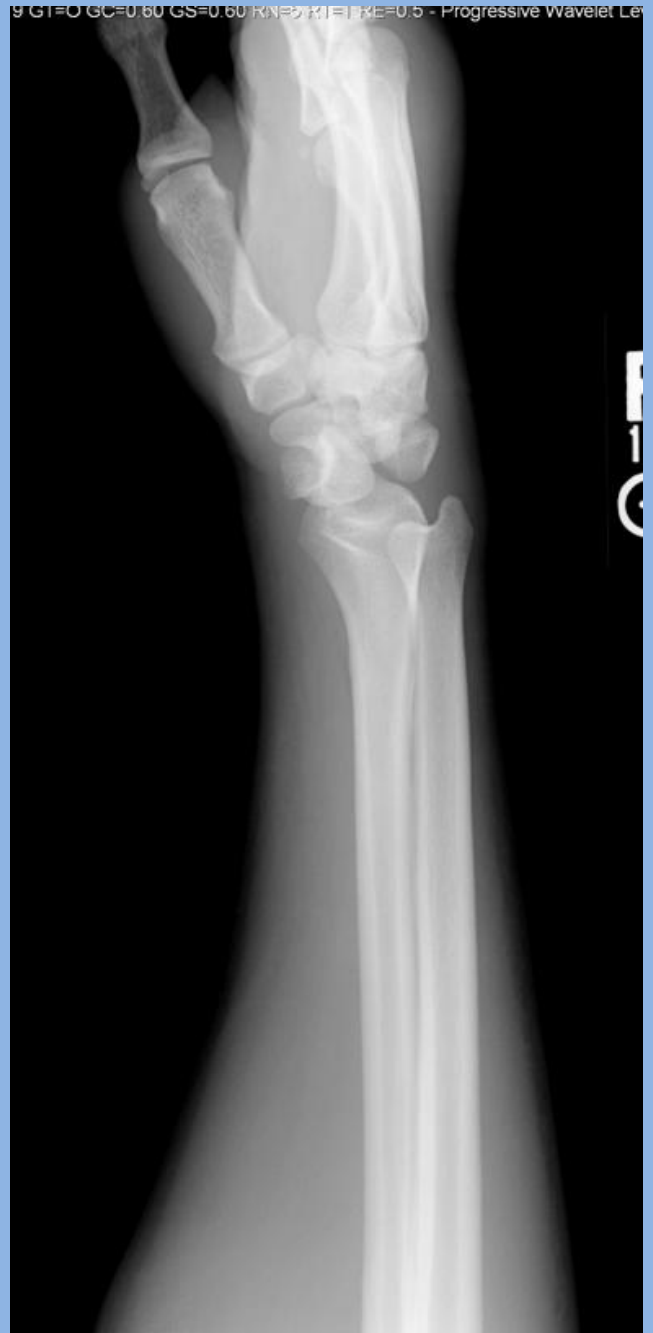
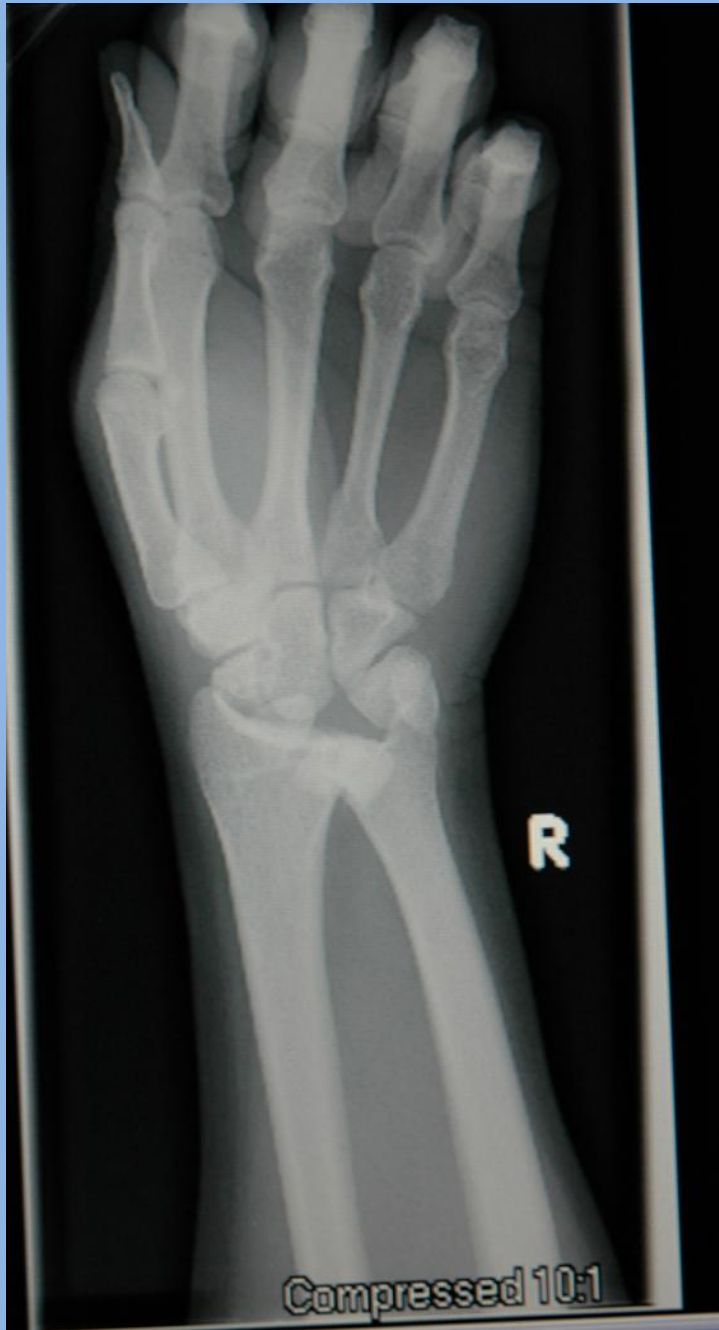


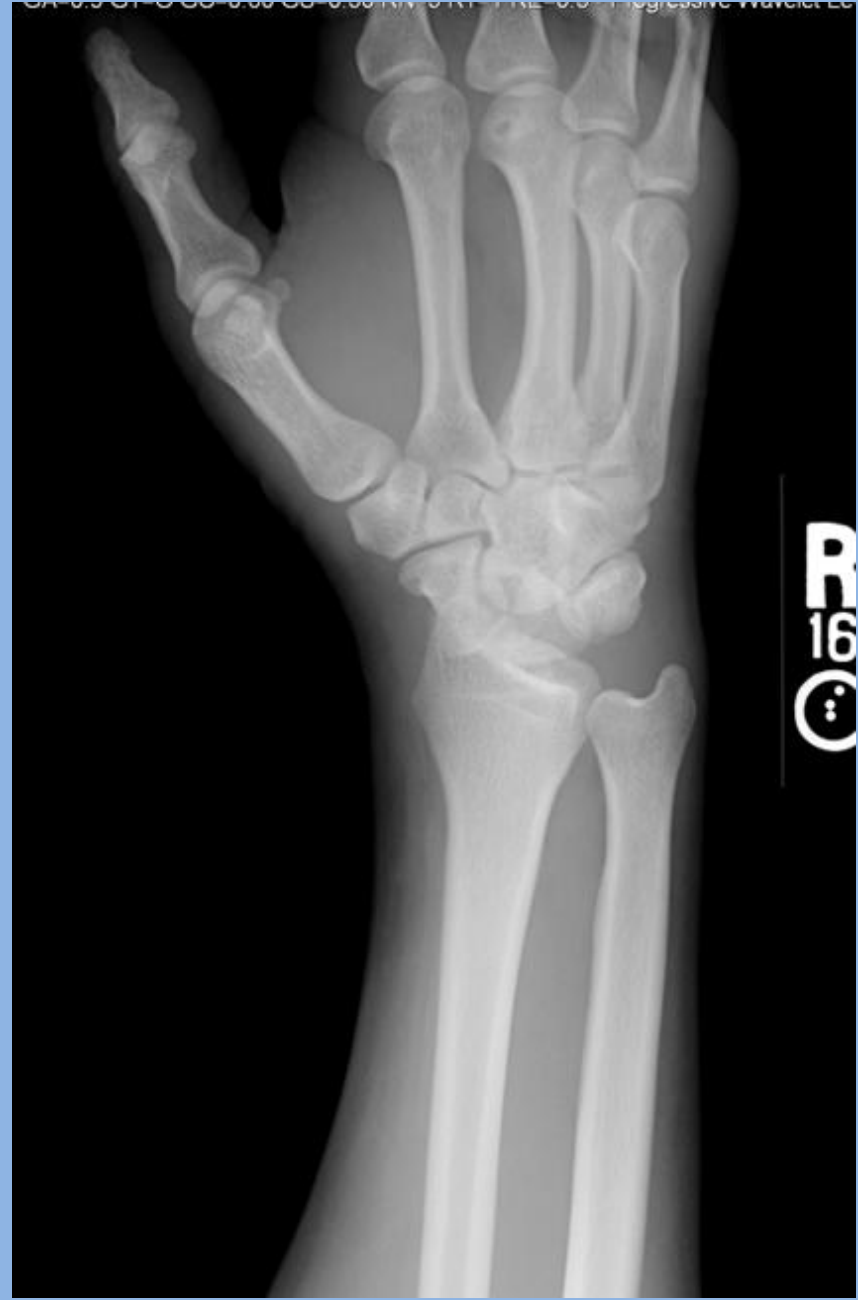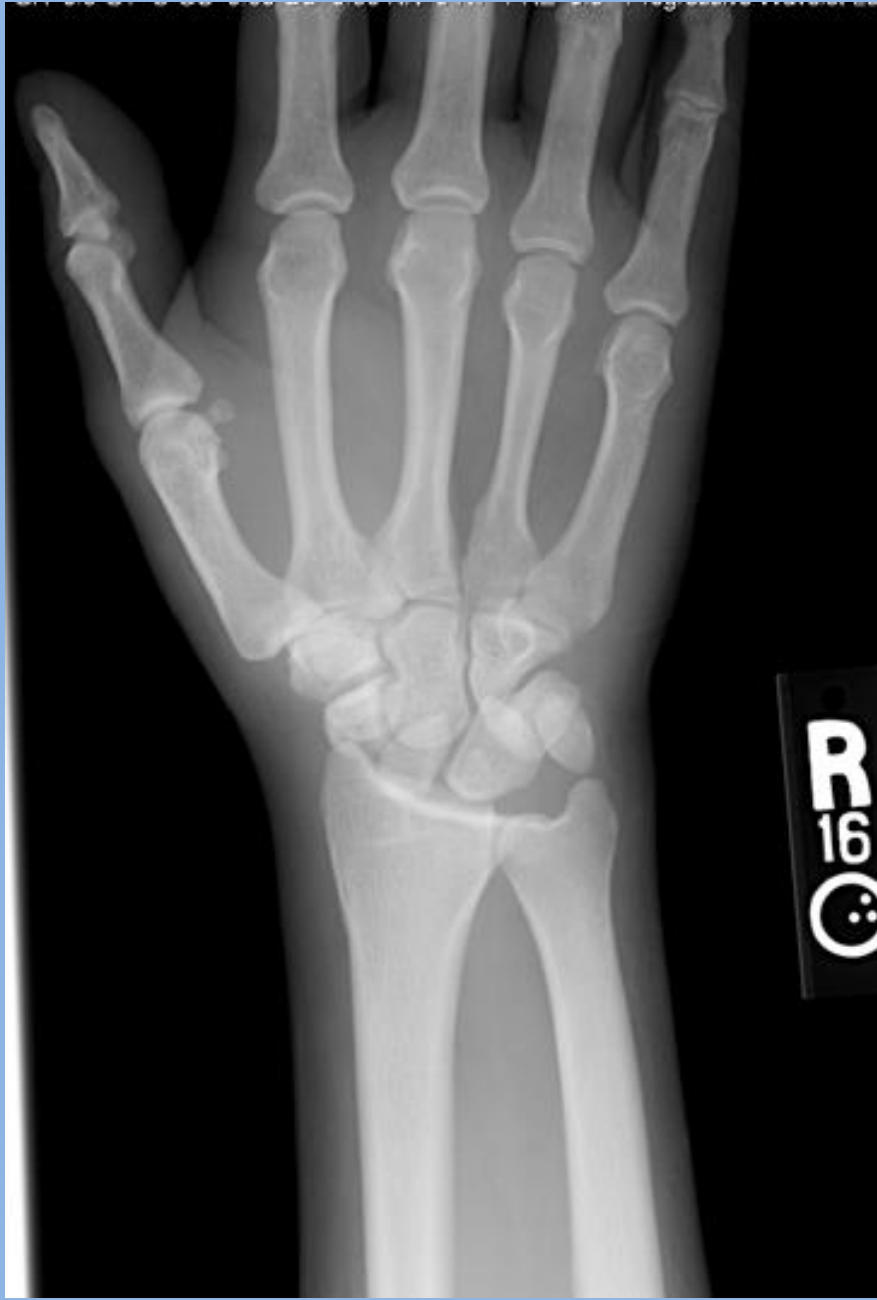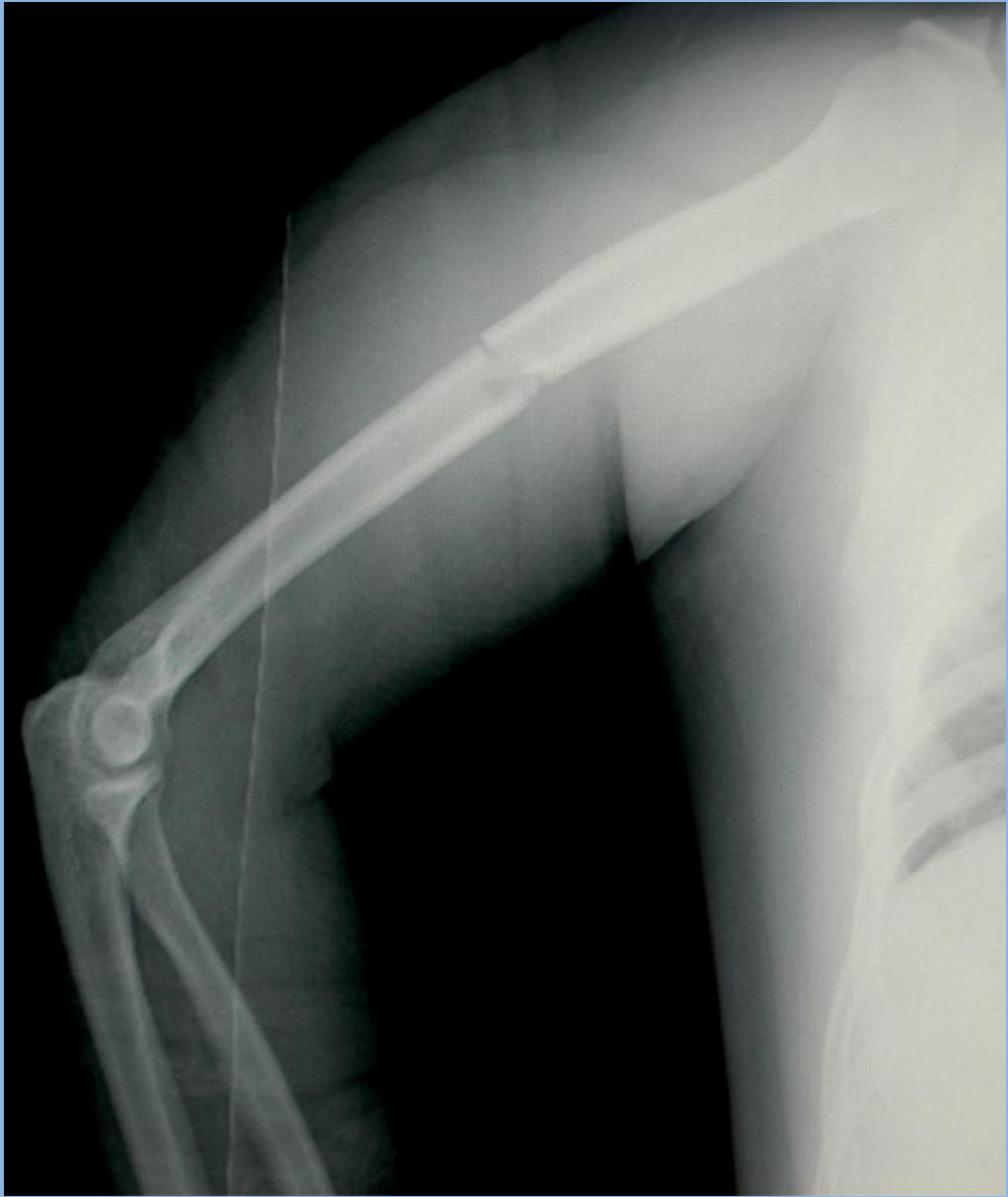Case

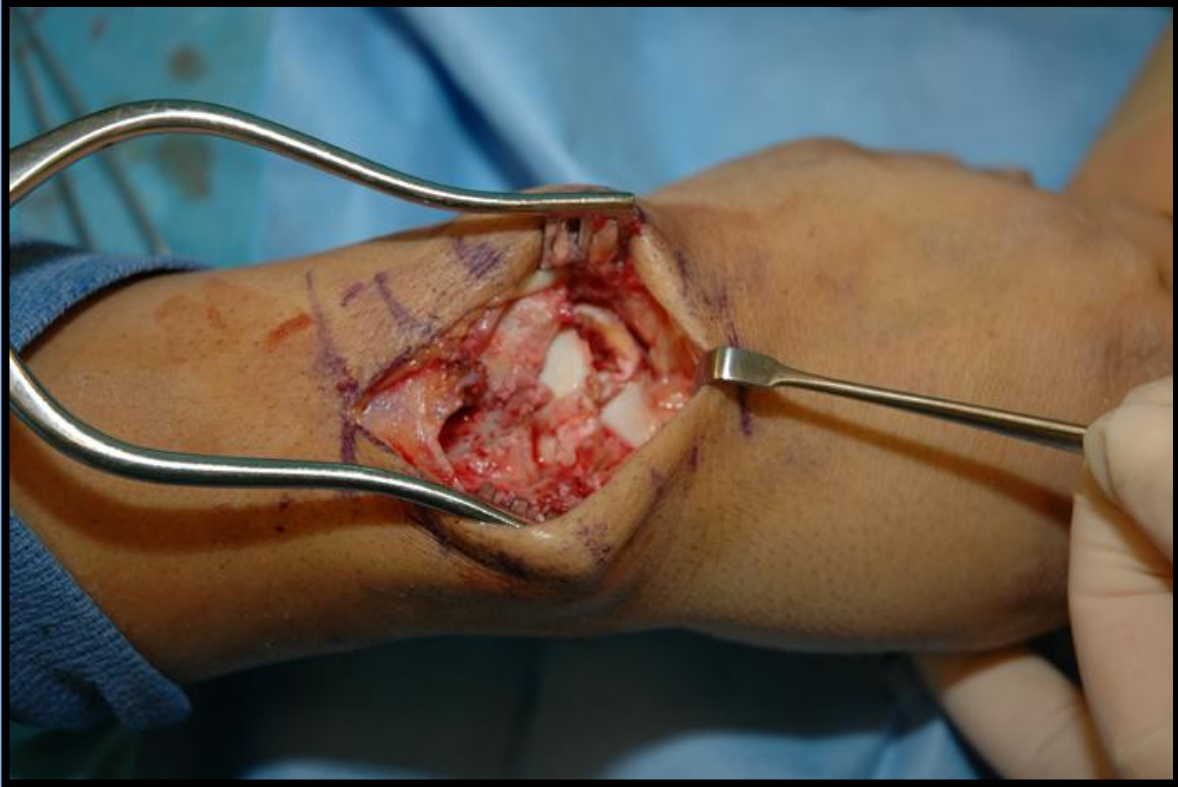
- 35 y.o. RHD man s/p fall to right upper extremity (outstretched hand)
- C/o right wrist pain, N/T of thumb, IF, MF, RF and SF



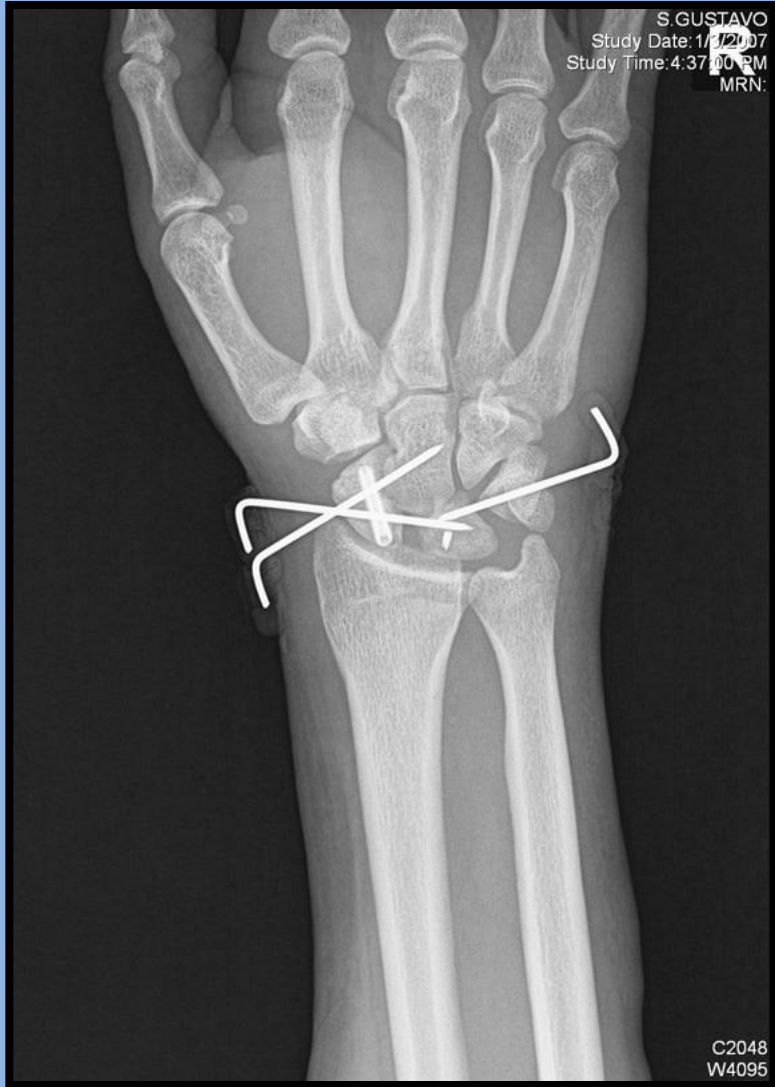



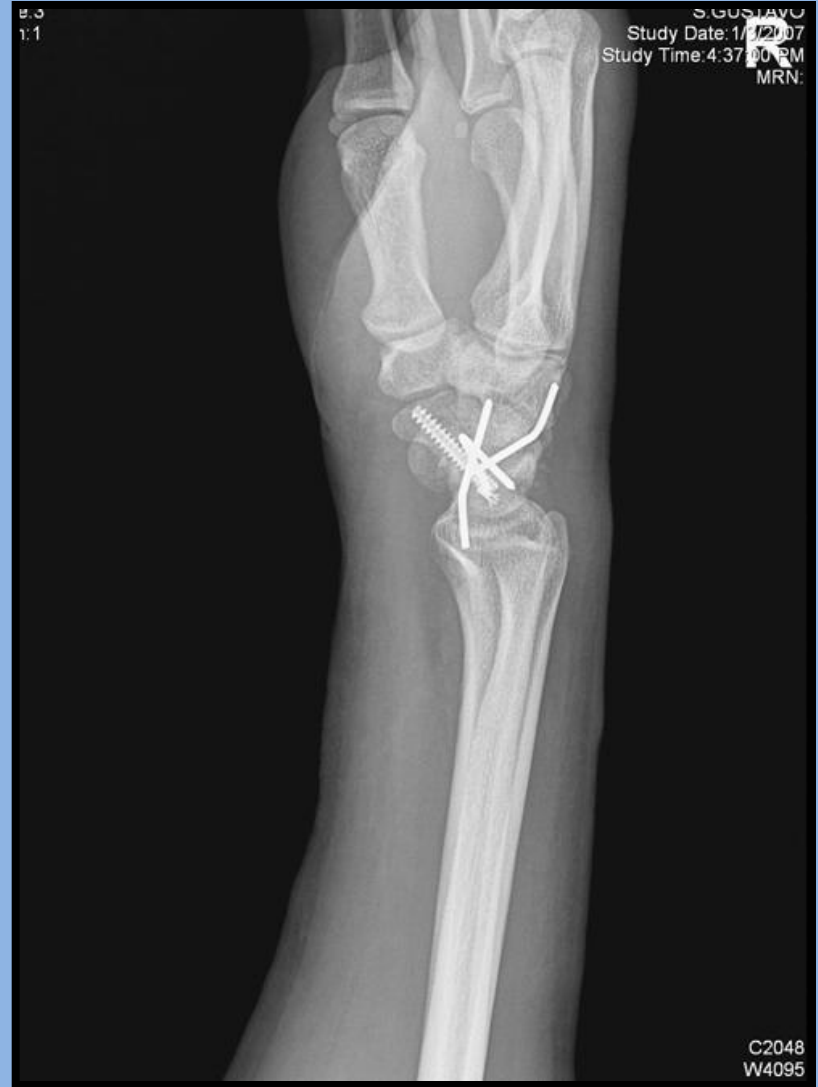Treatment Options?



R



R



- CTR/UTR
- Reduction of lunate and k-wire fixation
- ORIF Scaphoid
- Repair S-L ligament

