



DR. DWENIG, MD  
PROF. OF PATHOLOGY  
UNIVERSITY OF CALIFORNIA

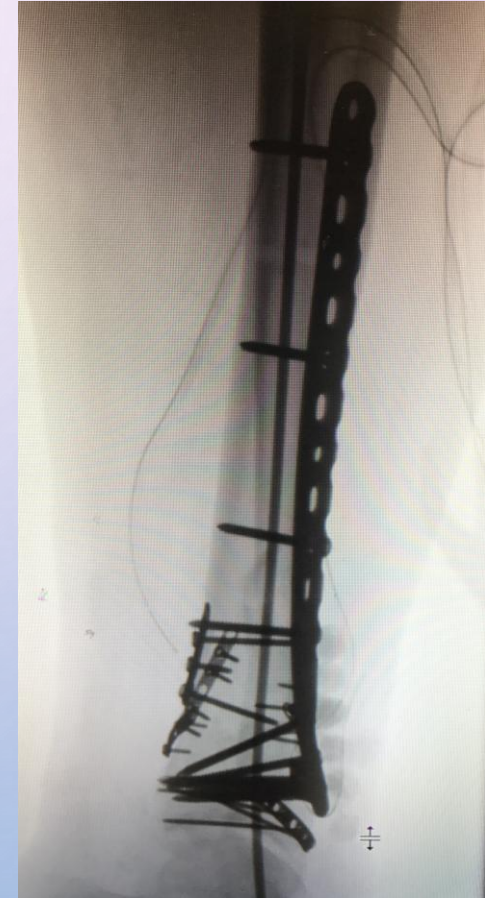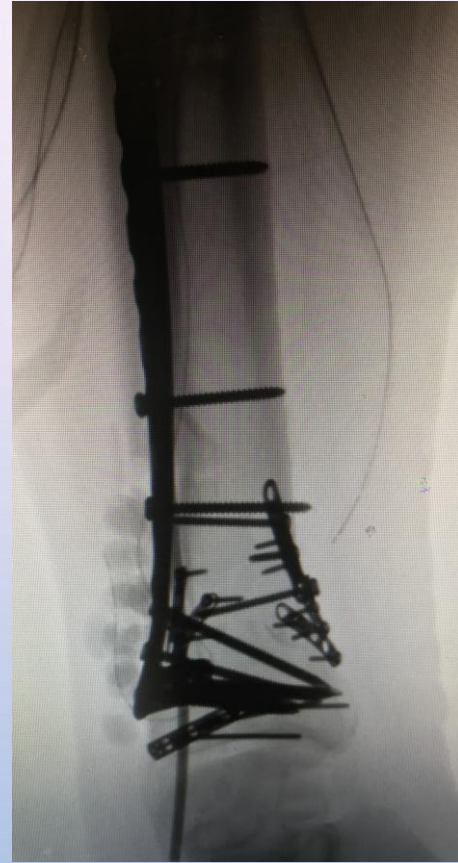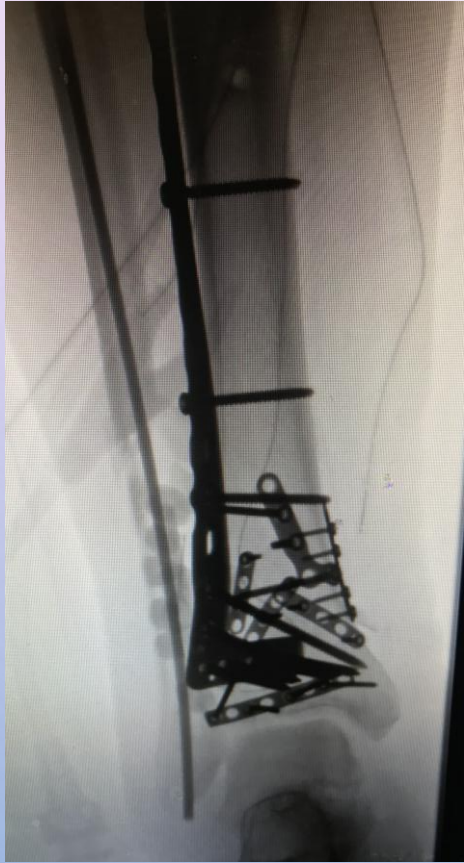# 51 Y / O M S P X R O L O V R

- N U S H T B C A N E A M H S D A P E 2 O P E N G H T Y L O N E M H S K E S O N .
- F A R I D M E
- G H P Y L O N E M H N E S D A D A N N I N G E R A F A O N E L O W E I O S E M H E R M A C F

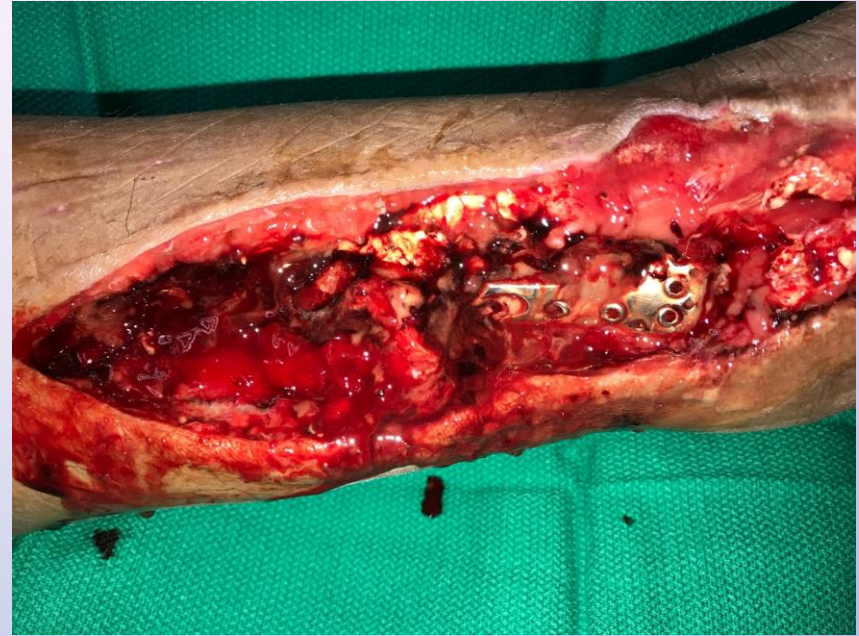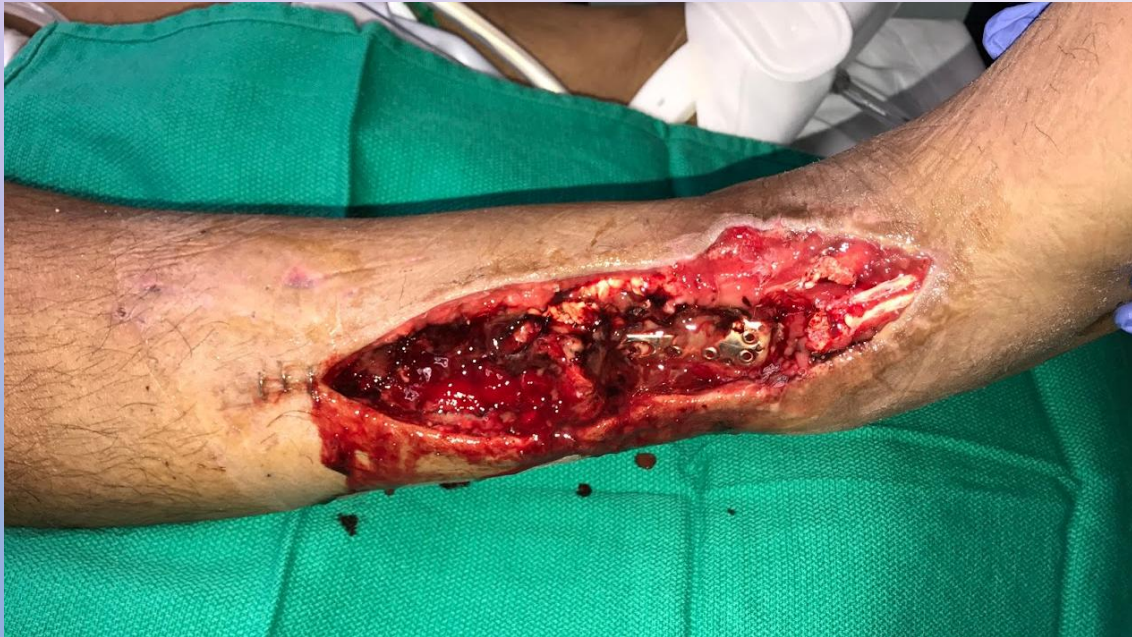# 51Y/OMSPX RLOVR

- PENTOPROFENONE DOWNNAROL.
- PENTOPROFENONE TO ENDOXOR
- AD
- NOWOR

# NEUROSCIPYSELO WING OF

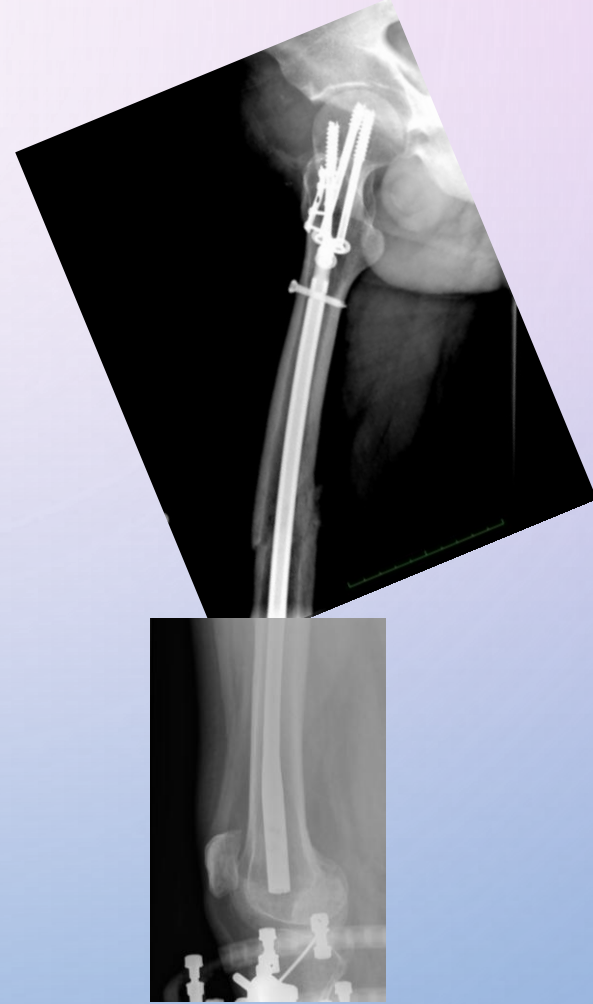
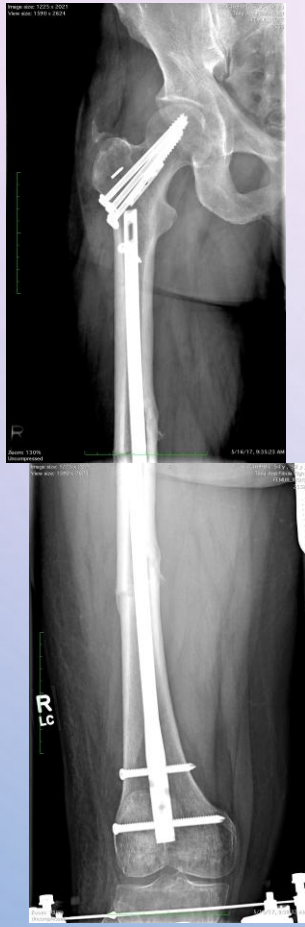

# TENDON CREW

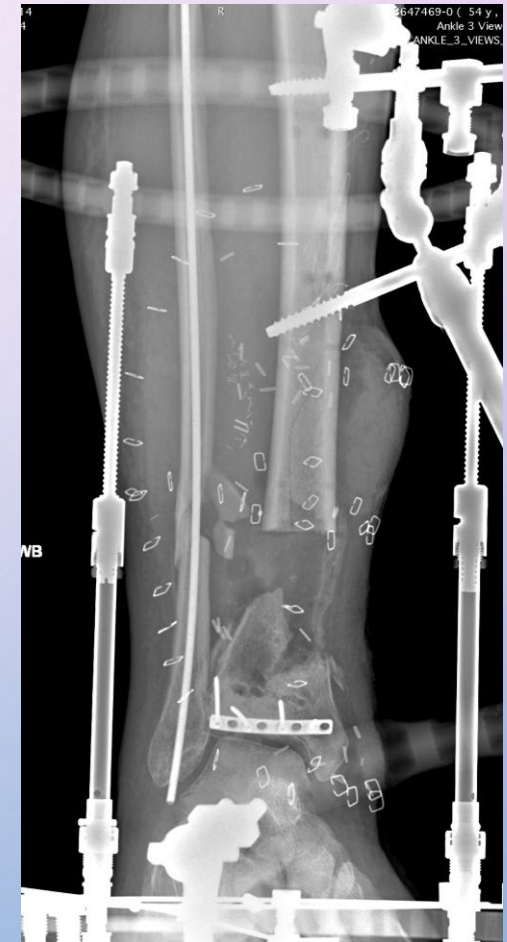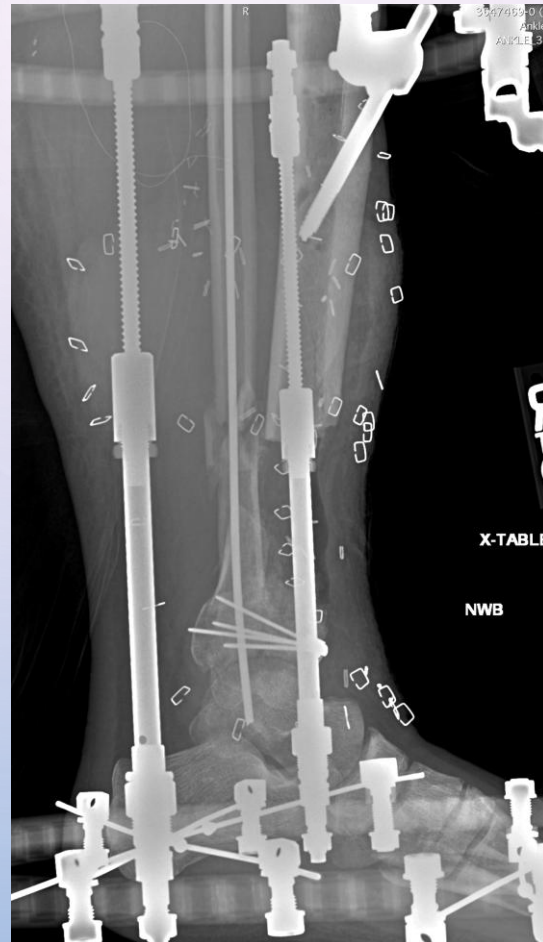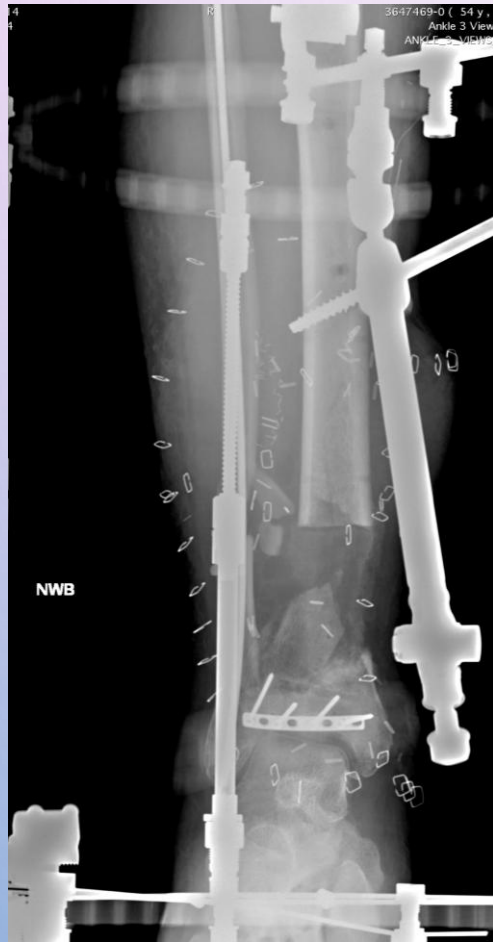


- **SMALL BONE**
- **FOR MIFG ADVENT**

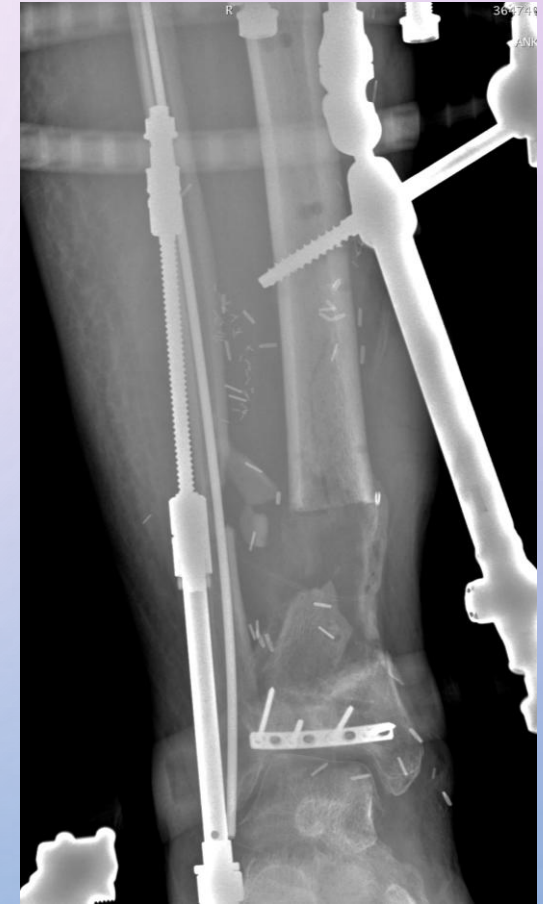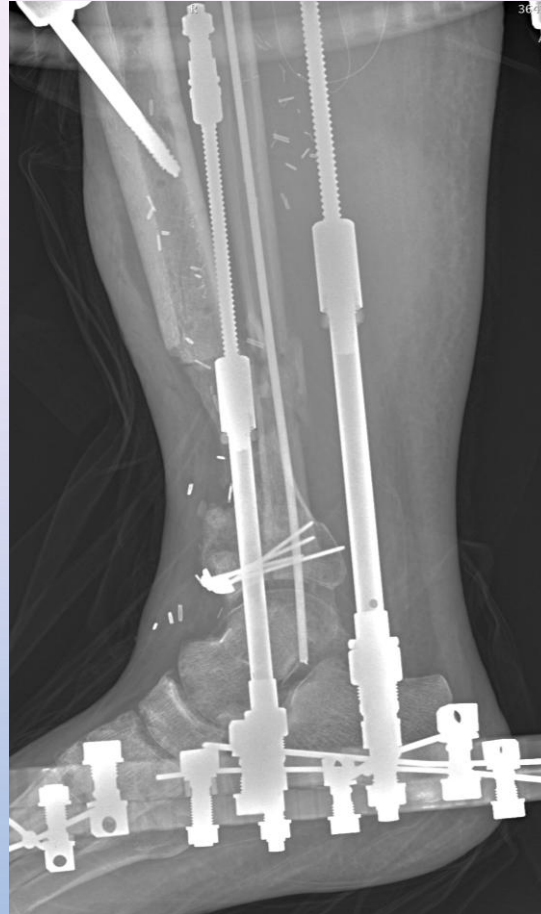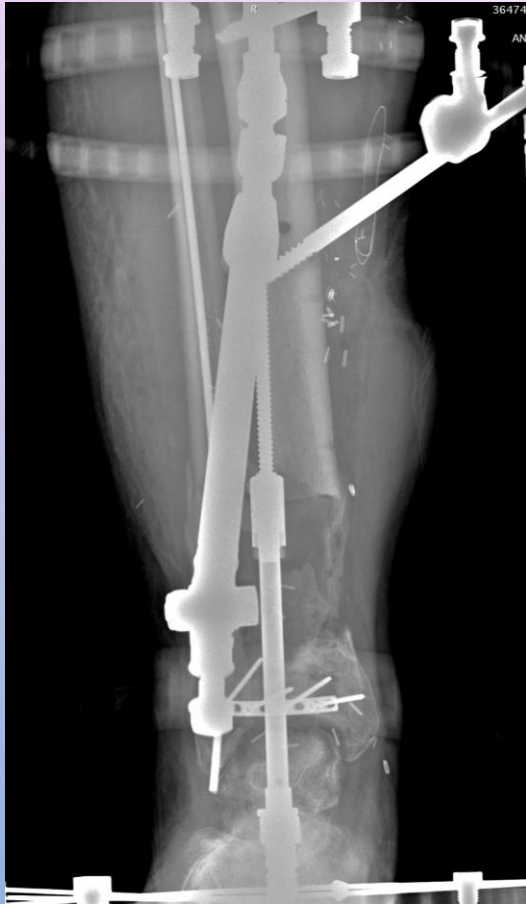# ORPHEUS ORANGE ALGHE



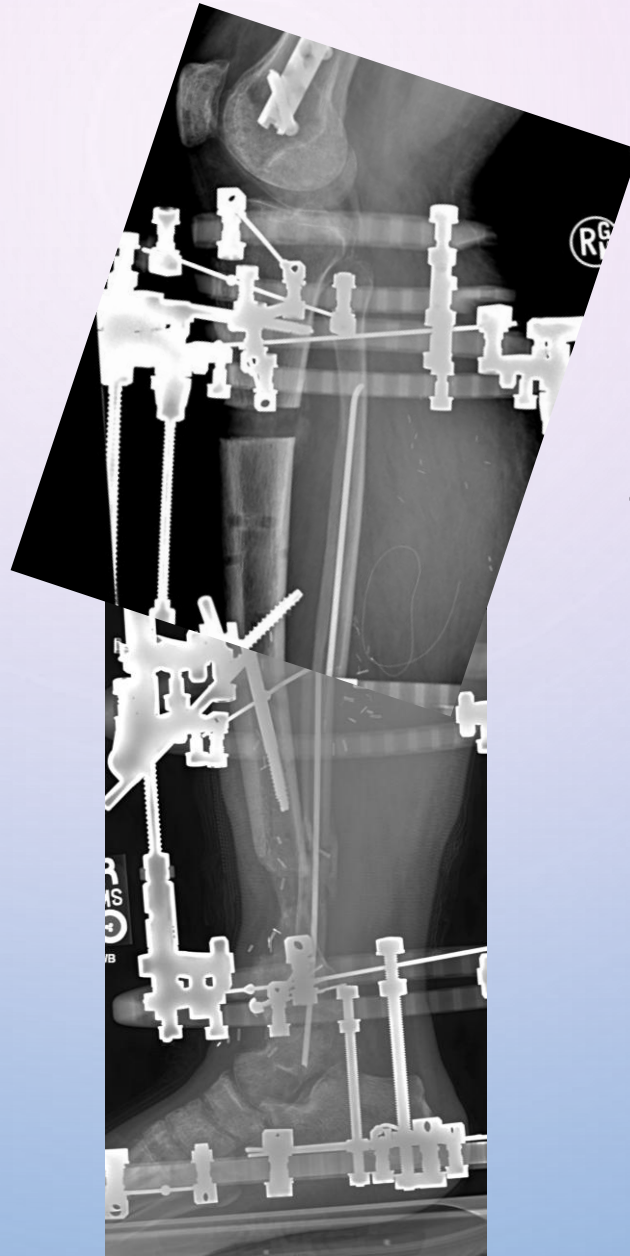
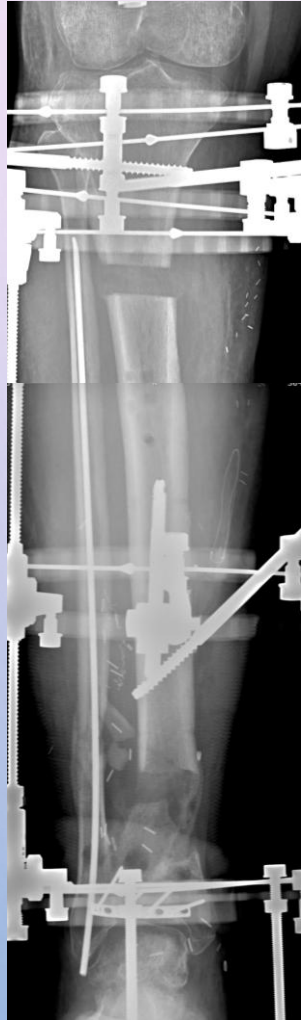
# NON-IDENT, NON-NON, NON-REASON



# NEW MINIMALLY INVASIVE MUSCLE SAVING


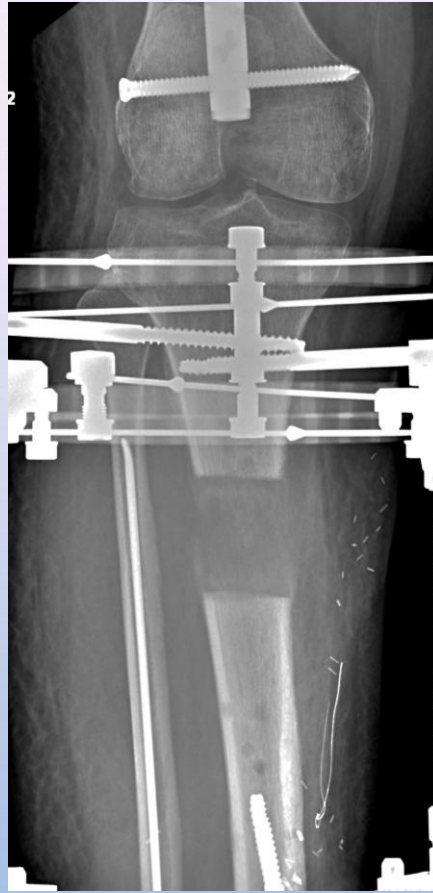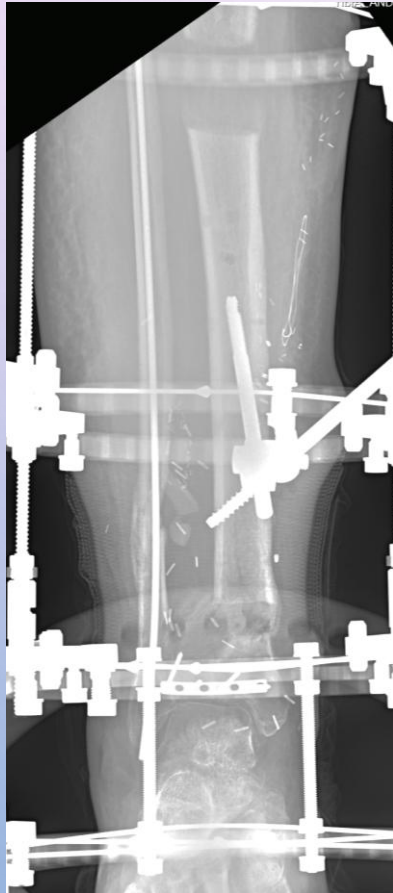


# 3) NEARPORT

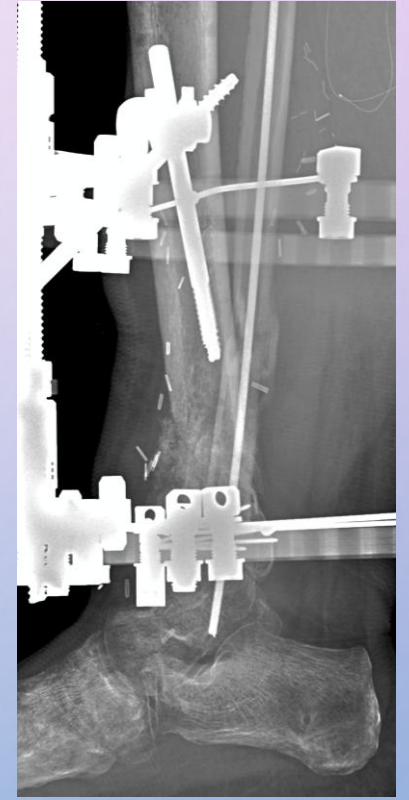
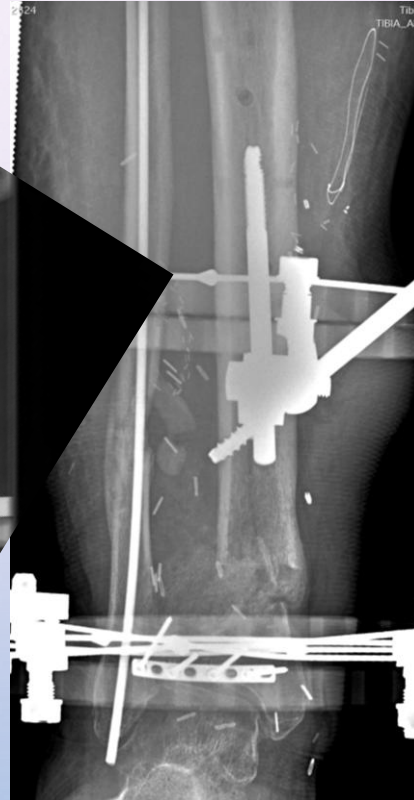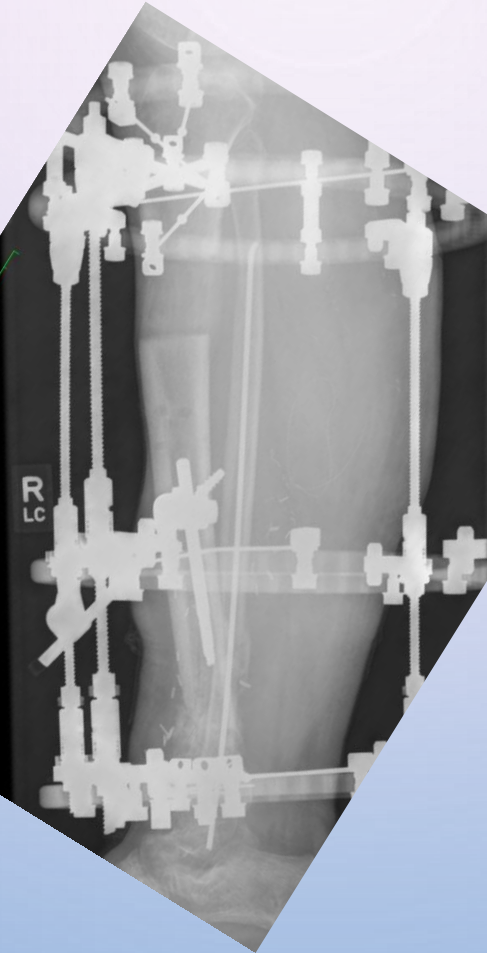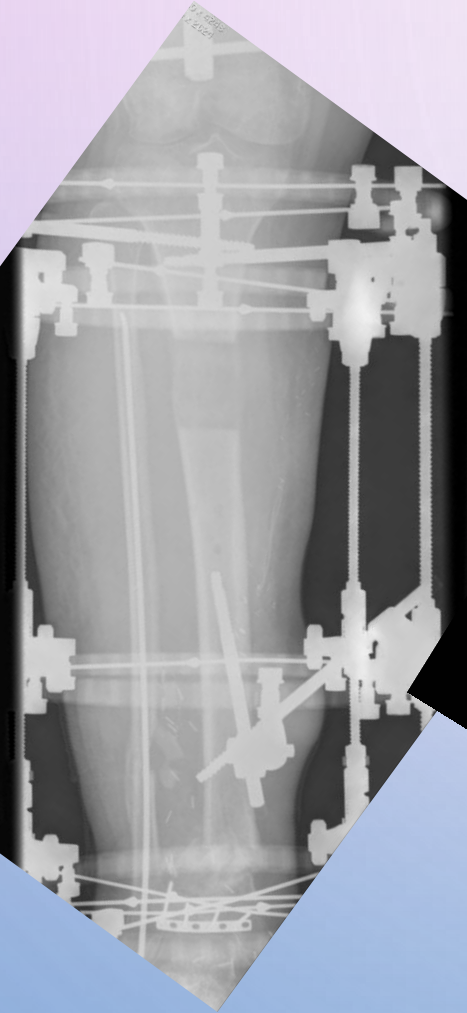


- PROXIMAL NEARPORT
- PROXIMAL NEARPORT

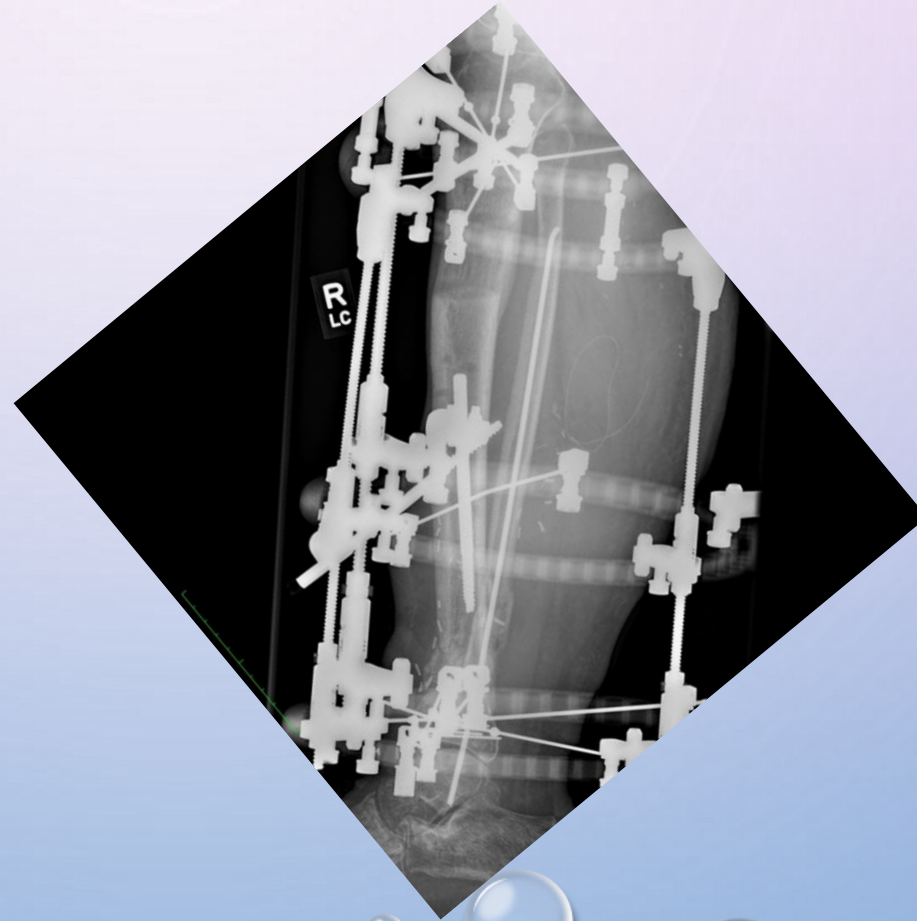
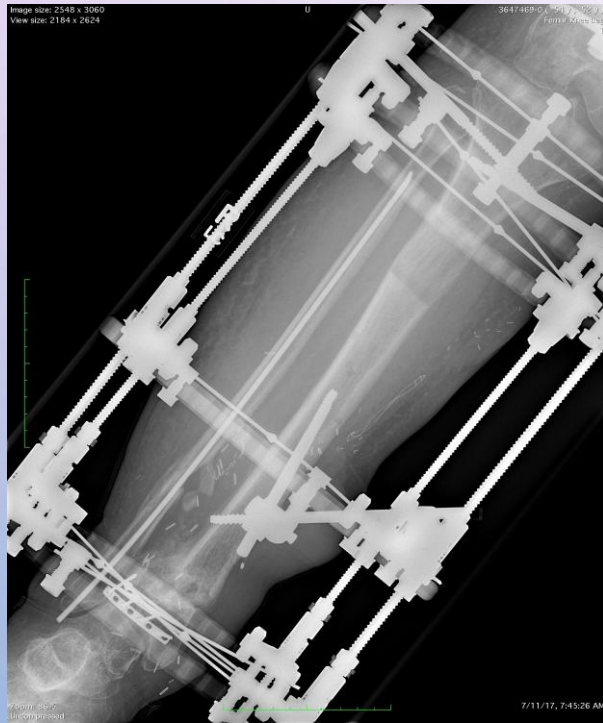
# REPORT




# LOCKING WITH B



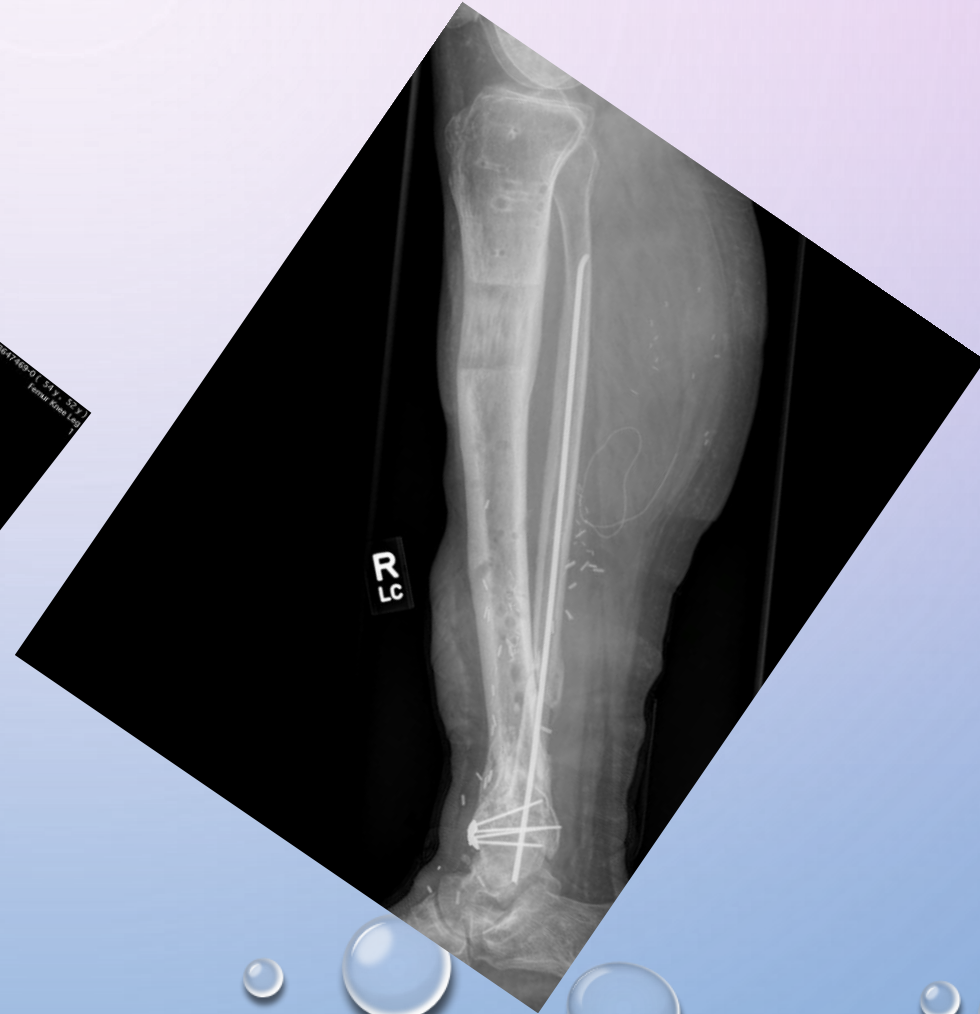
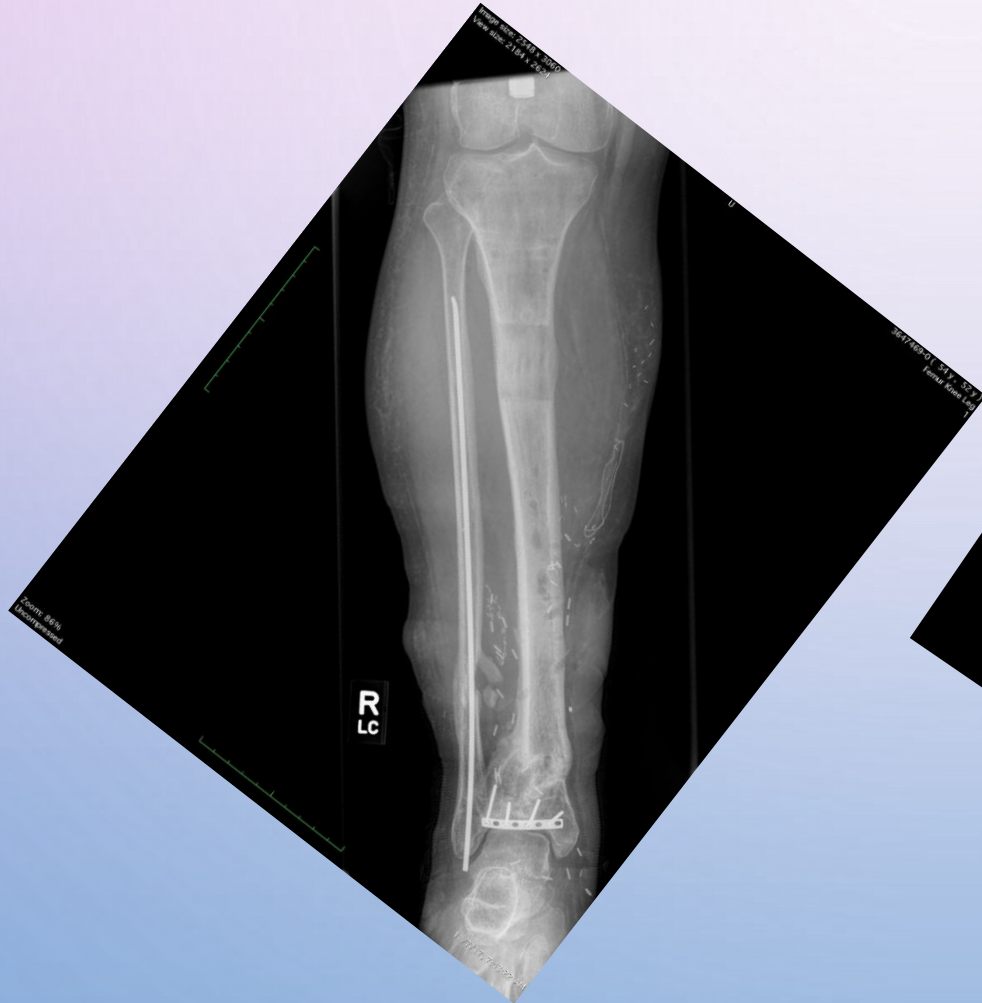
# WANG BONE MAN



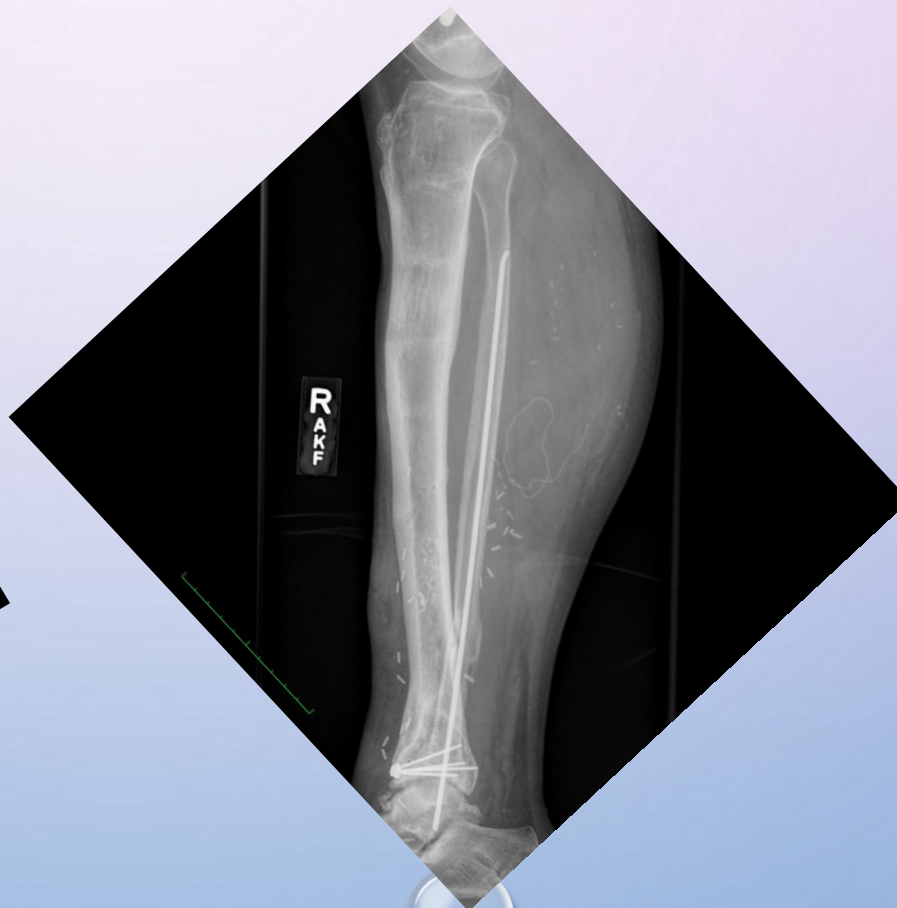
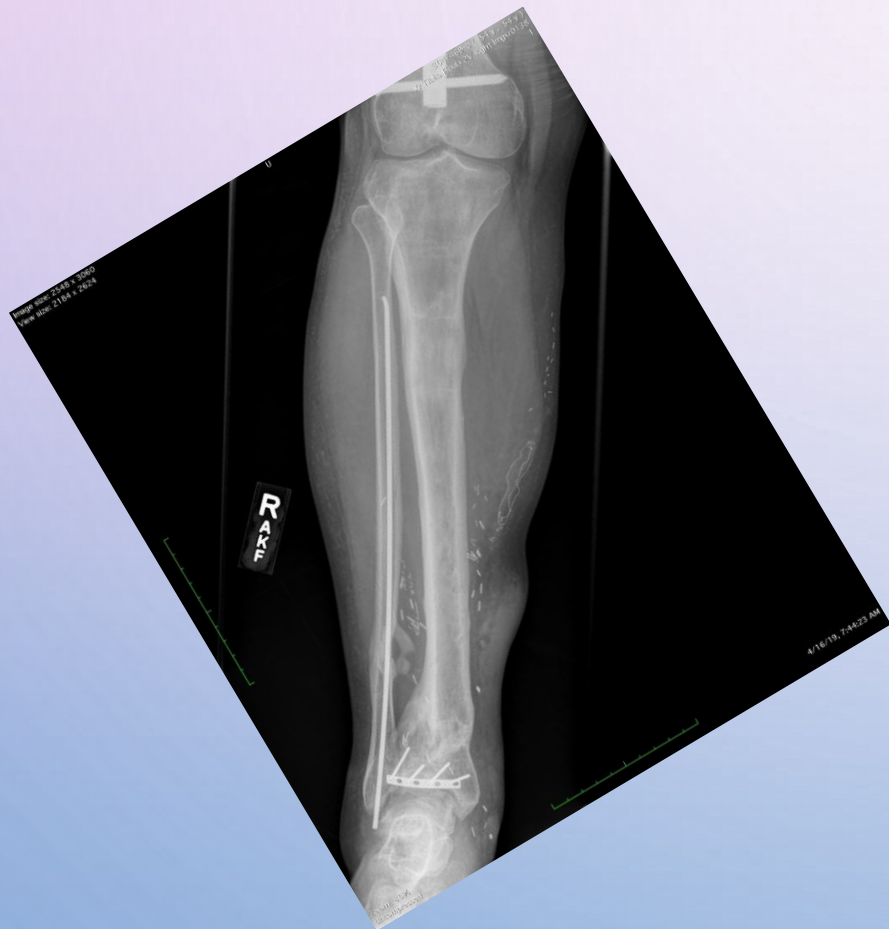# COMPRESSION



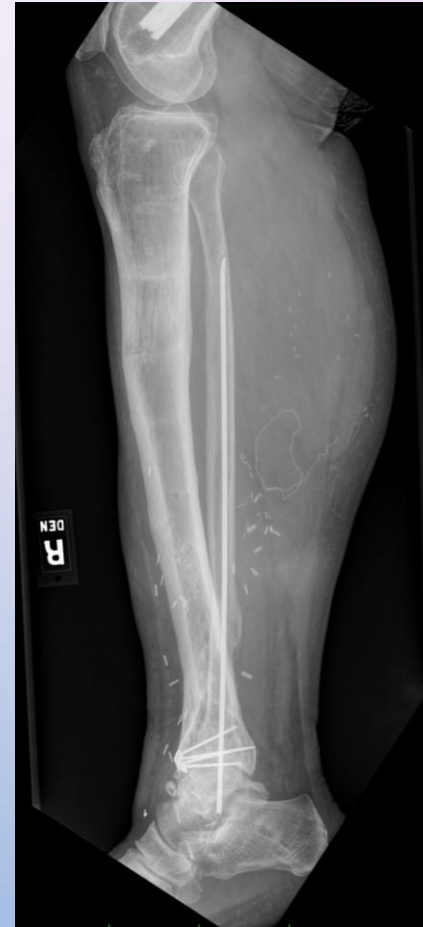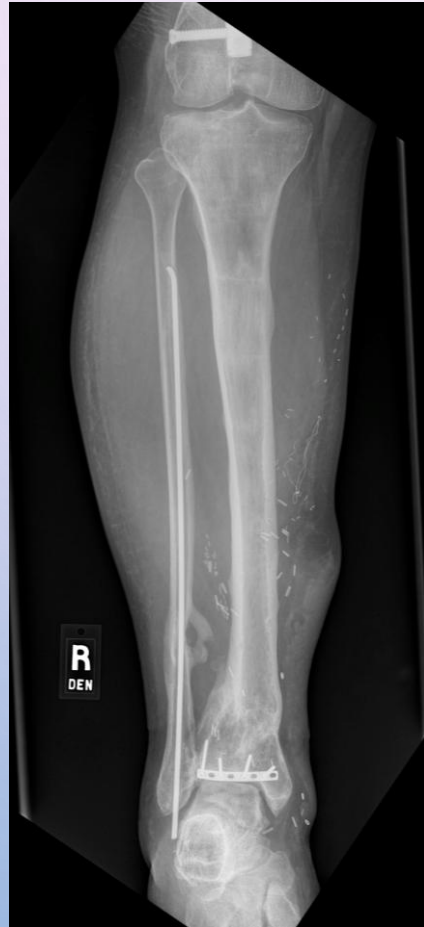# FLOWING ~~REMOVAL~~



18 MONTHS FOLLOWING REMOVAL WORKING FIBERWALKER KINGON 3.5  
MEIKENOCOPAN.



# 3 YR POST OP A WORKING FEMURAL TUMOR



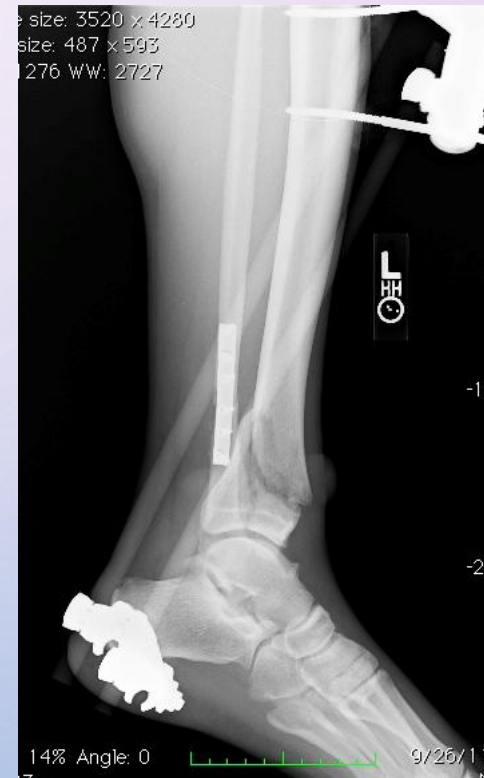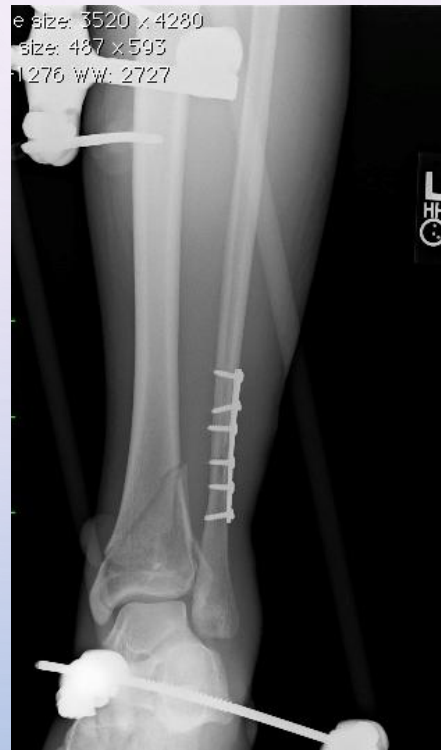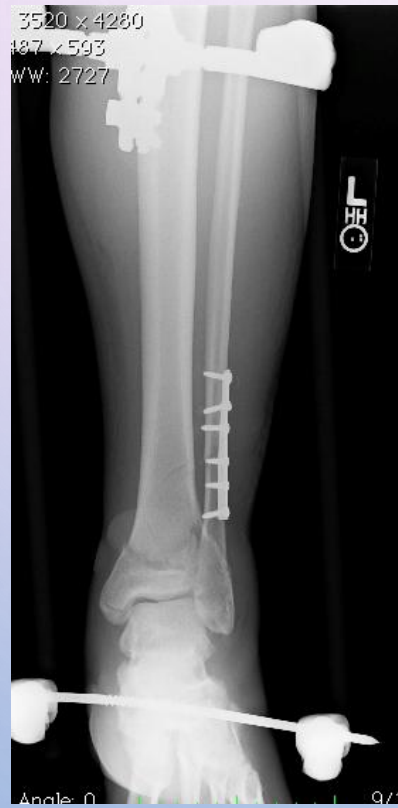# 4 YEAR FOLLOW UP

- B'HEE'.
- WORKING FOR ANCHORAGE 56.
- NO COPAN.
- WAKING 3D 4MBA.
- CONTINUED BUILDING FE'.

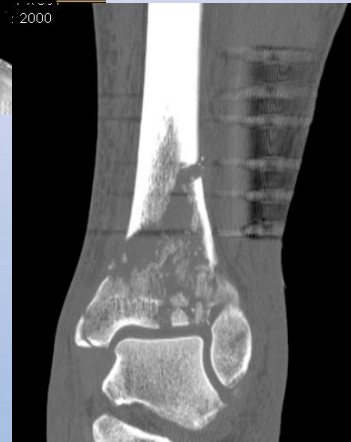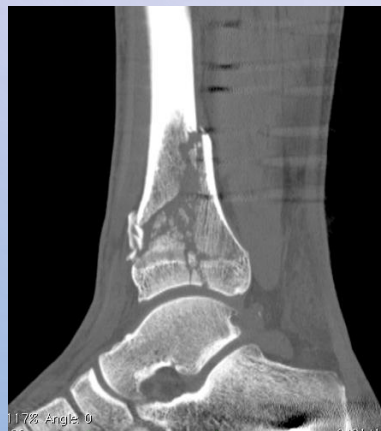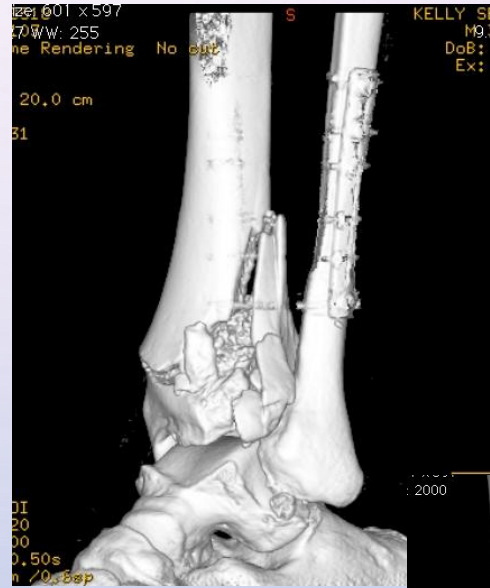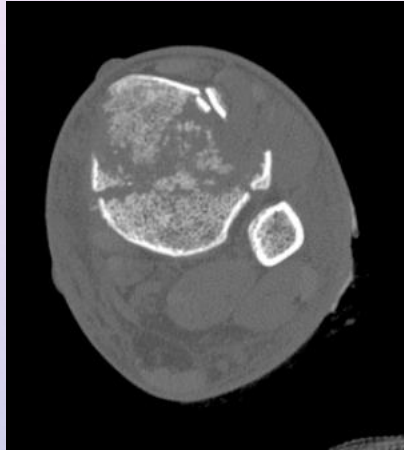
\$K.:38Y/OM

- \$POM12EOTA
- SADDLONER
- PROVIDOR WITH READING.
- GHOPE
- PATRONS

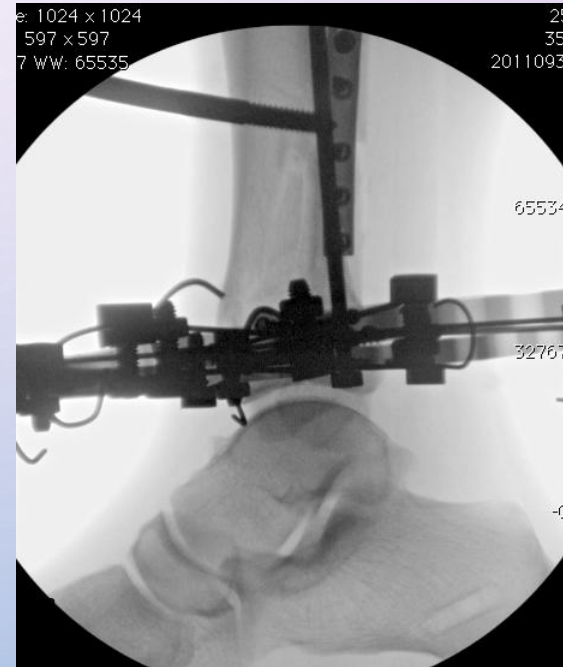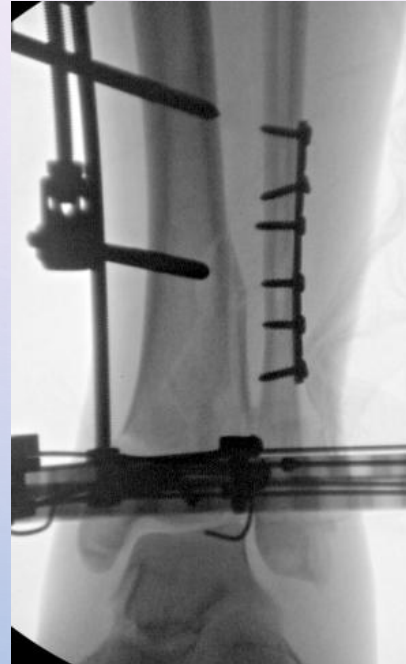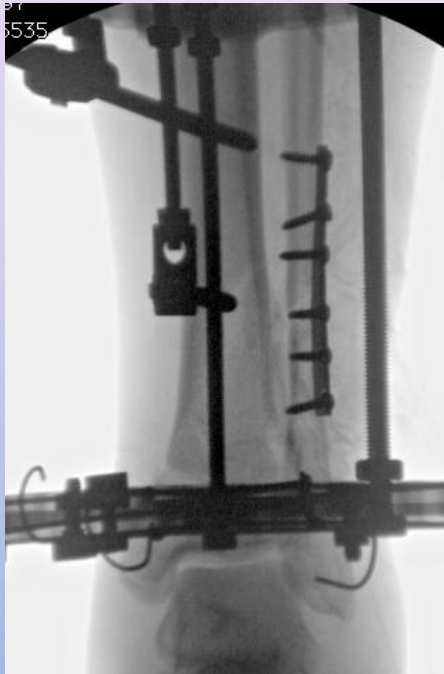# SK.:SPDM



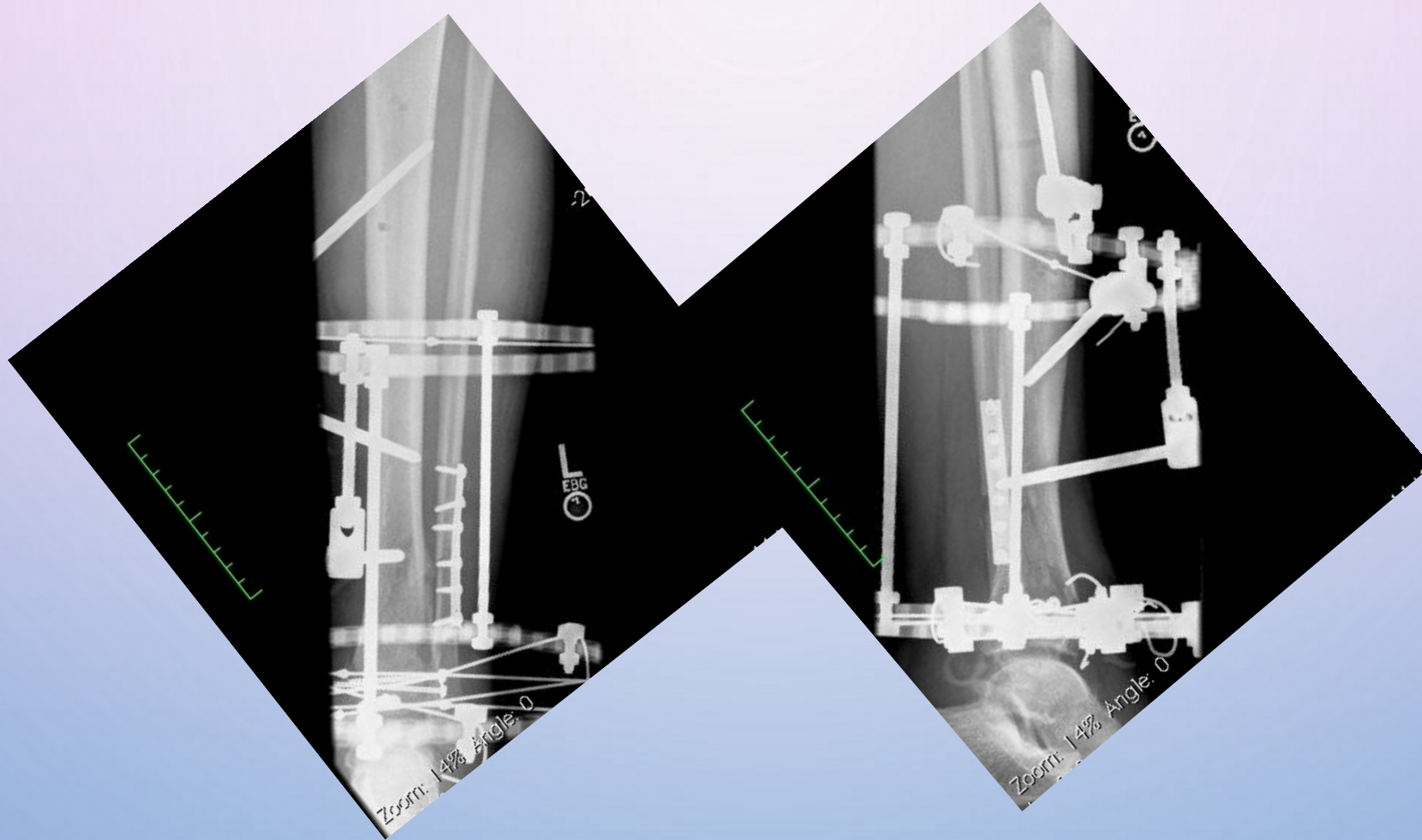
# SK.:POSSANNINGT



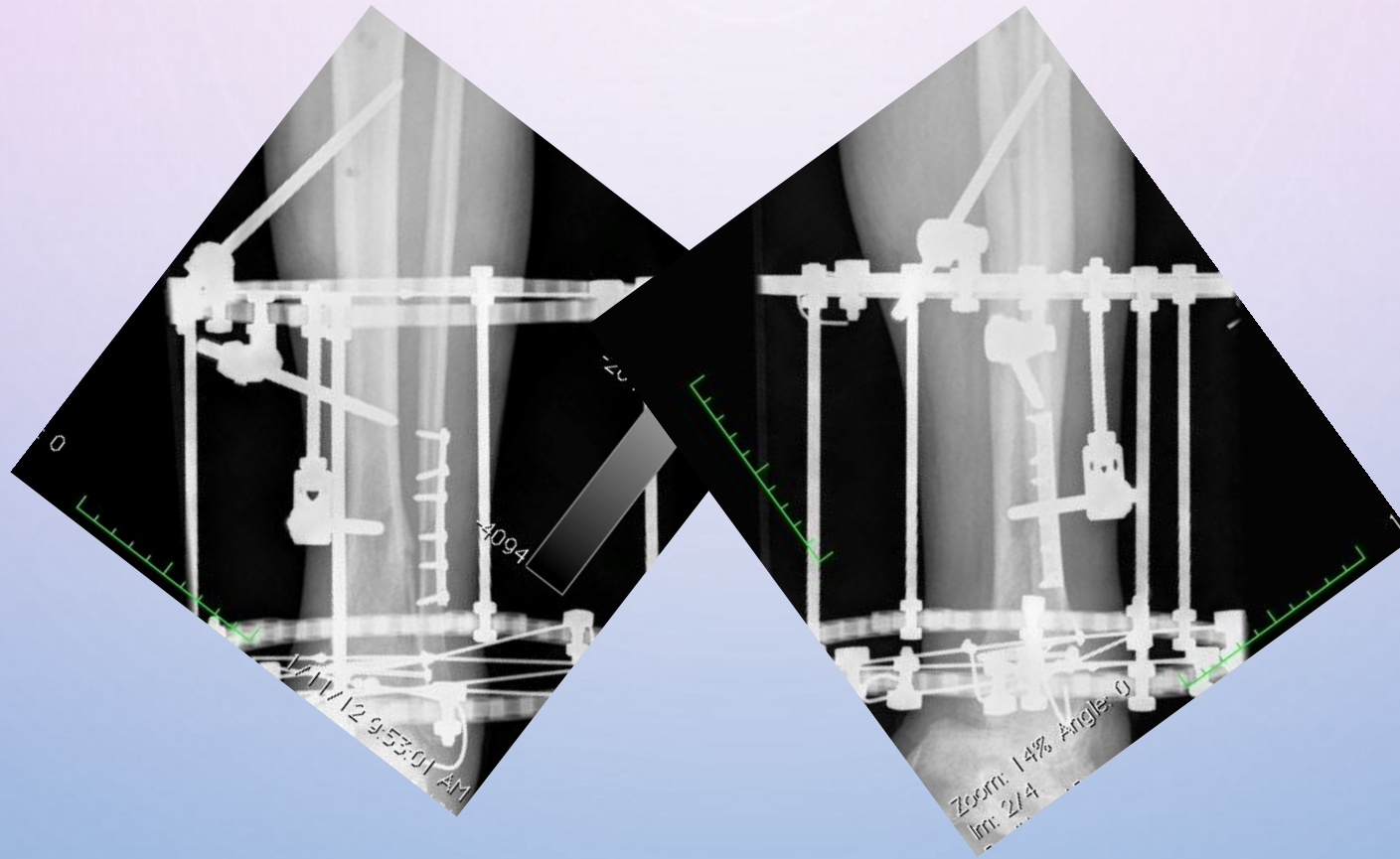
# SK.: MÖRJOININ KOKONAISKOMPONENTIT



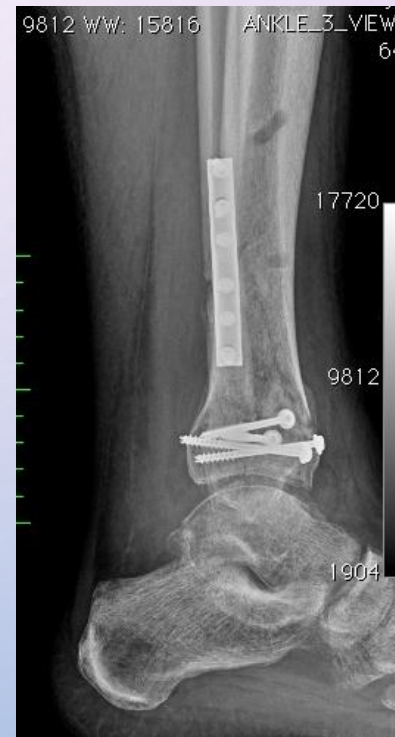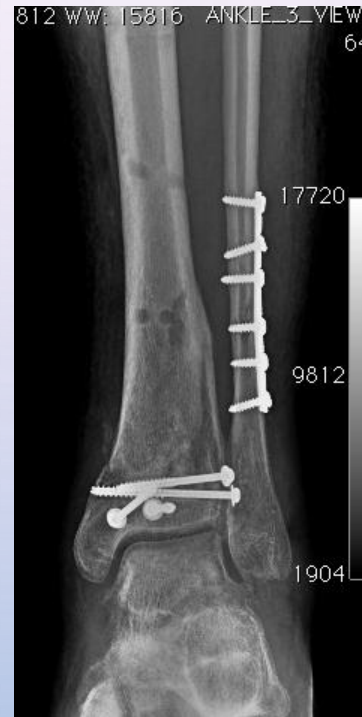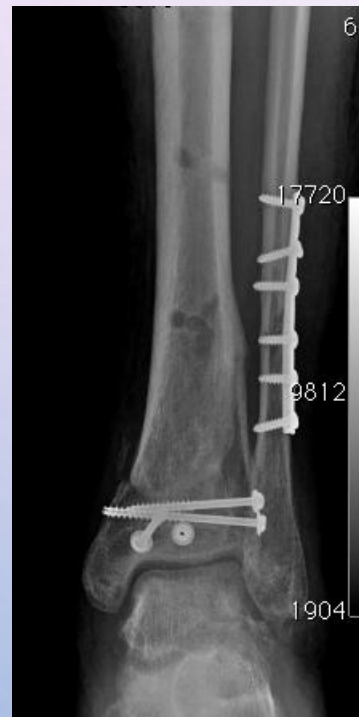# SK.:6 WKS POST OP



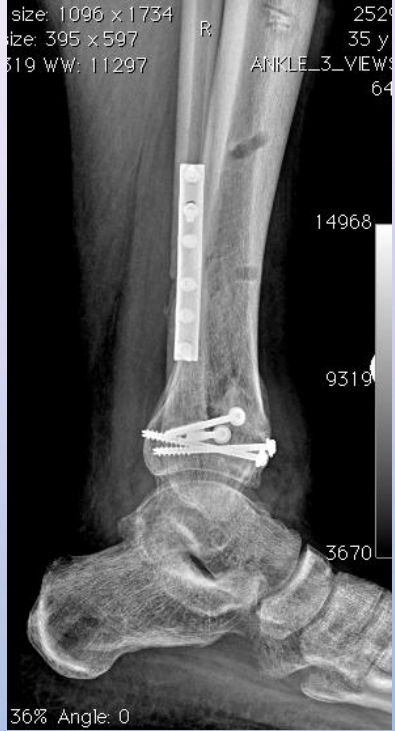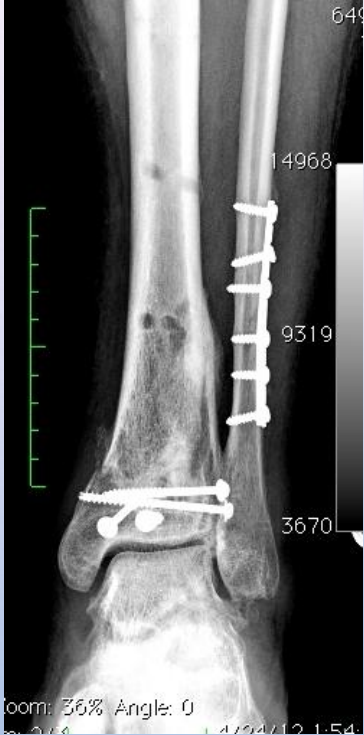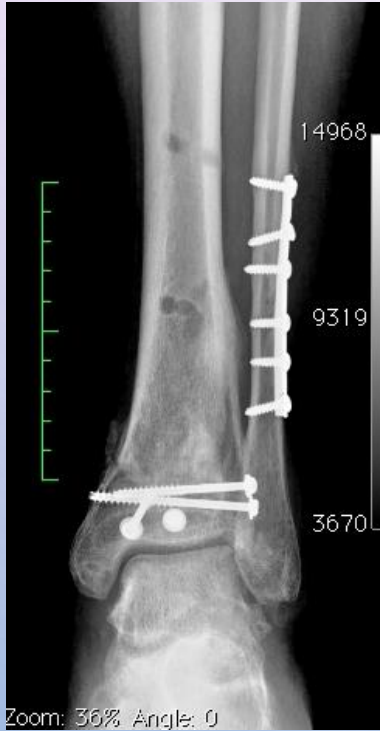# S.: 3 MONTHS POST OP



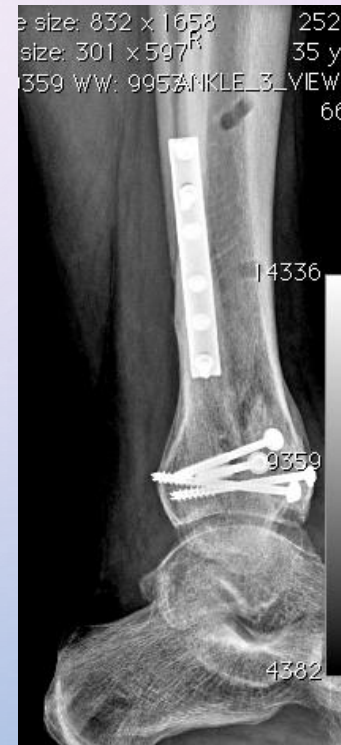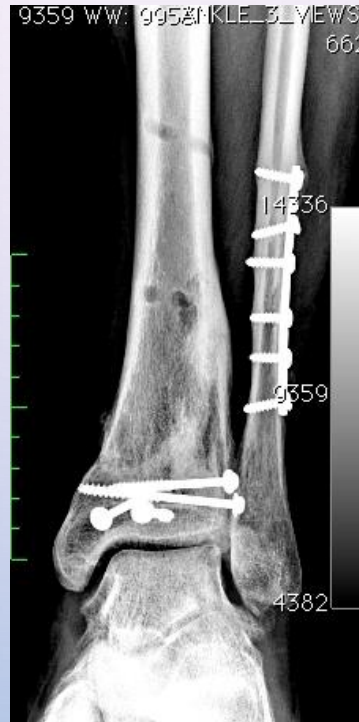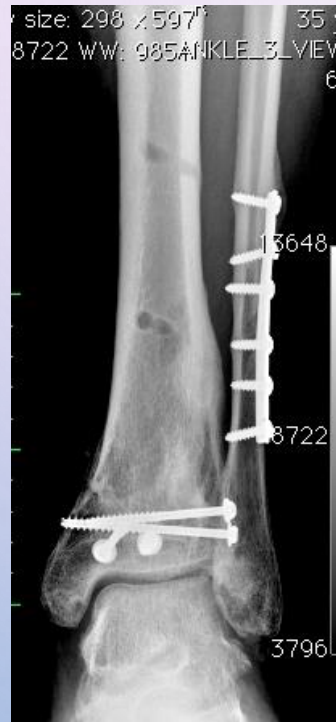# SK.: FLOWING MEMO VA



# SK.: 3 MONTHS POST OPERATIVE



# SK.: 1 YER OSNIV, REDIB NOGNITAN



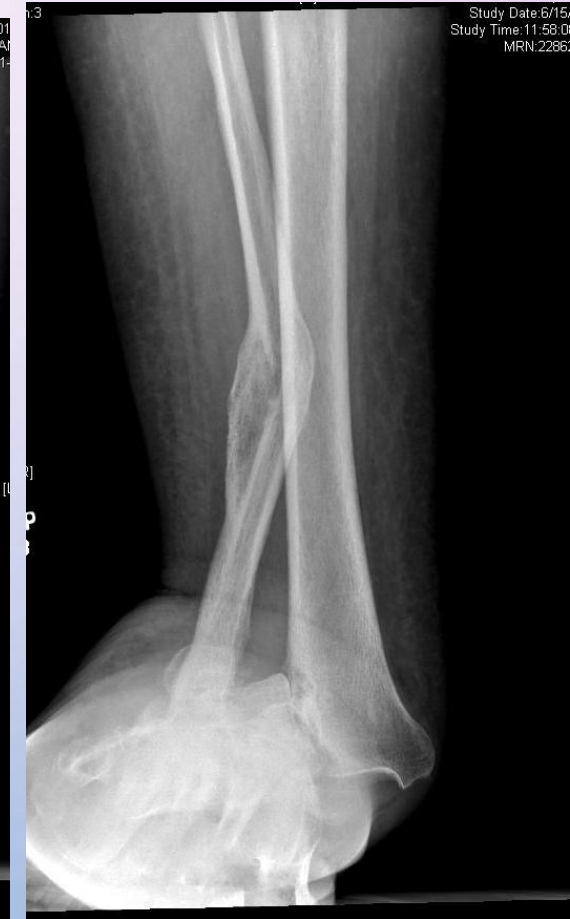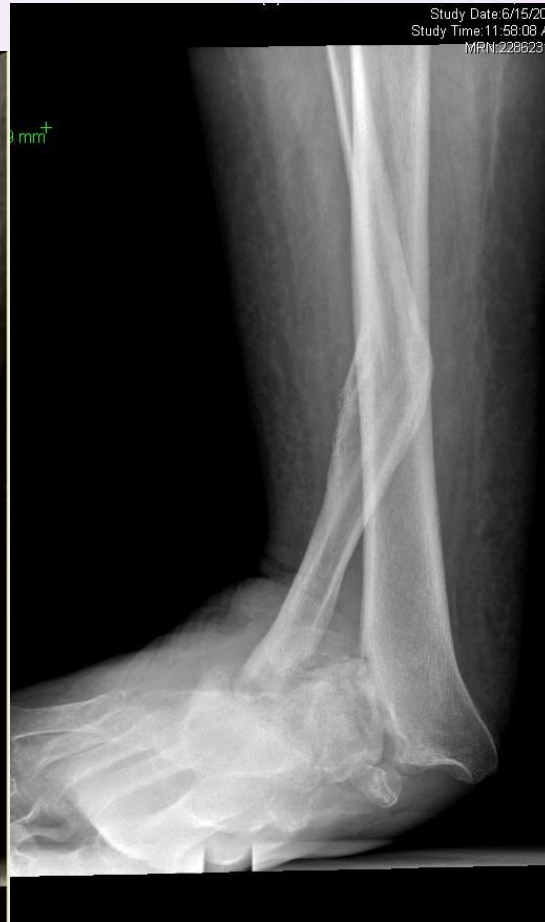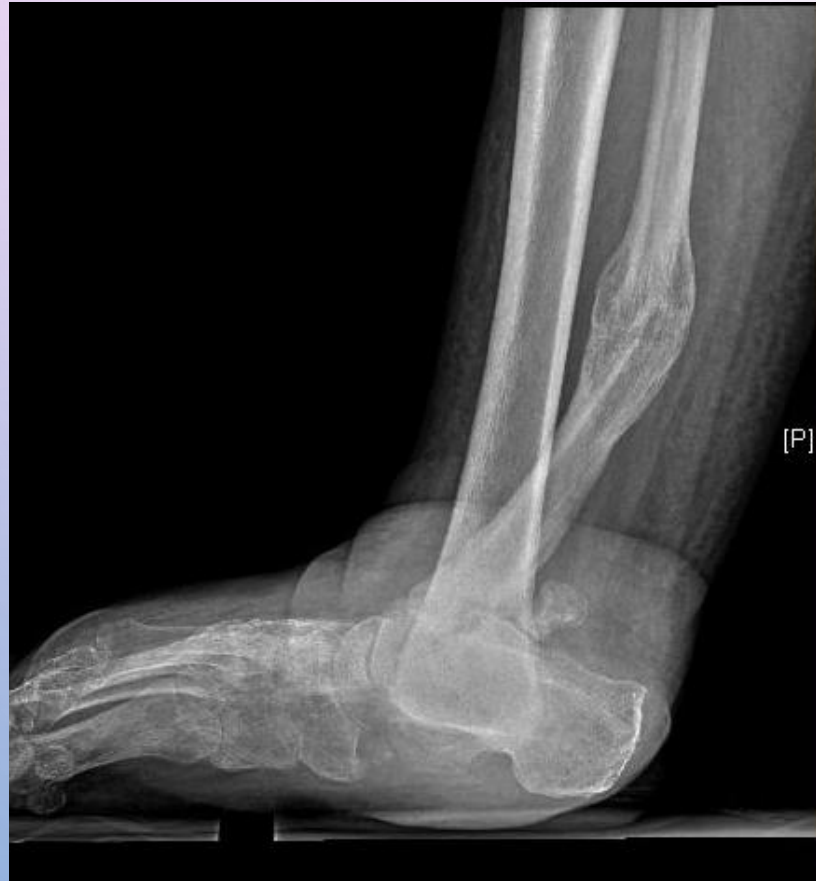SK.: 14 YERLOW PJ

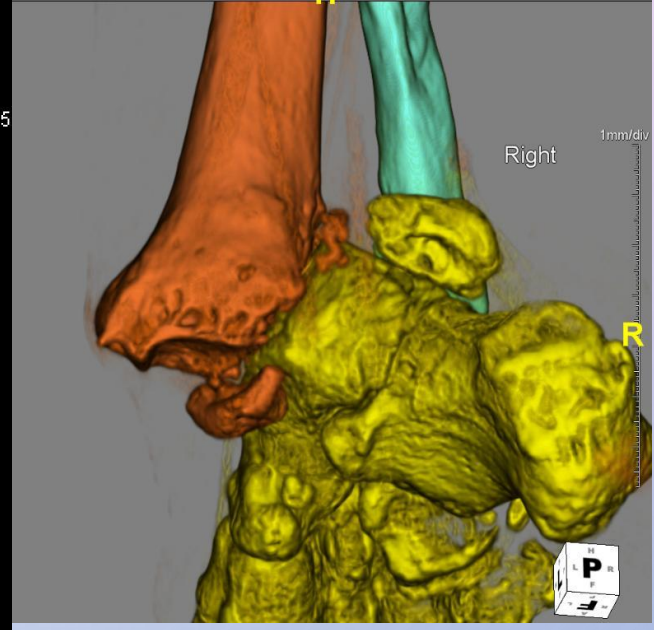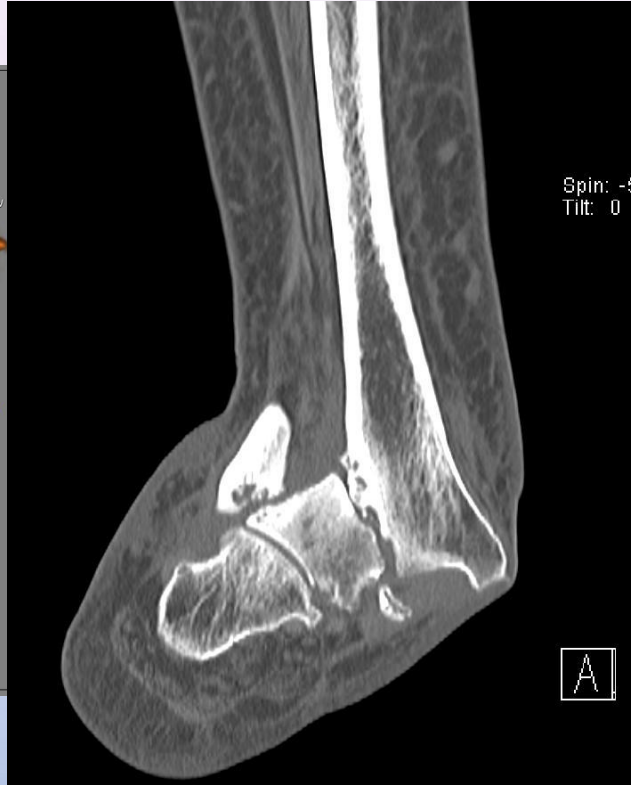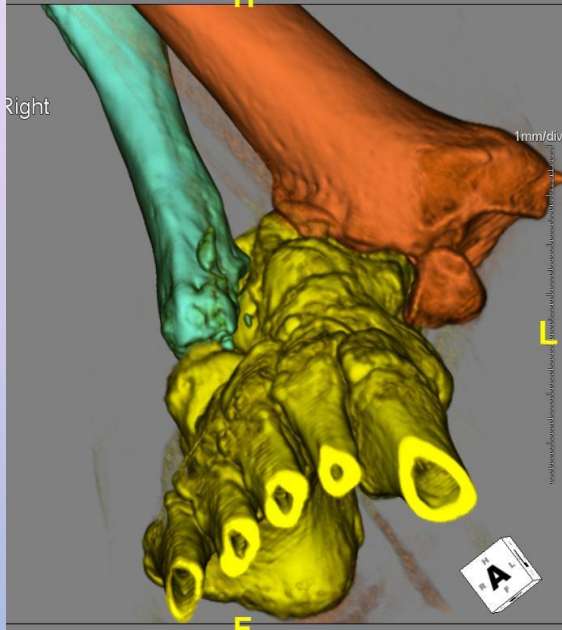- NOW 52Y/O.
- NOMINITY.
- A JOGADAKI 8HOGORU.

# J.W. CRONKLE SR

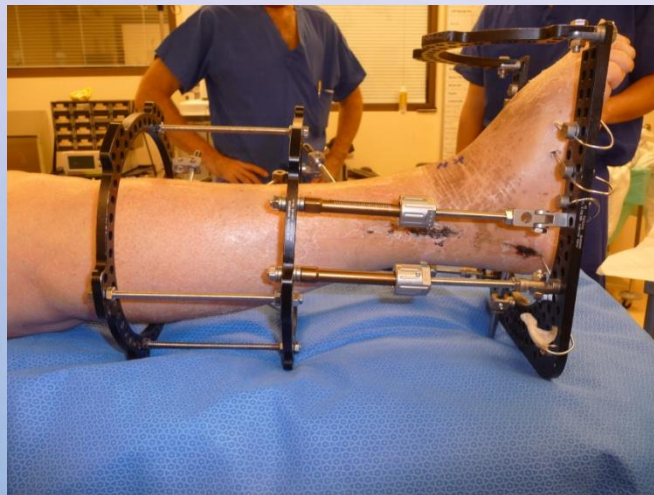
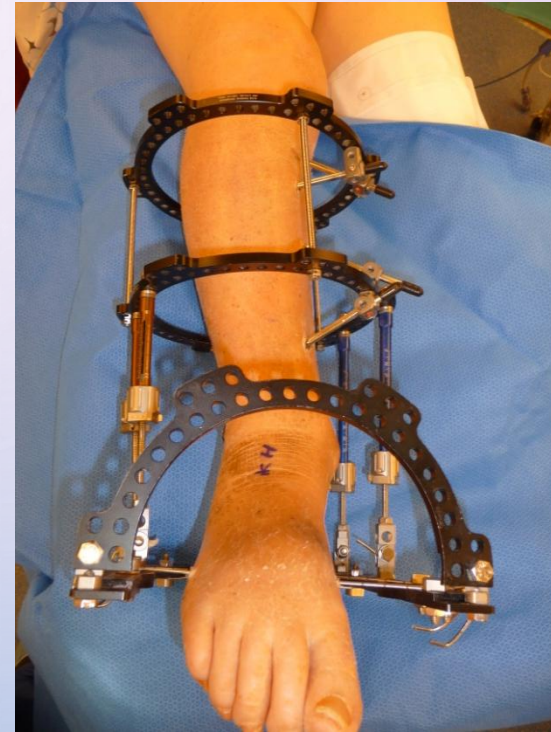
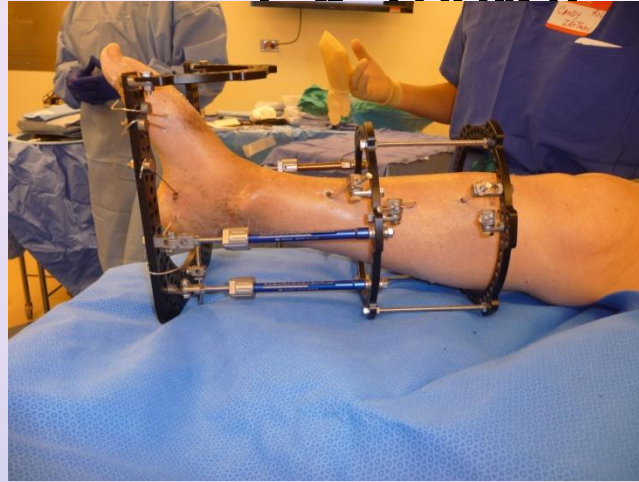- 63Y/OM/PEM/HOS/MDR.
- H/OH/OVAD/ON/TNT.
- EVH/END/WH/ONLY/FE/OD/RS
- RES NOW 2Y/DL/OW/NG/NU/WH/ONLY/FE/OW/AS/ION/RS/WH/PA.

# PERITINEALS

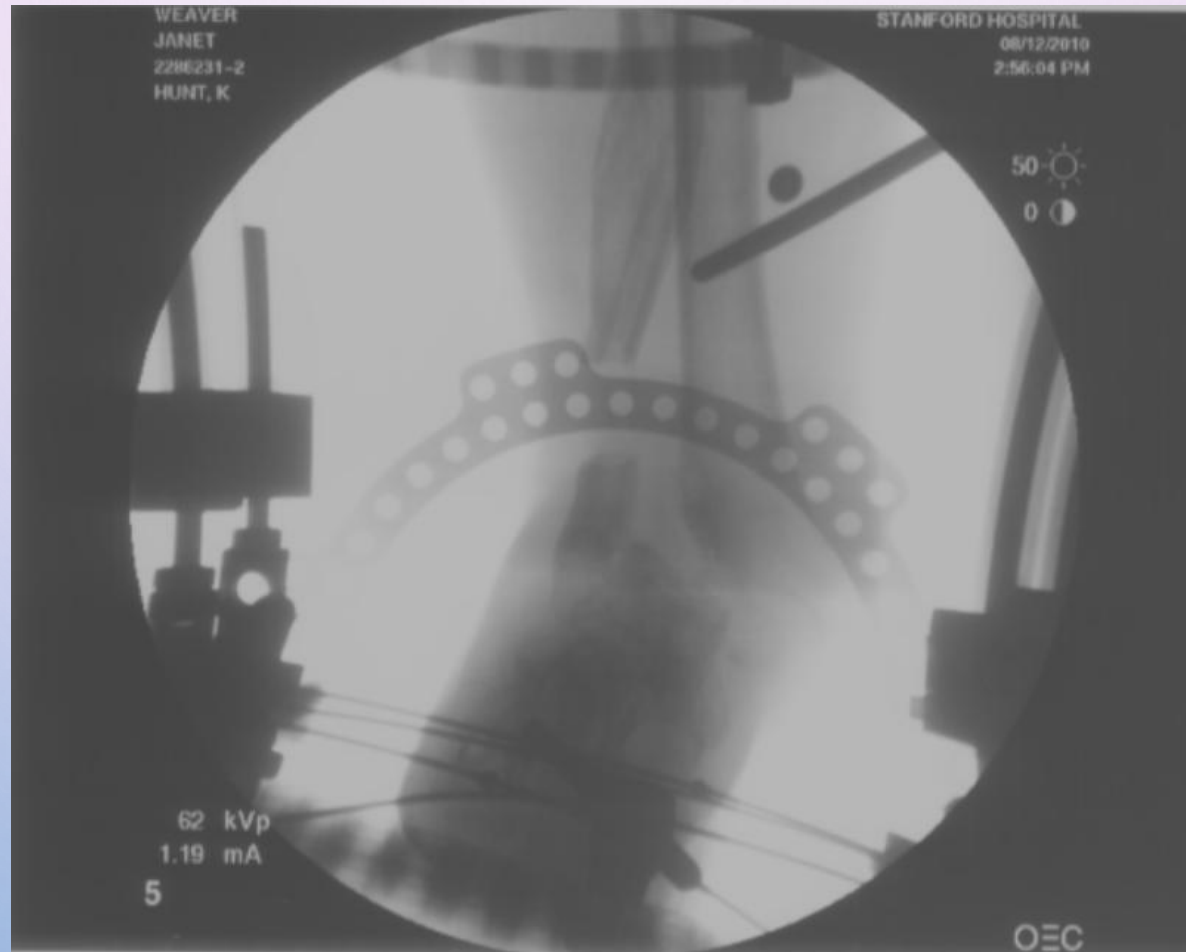




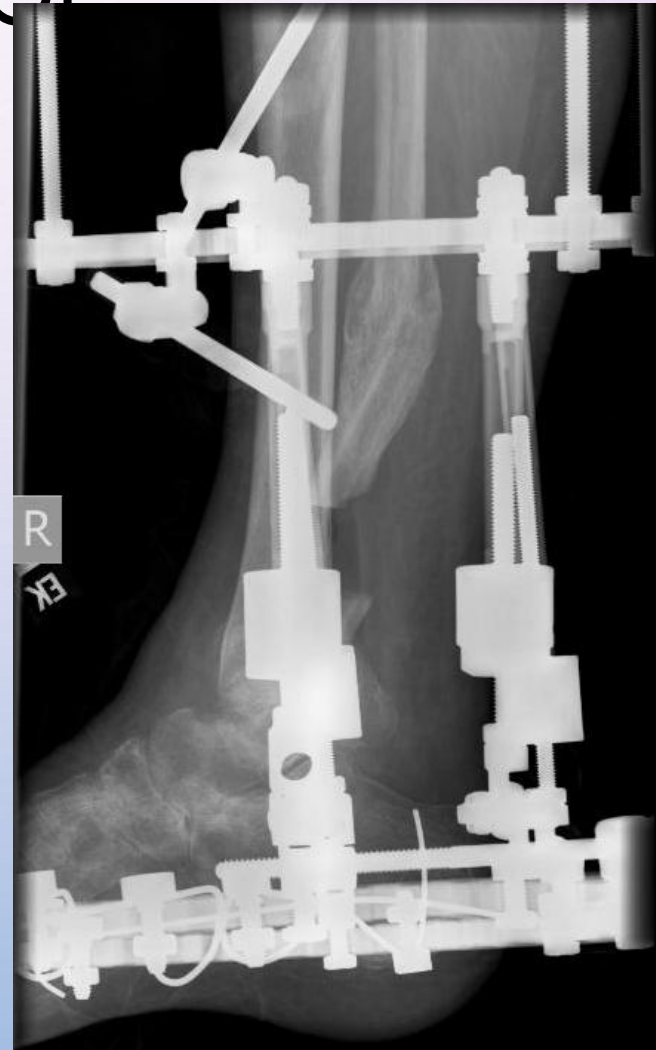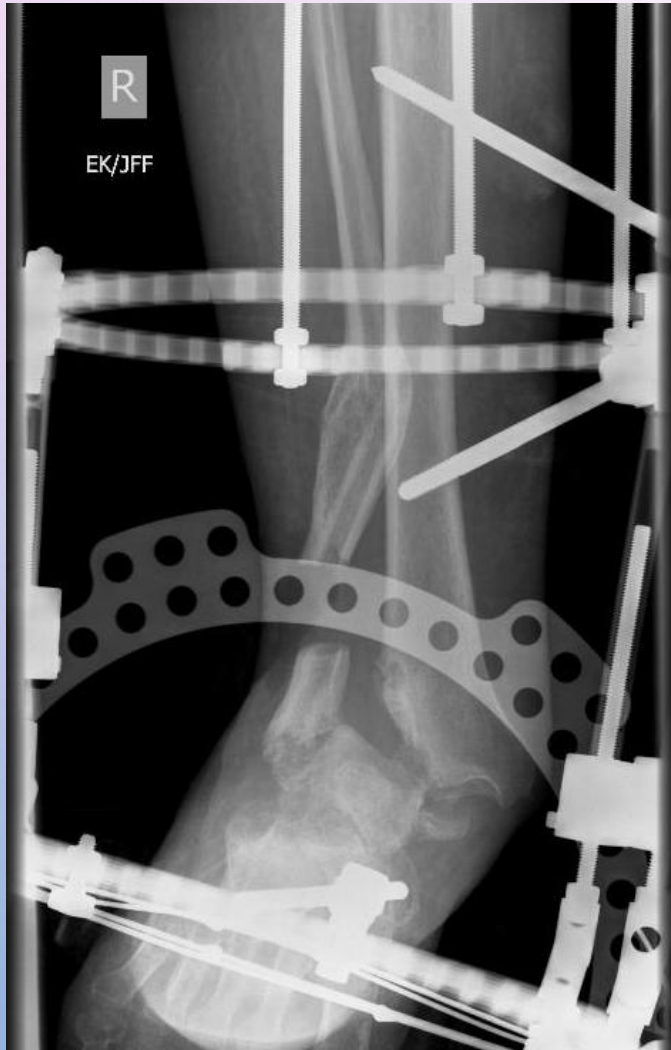
# DIY WALKER APPLICATION



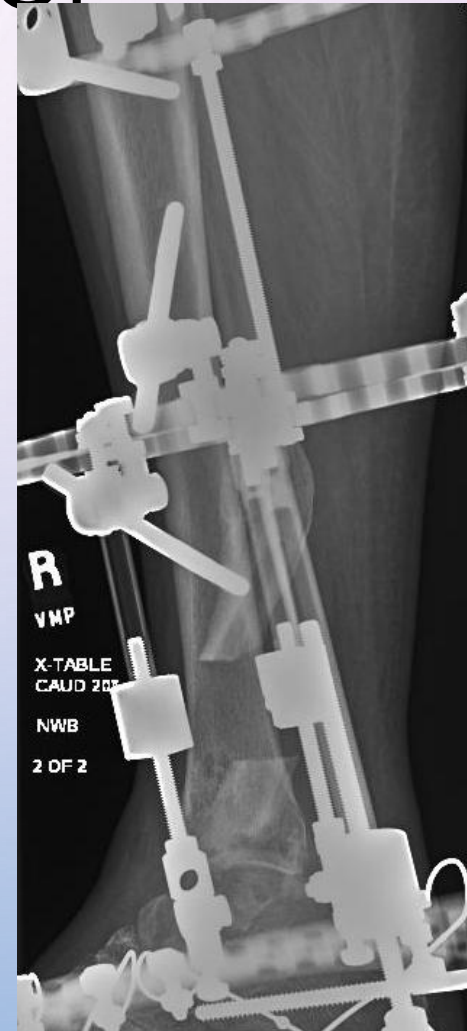
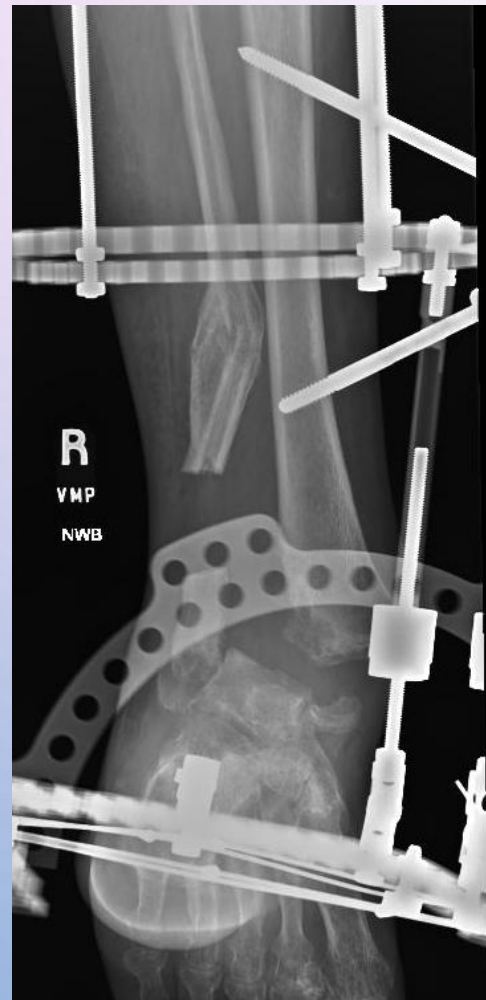
# NAOP



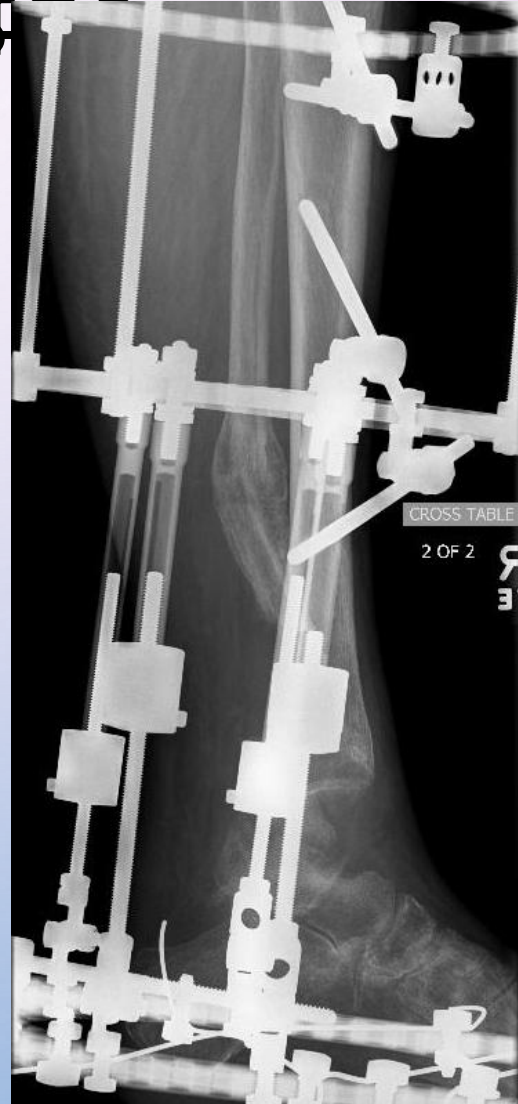
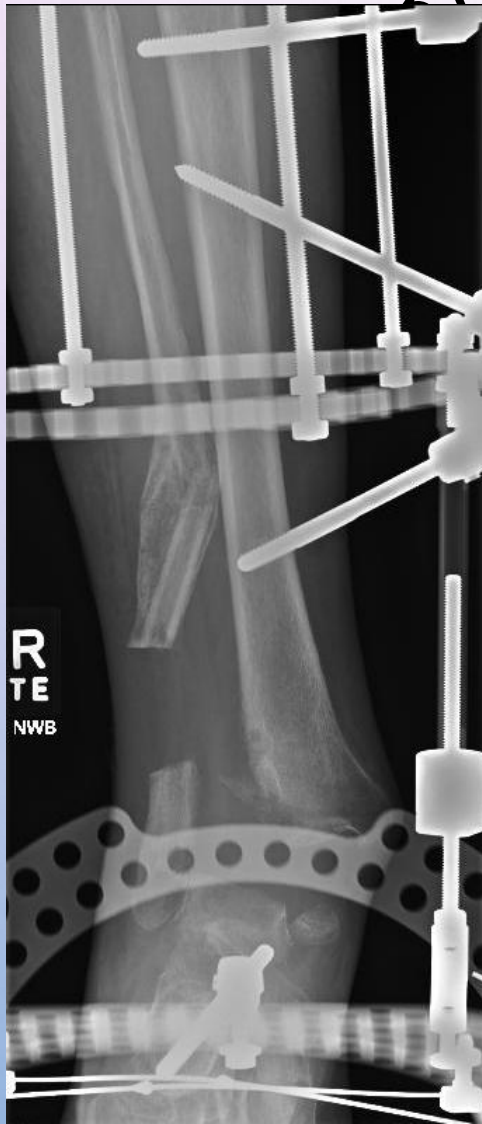# POSTOP



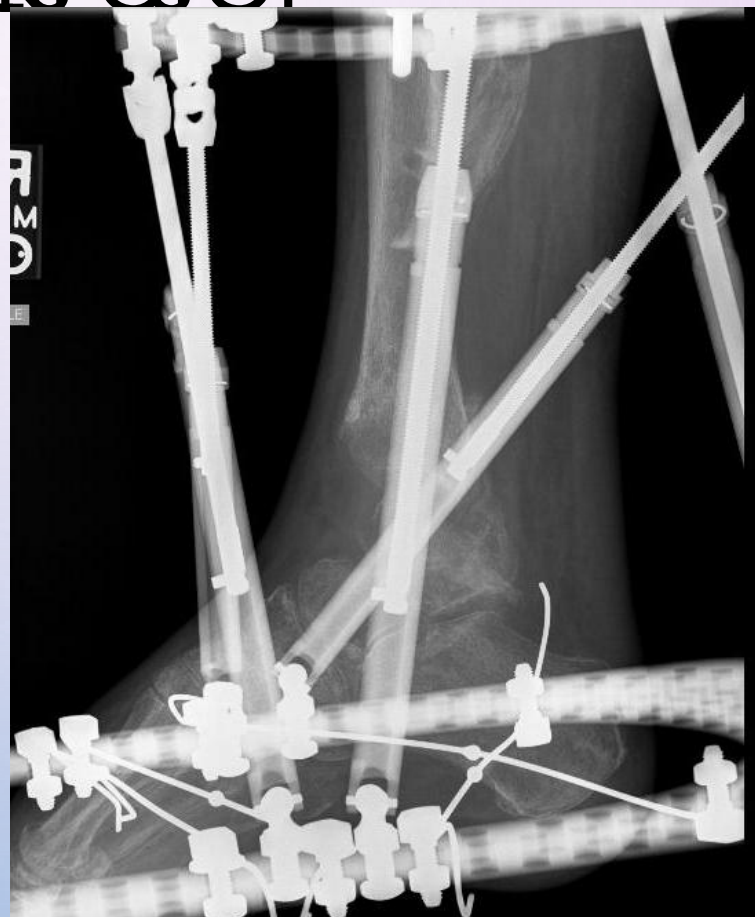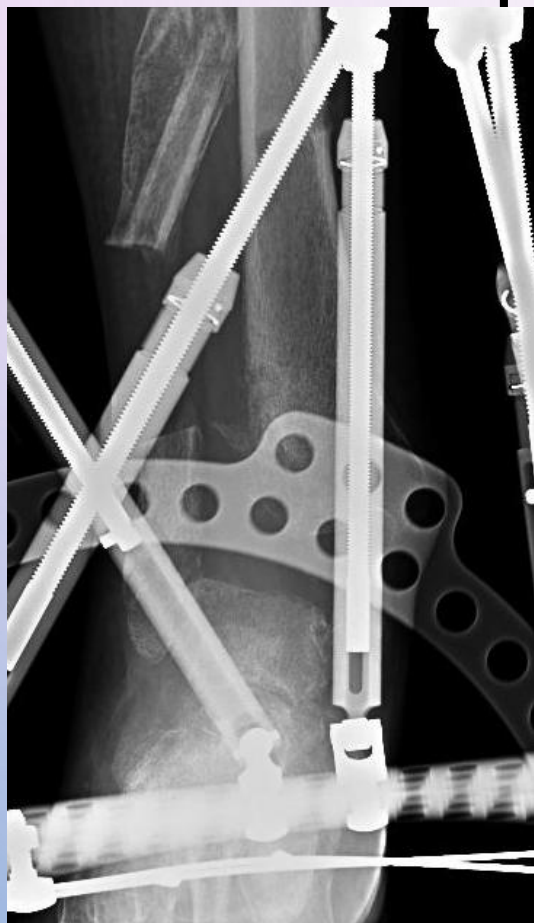
# 2 WEEKS POST OP



# WILSON'S

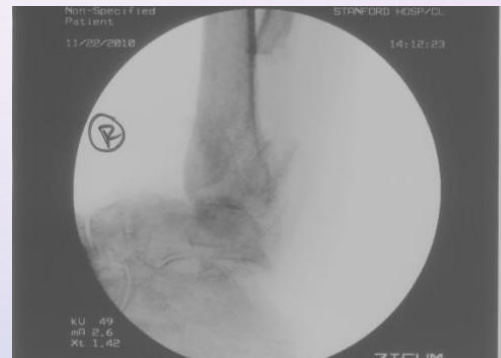
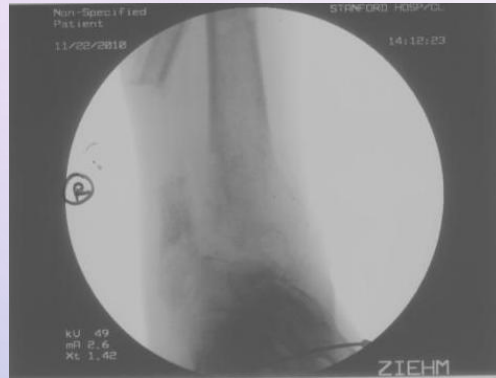
10 WEEKS POST OP

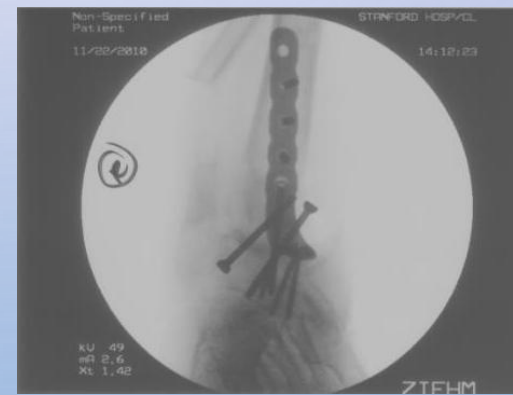
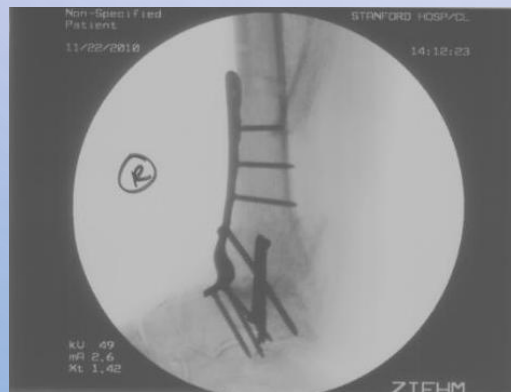
# NAOP

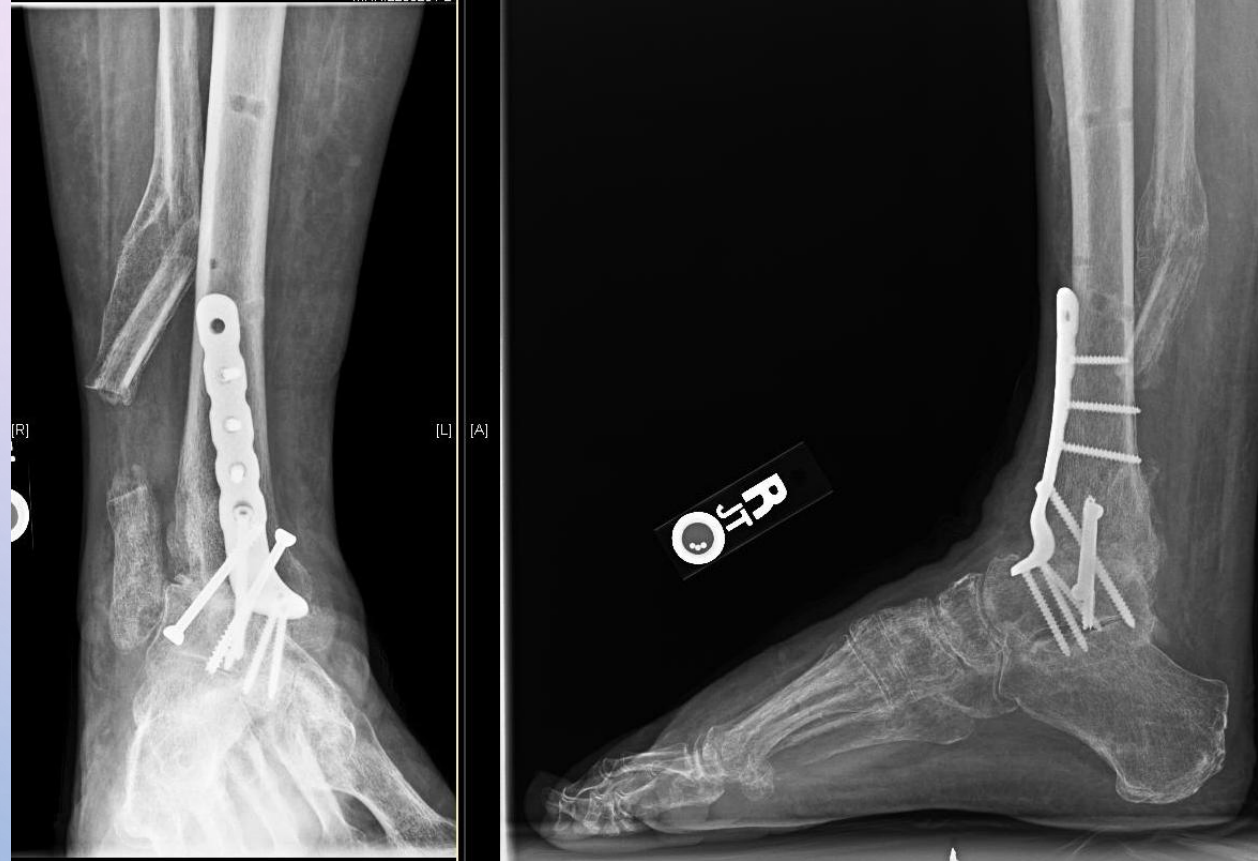- ~~ERODONM~~



- ~~SNWHA~~



2 MONTHS POST OP, NOW WALKING WITHOUT



J.W.: 6 MONTH FOLLOW UP

