

Proximal Tibia Cases

Mark Xu MD

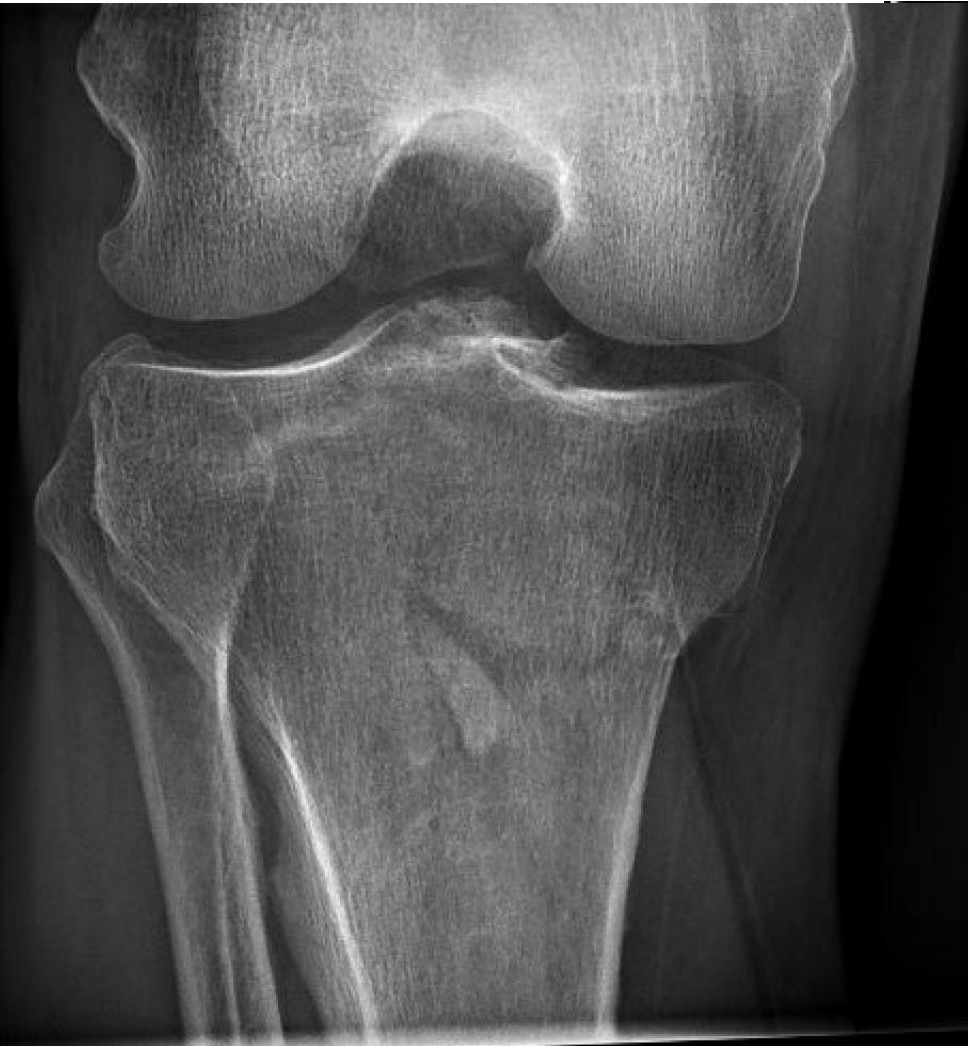Department of Orthopaedic Surgery
University of California, San Francisco



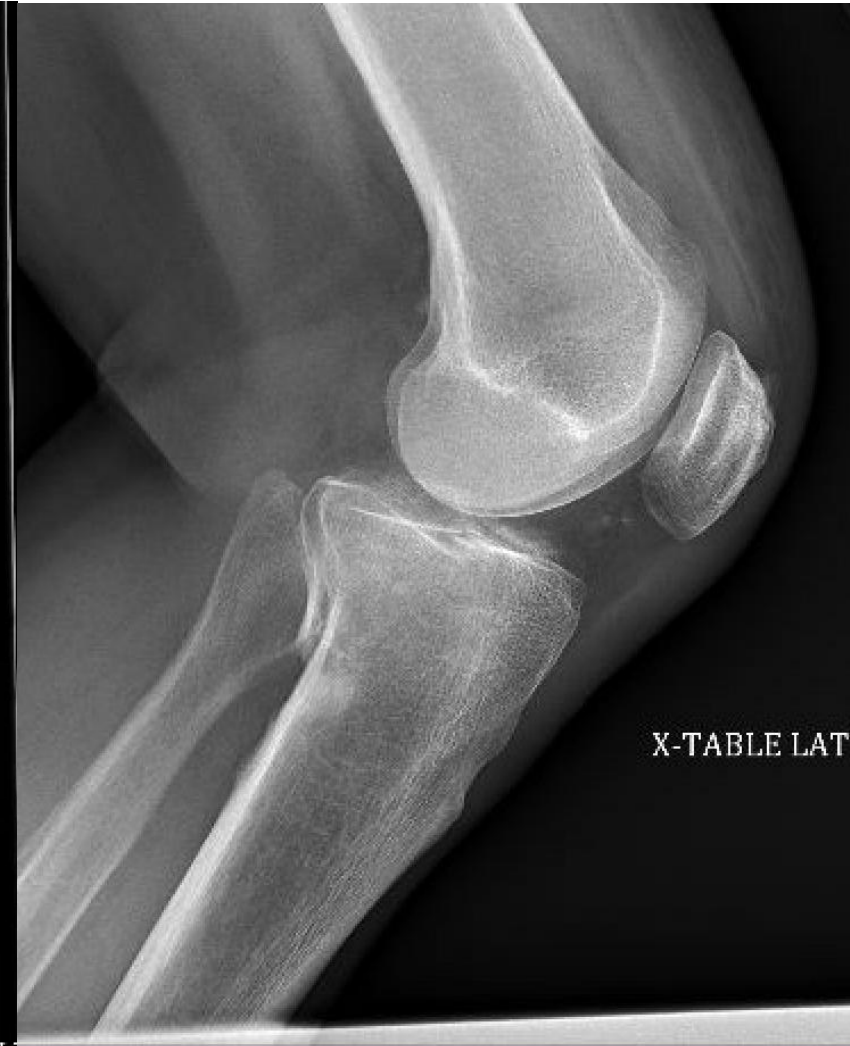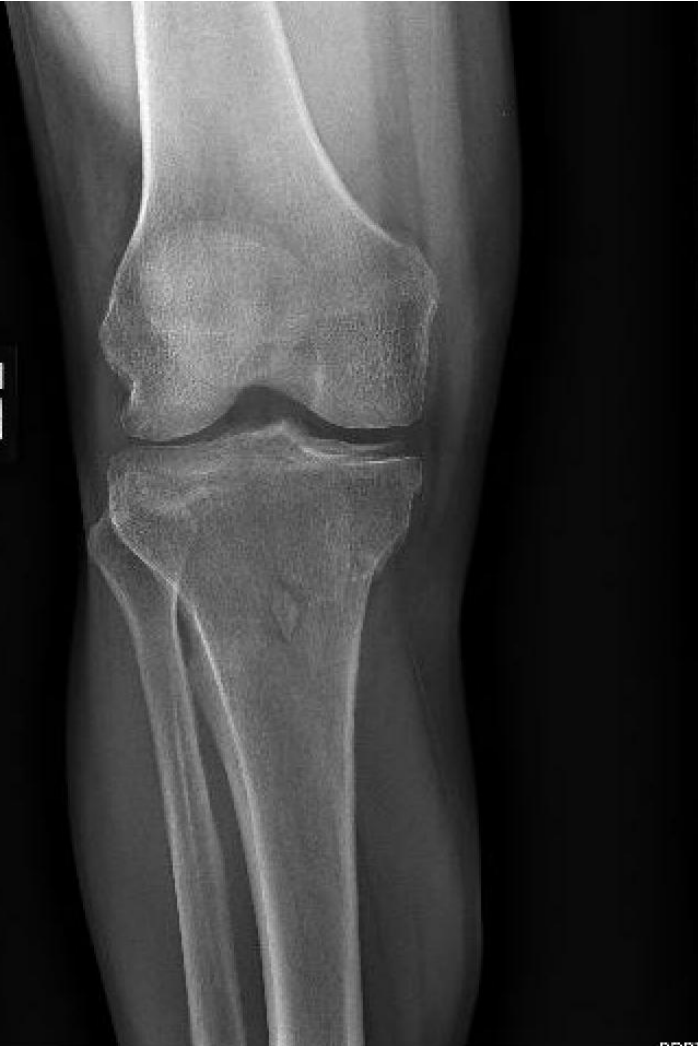77M fall from ladder

PMHX:

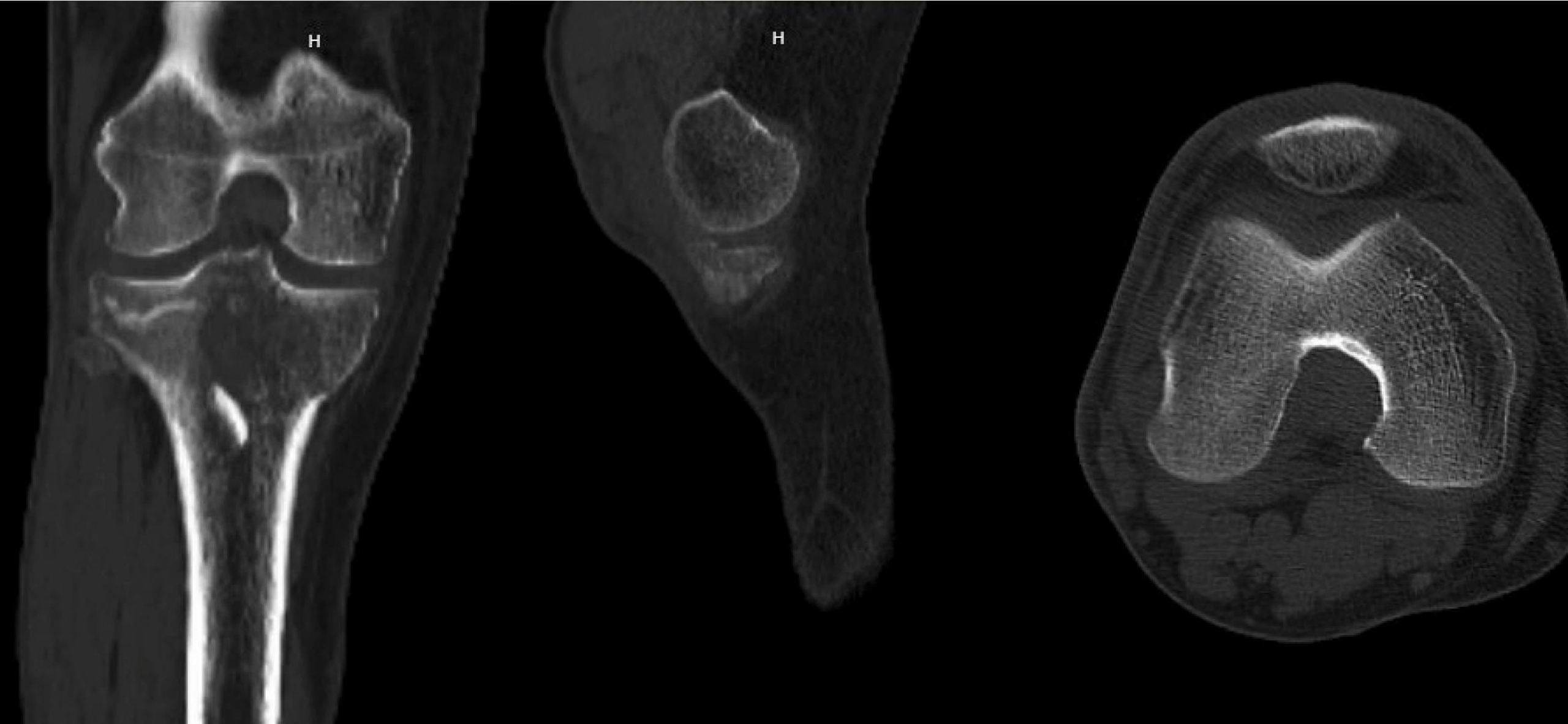
Crohn's disease, HTN, MI (prior PCI), Pre-DM



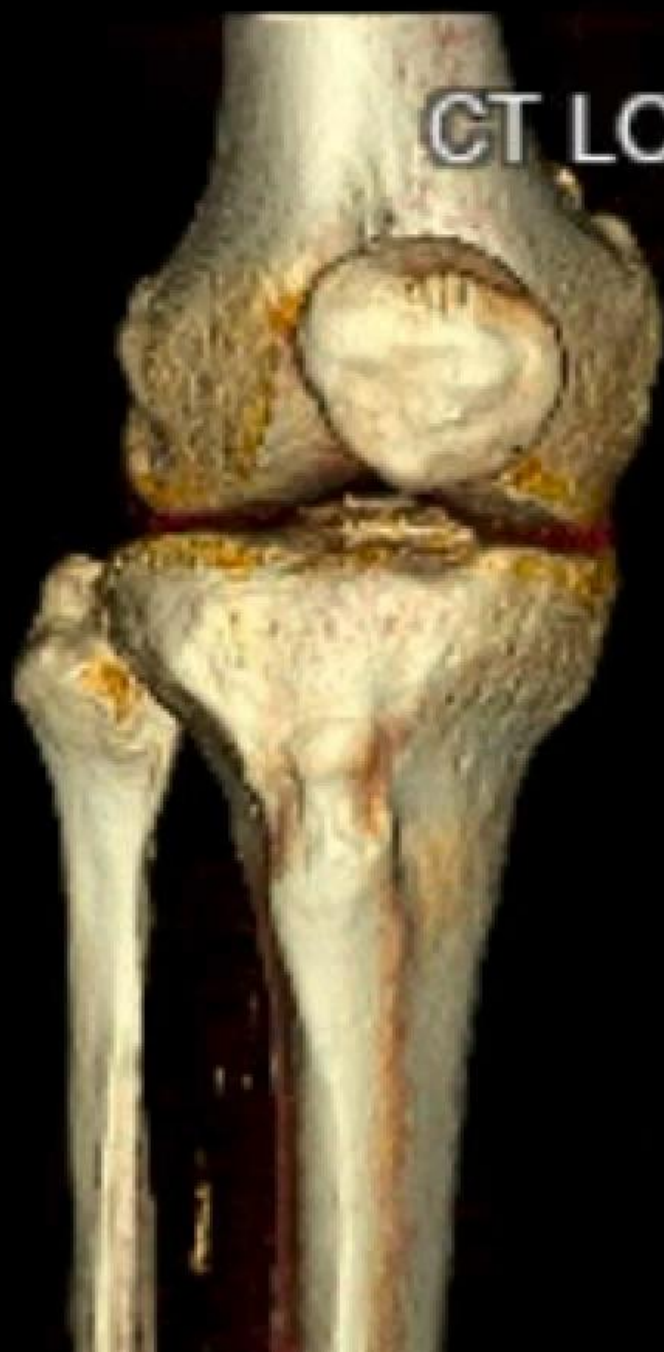AP



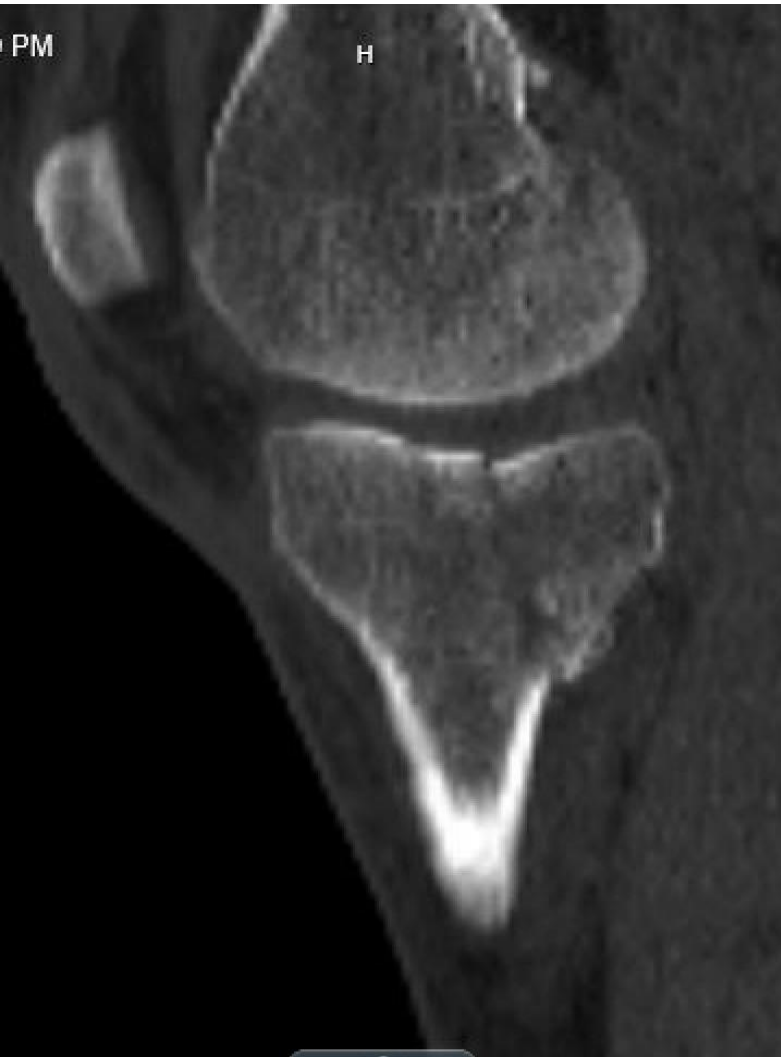
X-TABLE LAT



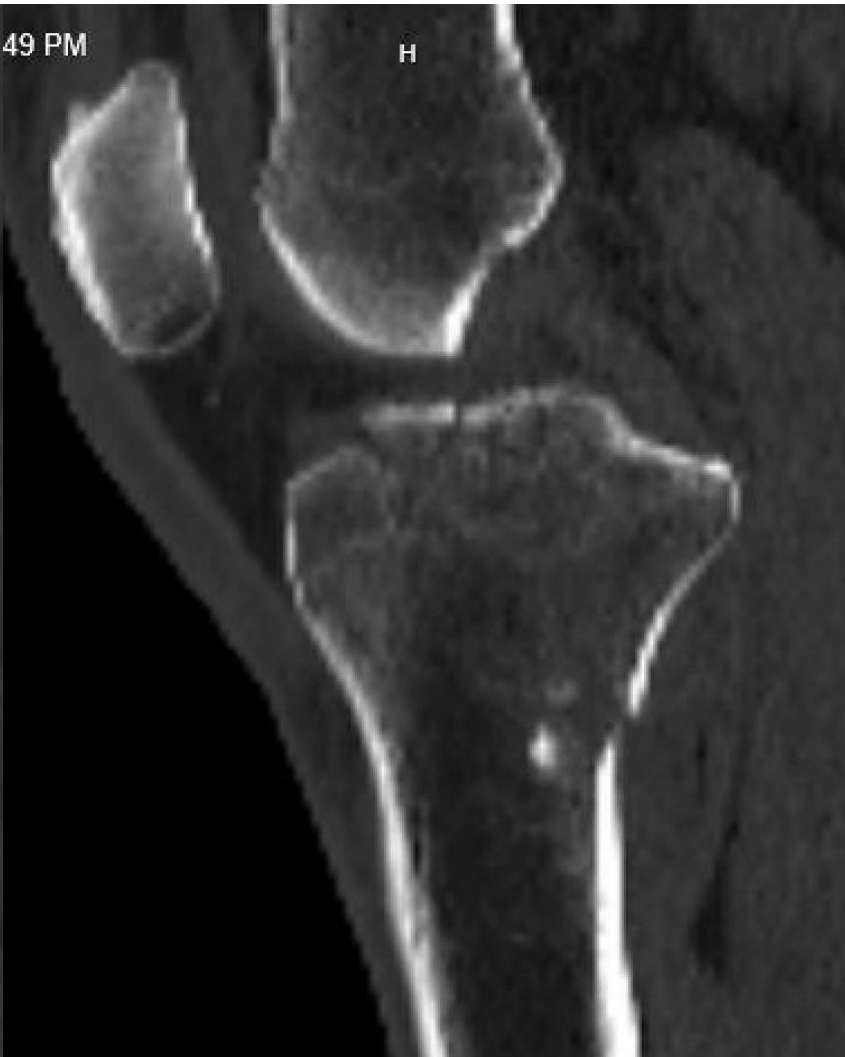CT LOWER EX
S



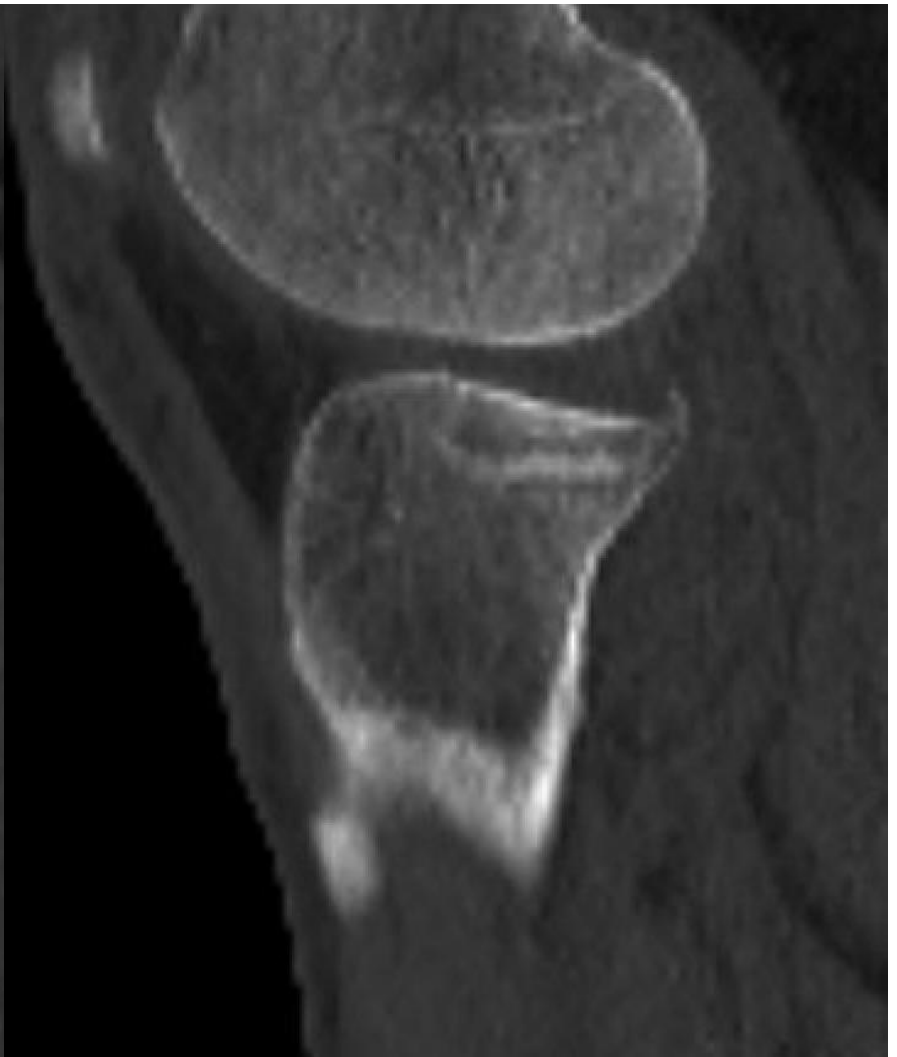Medial

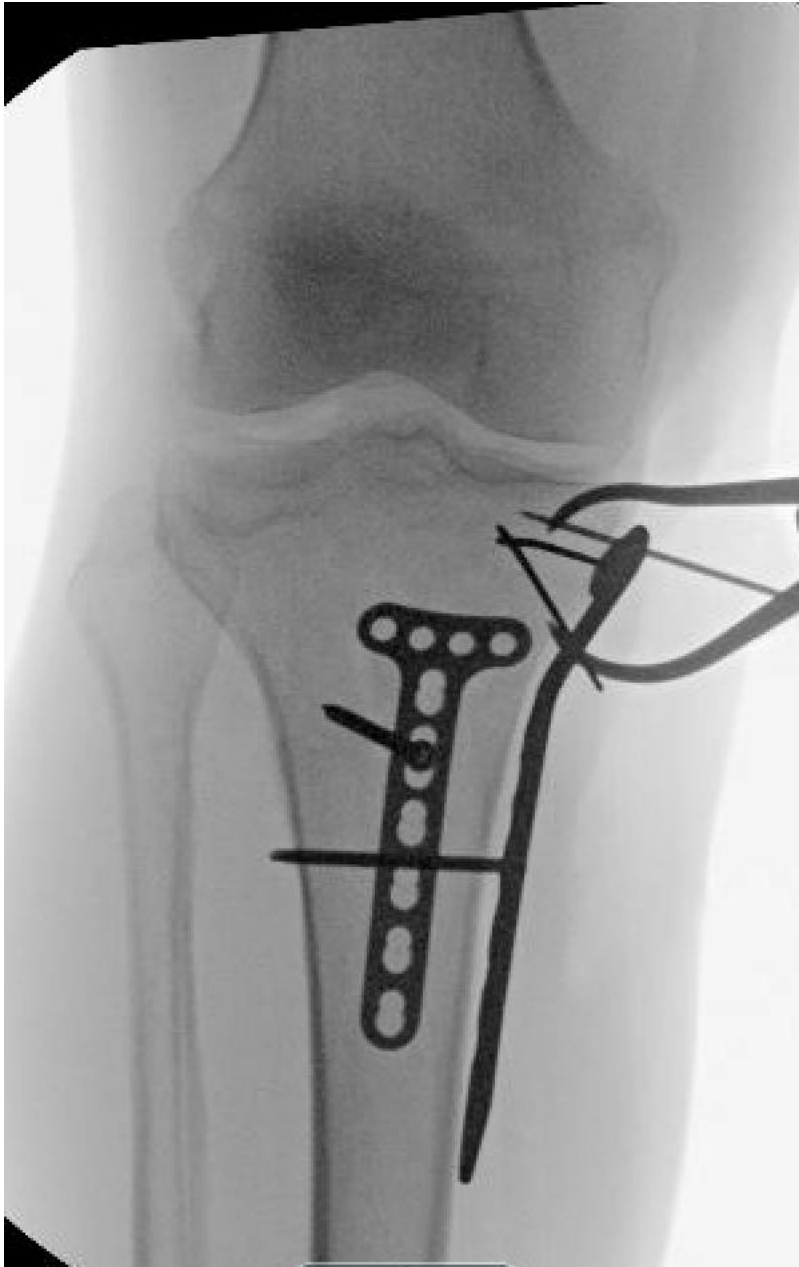

Medial




Lateral

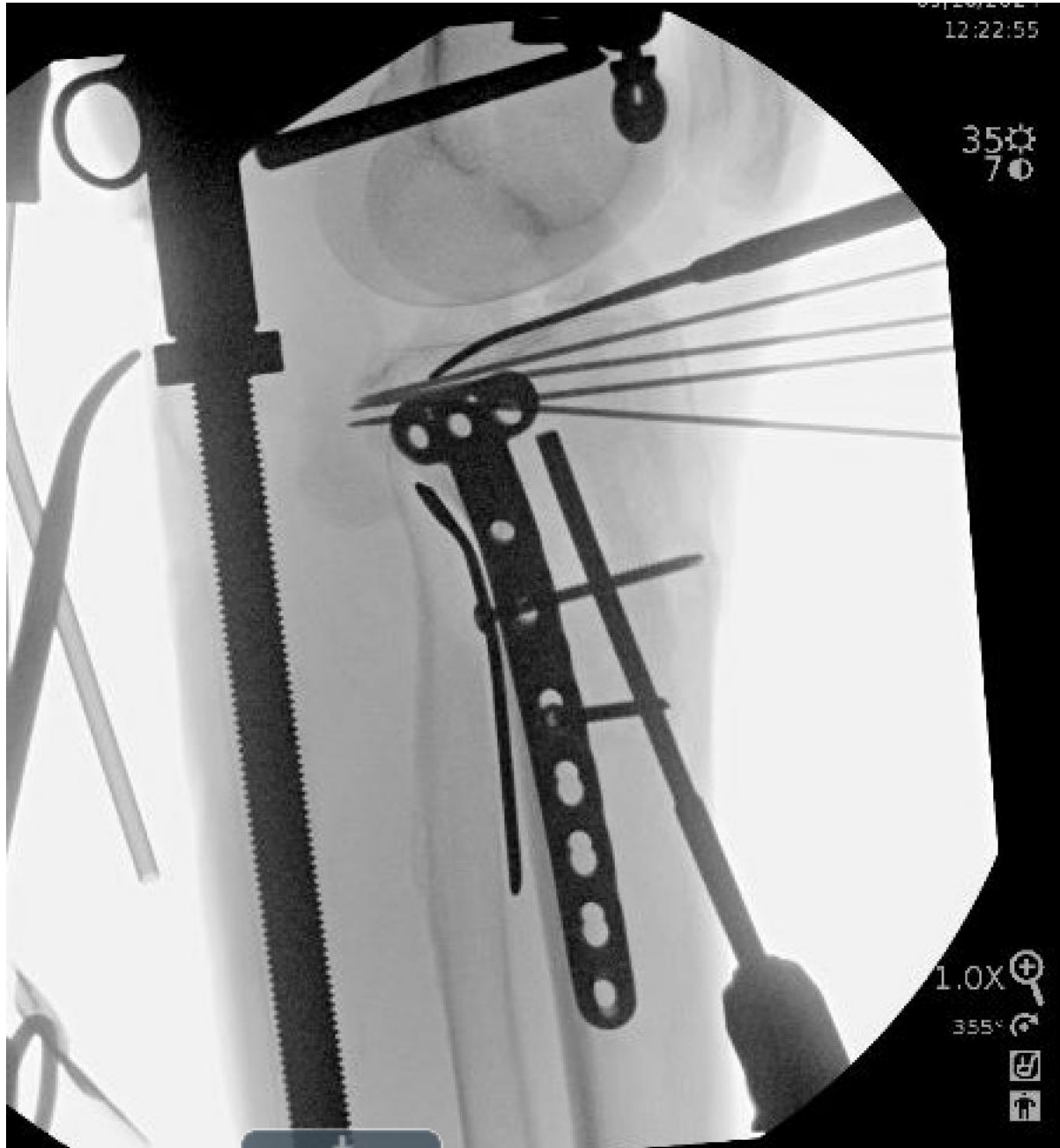



Medial plateau reduction



Medial plateau reduction

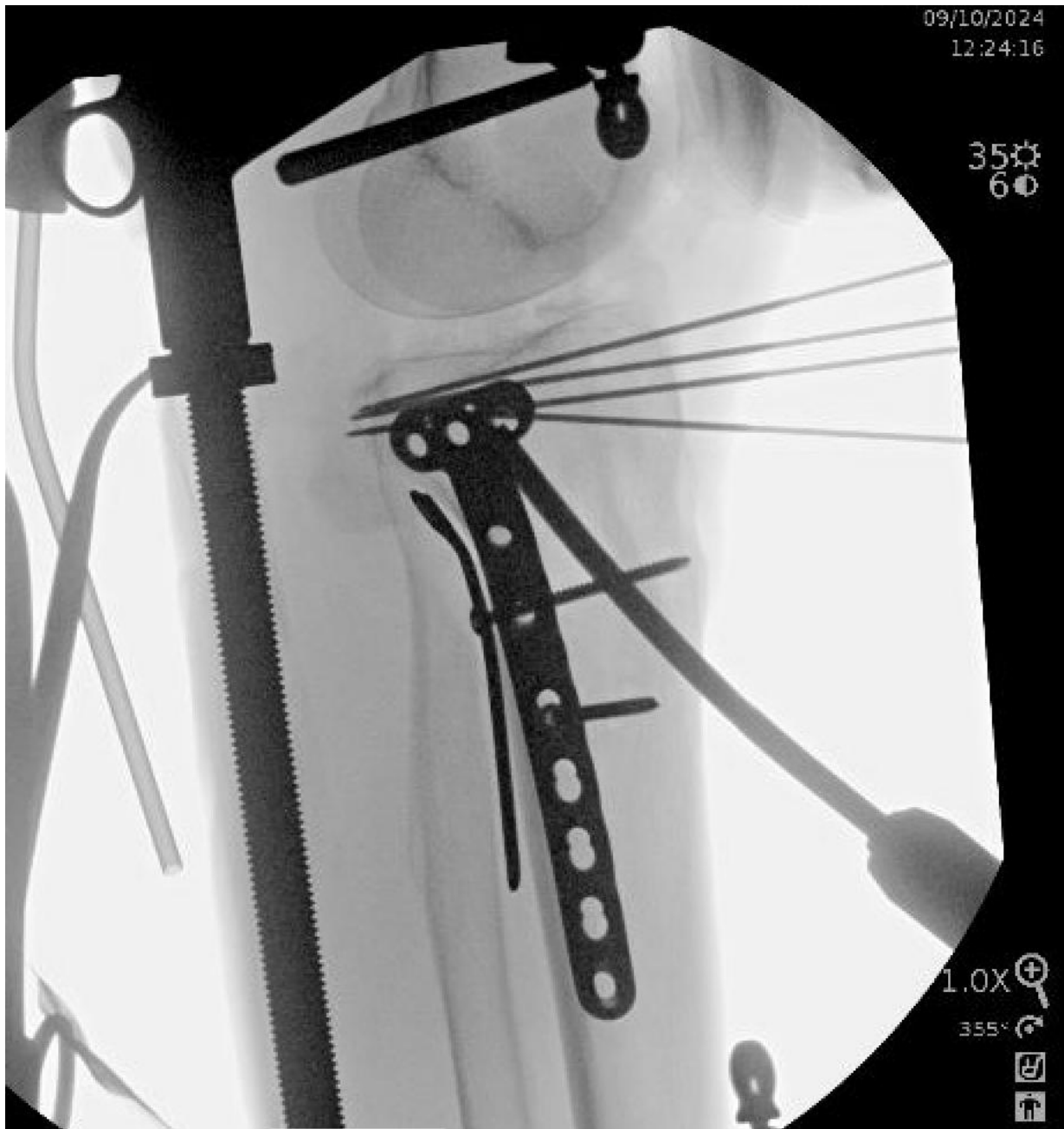

Lateral plateau
posterior tilt /
depression

09/10/2024

12:24:16

35
60



1.0X

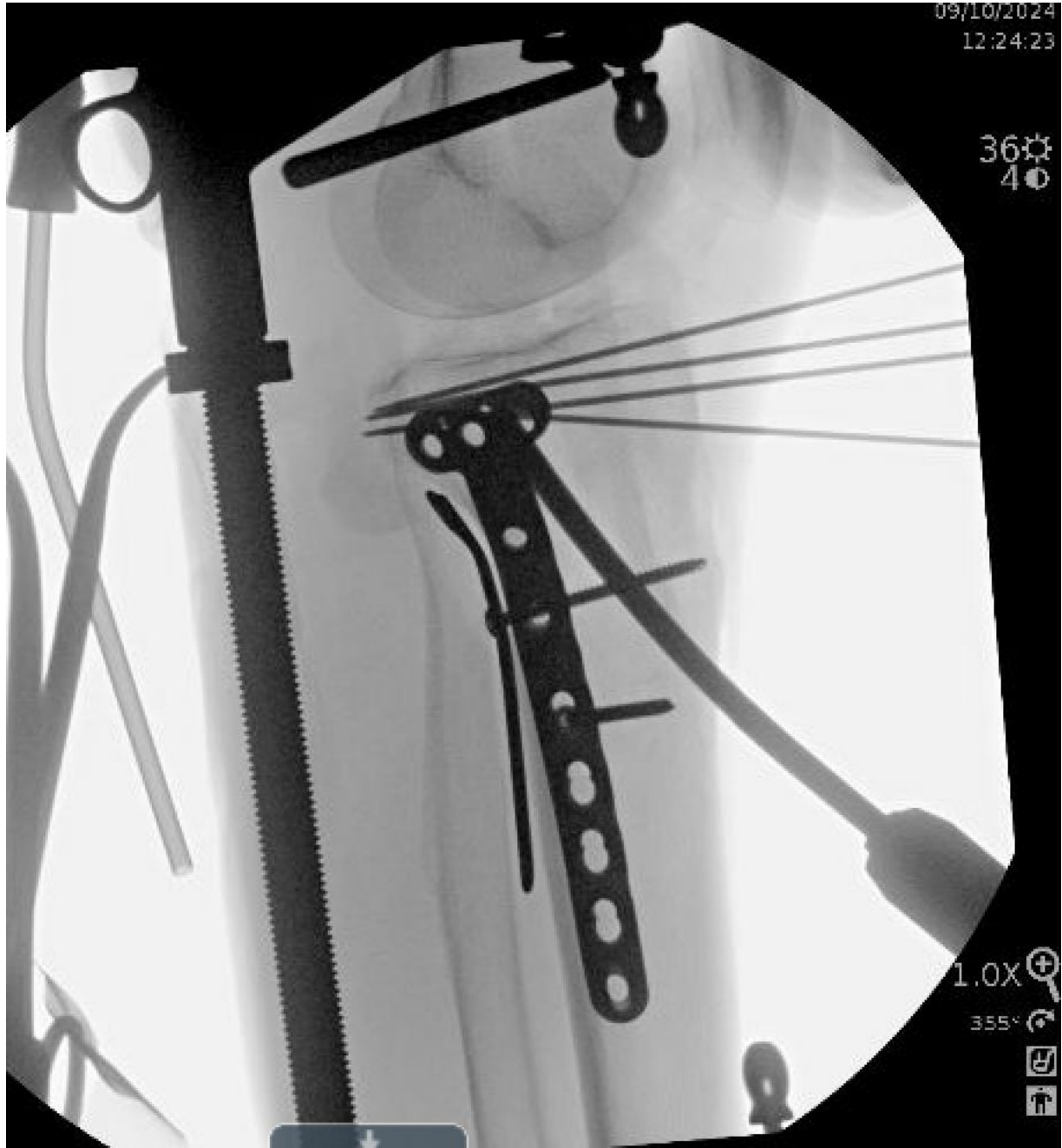
355°



09/10/2024

12:24:23

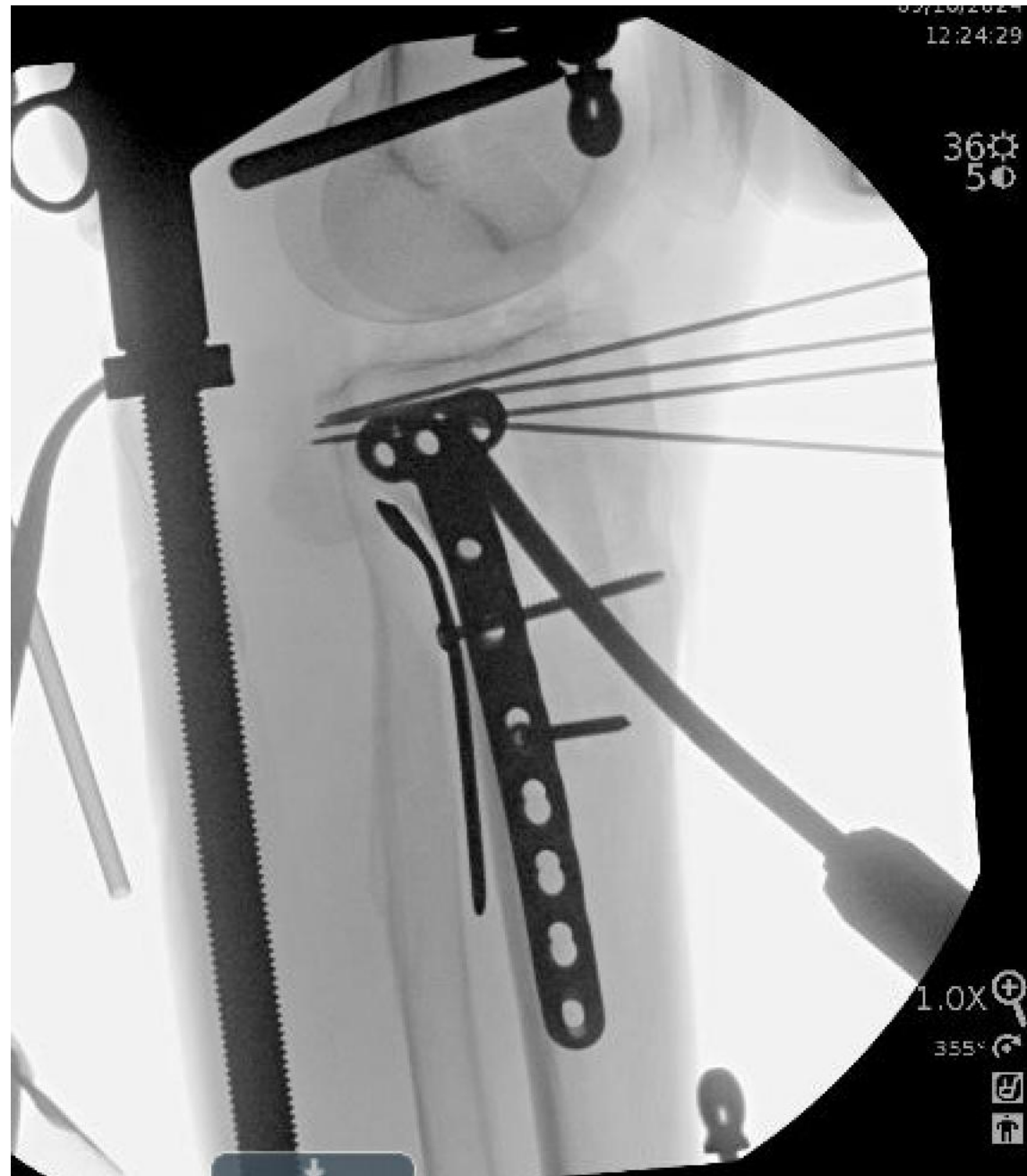
36°
40



1.0X

355°





05/10/2024

12:24:29

36°
50

1.0X

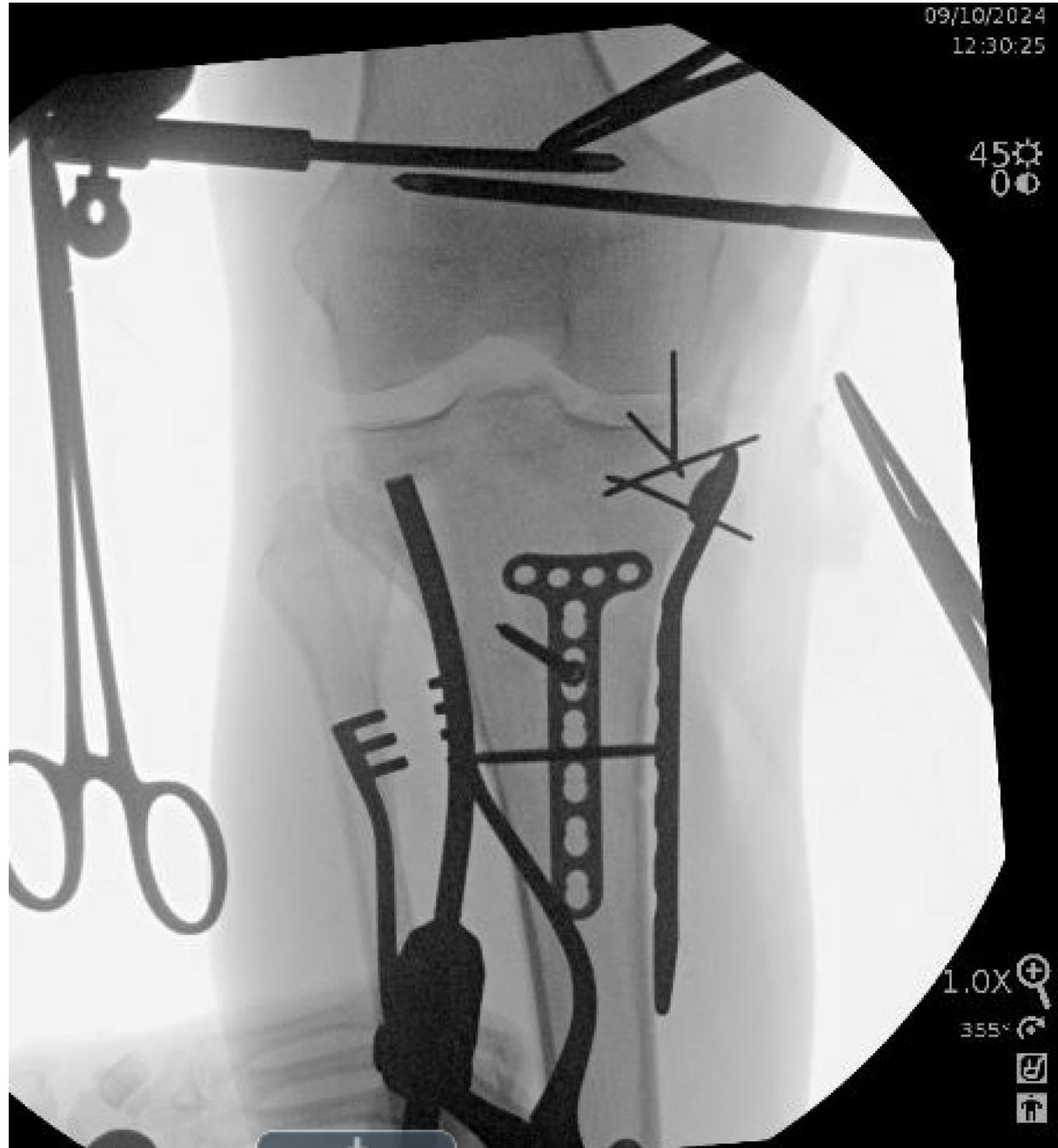355°



09/10/2024

12:30:25

45°
0°



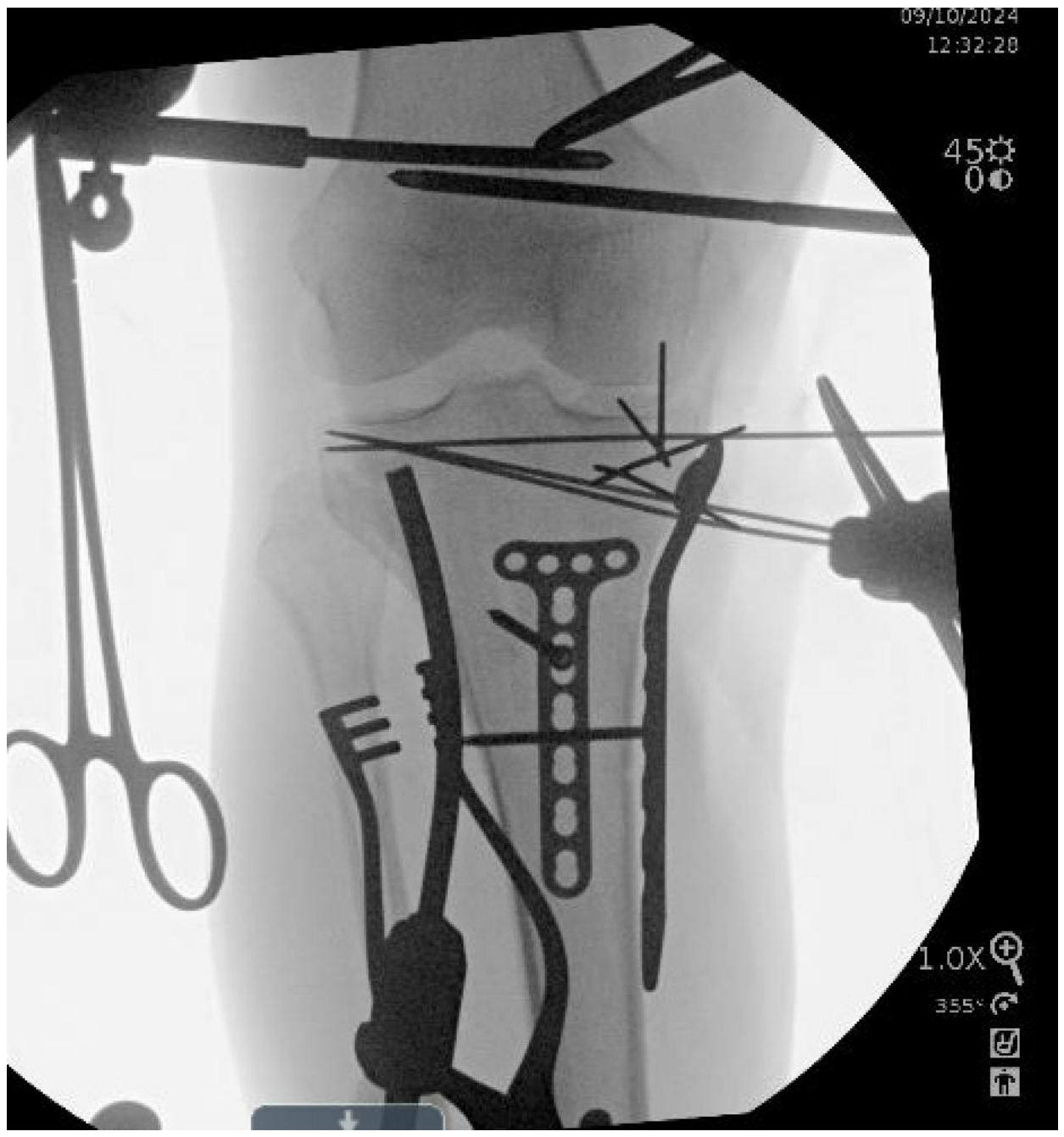
1.0X

355°



09/10/2024
12:32:20

45°
00



1.0X

355°



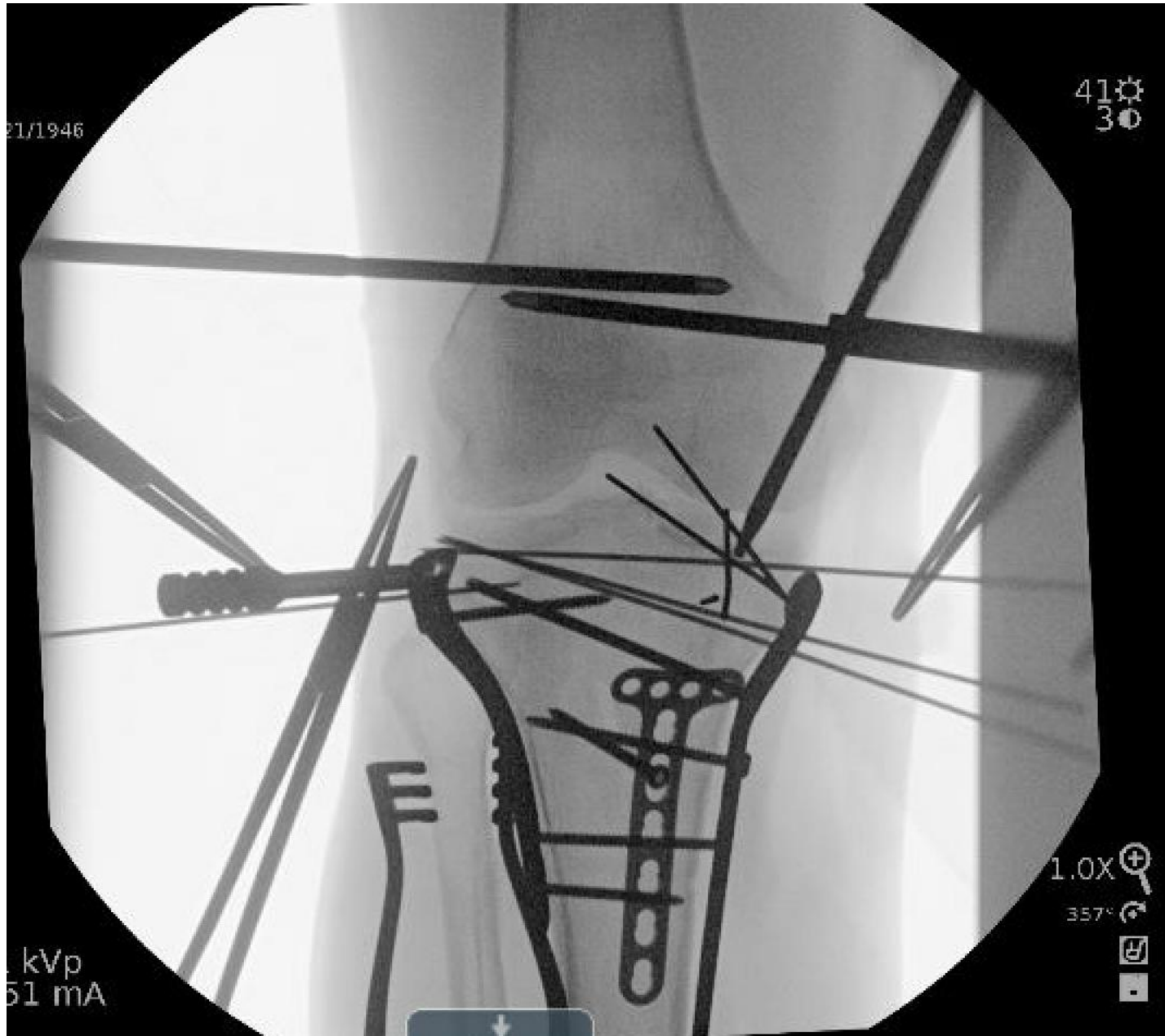
21/1946

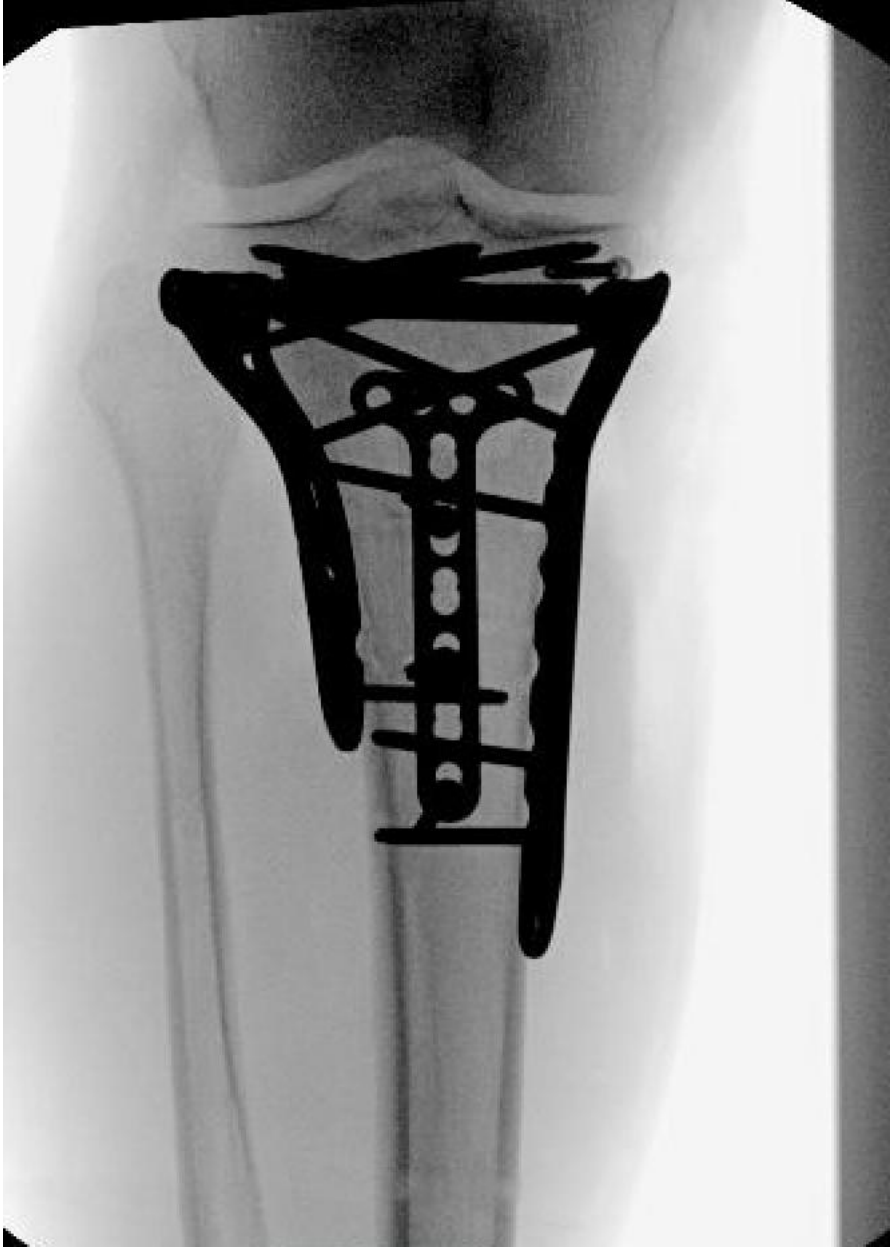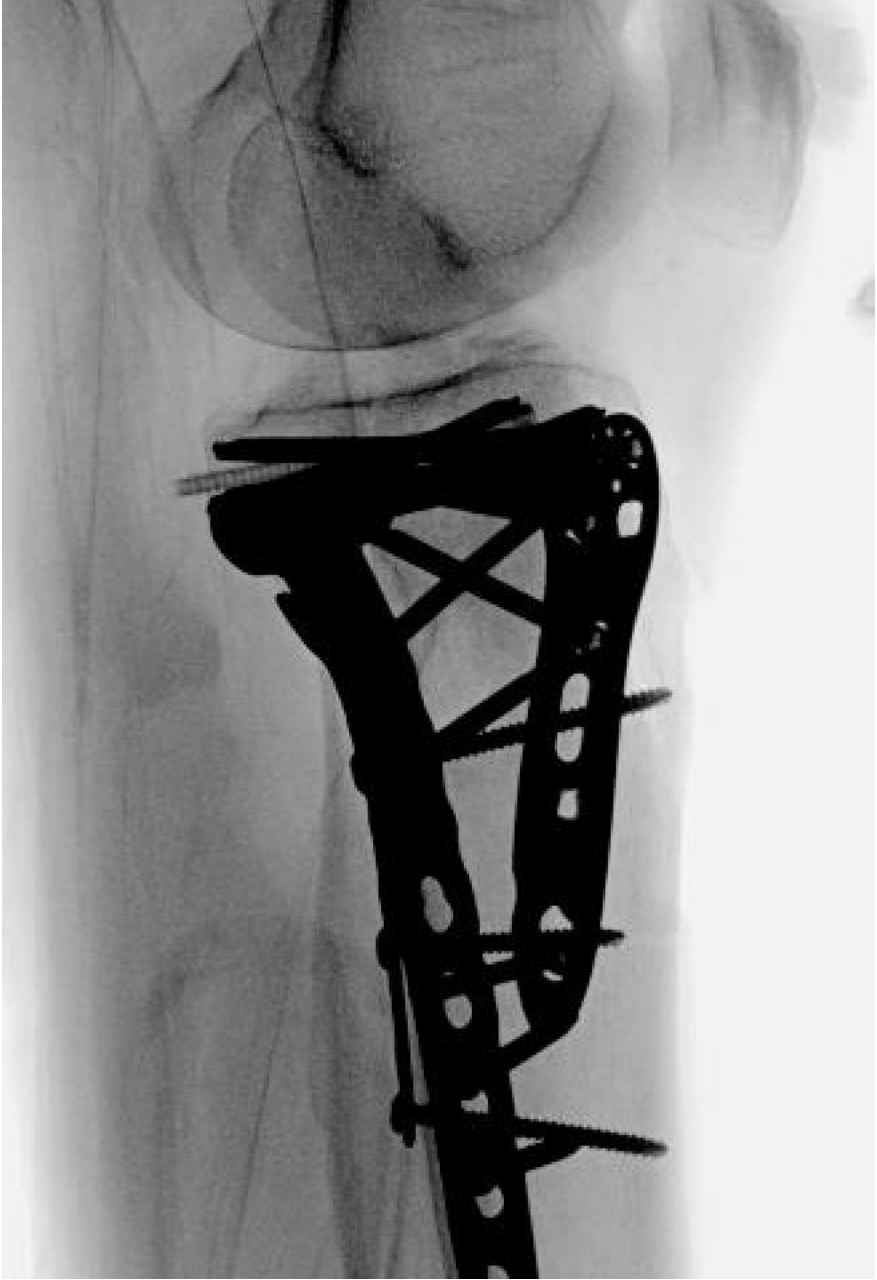41°
30°

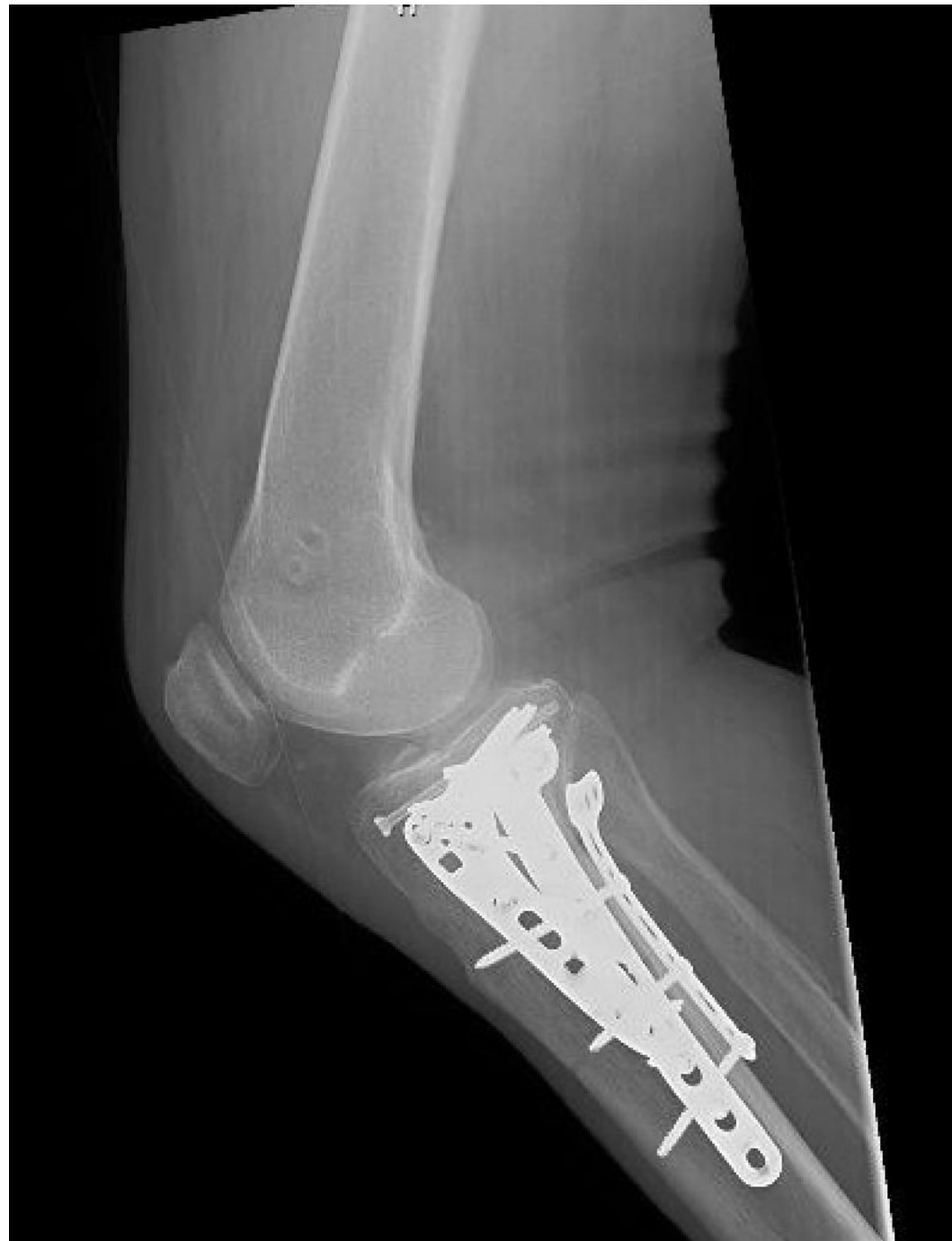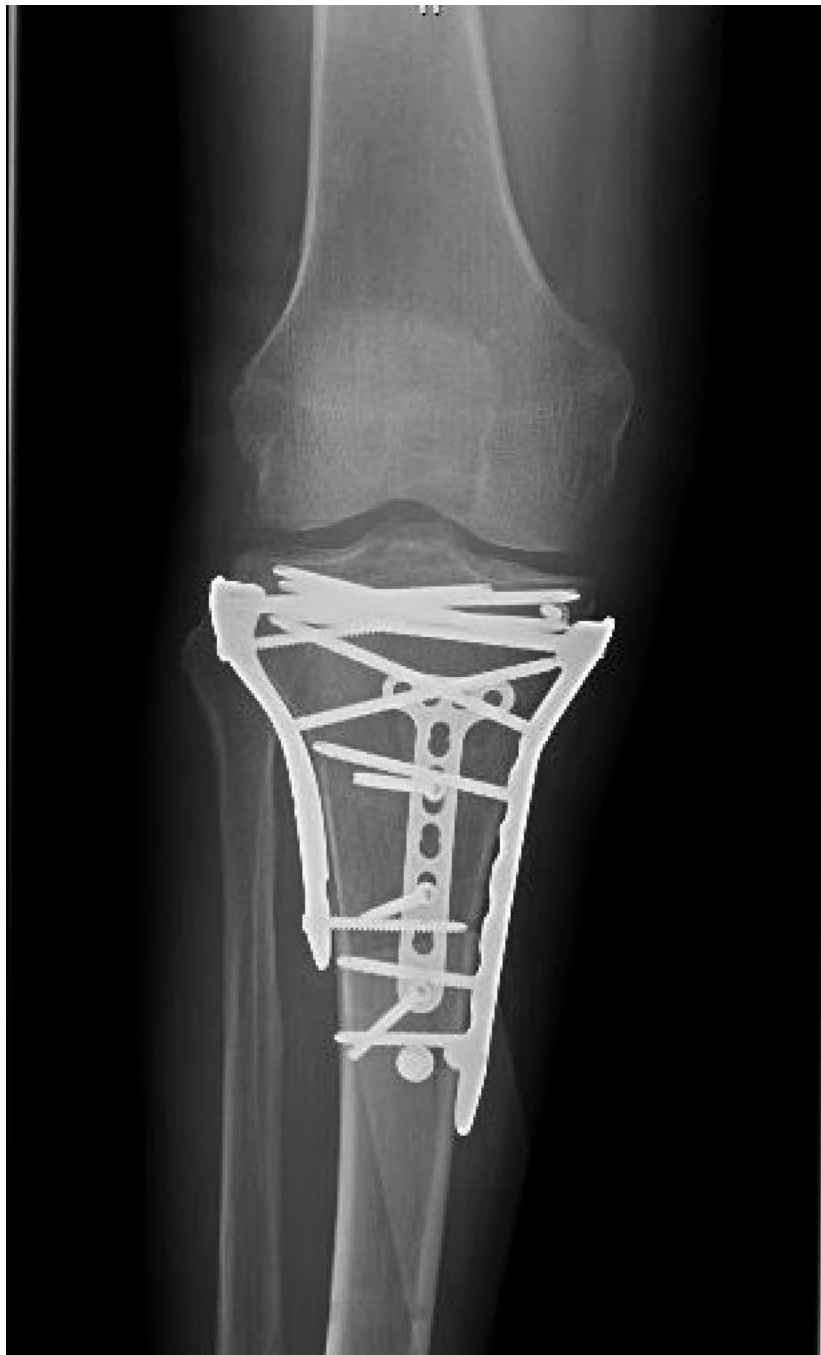kVp
51 mA

1.0X

357°





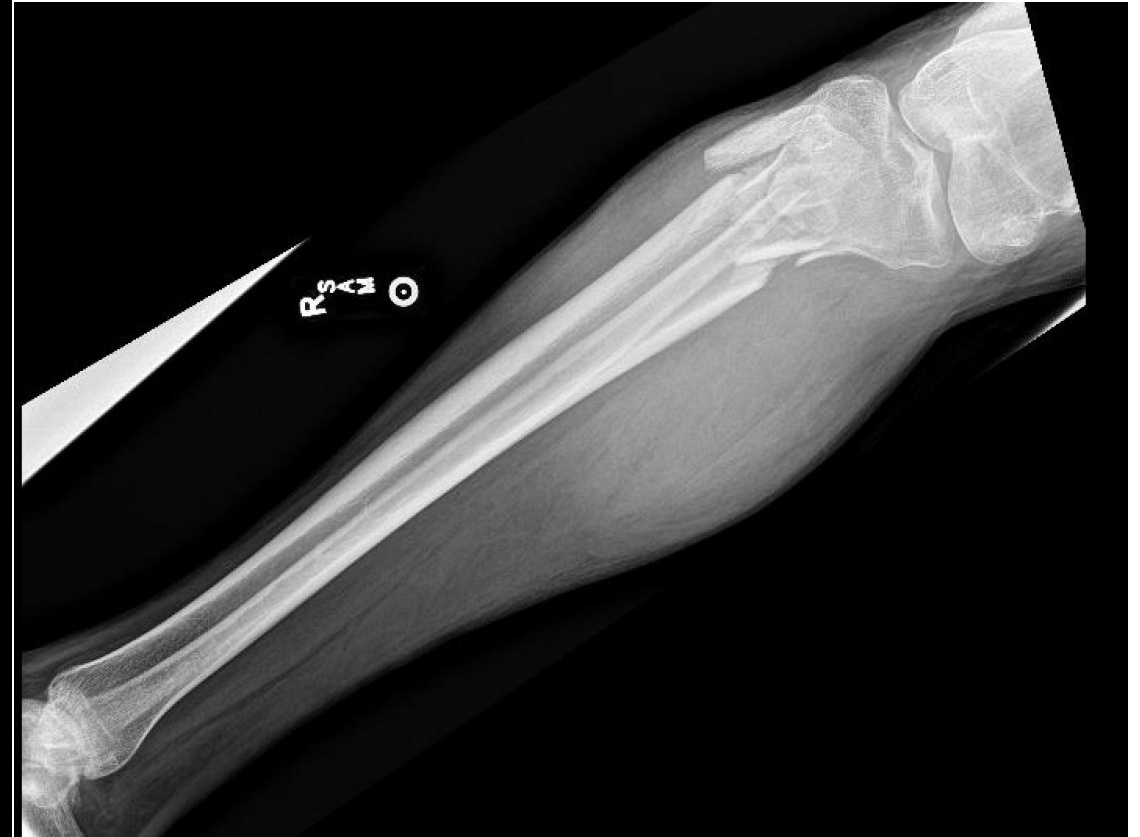
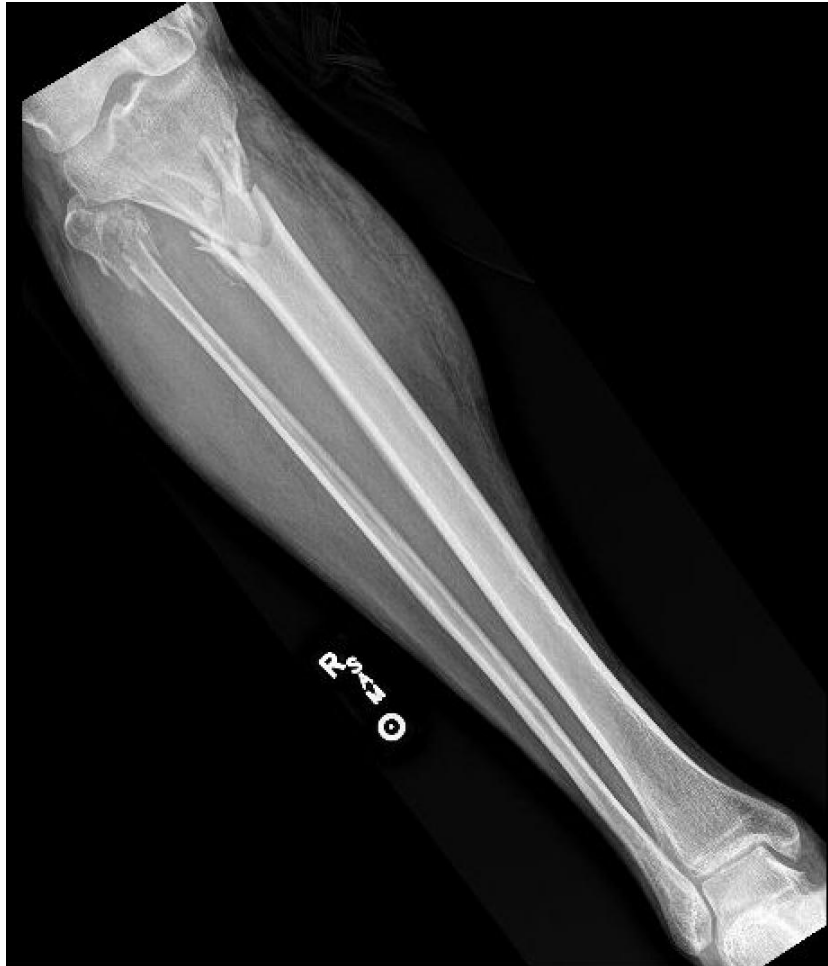
58M pedestrian struck by car

PMHx:

- ETOH abuse
- Unstable housing

Closed, NVI

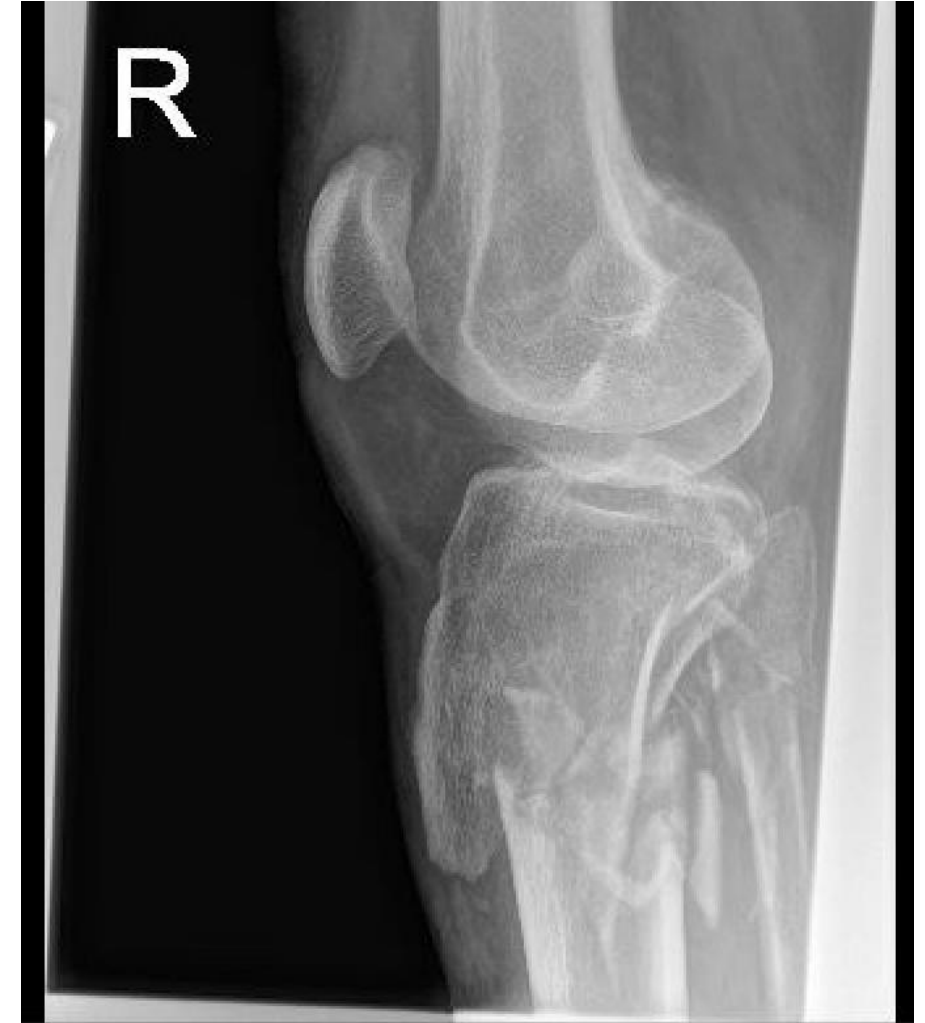
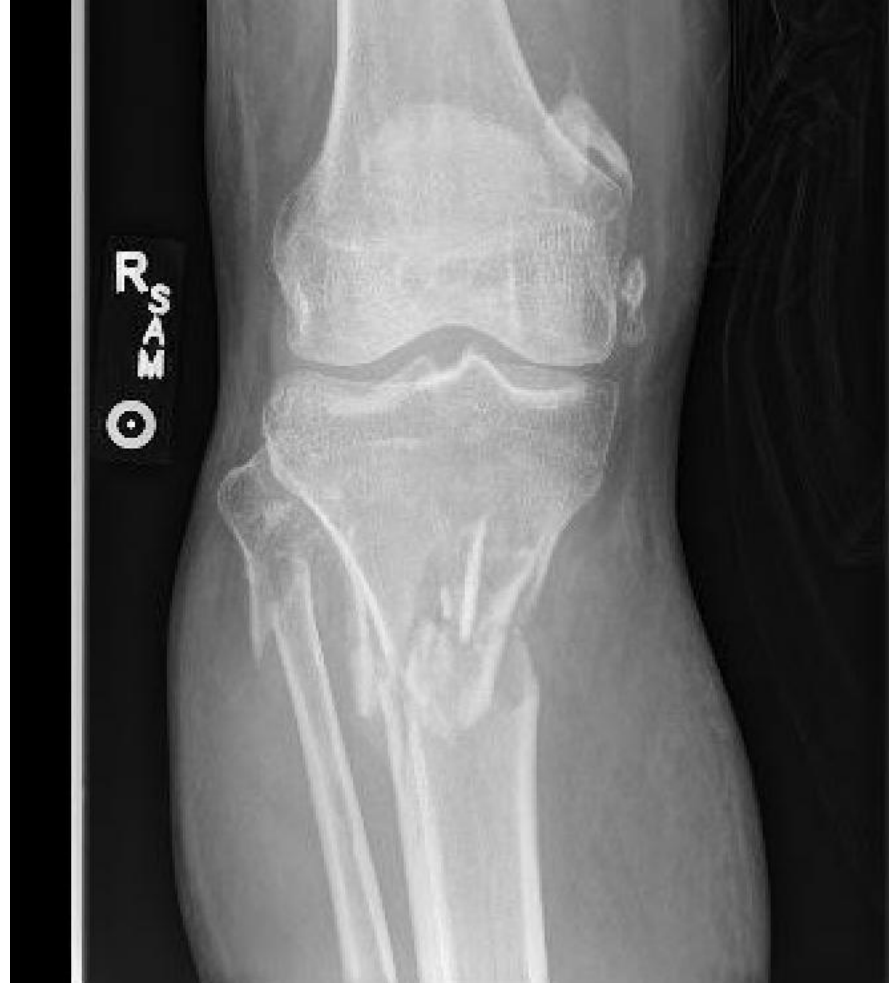
58M pedestrian struck by car

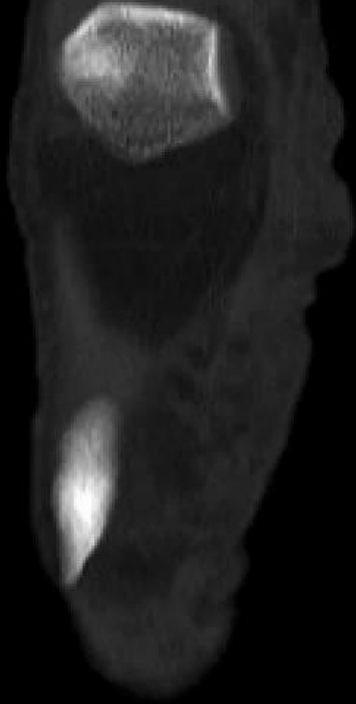
PMHx:

- ETOH abuse
- Unstable housing

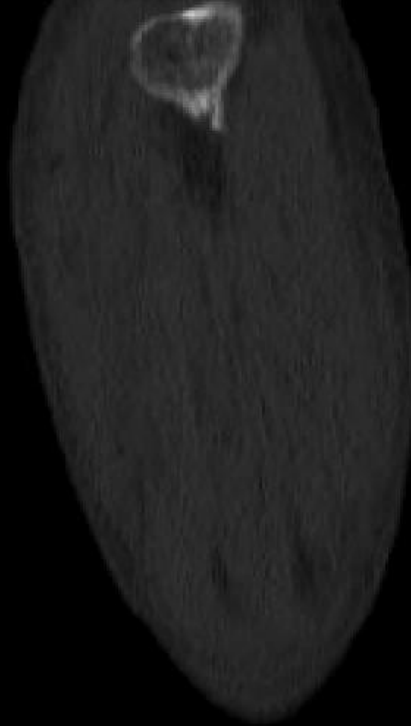
Closed, NVI



H

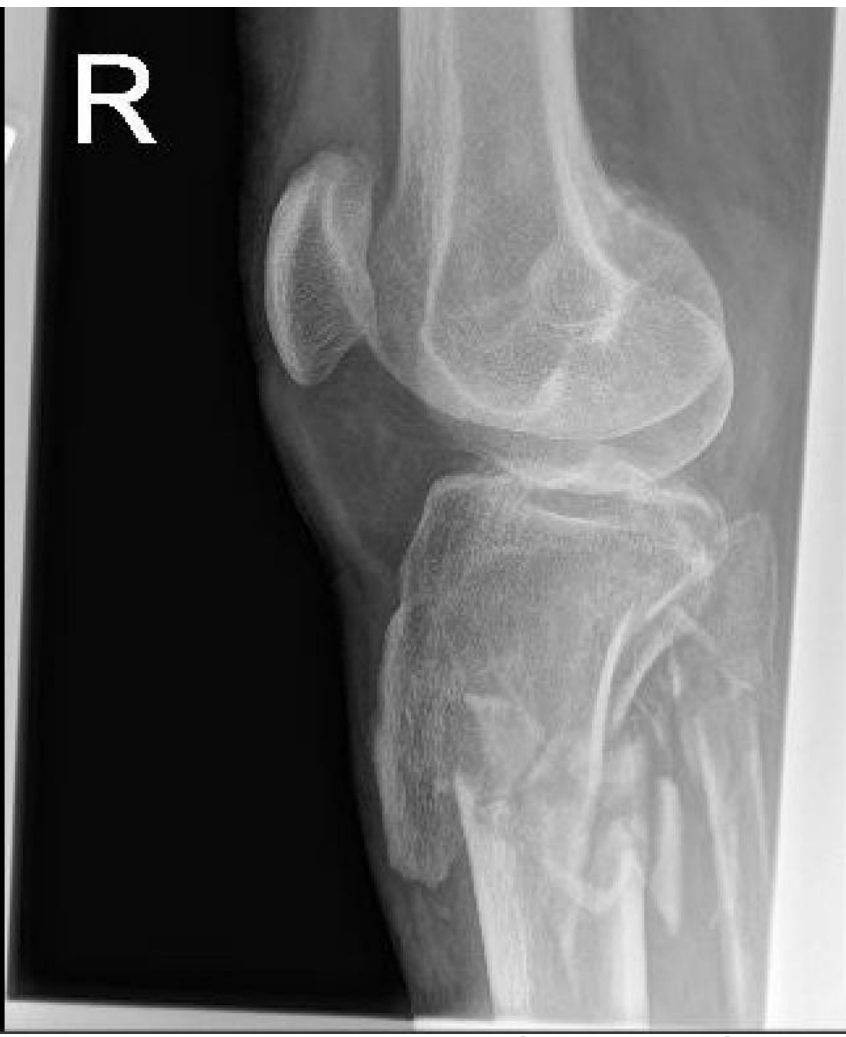
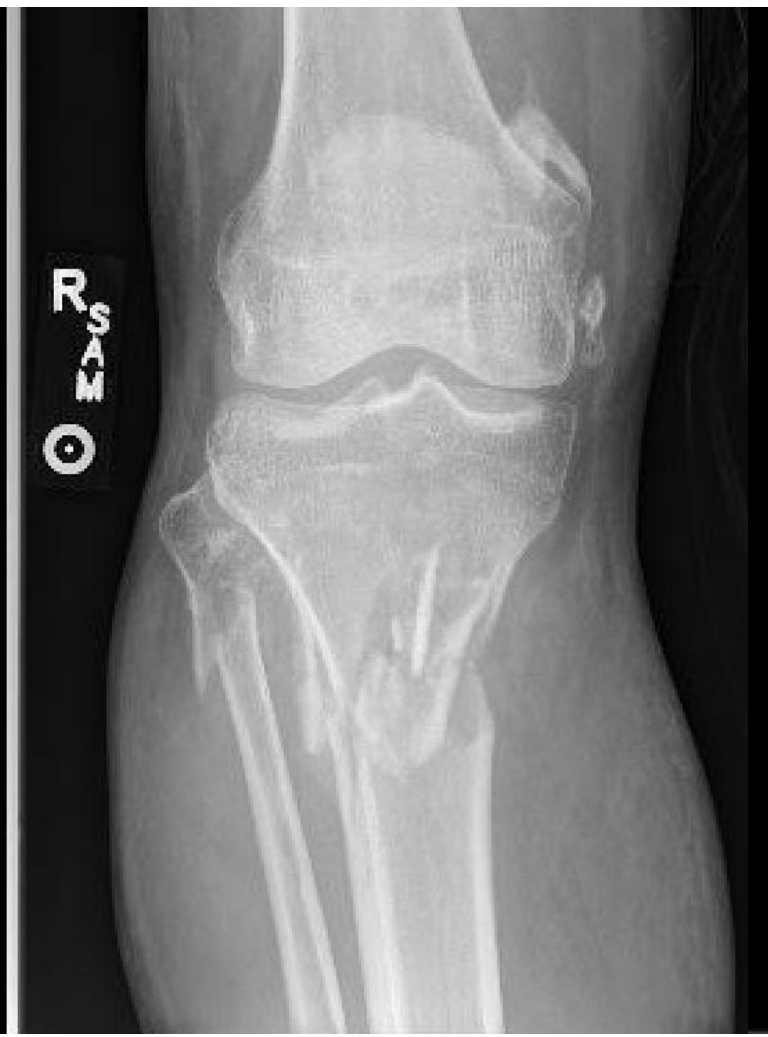
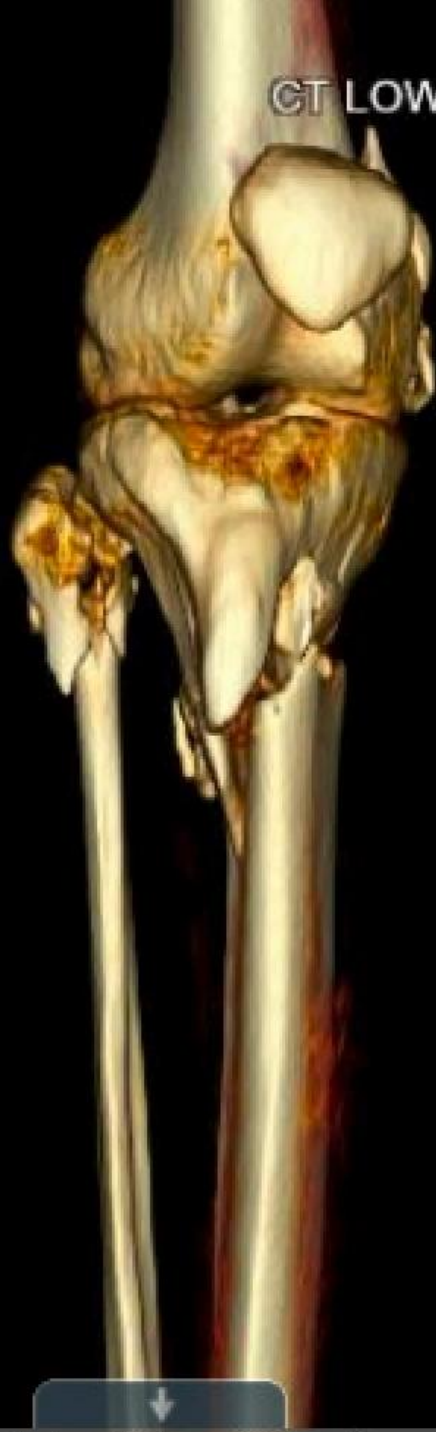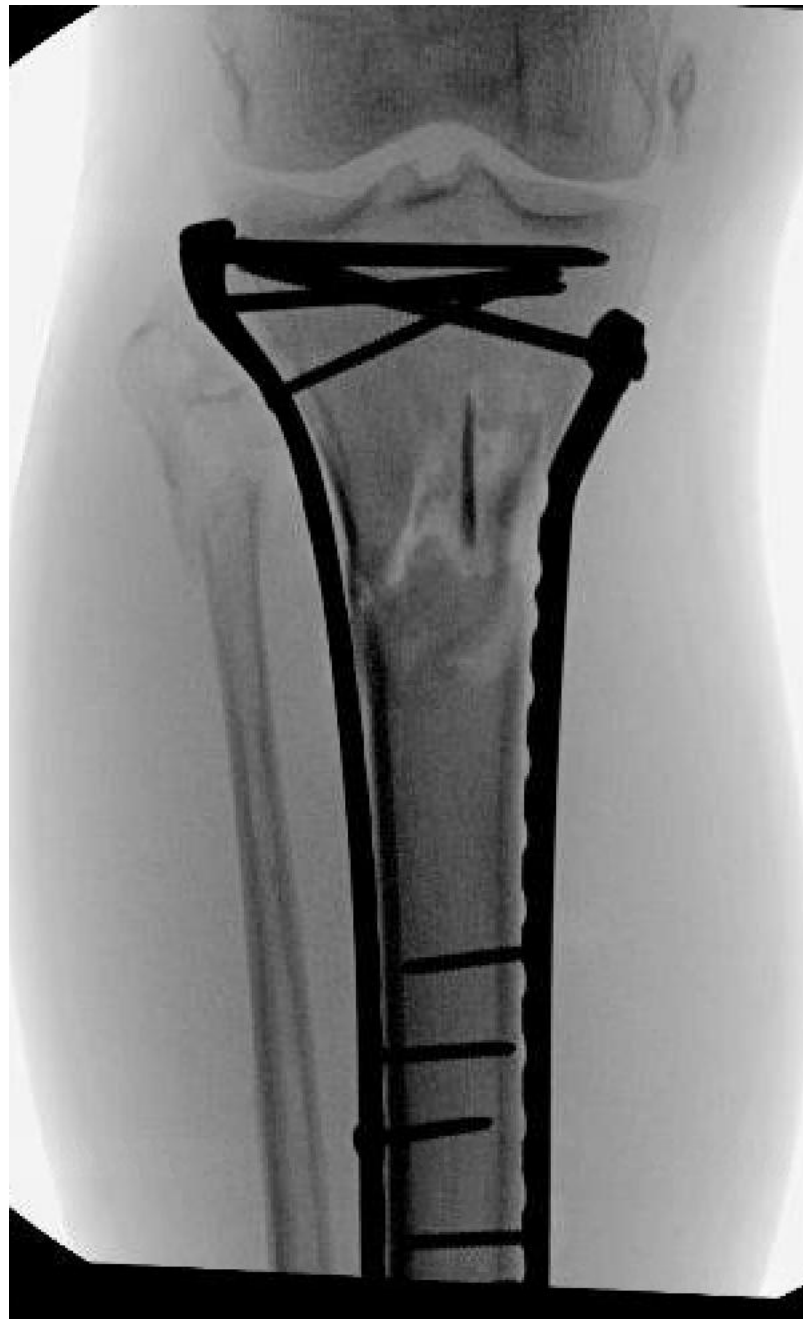H

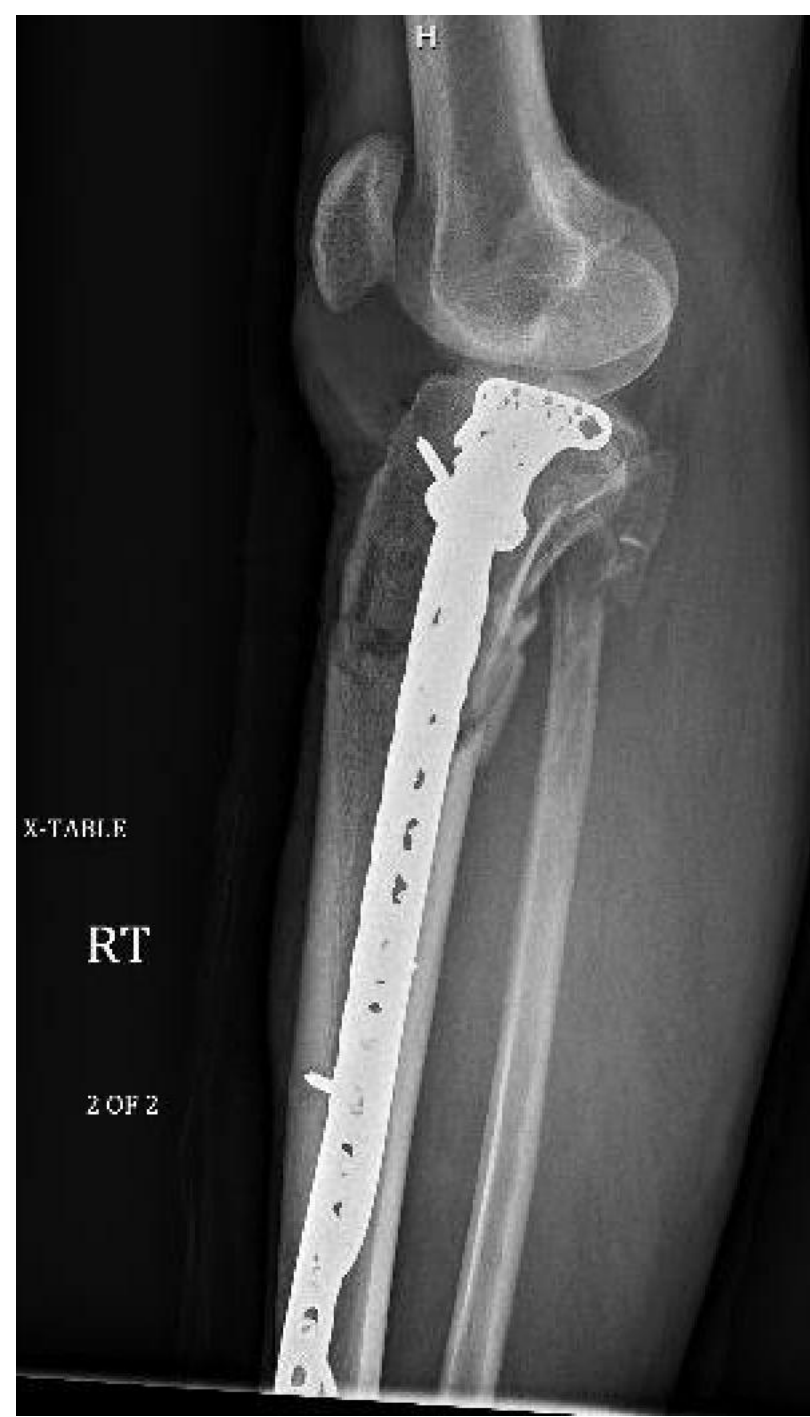
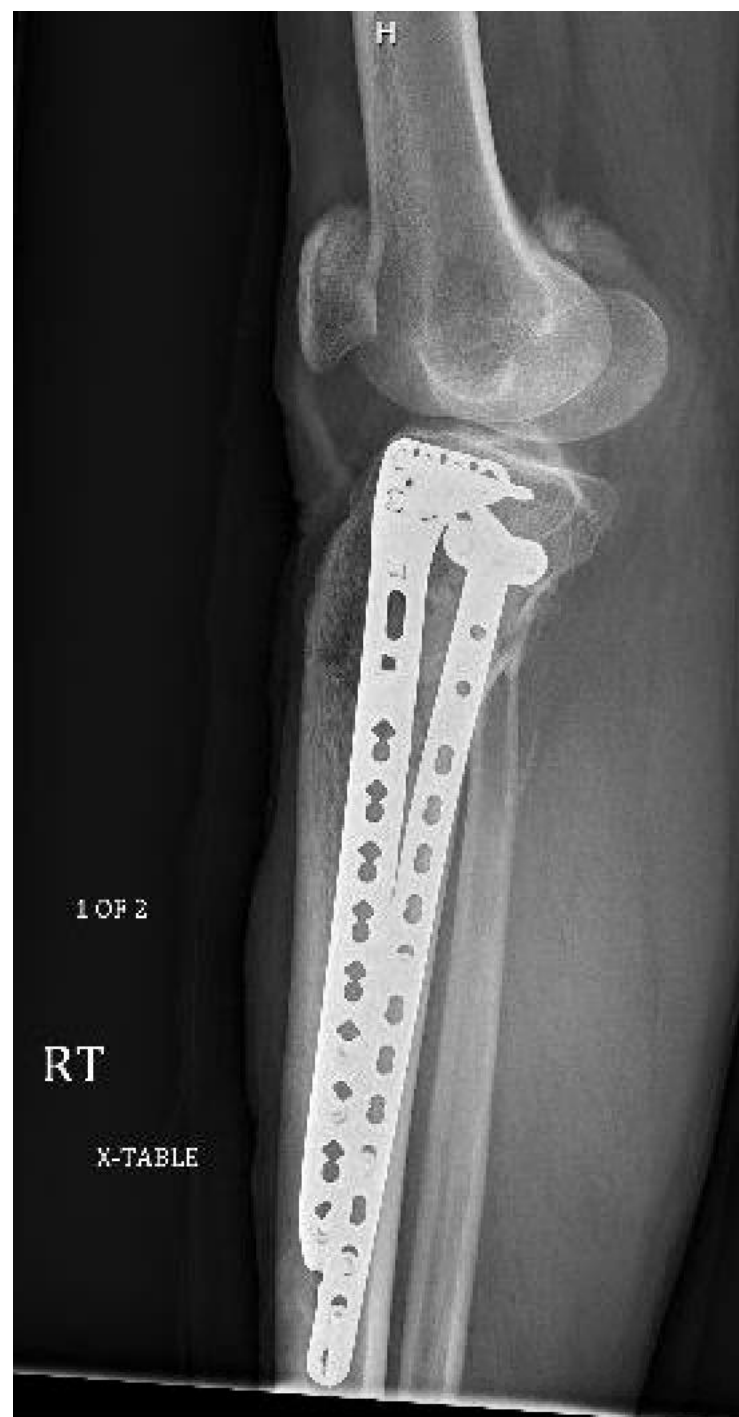
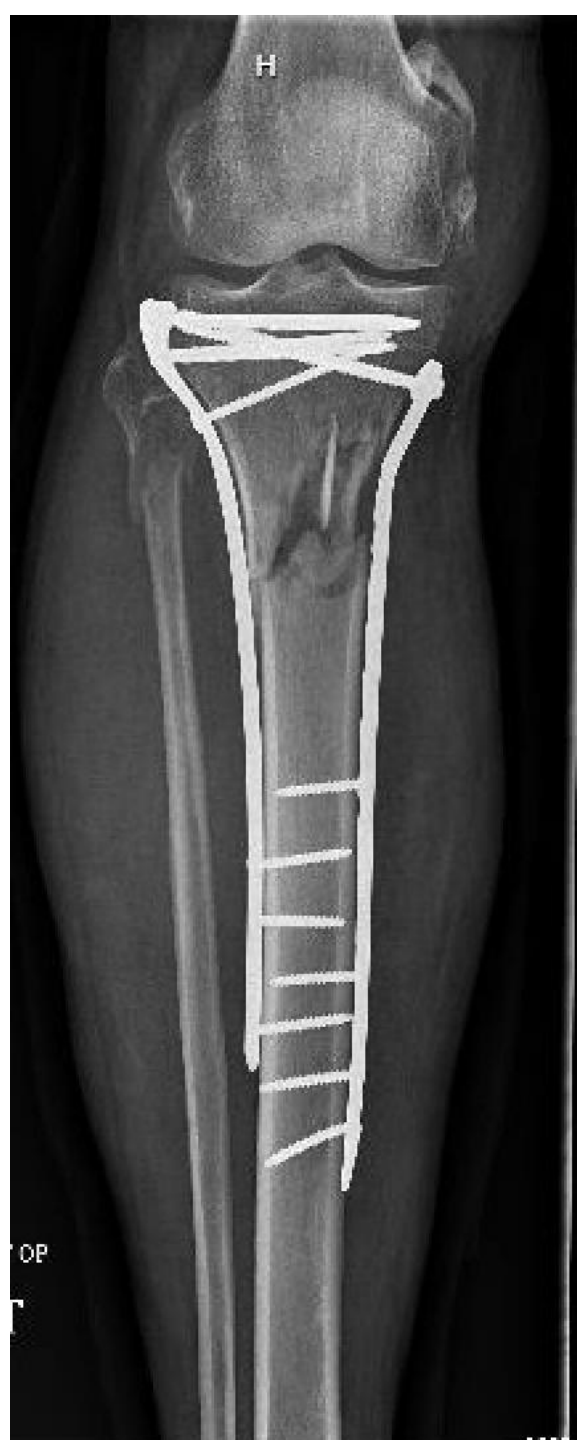CT LOWER EXTRE

Management plan?







Thank you!

