


Elbow Cases

Utku KANDEMIR, MD

Professor

Dept of Orthopaedic Surgery

University of California, San Francisco

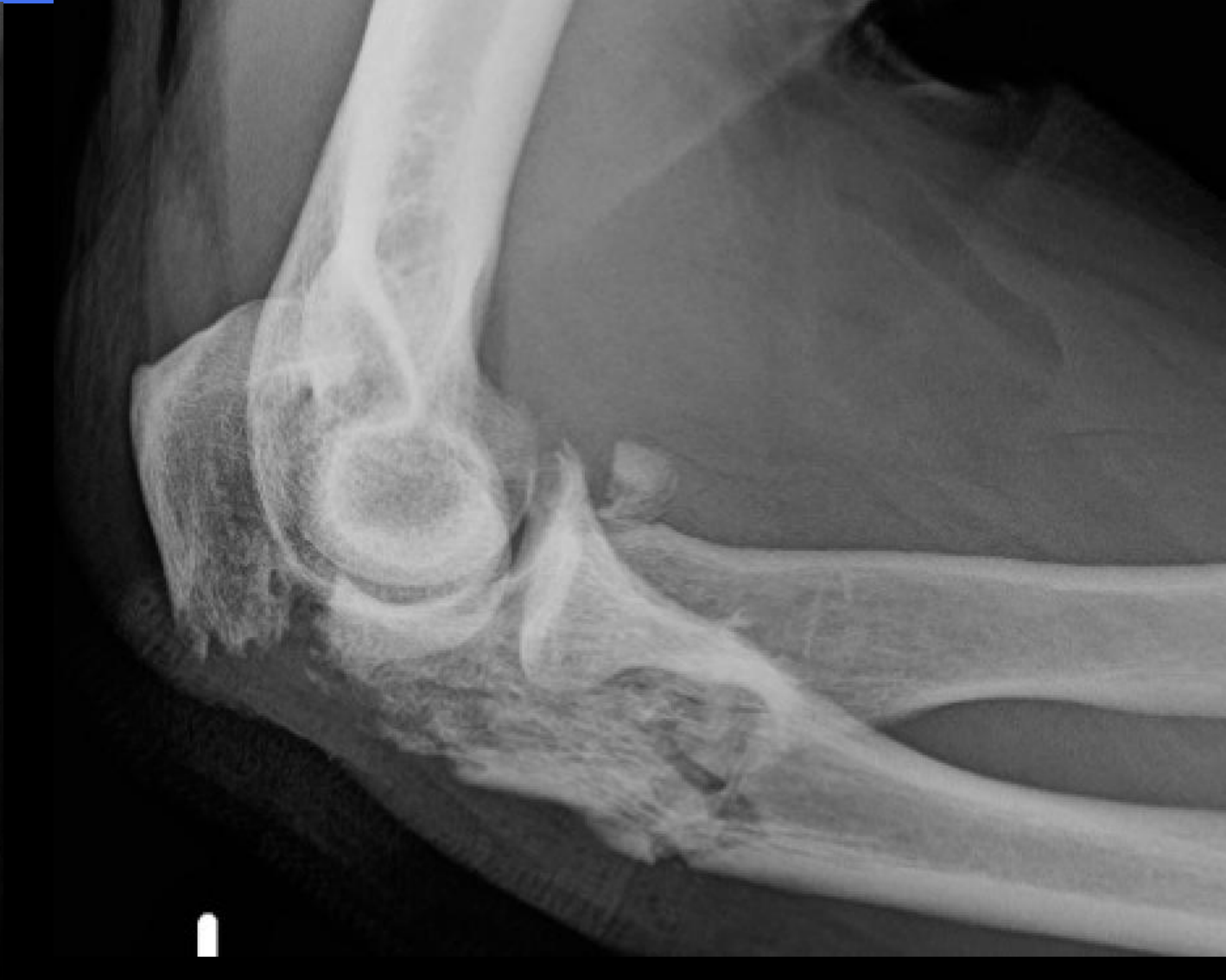
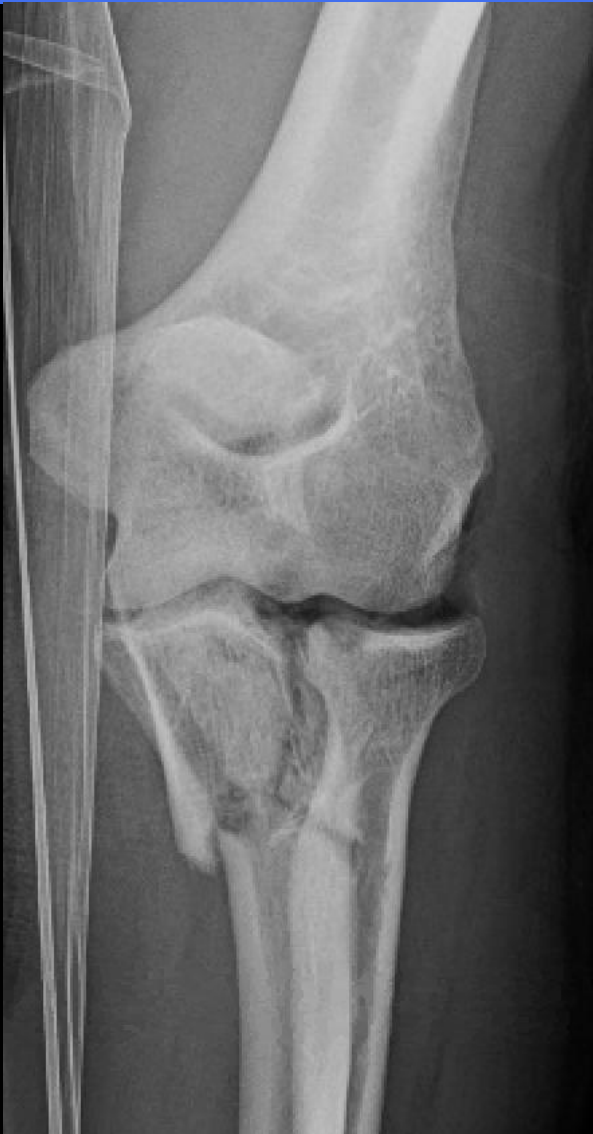
Case

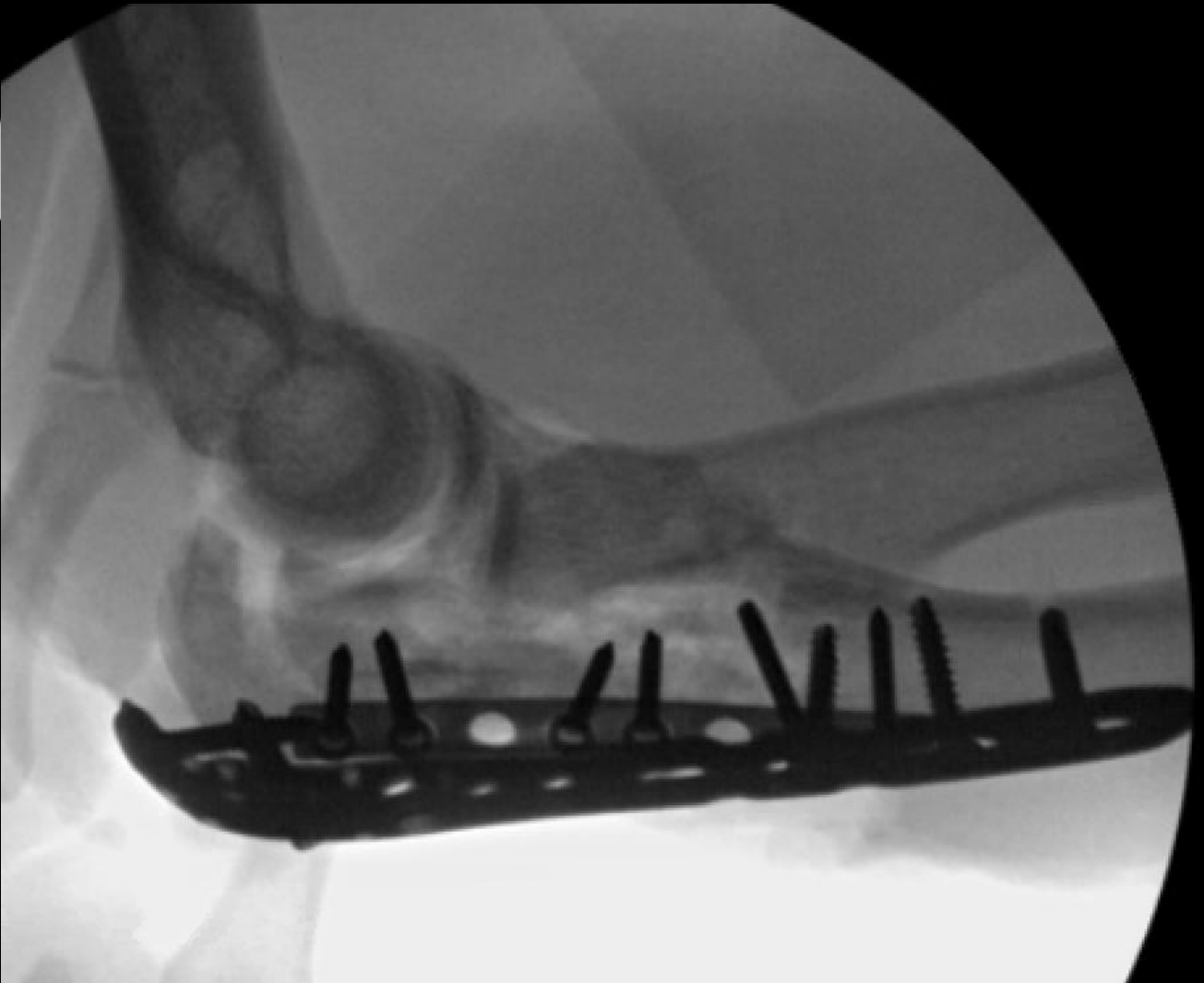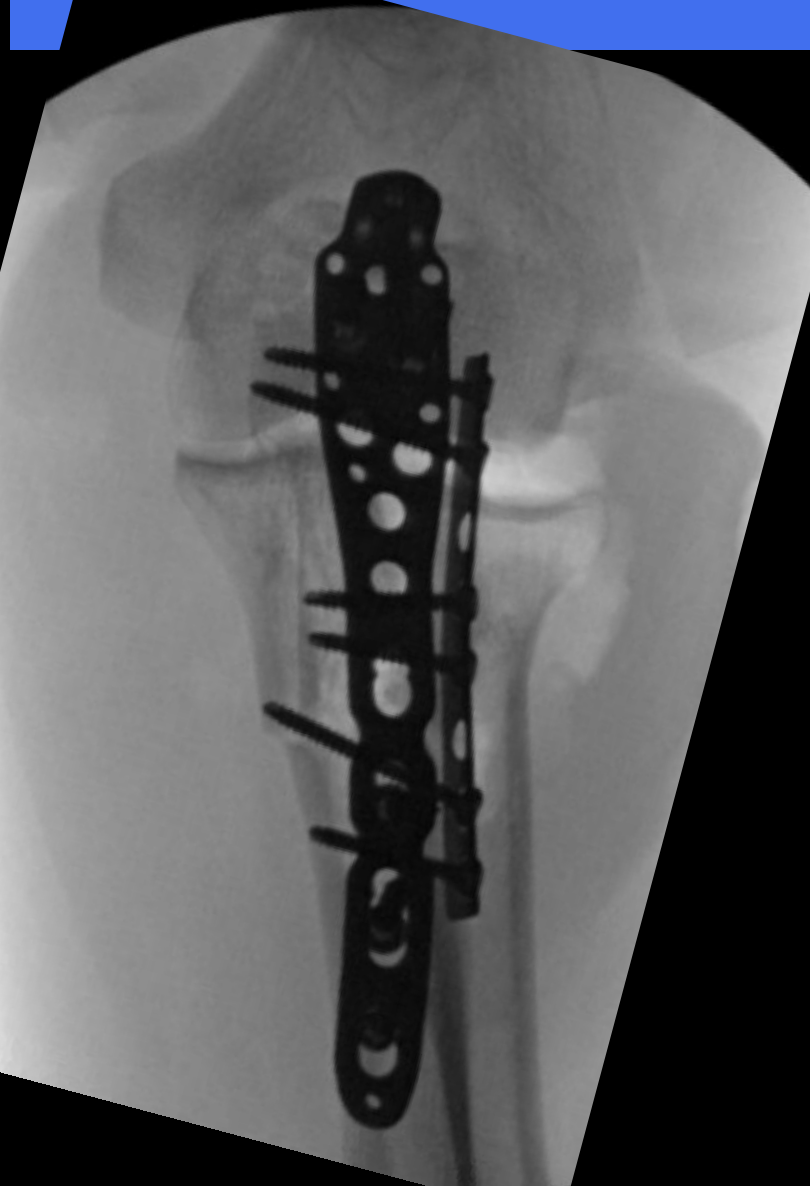
61 yo

- s/p fall of 4 feet ladder at work
- Open elbow injury
- Had I&D and ORIF
- Referred for persistent pain and stiffness
- Elbow ROM 40-85,
- Forearm: Supination:20, Pronation:50

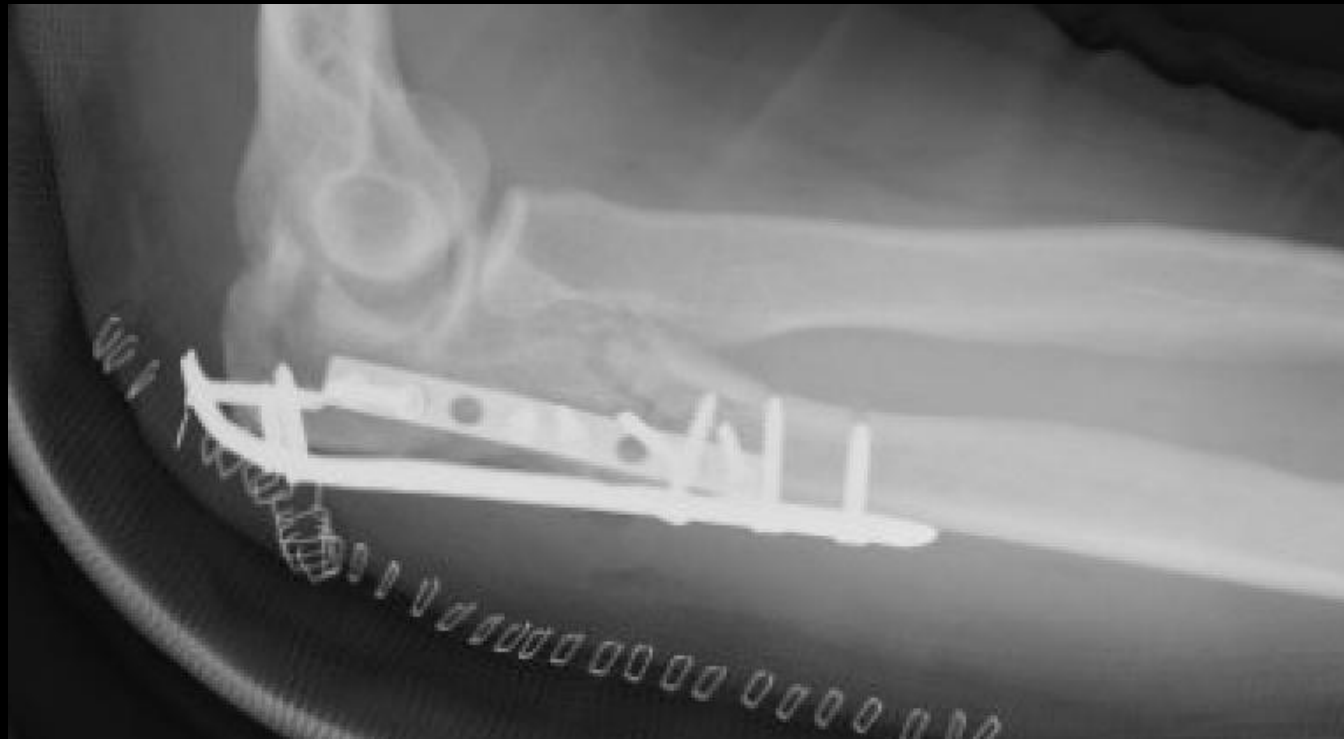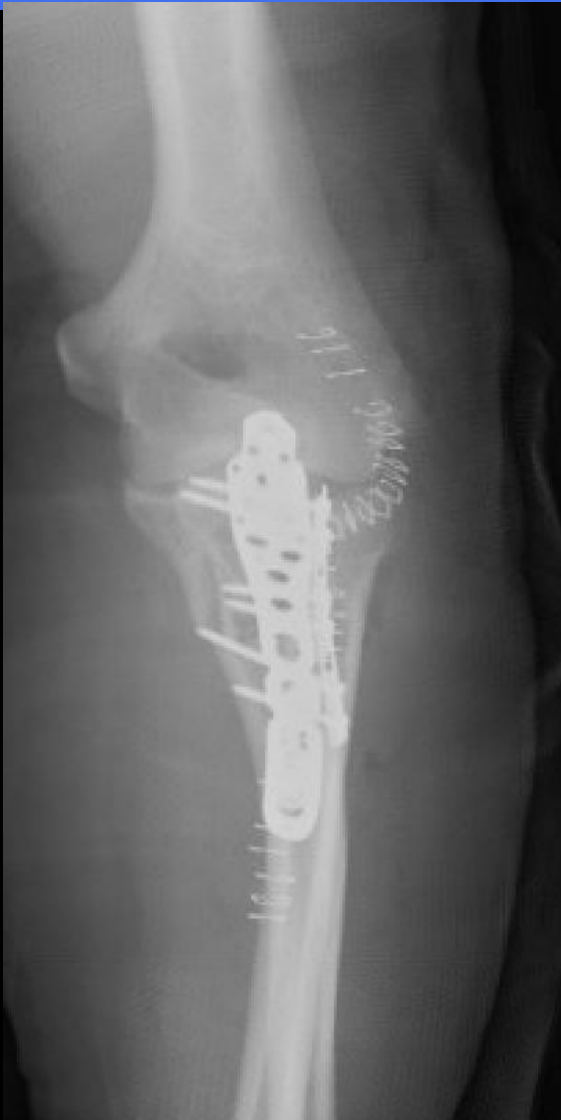61 yo



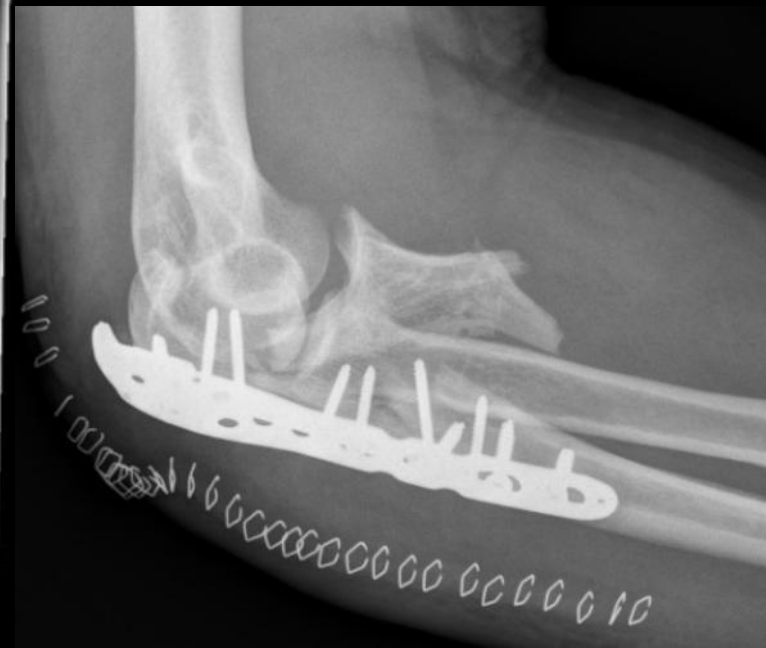
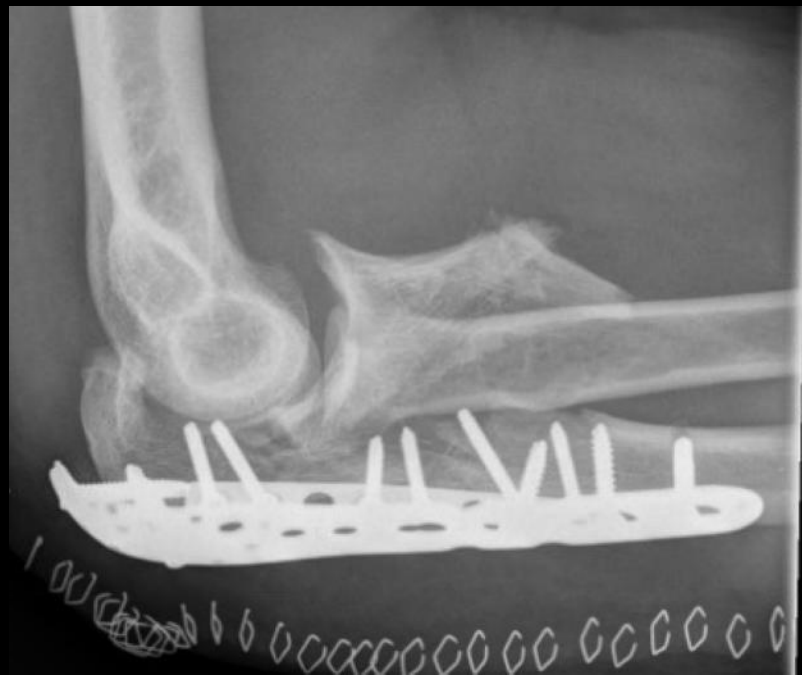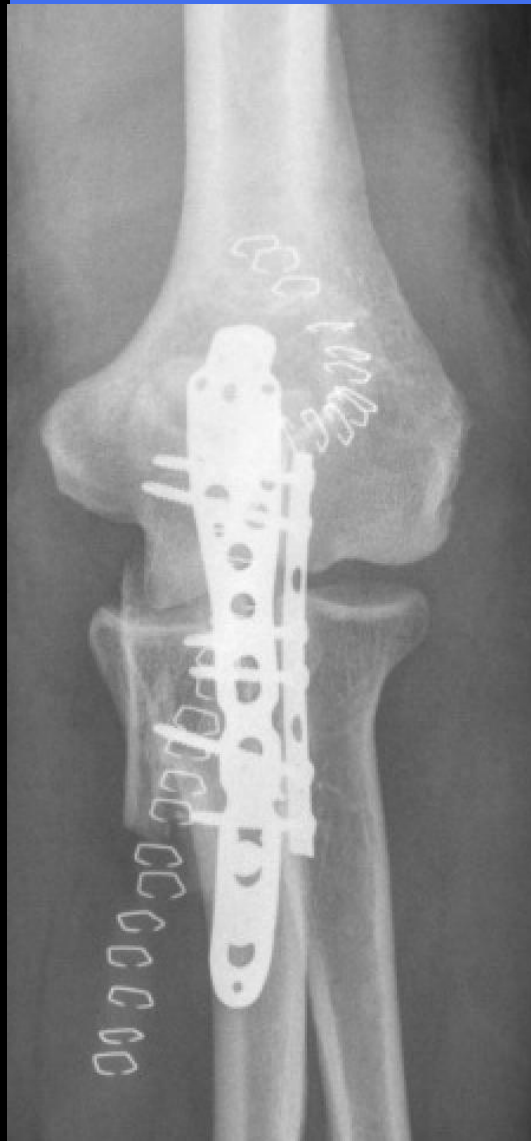
61 yo



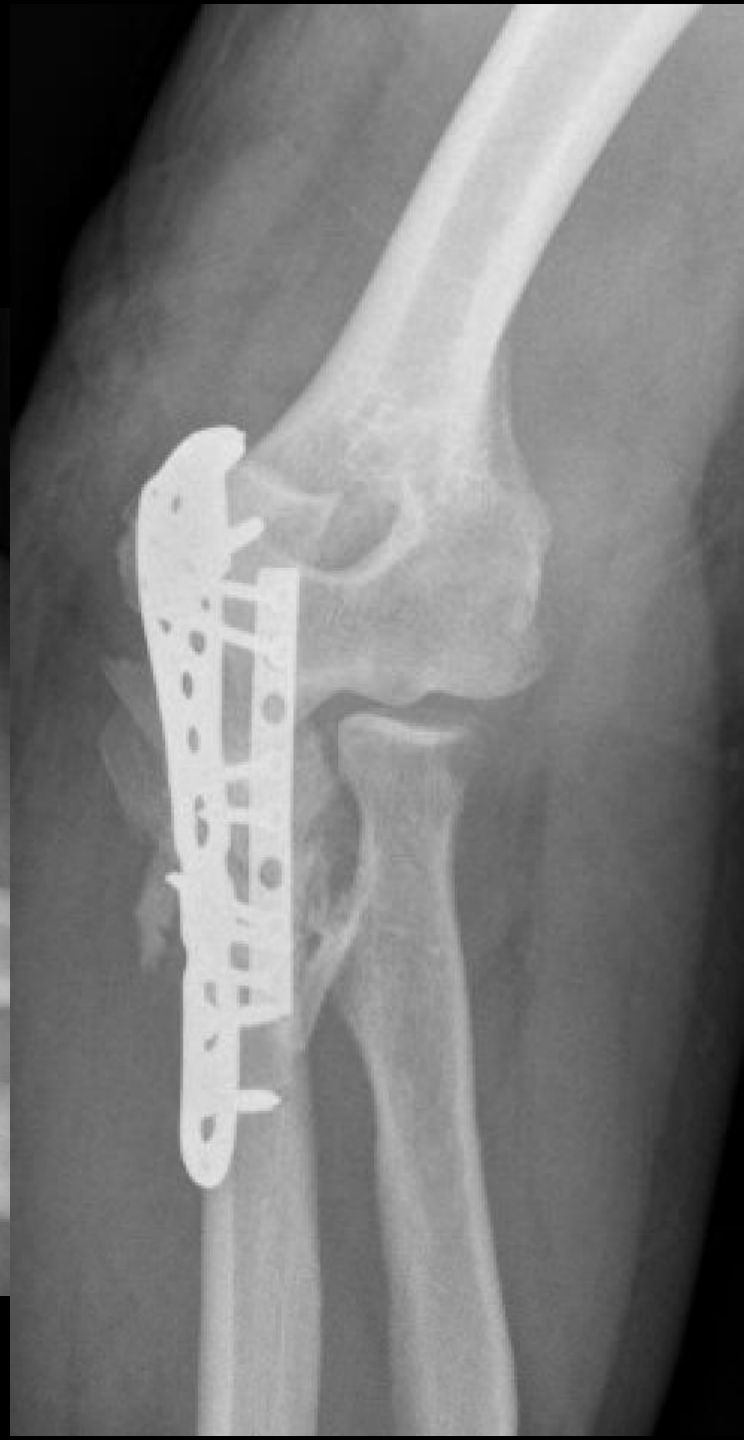
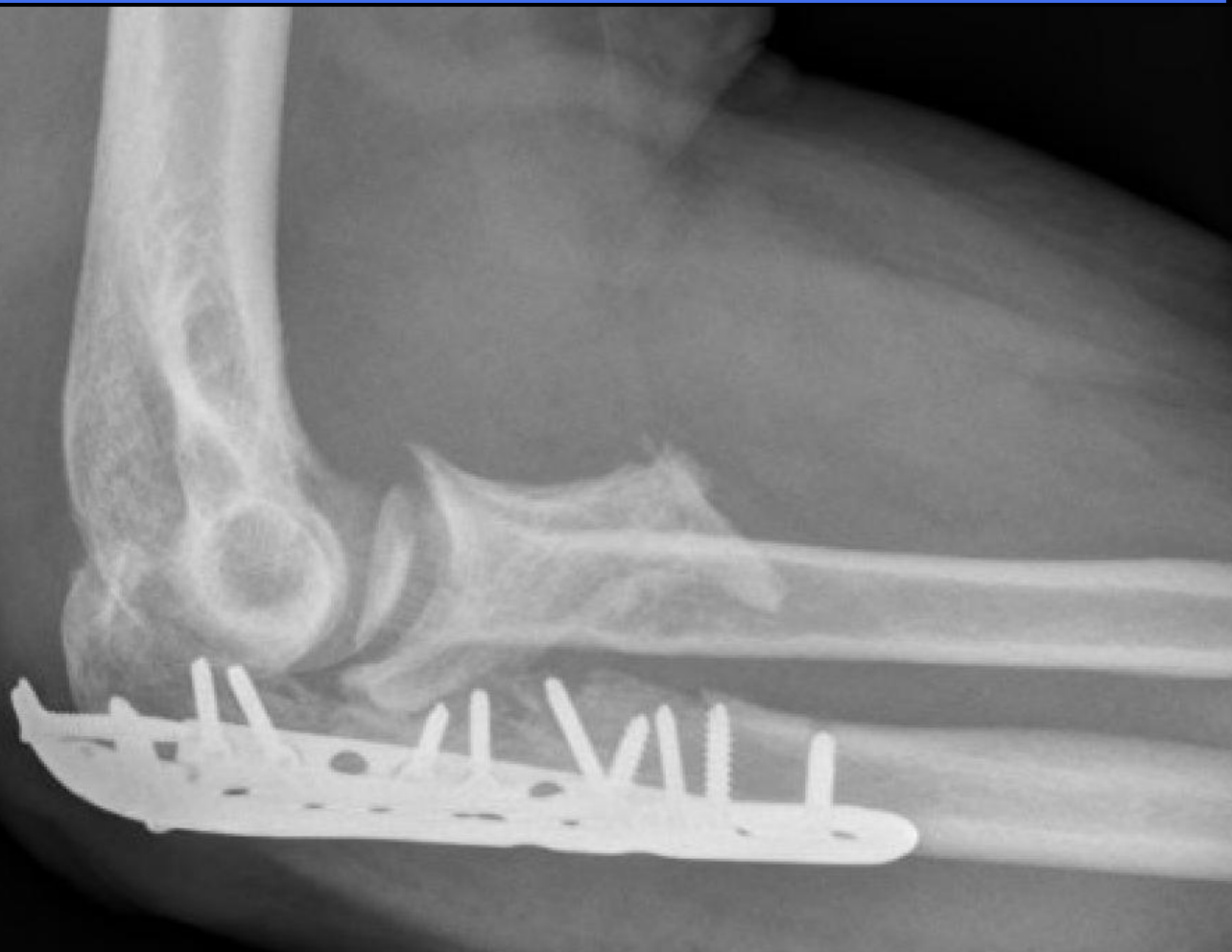61 yo, 1 week postop



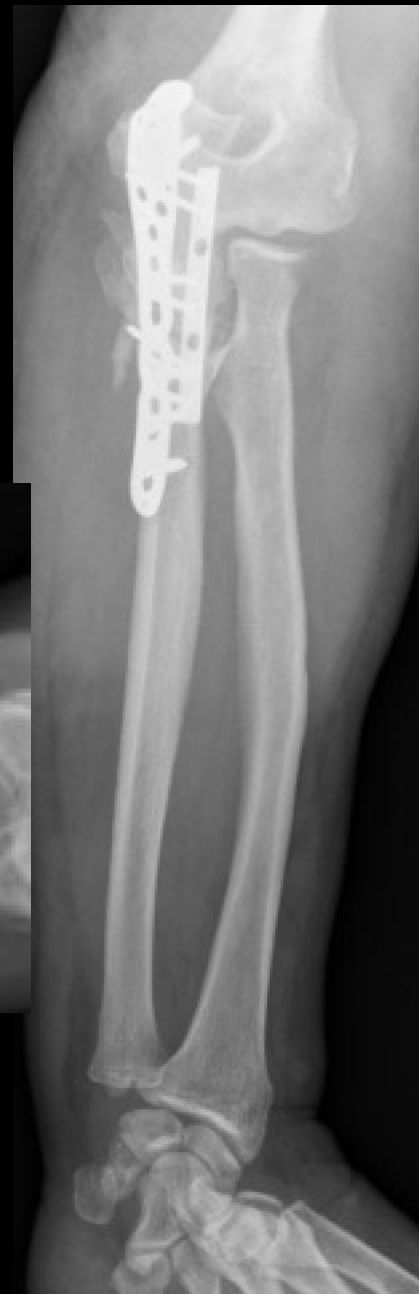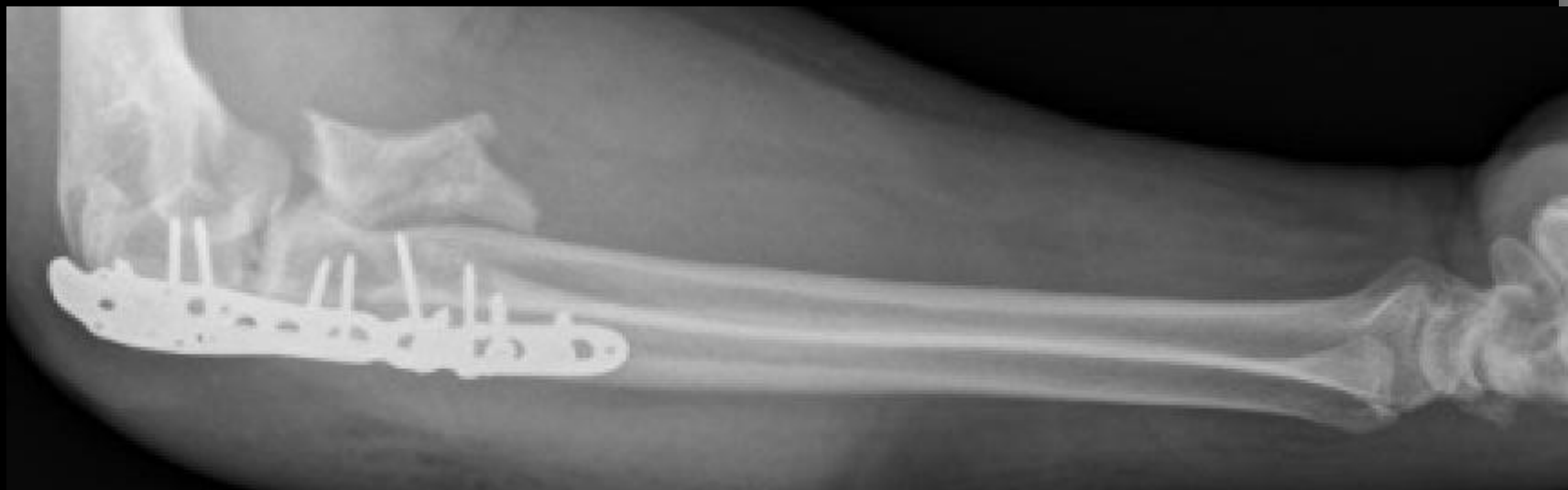61 yo, 4 weeks postop



61 yo, 6 weeks postop

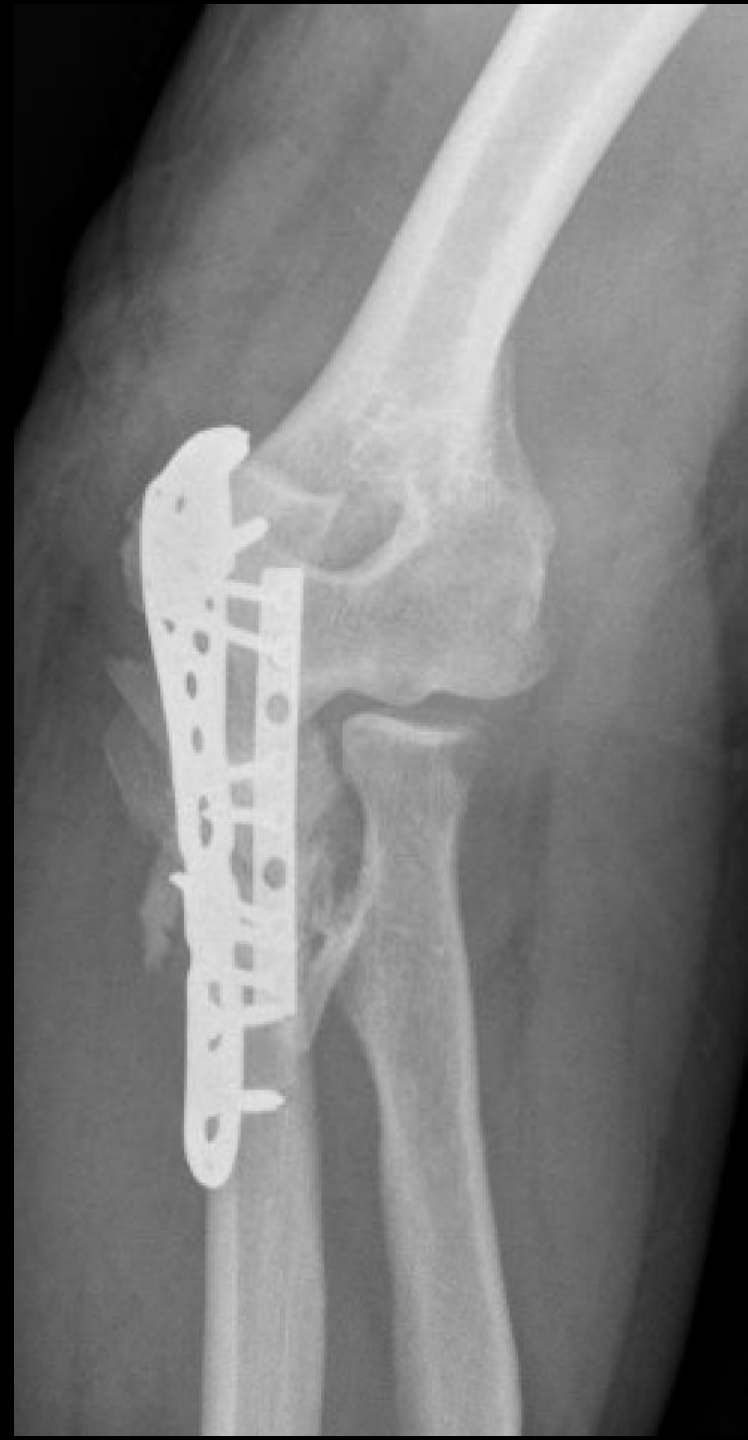
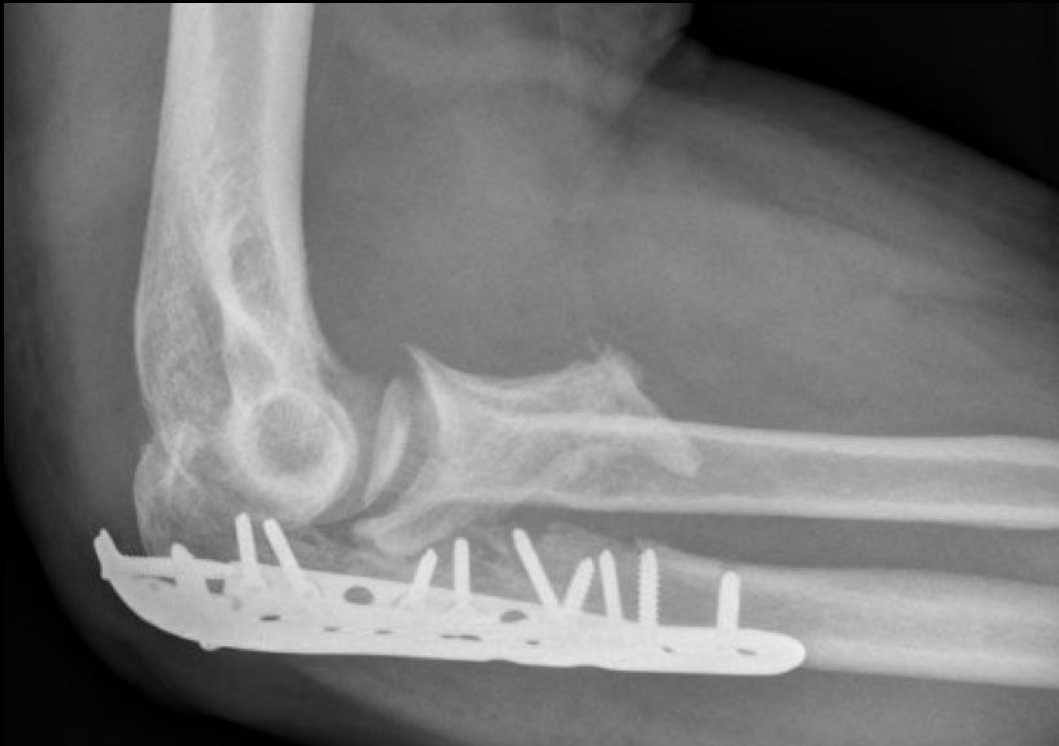


61 yo, 6 weeks postop

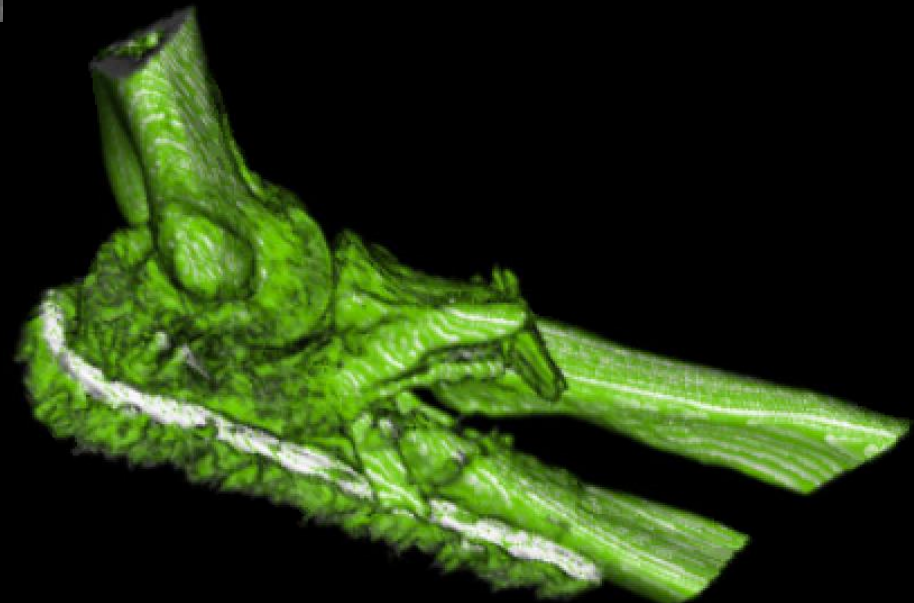
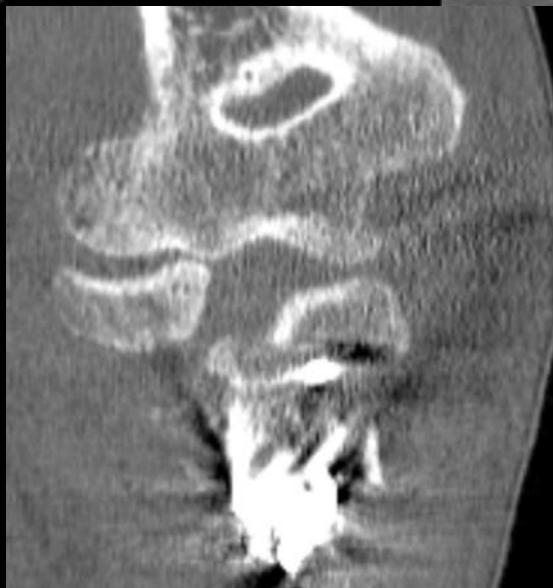
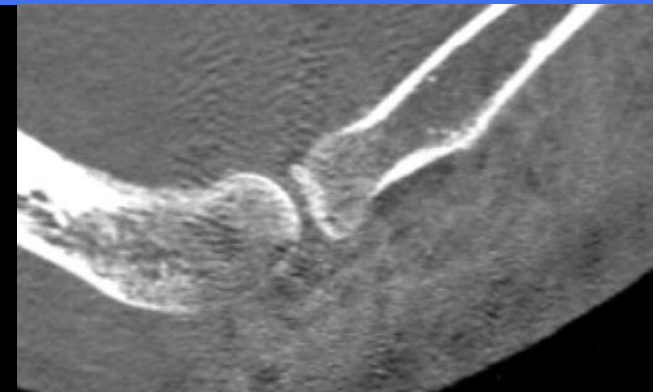
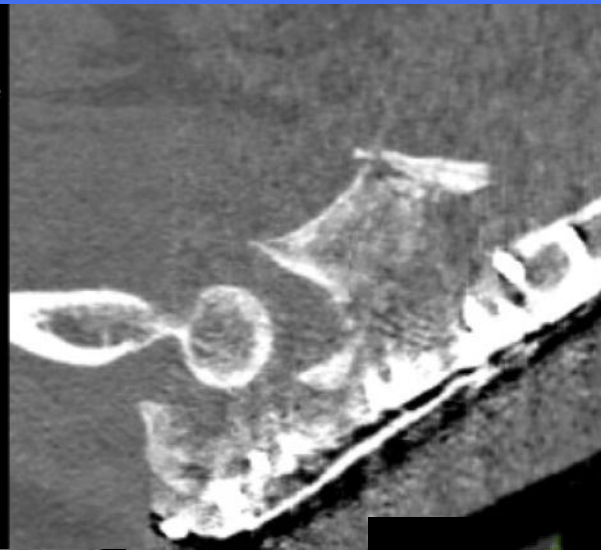
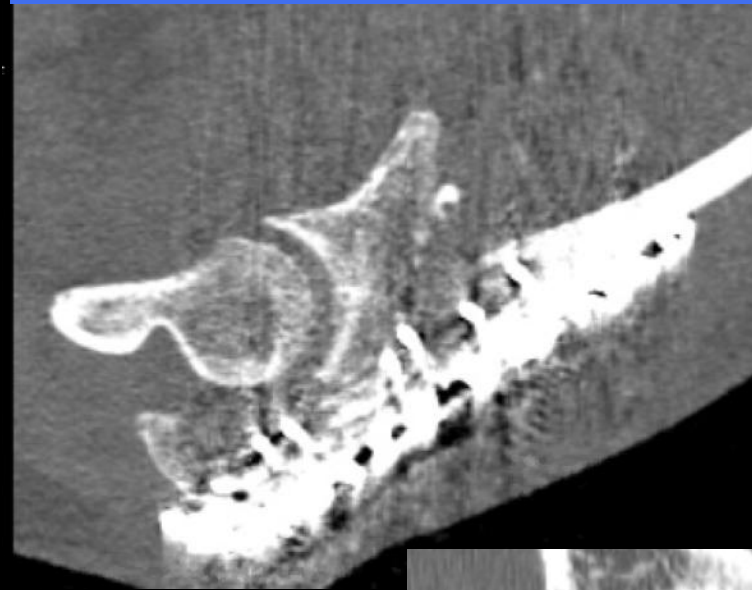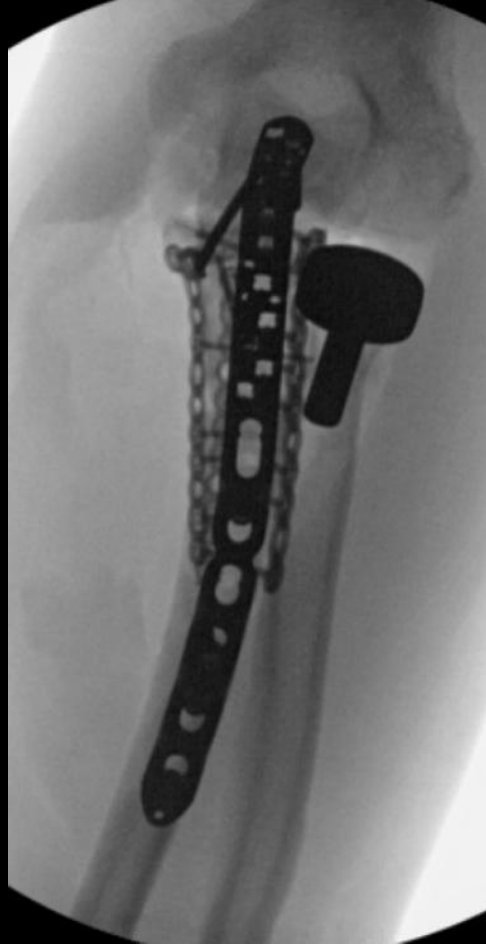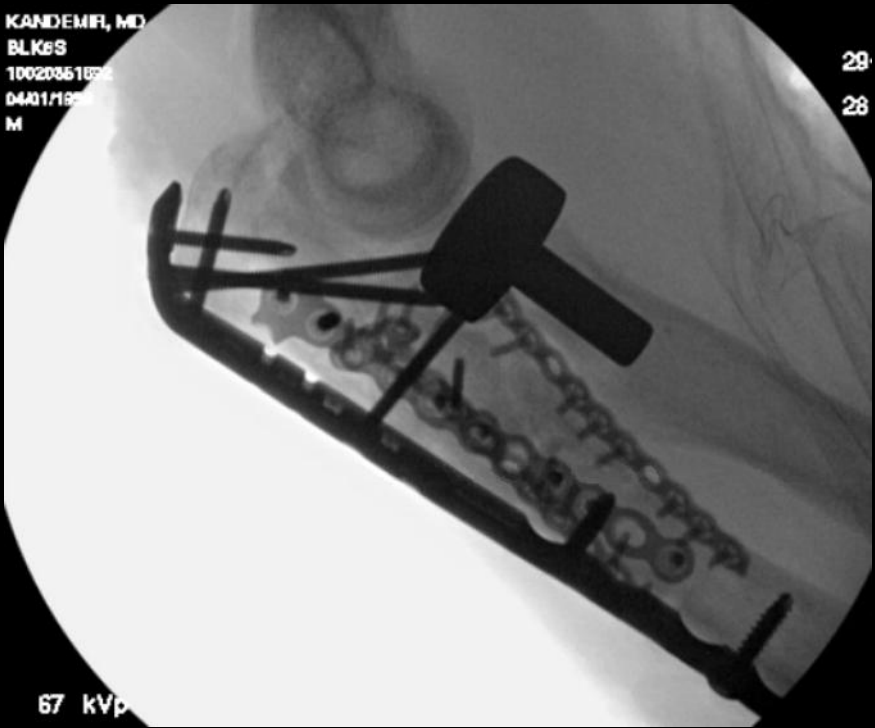
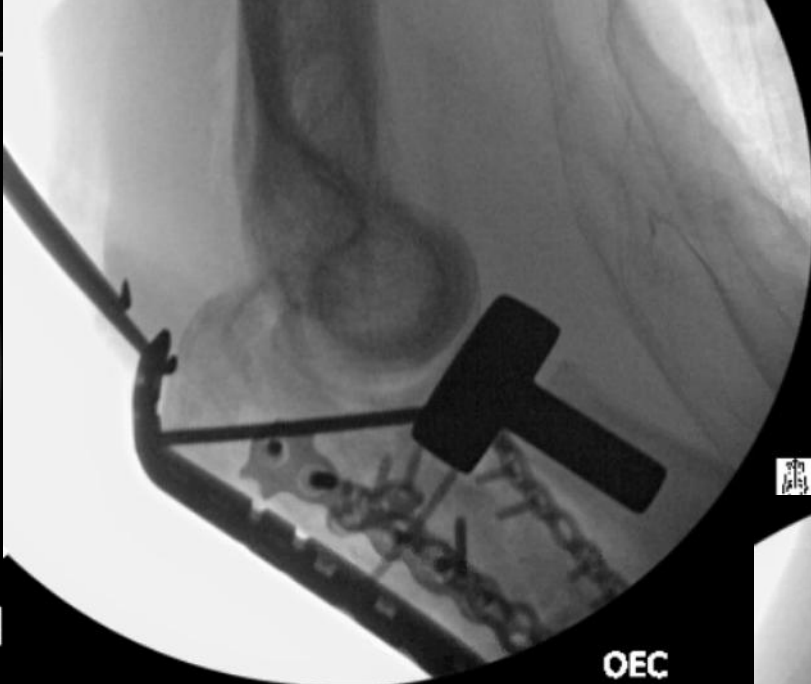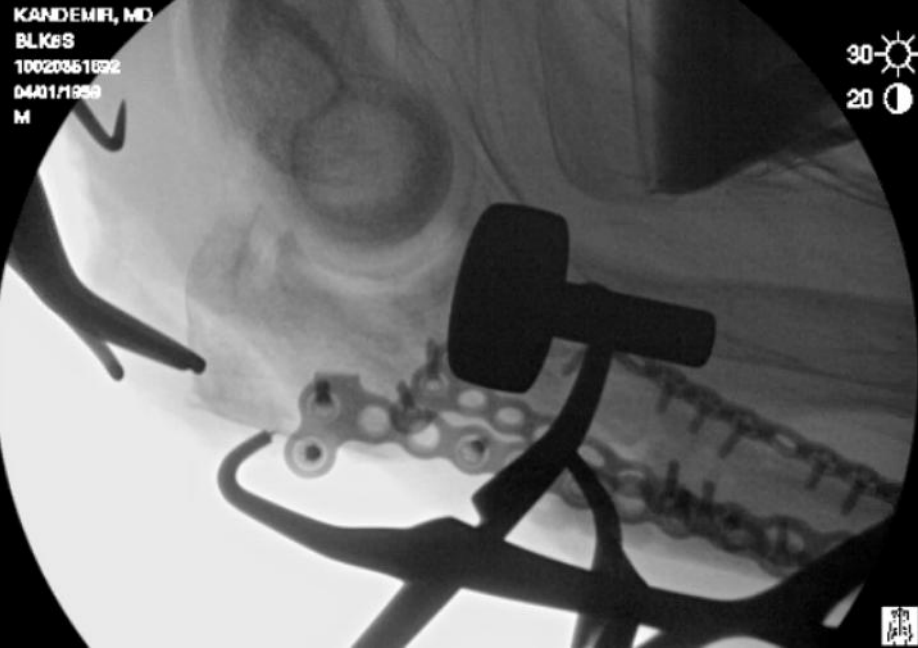61 yo, 6 weeks postop

□ What to do?

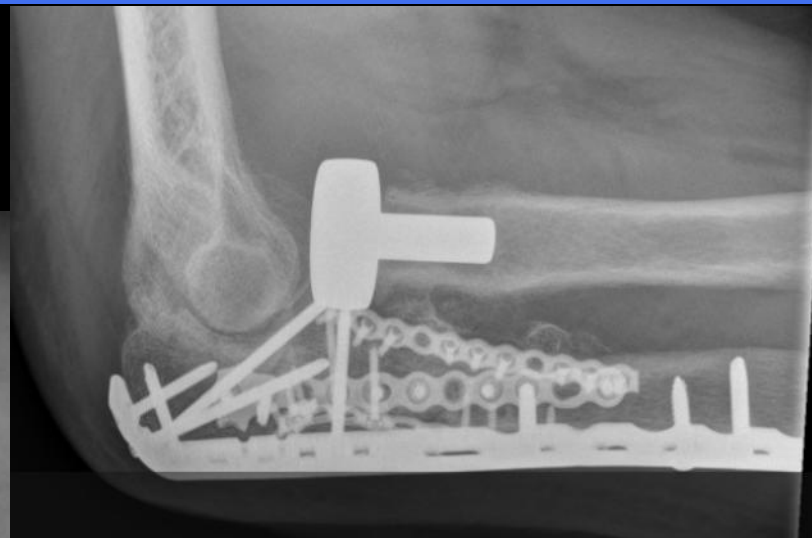
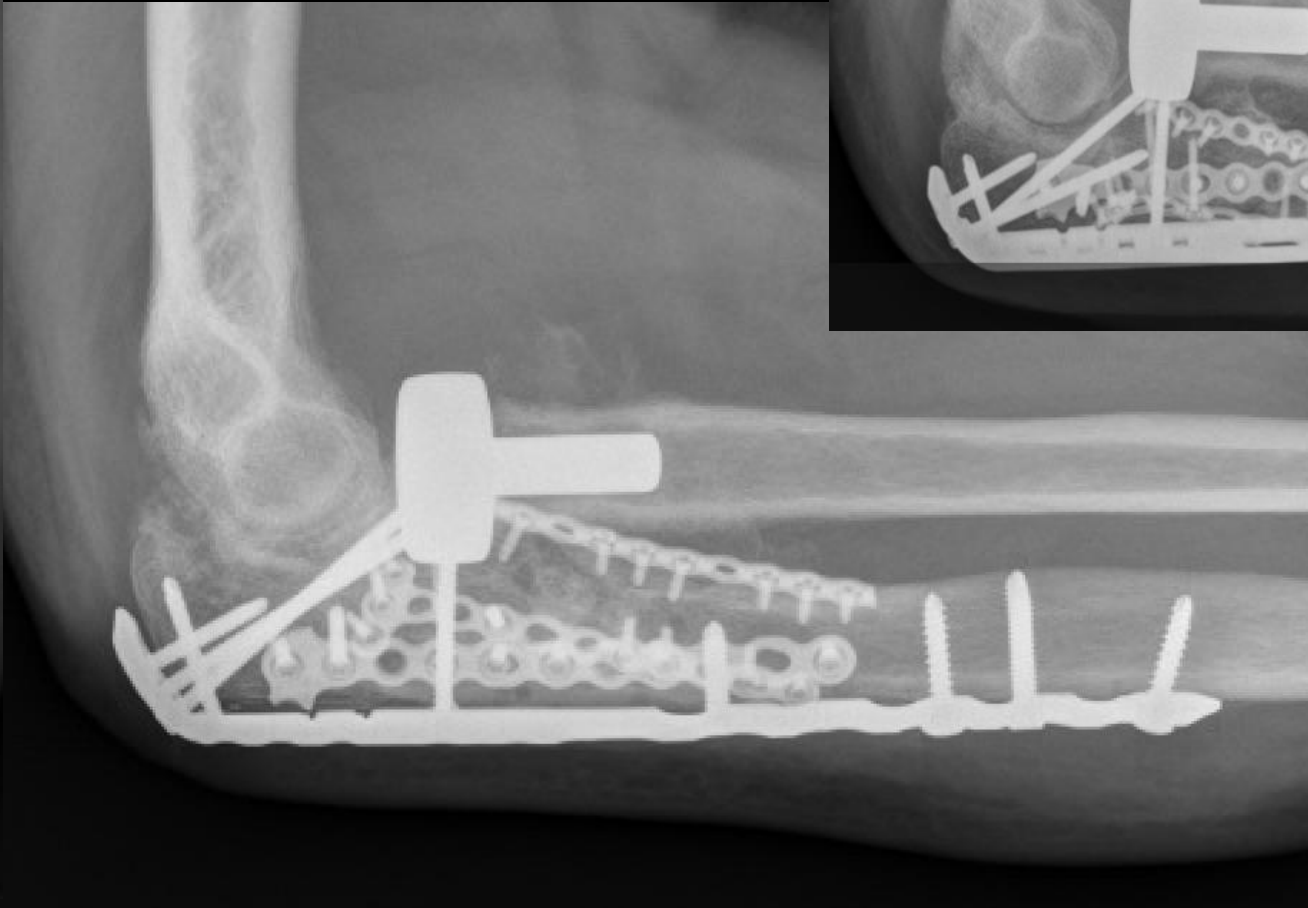
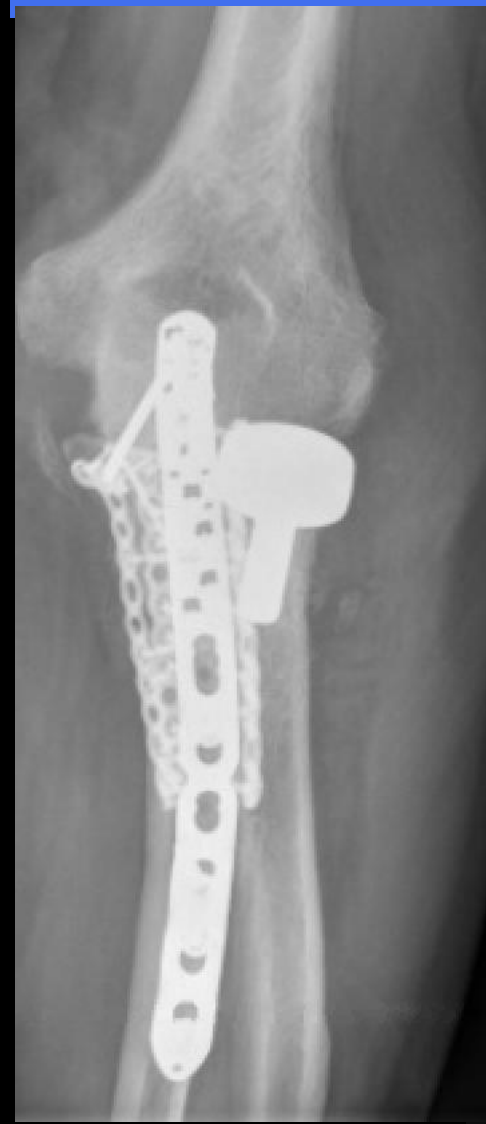

61 yo, 6 weeks





61 yo, 6 months post-revision



Case

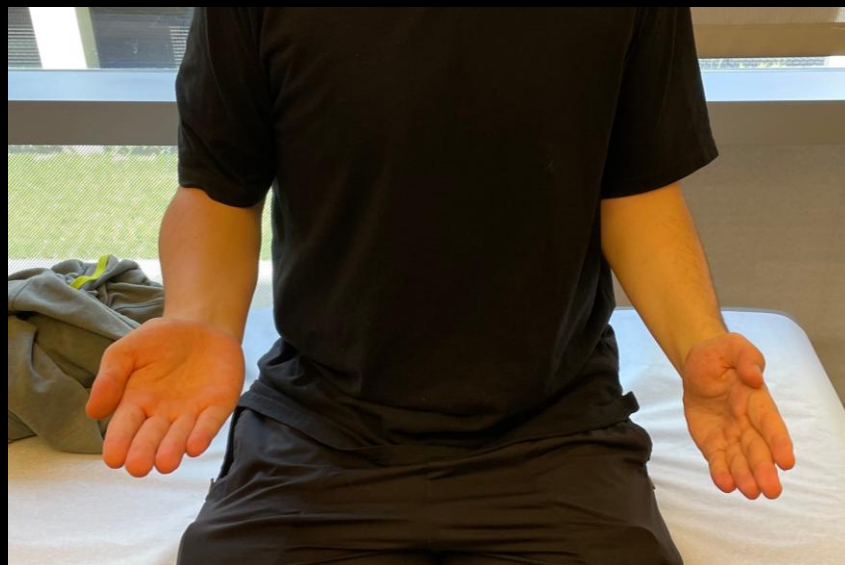26 yo

- s/p bike accident
- Had ORIF the day of injury

26 y/o

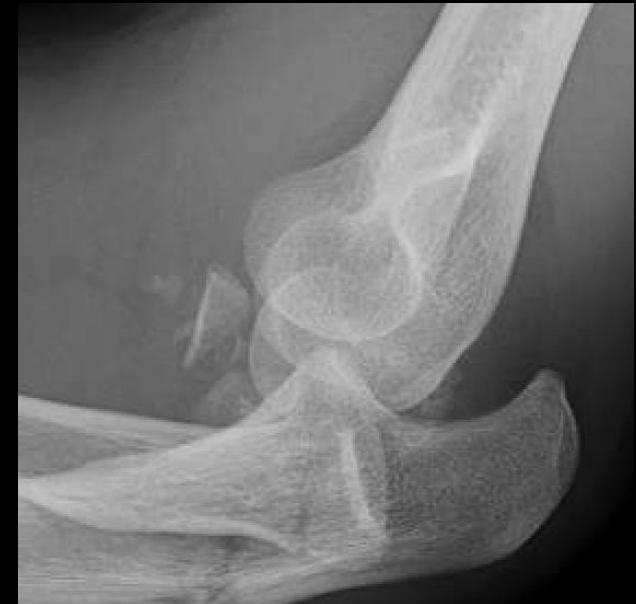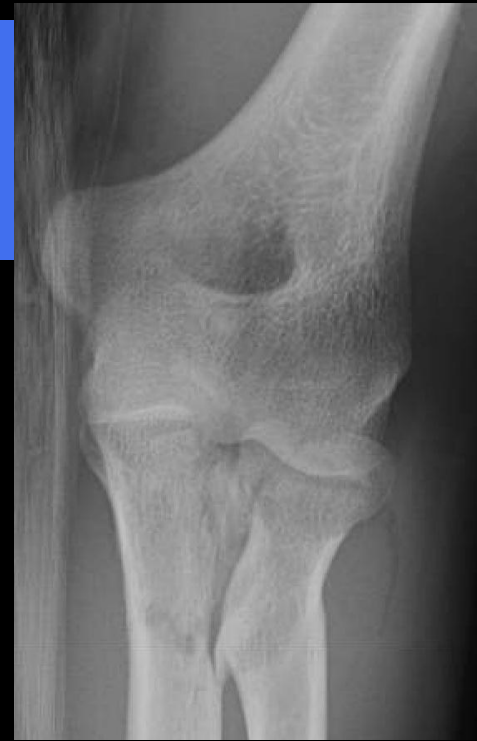- Presented 13 months postop
- c/o elbow and forearm stiffness
- Elbow ROM: 40-90
- Forearm: Supination 0, pronation 10
- DRUJ : ulna dorsal

26 y/o

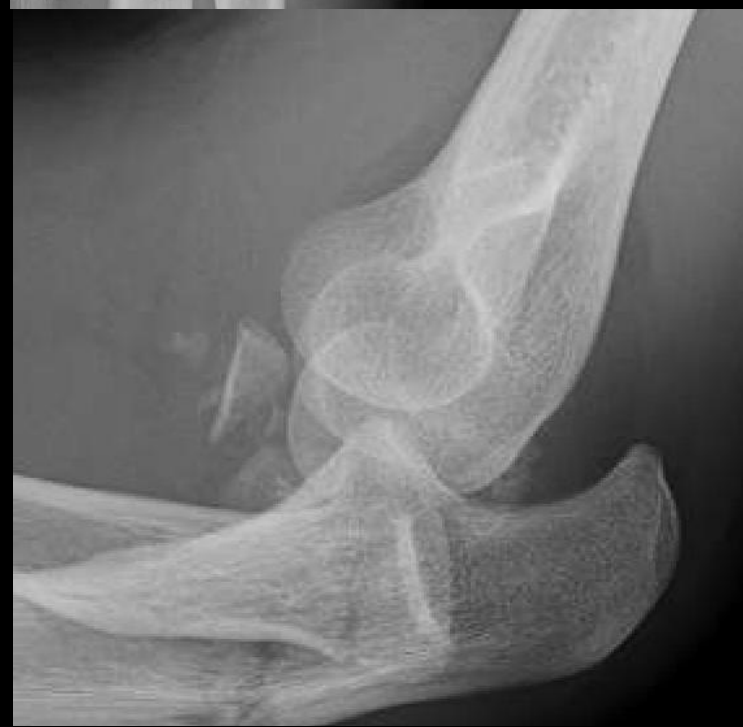
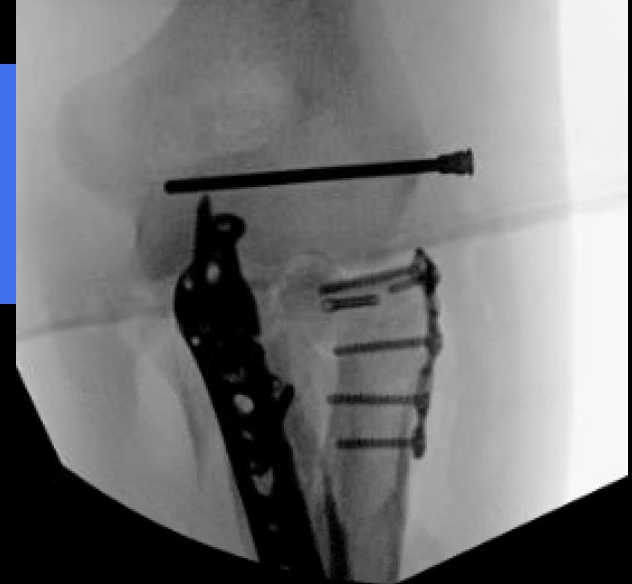
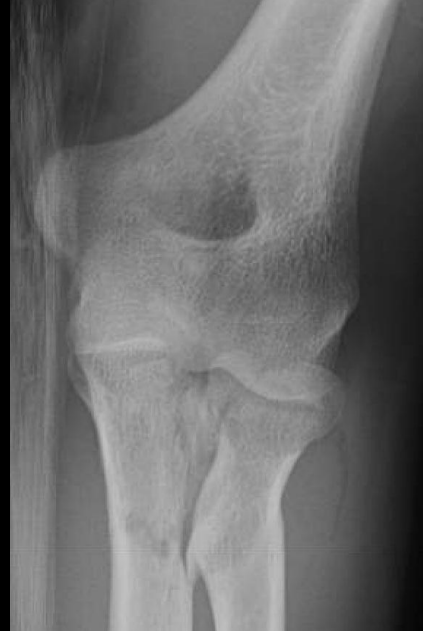26 y/o

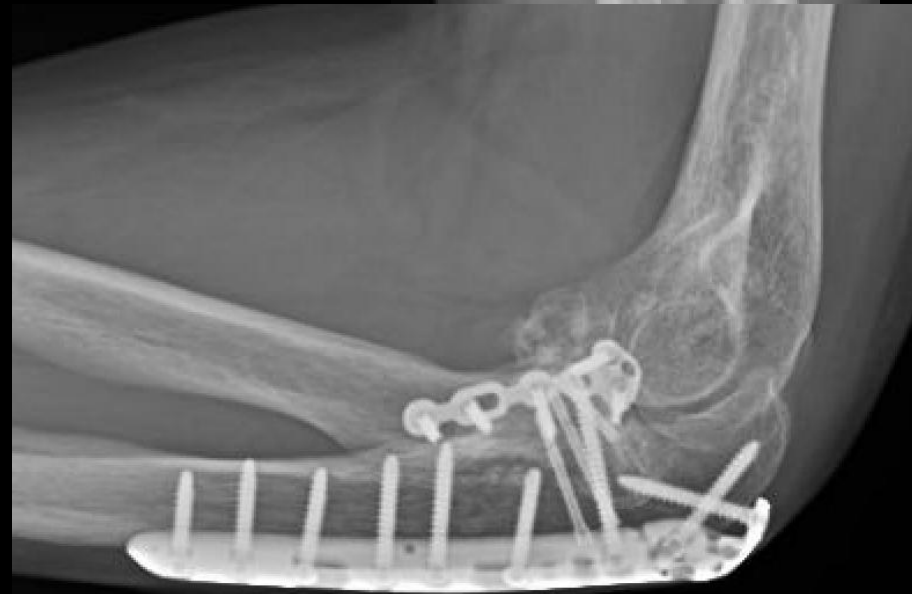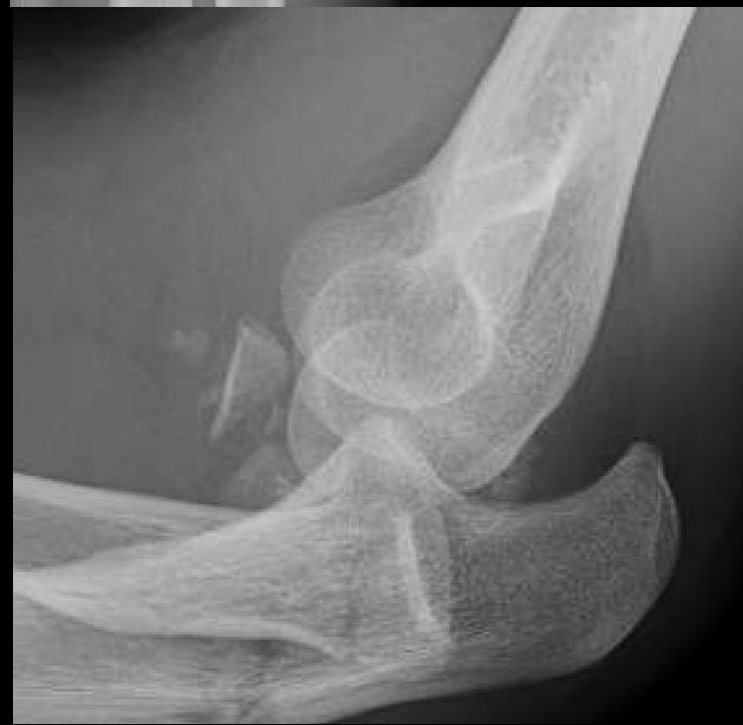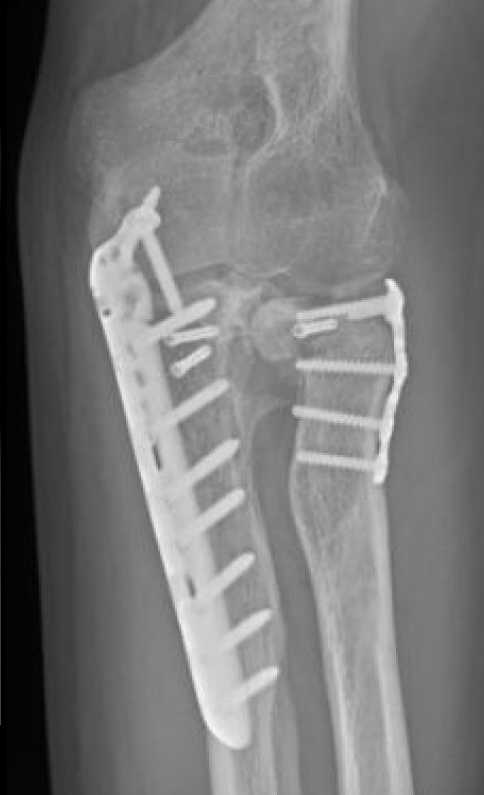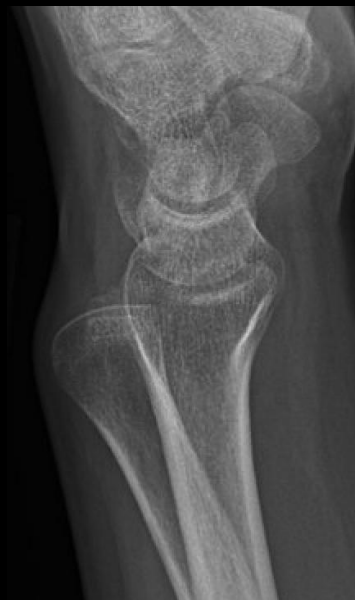- Bike accident
- s/p ORIF
postinjury day#1



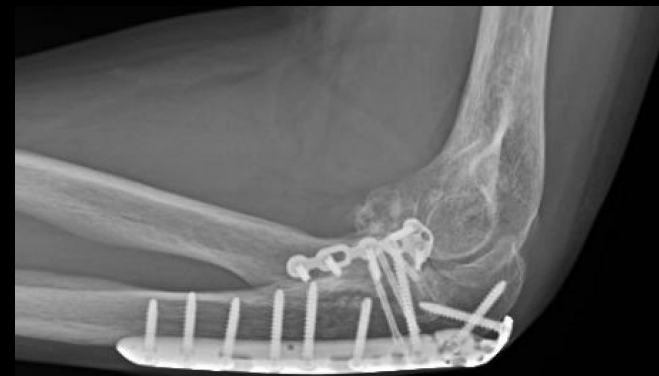
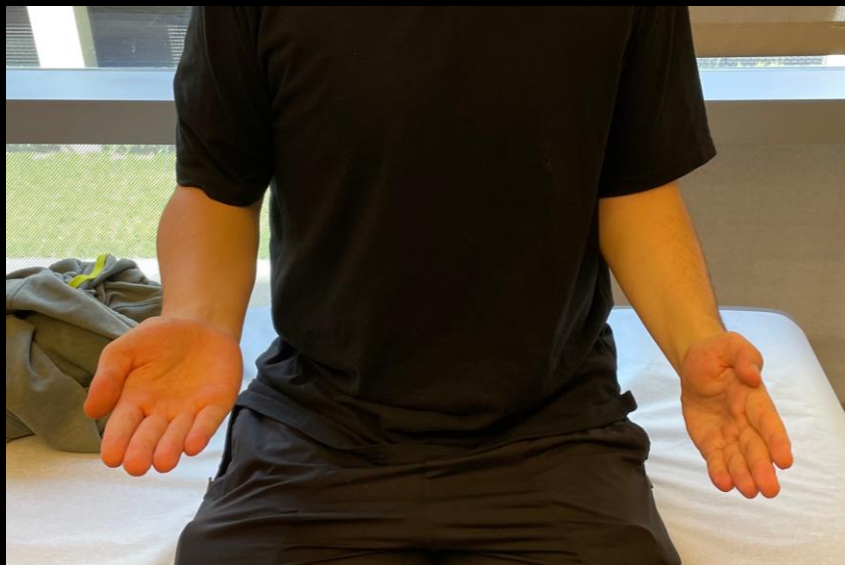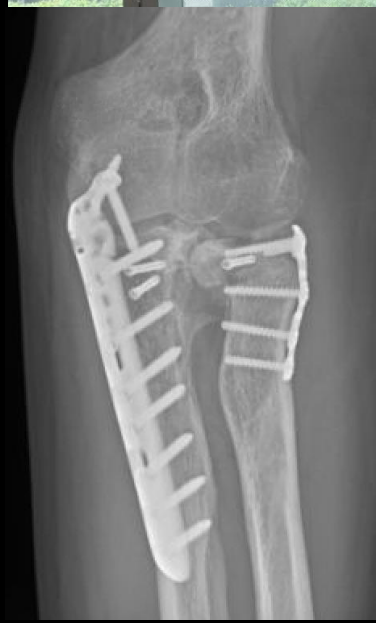26 y/o



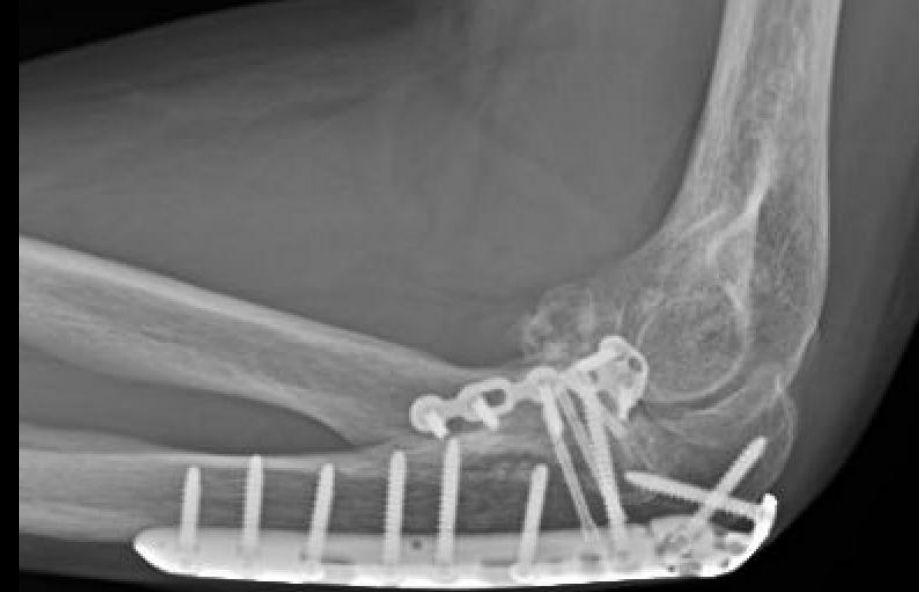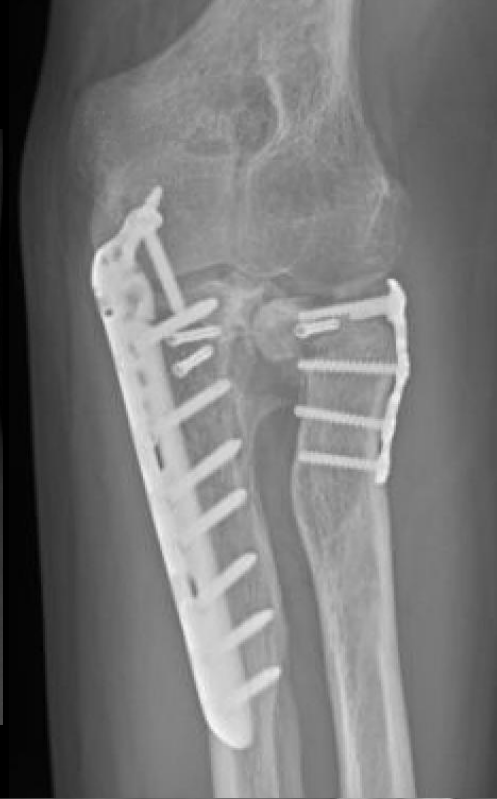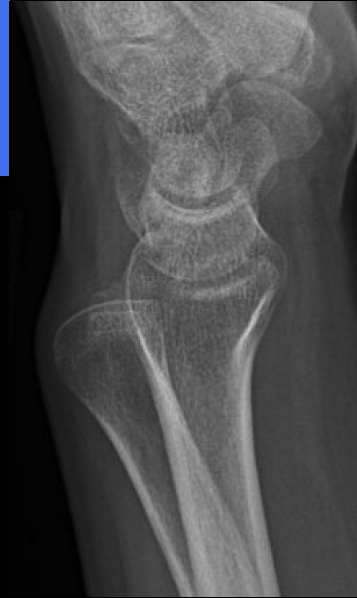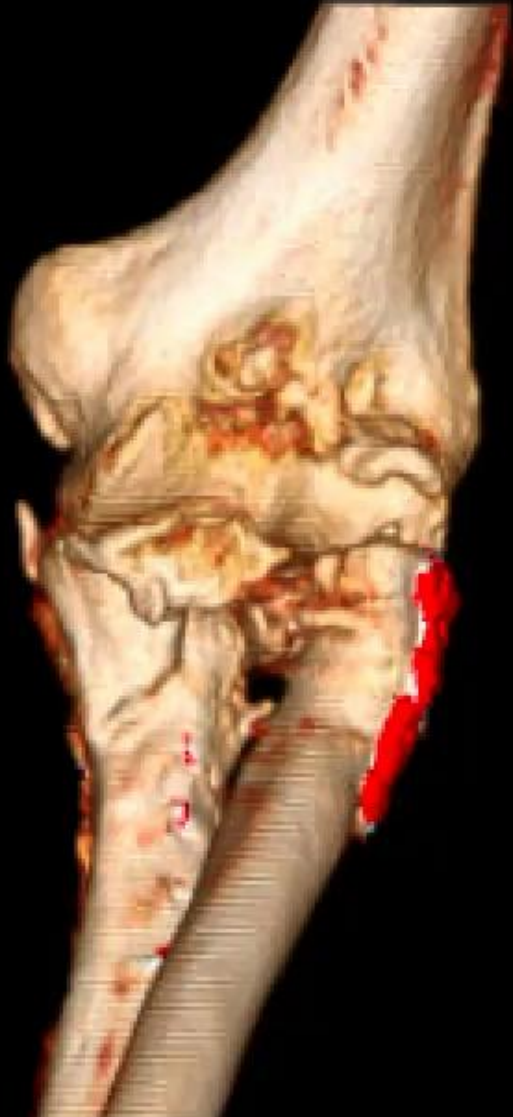26 y/o,
13 months
postop



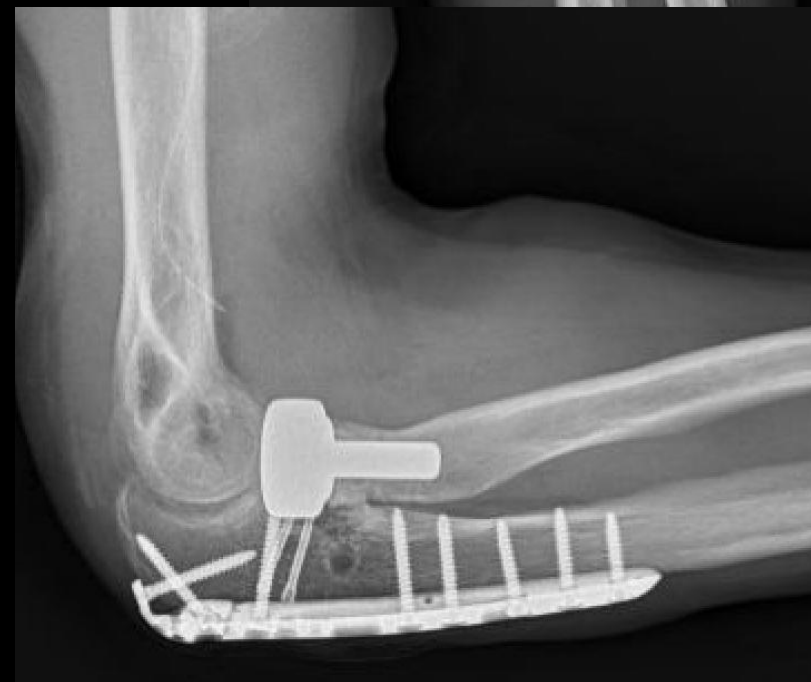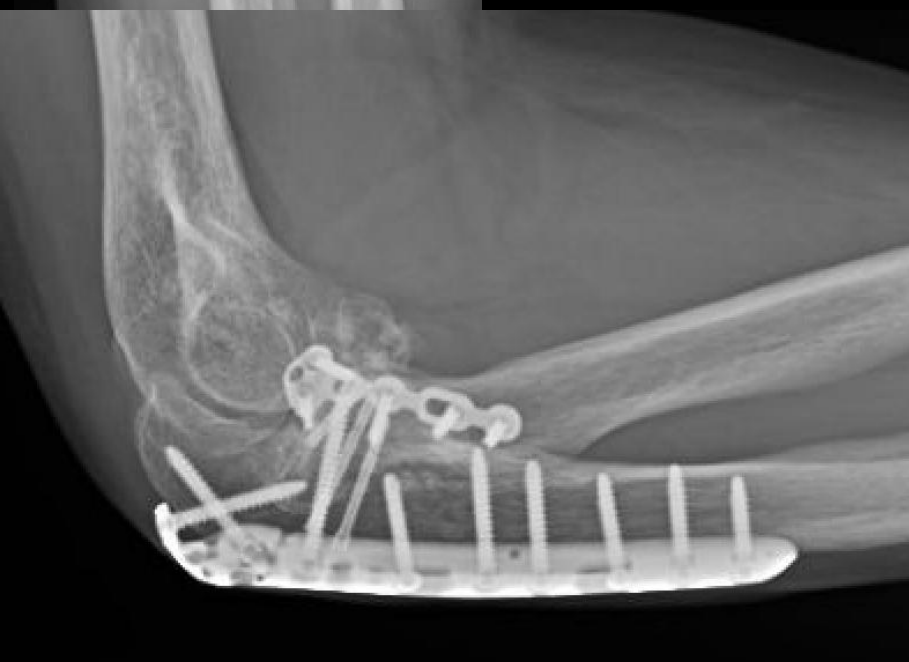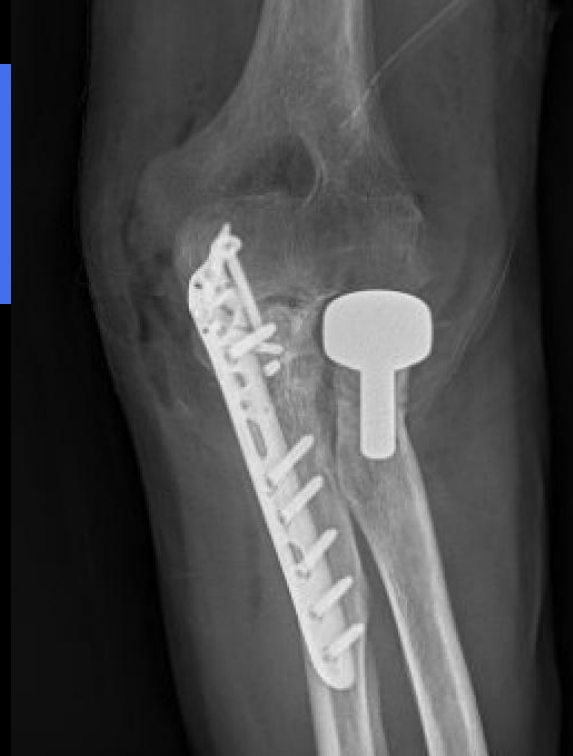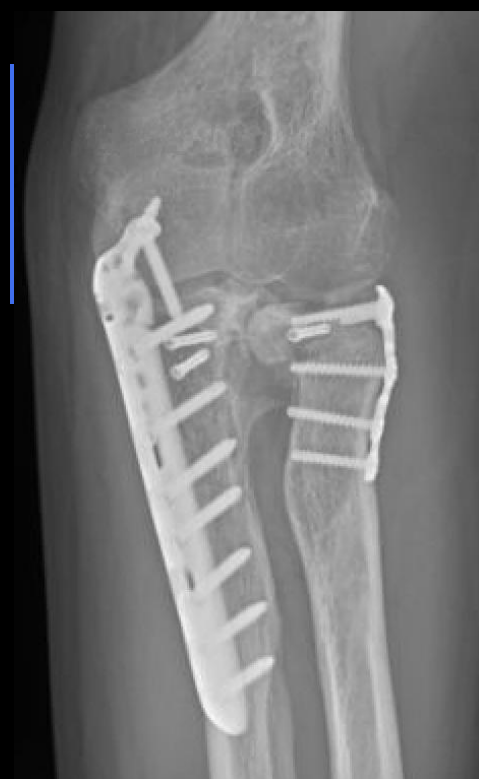26 y/o



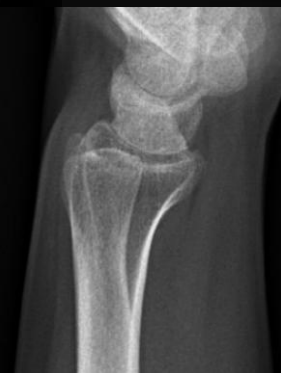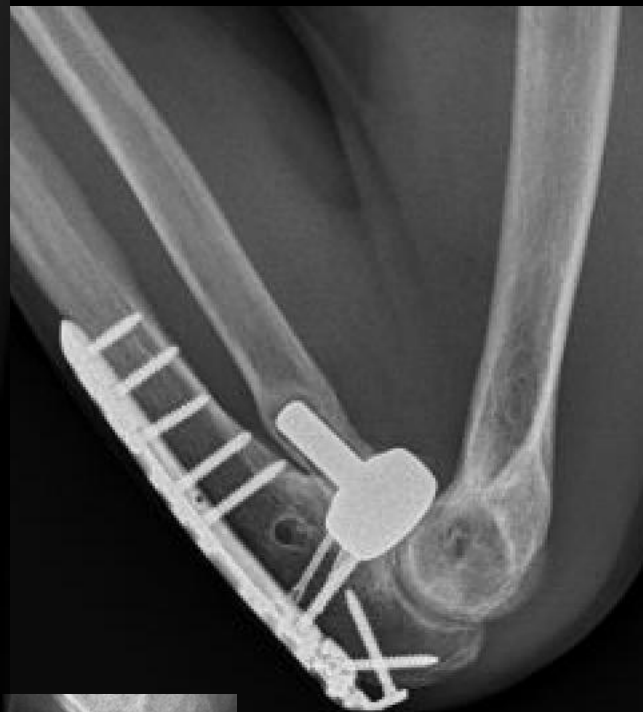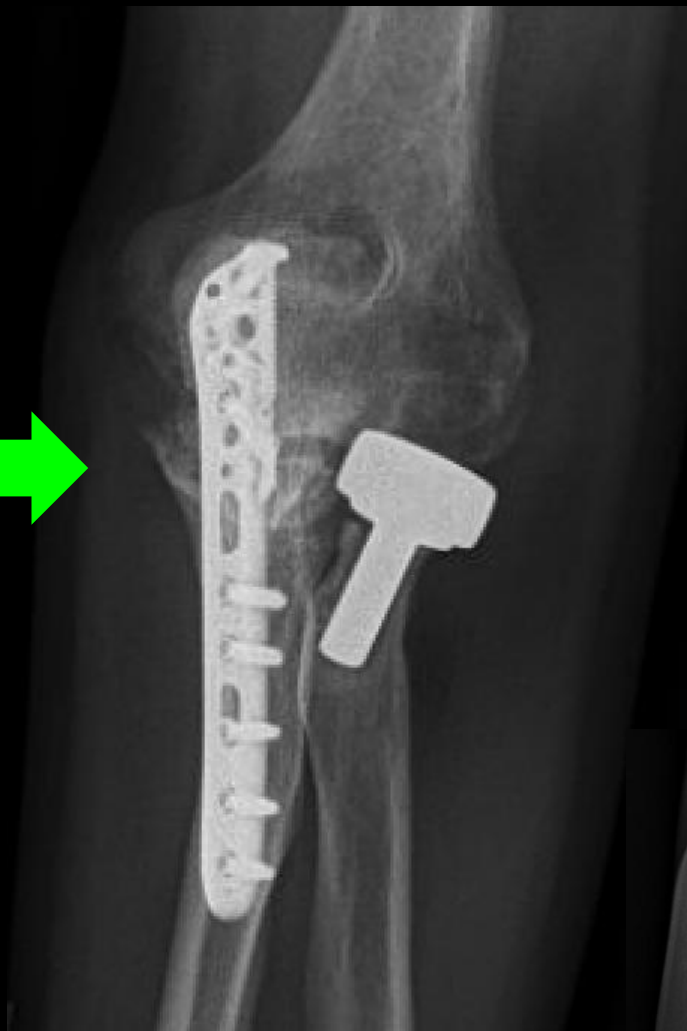
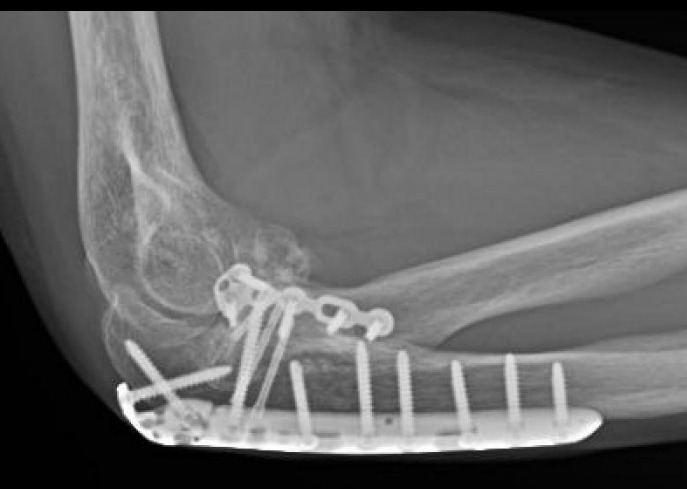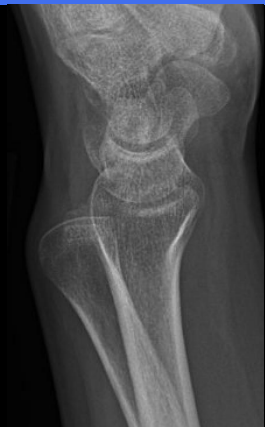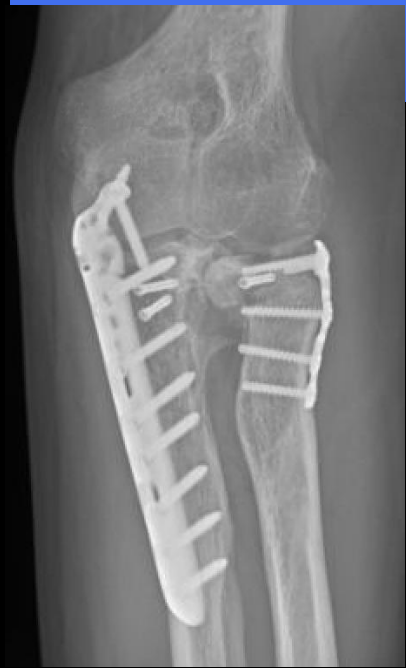26 y/o, 13 months
postop



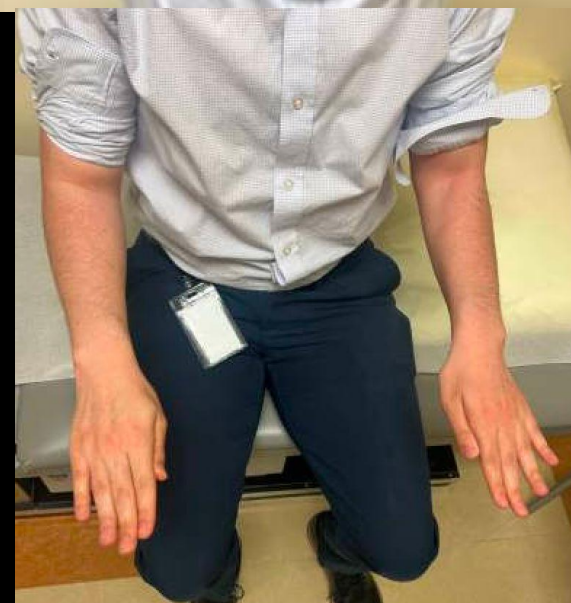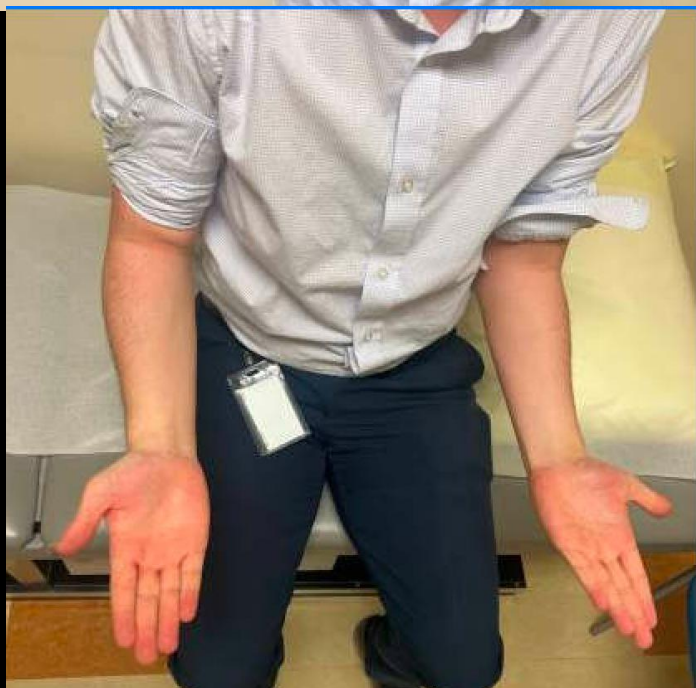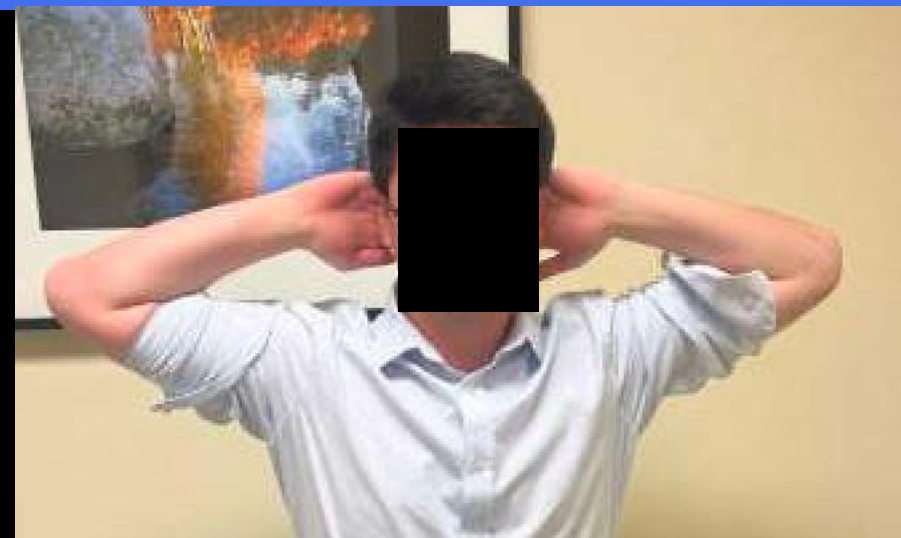
26 y/o



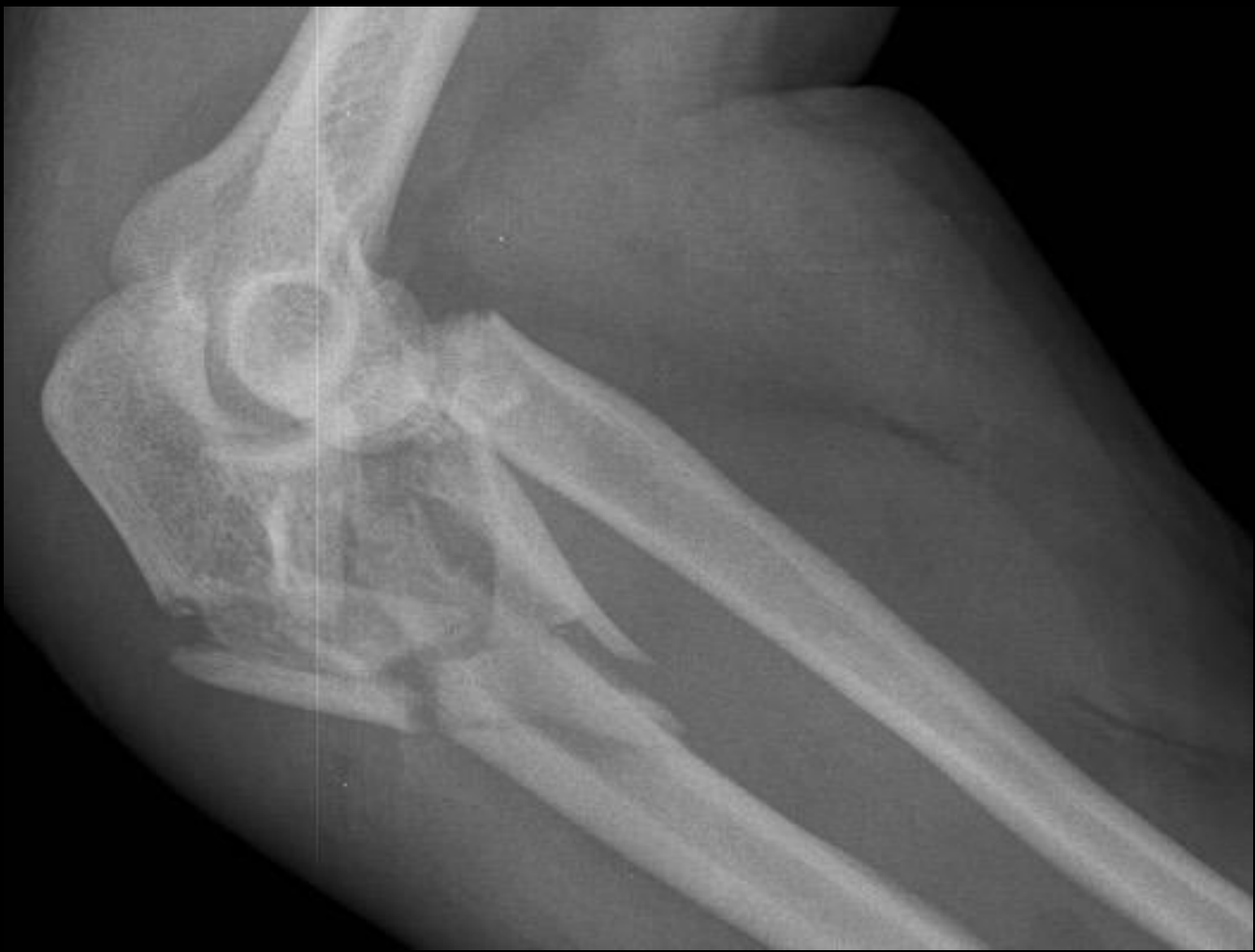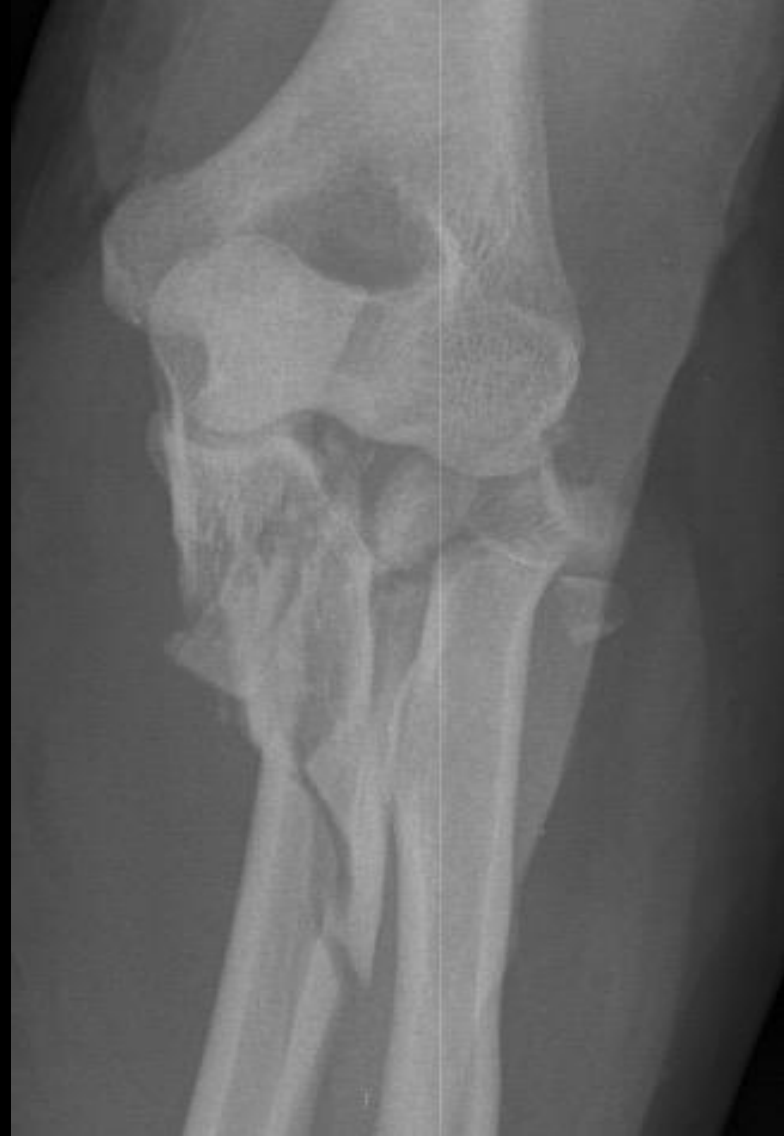26 y/o, 1 year f/u

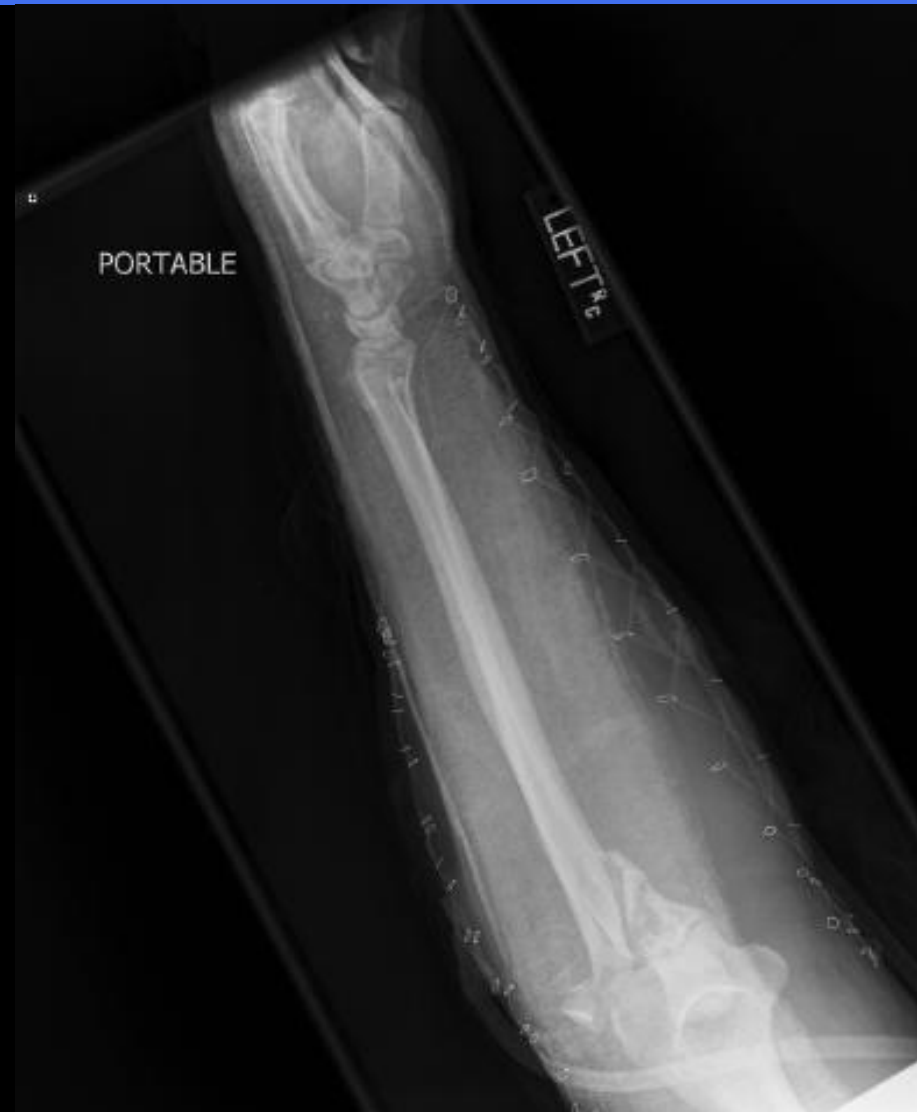
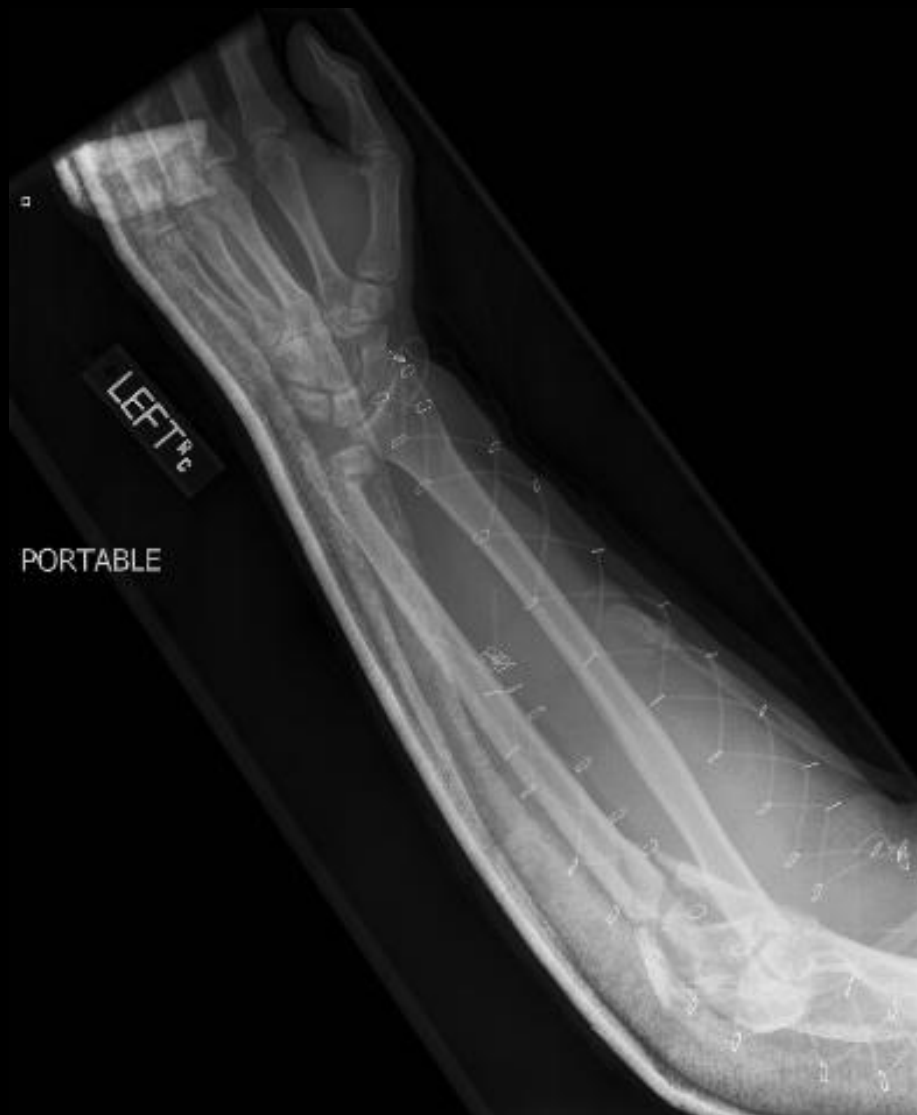
26 y/o, 1 year f/u


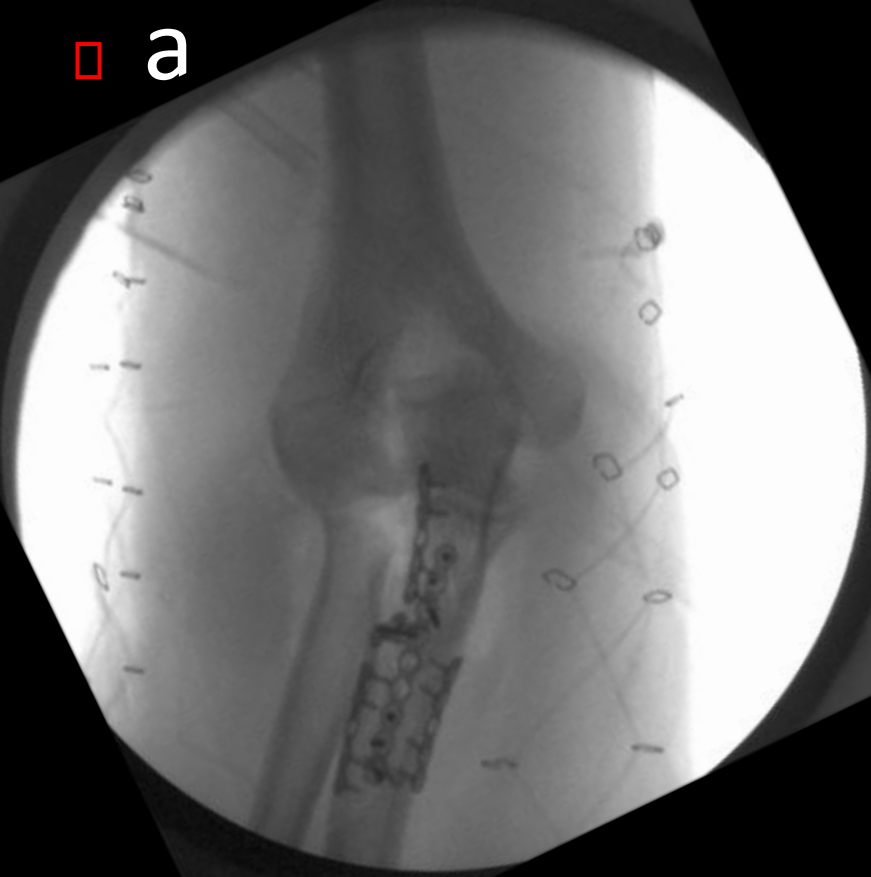


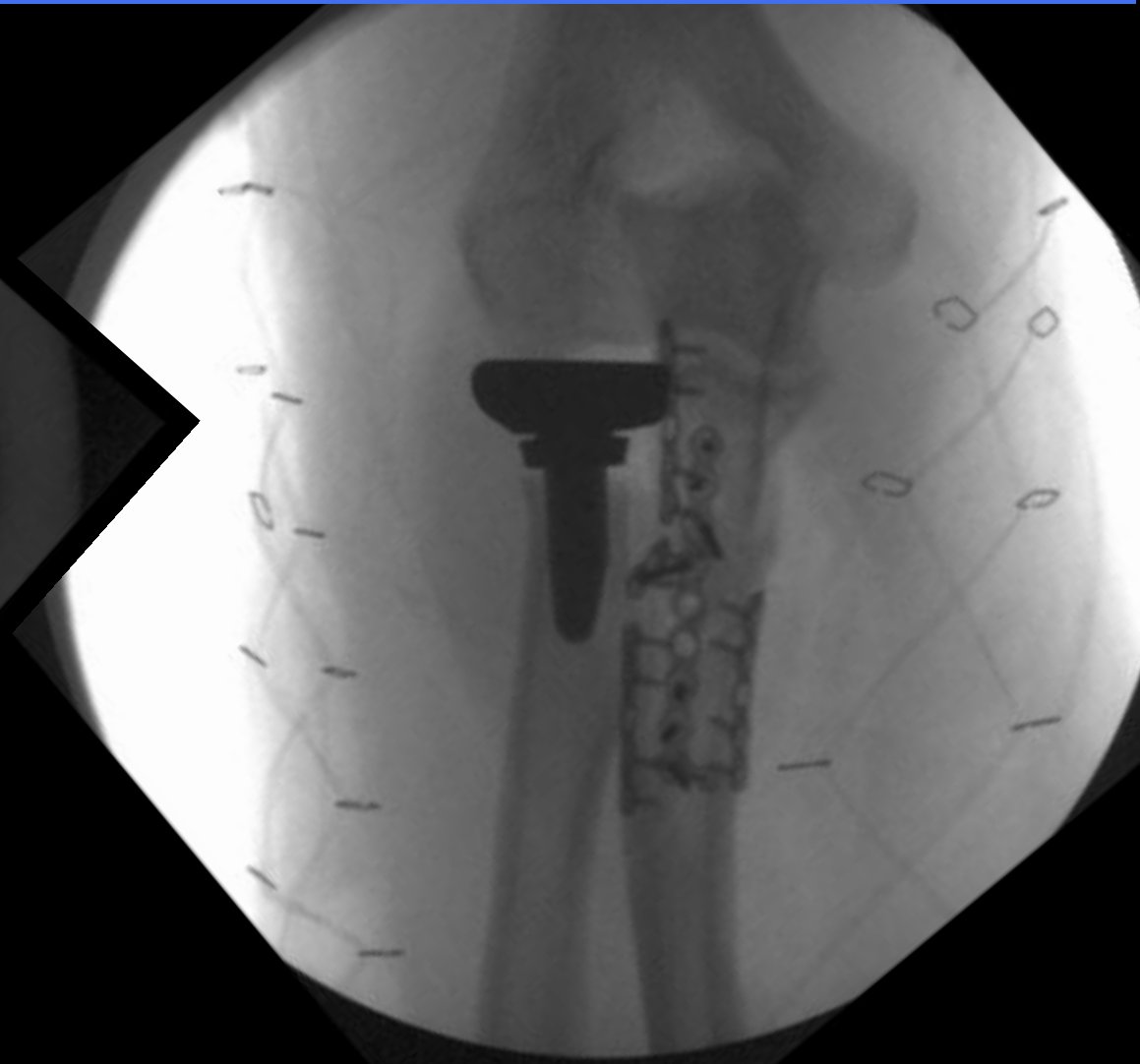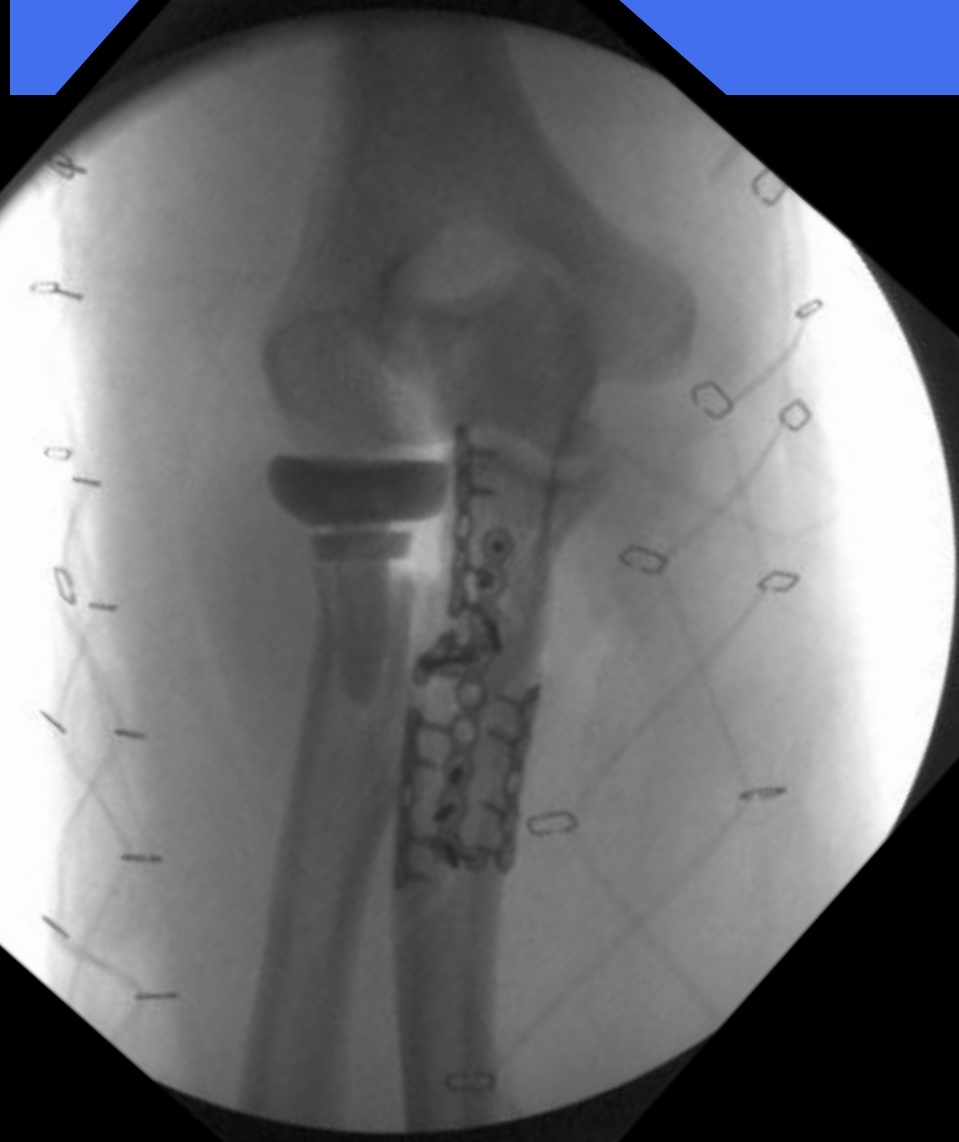
Case

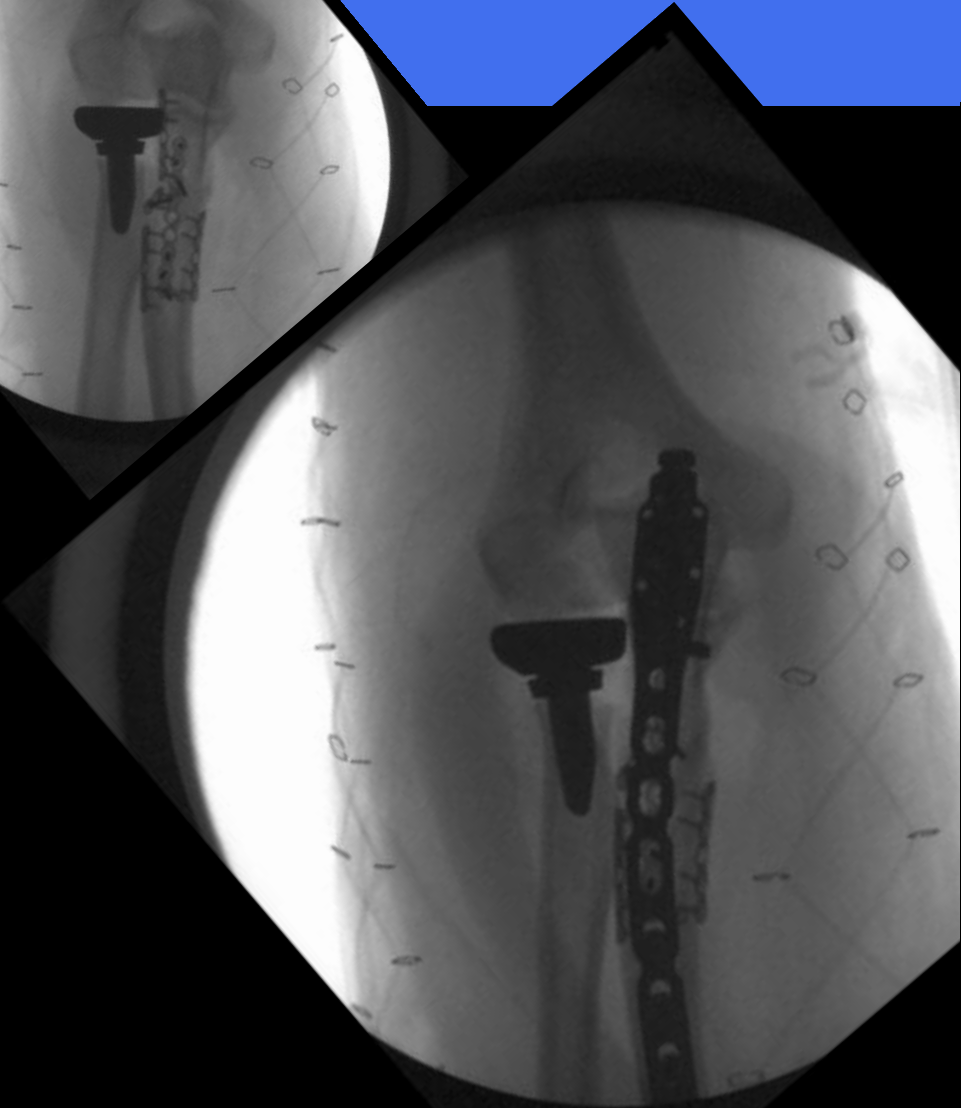
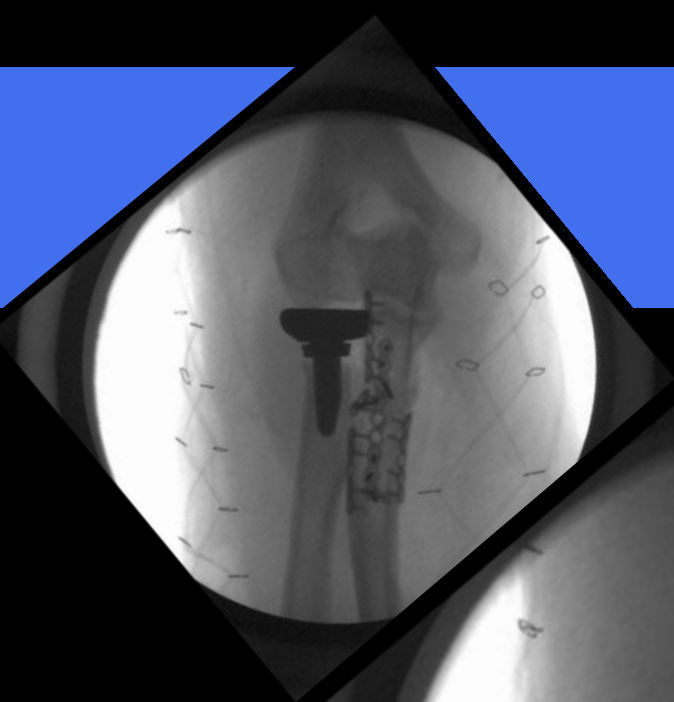


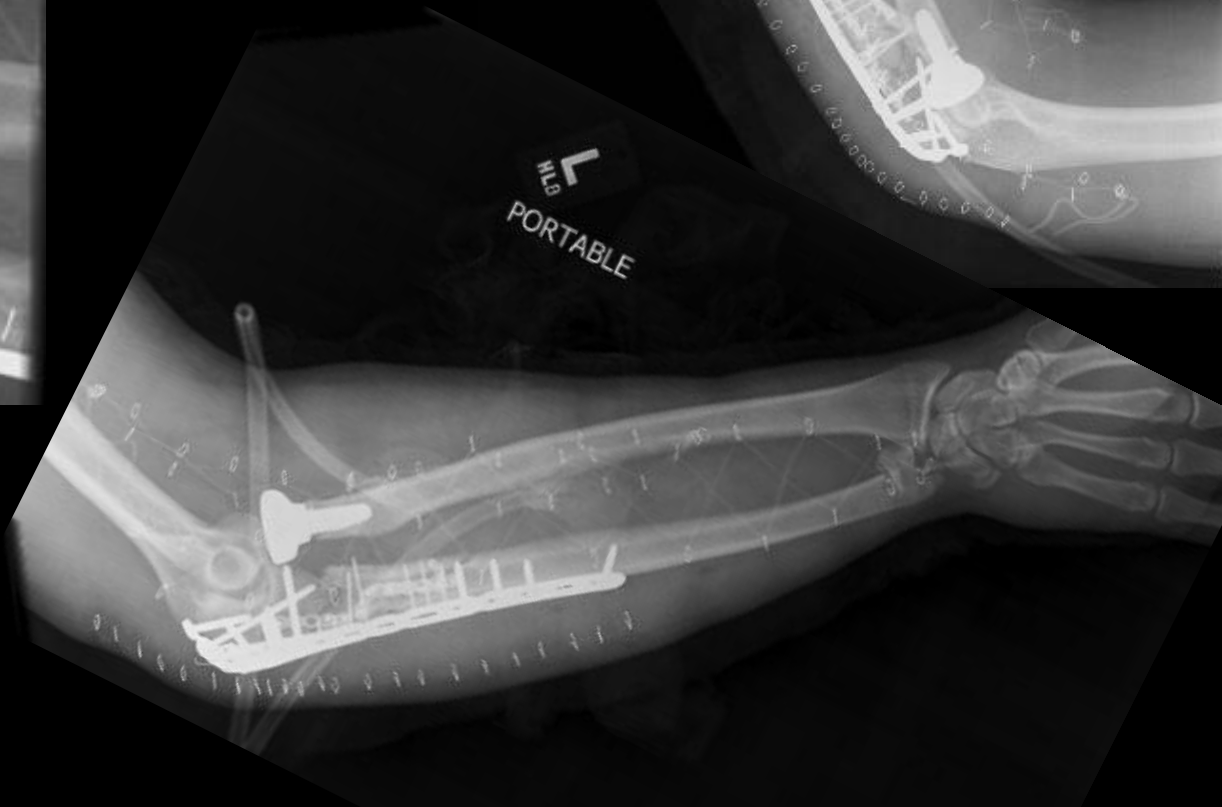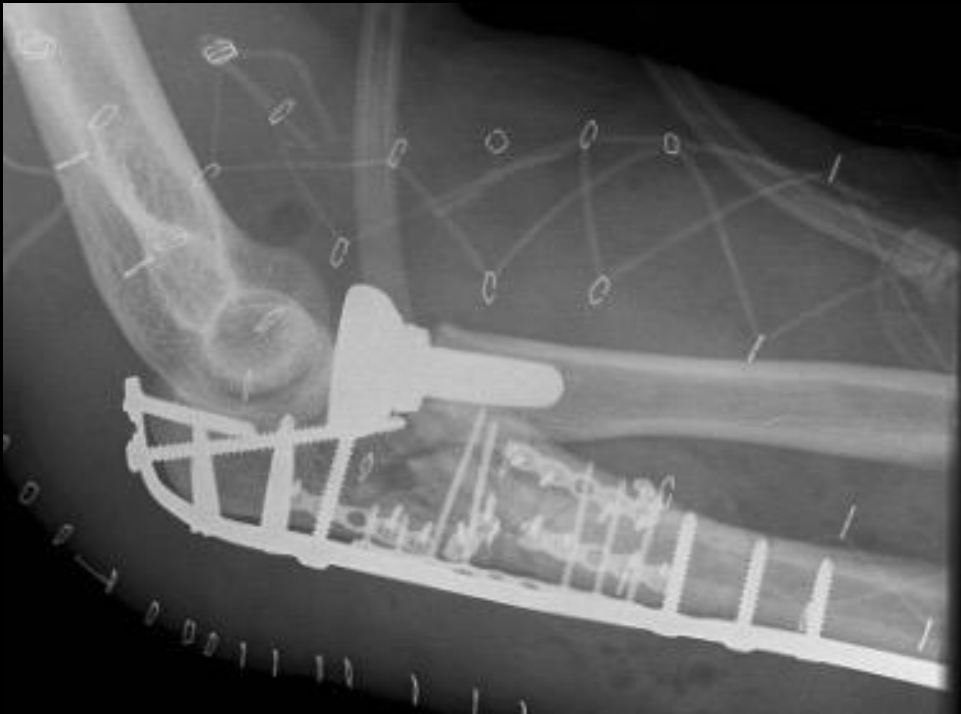

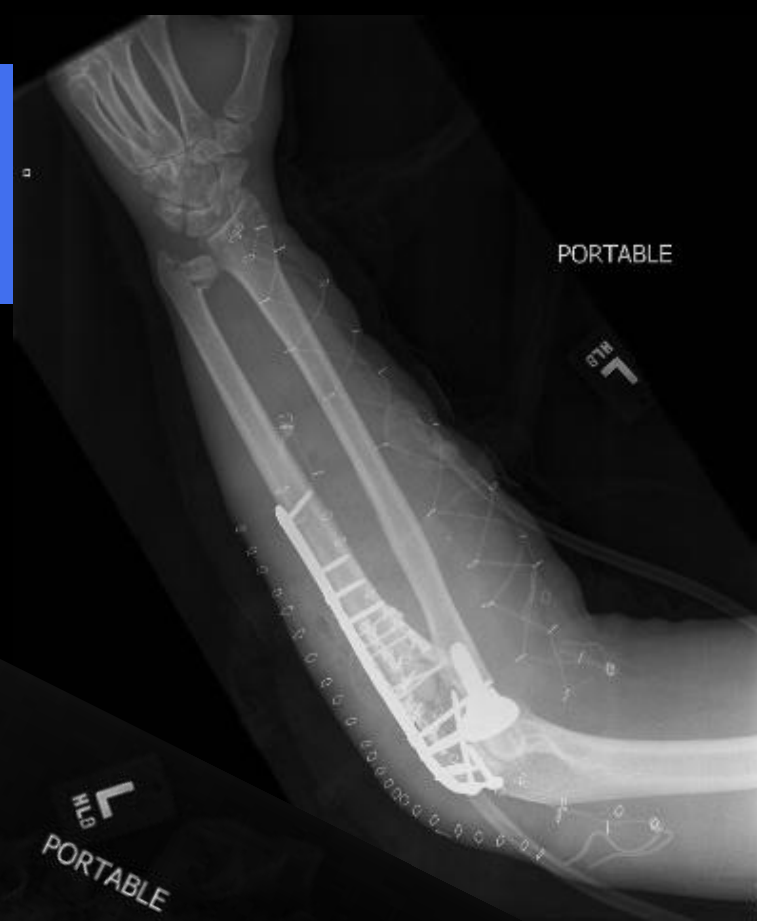
□ a



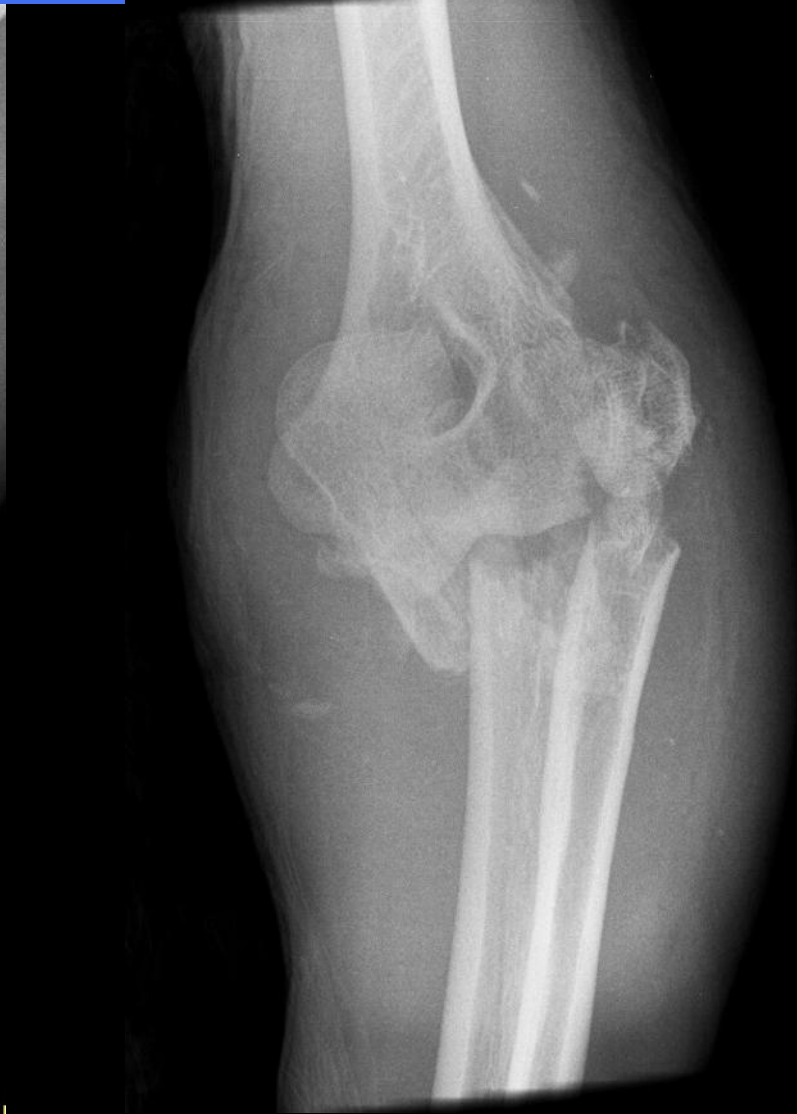
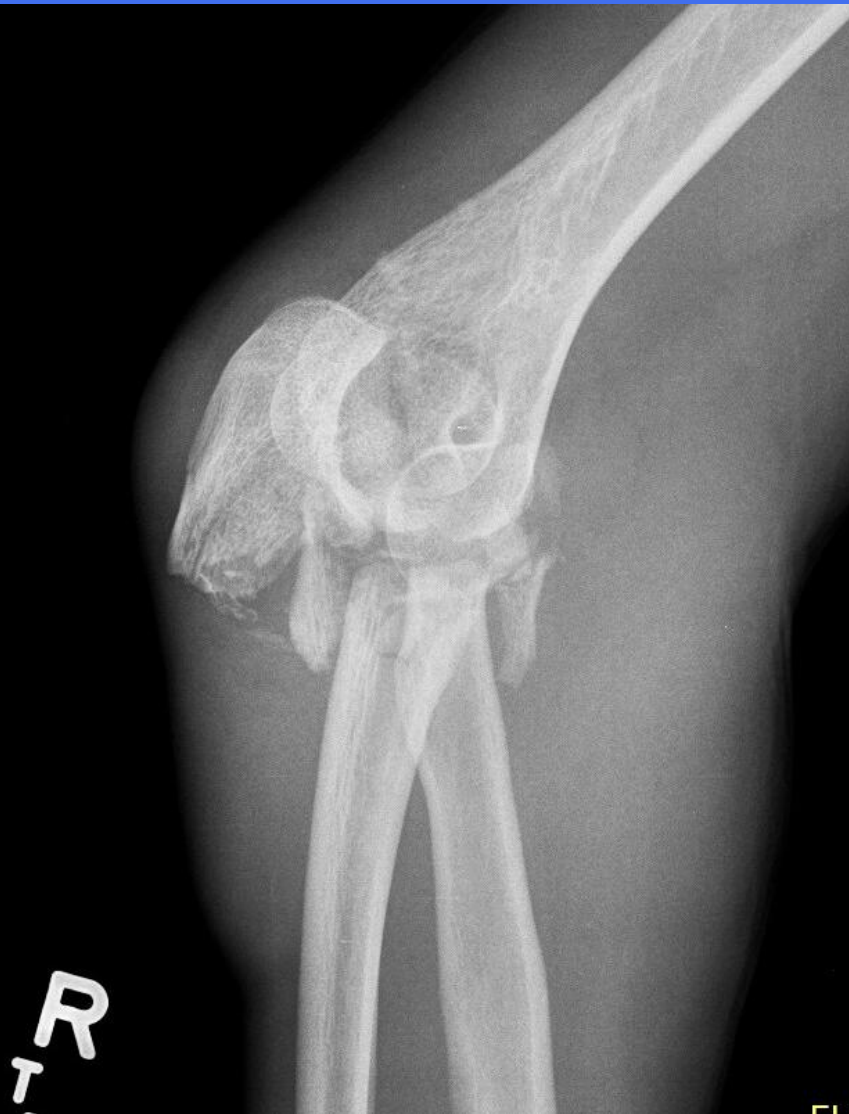




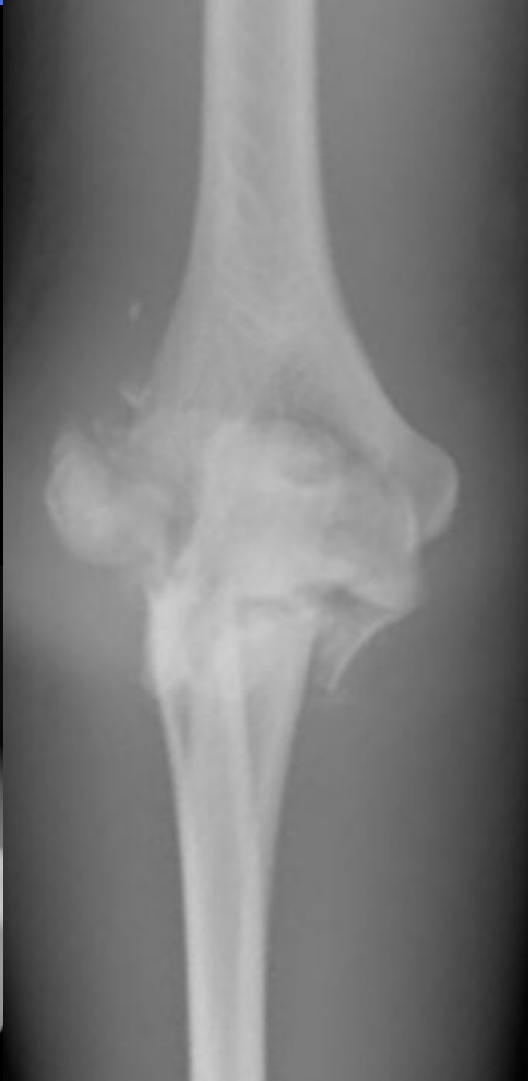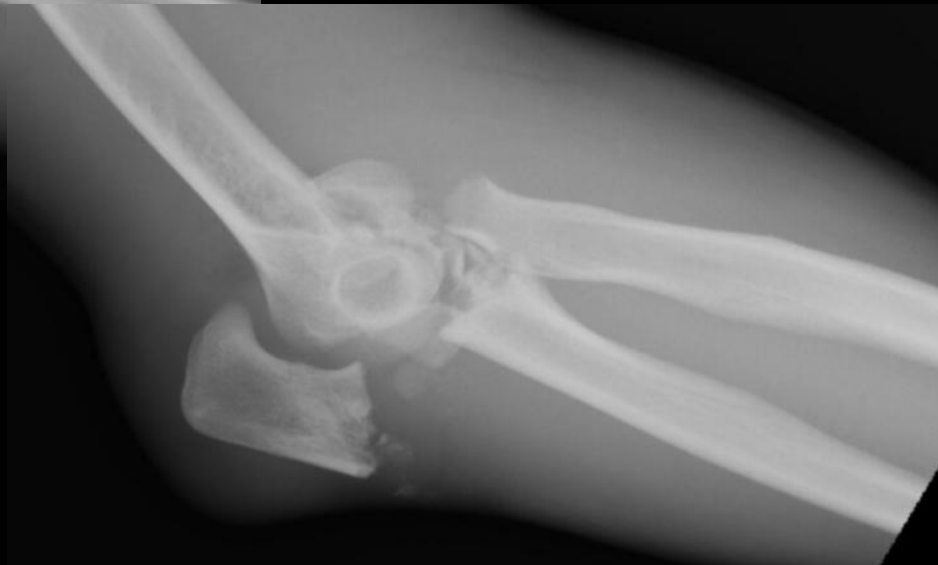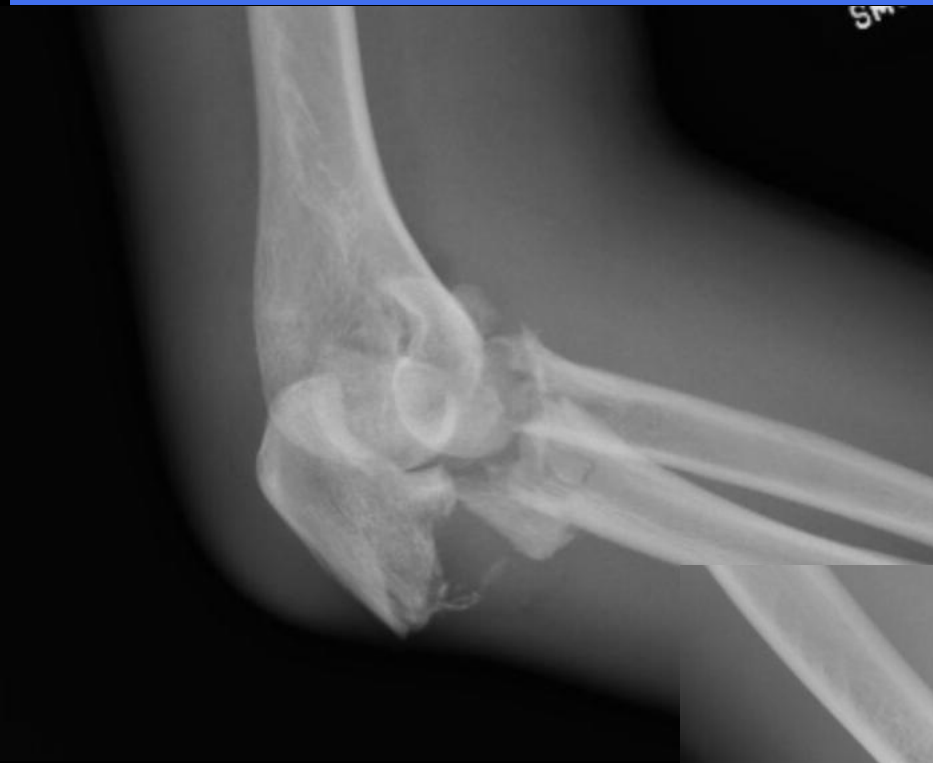Case

41 yo fall from 3 stories



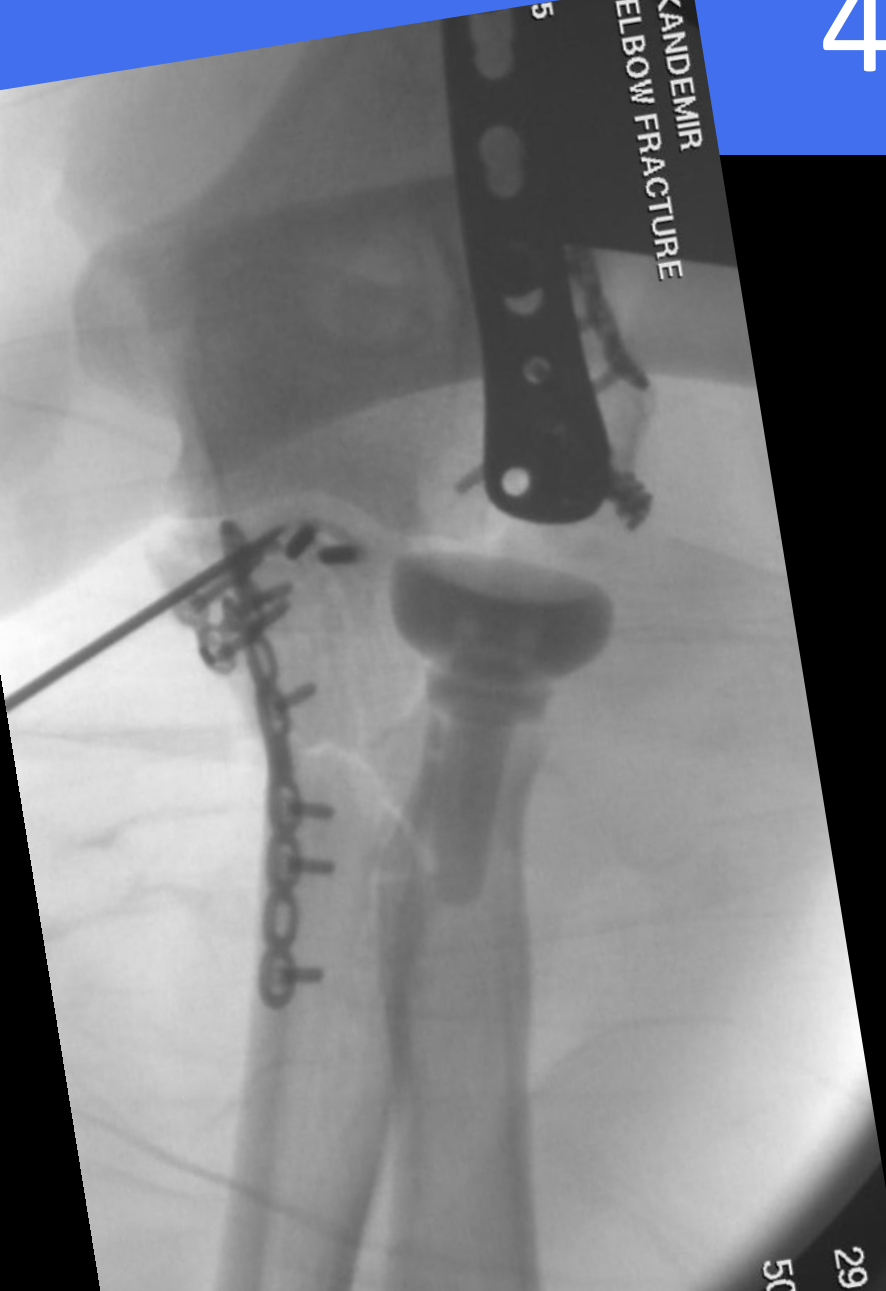41 yo



41 yo

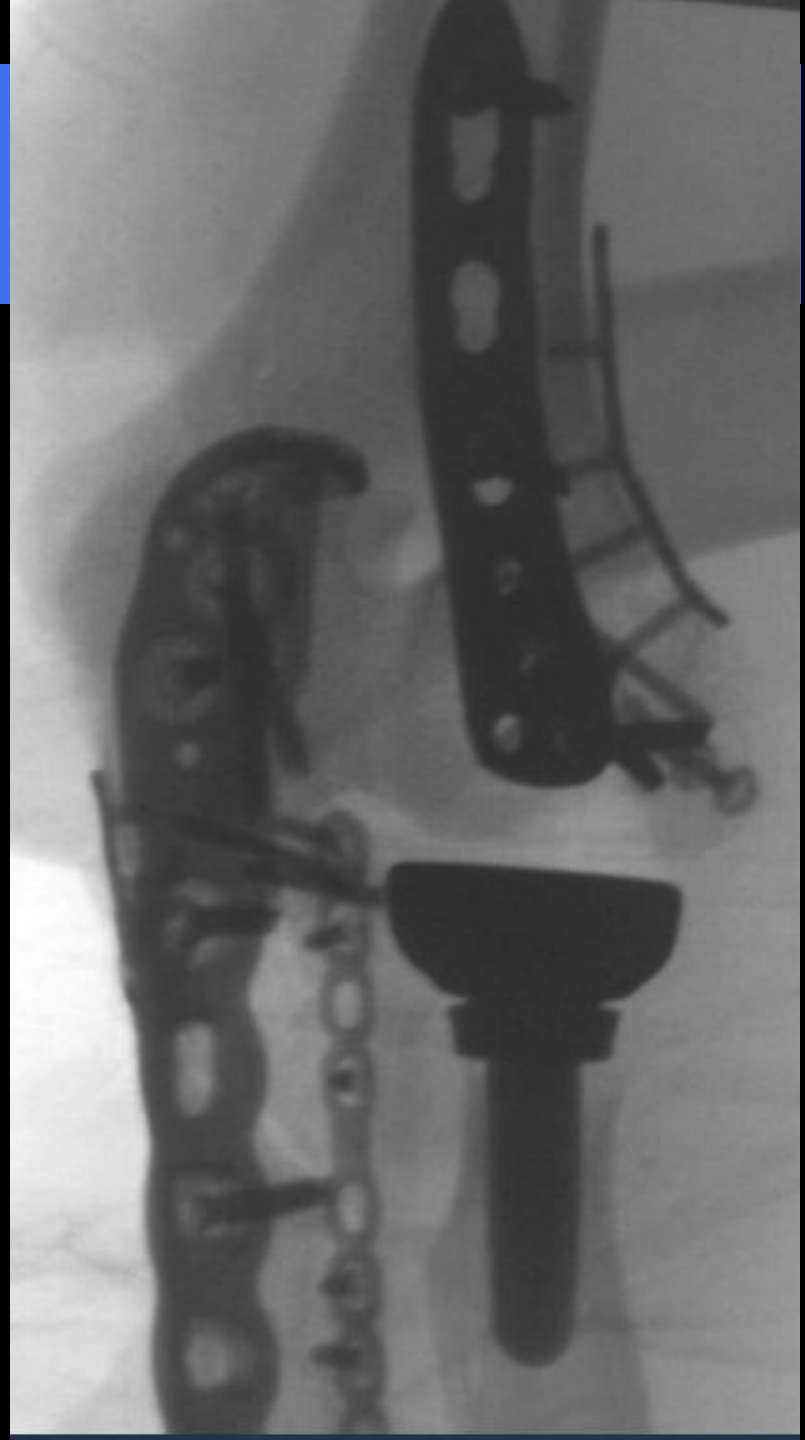
KANDEMIR
ELBOW FRACTURE

5

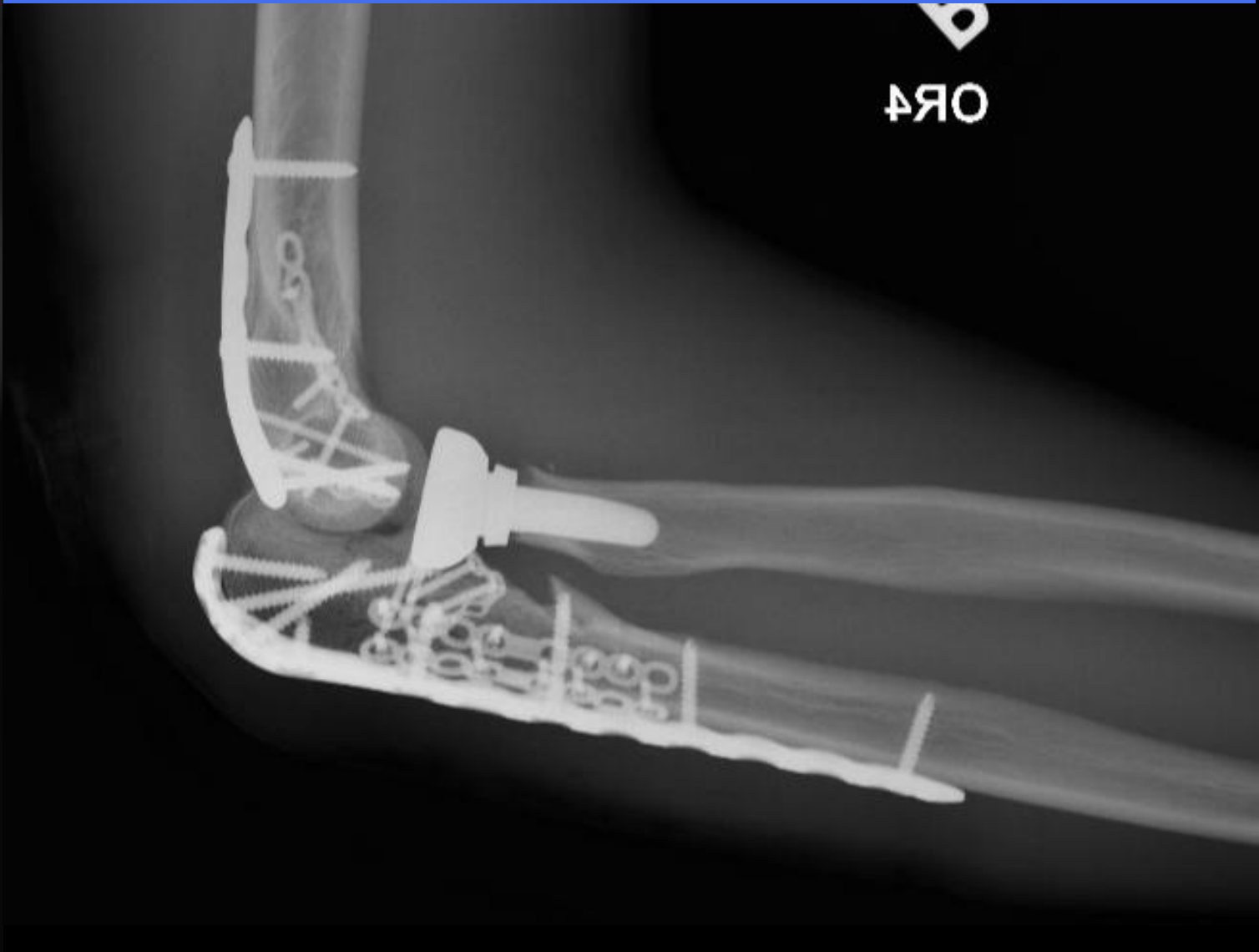
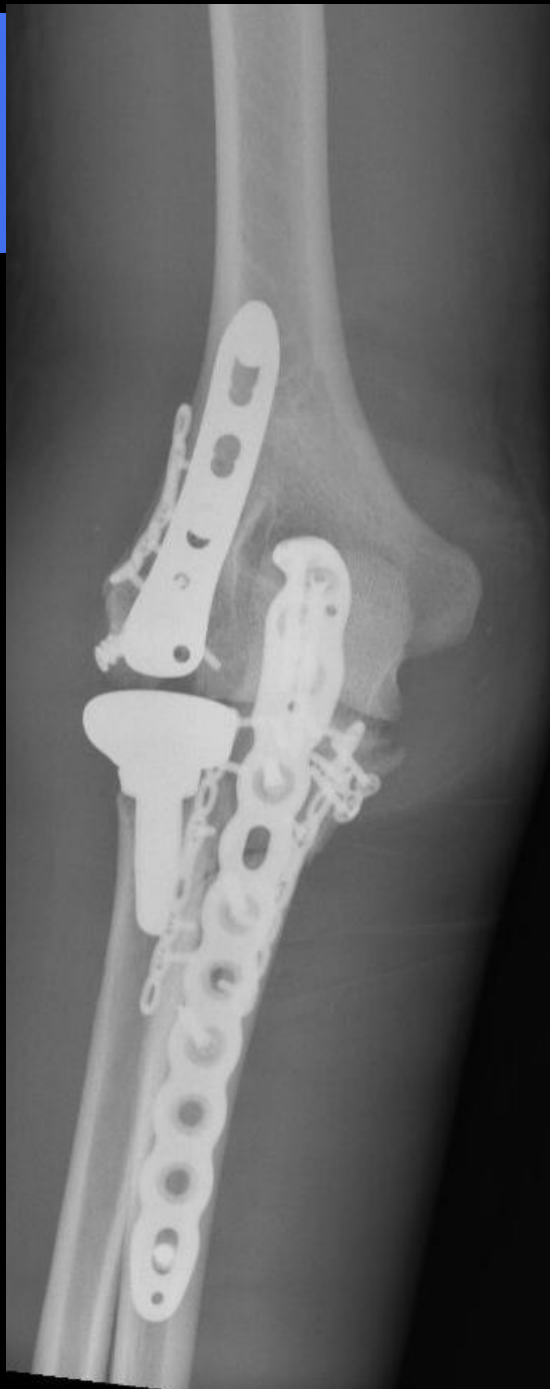
29

50



41 yo



THANK YOU



Utku.Kandemir@ucsf.edu

