

# Distal Humerus Fractures CASES

**Edward J Harvey MD MSc**

Professor | **McGill University**

Head of Surgery and Interventional Sciences Program | **MUHC-RI**



McGill

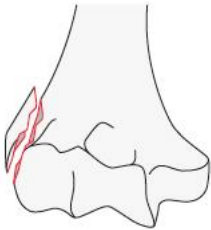
# Distal Humerus Fx Assessment

Extra-articular

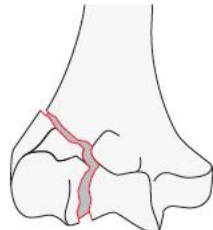
Simple

Complex

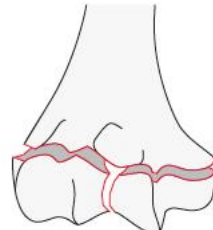
Humerus, distal end segment,  
**extraarticular fracture**  
13A



Humerus, distal end segment,  
**partial articular fracture**  
13B



Humerus, distal end segment,  
**complete articular fracture**  
13C



JANUARY 2018 VOLUME 32 NUMBER 1 SUPPLEMENT TO

# JOT

www.jorthotrauma.com

# JOURNAL OF ORTHOPAEDIC TRAUMA



AO Foundation

## FRACTURE AND DISLOCATION CLASSIFICATION COMPENDIUM—2018

OFFICIAL JOURNAL OF

**Orthopaedic Trauma Association**  
AOTrauma North America  
Belgian Orthopaedic Trauma Association  
Canadian Orthopaedic Trauma Society  
Foundation for Orthopedic Trauma  
International Society for Fracture Repair  
The Japanese Society for Fracture Repair

Wolters Kluwer

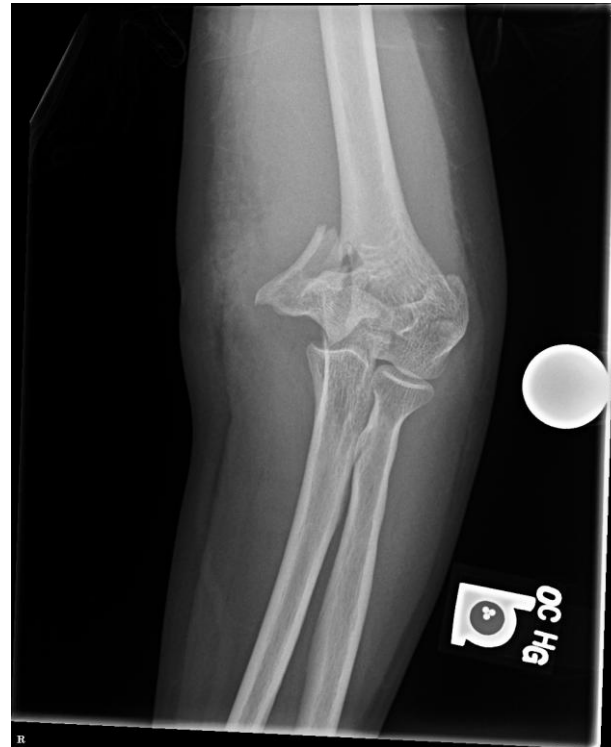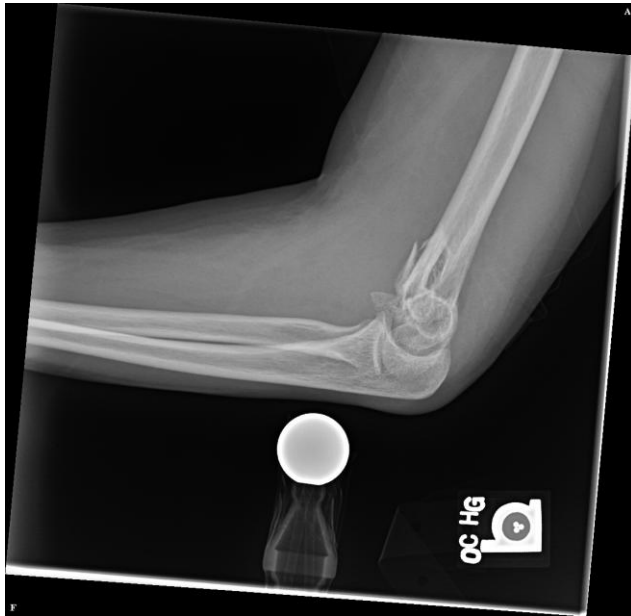## Distal Humerus Fx Assessment

These type of fractures

Extra-articular

Simple


Complex



## Distal Humerus Fx Assessment

Talk about these type of fractures

Complex



All pieces easily reducible

Some bone missing

Some cartilage missing

What cartilage

Is that an elbow?



# McGill

All pieces easily reducible

Some bone missing

Some cartilage missing

What cartilage

Is that an elbow?

## Options for Discussion

**Approaches**

**What to do with the pieces**

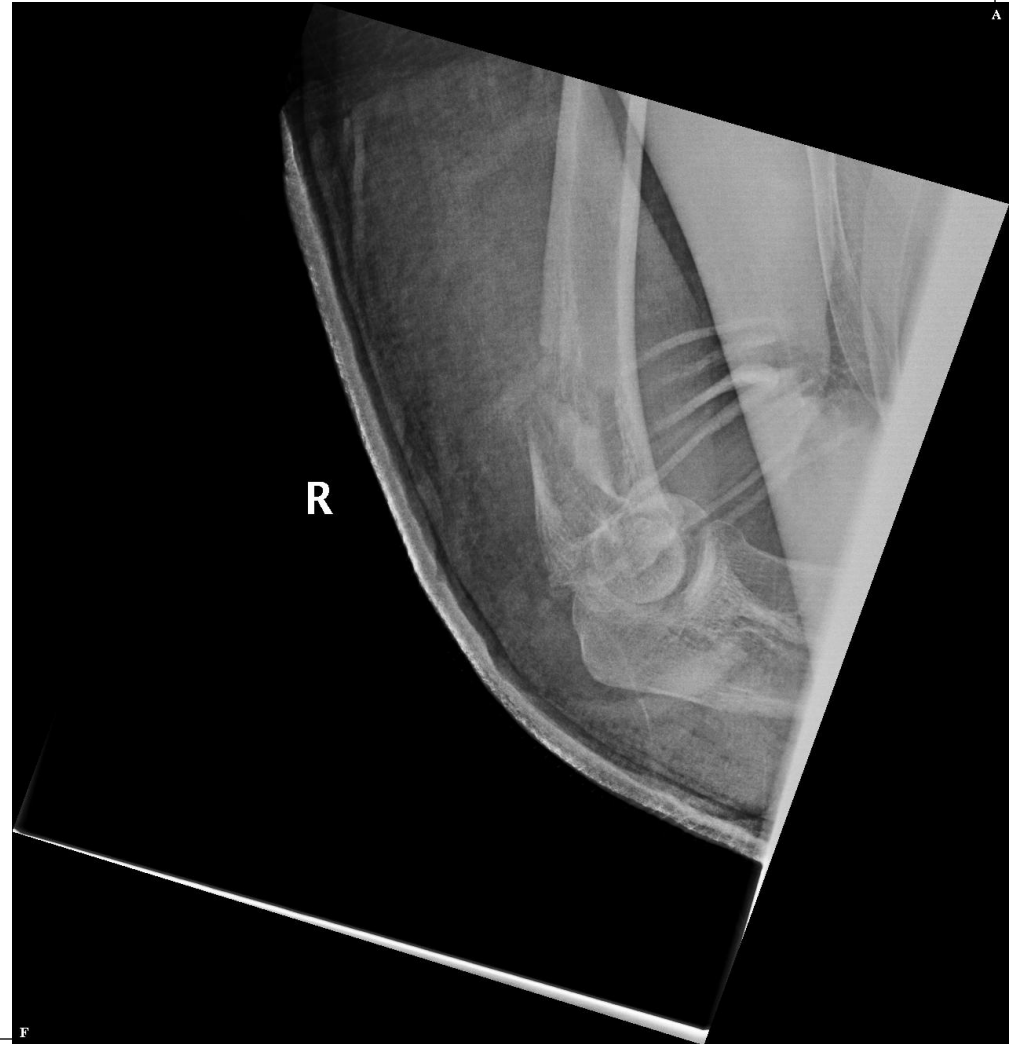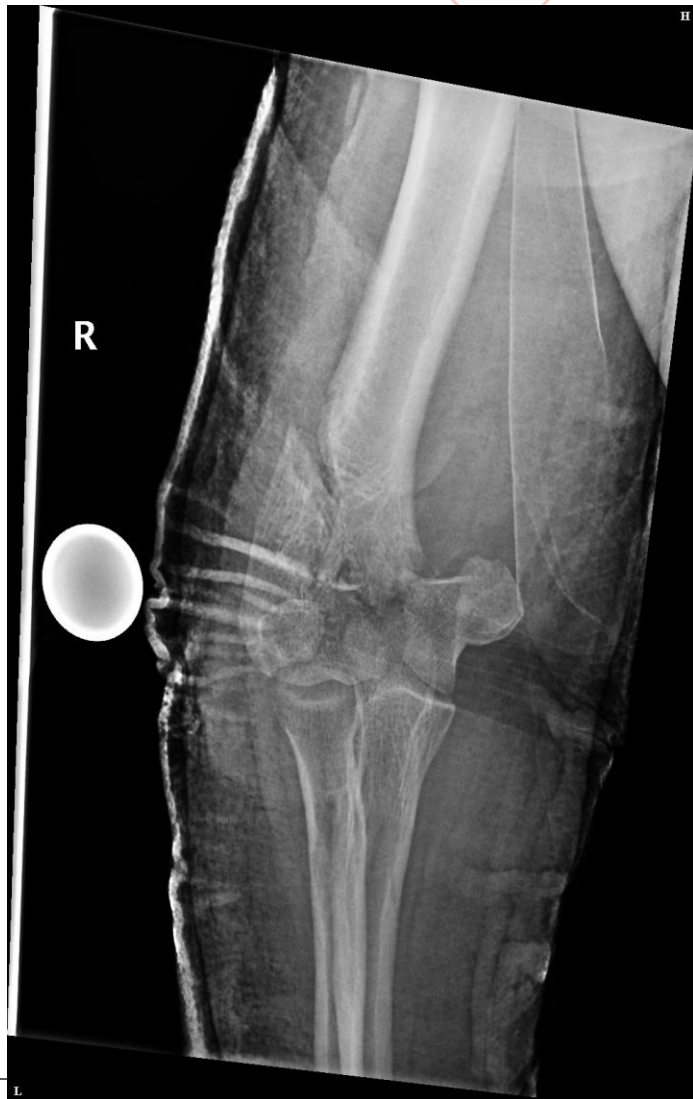**Where to find new pieces**


**What pieces of metal to use**

48 yo male



# McGill





# McGill

All pieces easily reducible

Some bone missing

Some cartilage missing


What cartilage

Is that an elbow?

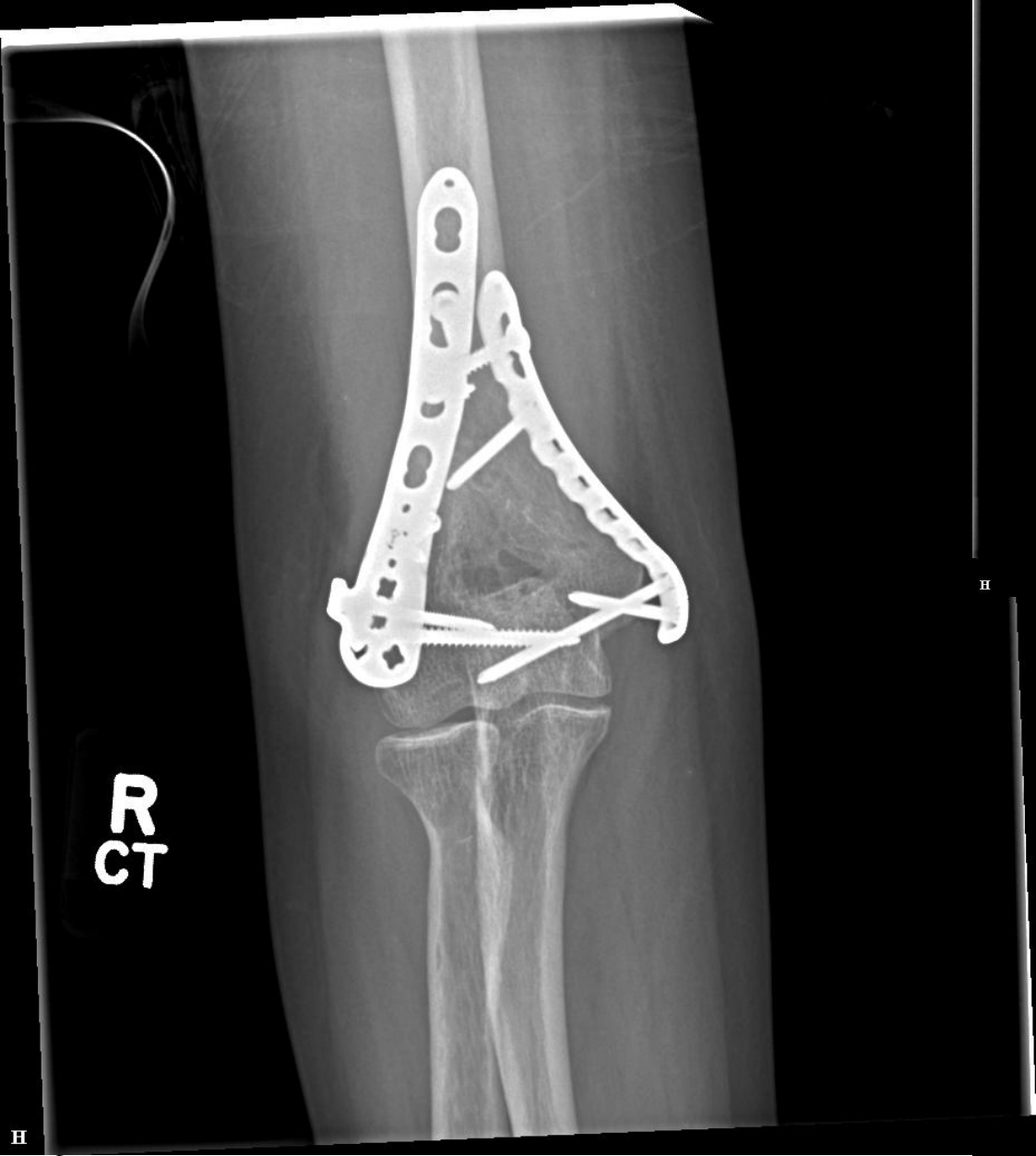## Surgery?

## Approach?

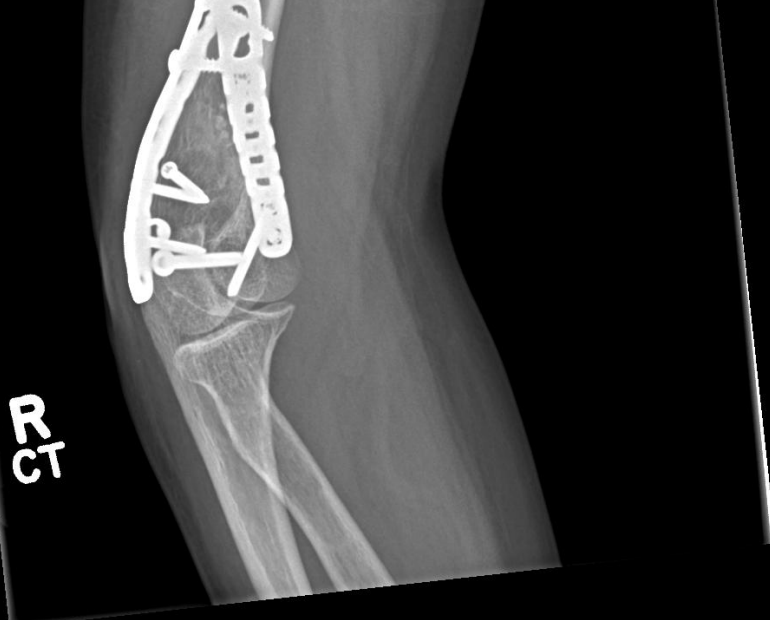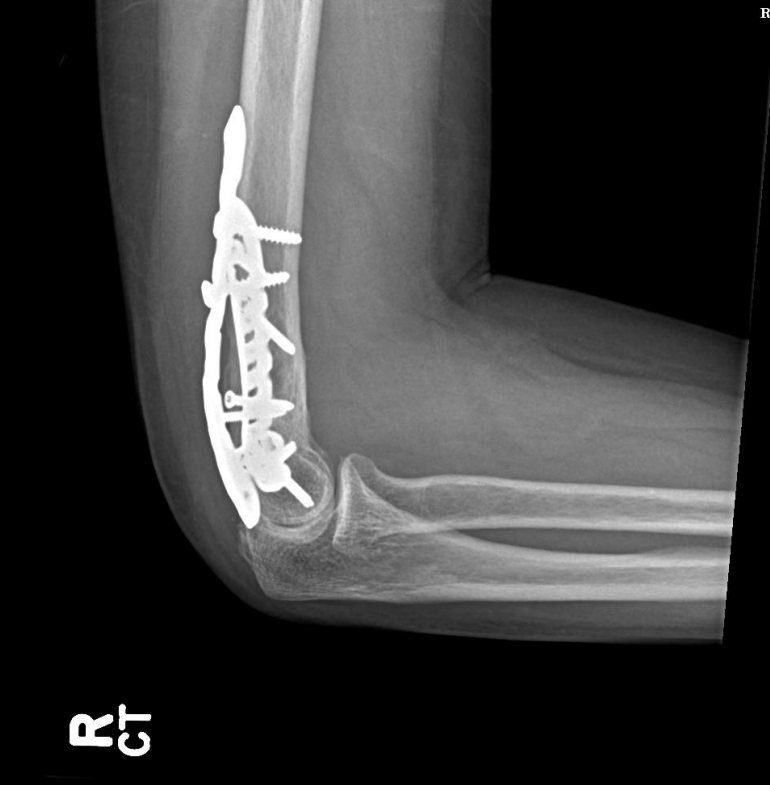## Hardware?



# 8 Year follow up



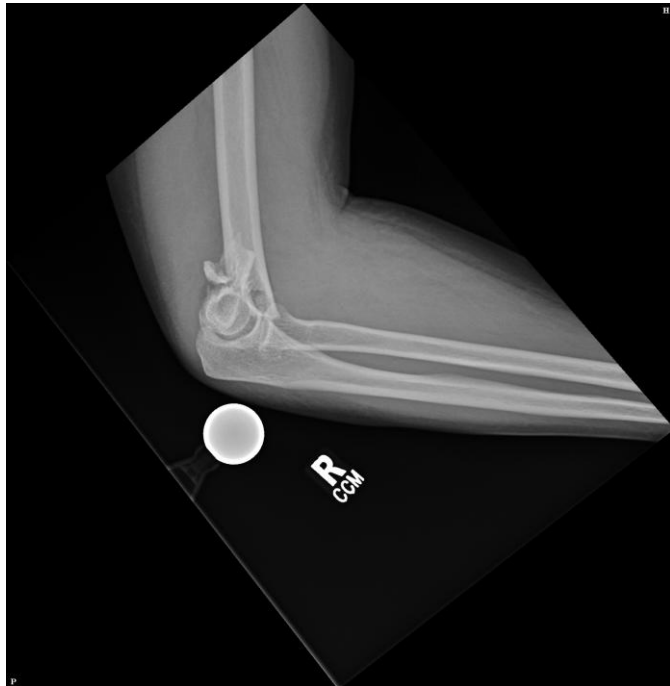
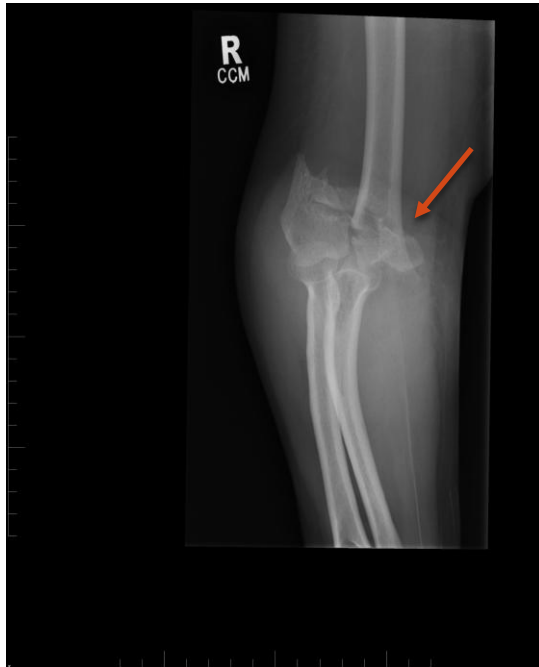H



H

# 40-year-old male

- ✗ Otherwise well
- ✗ 3 pieces some medial column compaction
- ✗ Fall from his own height on stair





# McGill

All pieces easily reducible

Some bone missing

Some cartilage missing


What cartilage

Is that an elbow?

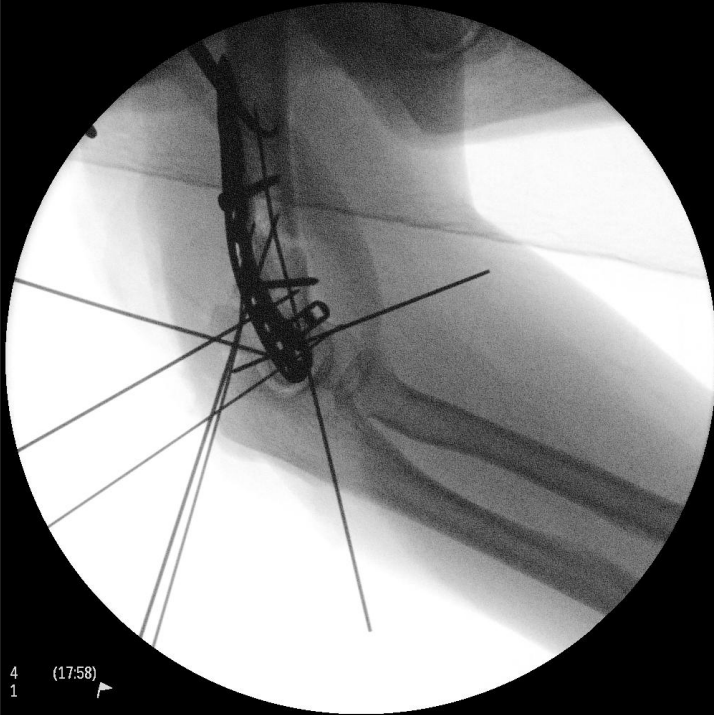## Surgery?

## Approach?

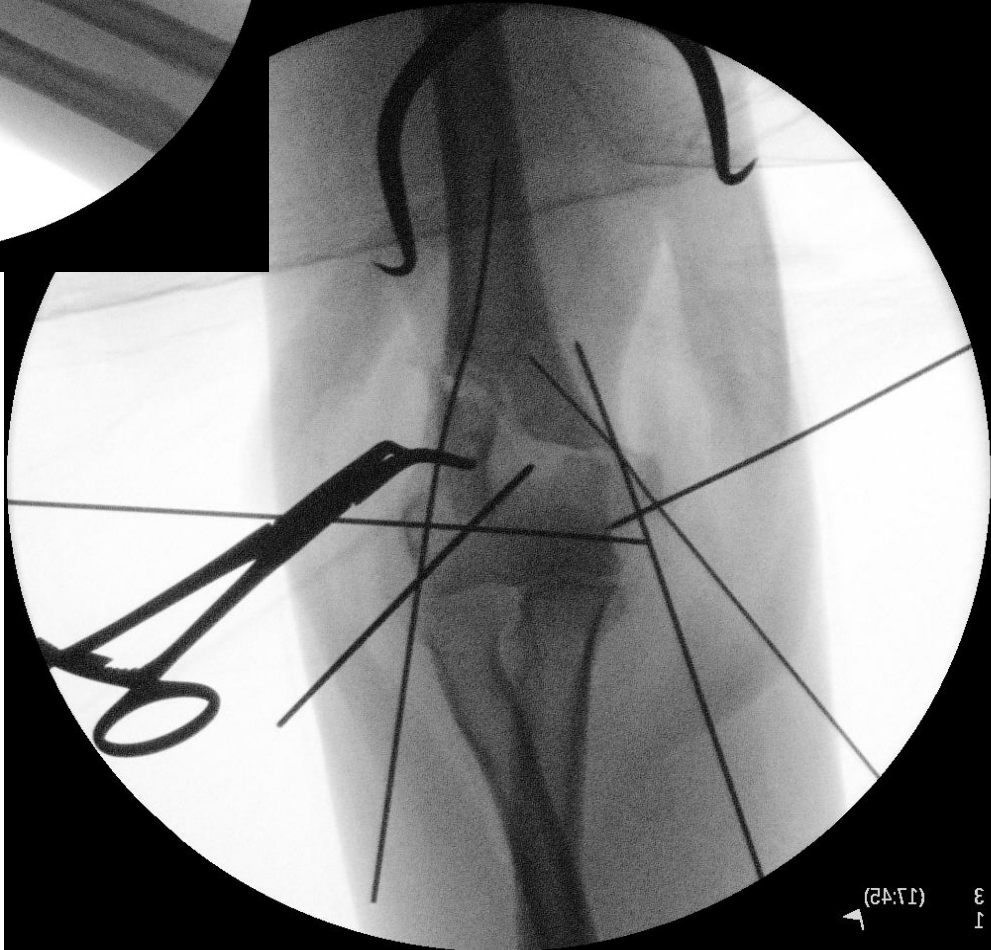
## Hardware?



# McGill

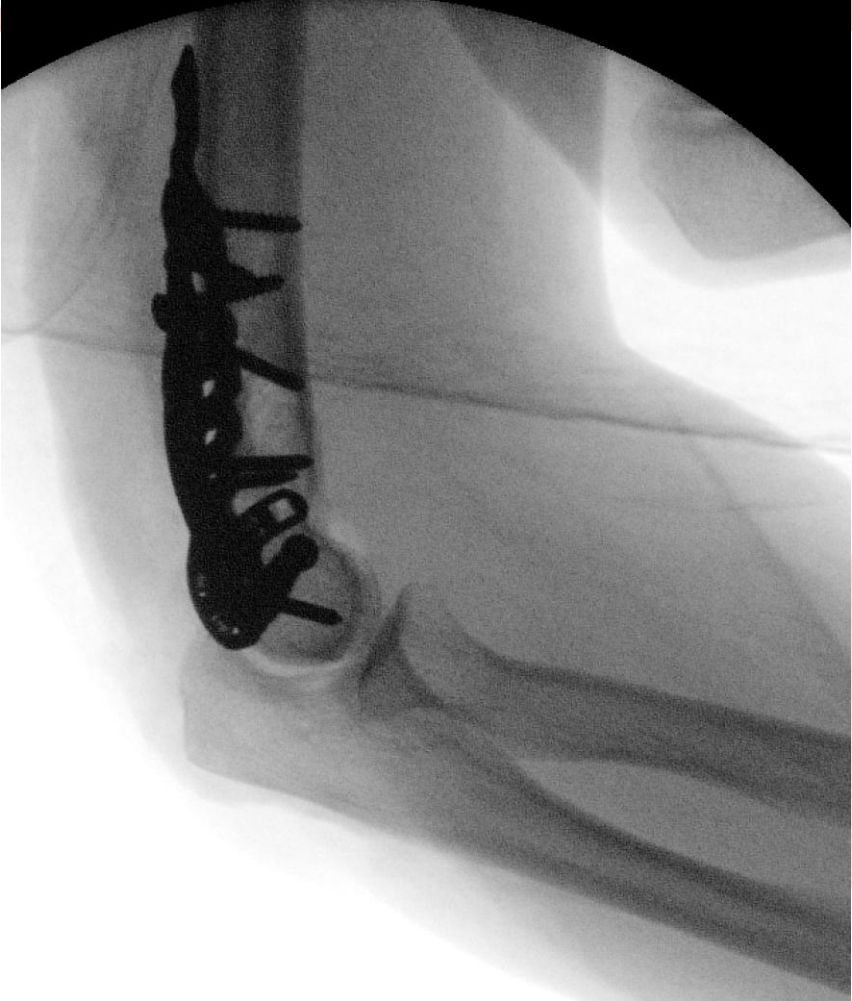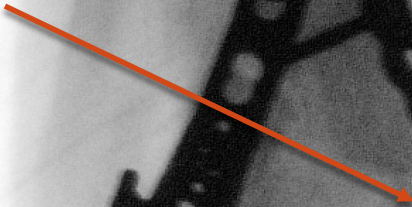


4 (17:58)  
1



3 (17:42)  
1

Bone Bank  
Allograft



# Approach



All pieces easily reducible

Some bone missing

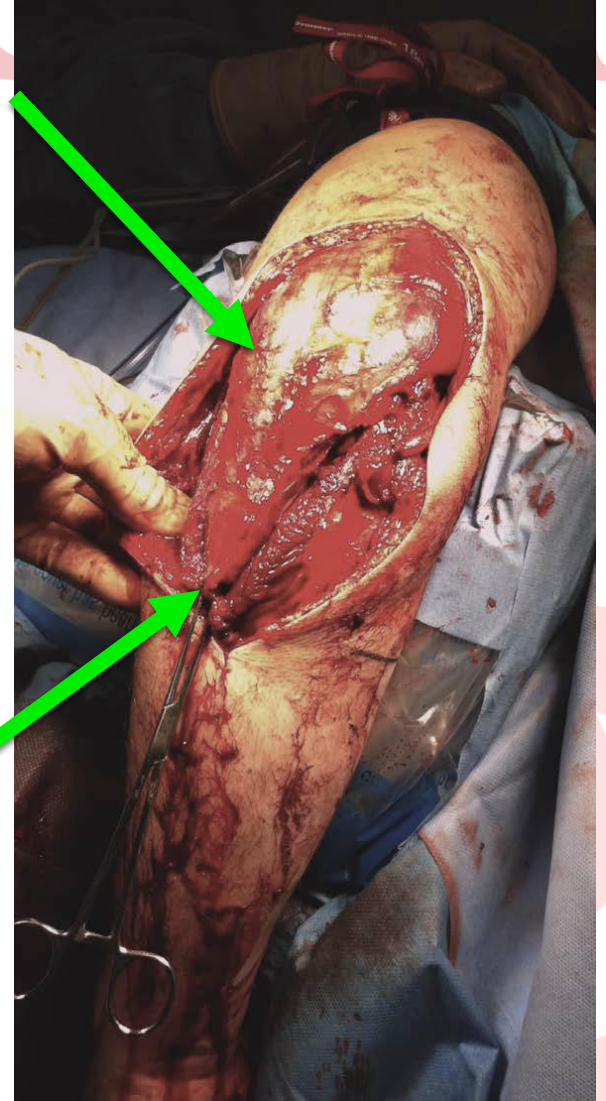
Some cartilage missing

What cartilage

Is that an elbow?

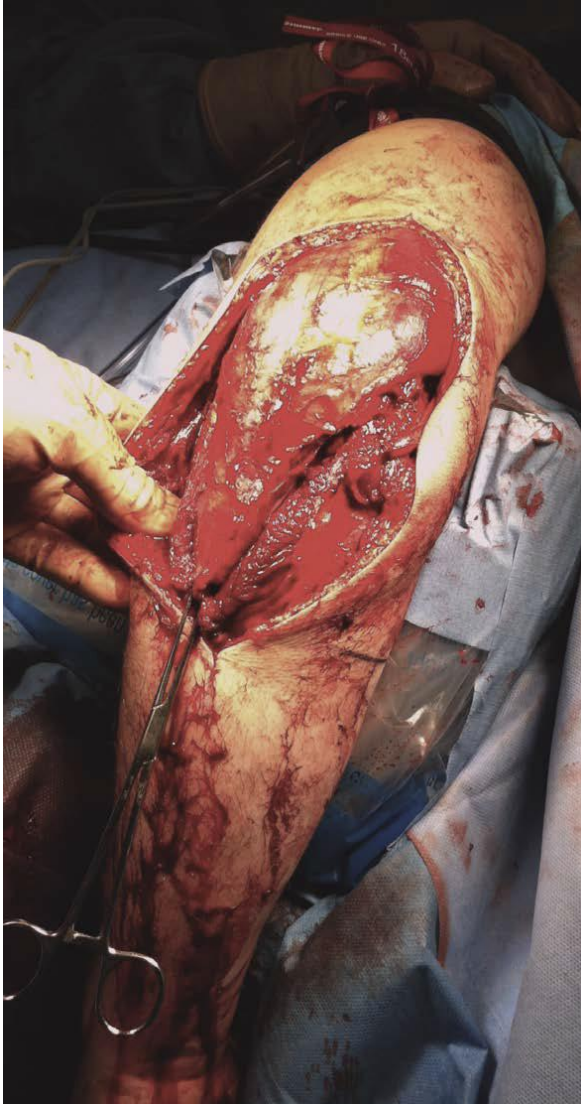
# McGill

## TRAP



# Approaches

# McGill



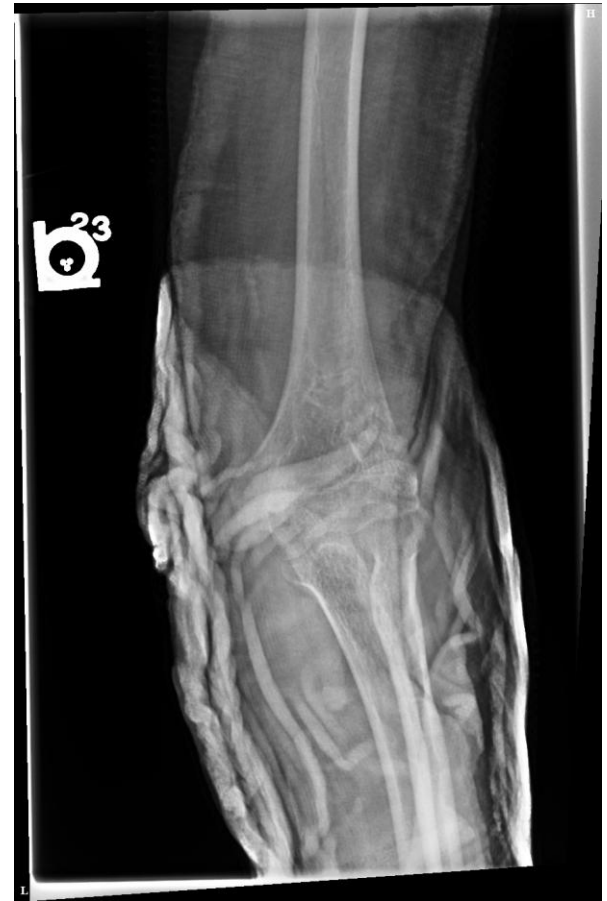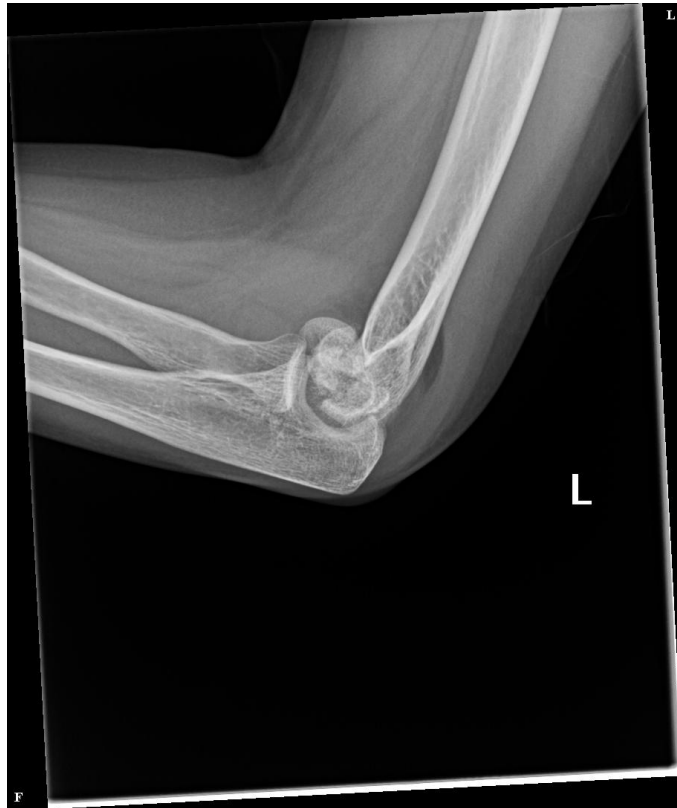## **TRAP Flap (complex cases )**

- Posterior approach
- Flap lifted off ulna to about 15 cm distal to joint
- Preserve triceps to anconeus NV Bundle
- Preserve MCL and LCL
- Repaired through 3 ulna holes with FibreWire

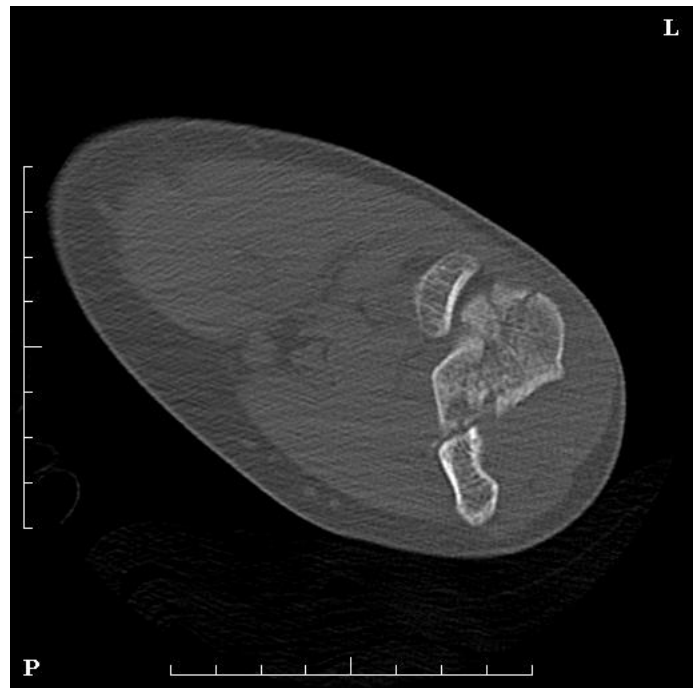
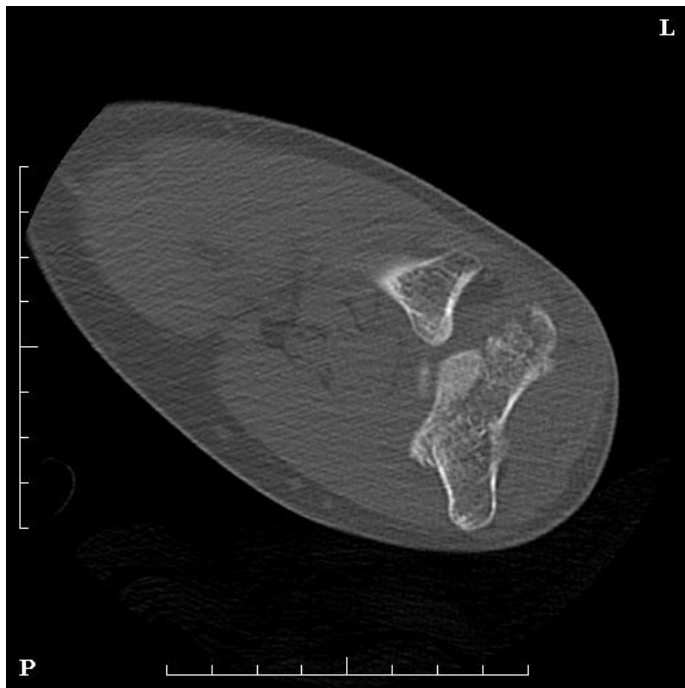
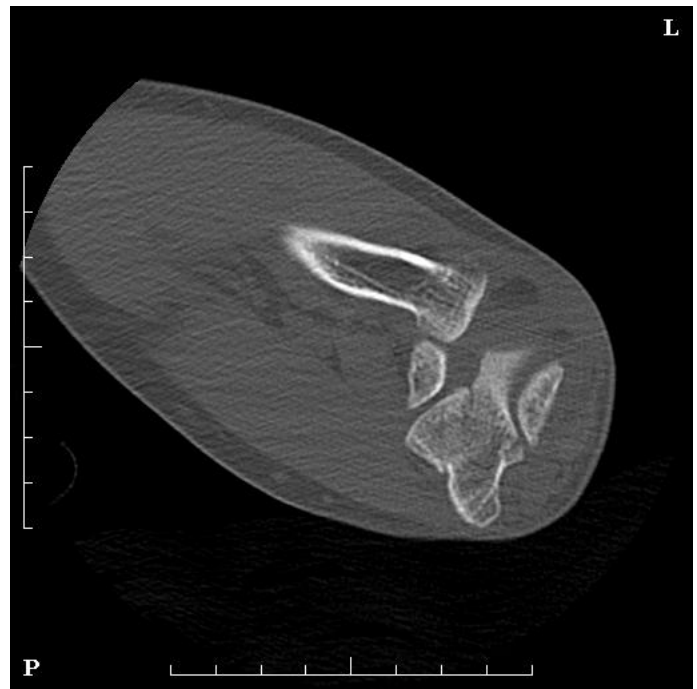# 60 yo female

✗ Closed fracture low energy

✗ Neuro intact



CT



//



# McGill

## **Surgery?**

All pieces easily reducible

Some bone missing??


Some cartilage fractured

What cartilage

Is that an elbow?

## **Approach?**

## **Hardware?**





# McGill

Surgery?

Approach?

Hardware?

**Just need to see the joint completely**

//

All pieces easily reducible

Some bone missing??

Some cartilage fractured

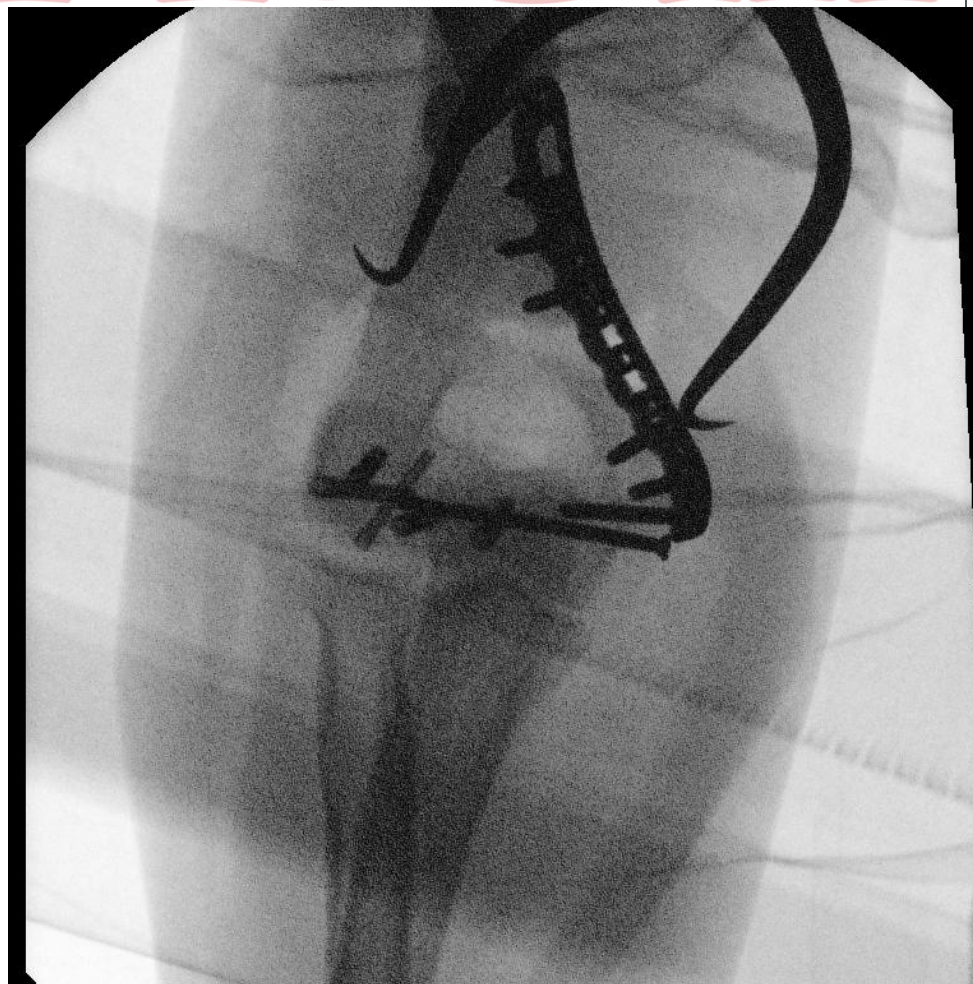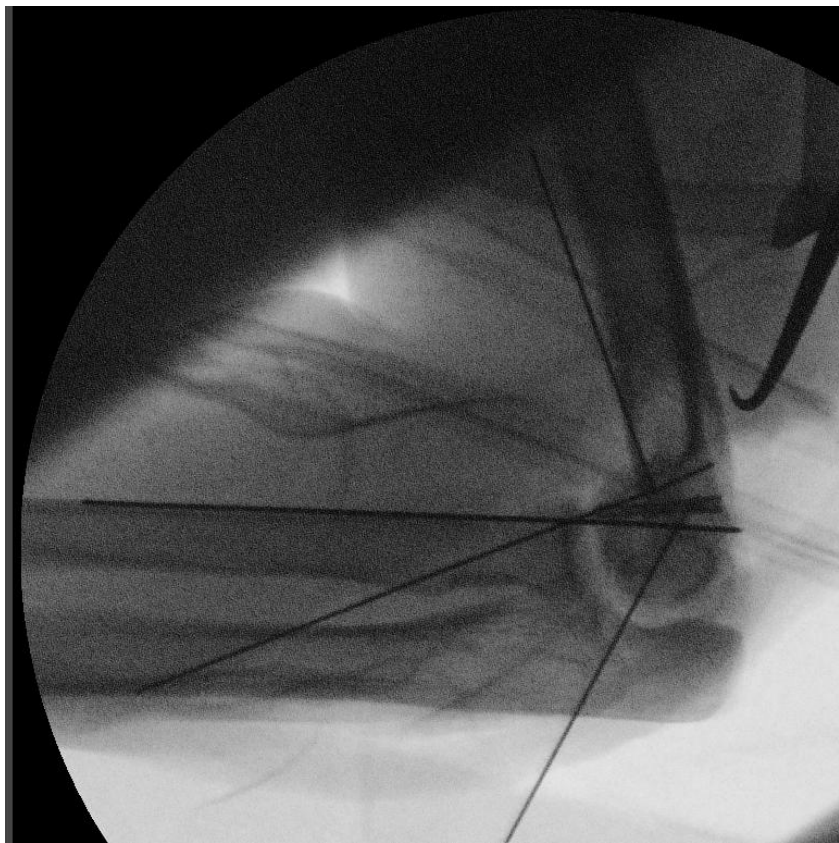
What cartilage

Is that an elbow?

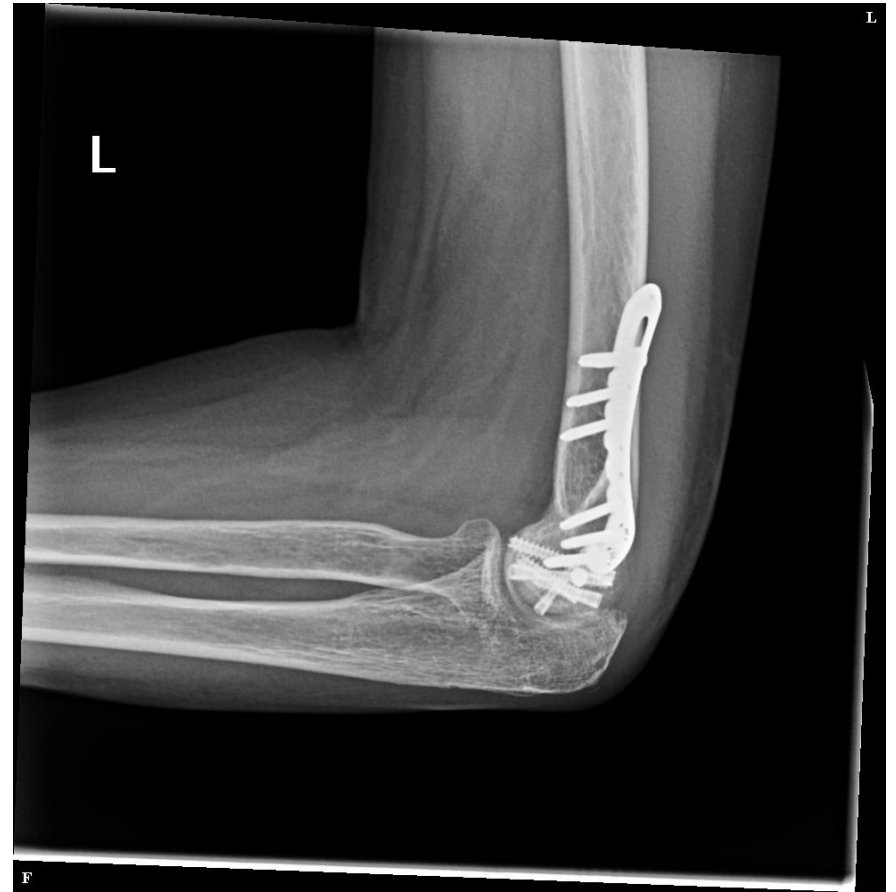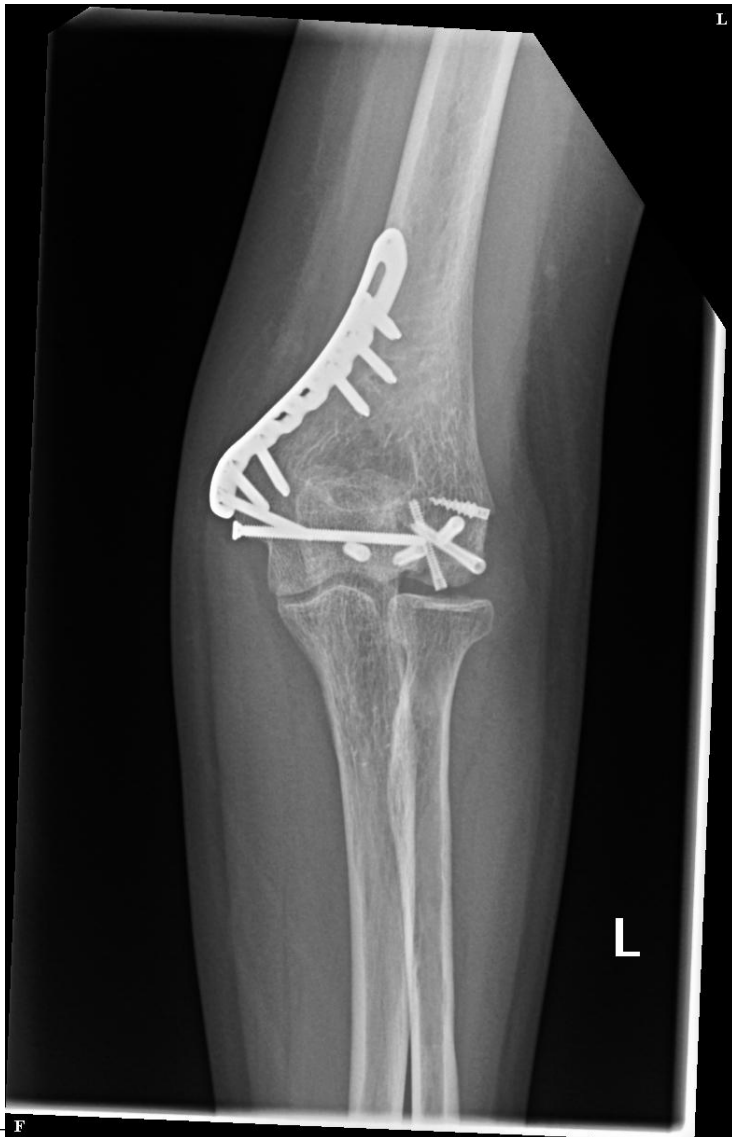Surgery



# McGill

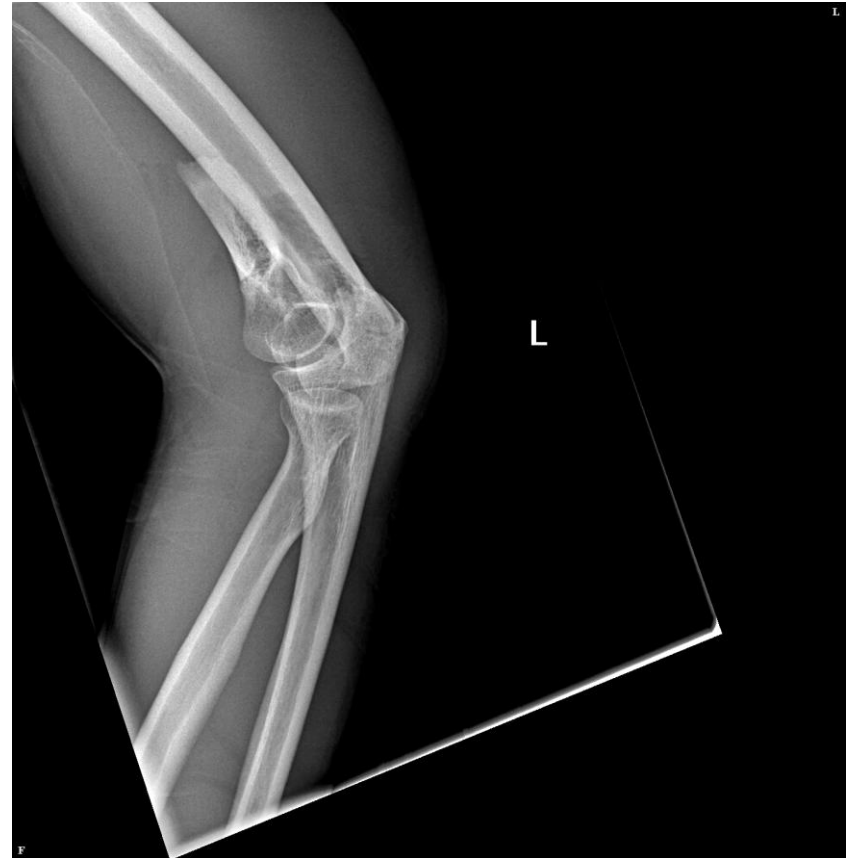
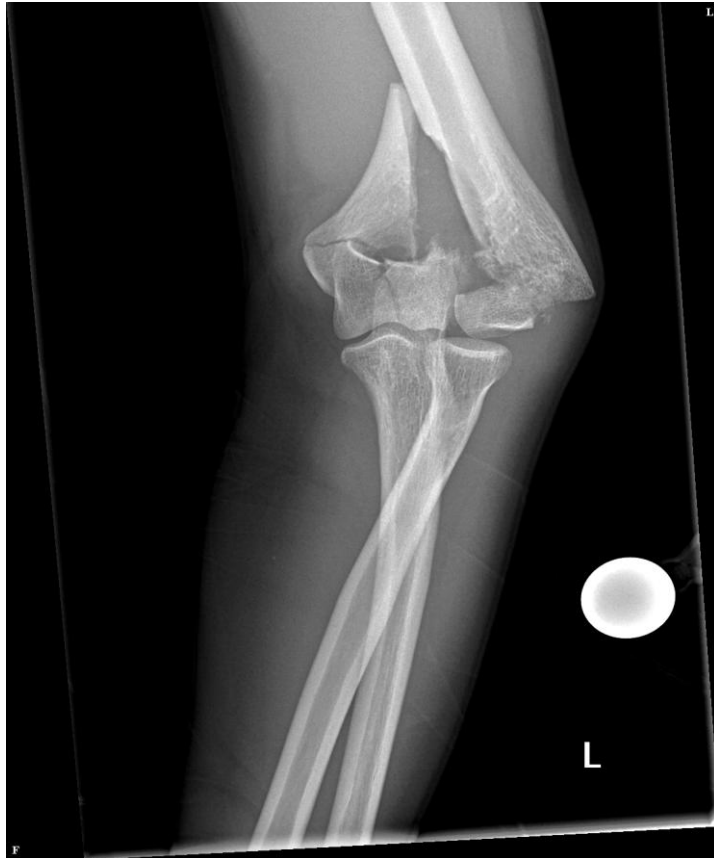
# 3-year follow up

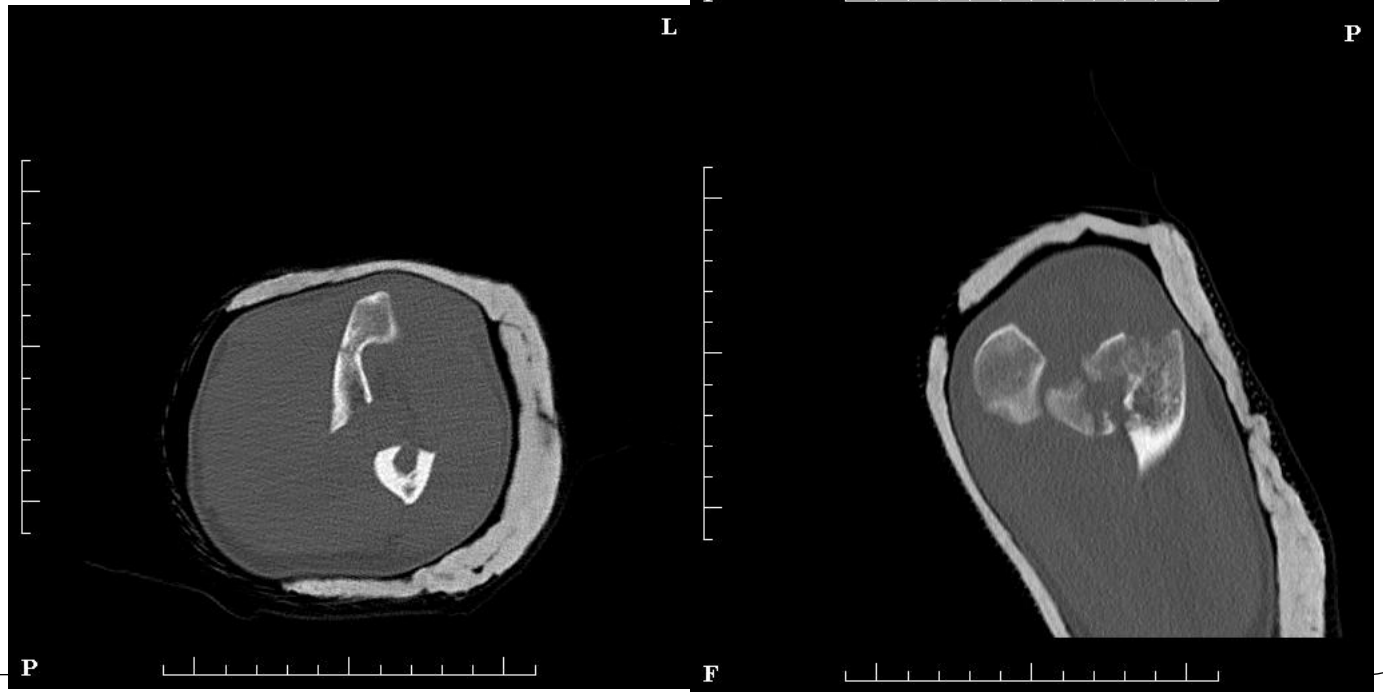
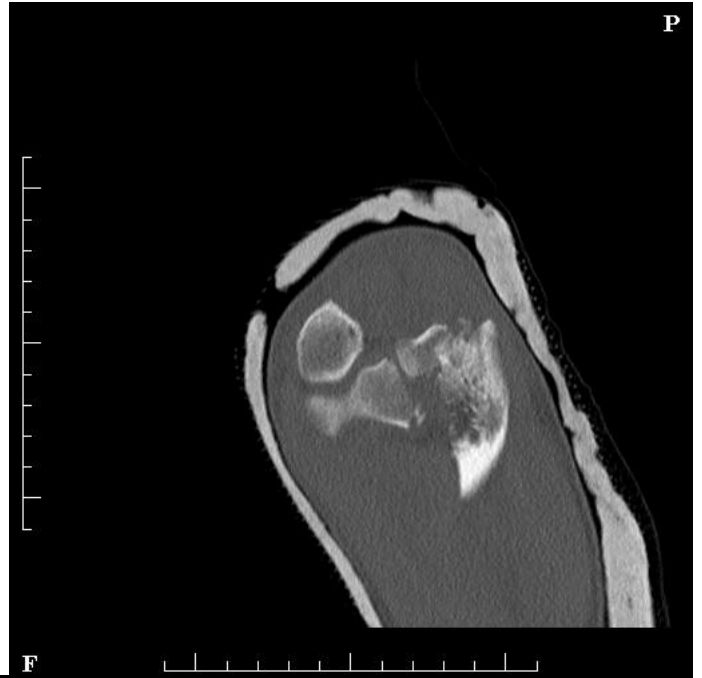

# Young male MCA closed elbow

✗ Neuro intact



CT



# Examples



# McGill

All pieces easily reducible

Some bone missing

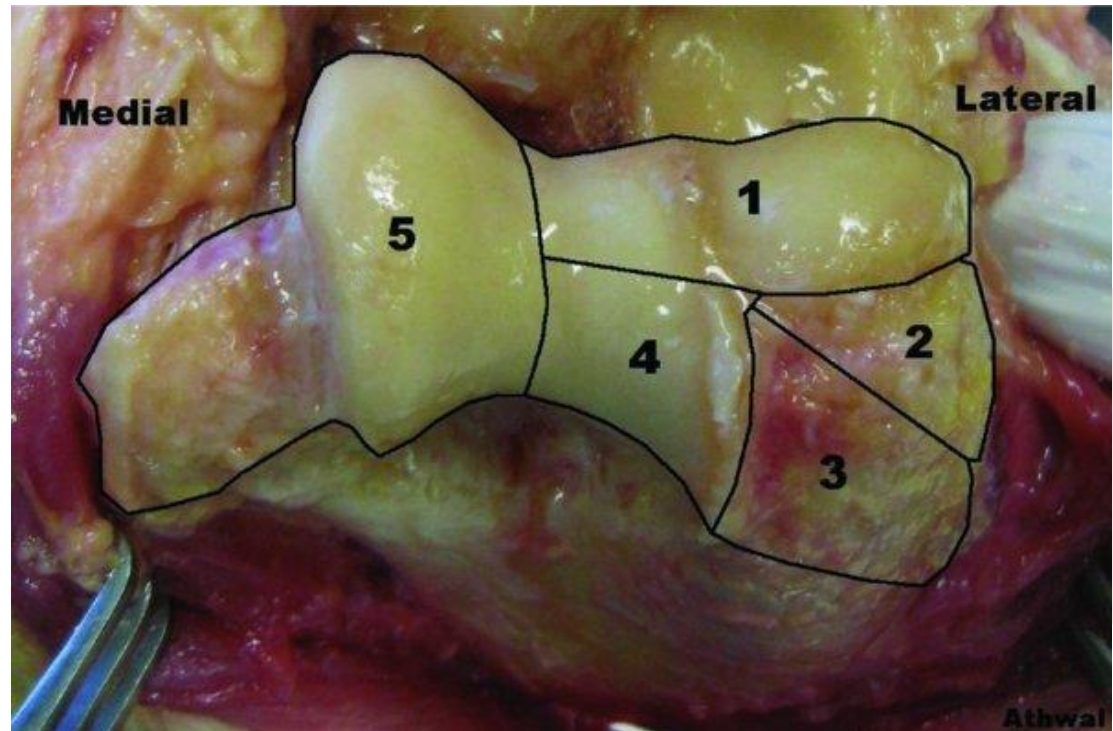
Some cartilage missing

What cartilage

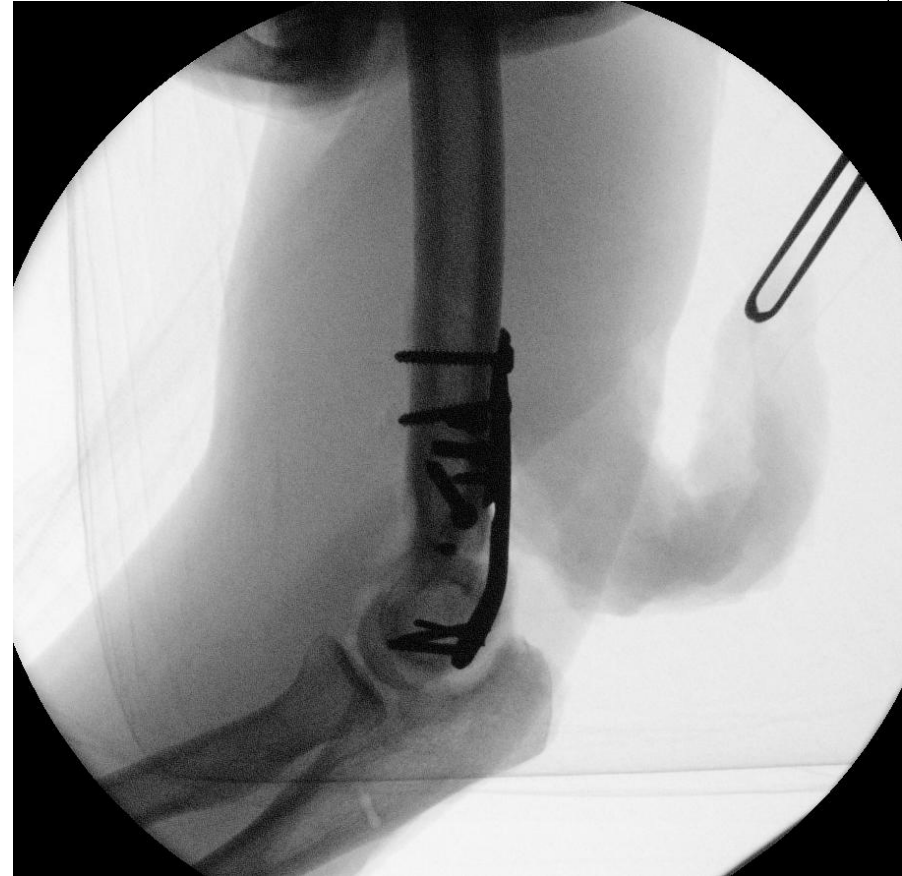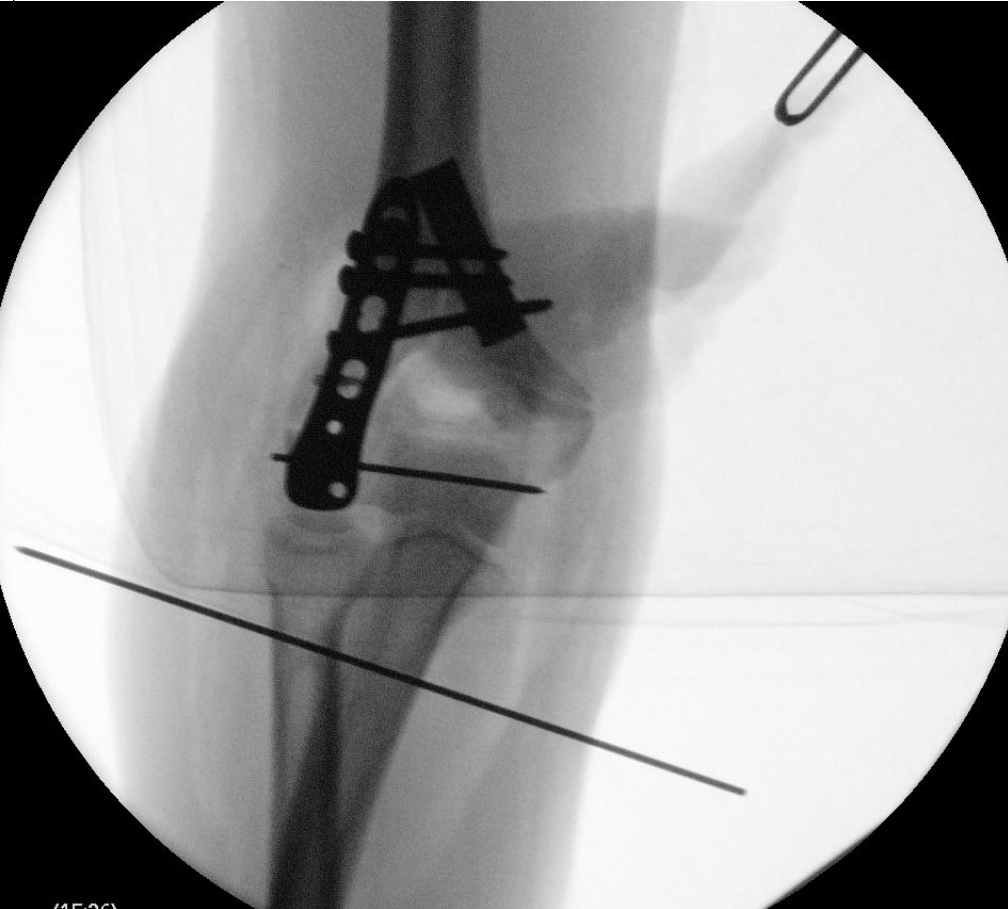Is that an elbow?

Realize where it is missing from

Ring Classification



OR



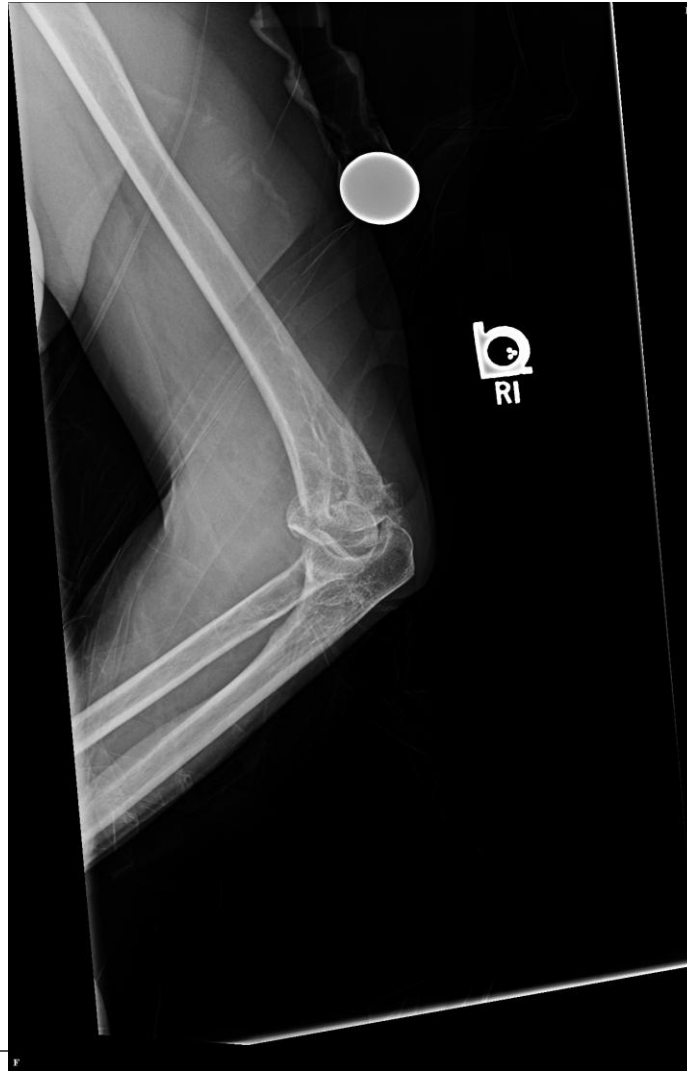
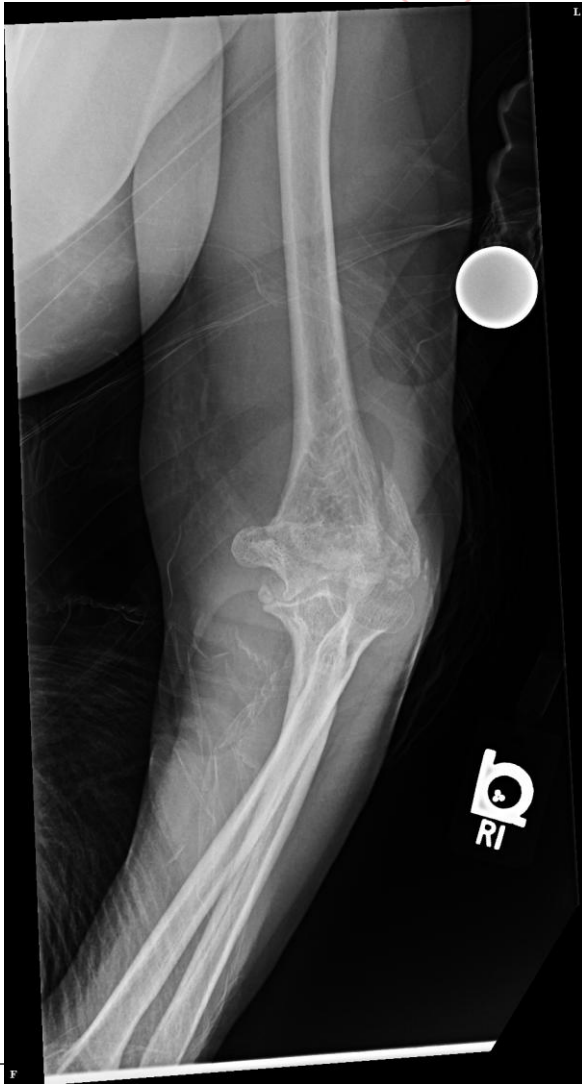# Maybe you hate those xrays

- × Interpretation of Post-operative Distal Humerus Radiographs After Internal Fixation: Prediction of Later Loss of Fixation. Femke et al. J Hand Surg Am. 2016 Oct;41(10):e337-e341
- × Doesn't matter if you hate it
- × If it moves in OR and is stable seems to make it through

45 yo male



McGill





# McGill

All pieces easily reducible

Some bone missing

Some cartilage missing


What cartilage

Is that an elbow?

## Surgery?

## Approach?

## Hardware?





# McGill

All pieces easily reducible


Some bone missing??

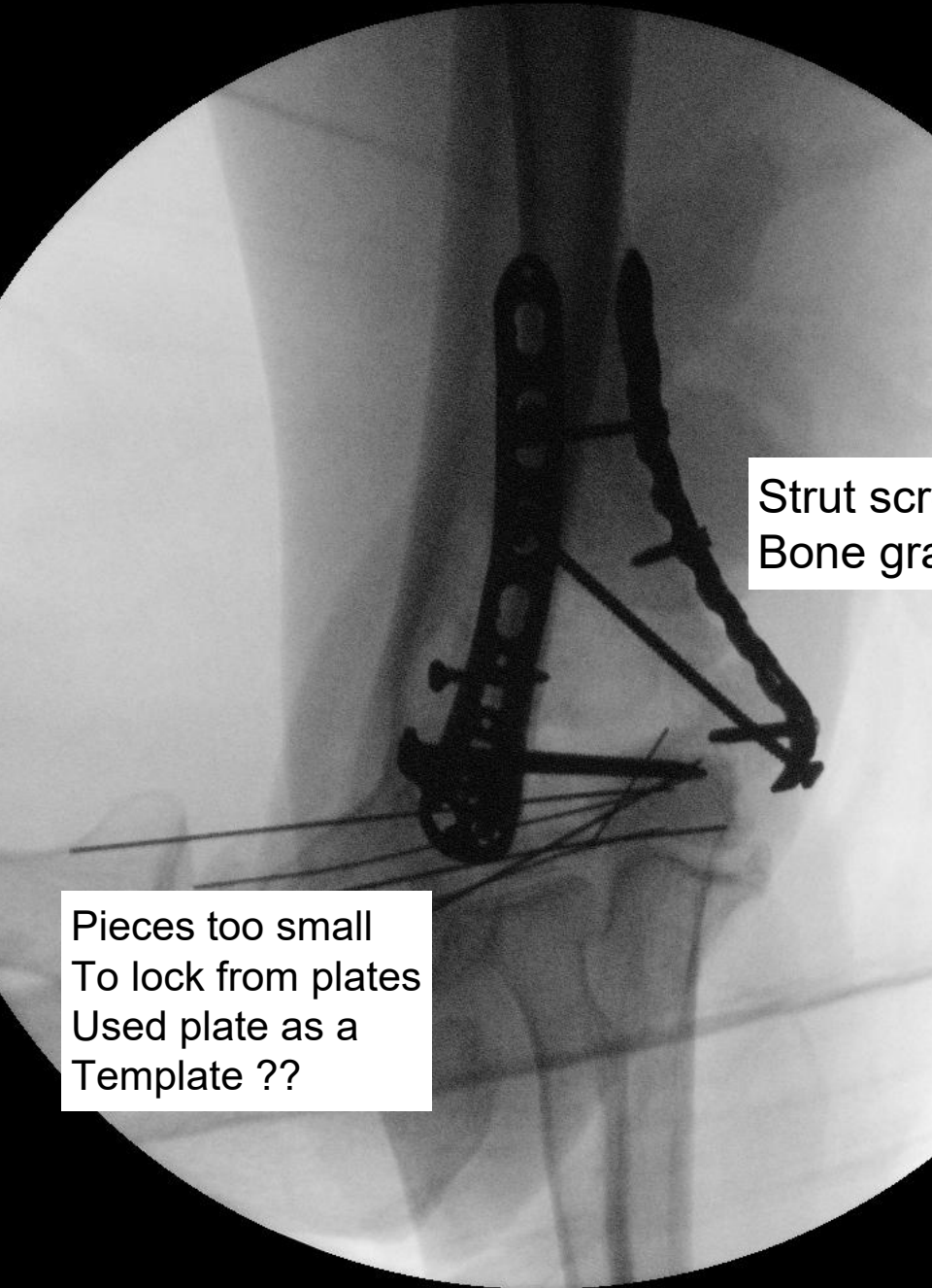
Some cartilage fractured

What cartilage

Is that an elbow?

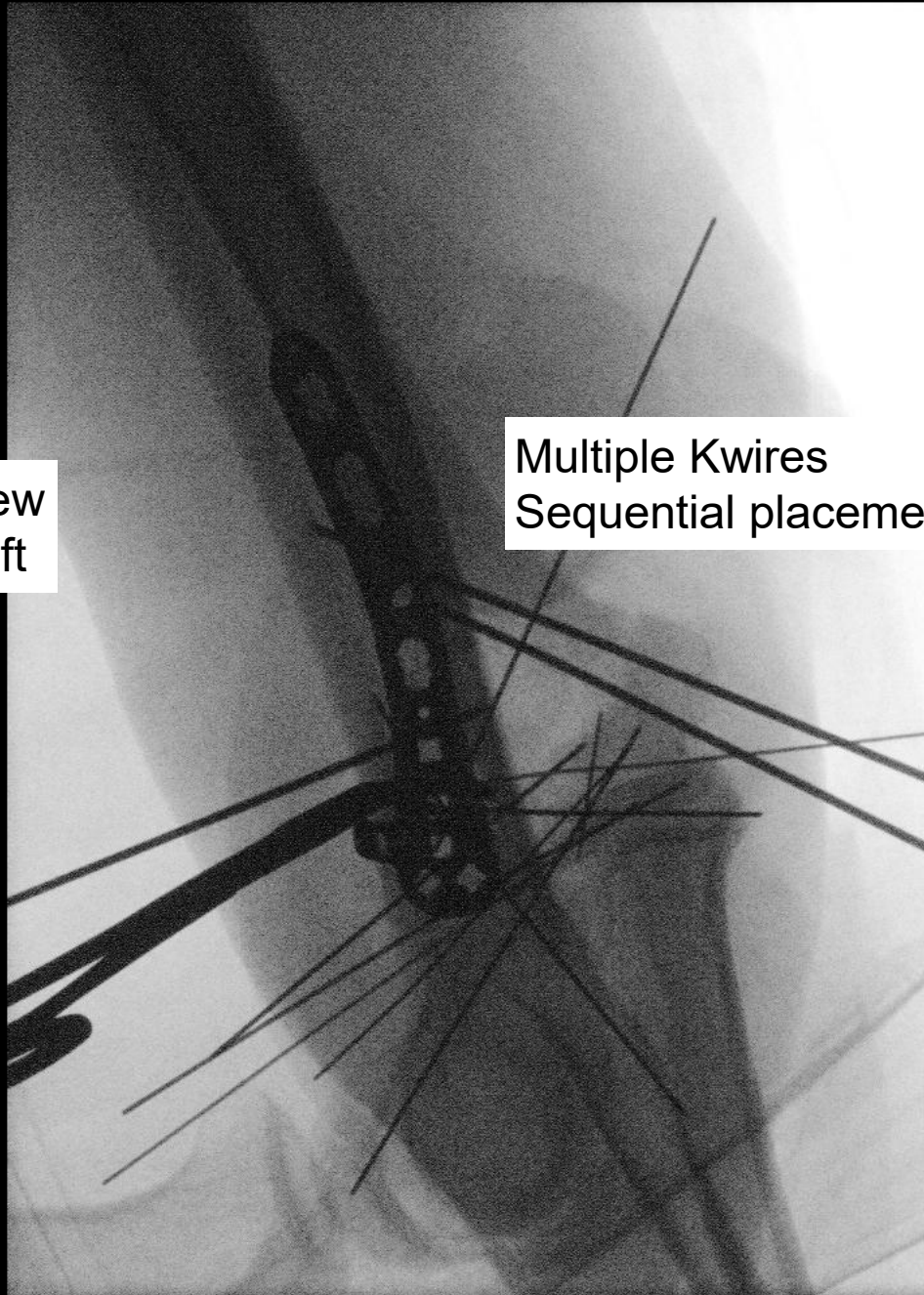
**Just needed to see  
the joint completely**





Strut screw  
Bone graft

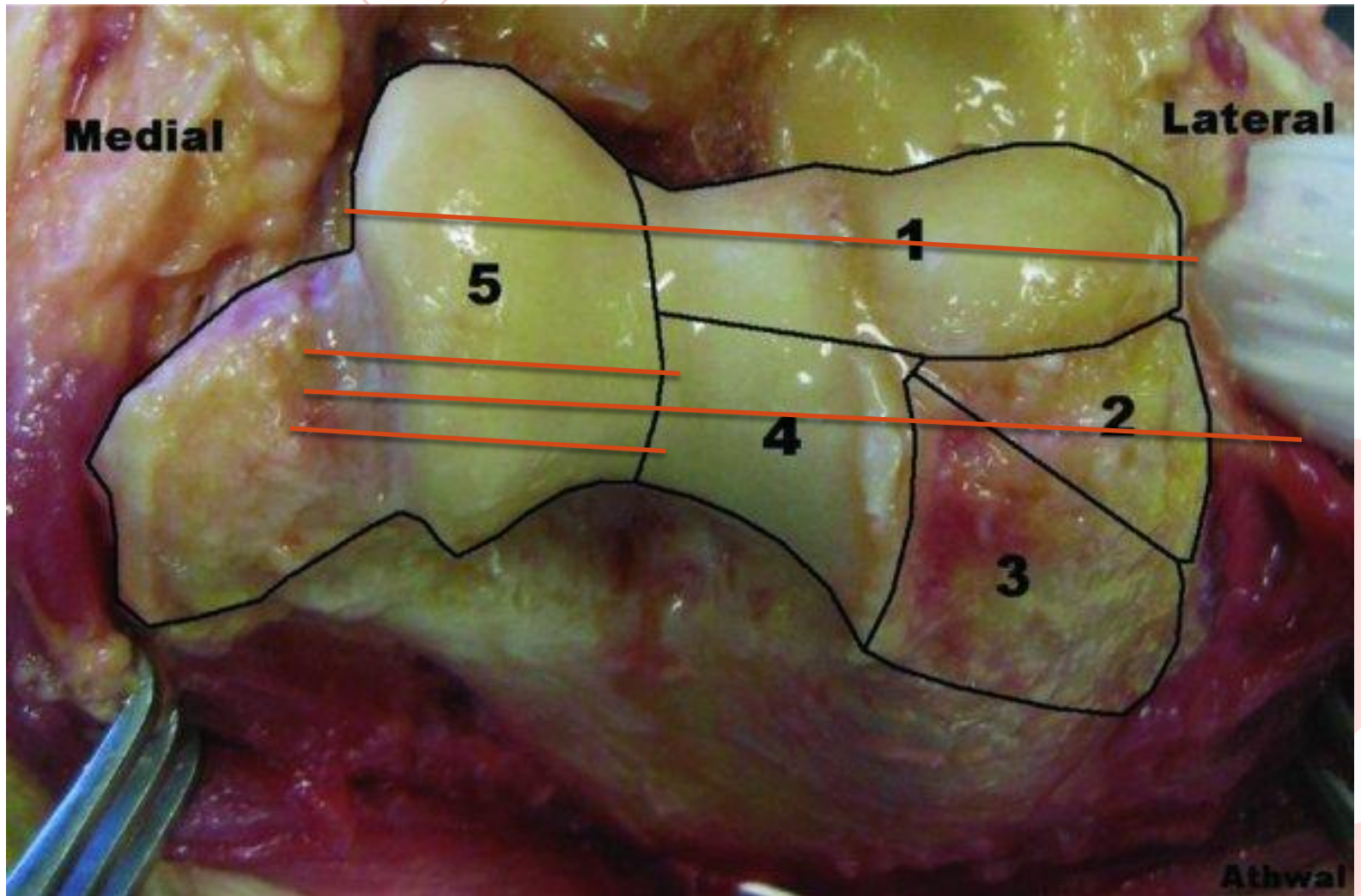
Pieces too small  
To lock from plates  
Used plate as a  
Template ??



Multiple Kwires  
Sequential placeme

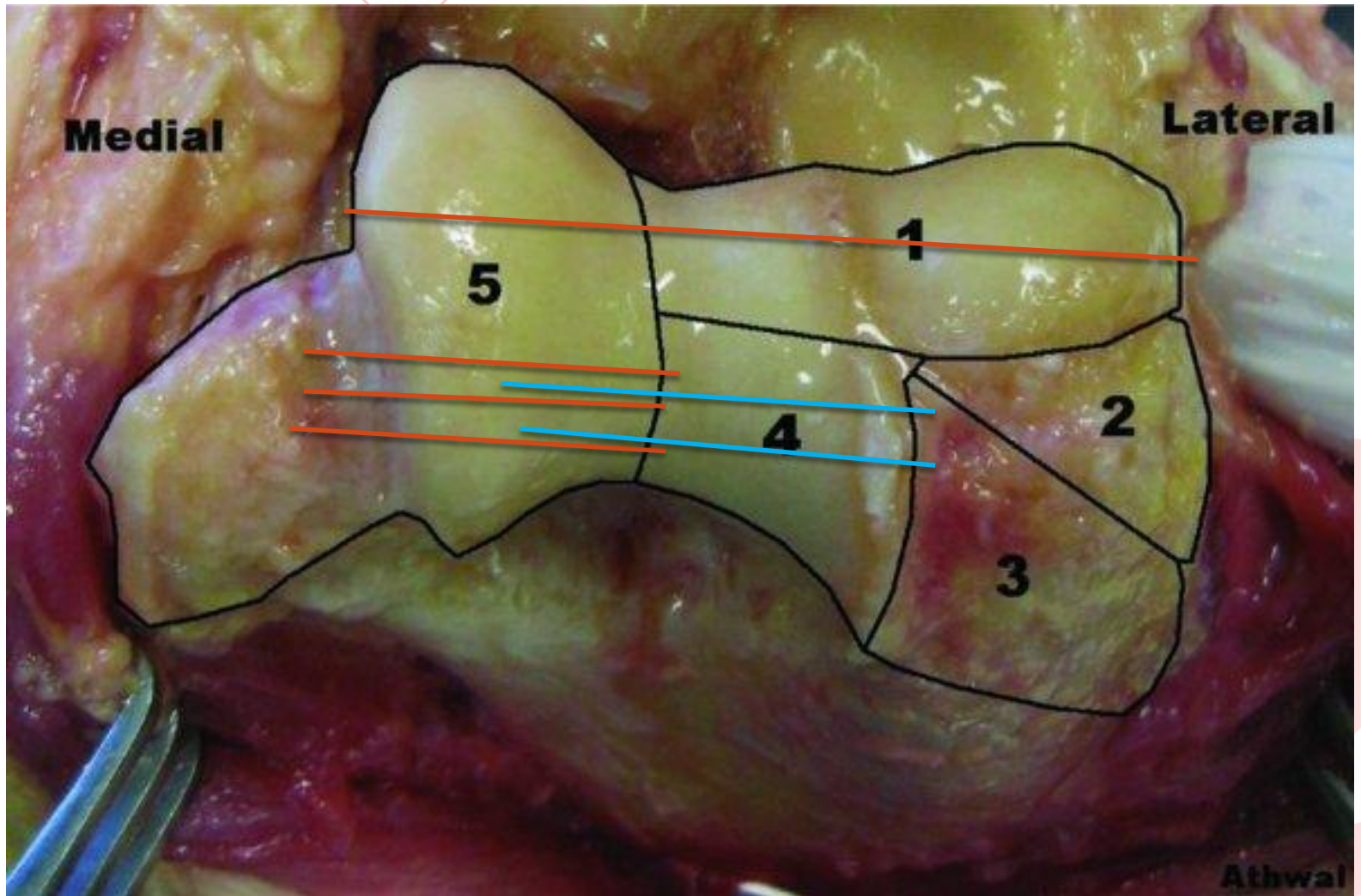


## Small K-wire Usage





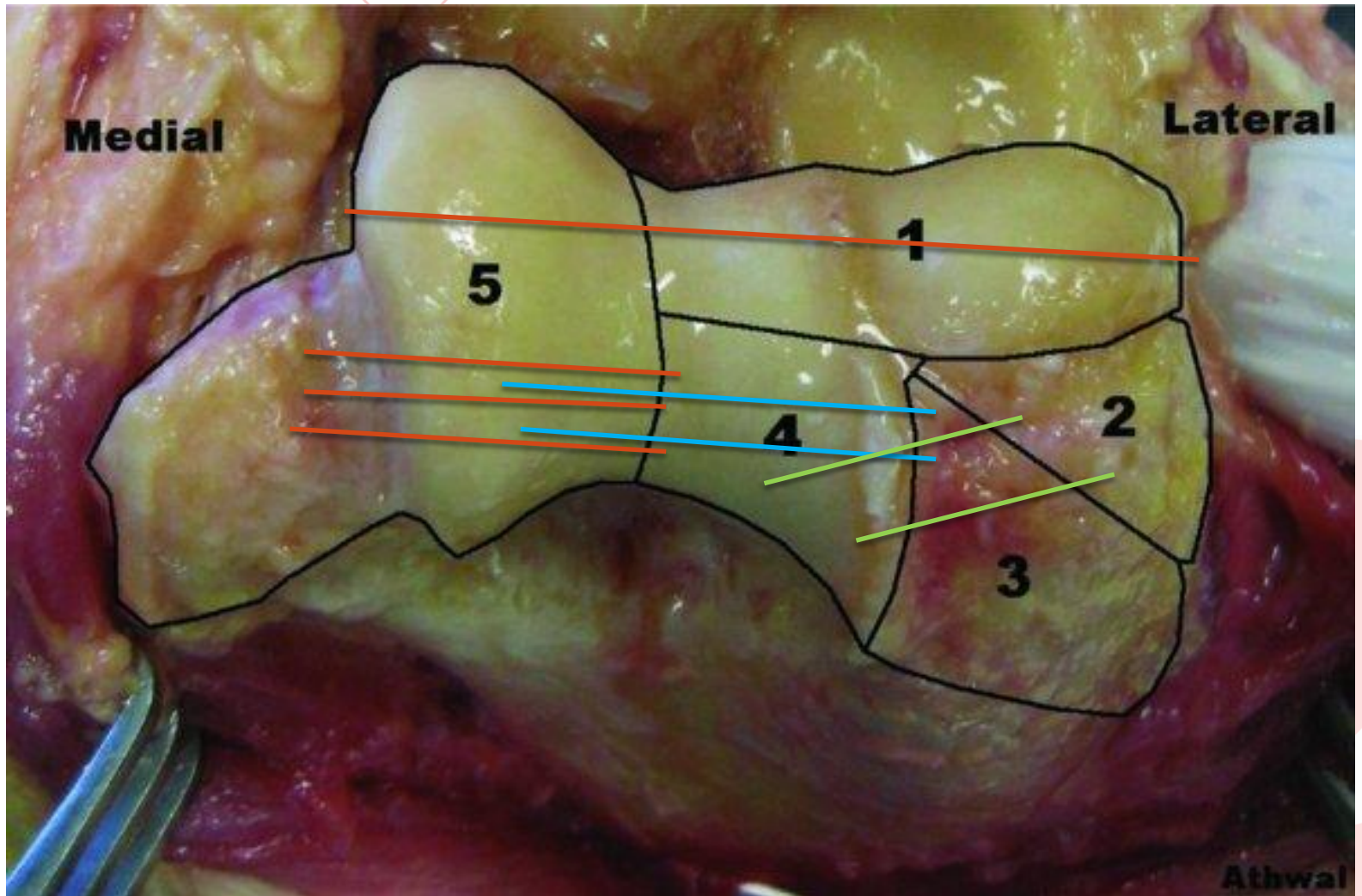
## Small Kwire Usage



# Small Kwire Usage



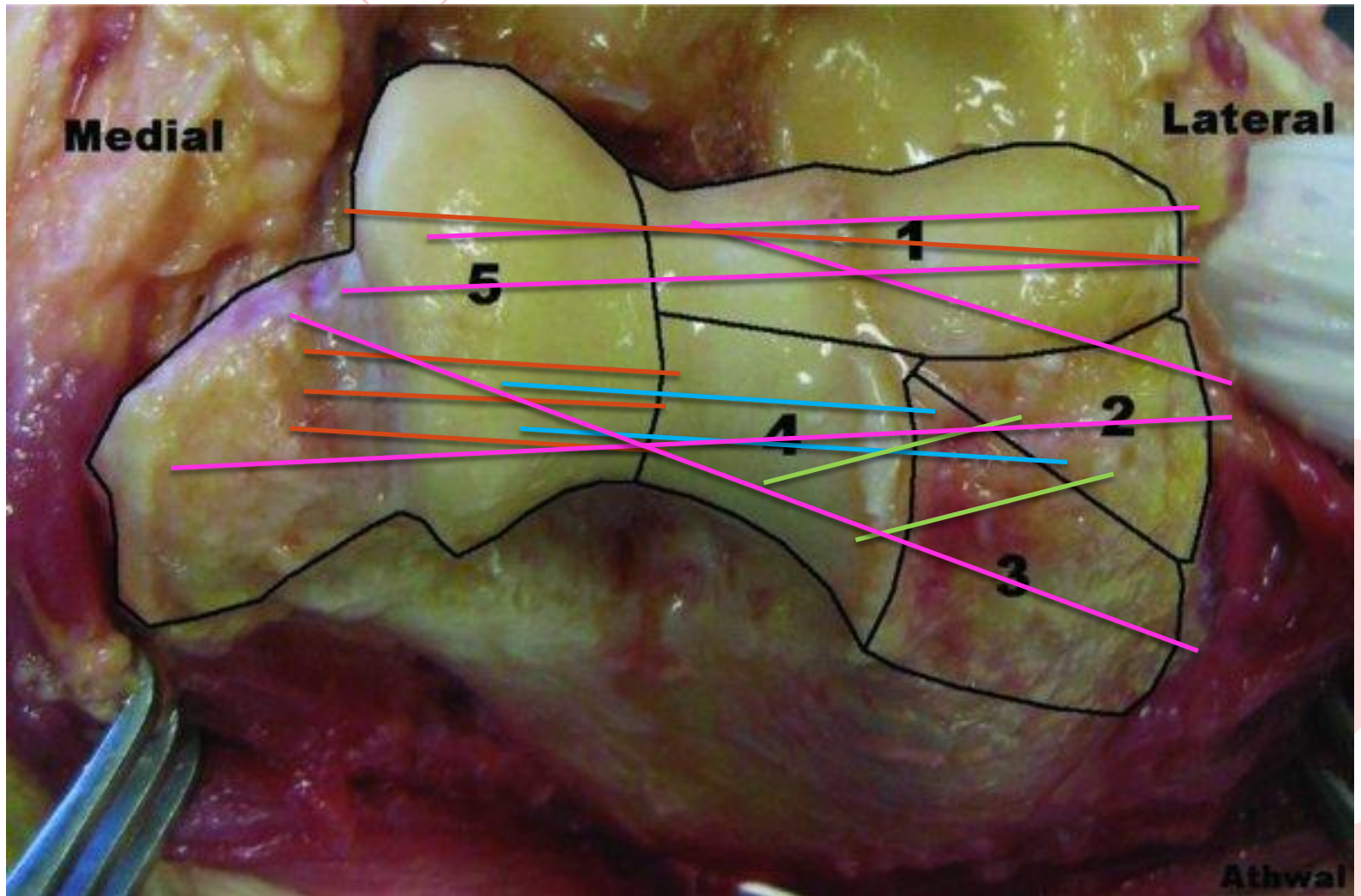
# McGill




# Small Kwire Usage



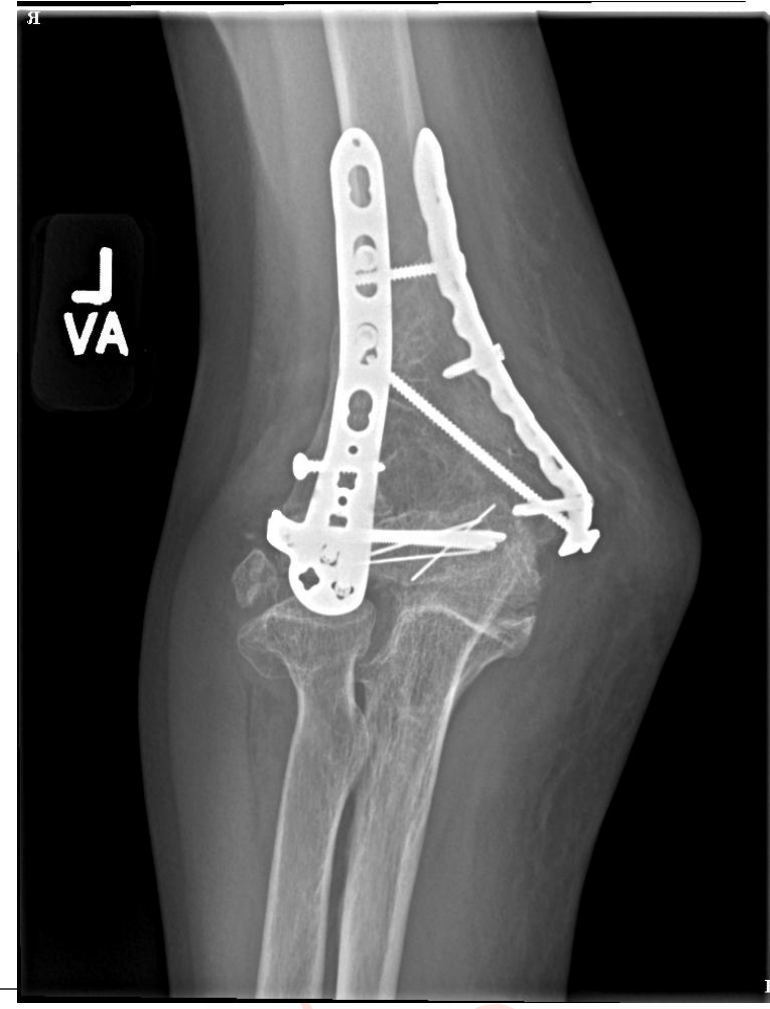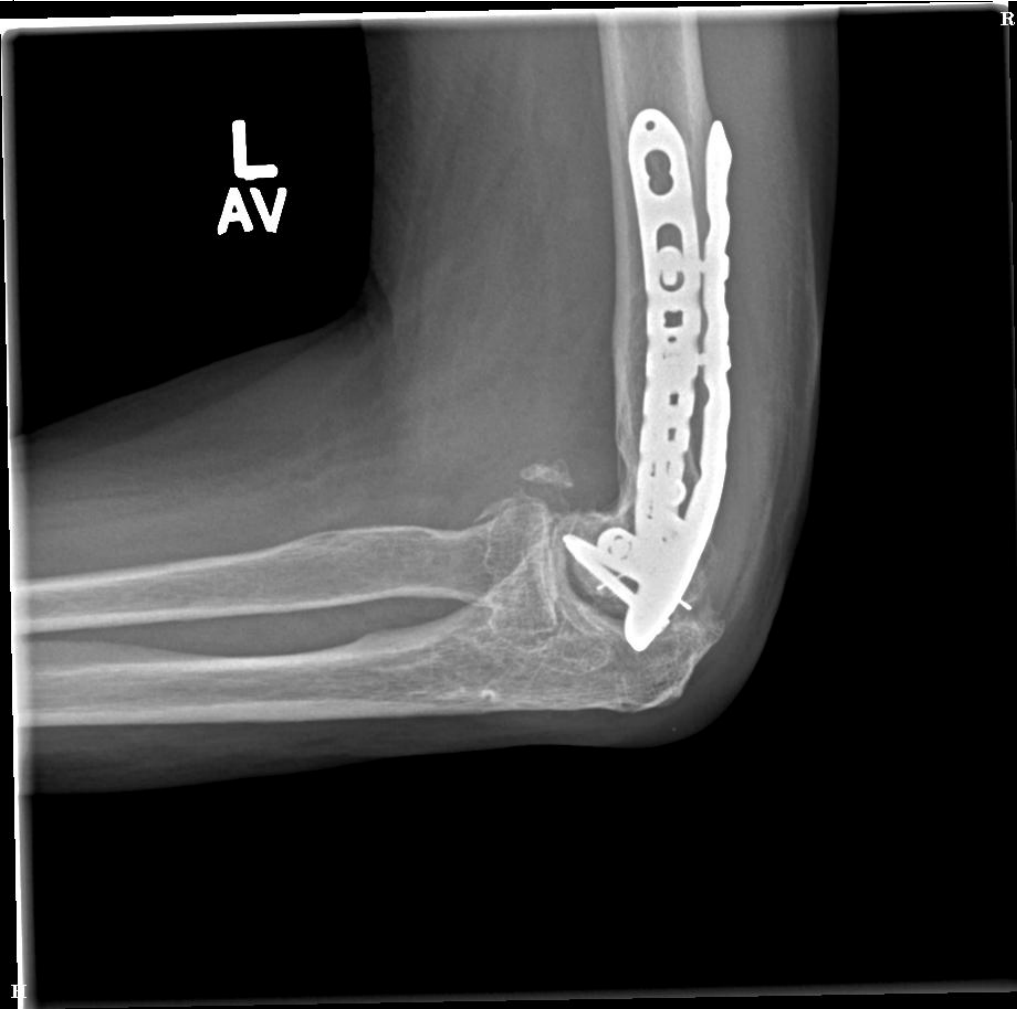# McGill





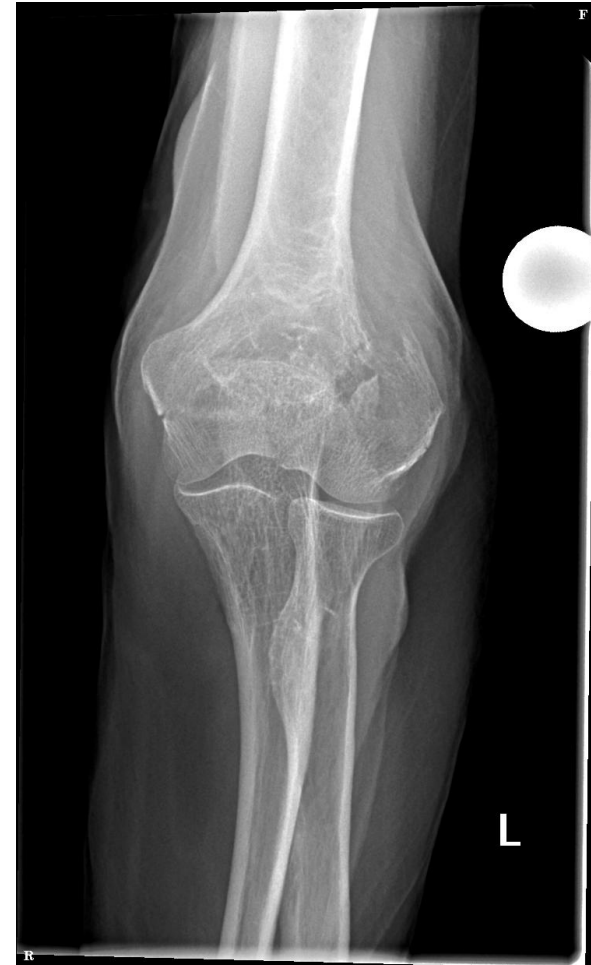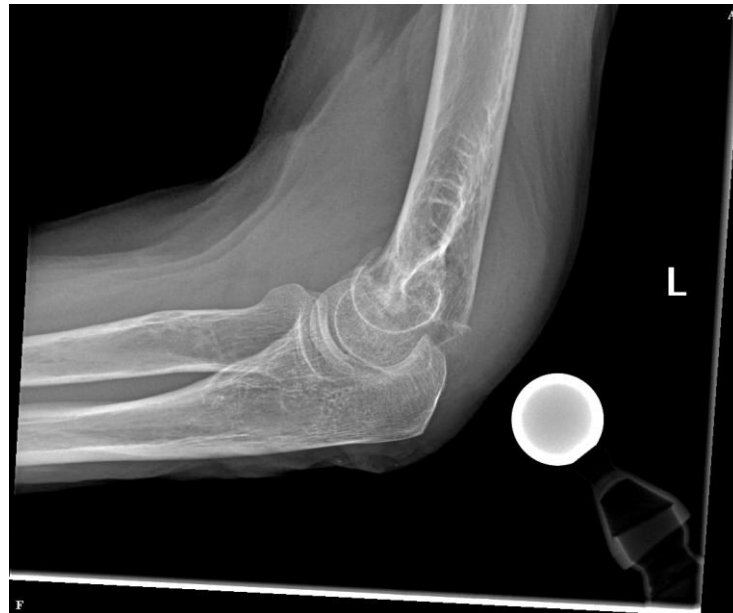6 year Follow up

McGill

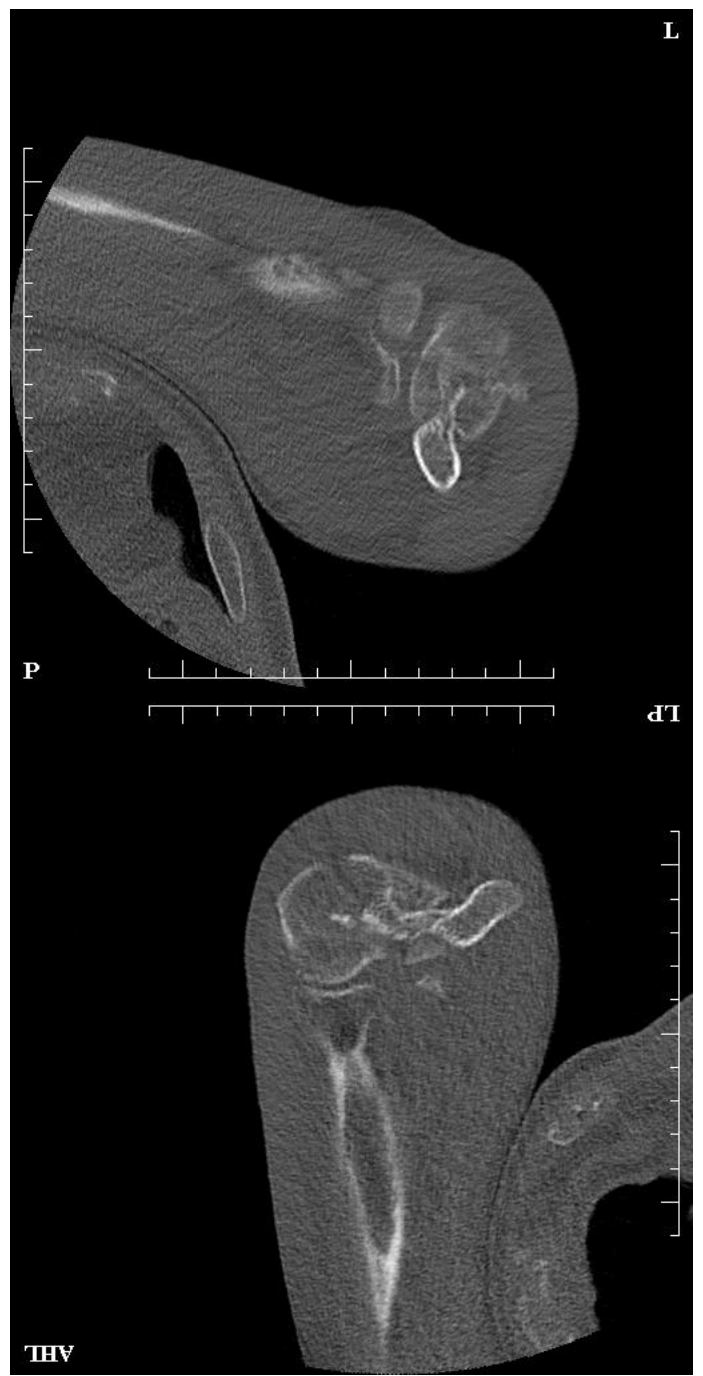
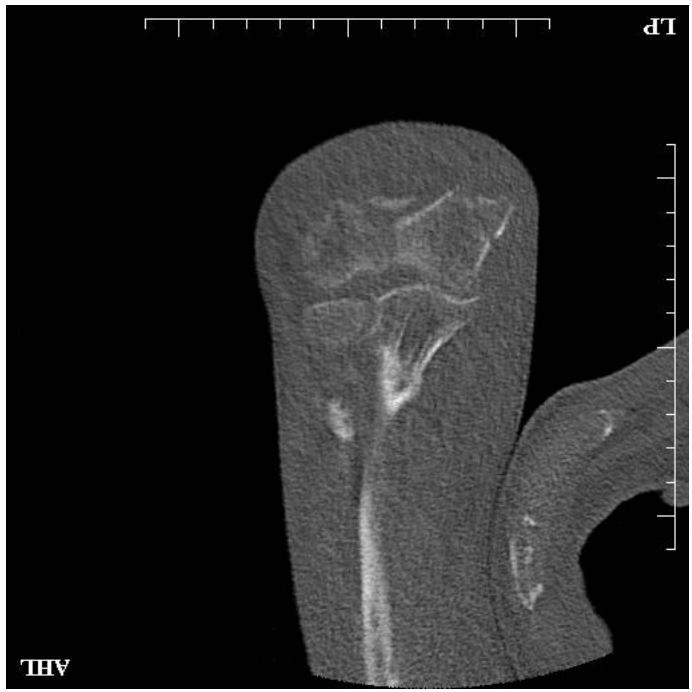

# 70 yo male MVA week before

- ✗ Transferred to MTL
- ✗ Neurointact
- ✗ Lawyer



# CT





# McGill

//

All pieces easily reducible

Some bone missing

Some cartilage missing

What cartilage


Is that an elbow?

## Older patient

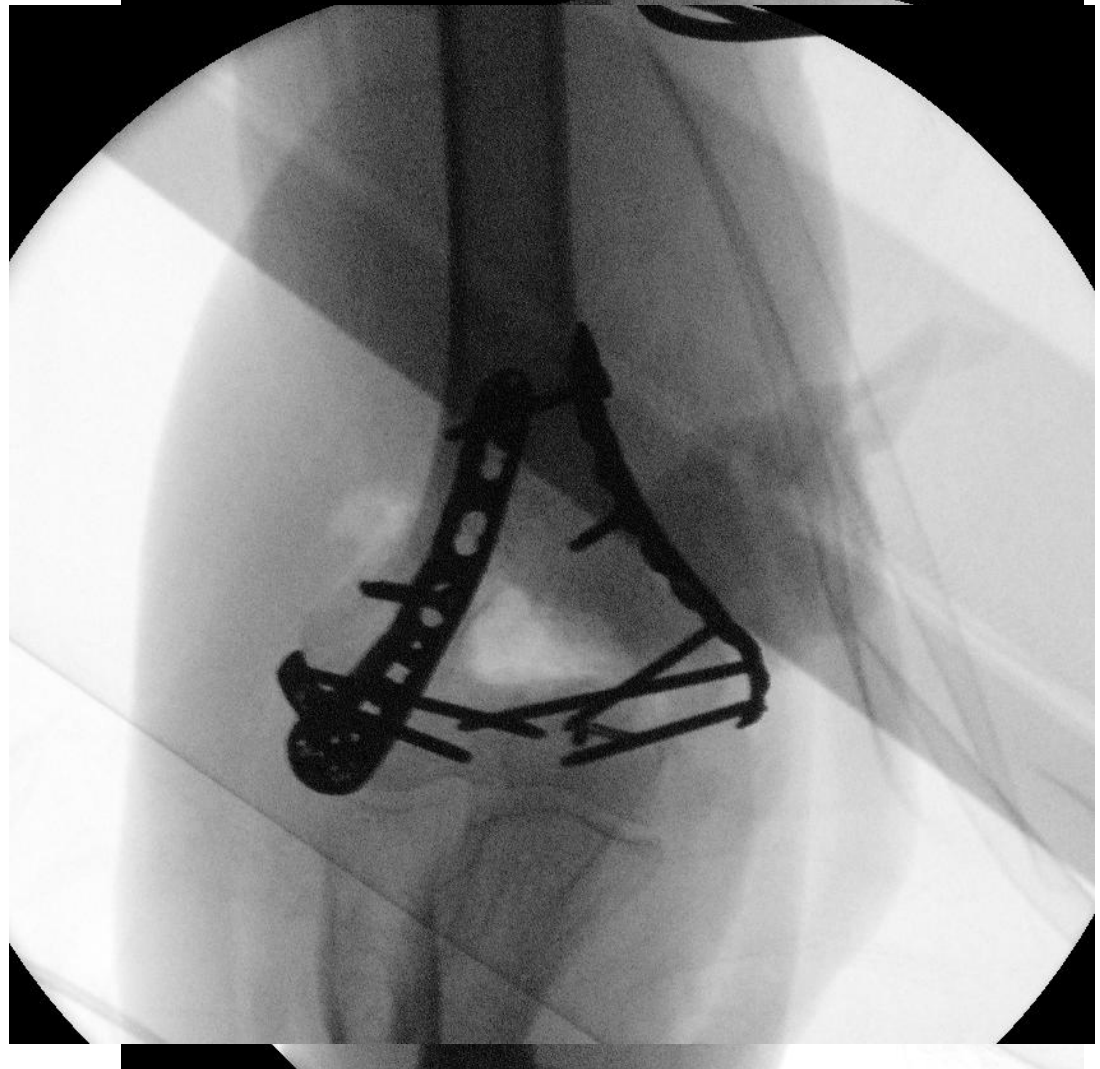
## Surgery?

## Approach?

## Hardware?



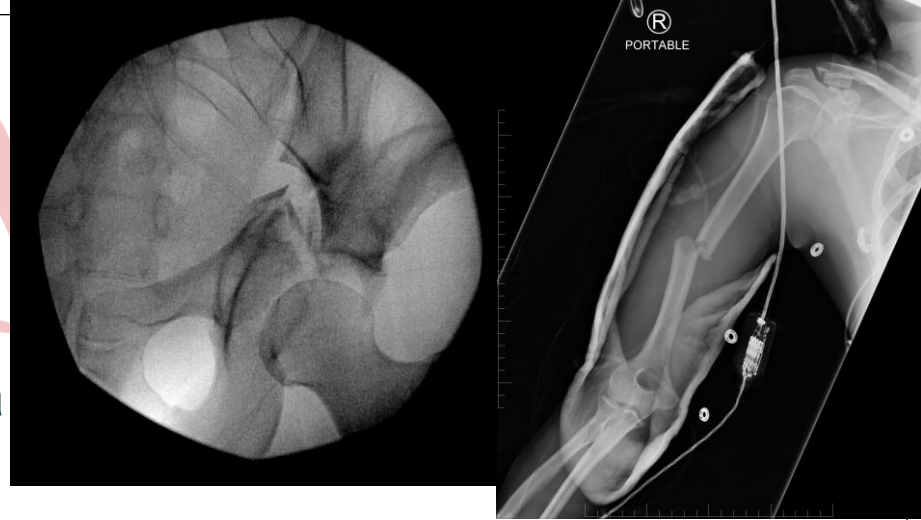# Result



# Examples



I



All pieces easily reducible

Some bone missing

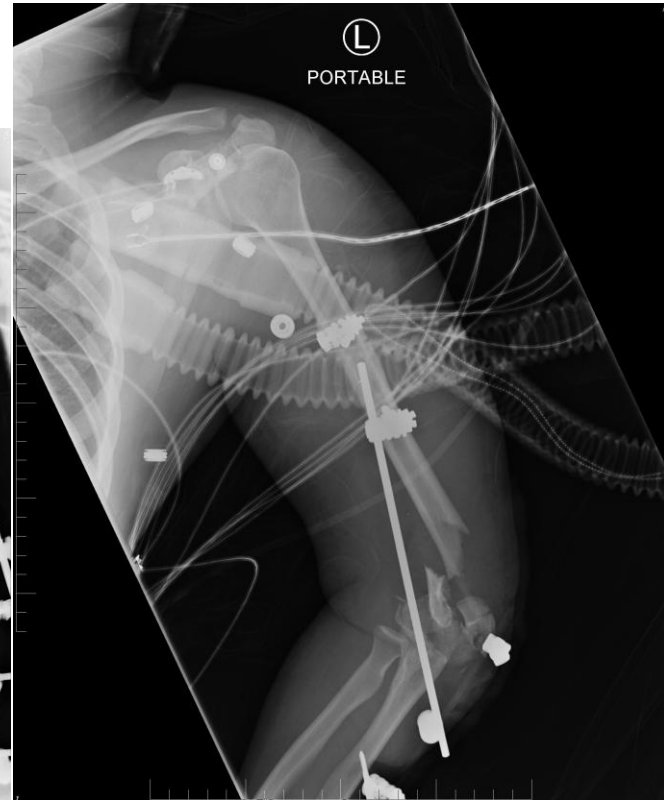
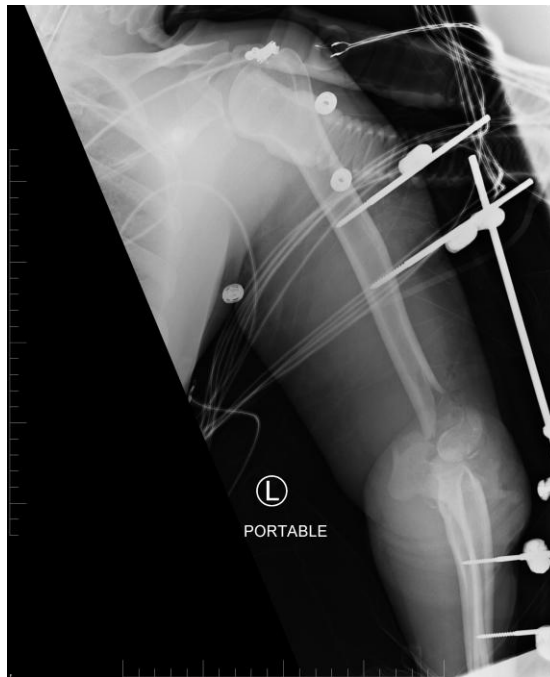Some cartilage missing

What cartilage

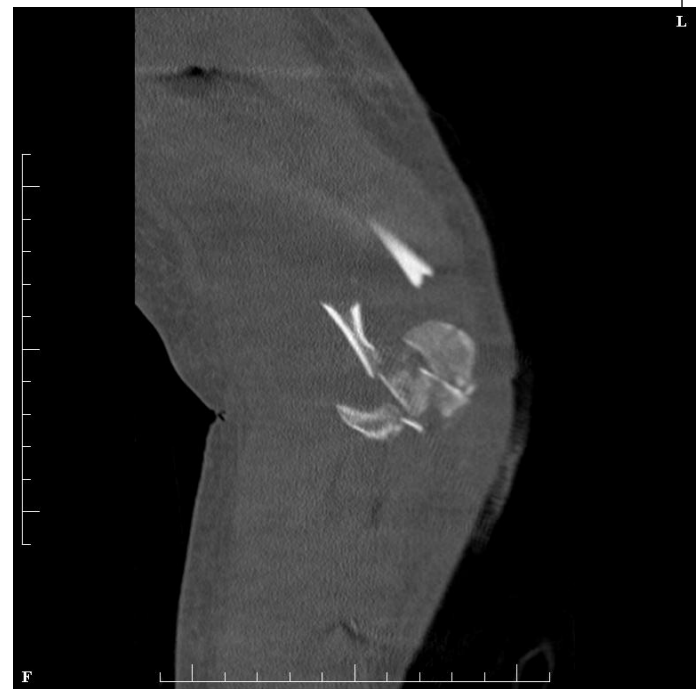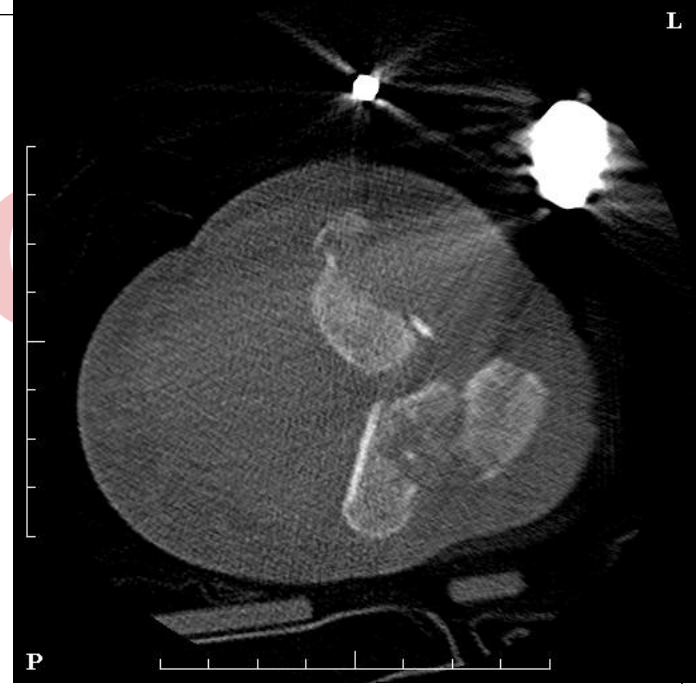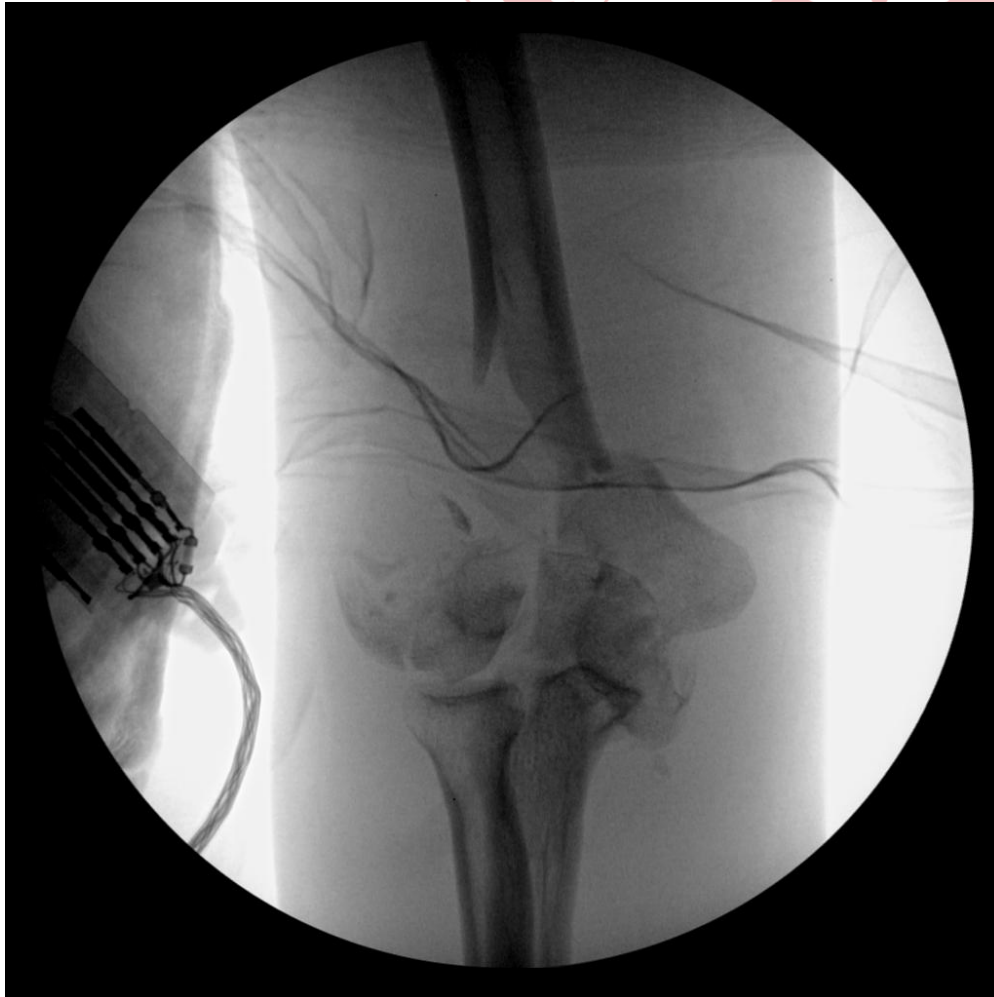Is that an elbow?

polytrauma

- NV?
- Intubated



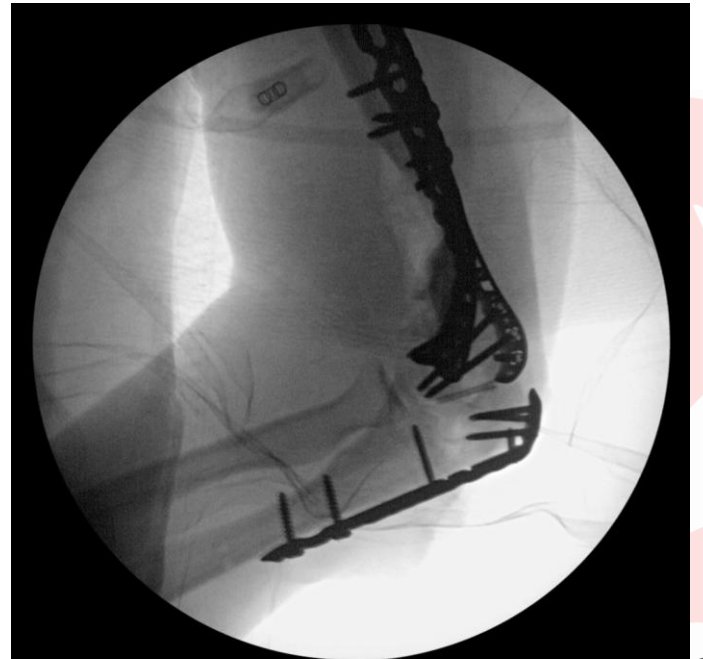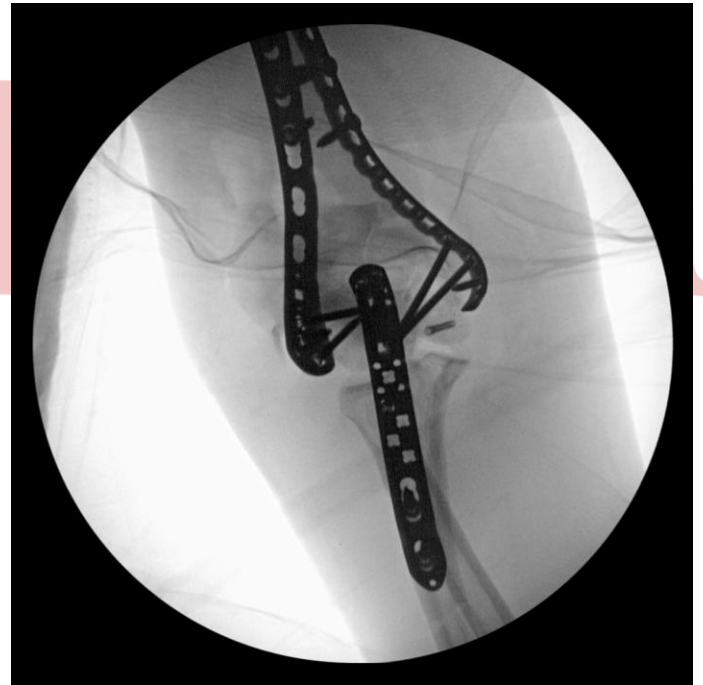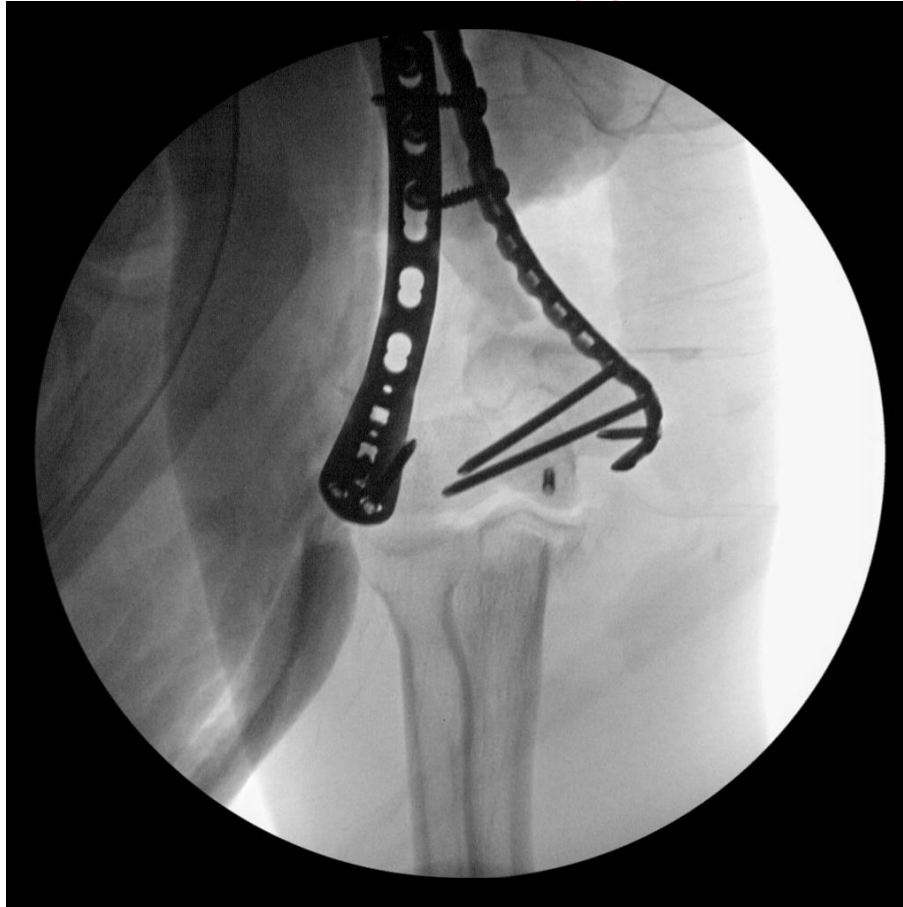# Osteotomy DONE!



Just a bad day



M



# Approaches



All pieces easily reducible

Some bone missing

Some cartilage missing

What cartilage

Is that an elbow?

# McGill

## Medial Morrey

TEA/Hemi  
Allograft

## Triceps Splitting

Allograft

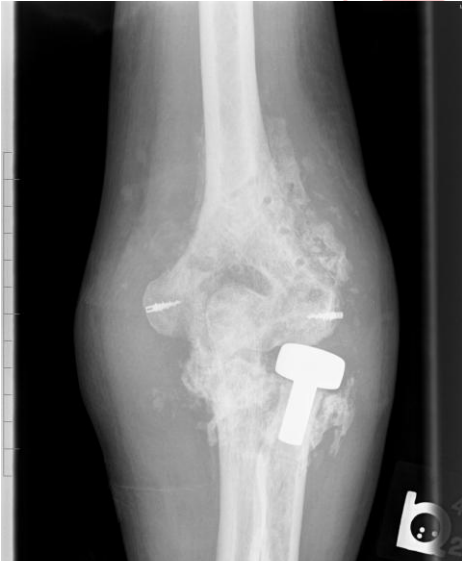

# Allograft

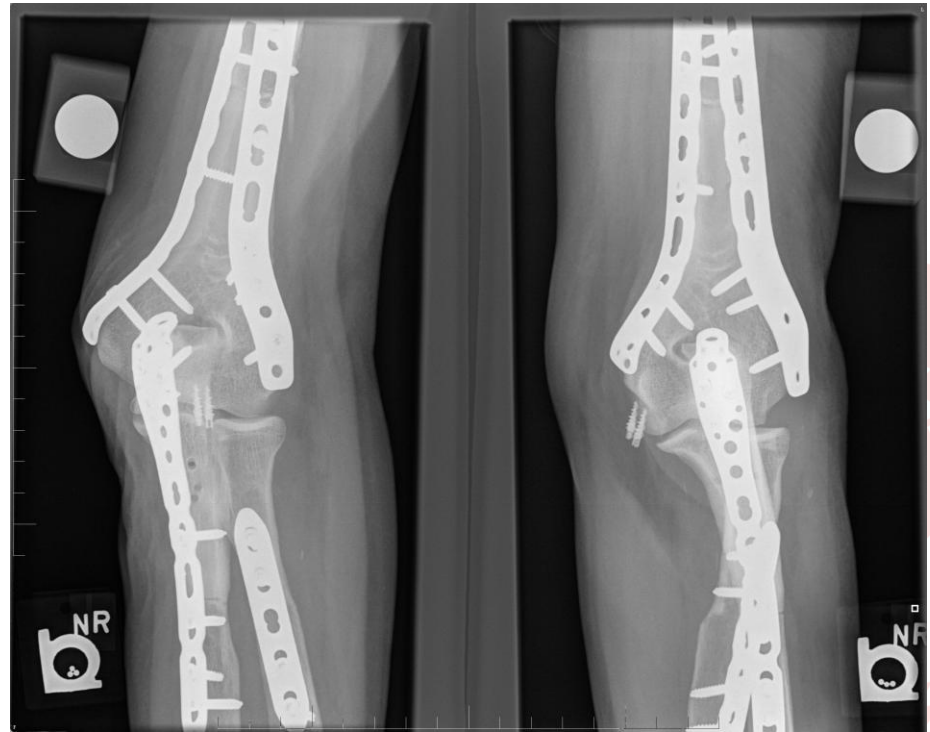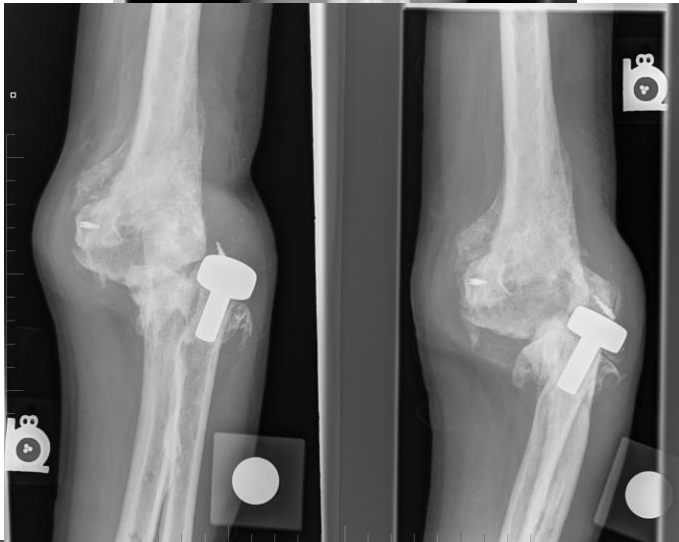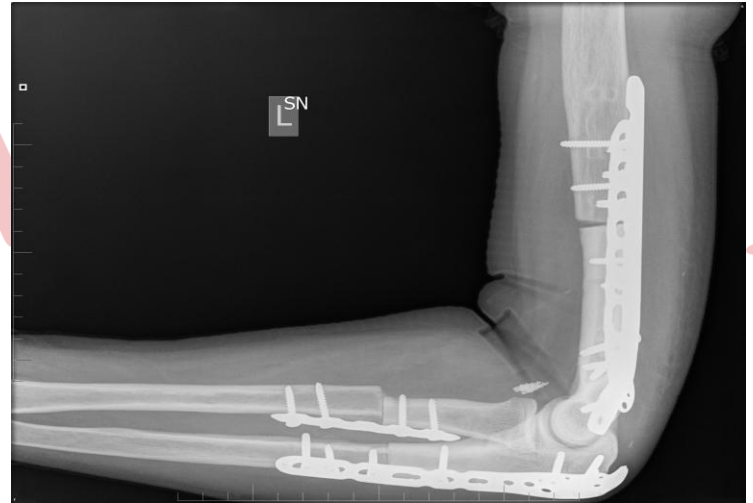


N

1



2 other sx  
Sent in



# Examples

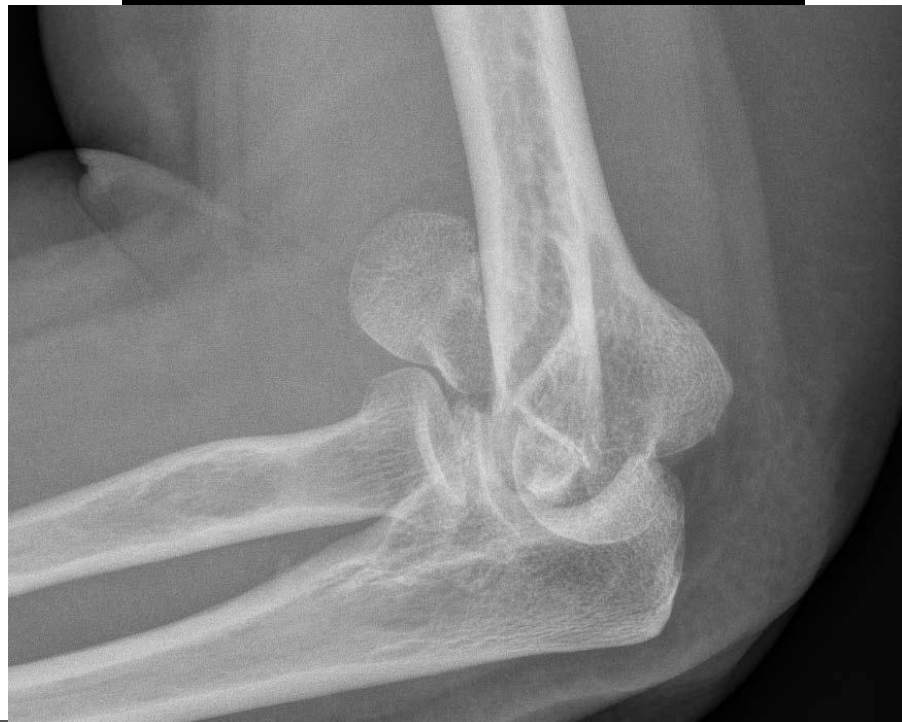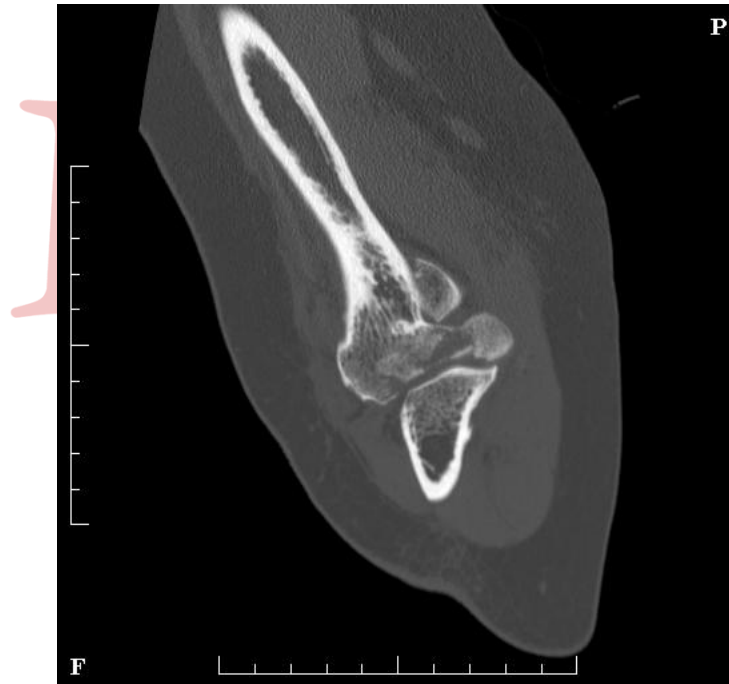
All pieces easily reducible

Some bone missing

Some cartilage missing

What cartilage

Is that an elbow?



# Examples



# M

All pieces easily reducible

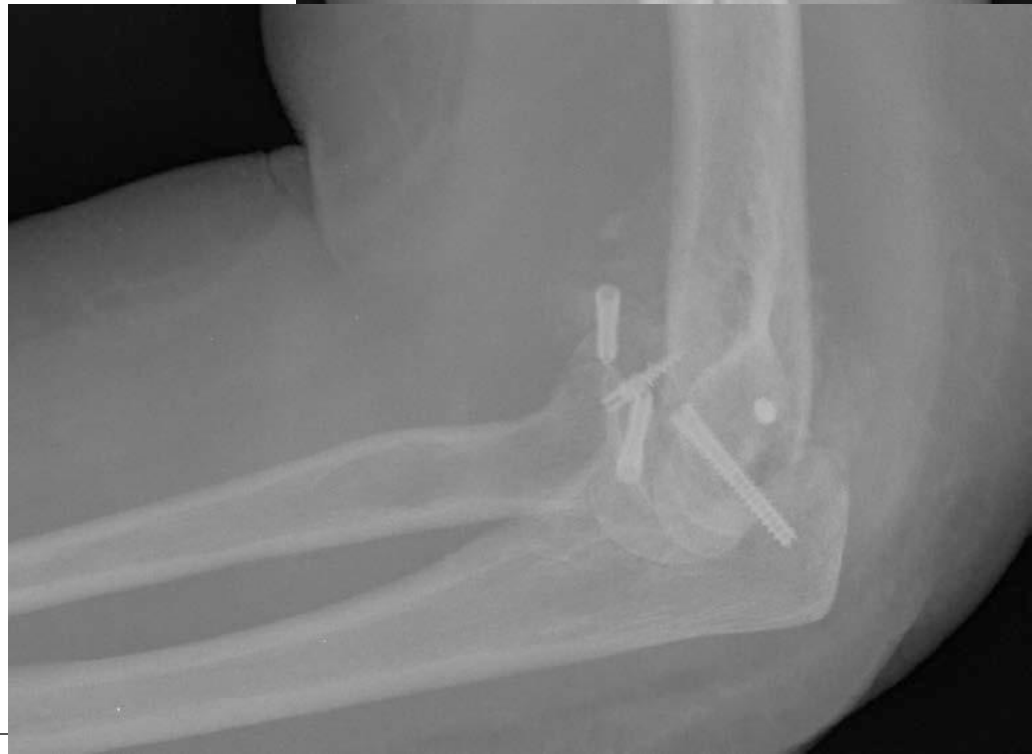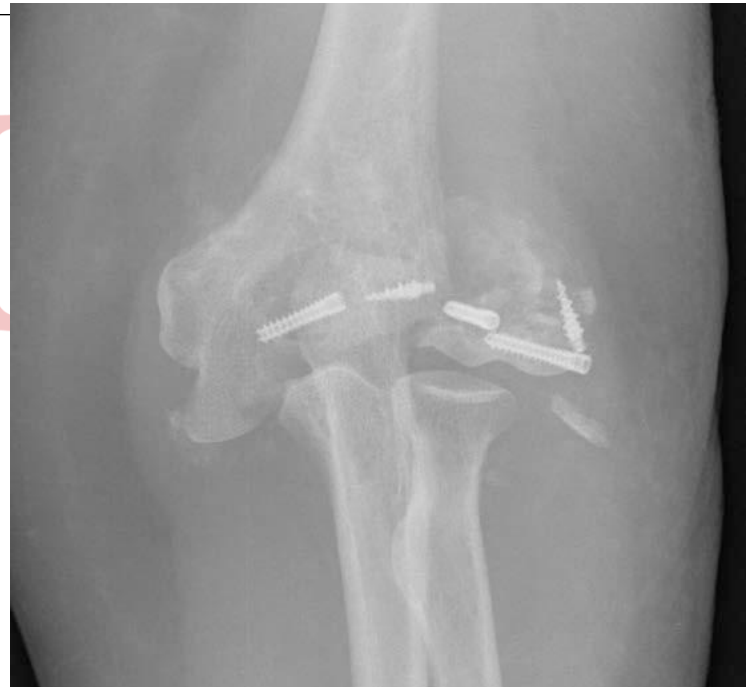Some bone missing


Some cartilage missing

What cartilage

Is that an elbow?

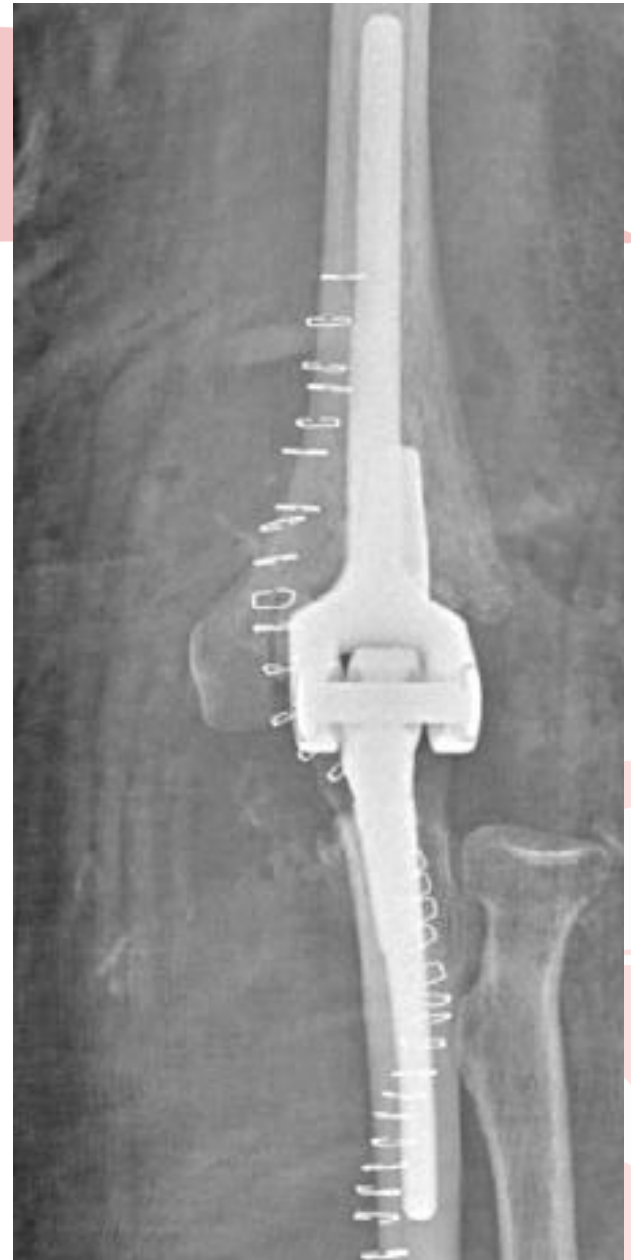
Somebody tried  
3 weeks old





# M

- Is there any good artificial elbow?
- One that lasts
- One that can be used under 60?



# 1

# Thanks

