

Humeral Shaft Fracture Case to Ponder

Melvin P. Rosenwasser, MD

Robert E. Carroll Professor of Orthopedic Surgery

Professor of General Surgery

Director- Orthopaedic Hand and Trauma Services

Columbia University Medical Center

85 y.o. RHD F

30 year history of RA

Rx: Embrel, Methotrexate, occ short courses of Prednisone for flares

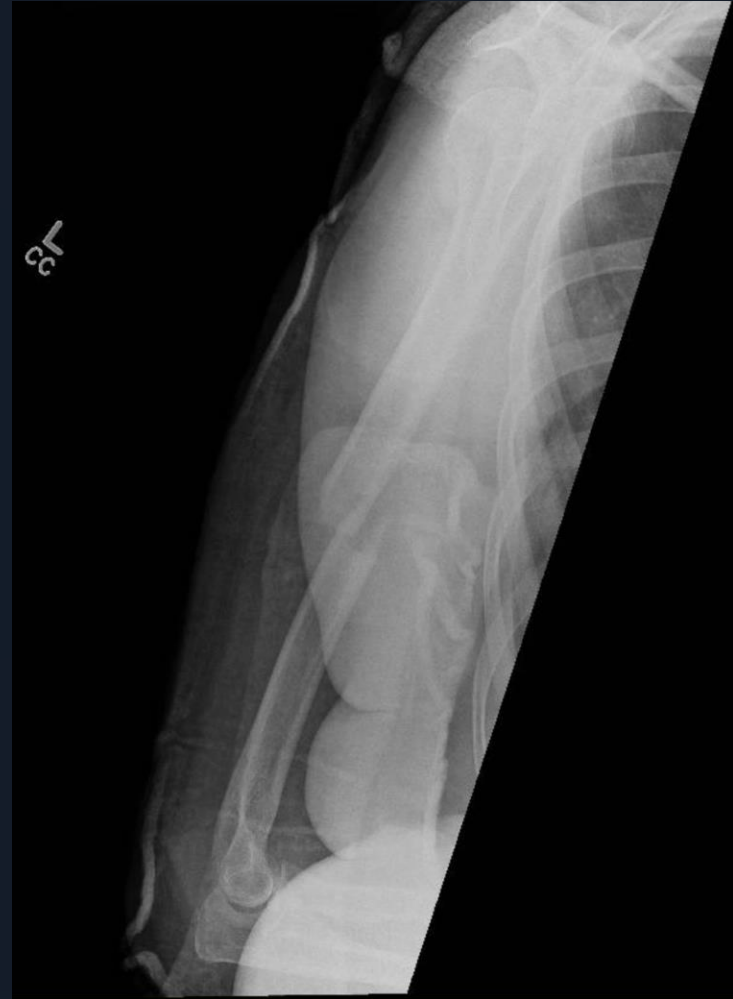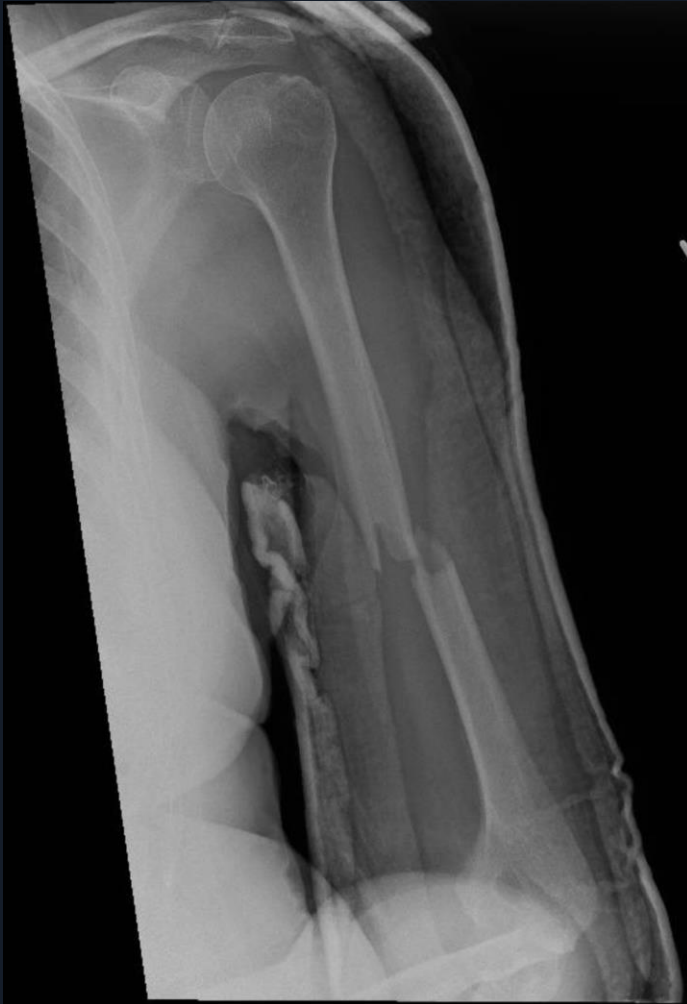Fell down steps at a St. Patrick's Day party she was hosting- 3/17/2023

Closed Left Humeral Shaft Fx

Radial Nerve Intact

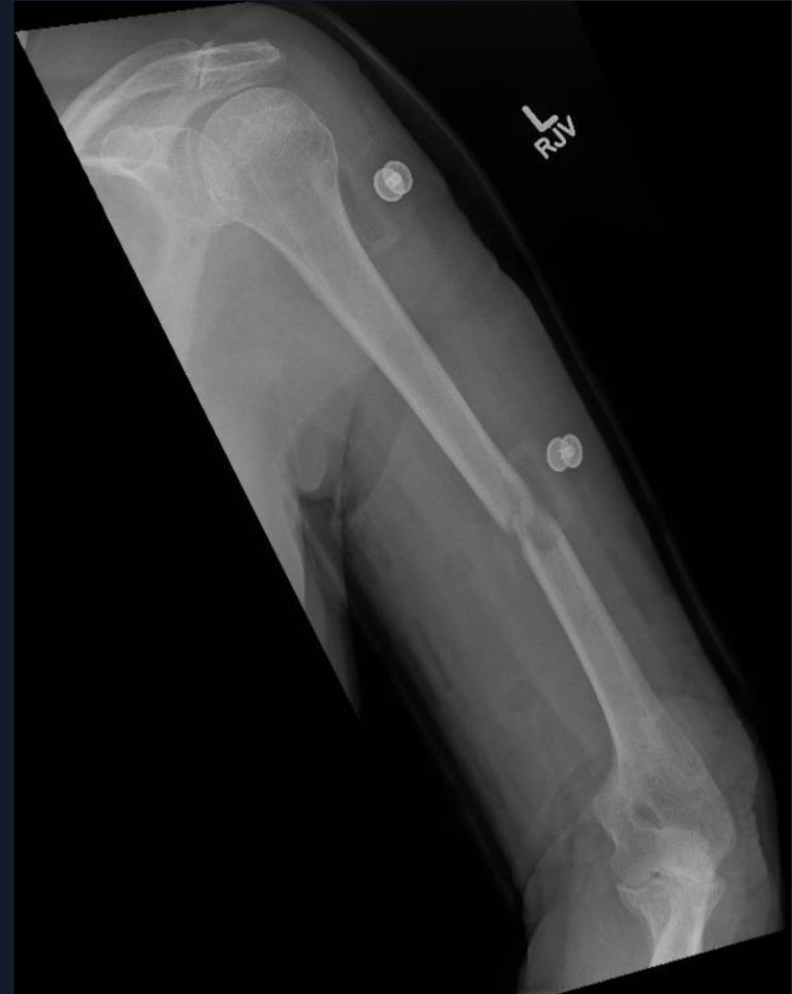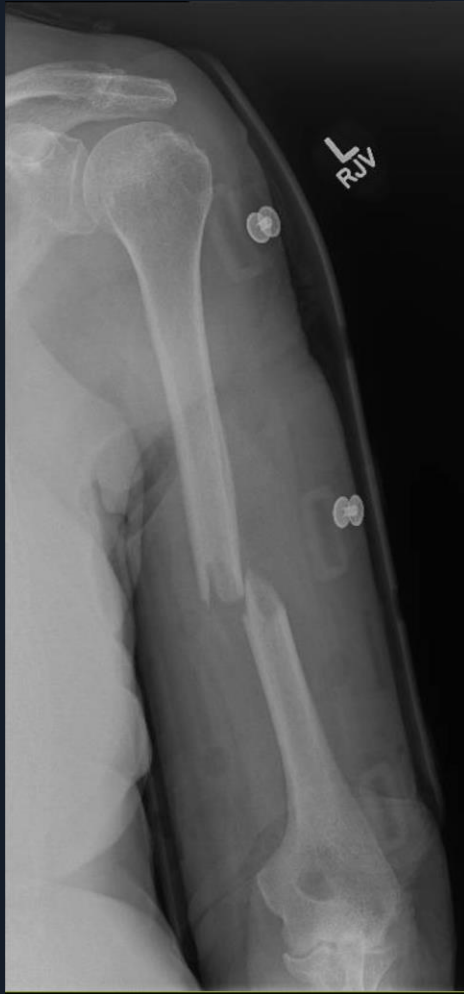KQ 3/21/2023

Treated with Coaptation Splint



KQ 4/4/2023

Switched to Sarmiento Orthosis



First Question

Is this acceptable treatment?

Who would operate on this immediately?

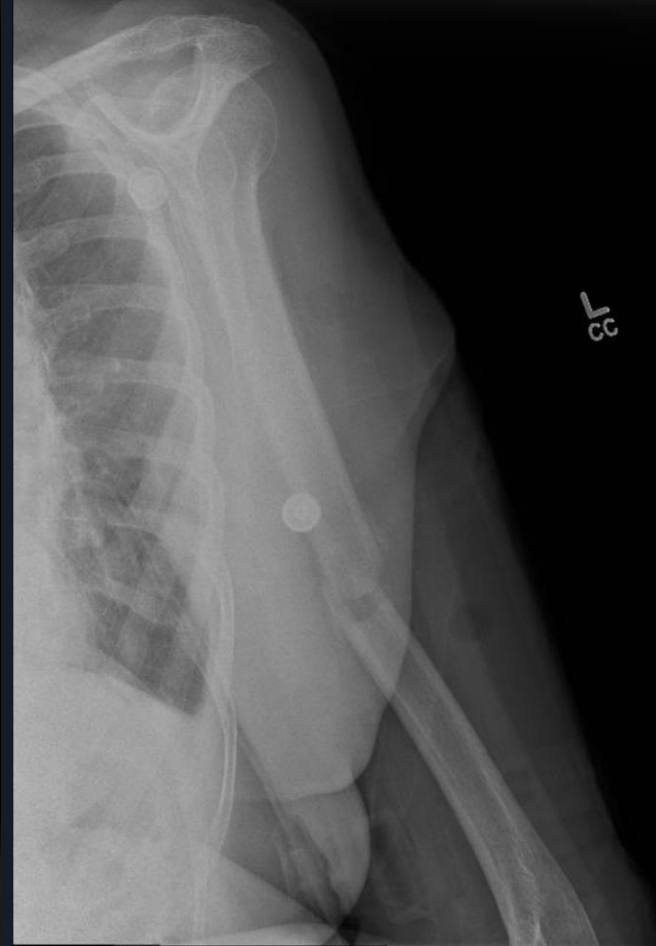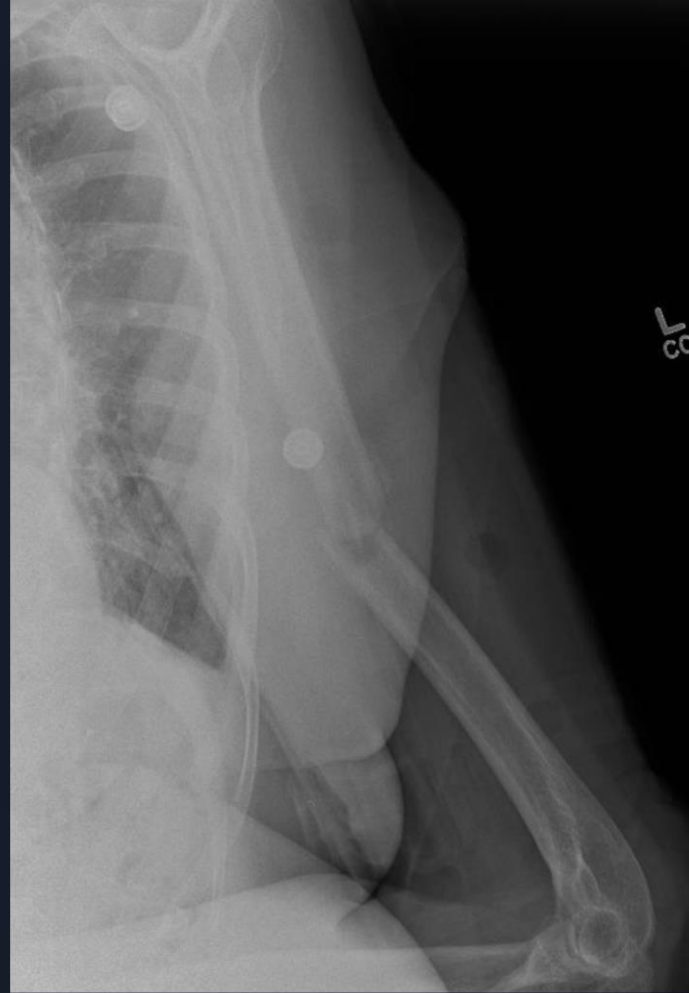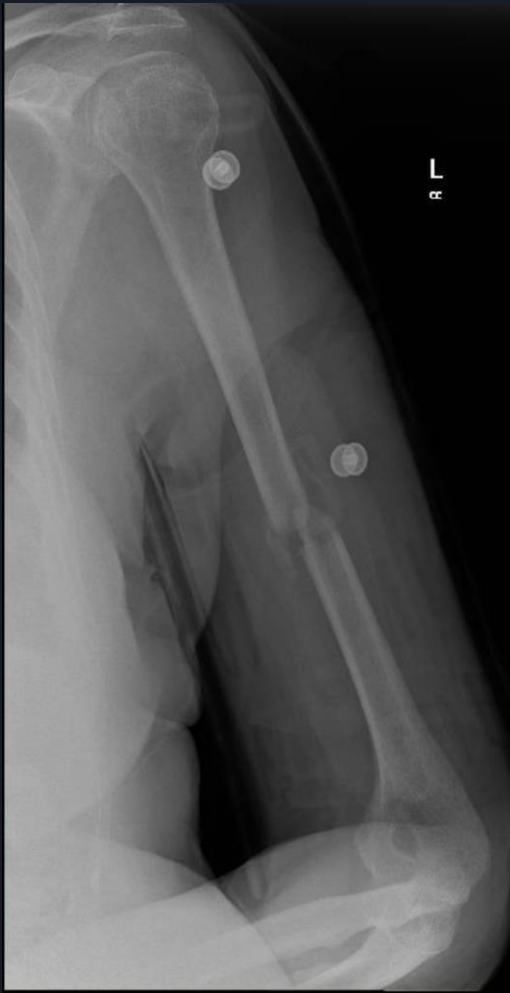Who would wait and how long?

Finally will this fracture heal ?

Mid Shaft with acceptable alignment and apposition.

KQ 4/18/2023

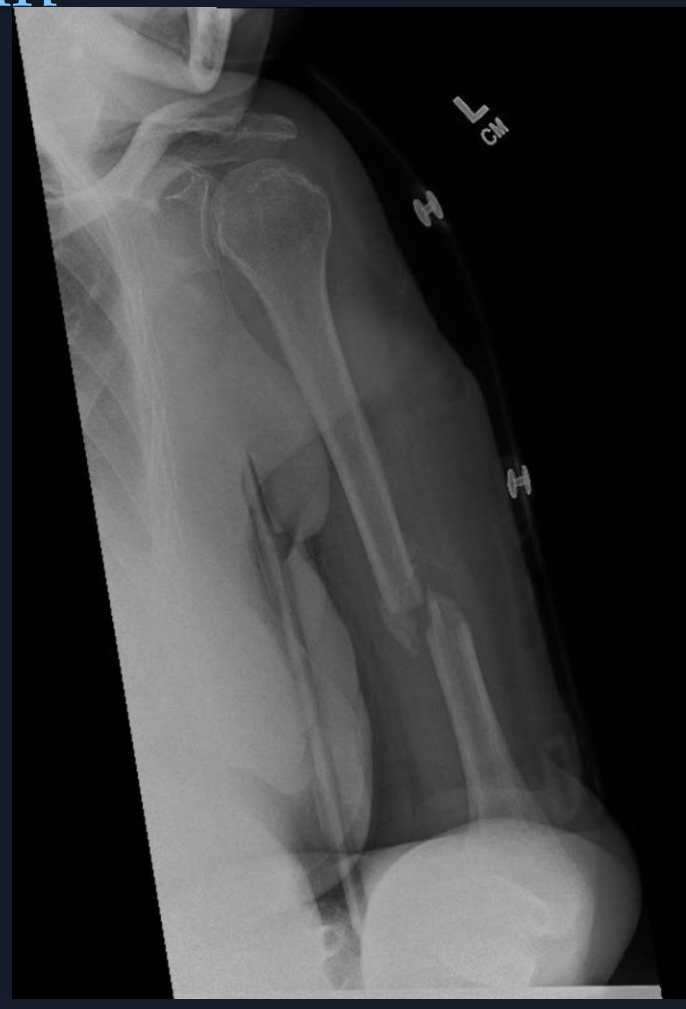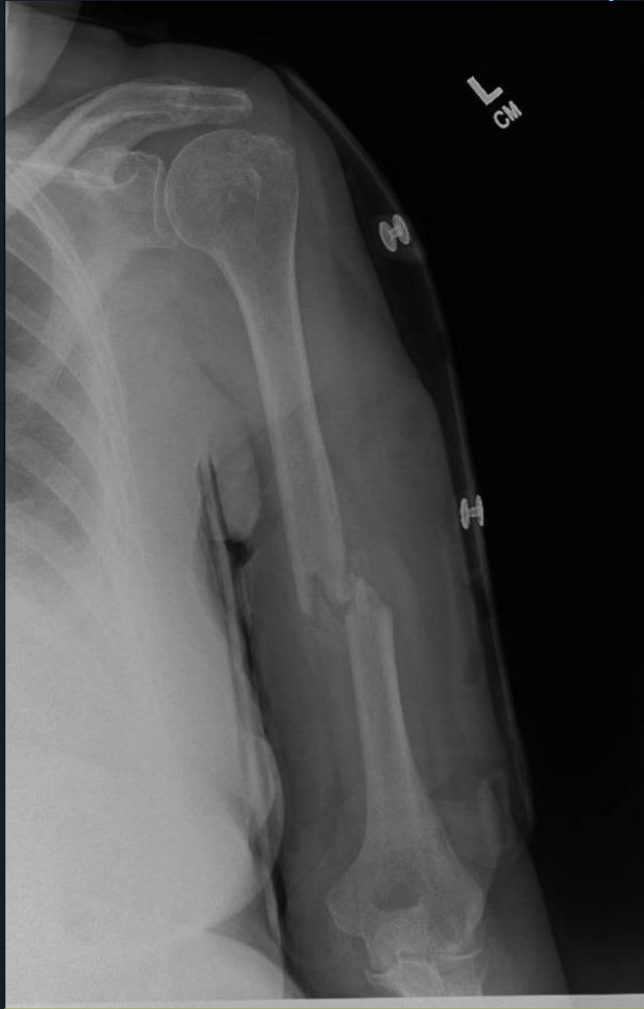
1 month out and callus forming



KQ 5/16/2023

2 months out Fx sticky

No pain



Critique

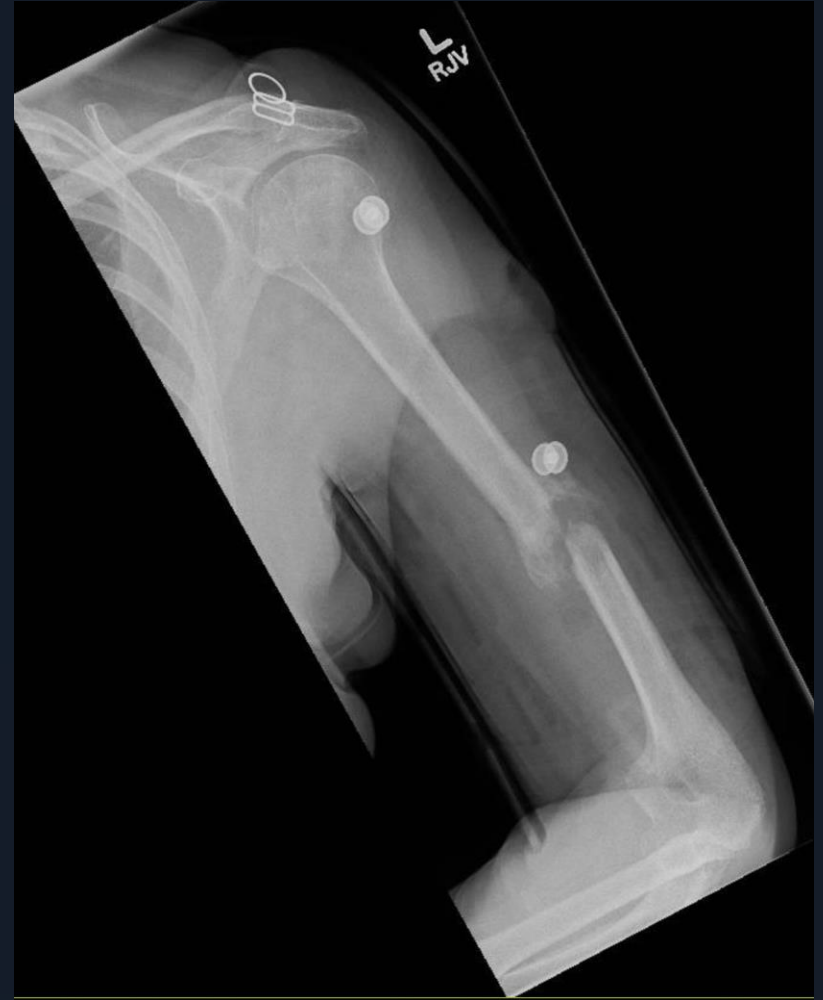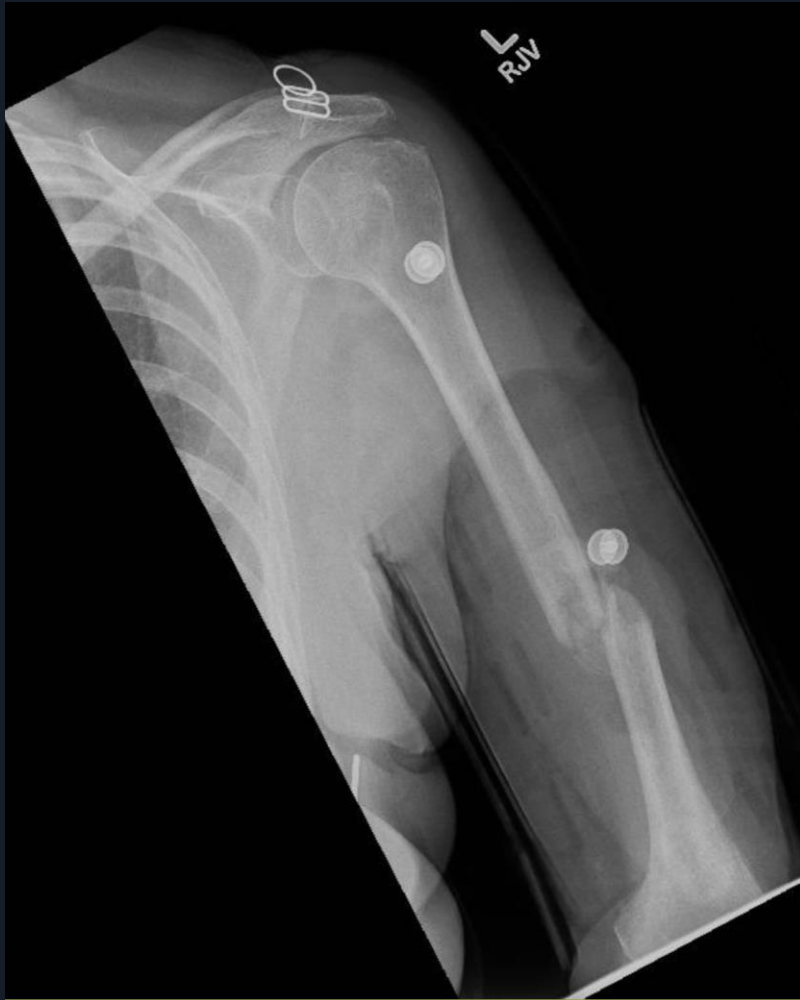Is Humeral Orthosis adequate?

Is Reduction adequate?

Will it Heal?

KQ 6/20/2023

3 months More Bridging Callus



What should we do?

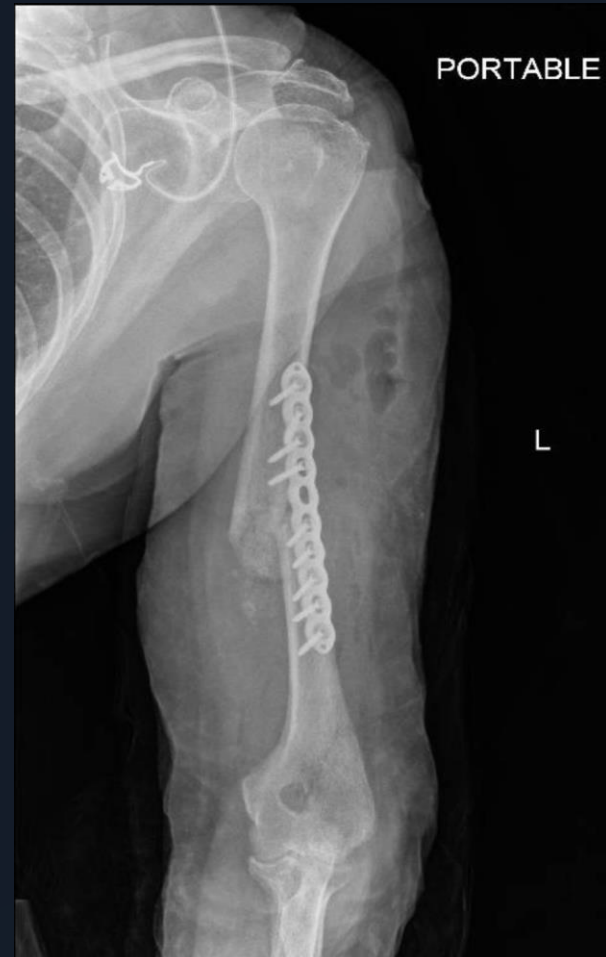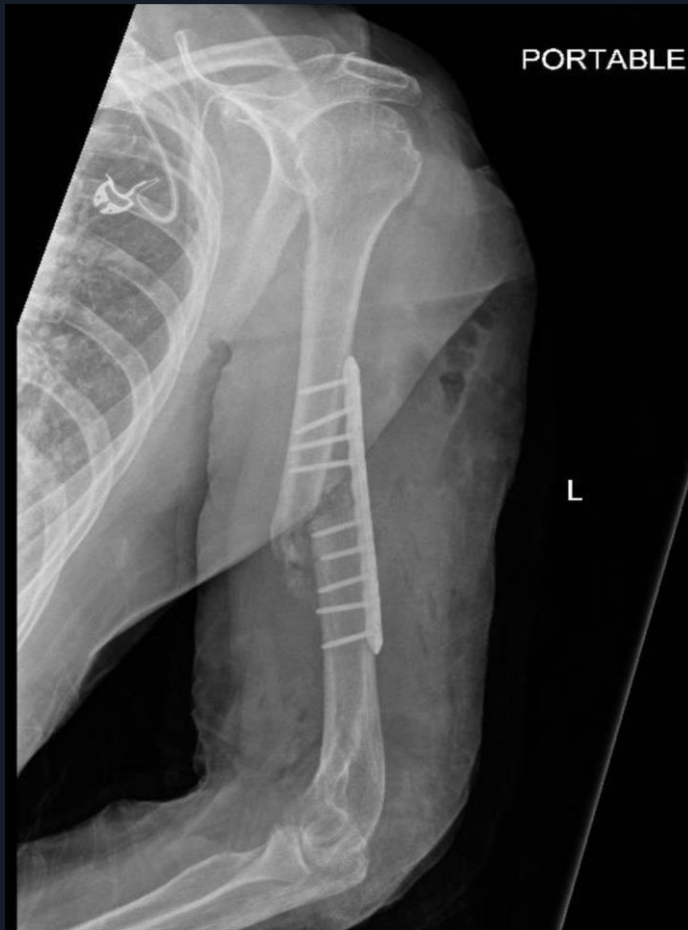Fx making progress to union

Do we continue?

Or do we bail?

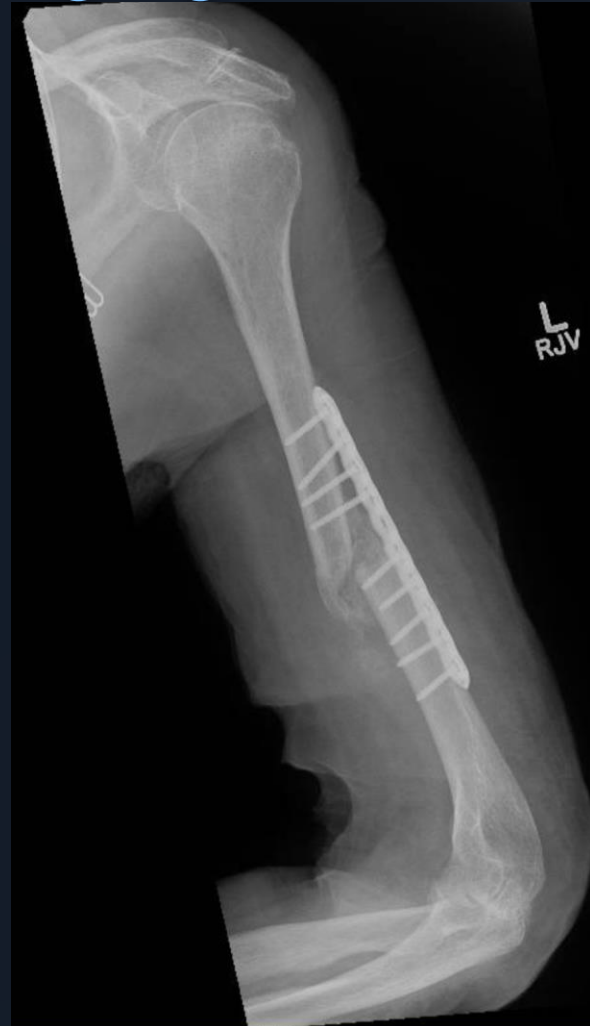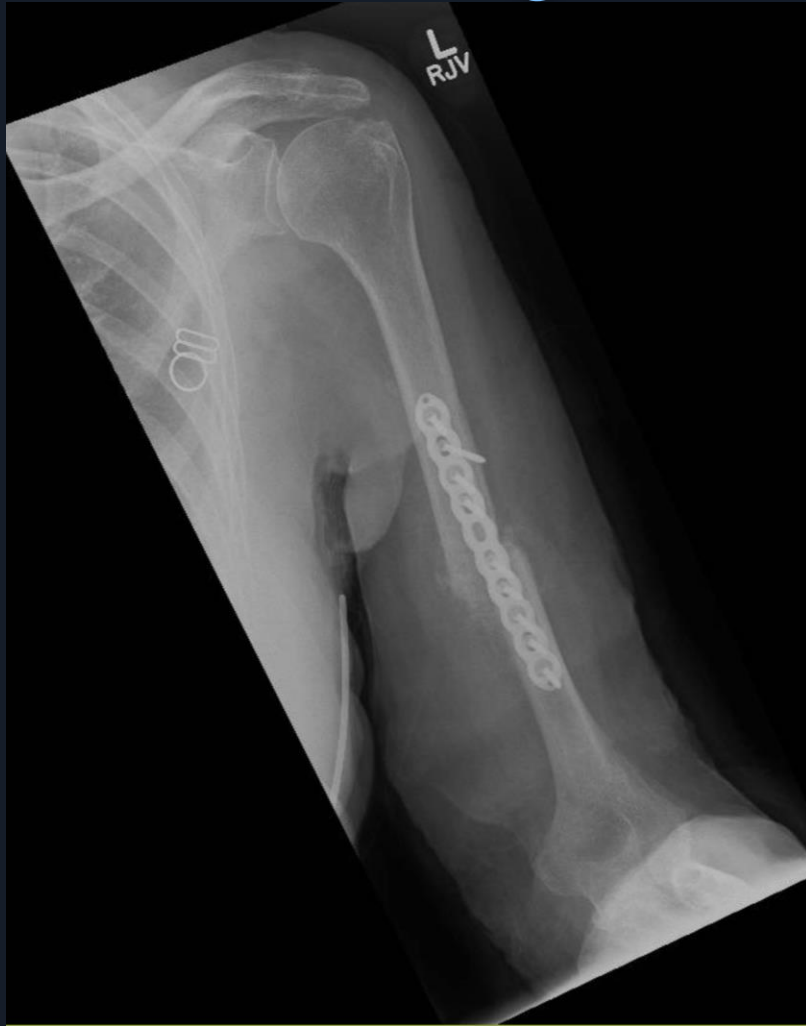KQ 6/26/2023

Post Approach- Left Callus Alone- Wave Plating Allograft and Iliac Crest Aspirate



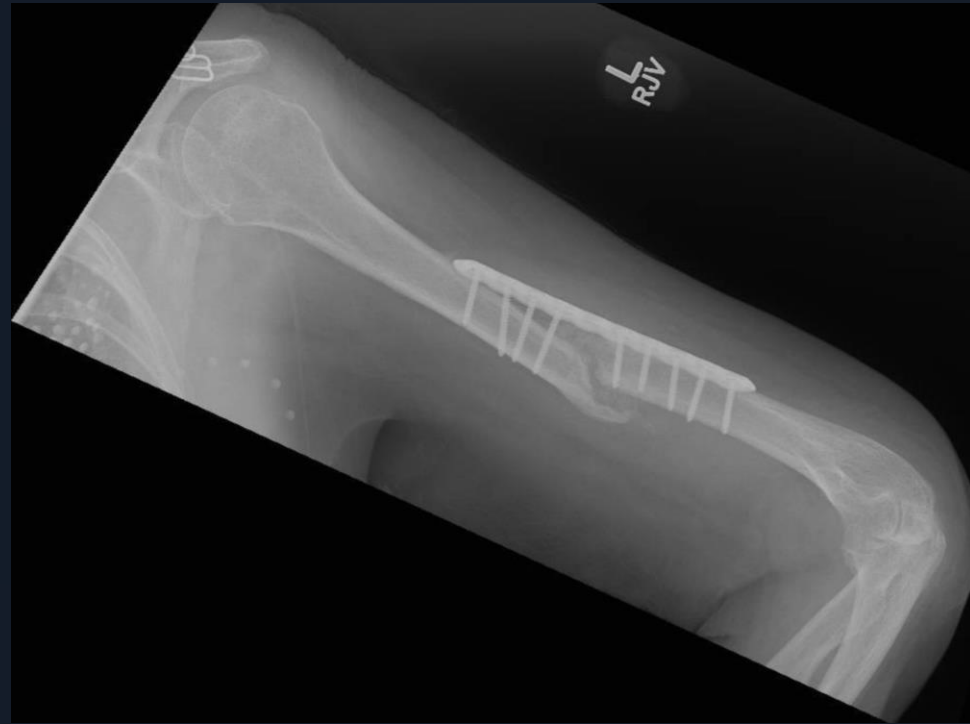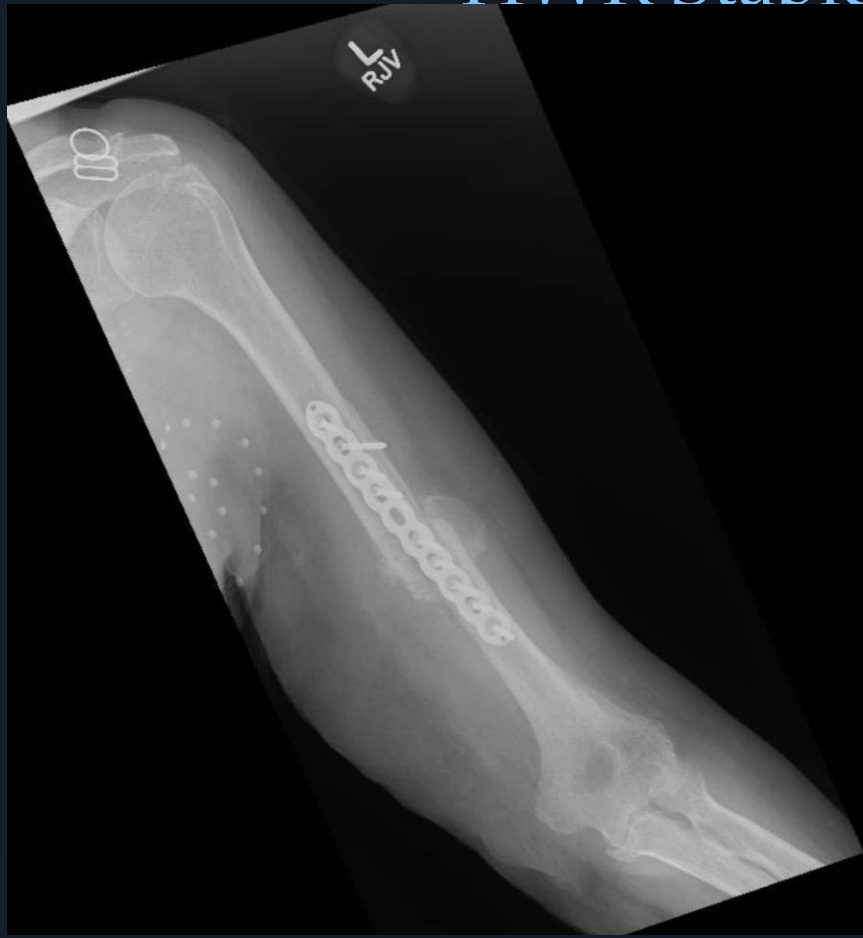KQ 7/18/2023

Making lots of bridging callus



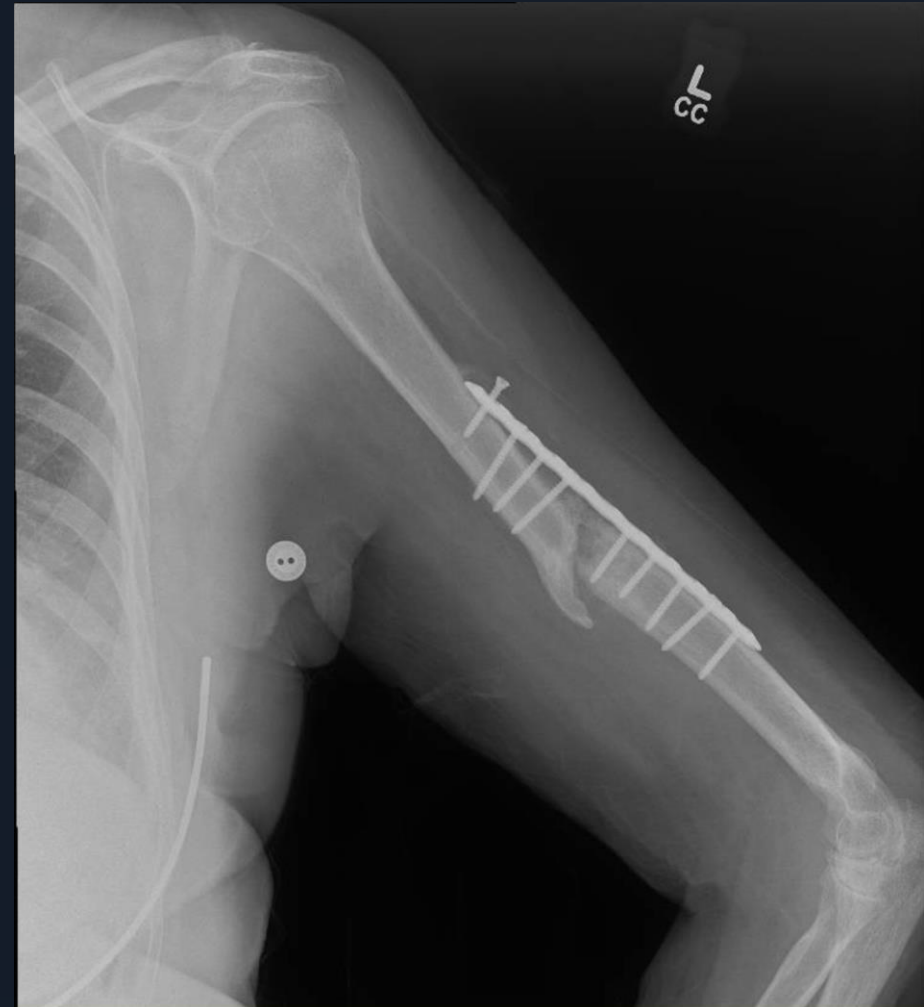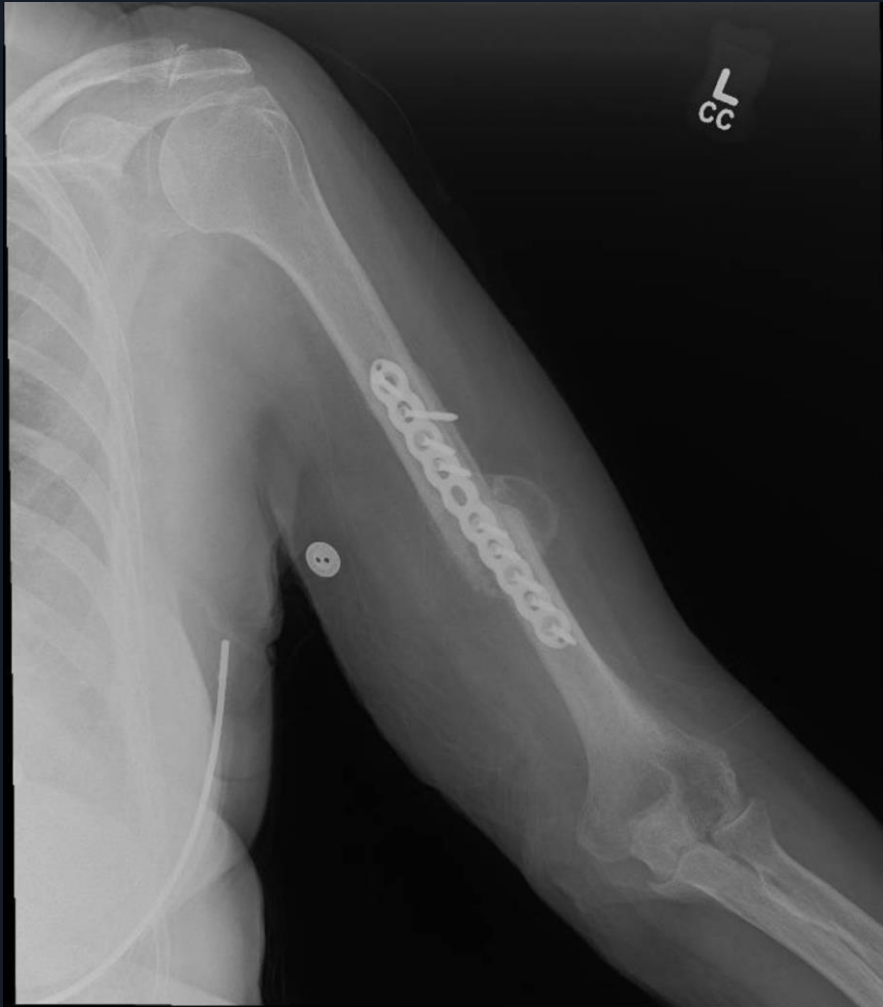KQ 8/29/2023

2 months out Callus bridging under plate
HWR Stable - Are we OK?



KQ 10/17/2023

4 mos out with HWR failing



Now What?

Sit Tight or Revision Now?

Approach?

Hardware?

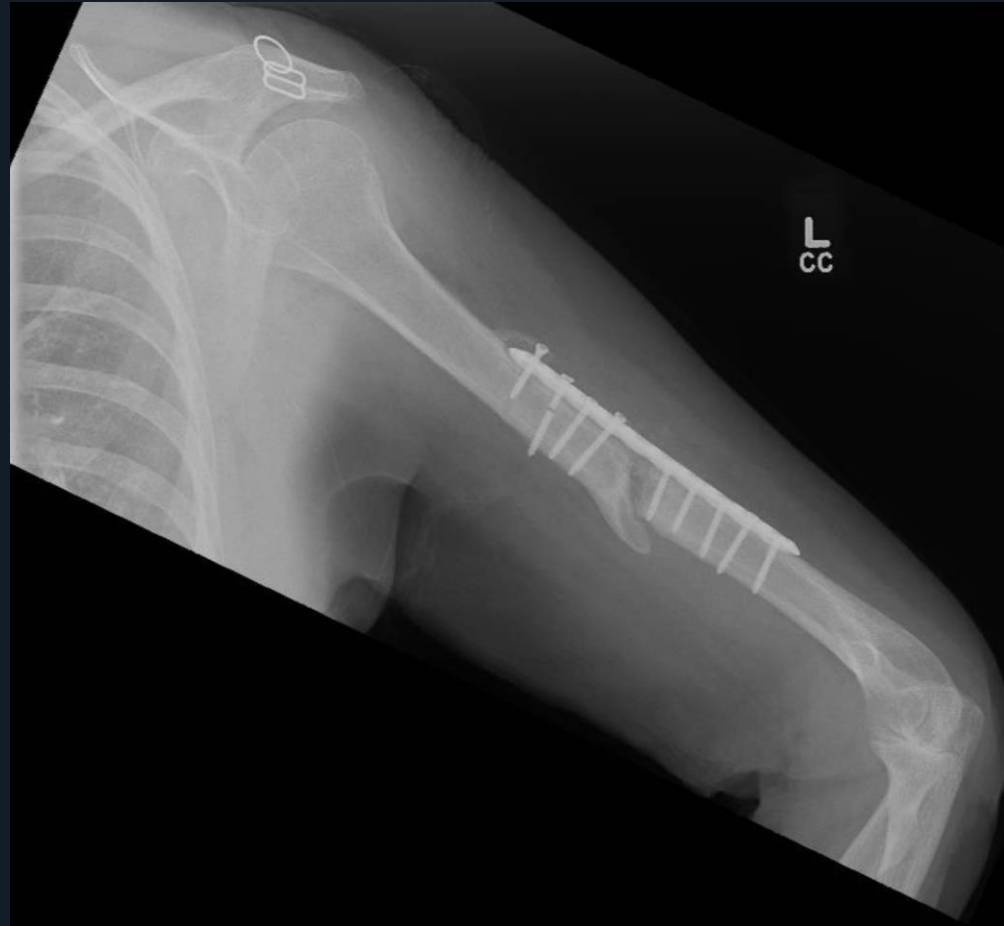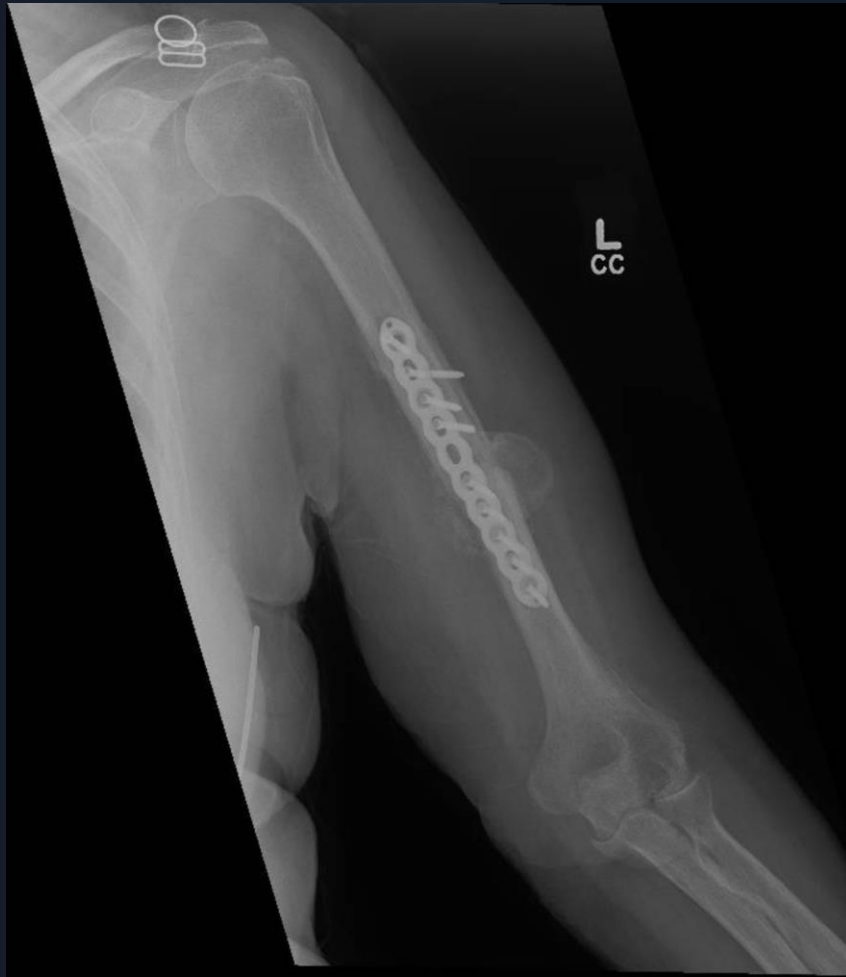Graft?

There has never been any sign of infection

Patient asymptomatic

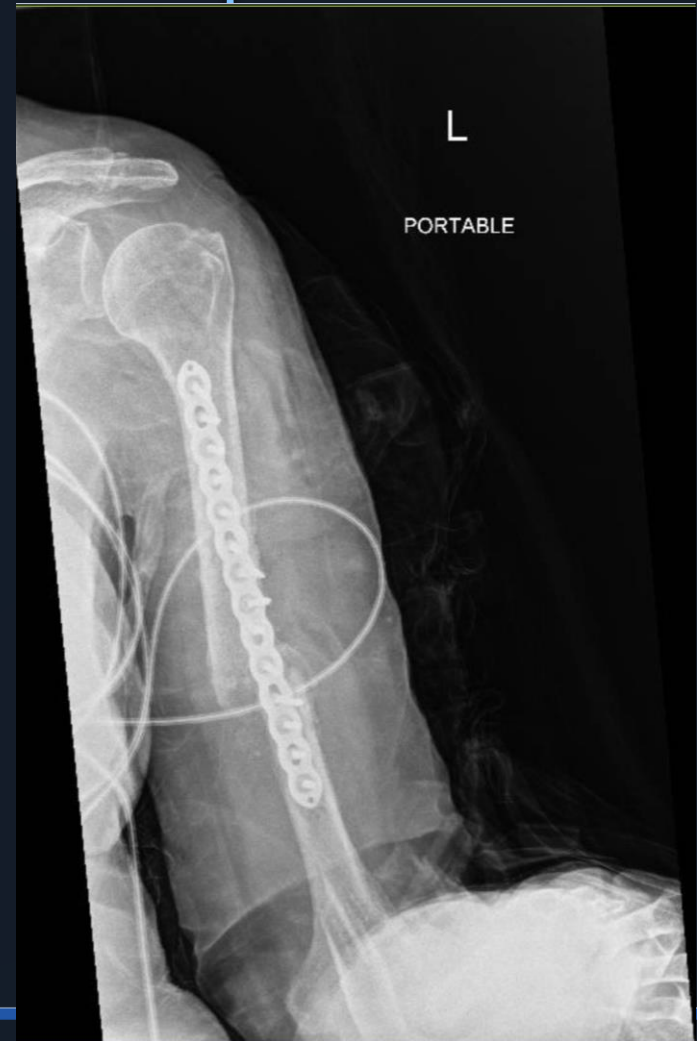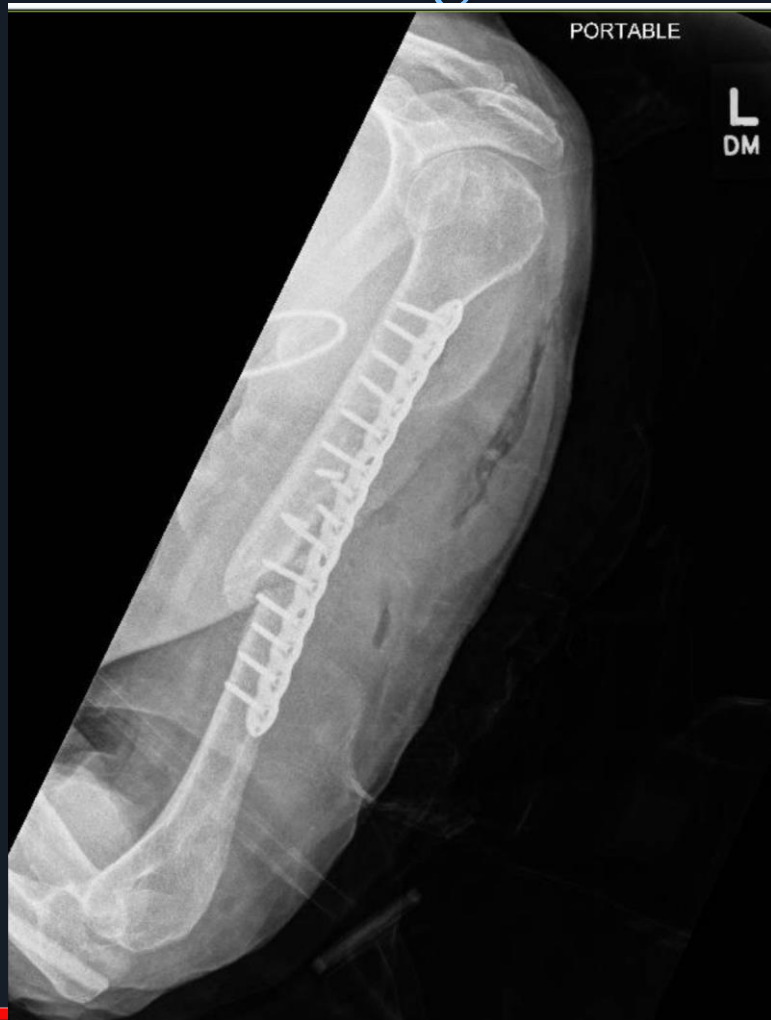KQ 12/19/2023

Kept watching



KQ 2/5/2024- OP # 2

Revised through Post App – 14 hole plate
Allograft and Iliac crest aspirate



Critique?

Approach

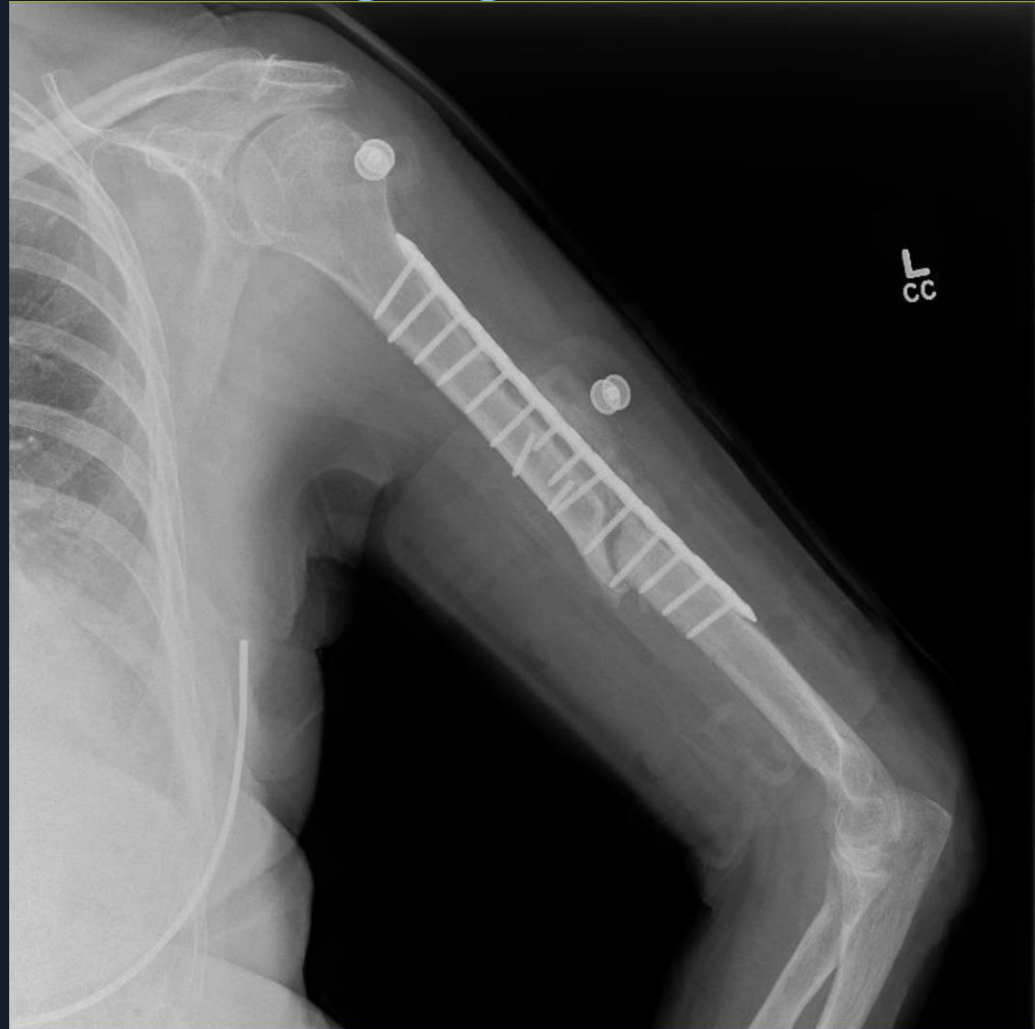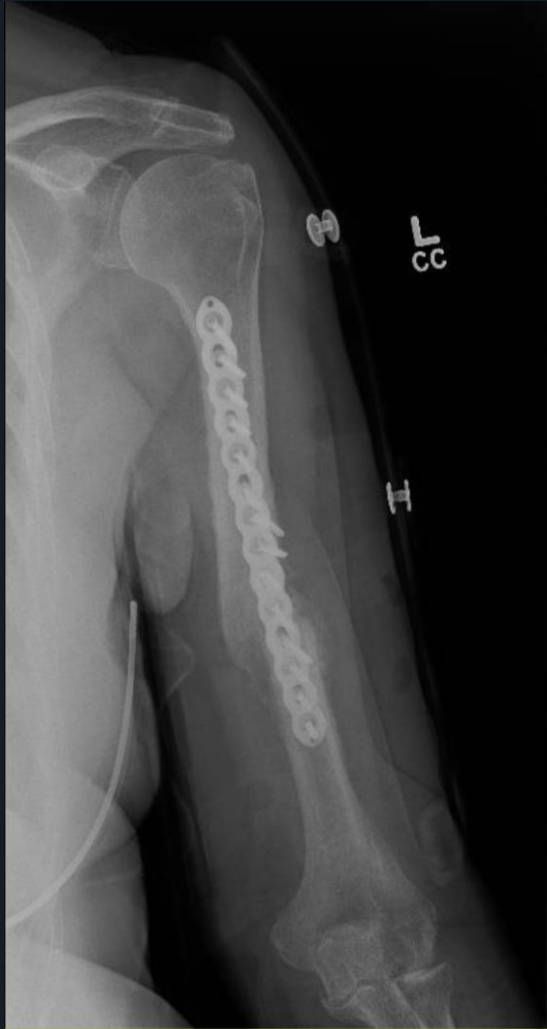Reduction

Hardware

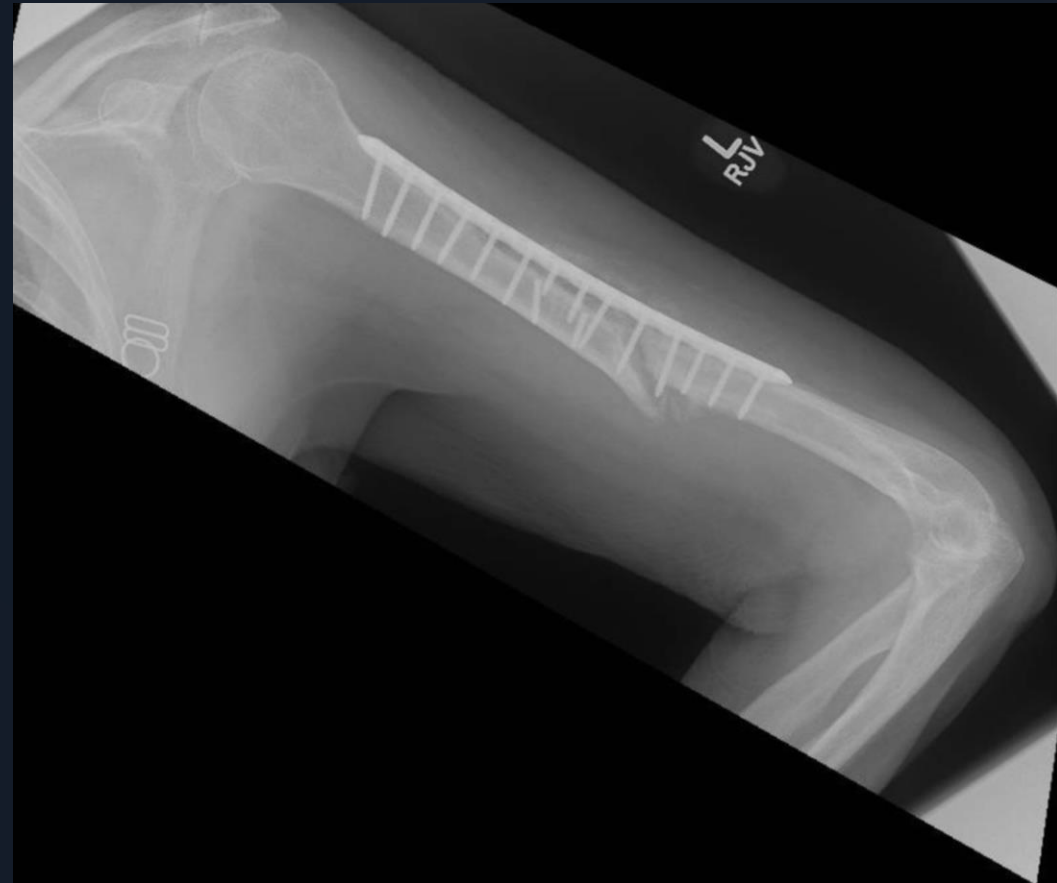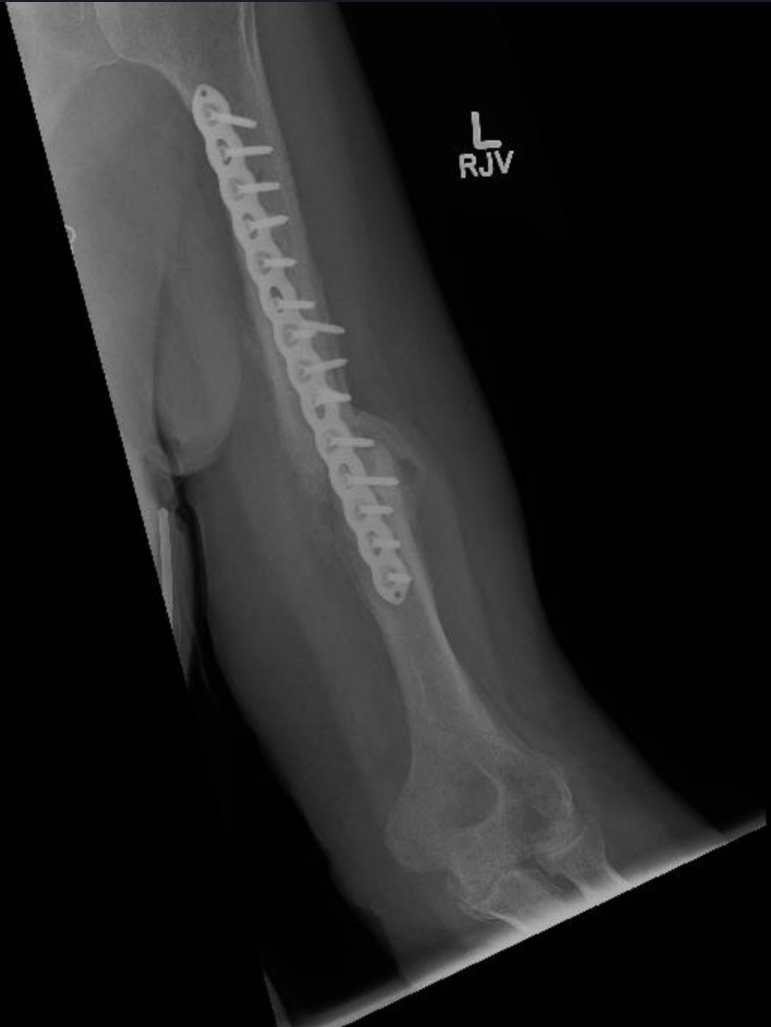Graft material

KQ 3/19/2024

6 weeks- BG bridging

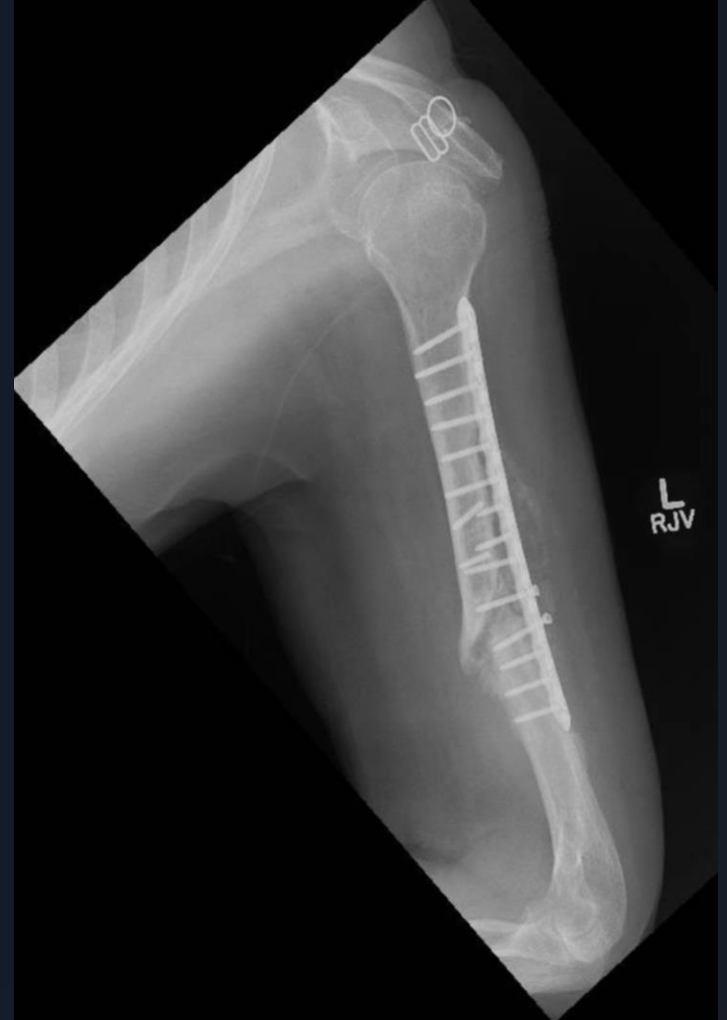
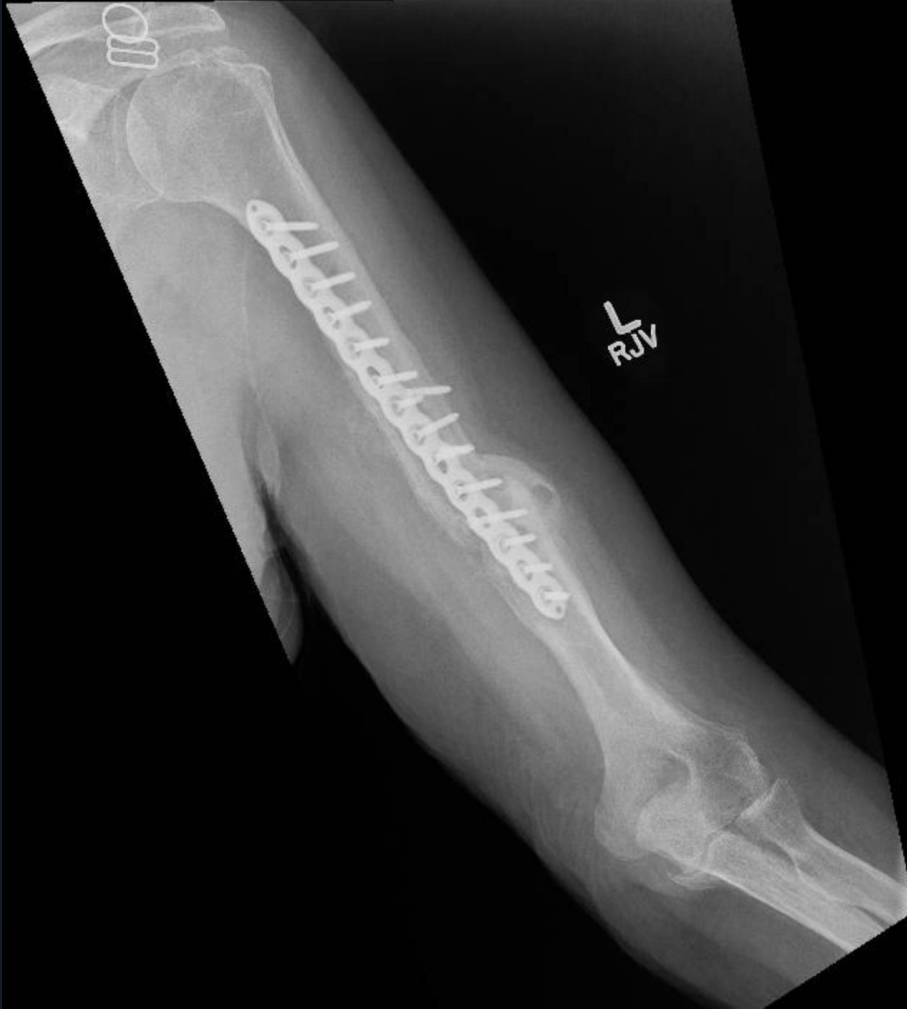
KQ 4/30/2024
@11 weeks

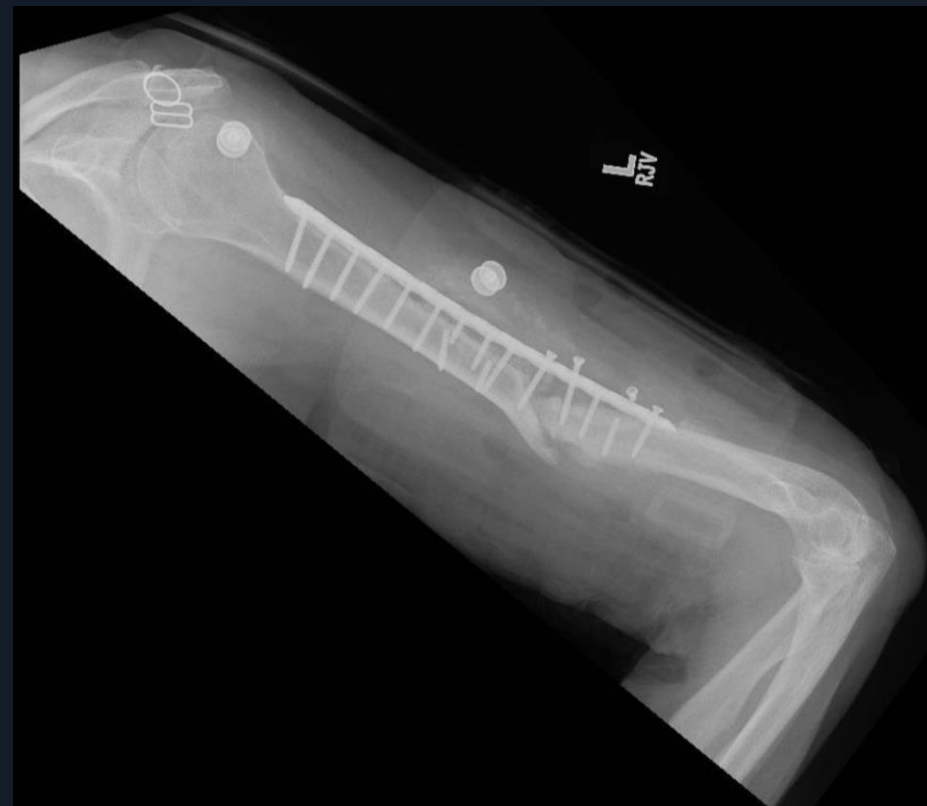
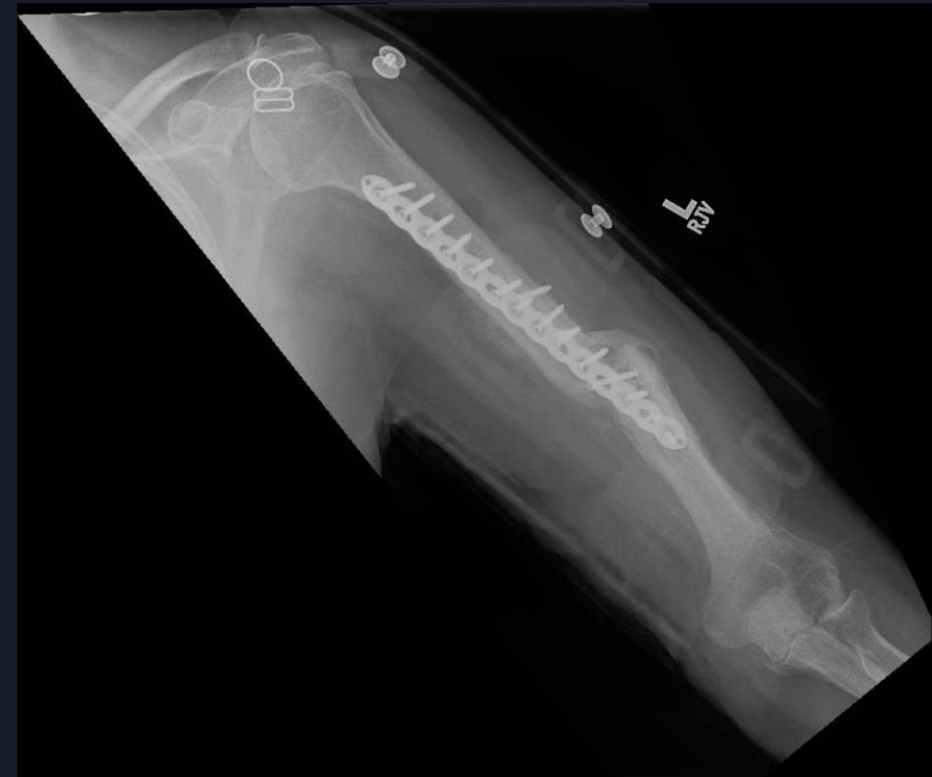
KQ 7/2/2024

5 months- Is it healing?
Screw backing out

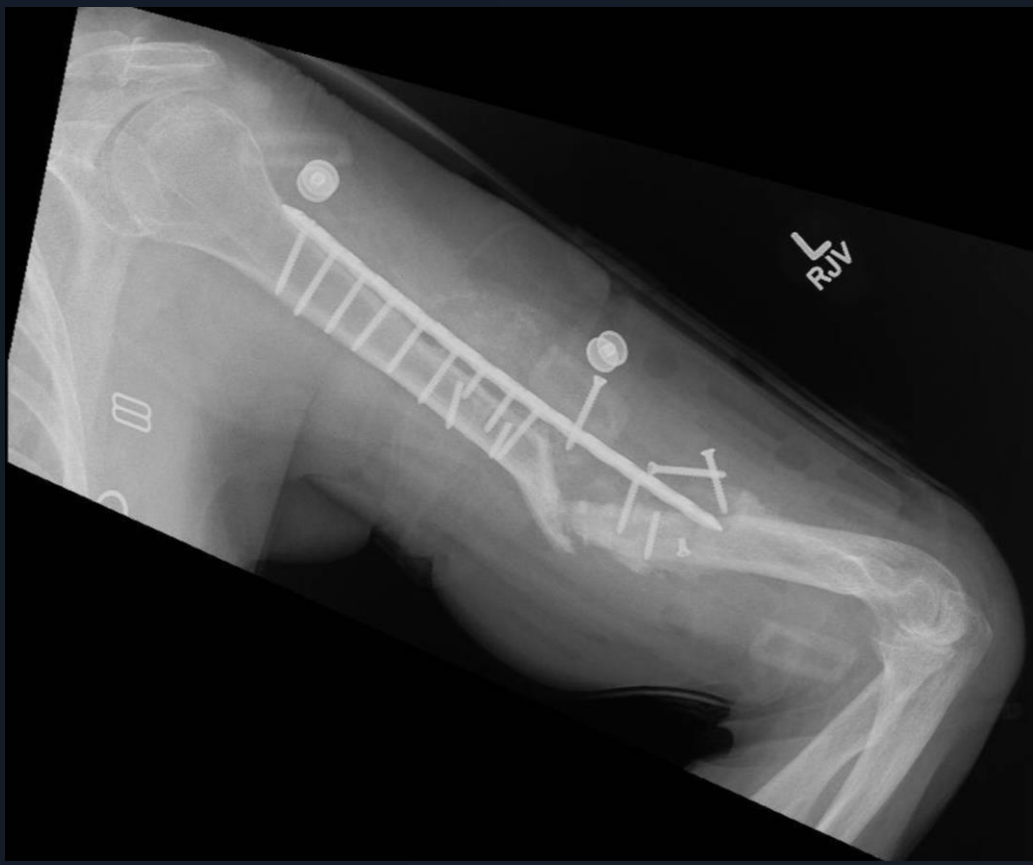
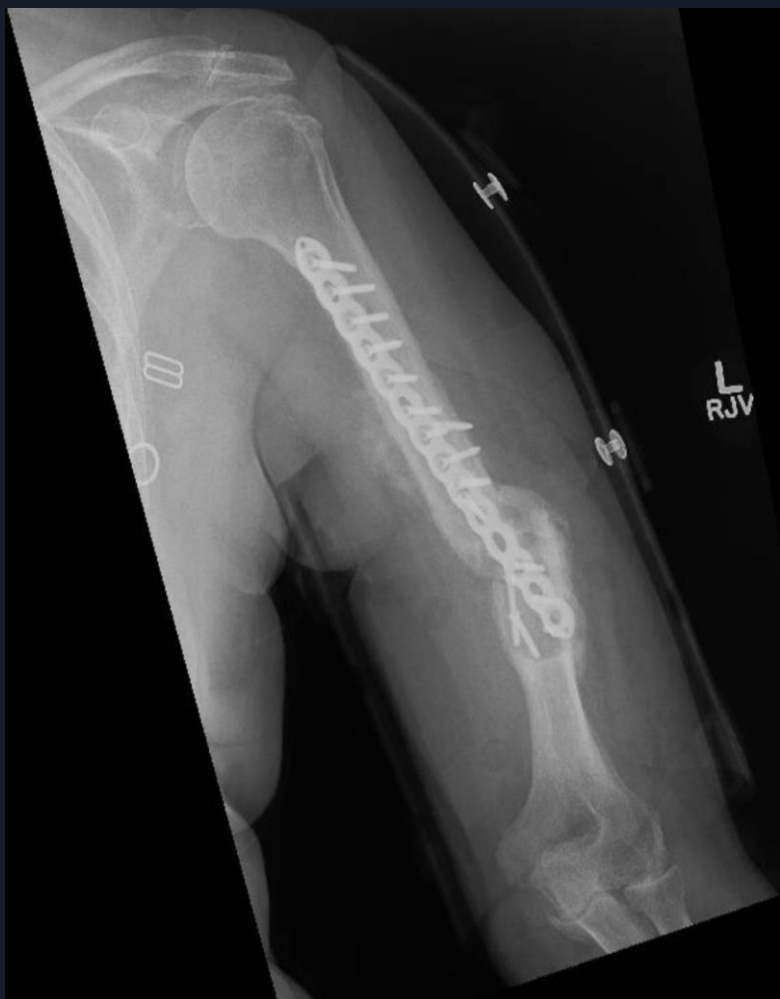
KQ 7/30/2024
6 mos- HWR failing



KQ 9/3/2024

@ 7 mos-Pseudoarthrosis- No Infection



Now What?

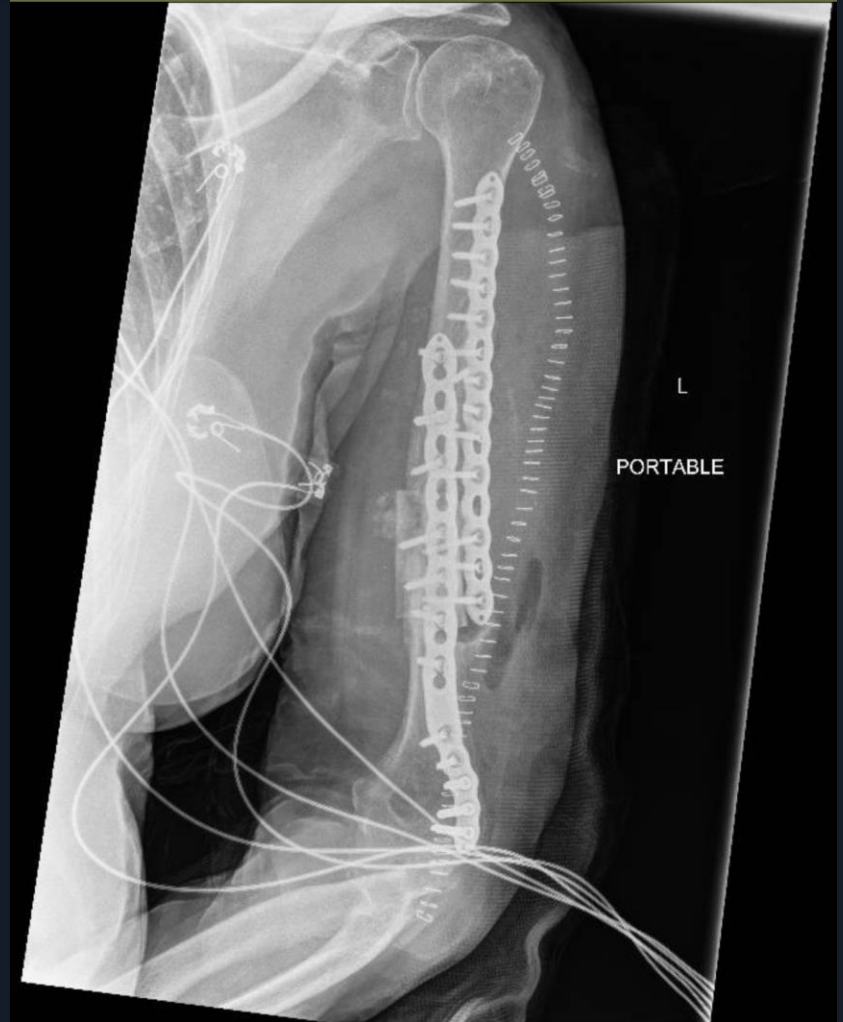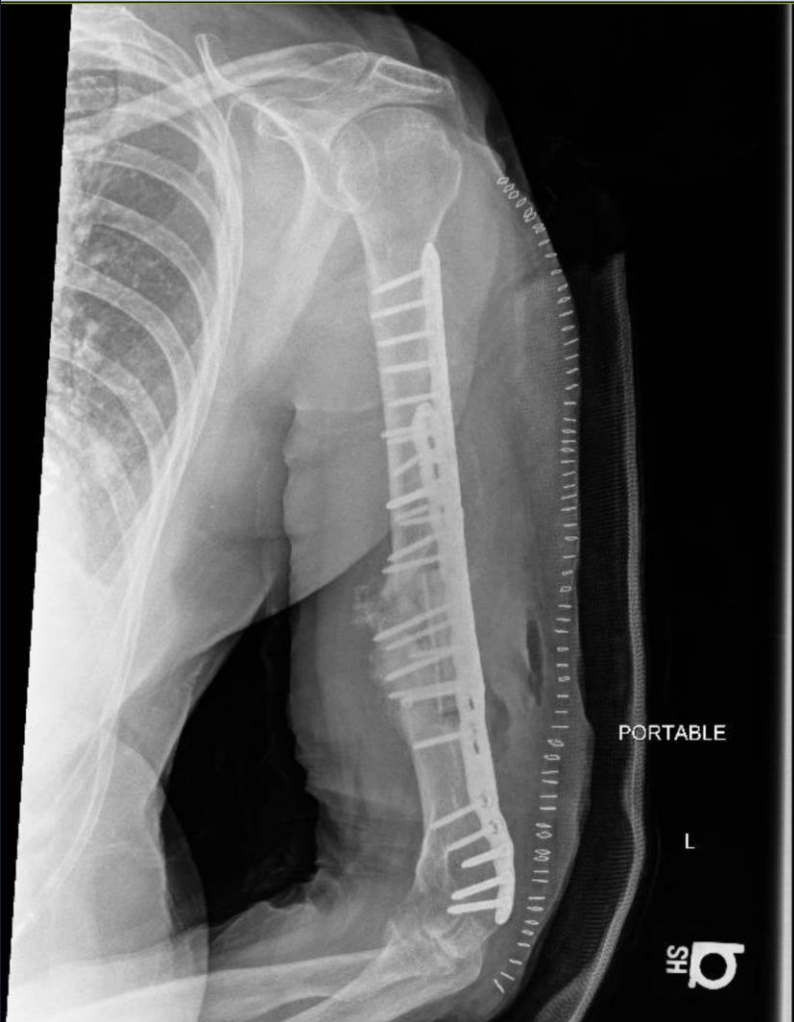Revision

Approach

Hardware

Graft

KQ 9/17/2024- Op #3 double plated- fibula intercalary graft



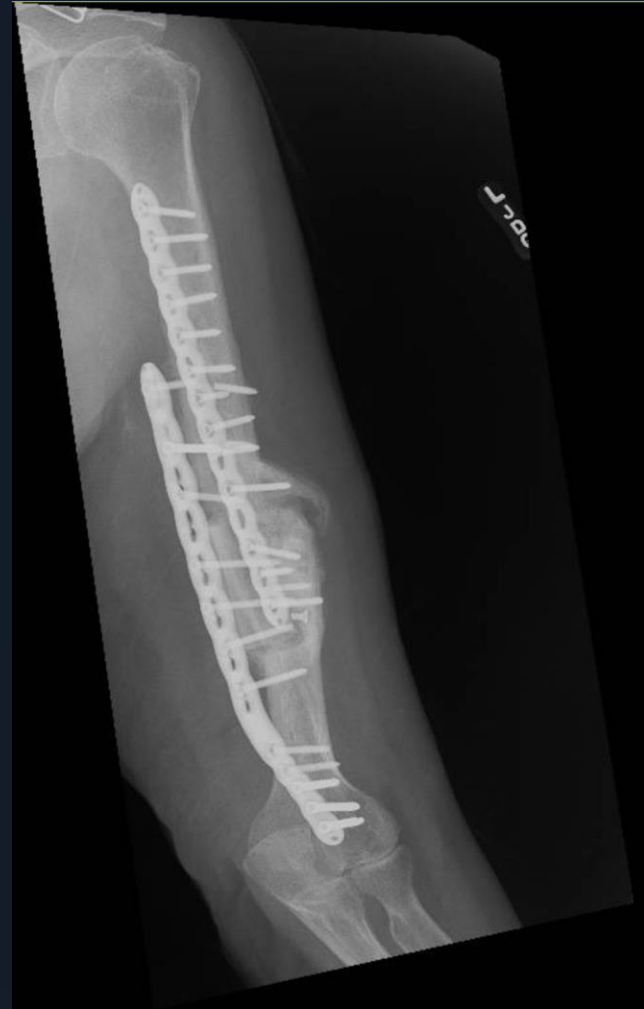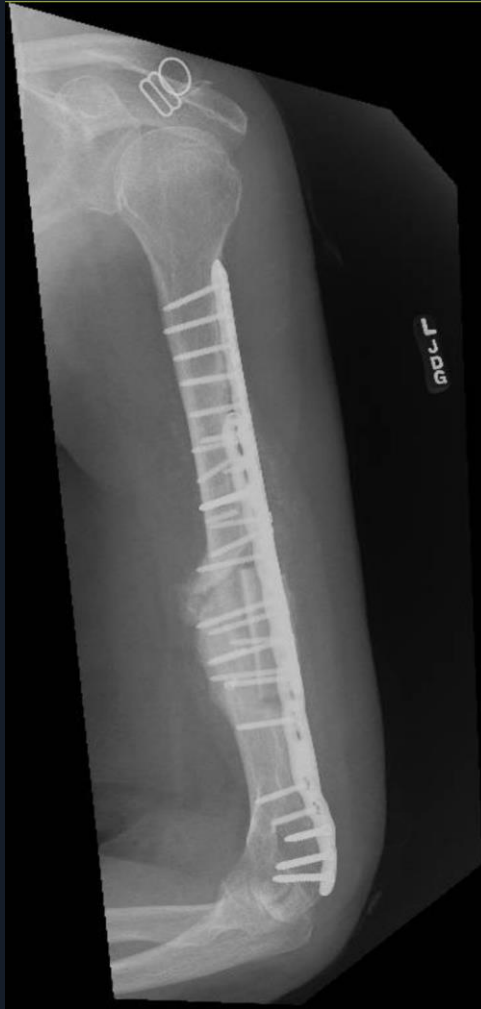Critique

Reduction

Hardware

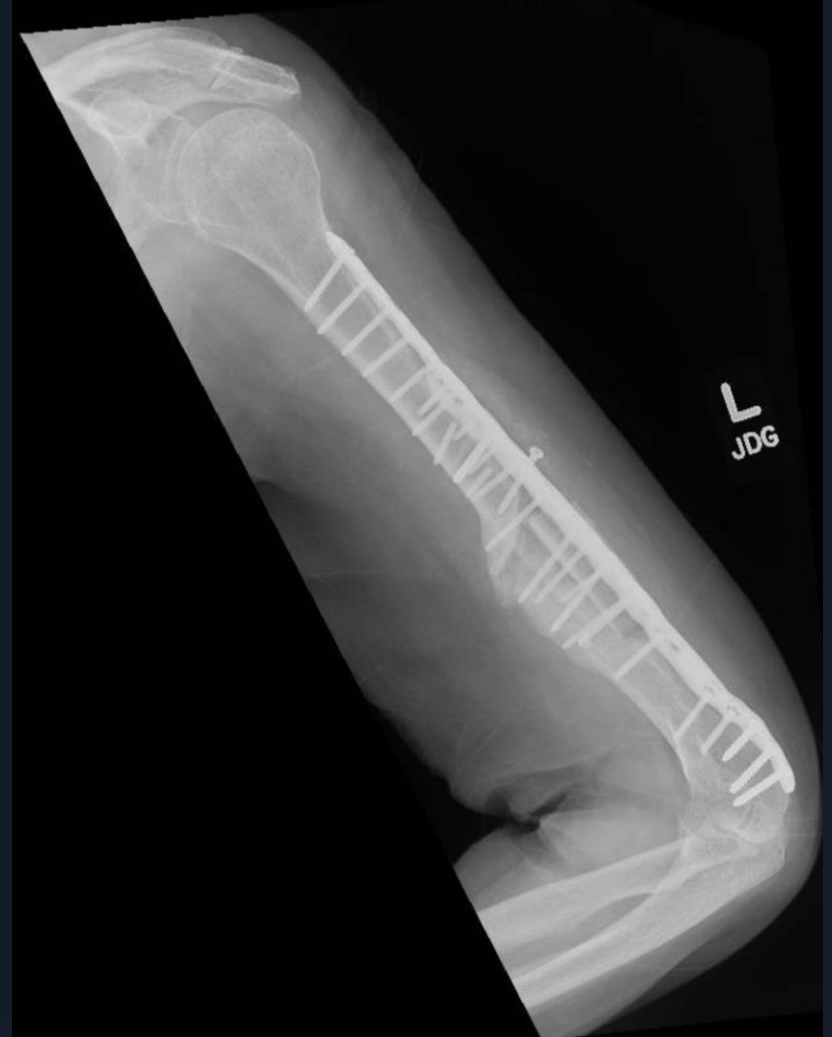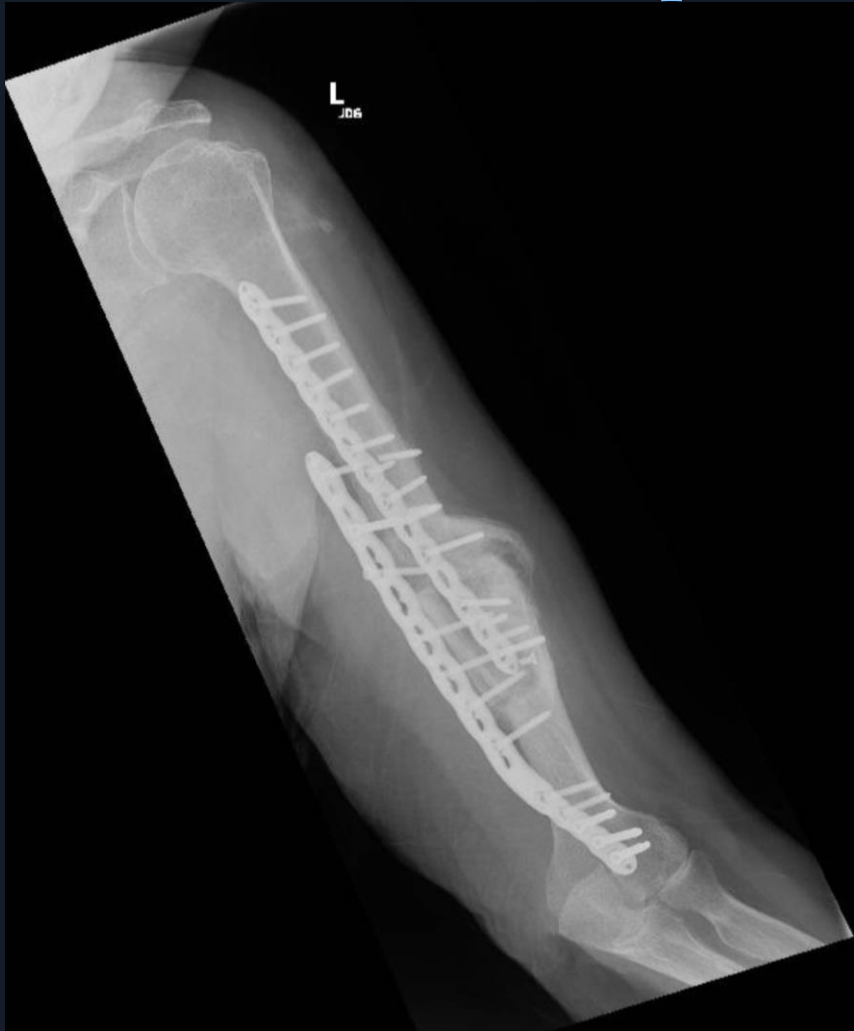Graft

KQ 11/5/2024
6 weeks stable



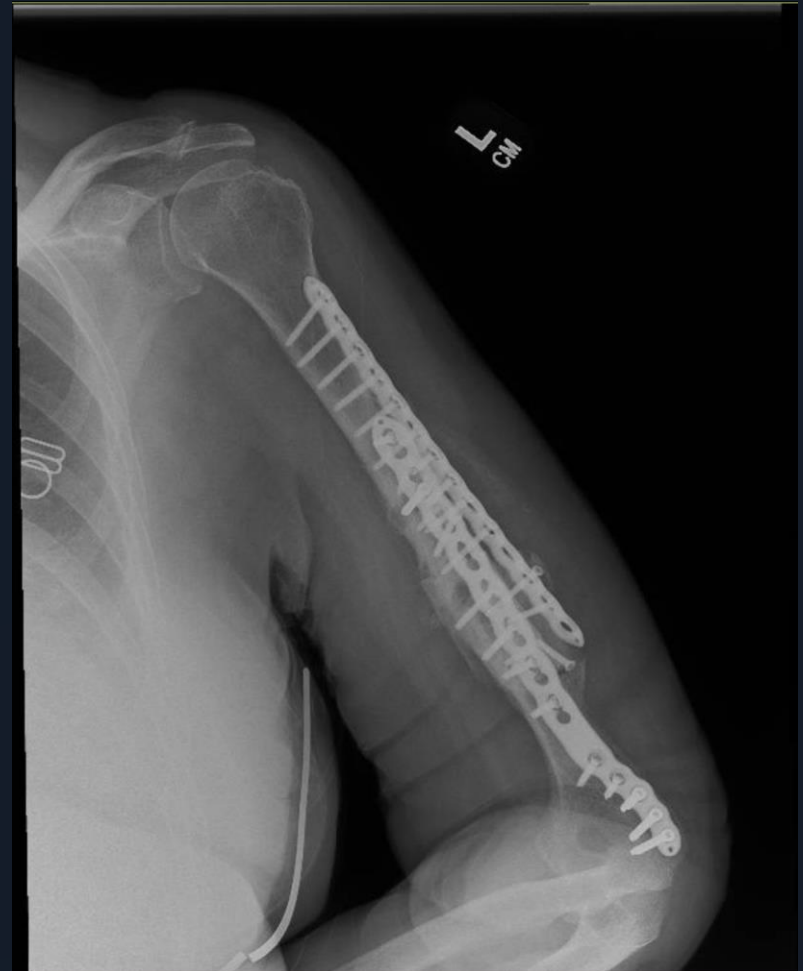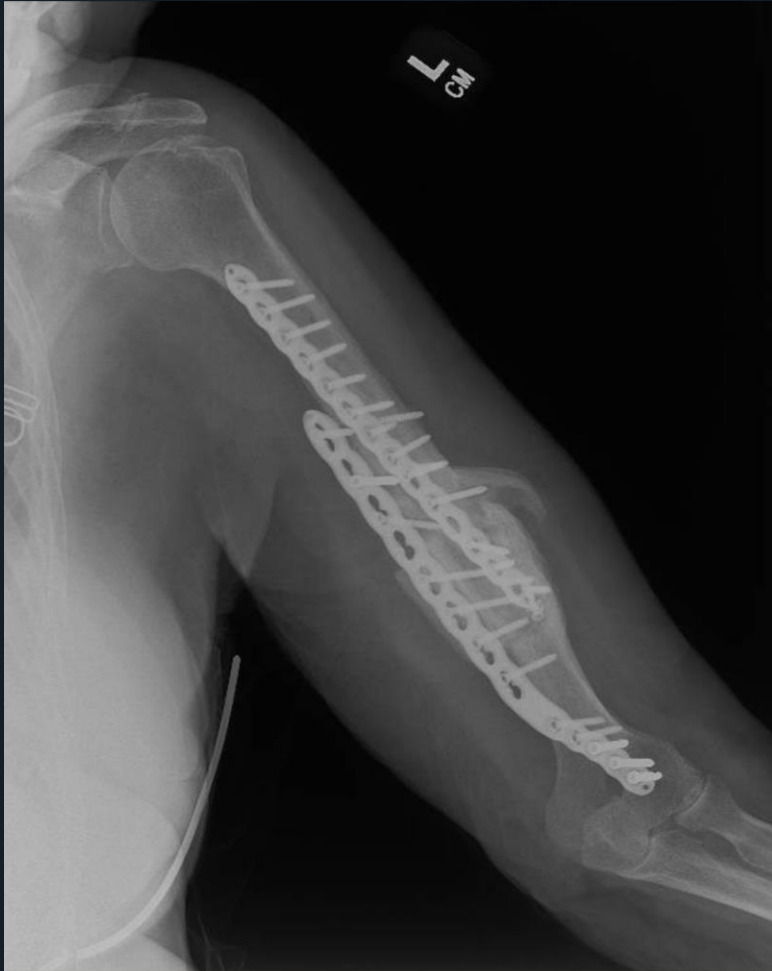KQ 12/17/2024

3 months p.o.- screw loosening



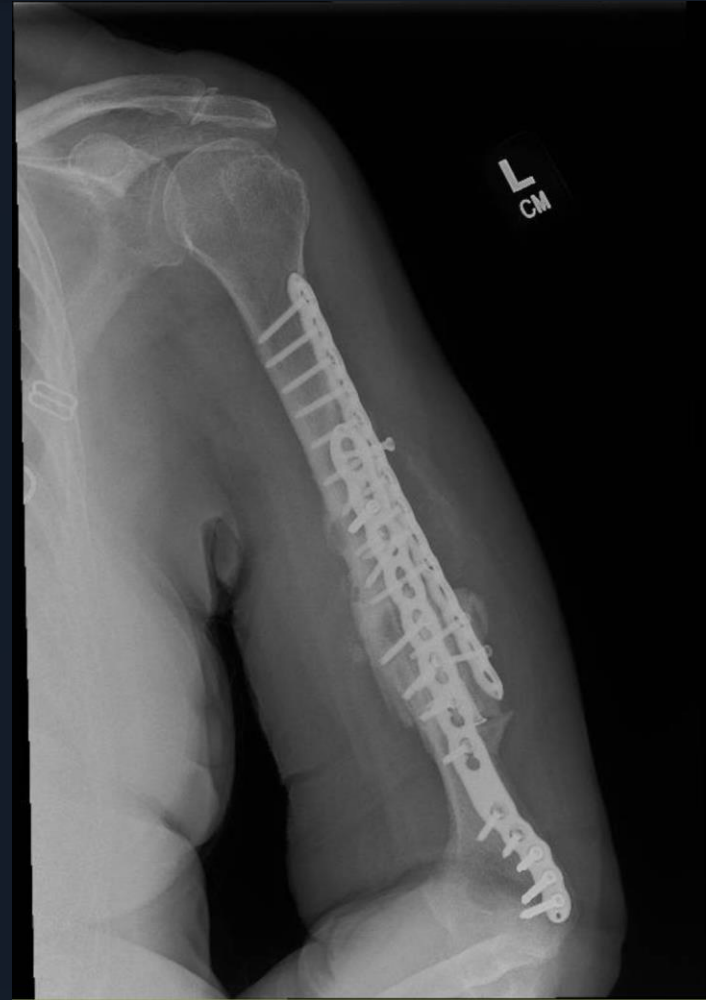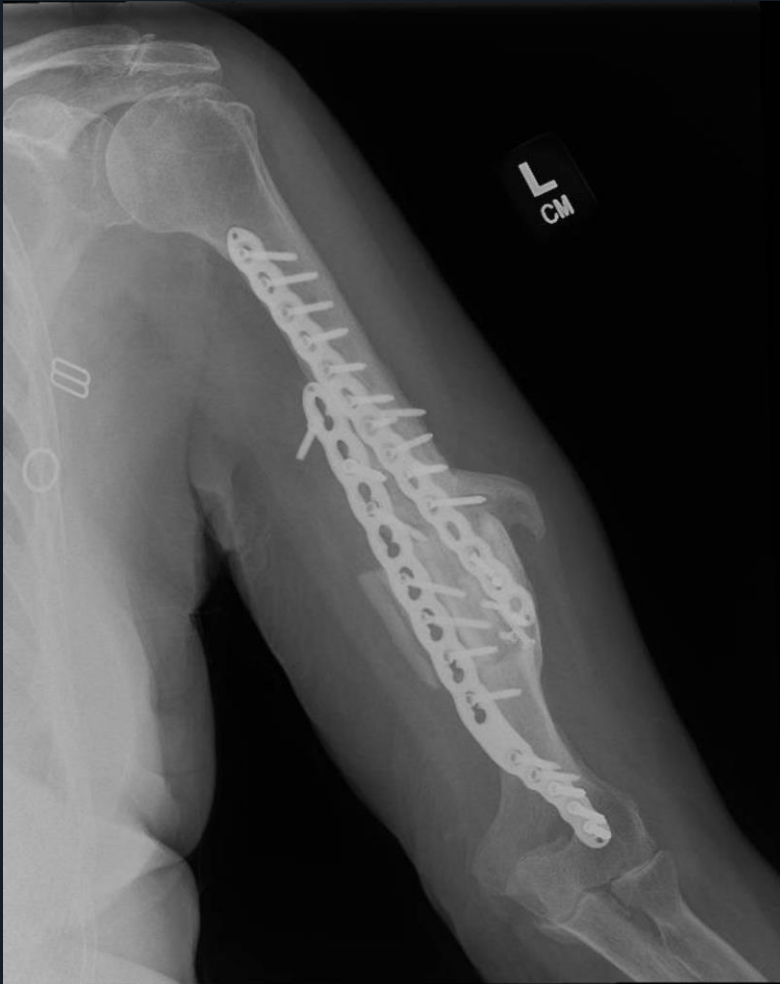KQ 2/26/2025

5 mos p.o. Patient asymptomatic
Progressive healing noted



KQ 4/15/2025

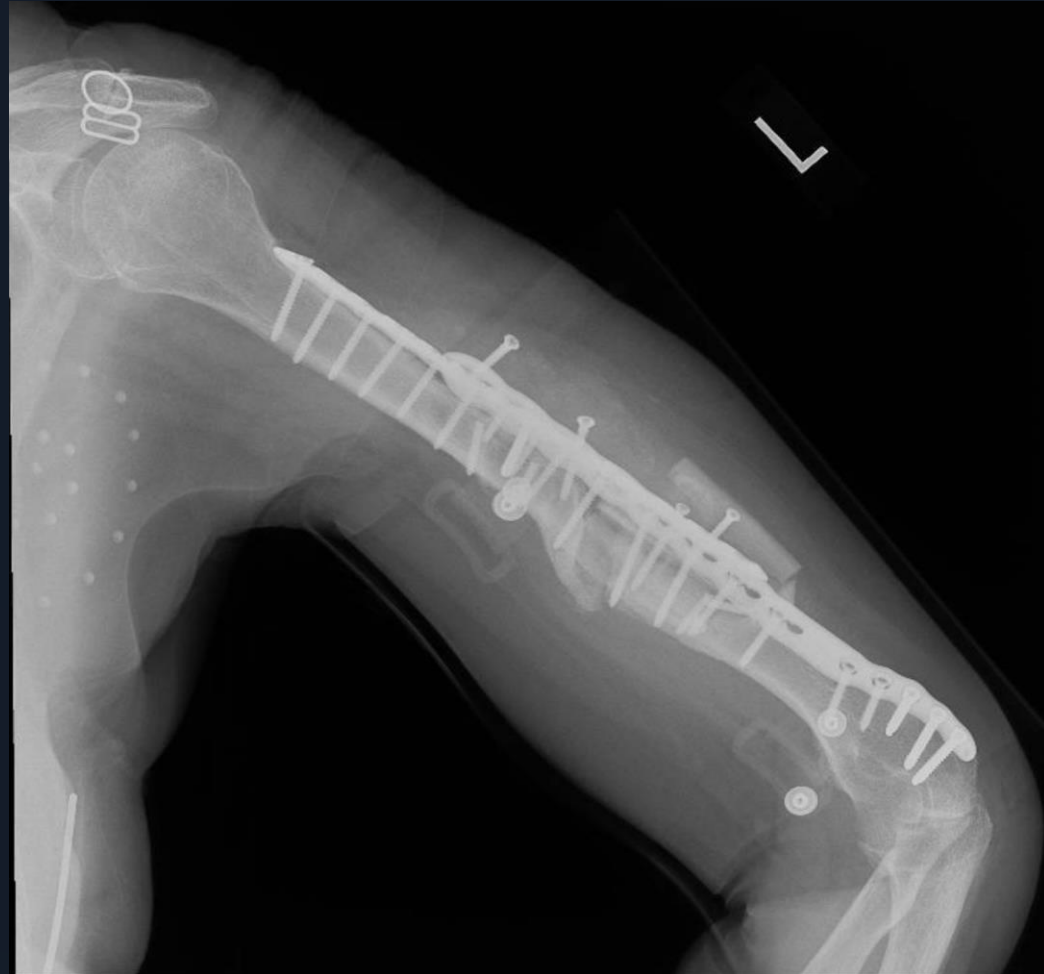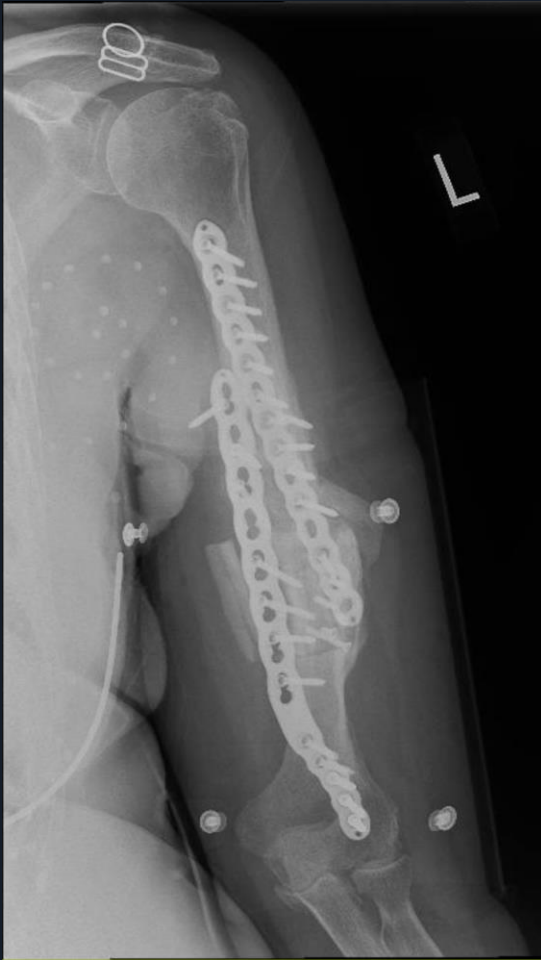7 mos p.o.- HWR loosening
Plan?



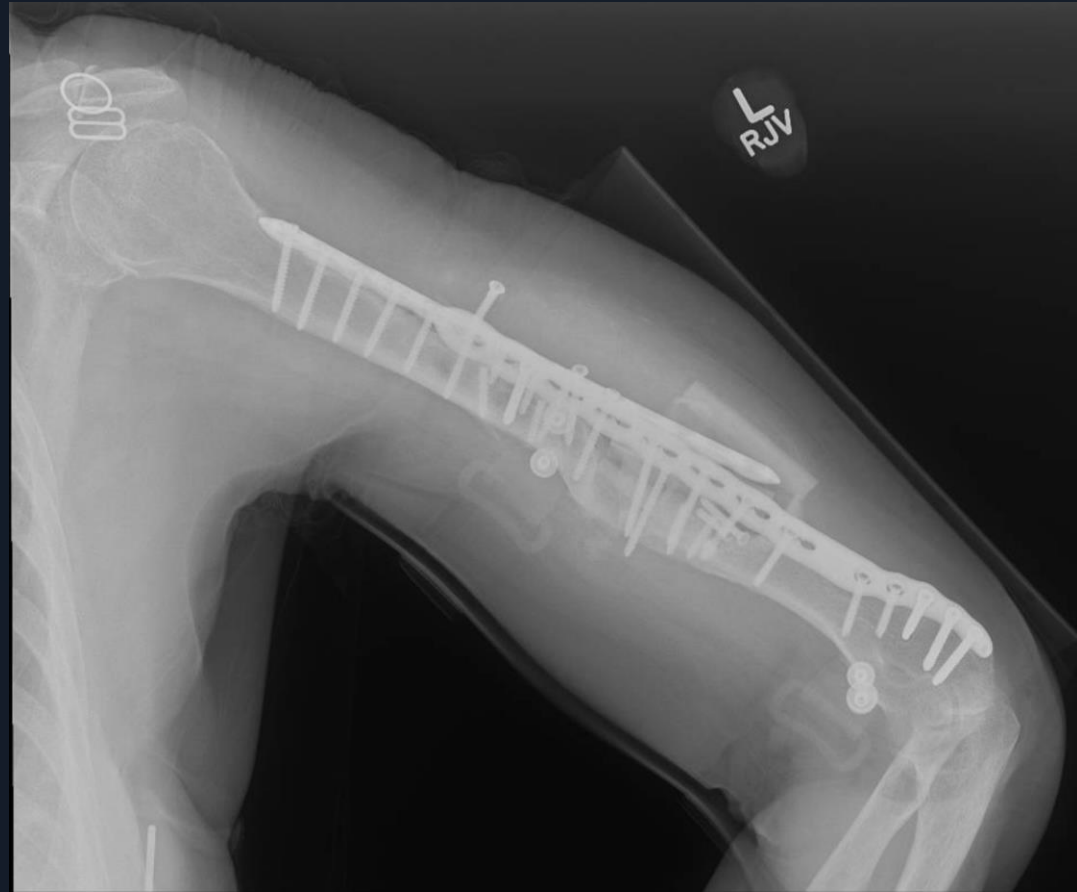
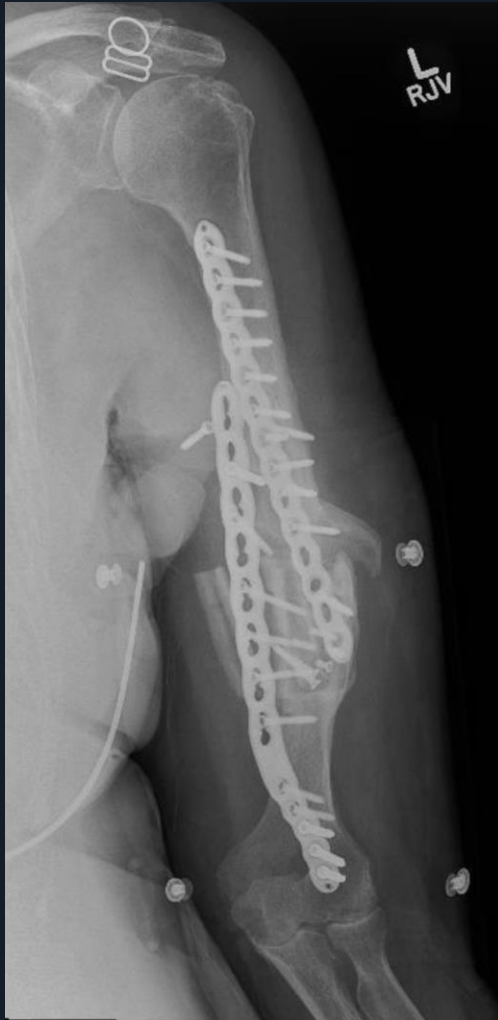KQ 6/3/2025

9 mos p.o.

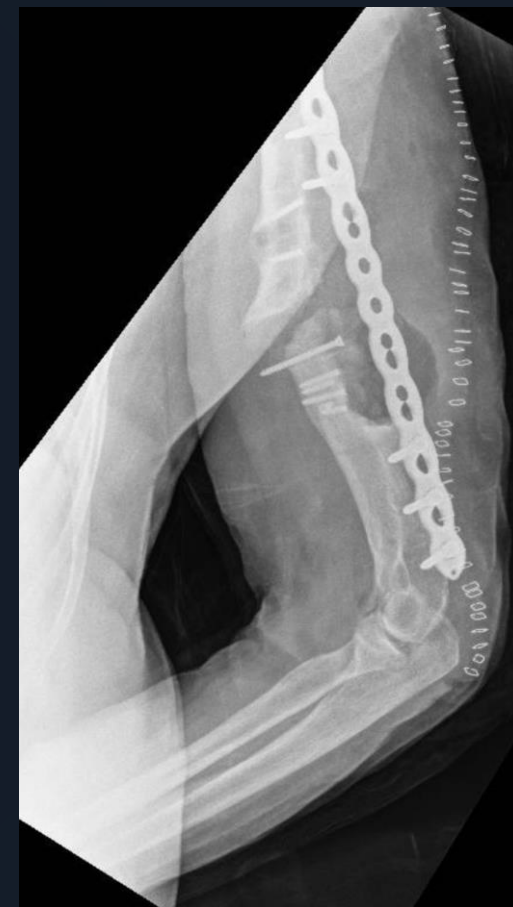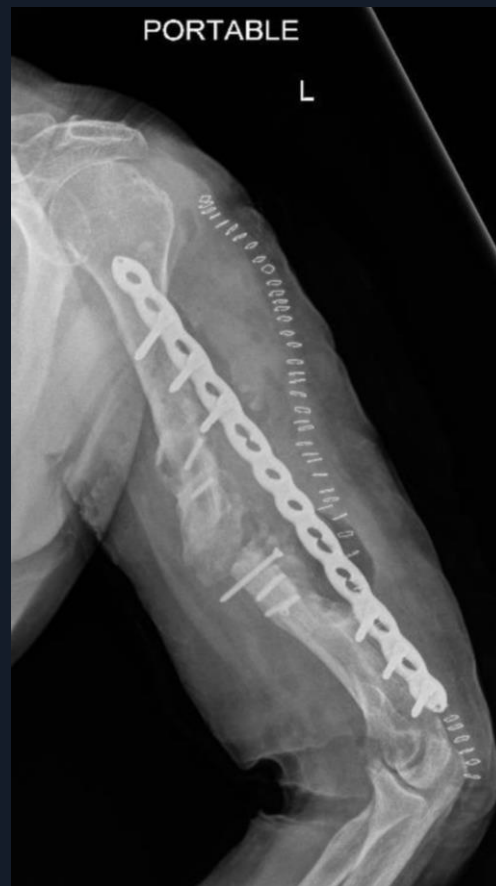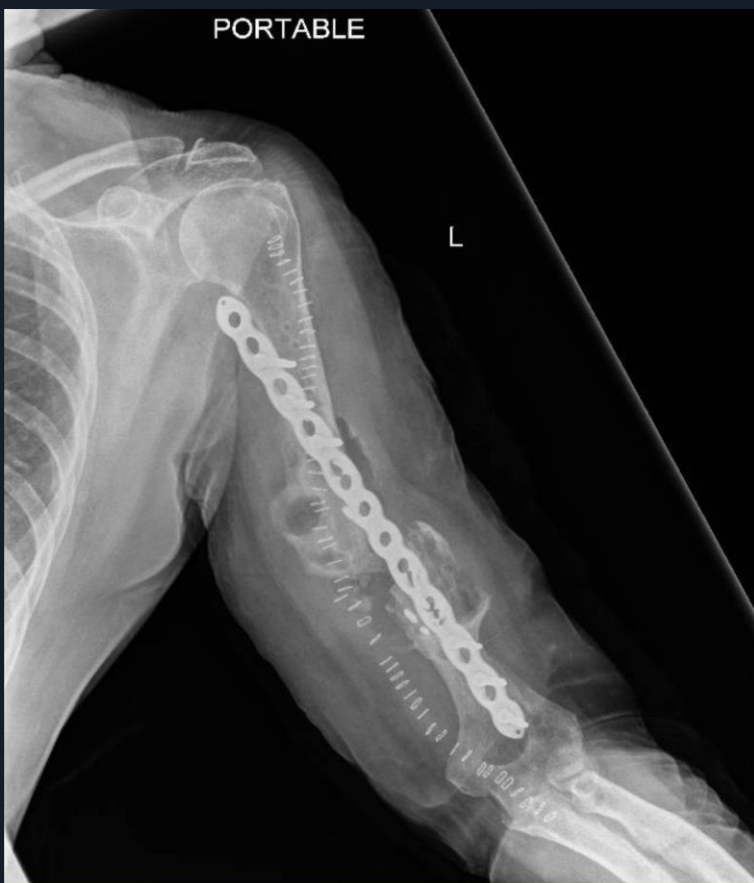Patient some discomfort



KQ 7/29/2025
10 months p.o.



KQ 9/8/2025 Revision- Op # 4 marked caseous material seen at NU Concern for TB- only Bridge plate placed



Caseous material seen at Surgery

Final Pathology

Fibrinoid Exudate

All cultures including AFB and Fungus Negative

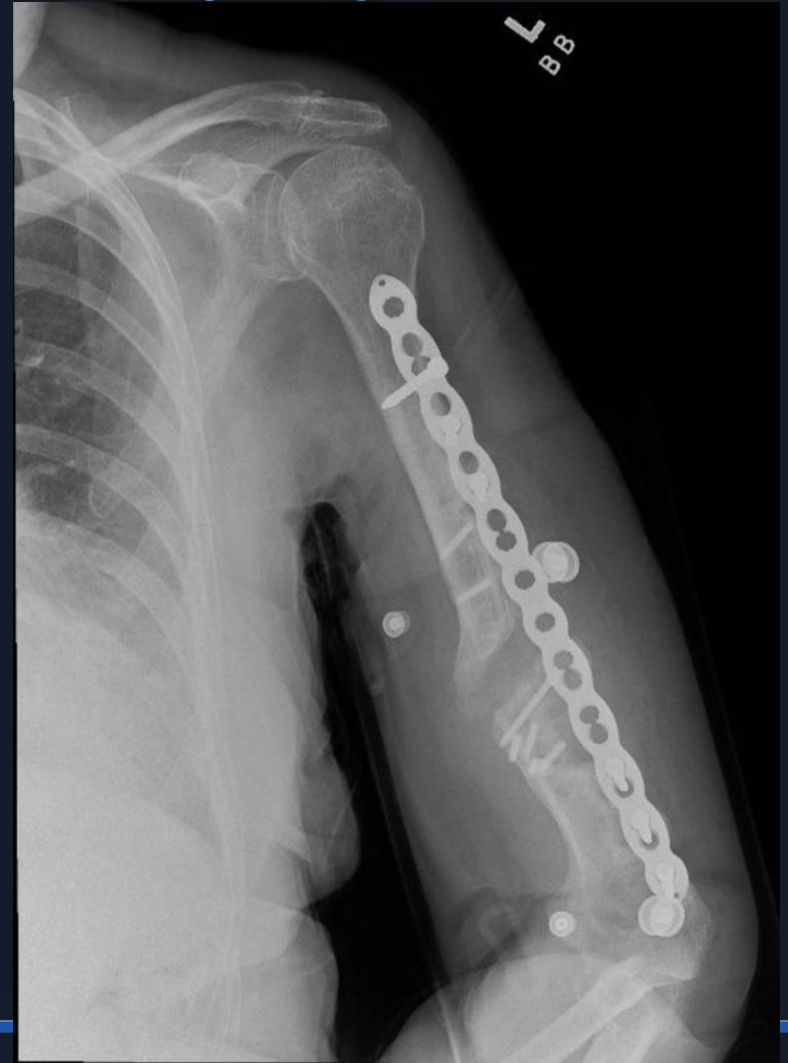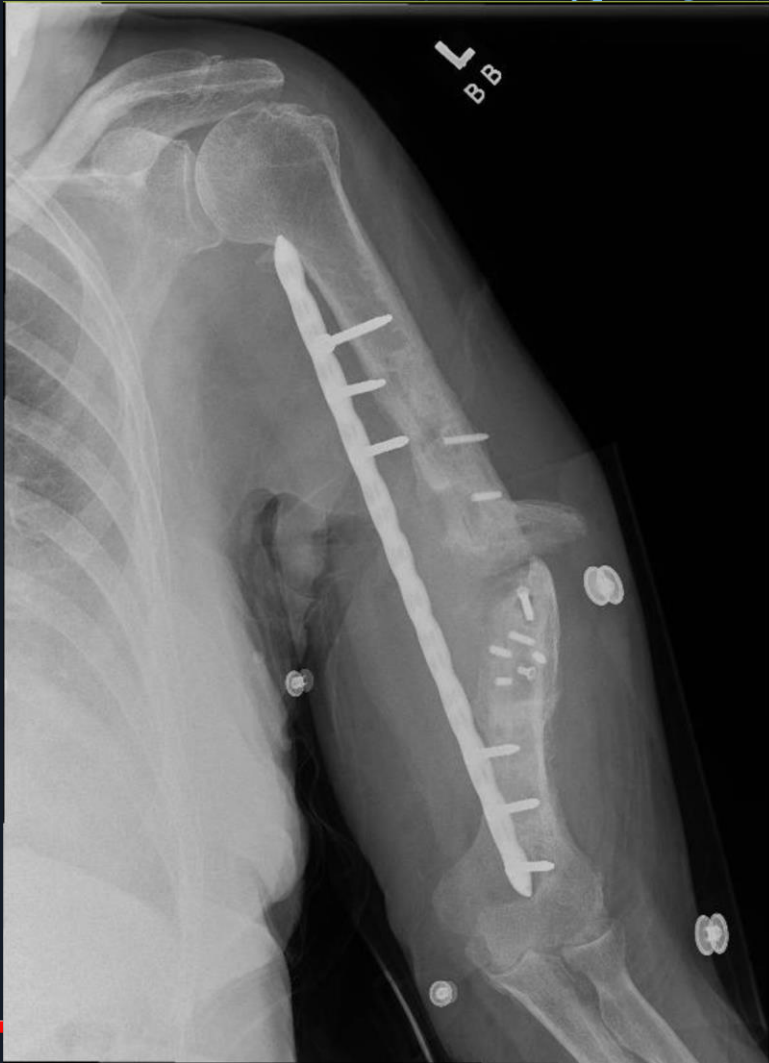**Concern for metabolic Bone Disease and Endocrine
consulted**

W/U Neg for significant osteoporosis

Patient placed on 4 months of Forteo anabolic

Prior to planned next surgery

KQ 2/3/2026 pre-op
3 years post original fracture- Pseudarthrosis
Taking Forteo X 4months



Now What?

Approach

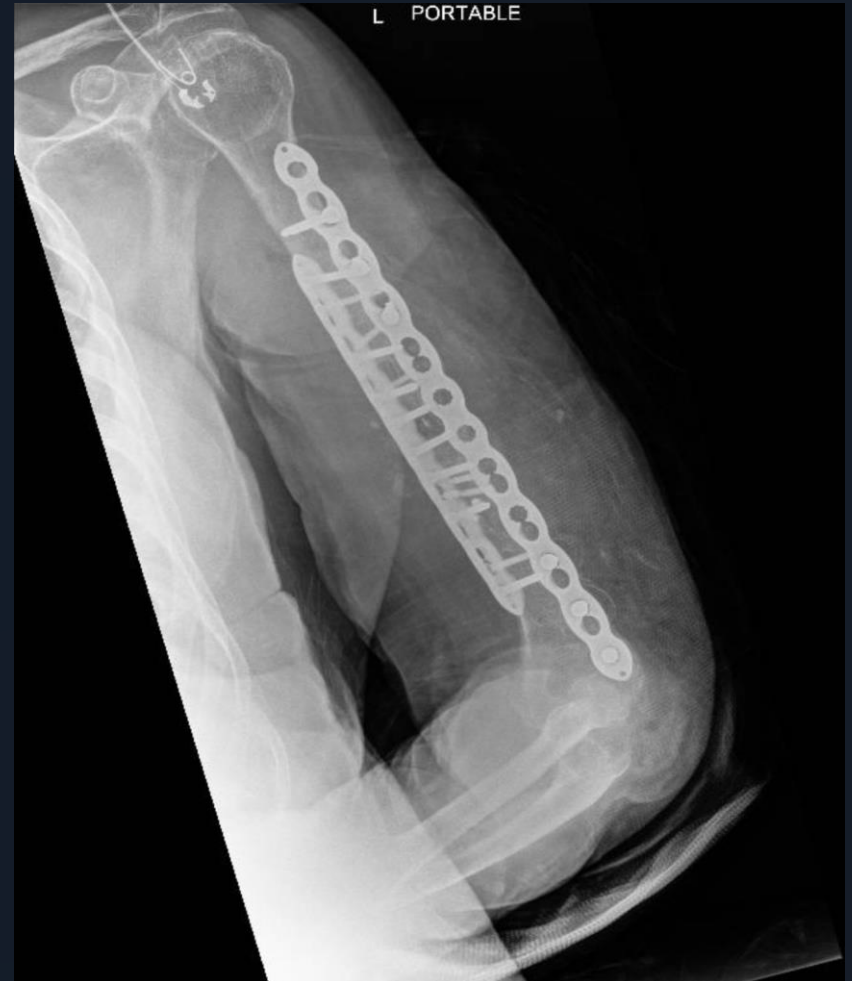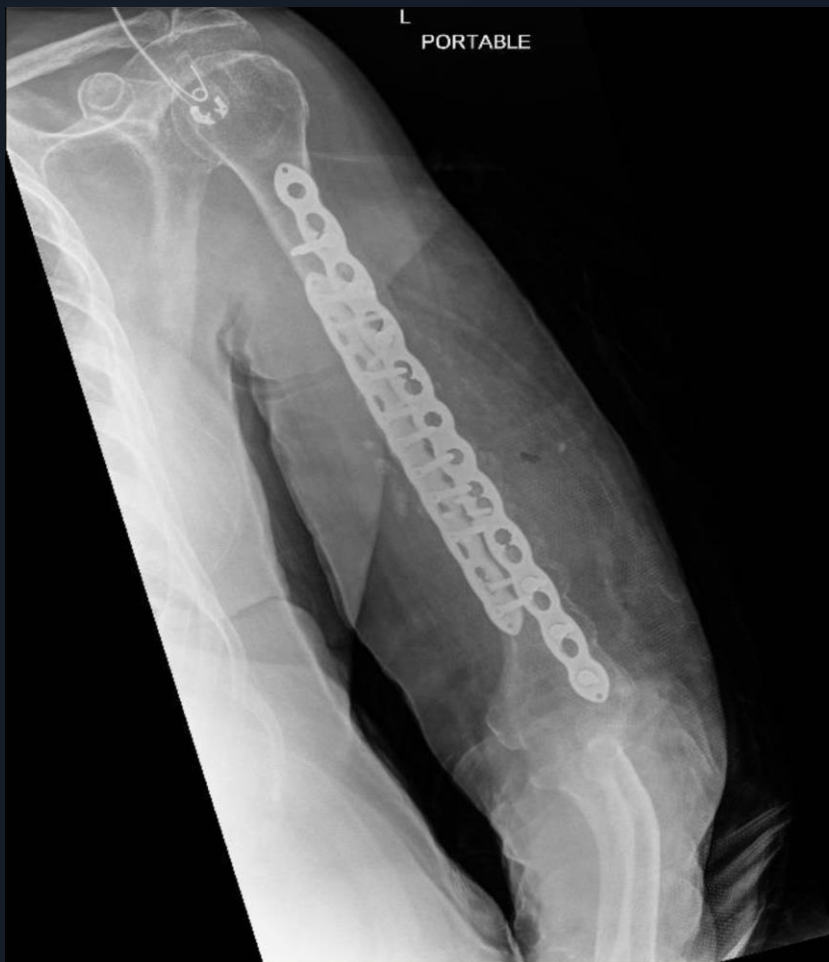Hardware

Bone Graft

KQ 3/23/2026- OP # 5

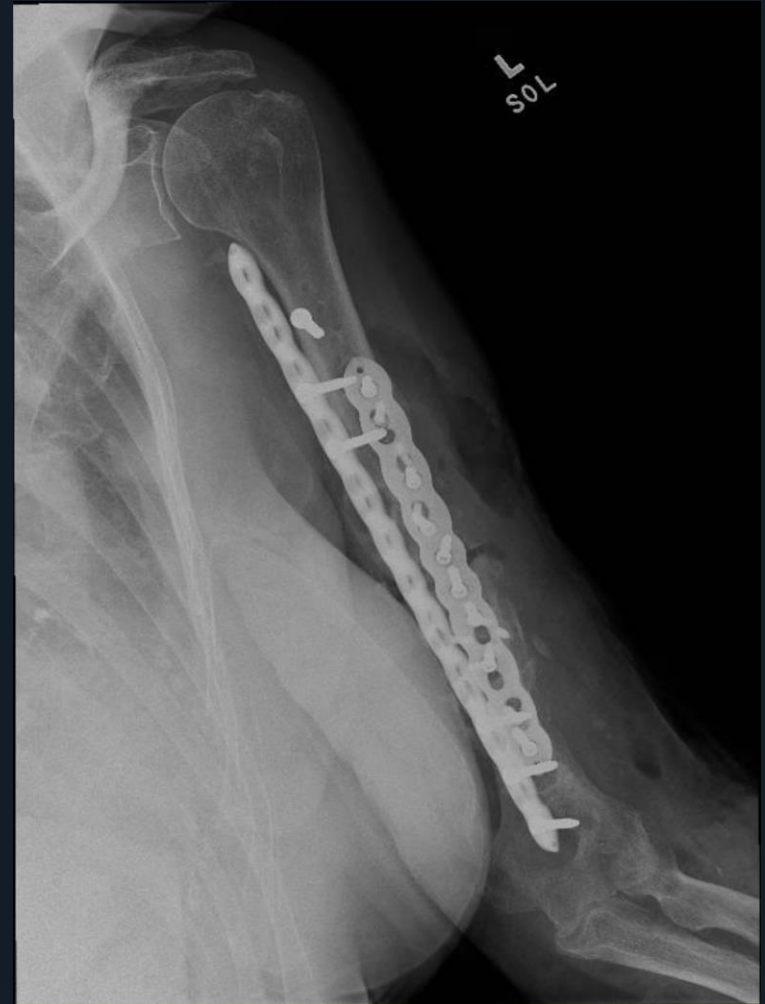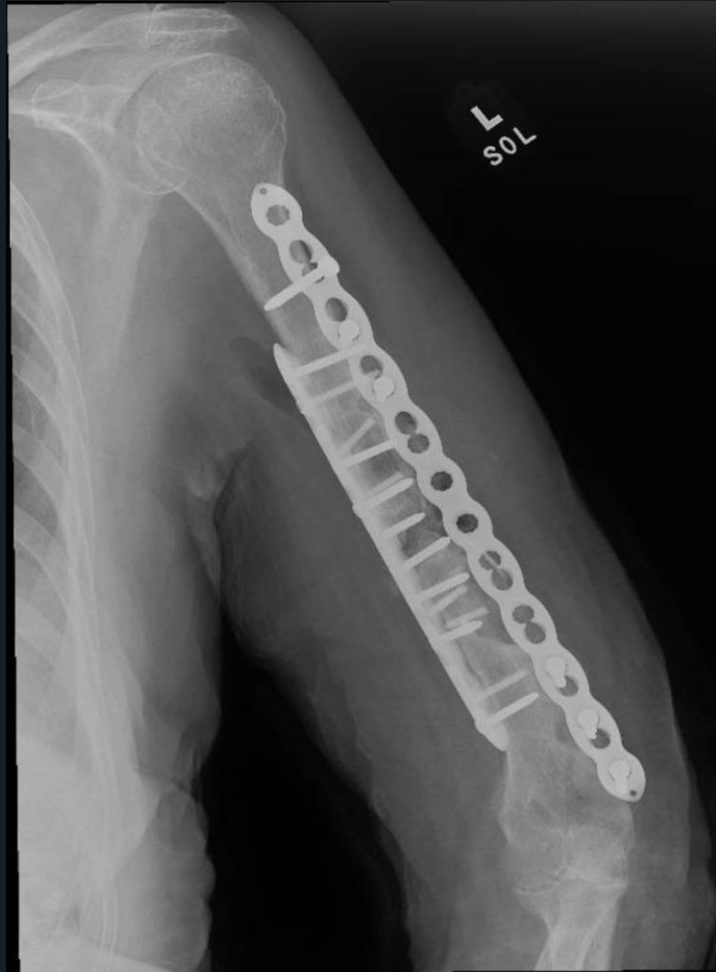Ant-Lat approach

Double Plating –Iliac Cortico-cancellous graft



KQ 4/7/2026

So Far So Good



Thank You I'll let you know if it heals

AMAZING
THINGS
ARE
HAPPENING
HERE

mpr2@cumc.columbia.edu