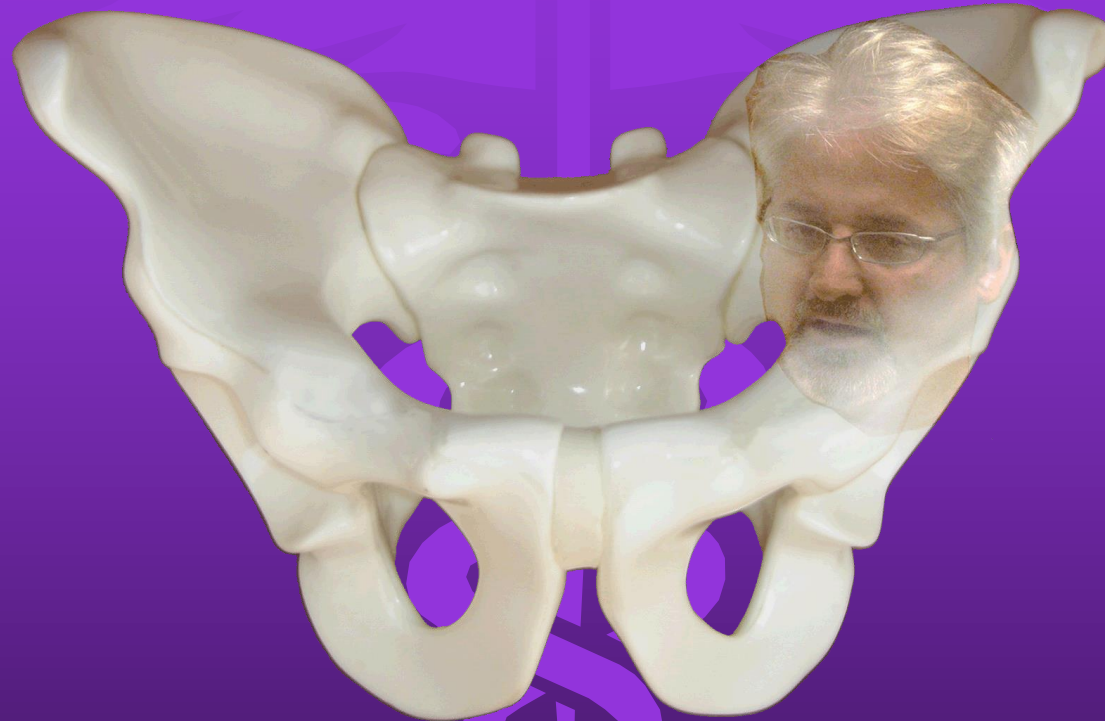

Kyle F. Dickson, M.D. M.B.A.



Professor Baylor College of Medicine
Southwest Orthopaedic Group, Houston, Texas
kyledickson99@gmail.com cell 713-208-4168

Fractures of the Femoral Head in Young Adults

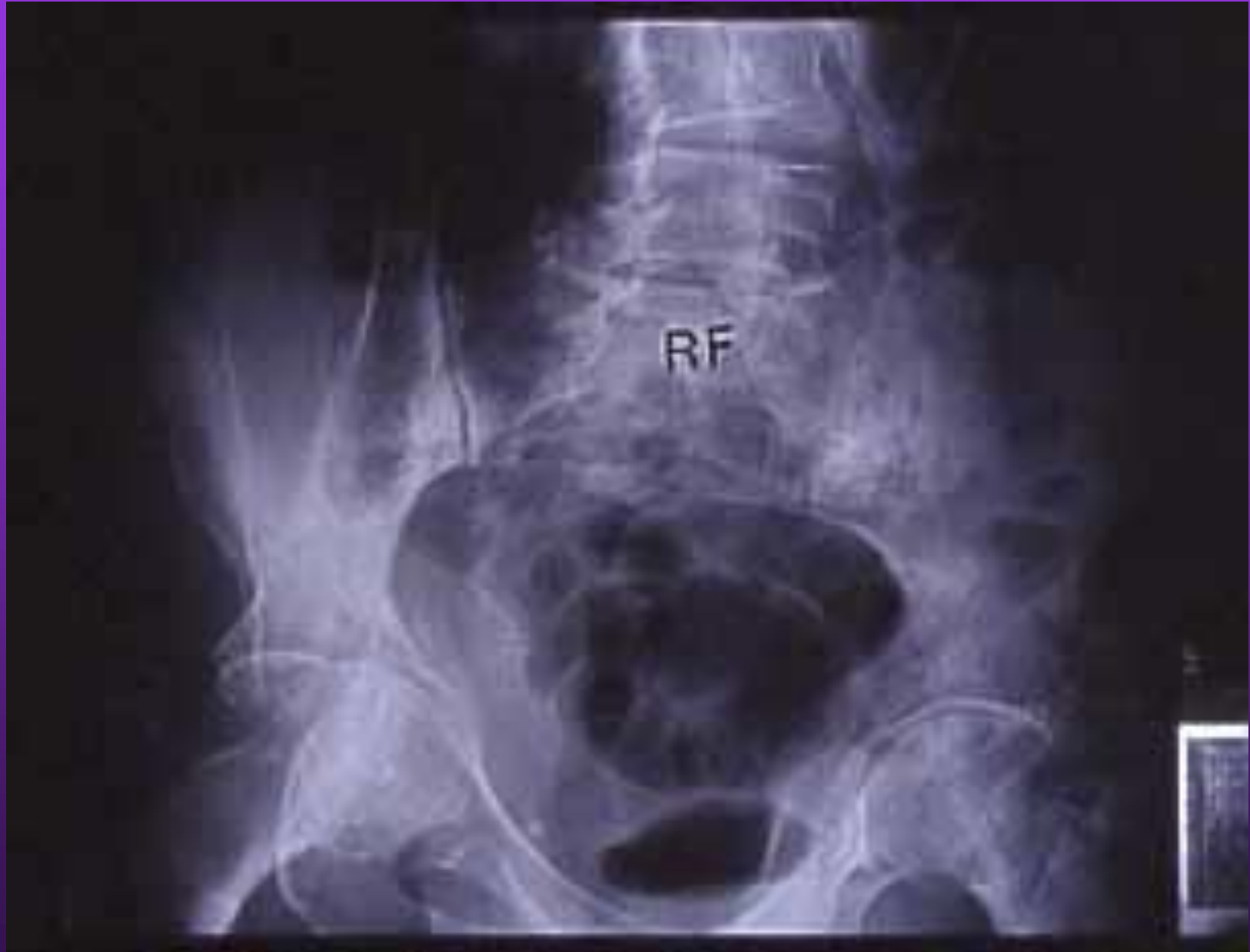

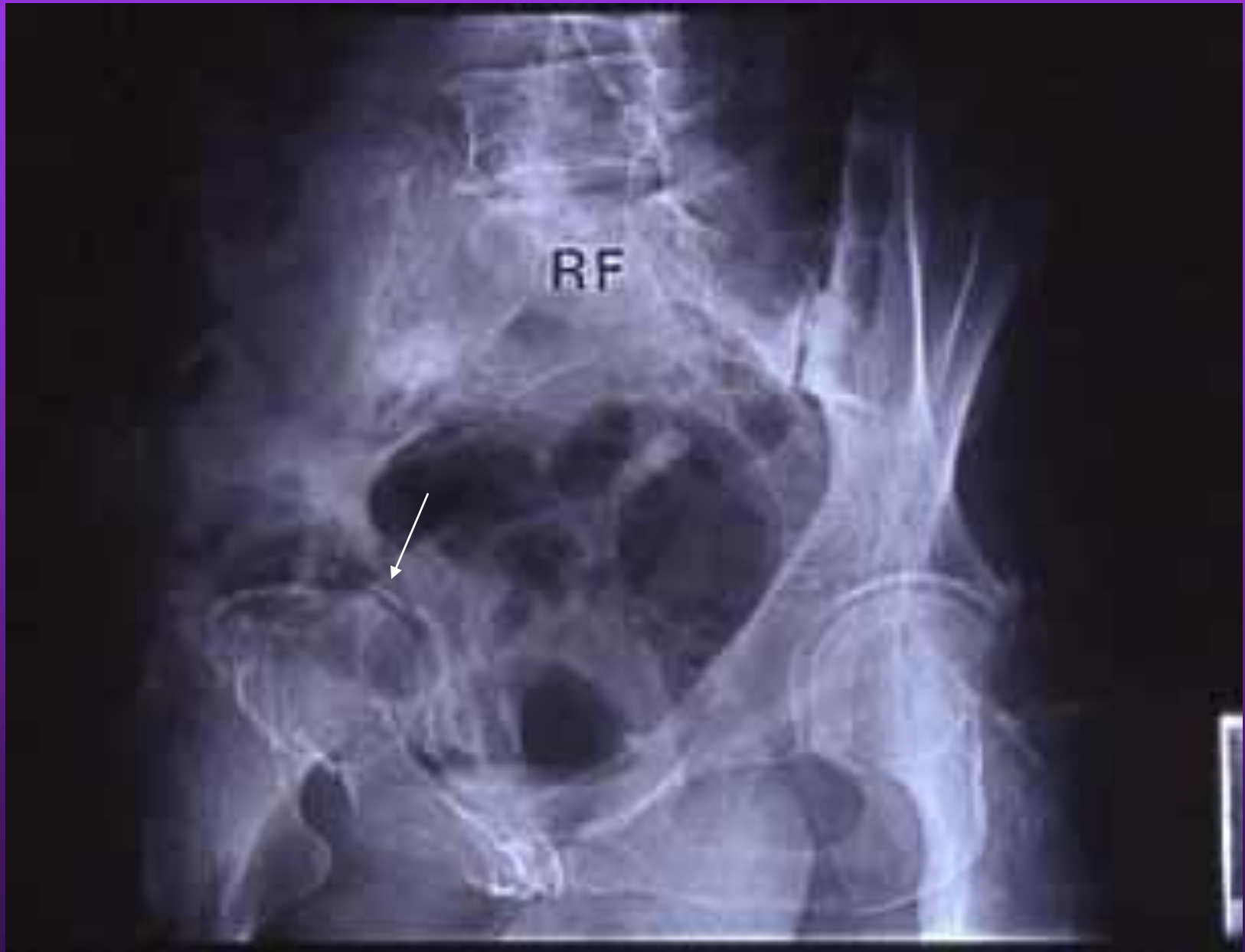Kyle Dickson MD, MBA

Professor of Orthopaedics Baylor College of Medicine

Total Hip Arthroplasty

- Never in isolated femoral head fracture
- Associated with femoral neck fracture or lateral dome impaction (never seen one with medial dome impaction)





DOPE

R
L

R

V 120
A 250*
Chart #A 213
L 1000

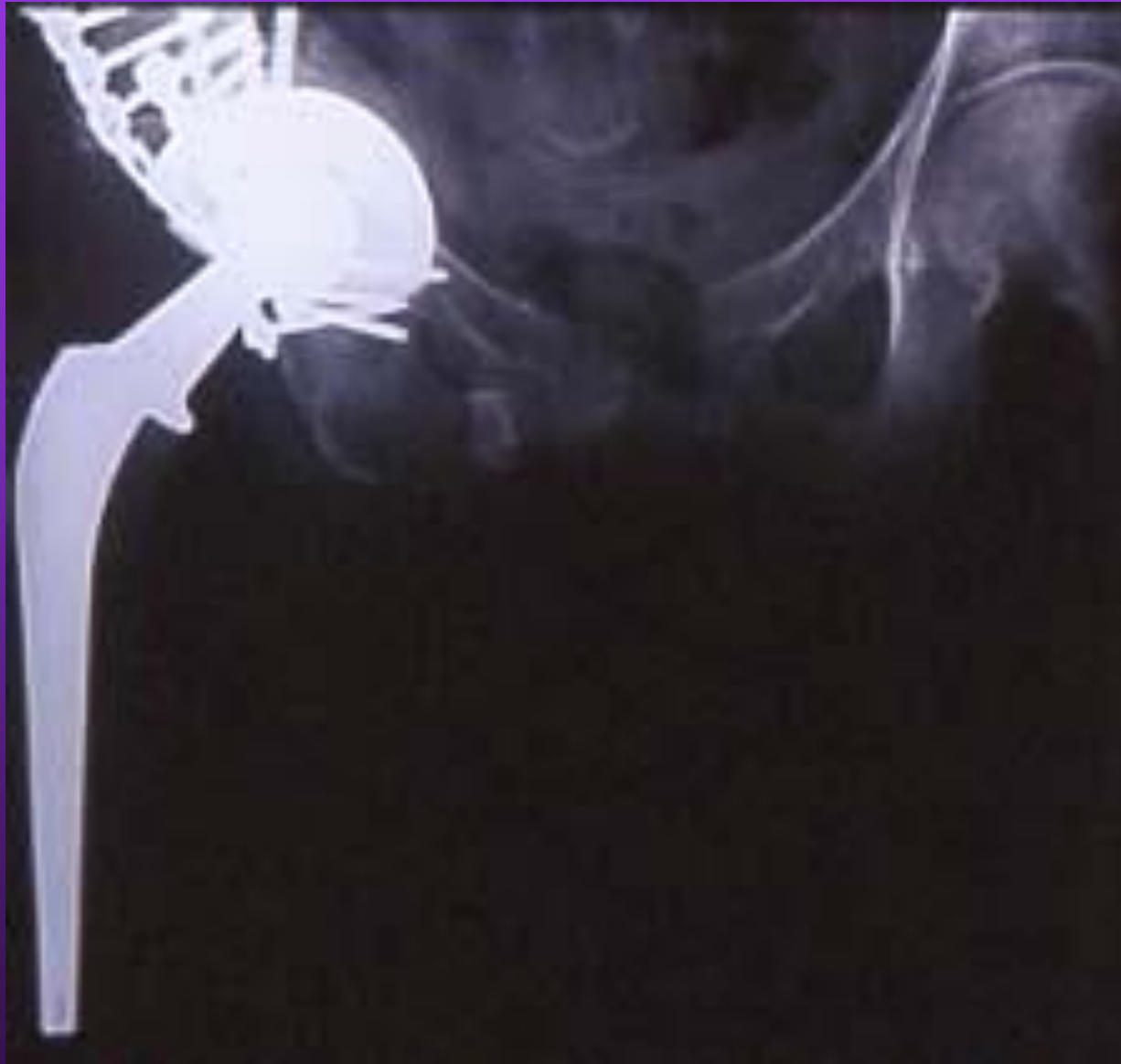

Anterior or Posterior Approach?

- Dependent on the type of fracture and what approach gives the easiest fixation (direction of the head migration)
 - II and or IF - quadrilateral surface comminution
 - KL - posterior wall

Posterior Approach


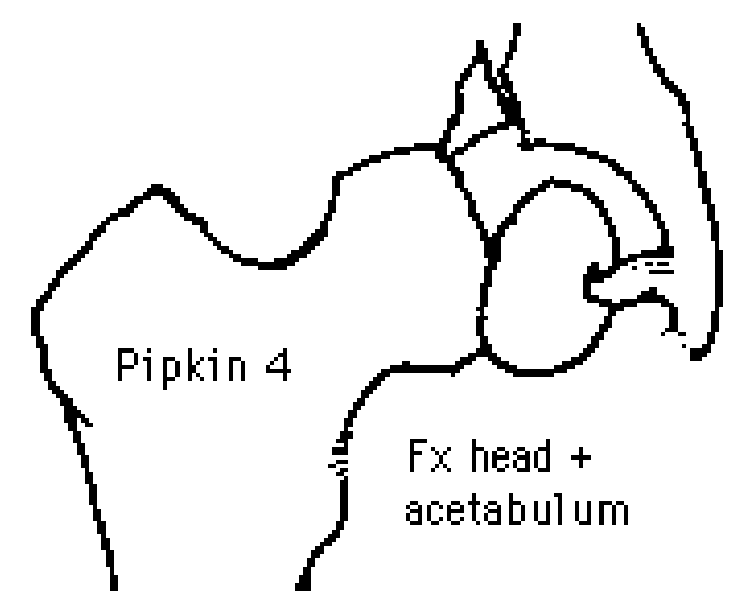
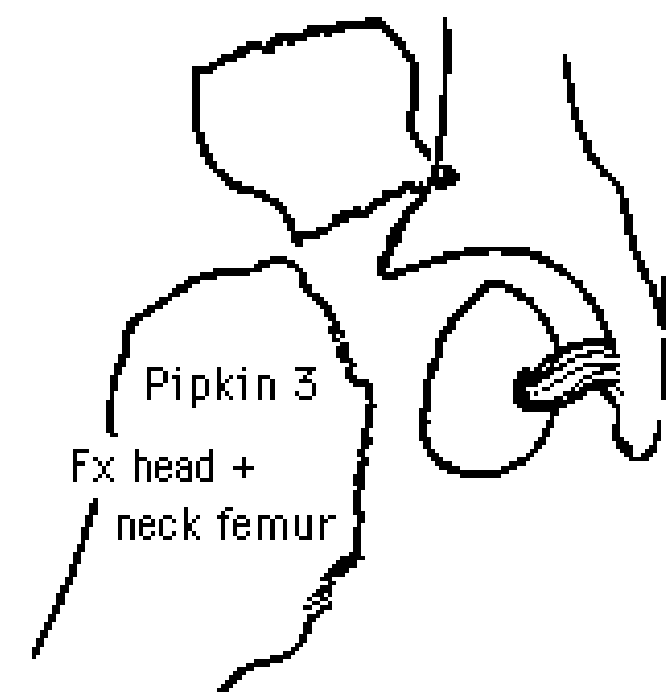
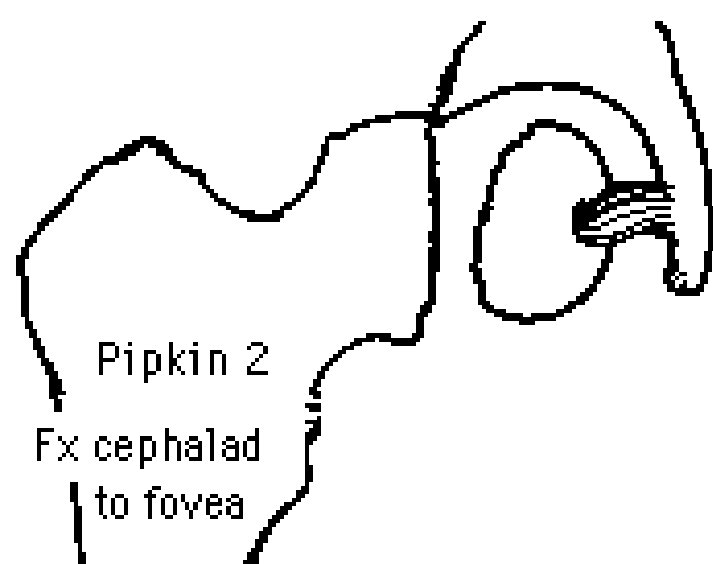
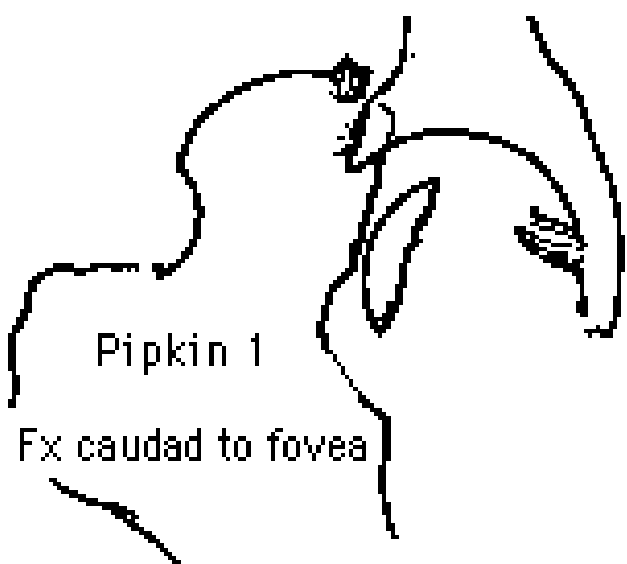
- KL for both fixation of acetabular fracture and THA (Femoral and dome impaction, OA) (Boraiah 2009)
- May do II to fix acetabular fracture but always KL for THA (?osteoporosis) (Herscovici 2010)





FEMORAL HEAD FXS

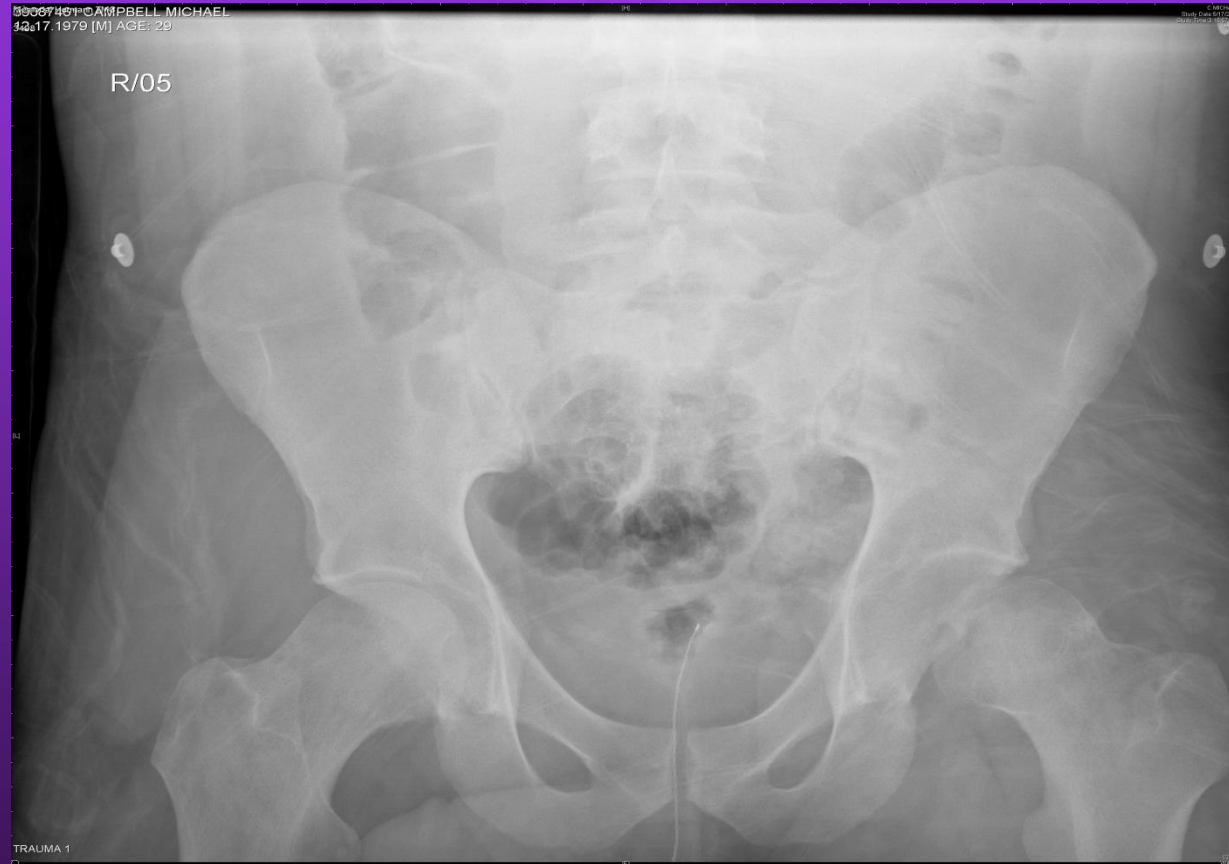Pipkin, JBJS 39 A 1027, 1197 1957



MC

- 29 yo healthy male s/p MVC with posterior hip dislocation
- Pipkin 1-2 fracture

MC Injury Films



Treatment

- Pipkin 1- conservative (<2mm displaced after closed reduction posterior dislocation) vs excision (open vs scope Lansford 2012) vs orif
- Pipkin 2- conservative (<1mm) vs orif usually anterior
 - Always check femoral neck before reducing posterior hip dislocation

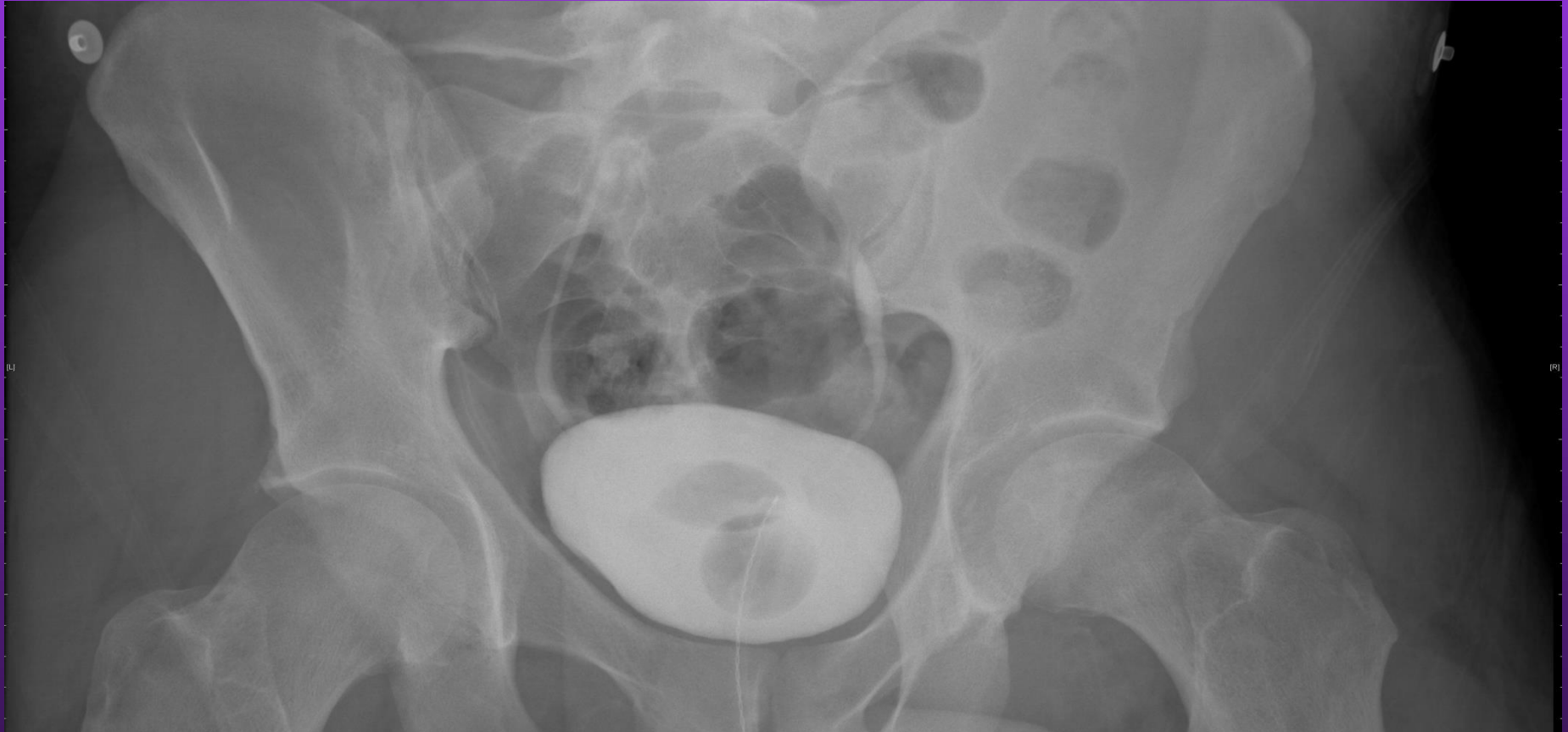
Treatment cont.

- Pipkin 3- conservative (<1mm) vs orif of femoral neck and head through anterior approach
- Pipkin 4- orif of acetabular fracture and femoral head with KL, trochanteric slide, and surgical dislocation (Solberg 2009 left OI intact)

Giannoudis Injury 2009

- 11.7% of posterior hip dislocations with femoral head fractures
- 84% due to MVA
- Timing of reduction <6hr (88% vs 42% G&E Hougaard 1986)

MC Post-reduction (note incongruent joint)



Pipkin 1 Studies

- Chakraborti 1975 – conservative Rx
- Epstein 1985 – open reduction internal fixation treatment of dislocation and femoral head
- Holms 2000- excise $<1/3$ nwb femoral head without clinical implication (cadavers)

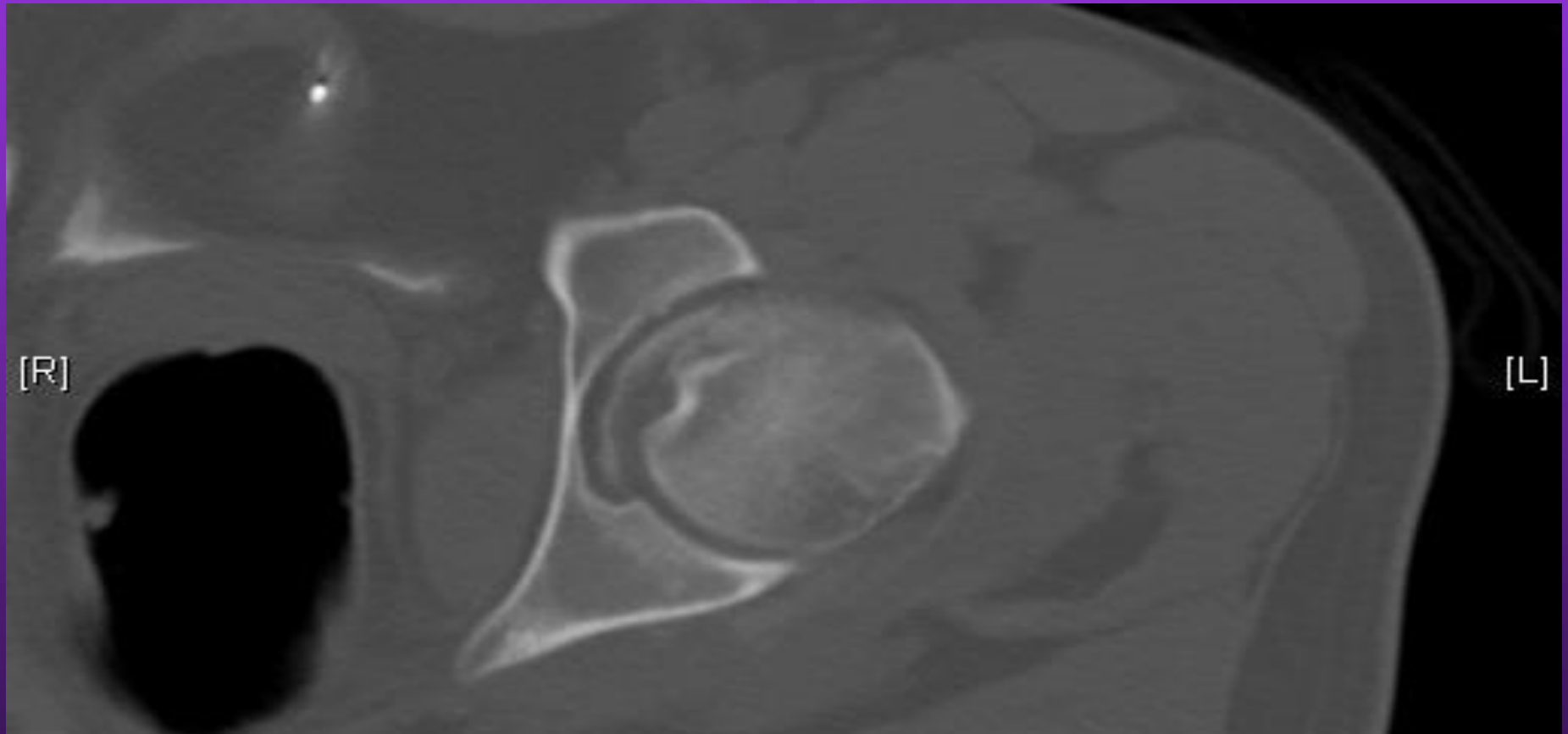
Chen et al Int Orthop 2011

- 16 patients Pipkin 1 conservative vs excision (1E, 3G, 2F, 2P vs 5E, 2G, 1F)
 - 2 AVN, 1 HO in cons.
 - 4 HO in Tx
 - <12 h for reduction (↑ in reduction for conservative rx)
 - Skeletal distraction 6 weeks, not randomized

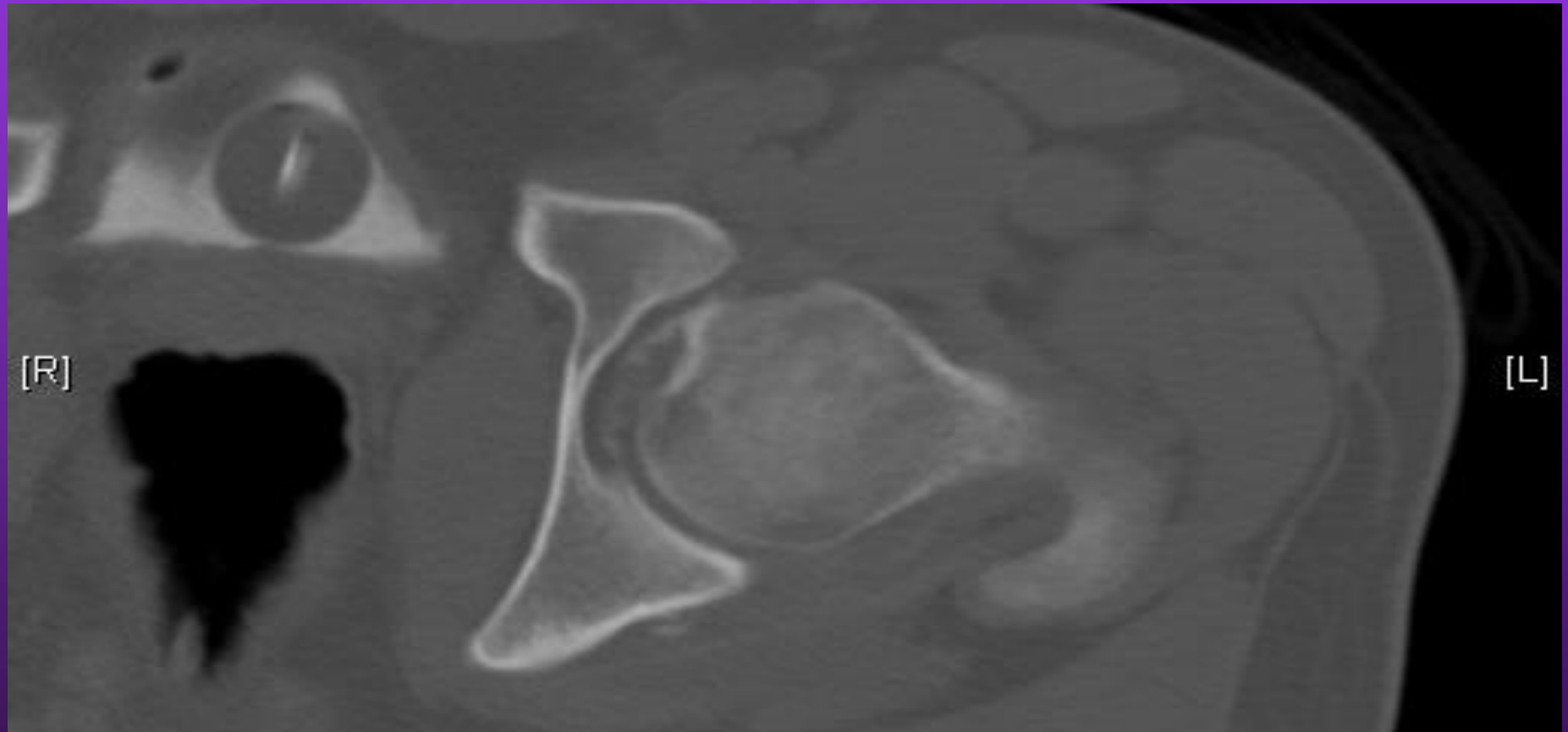
Anterior vs Posterior

- Fracture is usually anterior
- Check CT
 - Swiontkowski 1992

MC CT



MC CT



MC OR

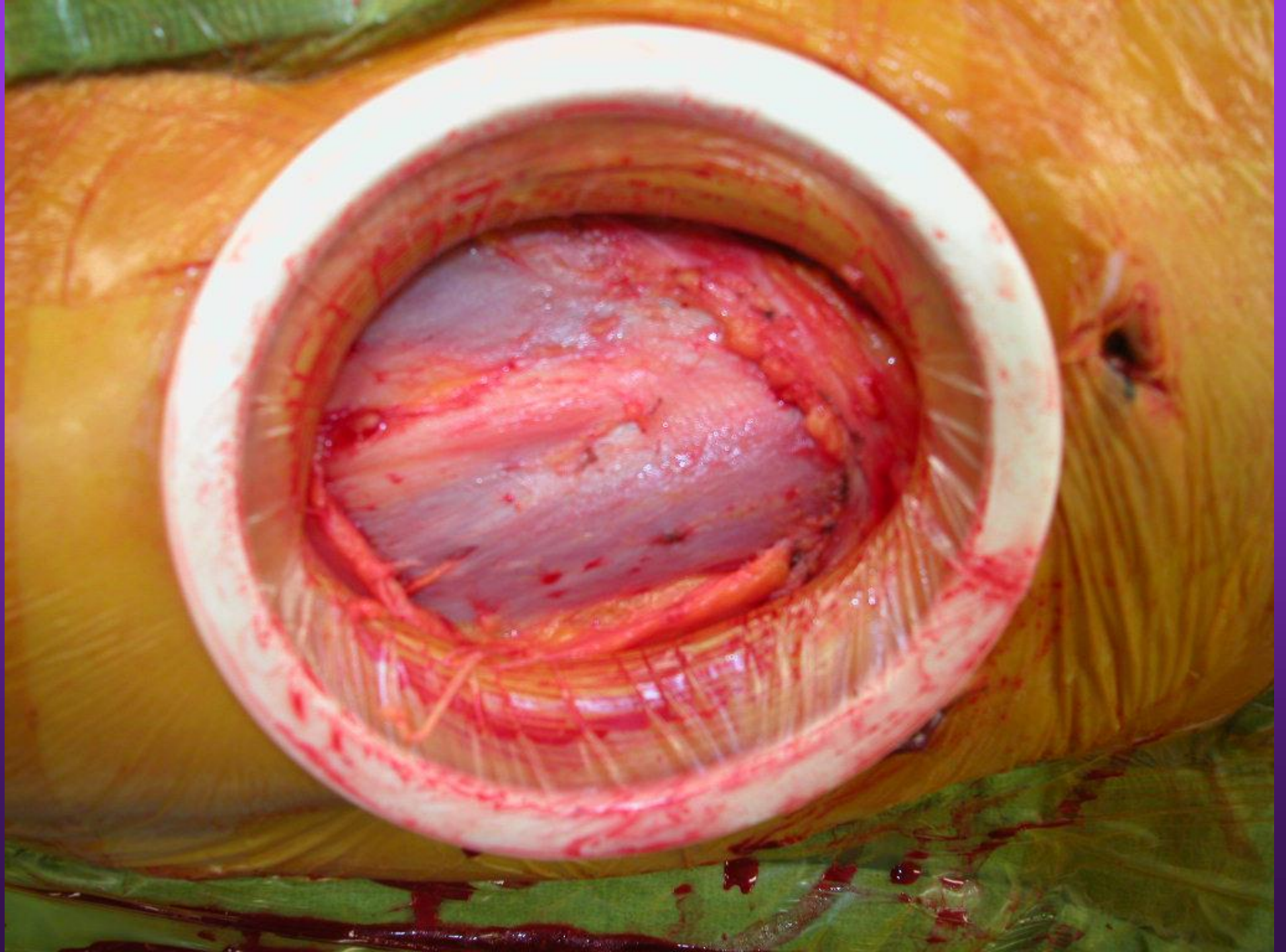
- ORIF through Smith-Peterson approach and surgical dislocation (initially done by a trauma fellowship trained surgeon and was unable to dislocate the hip)
- Fixation with 3.0 cannulated screws

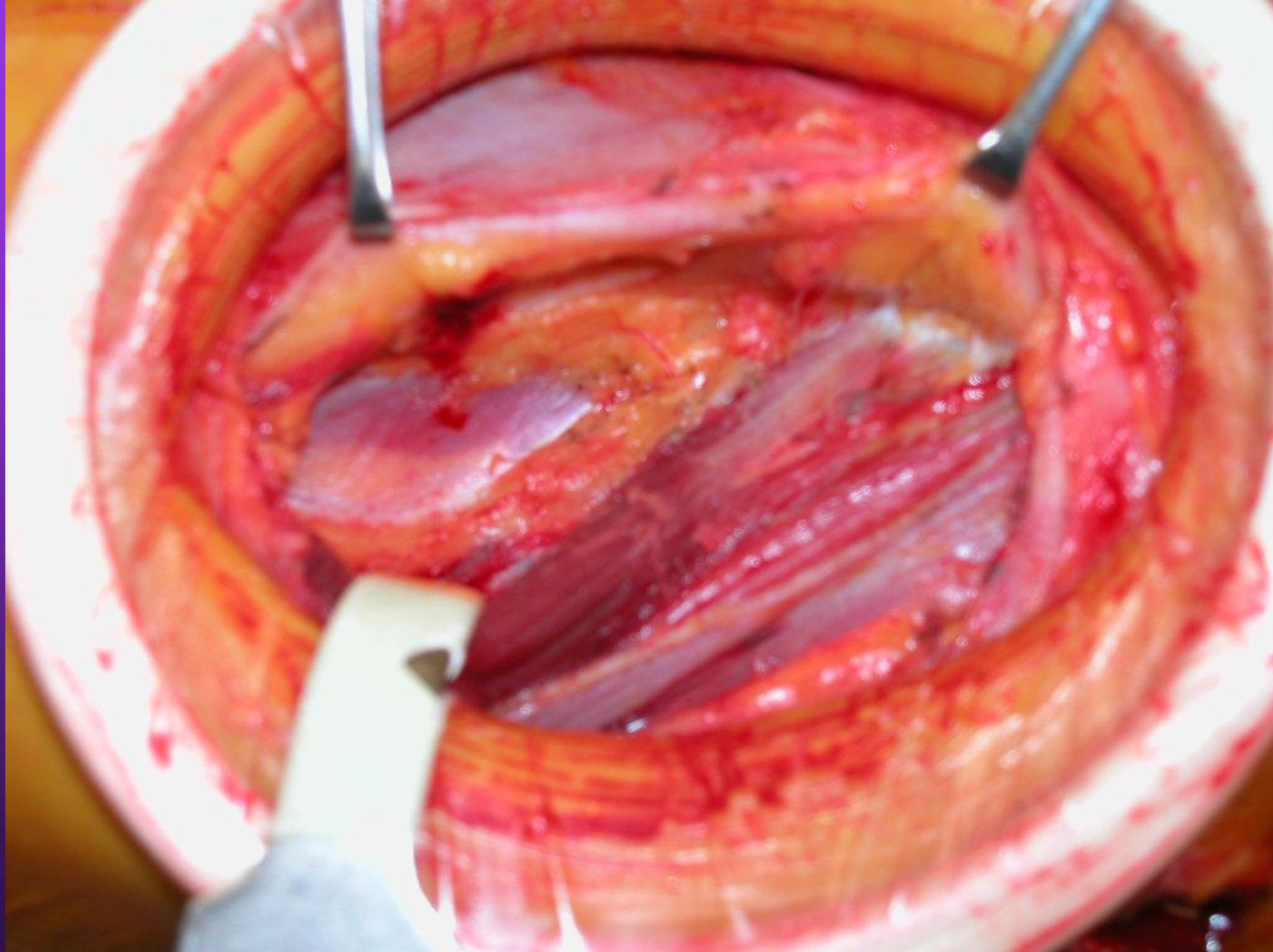

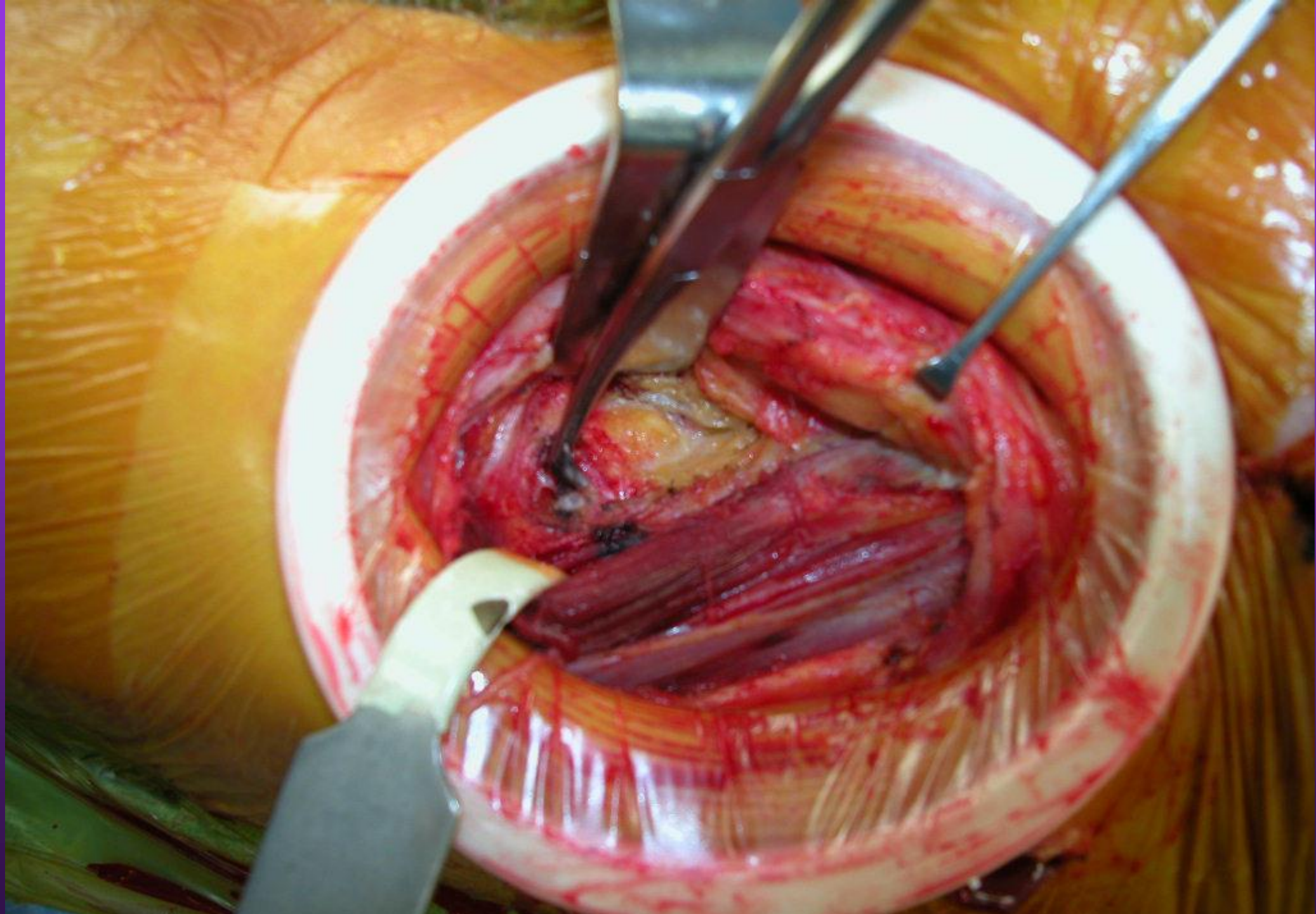
Dr. Kregor
slides

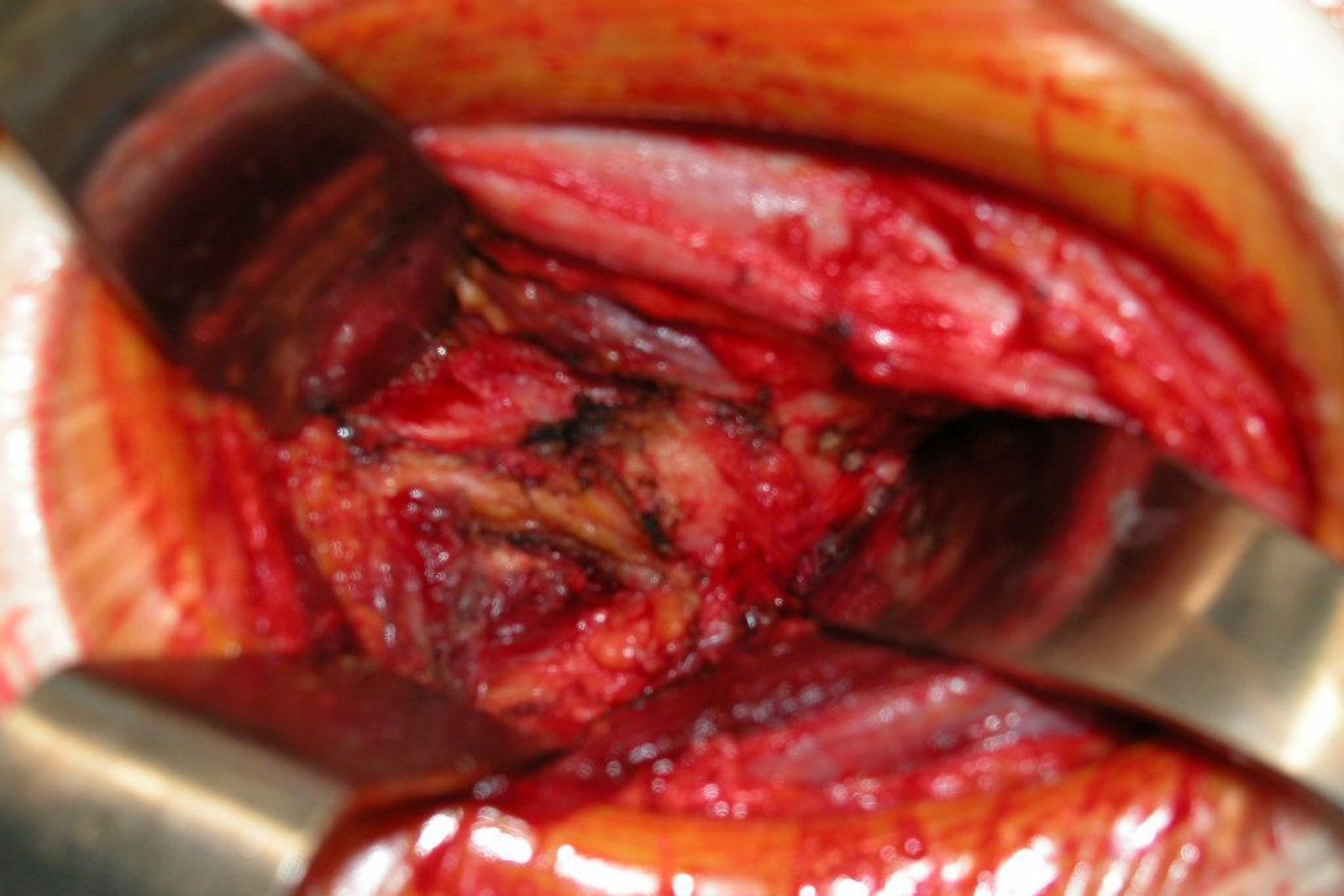
Case #1

Line of 10 cm skin incision.

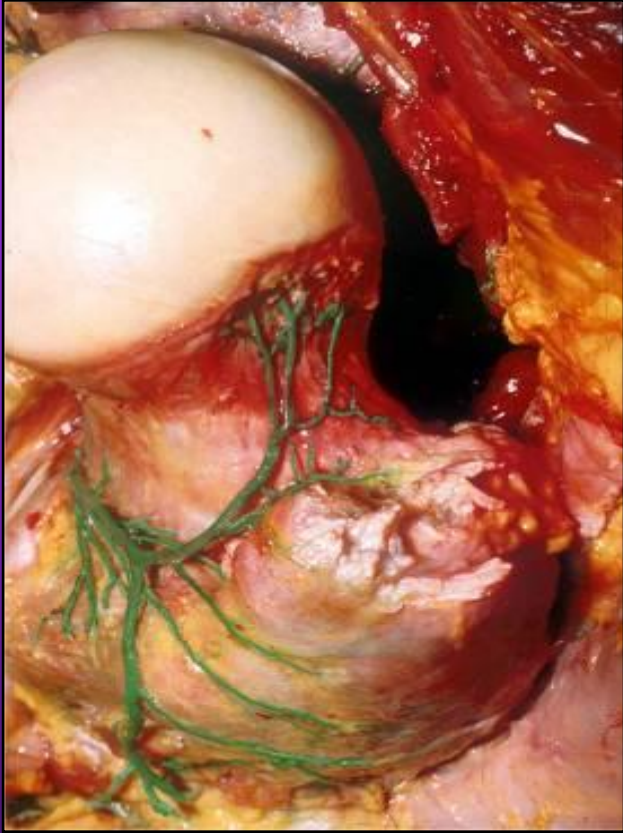




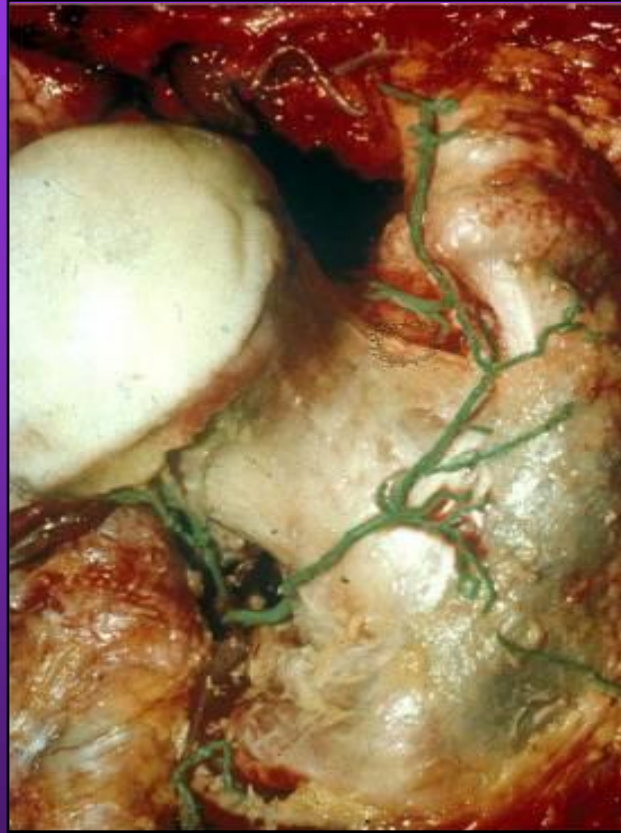



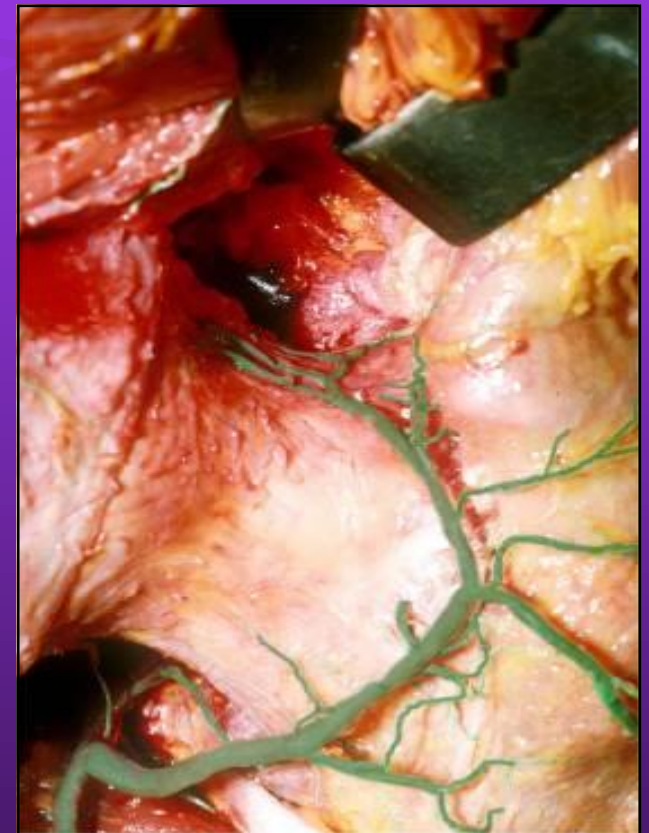Terminal subsynovial (retinacular) vessels



Superior
type

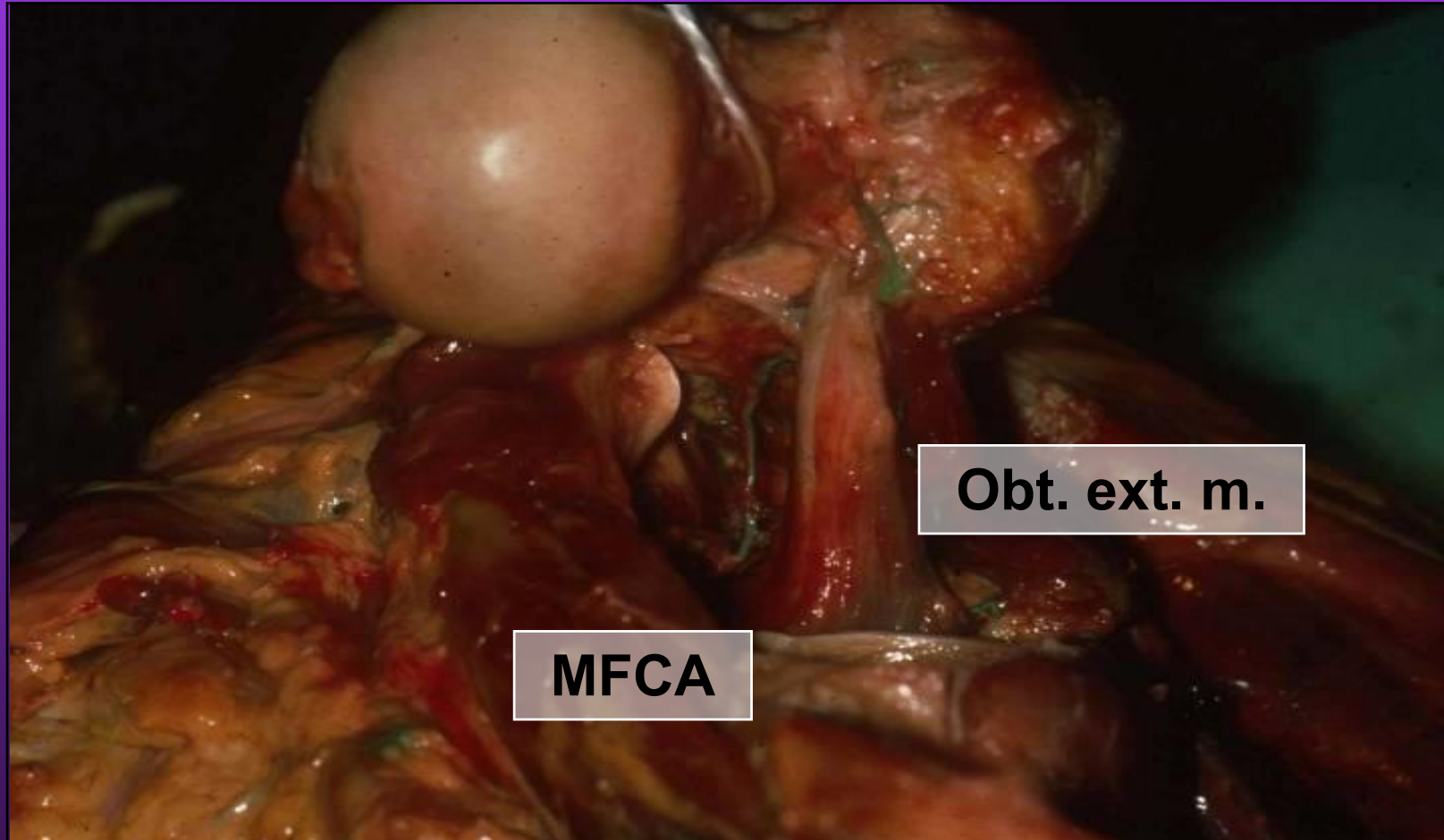


Mixed



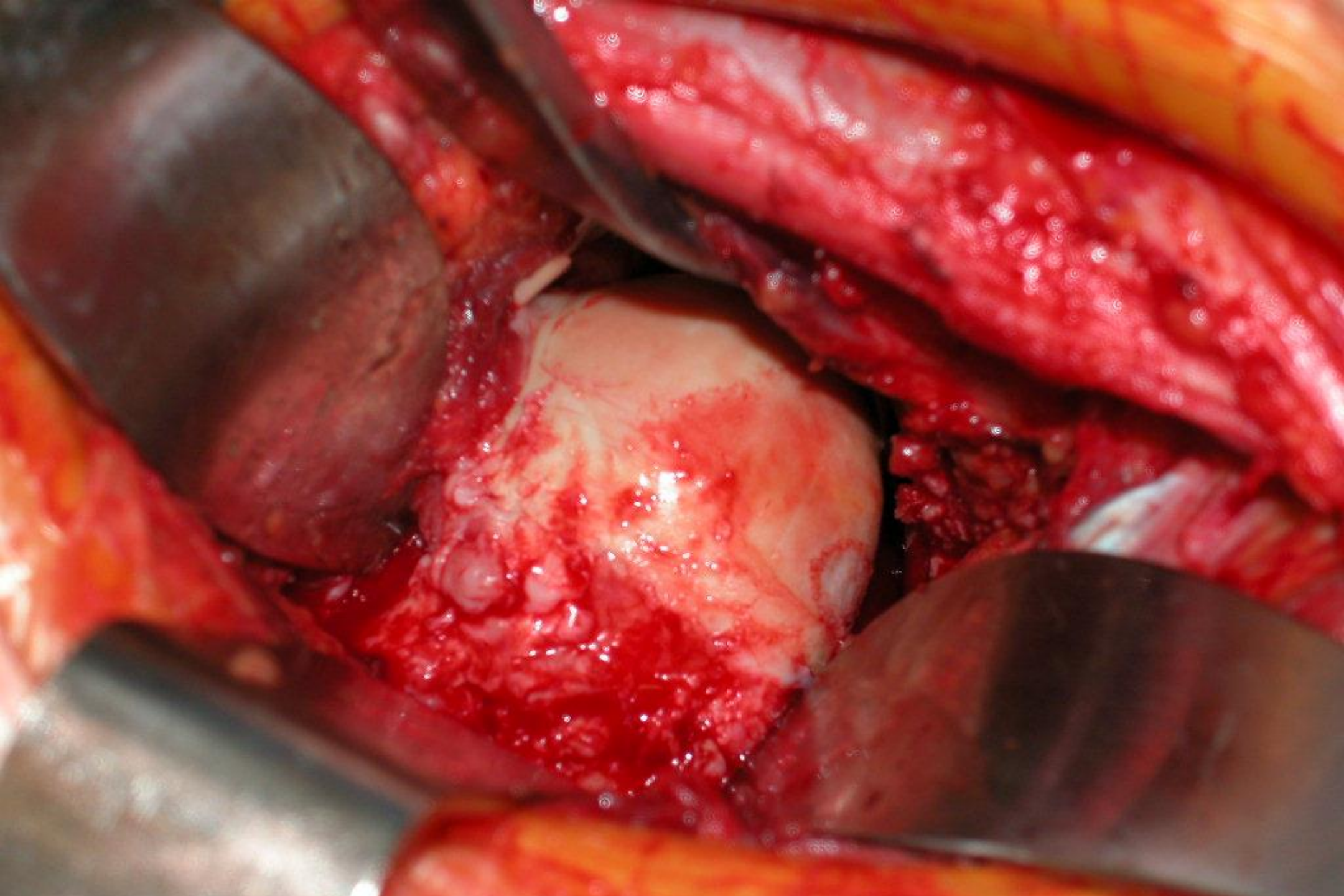
Post. neck
free of vessels

Obt. ext. m. protects MFCA



MFCA

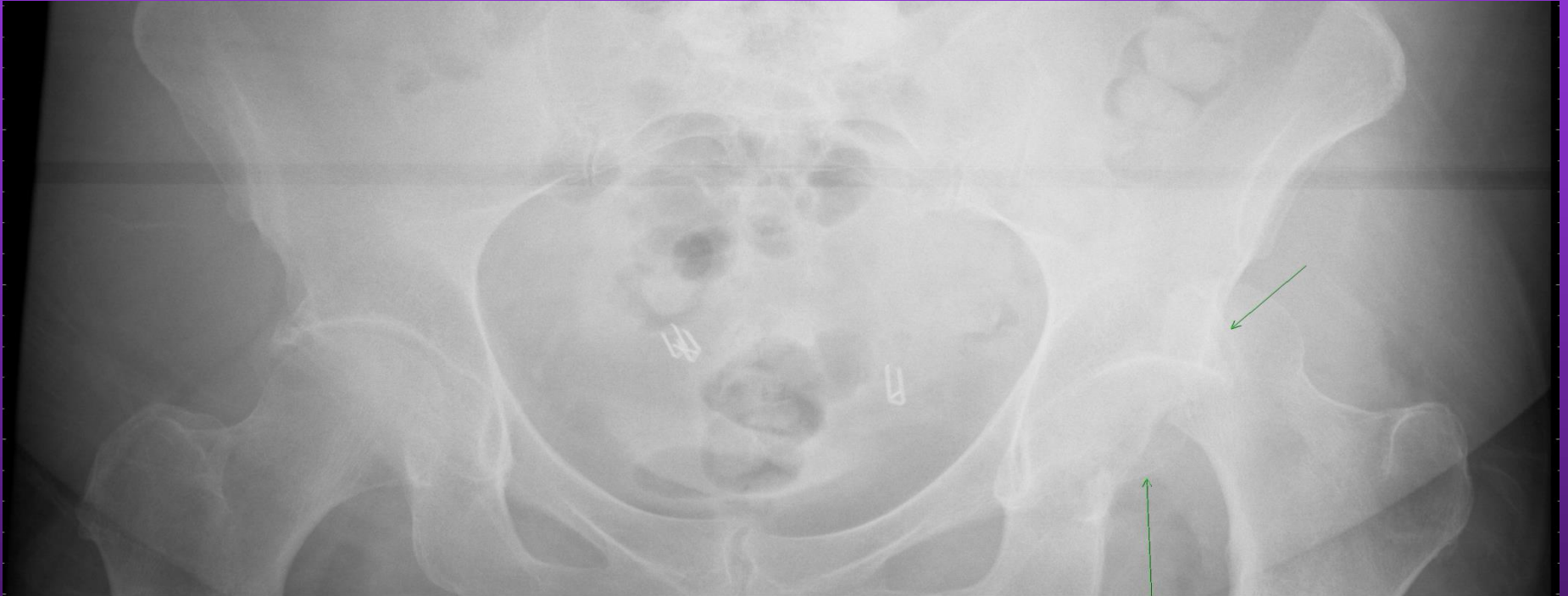Obt. ext. m.



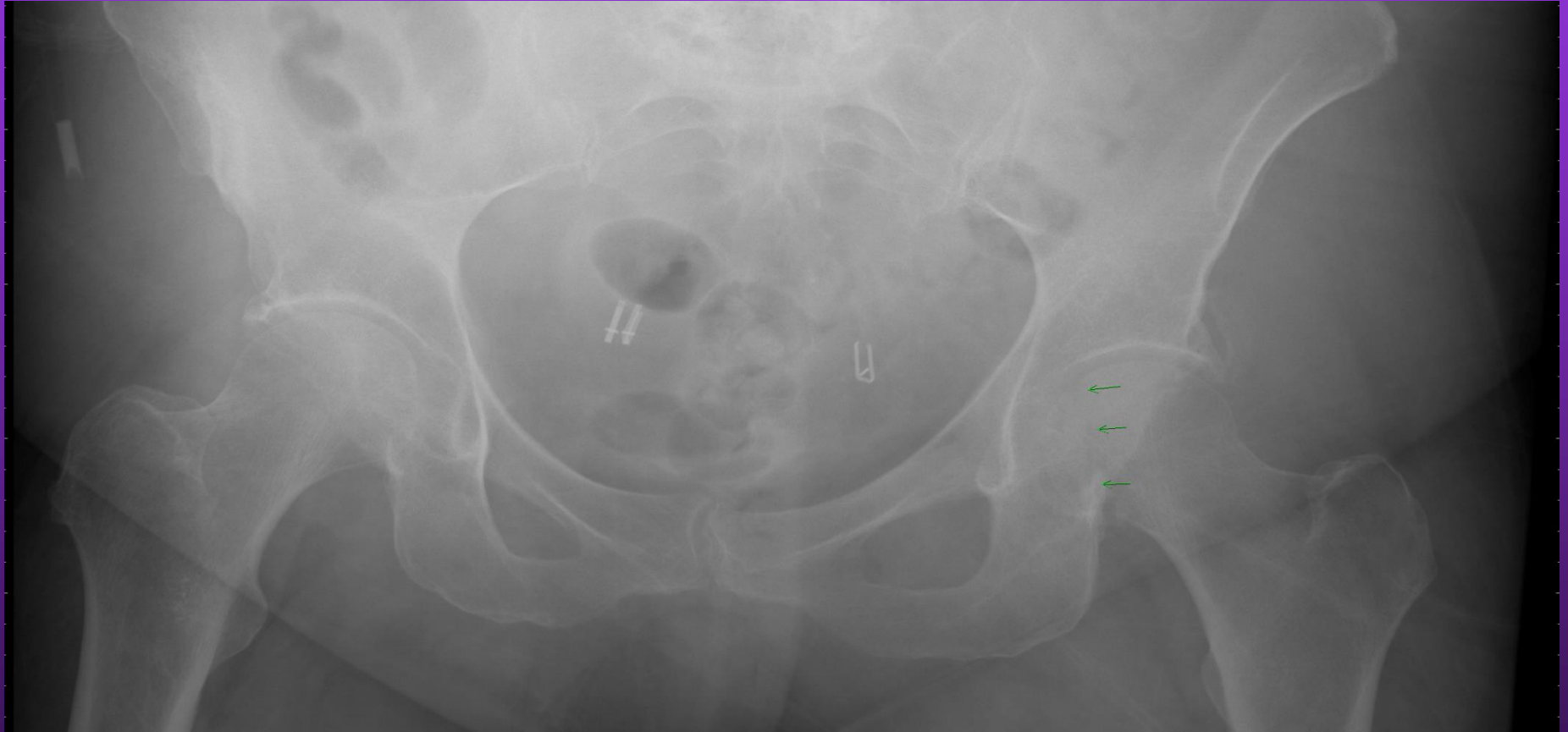
EL

- 56 yo female s/p MVA, unrestrained passenger
- h/o osteoporosis, hypothyroid, depression, OSA, breast cancer
- Posterior hip dislocation with Pipkin 2 fracture

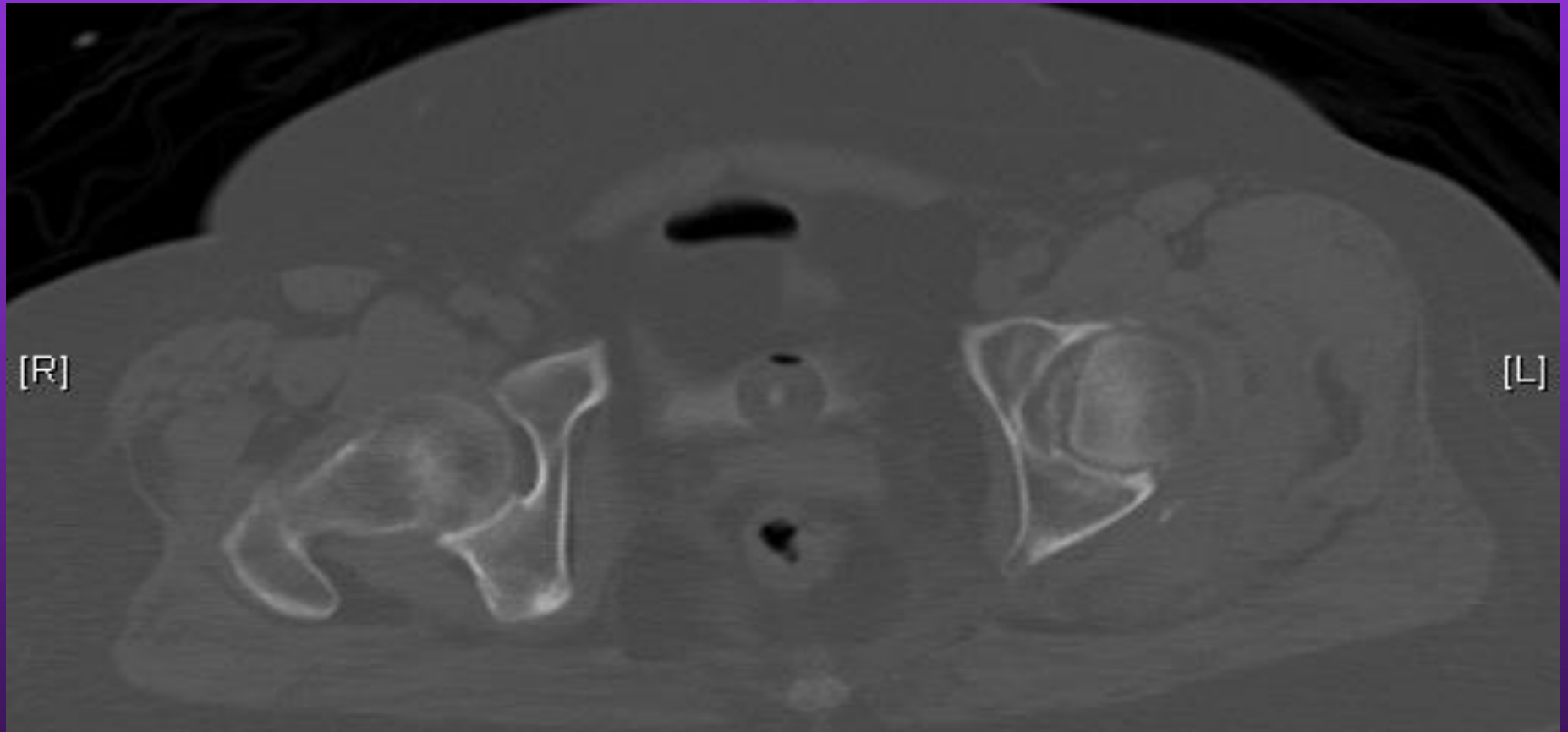
Injury Films



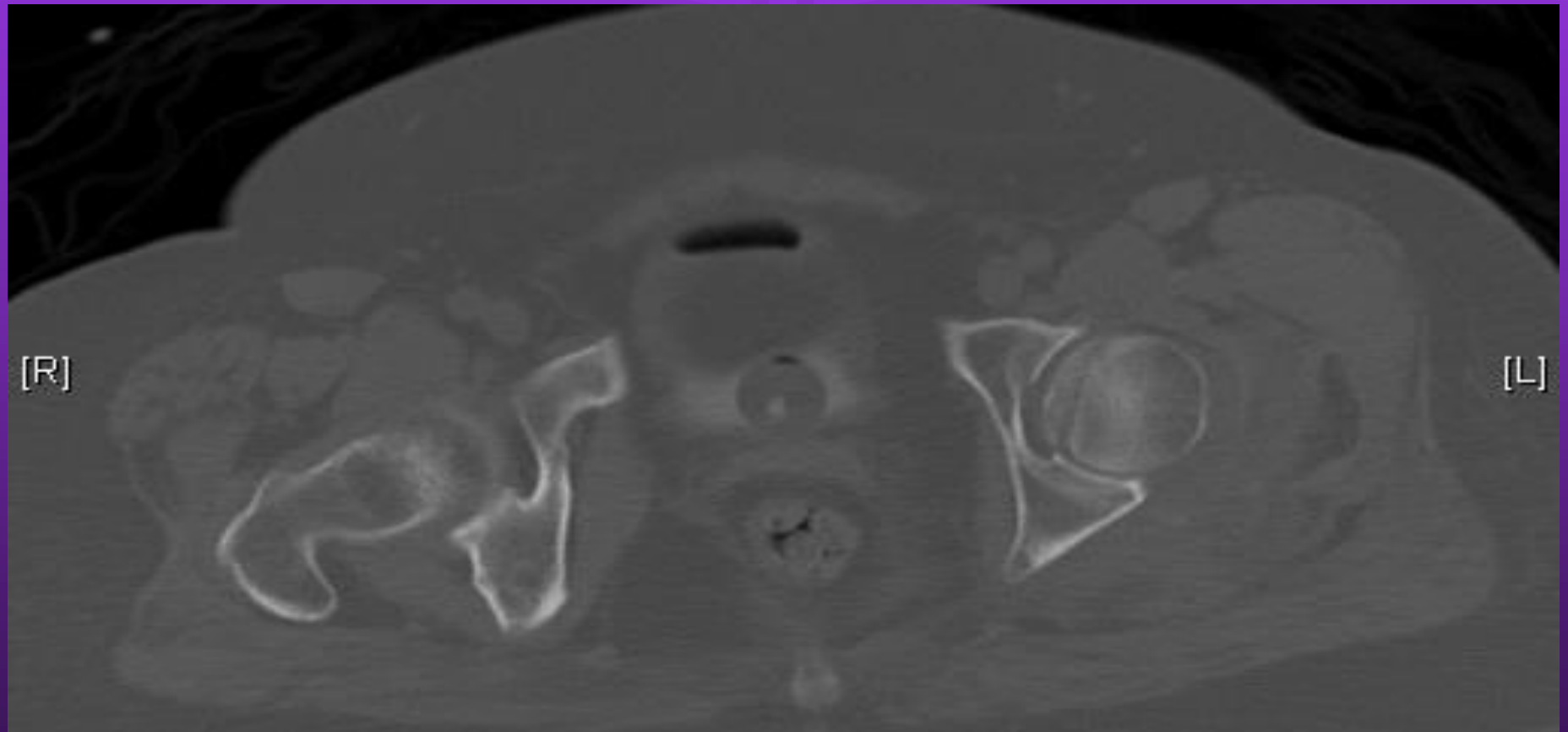
Post-Reduction



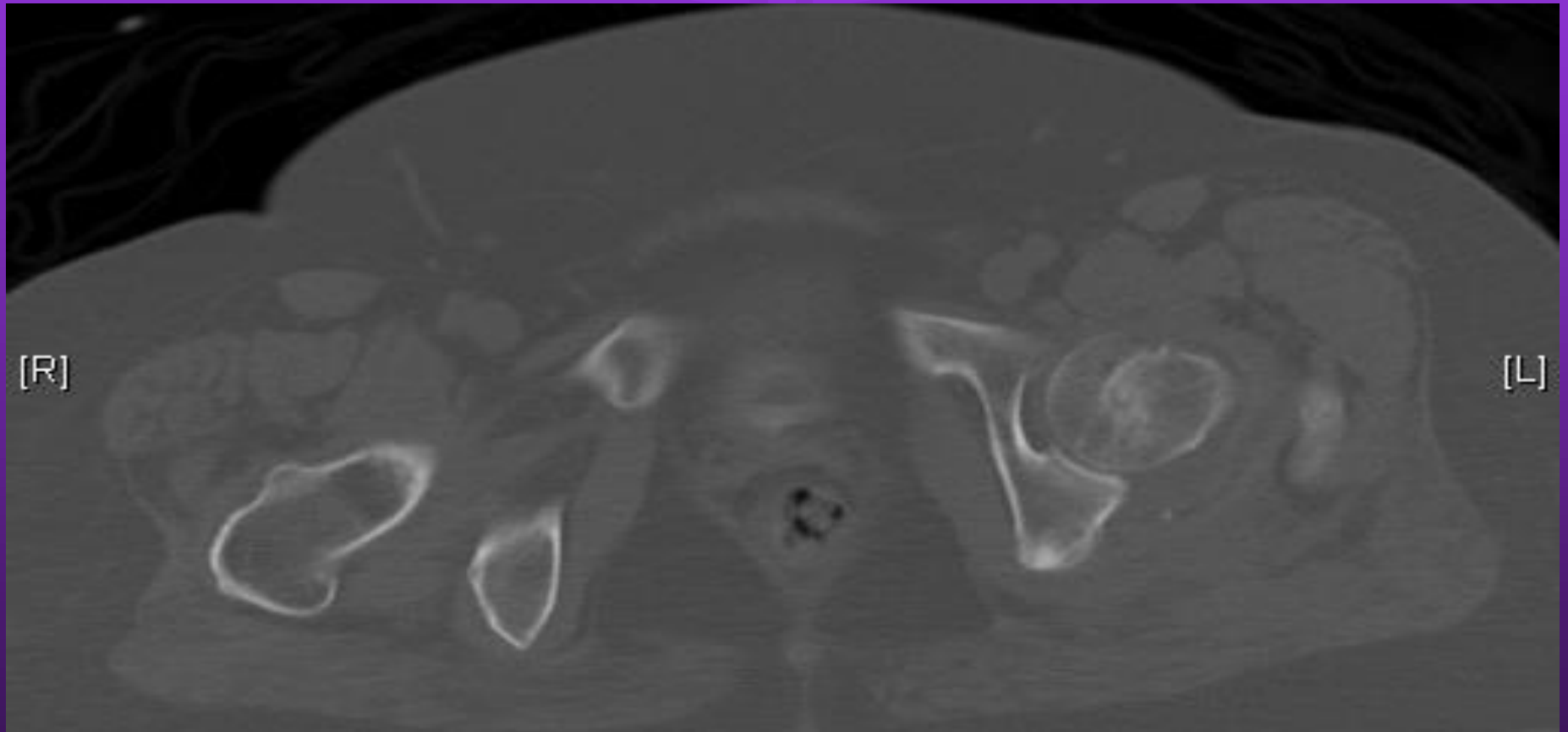
CT



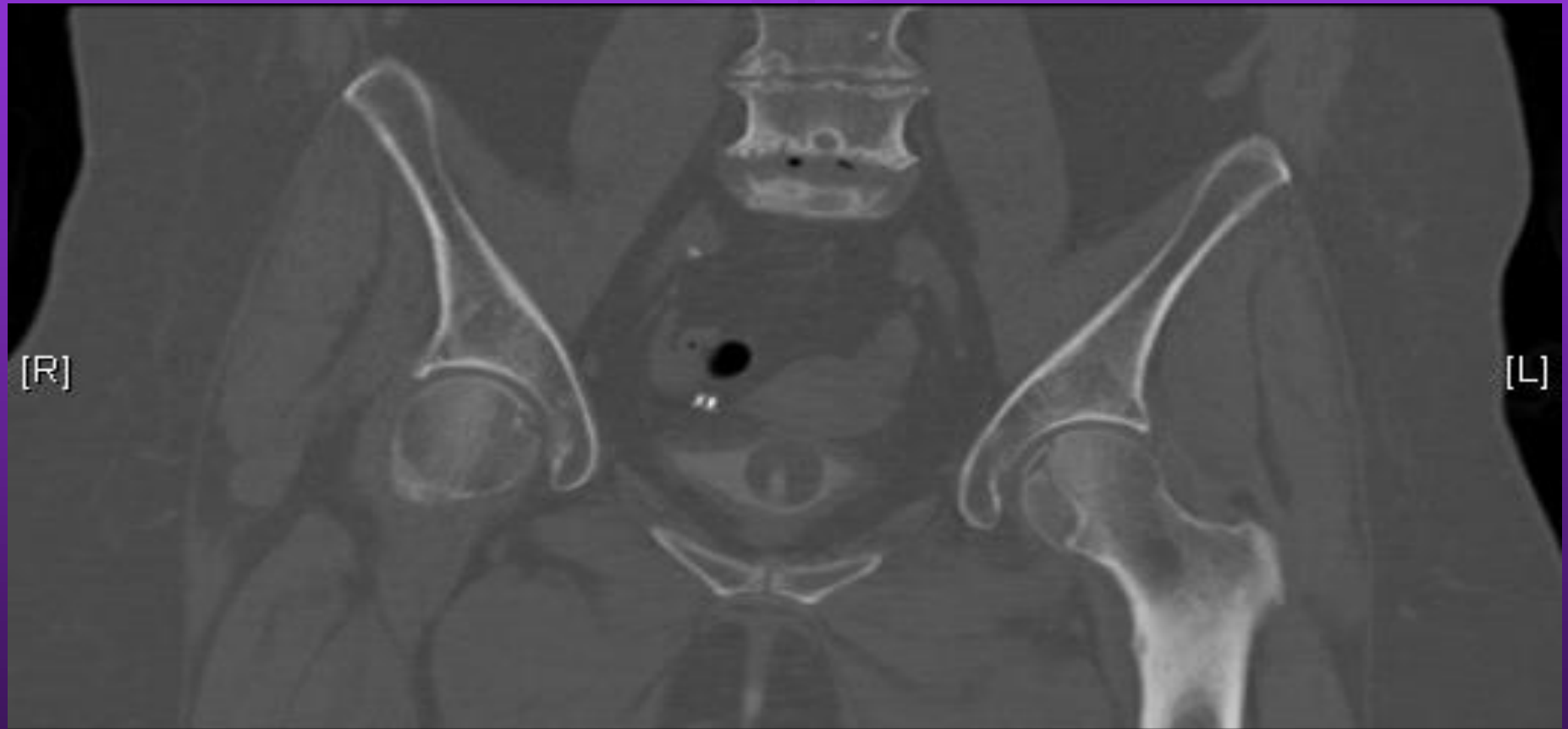
CT



CT



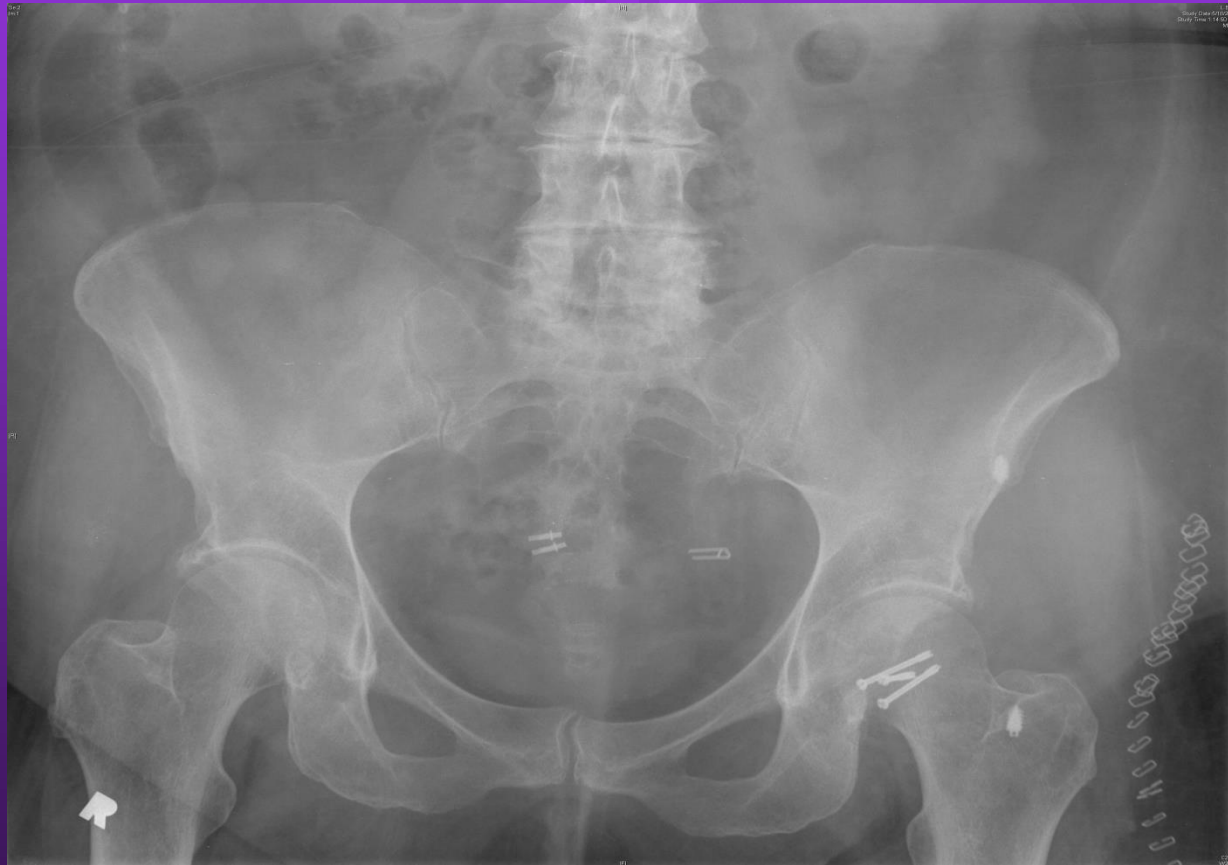
CT



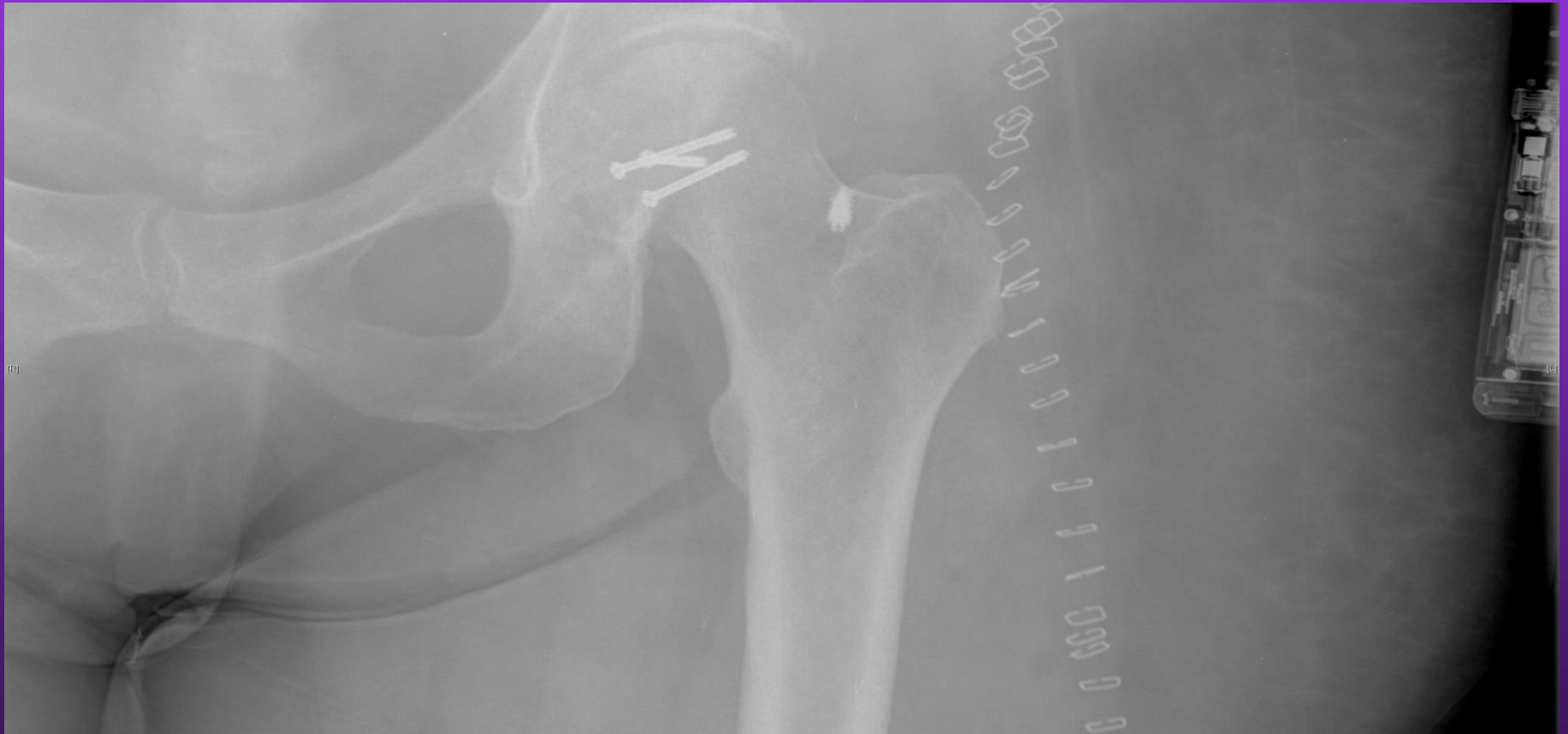OR

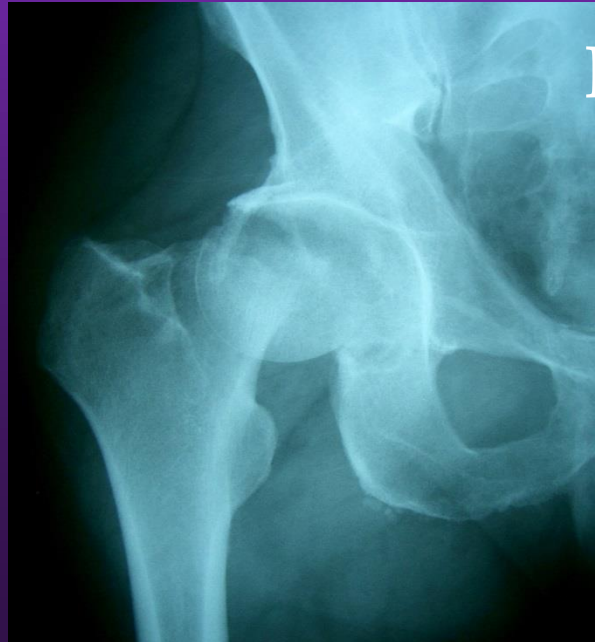
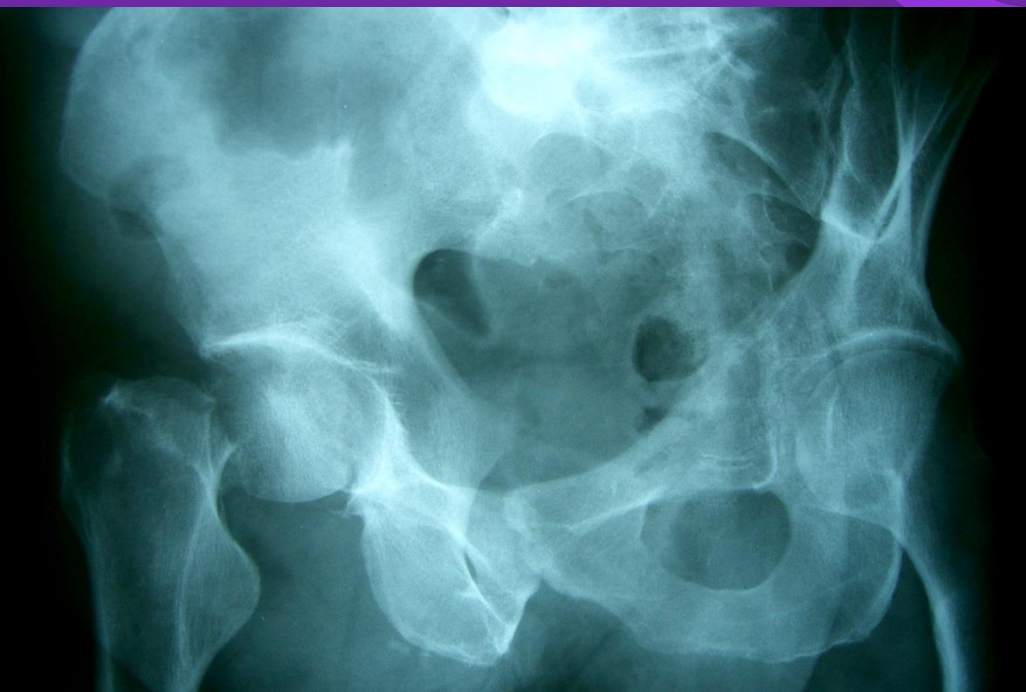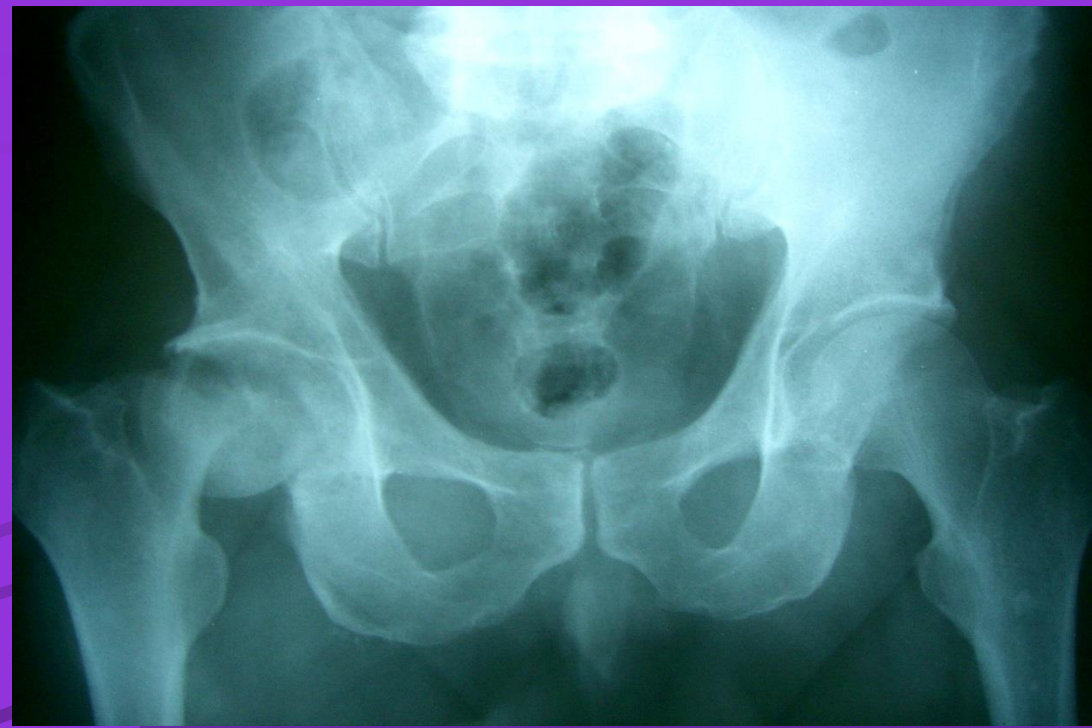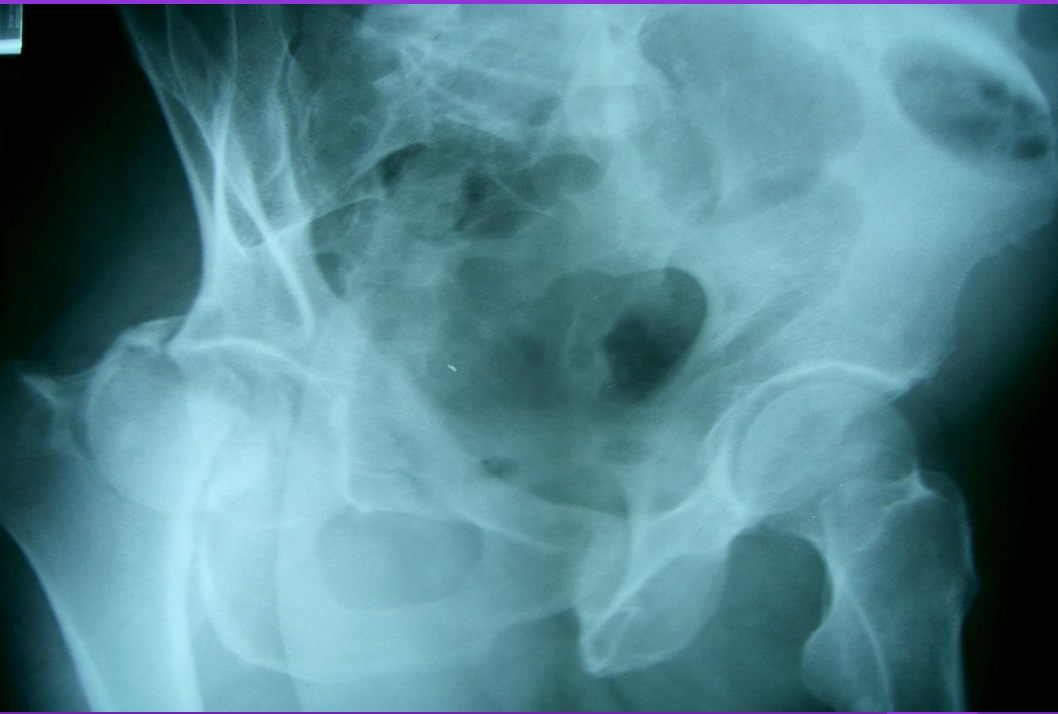- ORIF through Smith-Peterson approach
- 3.0 cannulated screws

Post-Op

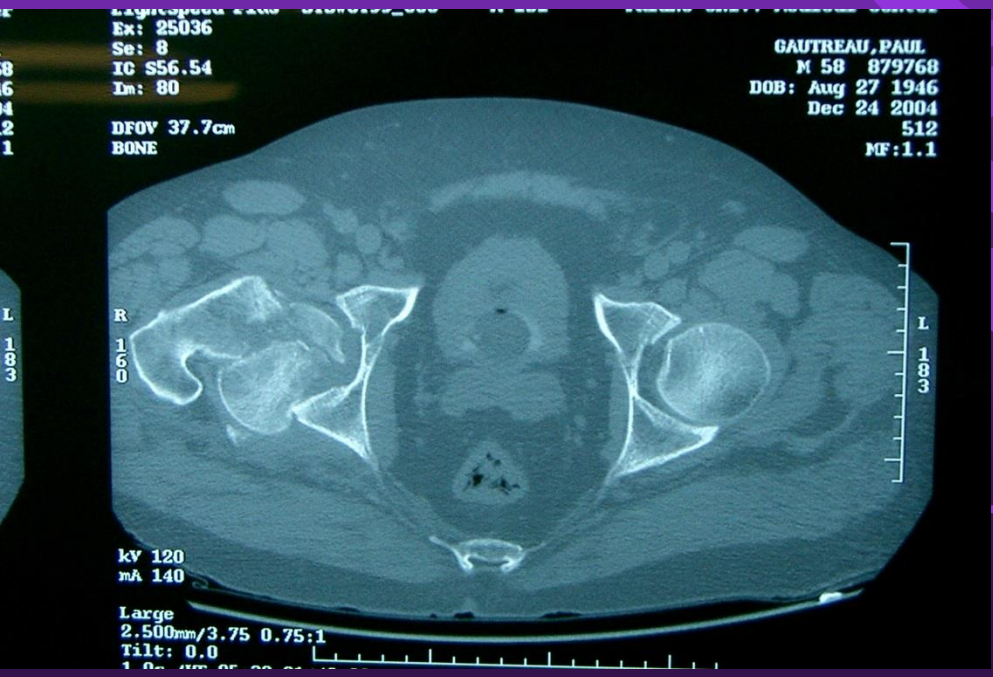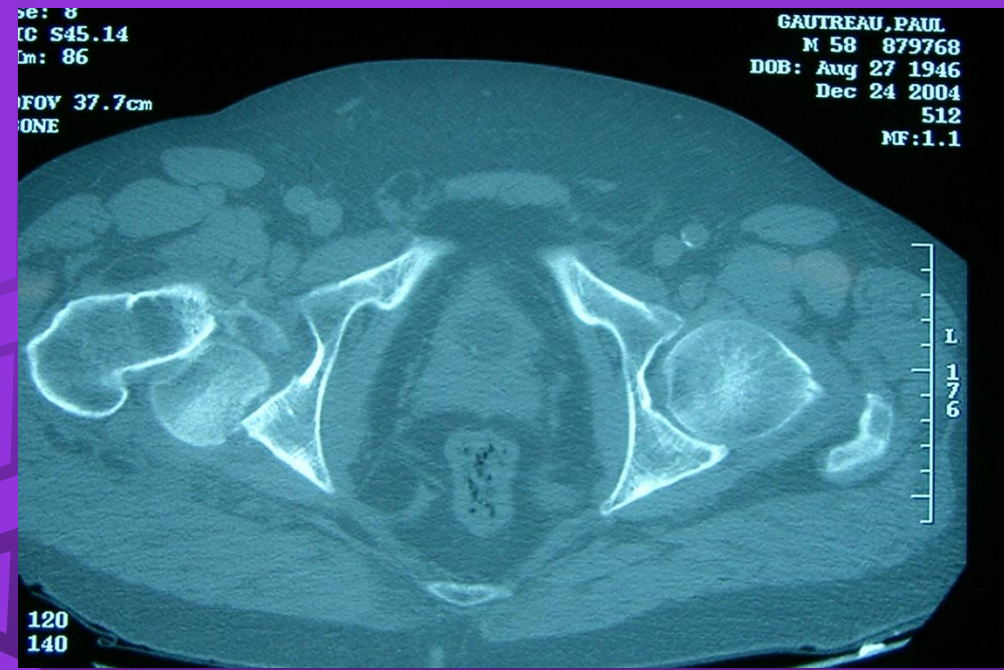

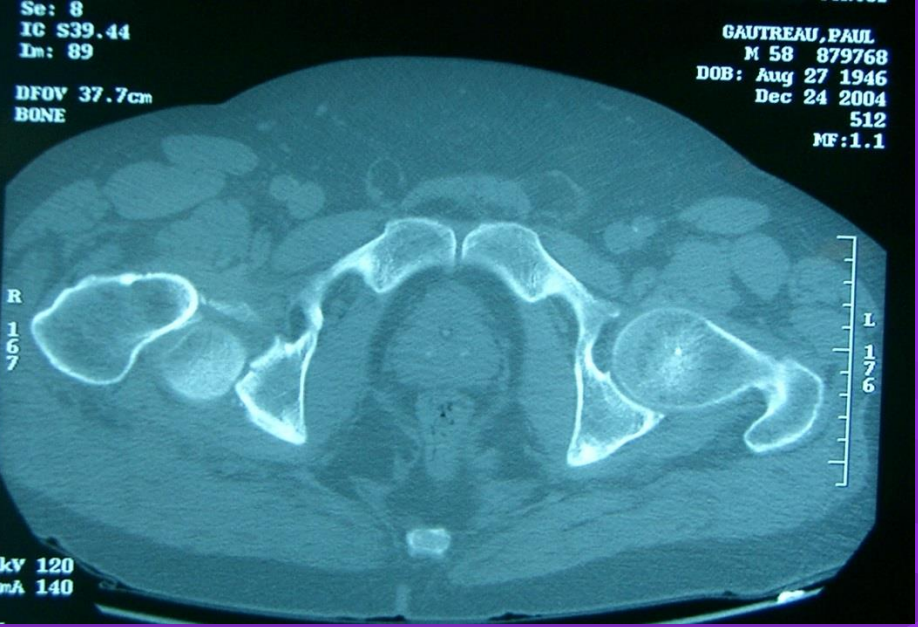
Post-Op

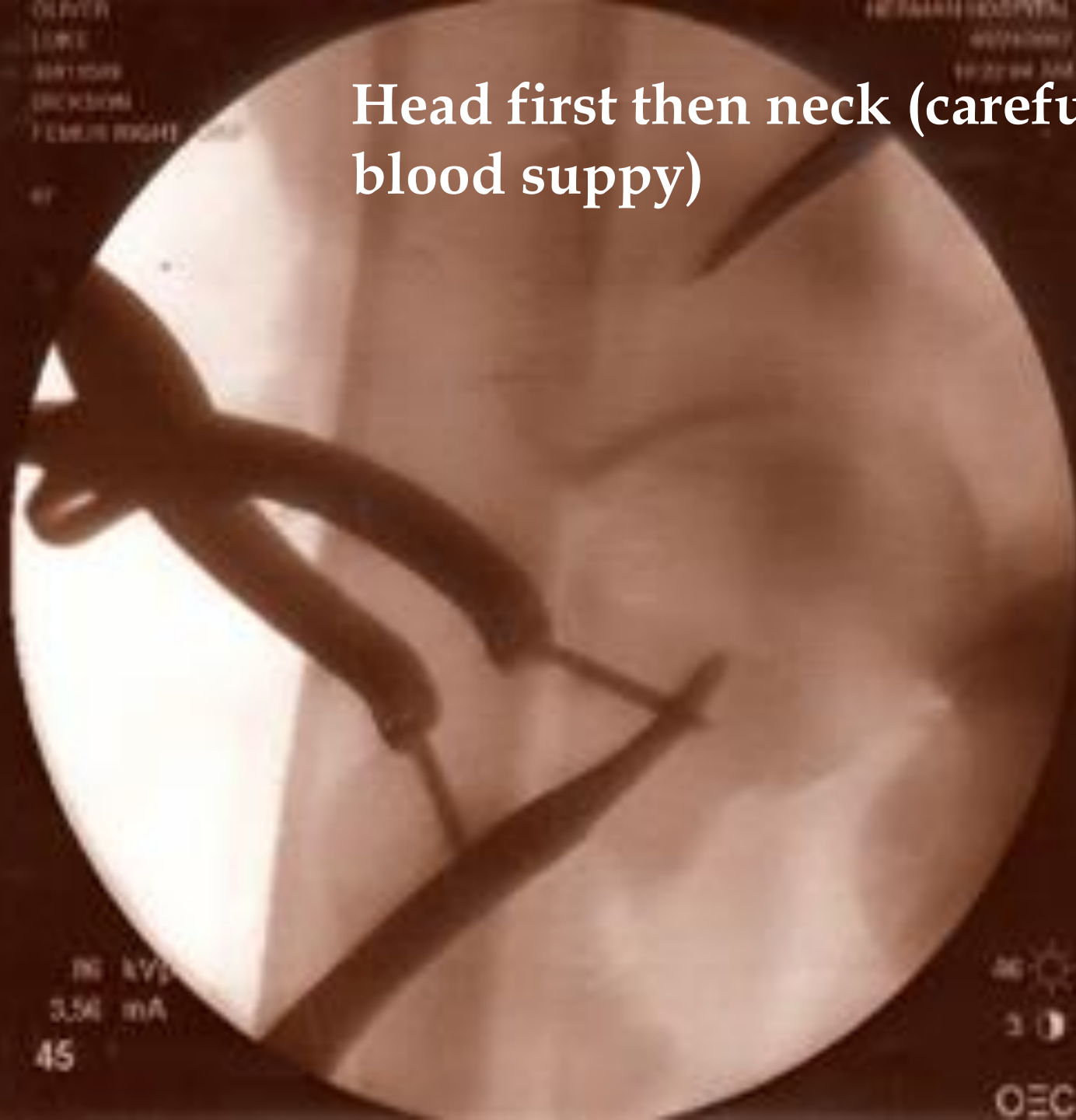



Pipkin 3

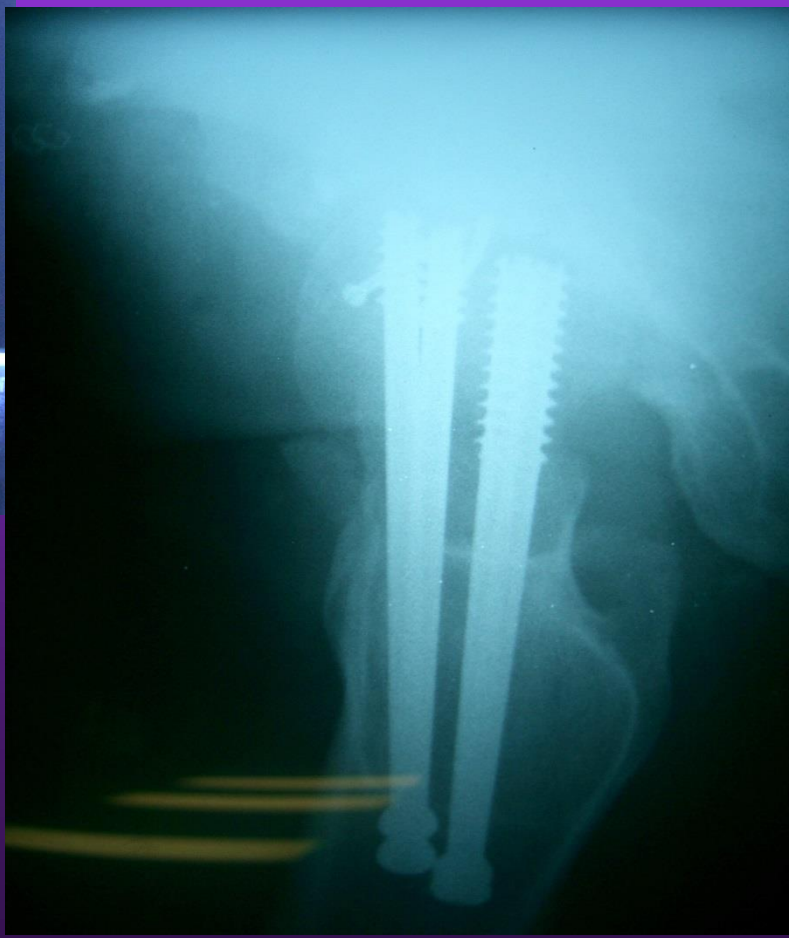
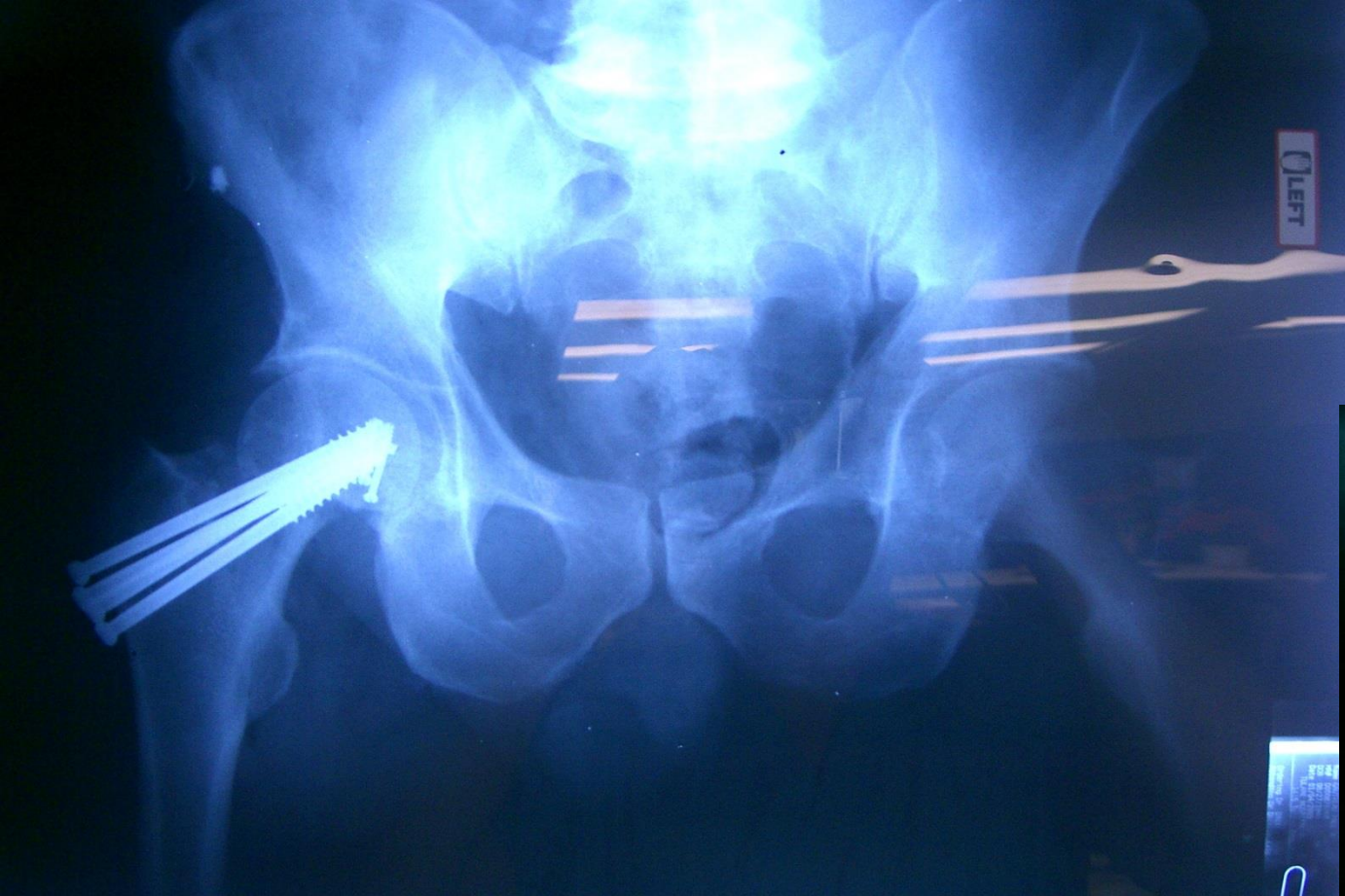
Head first then neck (careful with blood supply)



16 kVp
3.54 mA
45

26
3
OEC

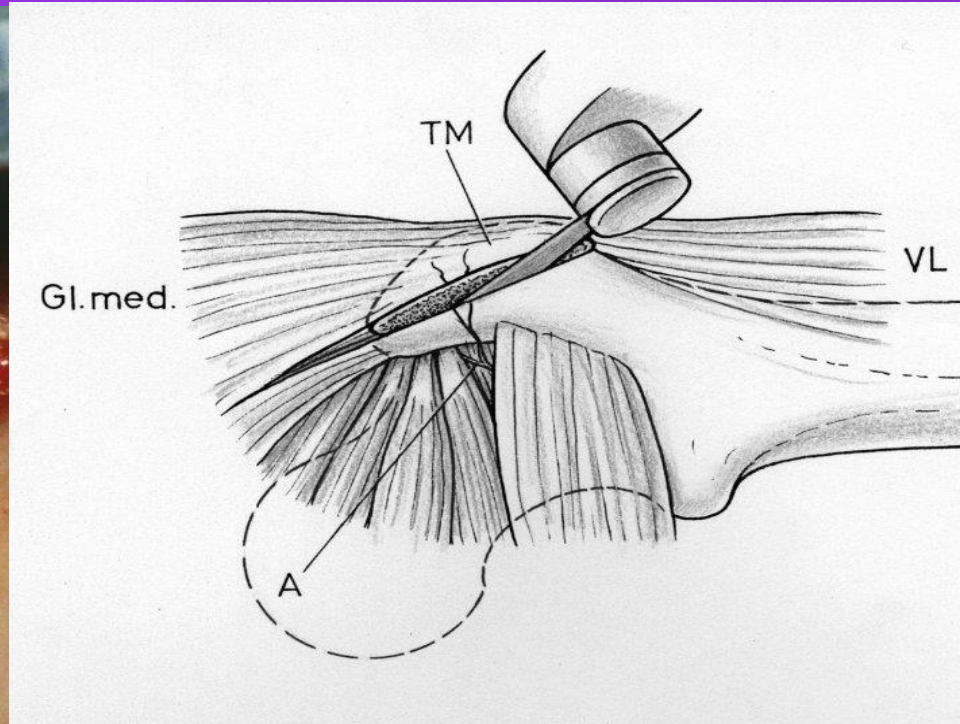
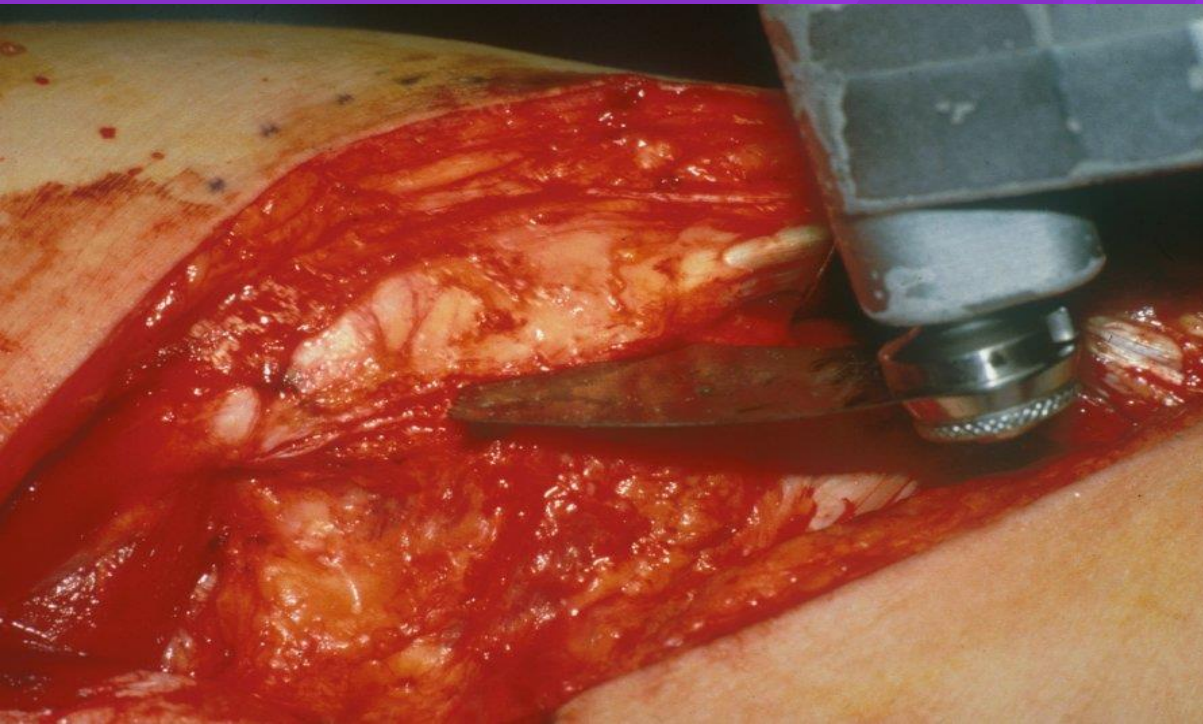


Ex

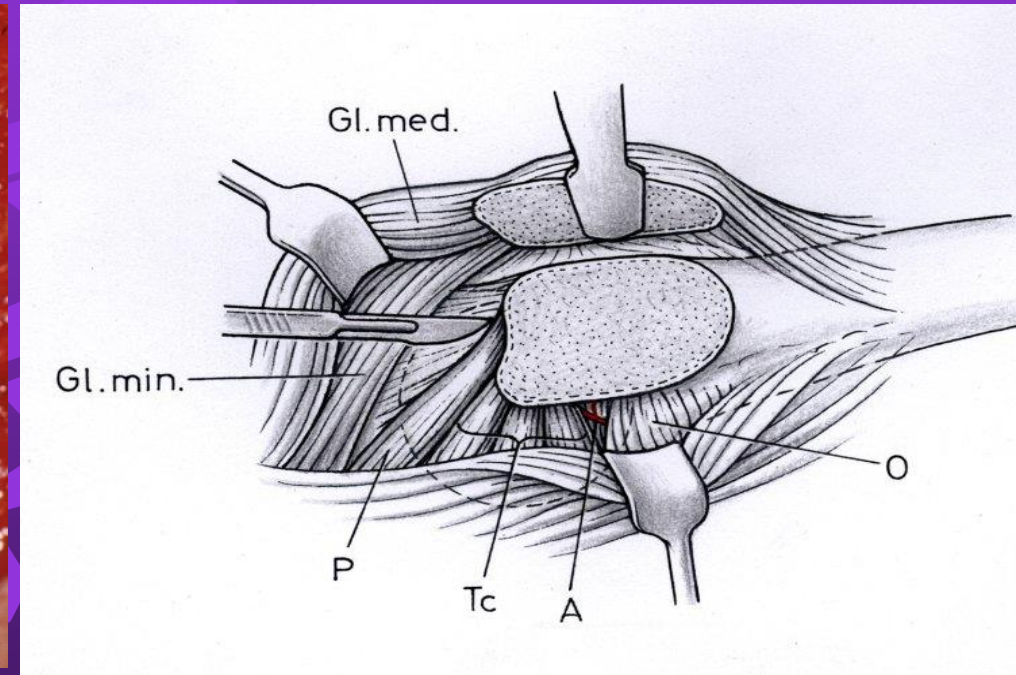
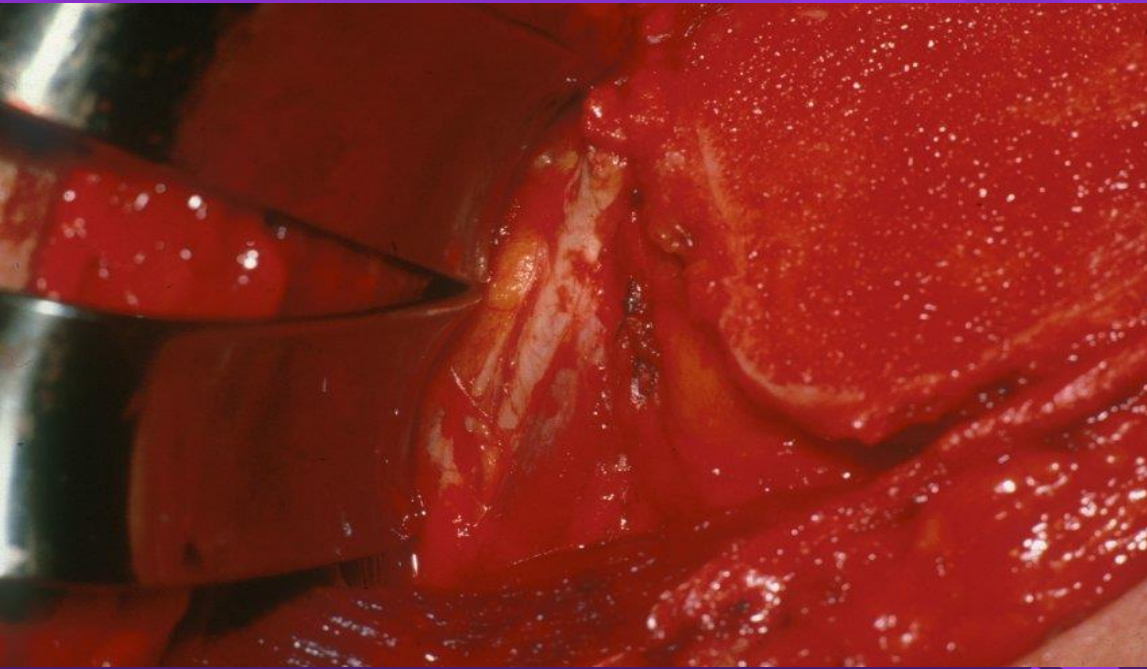
Pipkin 4 Surgical Dislocations

- KL in lateral decubitus with a trochanteric slide (instead of a flip)
- Pipkin fracture with a posterior wall
- Some use it in Tr to see the reduction

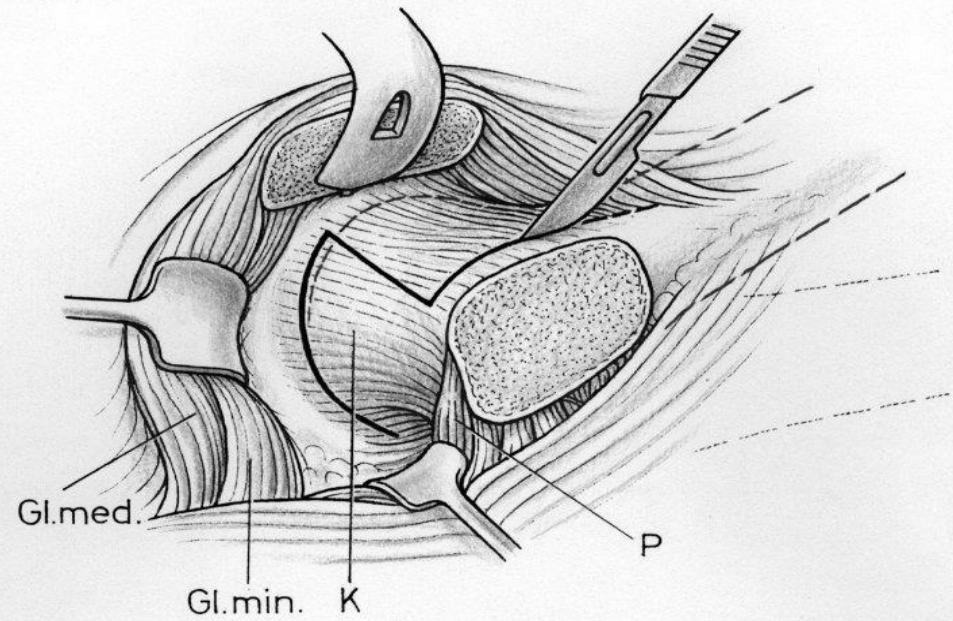
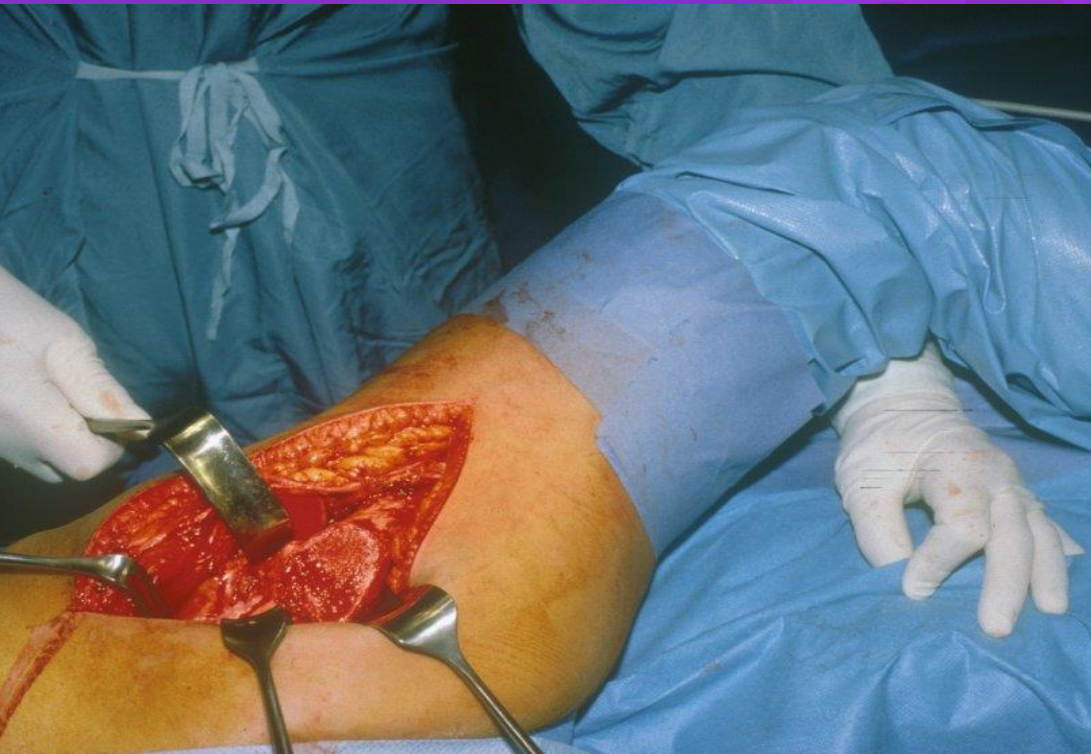
osteotomy of greater trochanter


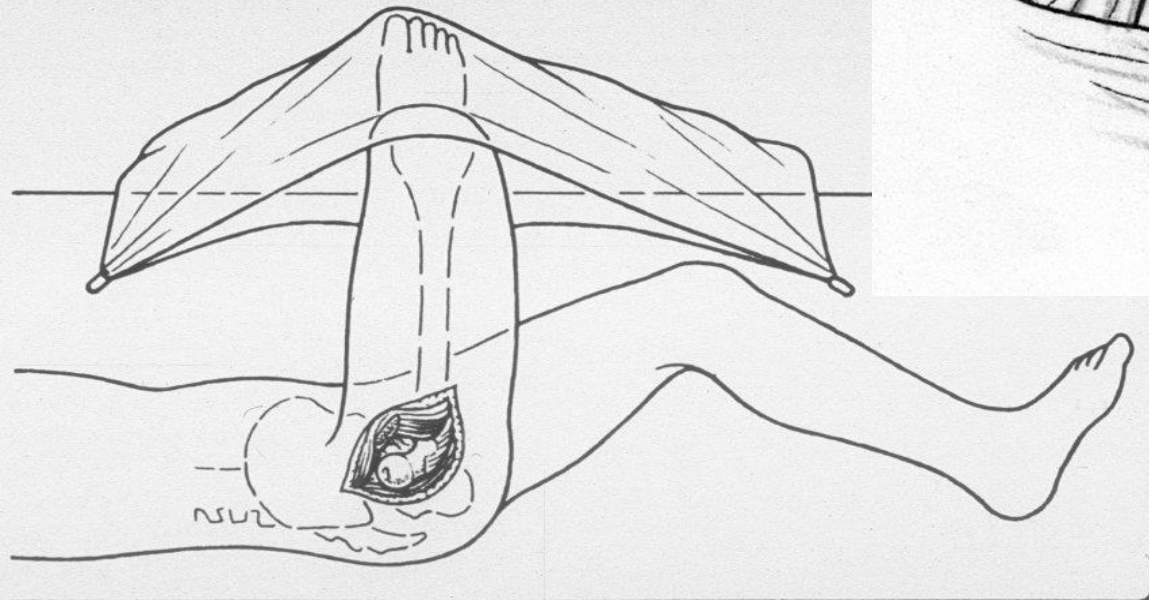
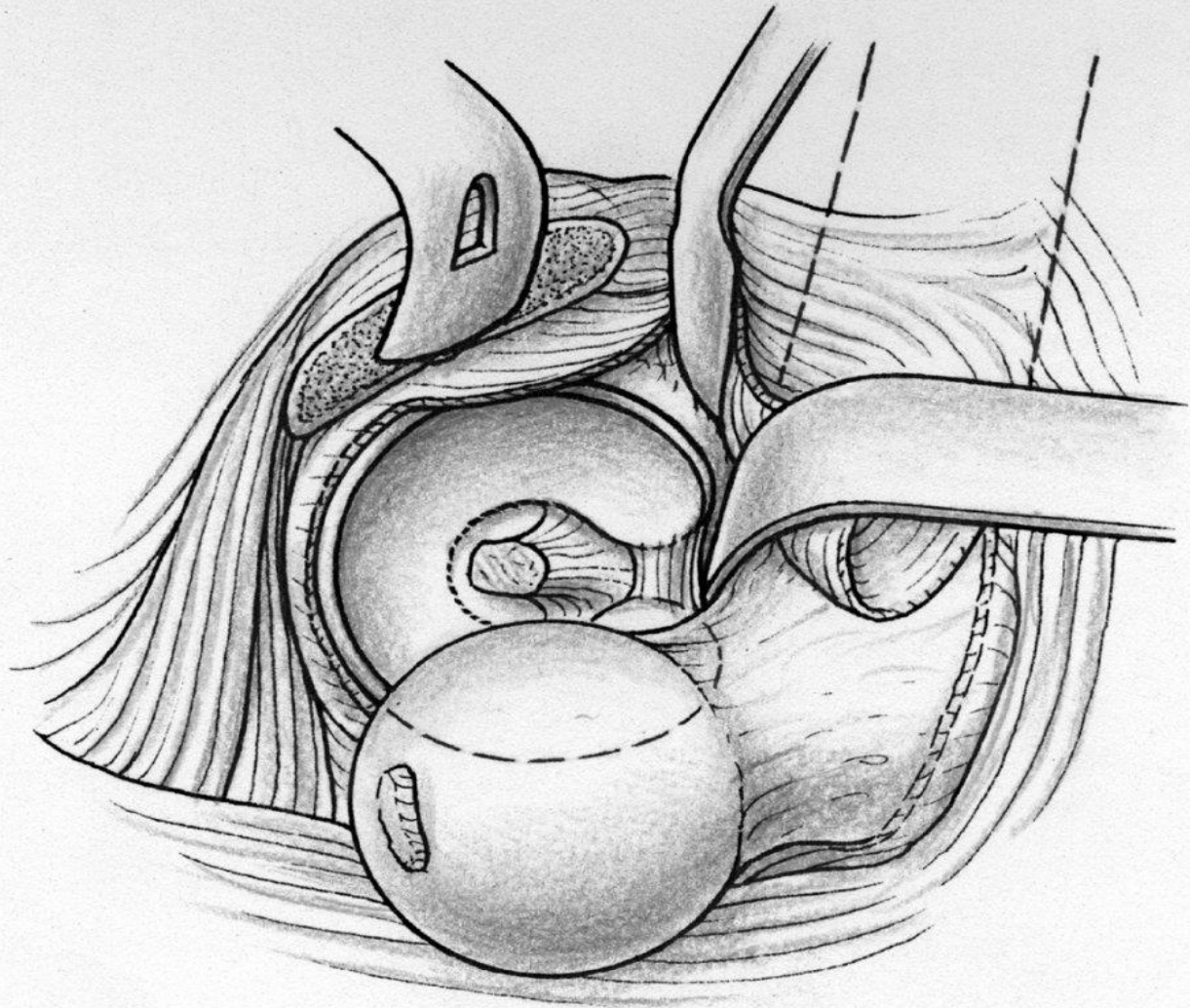


piriformis muscle

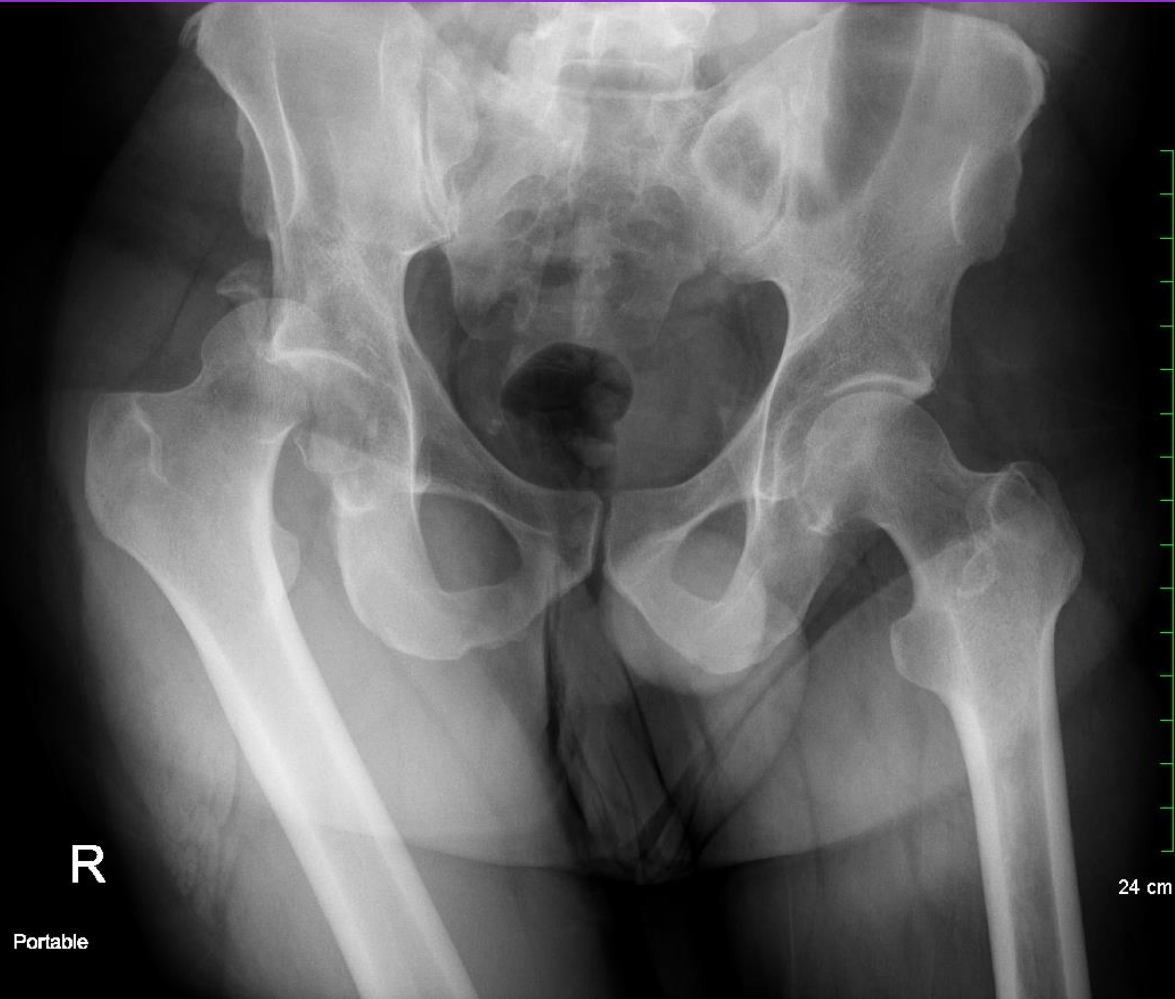

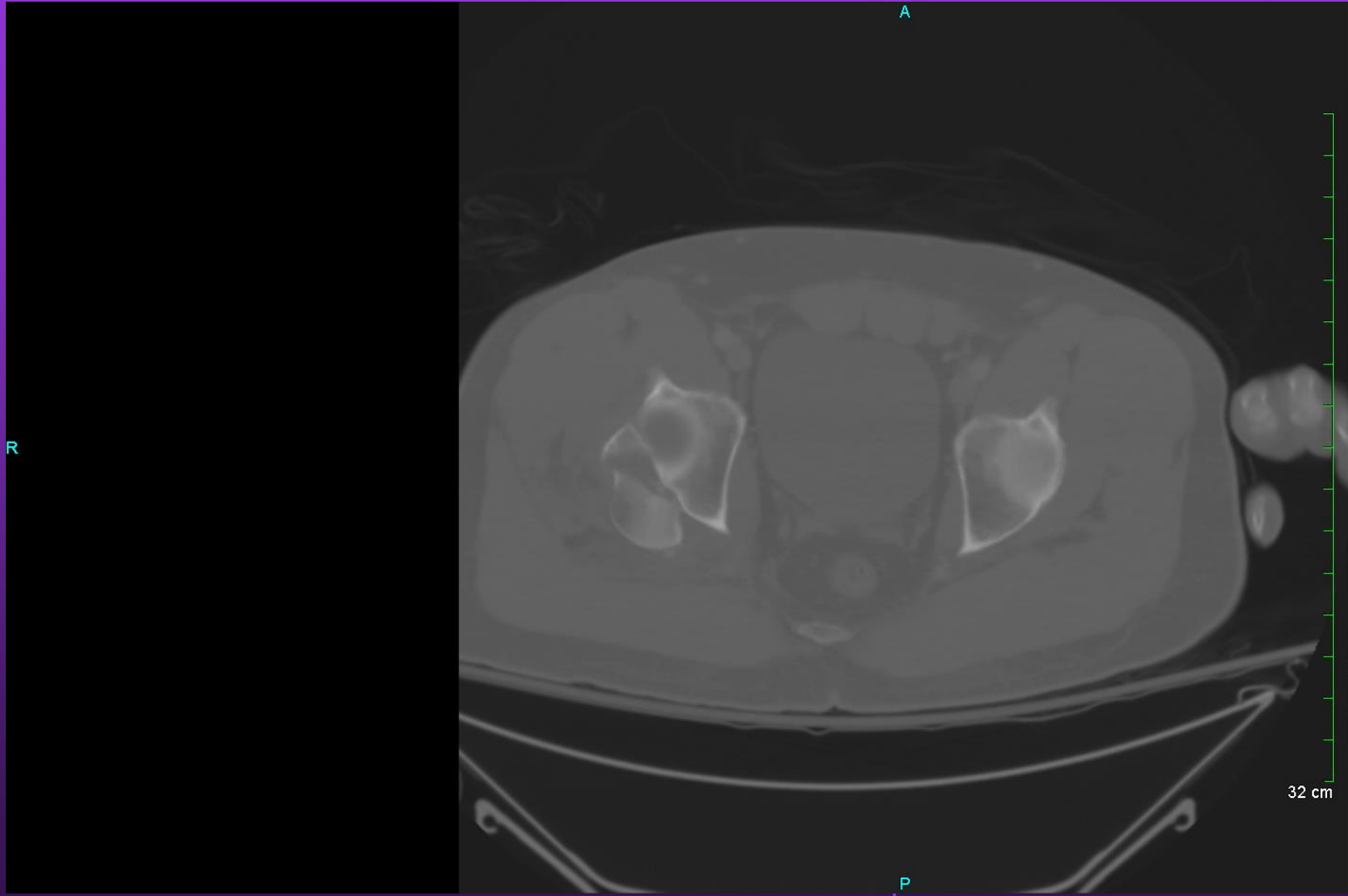
capsulotomy

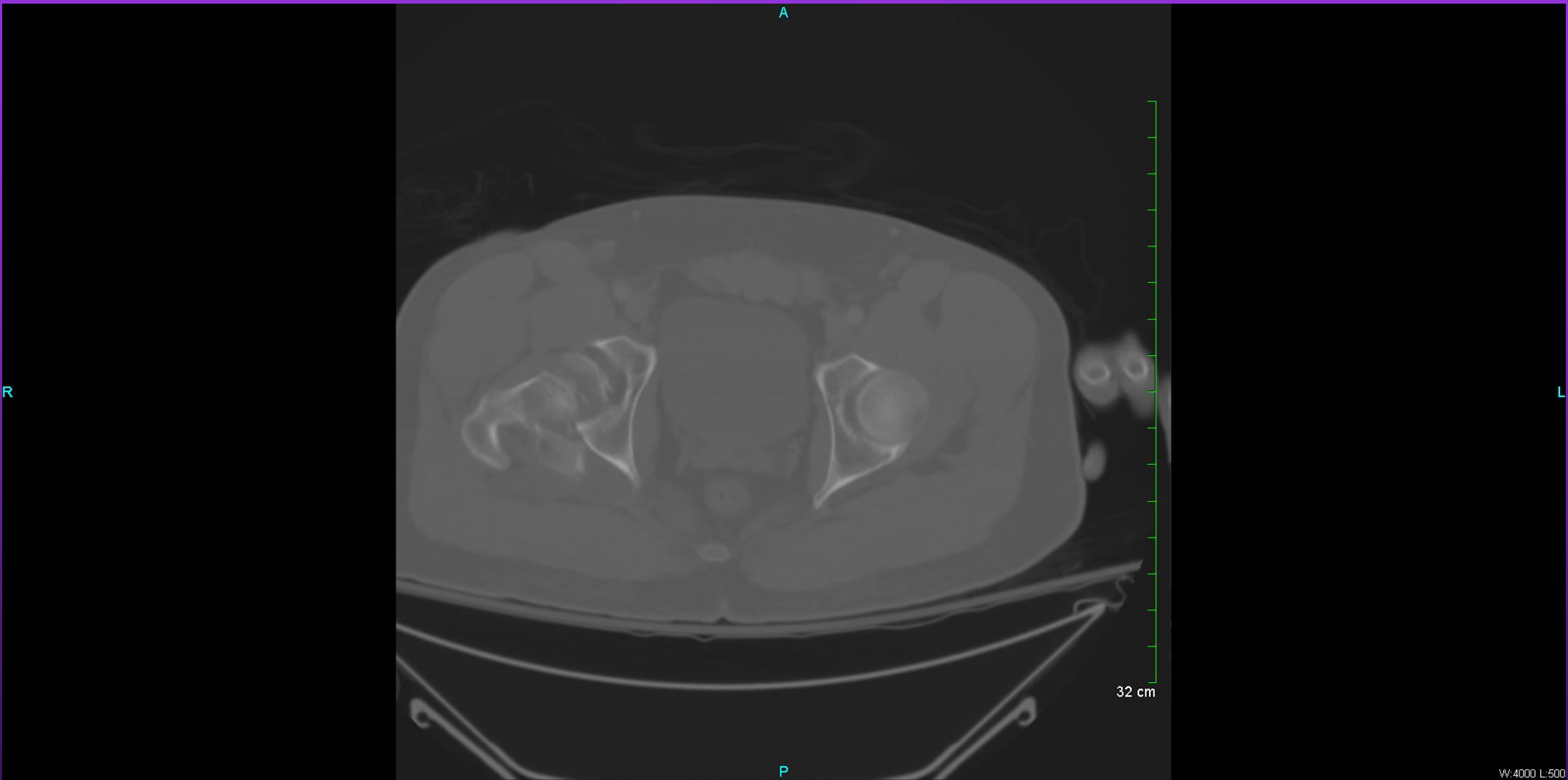




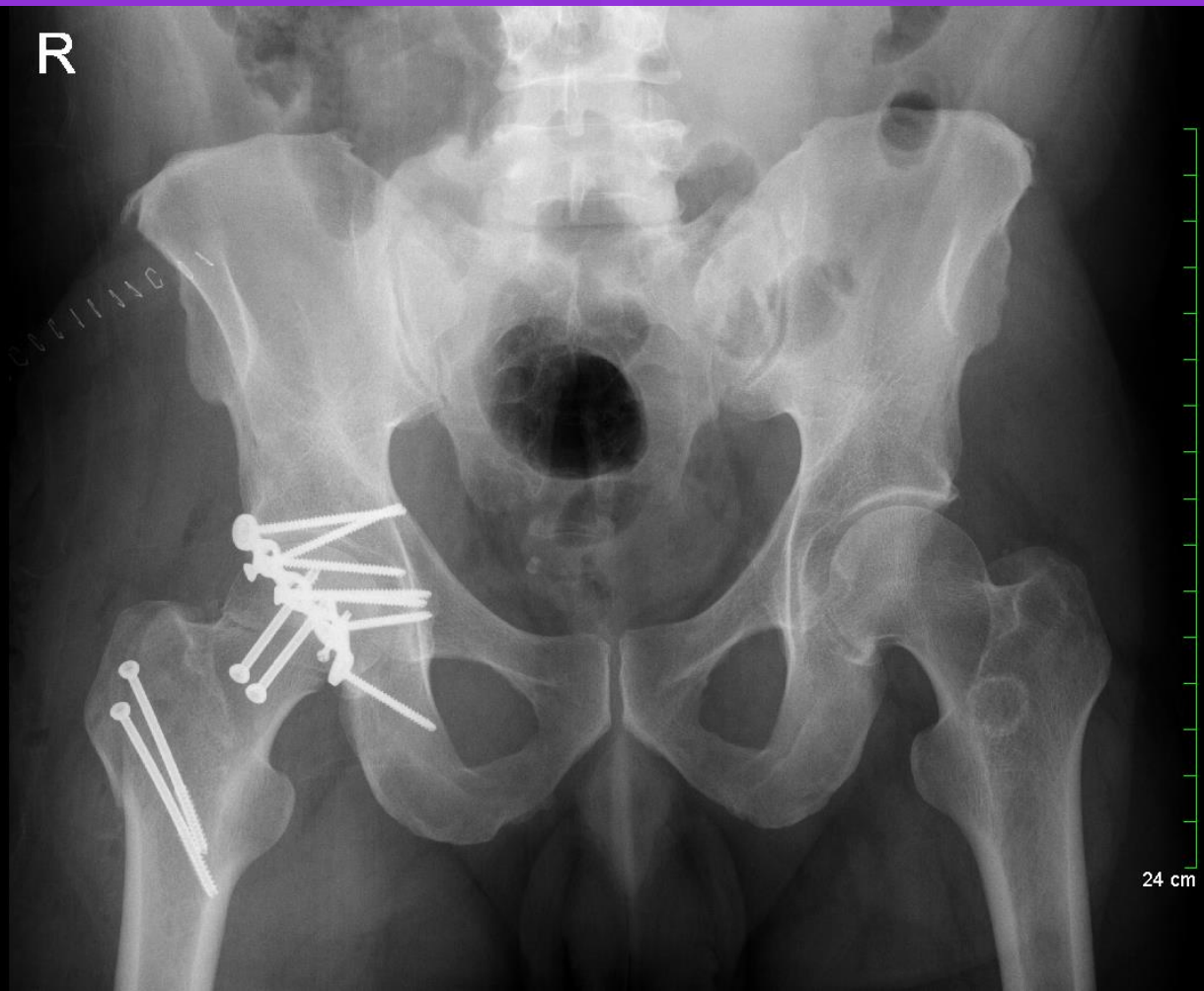41yo MVA RS







2/5/18 FH, FN, PW

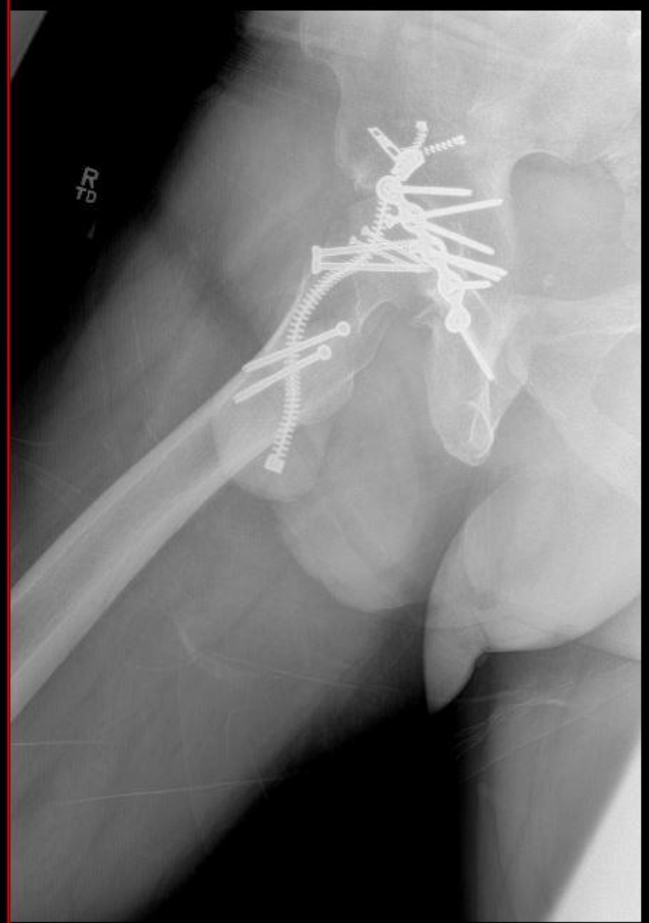
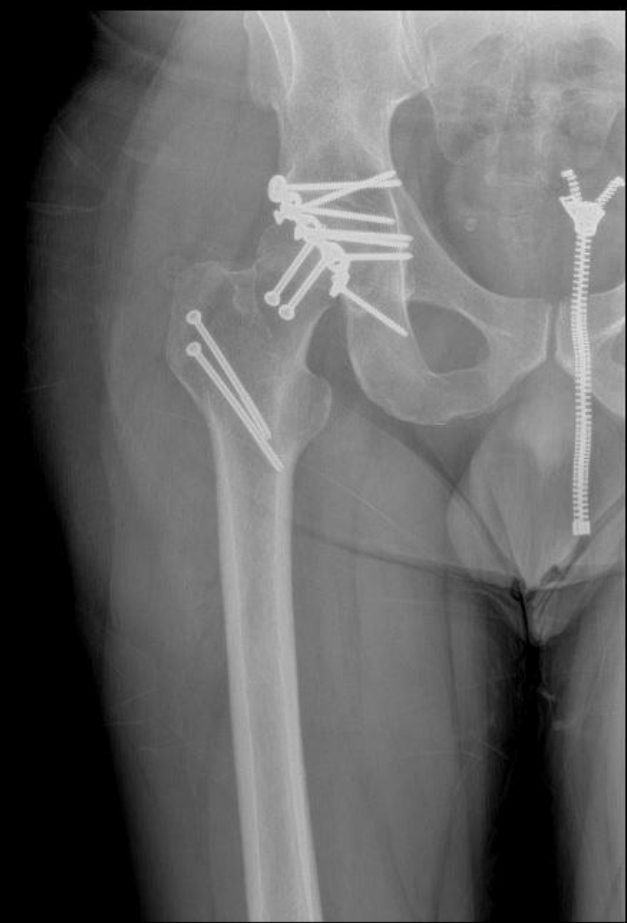
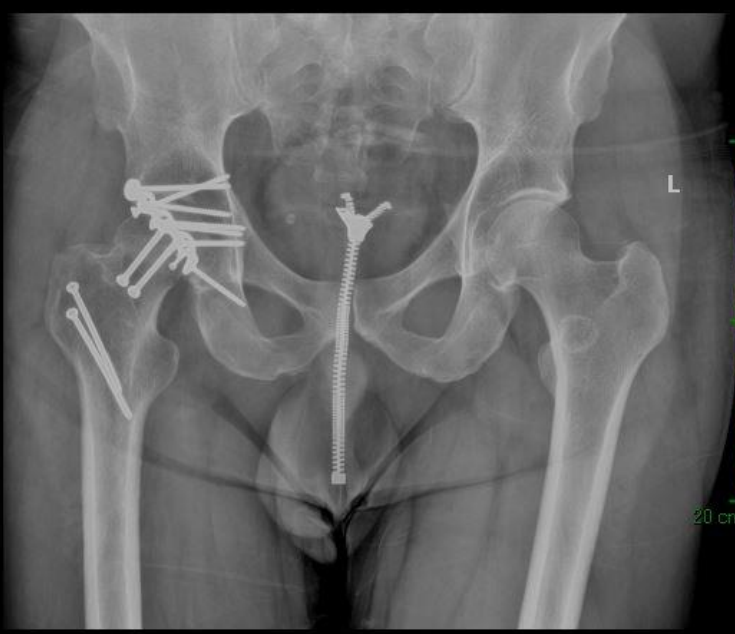< 4-4 (ALL) >

< 5-5 (ALL) >

< 6-6 (ALL) >

>3 months



Rel X Ray Exp: 1007

C 3793 Rel X Ray Exp: 1768
 W 15428

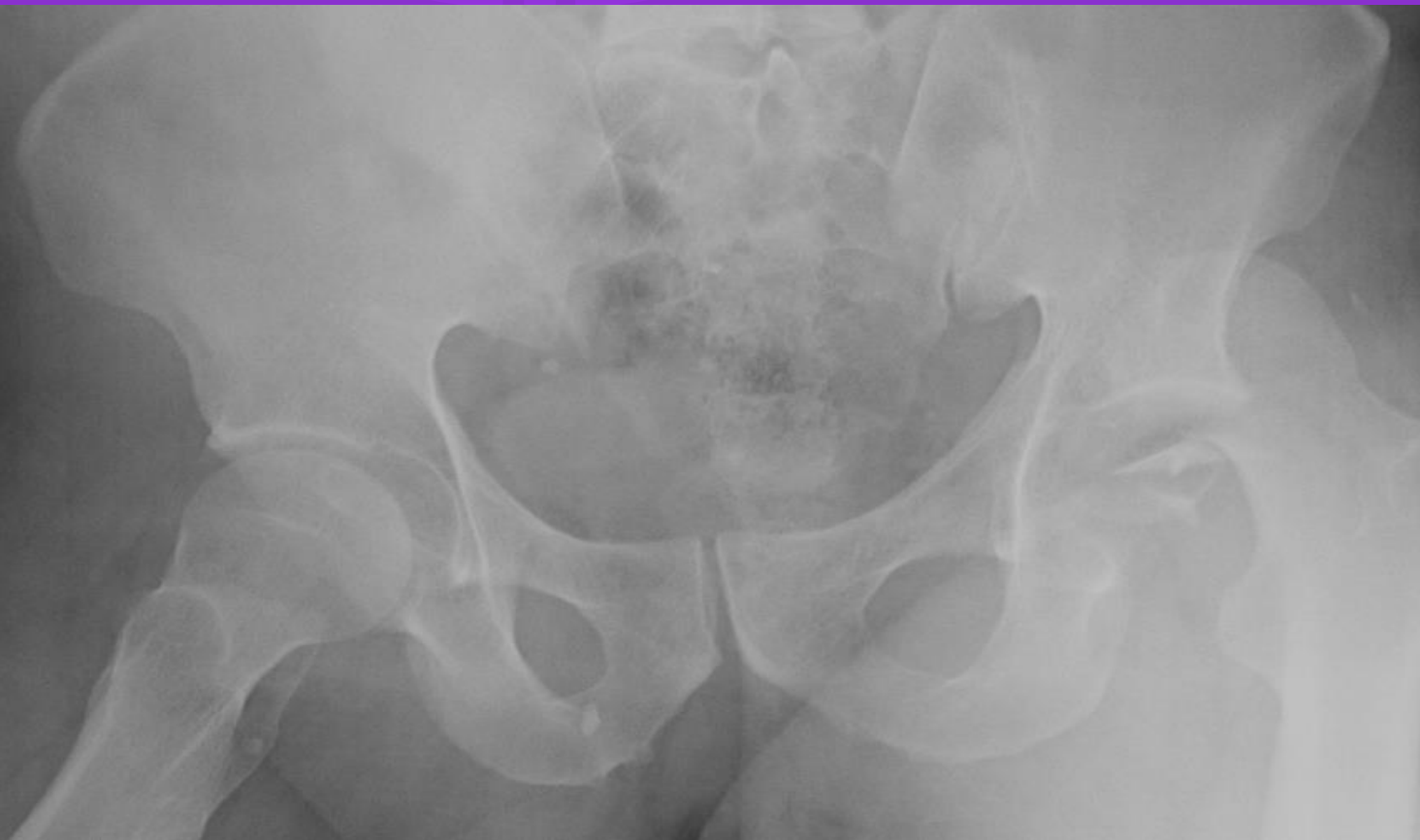C 6353 Rel X Ray Exp: 1638
 W 16206

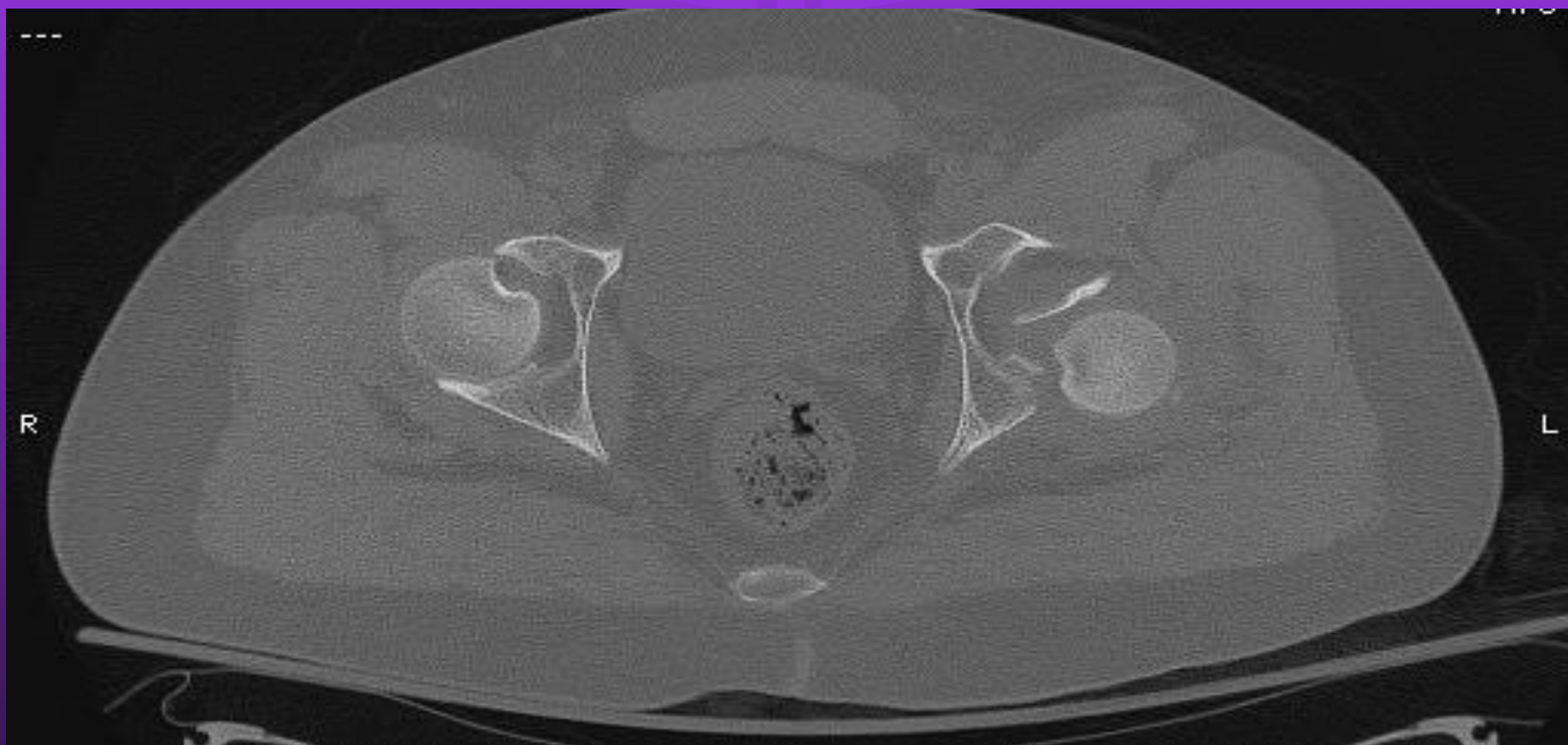
FM

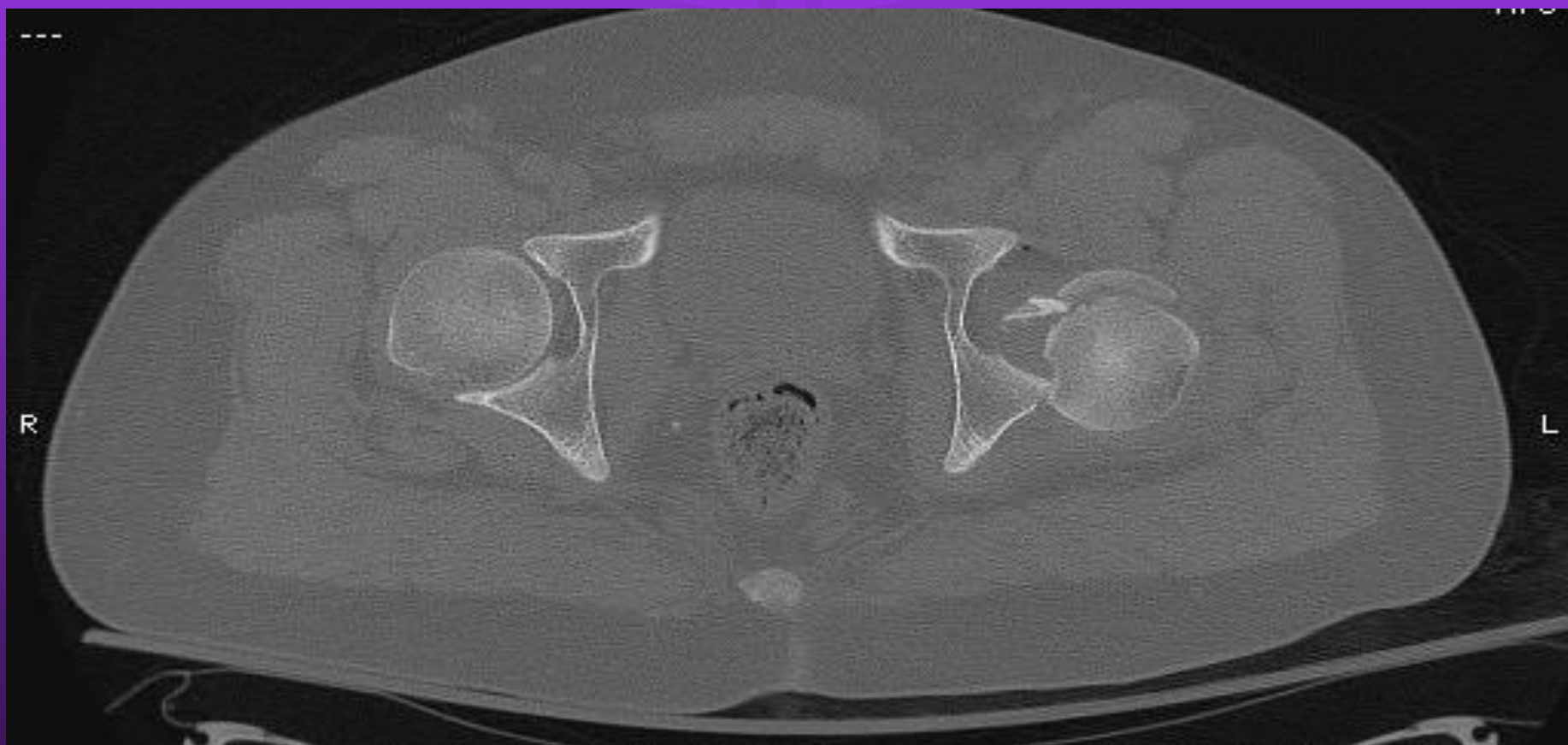
- 38 yo intoxicated pedestrian struck by motor vehicle
- Sustained Pipkin 4 fracture dislocation of hip with posterior wall fracture and irreducible dislocation

SUPINE

**SR5
76@80
0413**

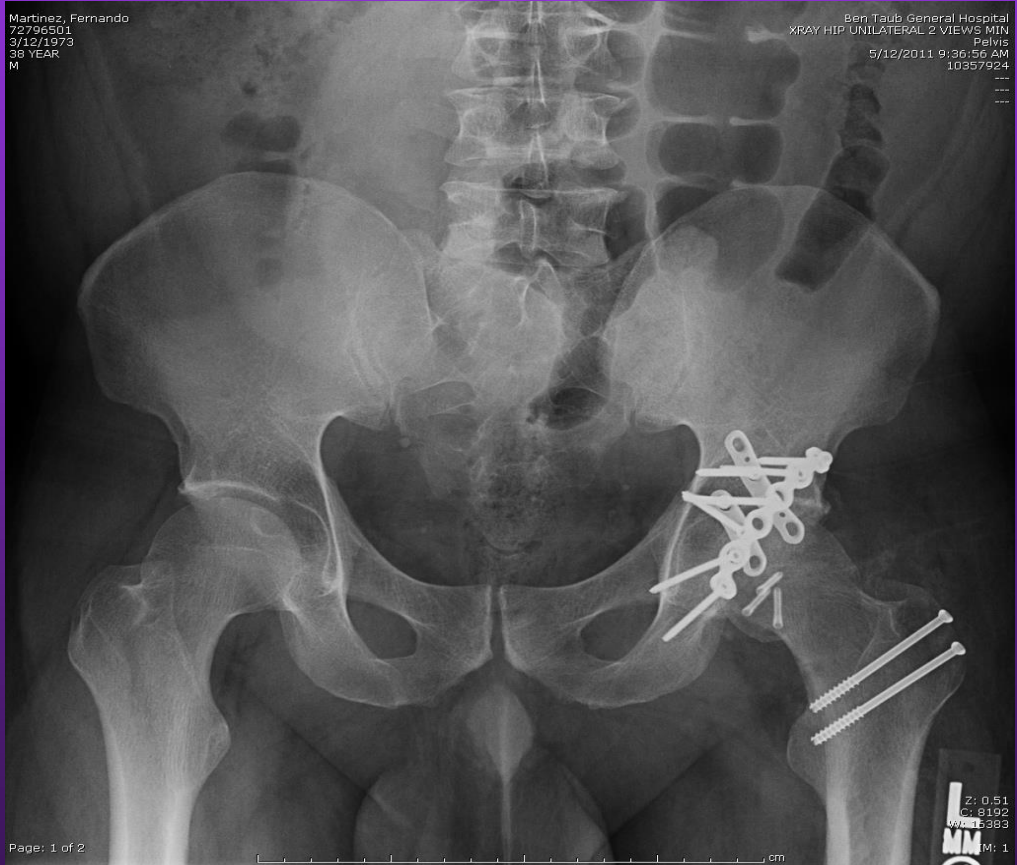





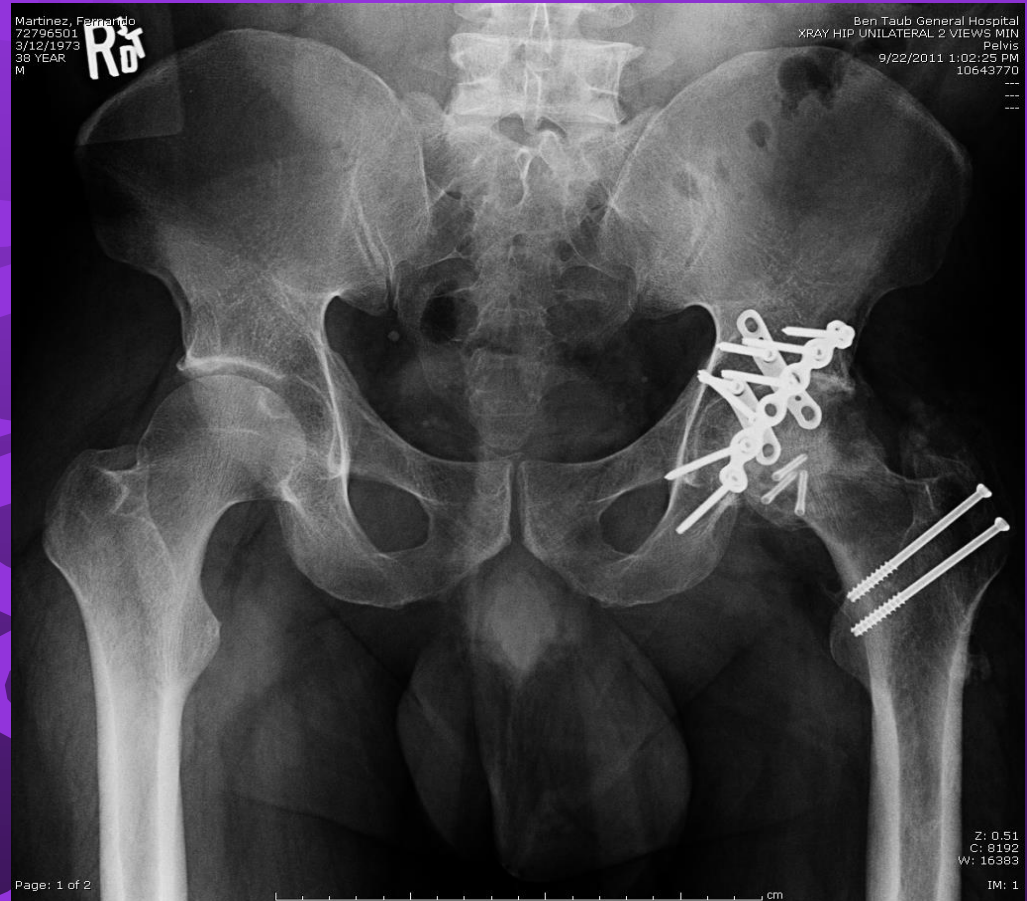OR

- Trochanteric osteotomy with surgical hip dislocation
- Femoral head fracture repaired with 3 Acutrak screws
- Marked comminution and chondral injury to posterior wall articular surface
- Posterior wall fixed with 2 hook plates and 6 hole pelvic recon plate



Post-Op Course

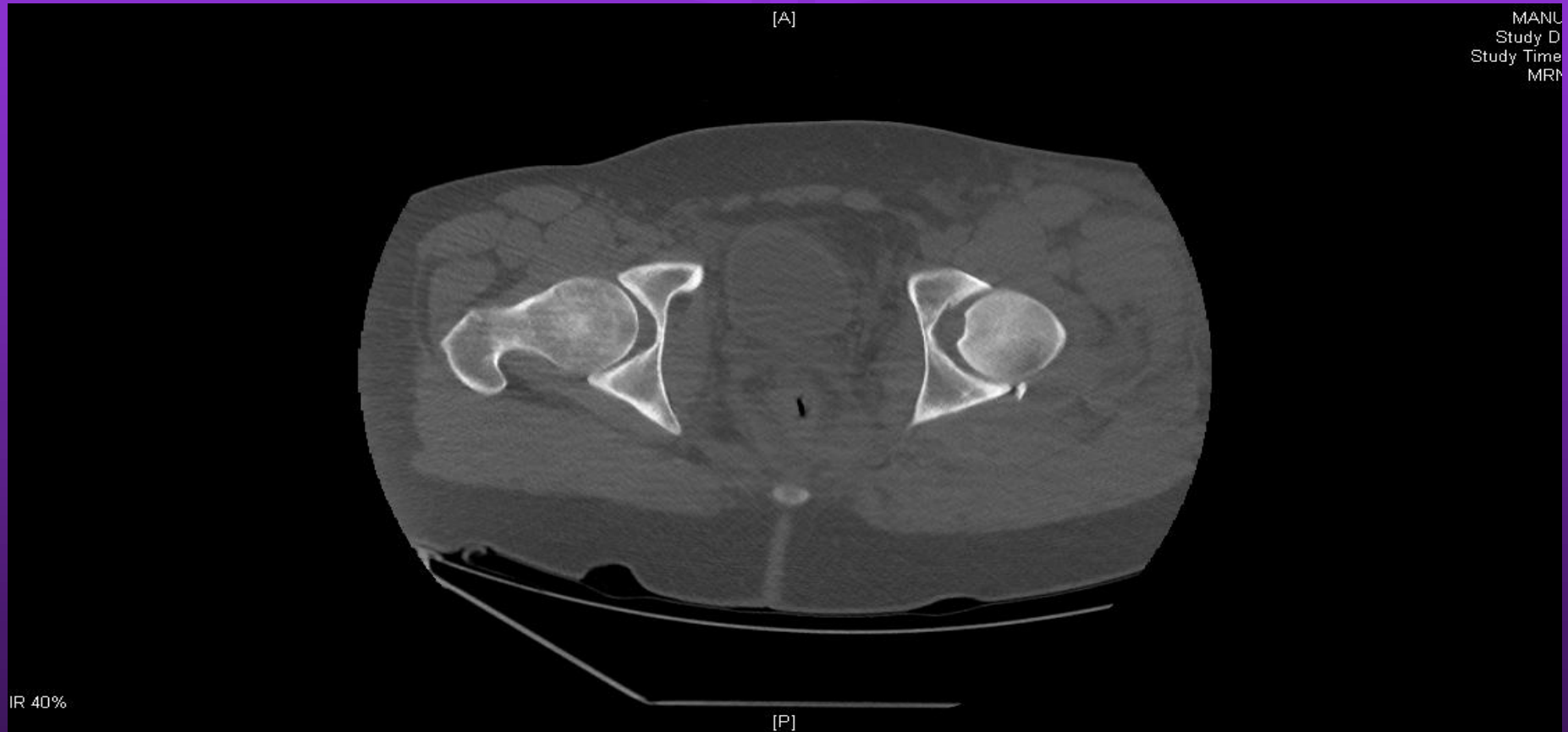
- TDWB 3 months
- Seen at 5 months follow up with no significant pain or limitations
- Stable HO seen



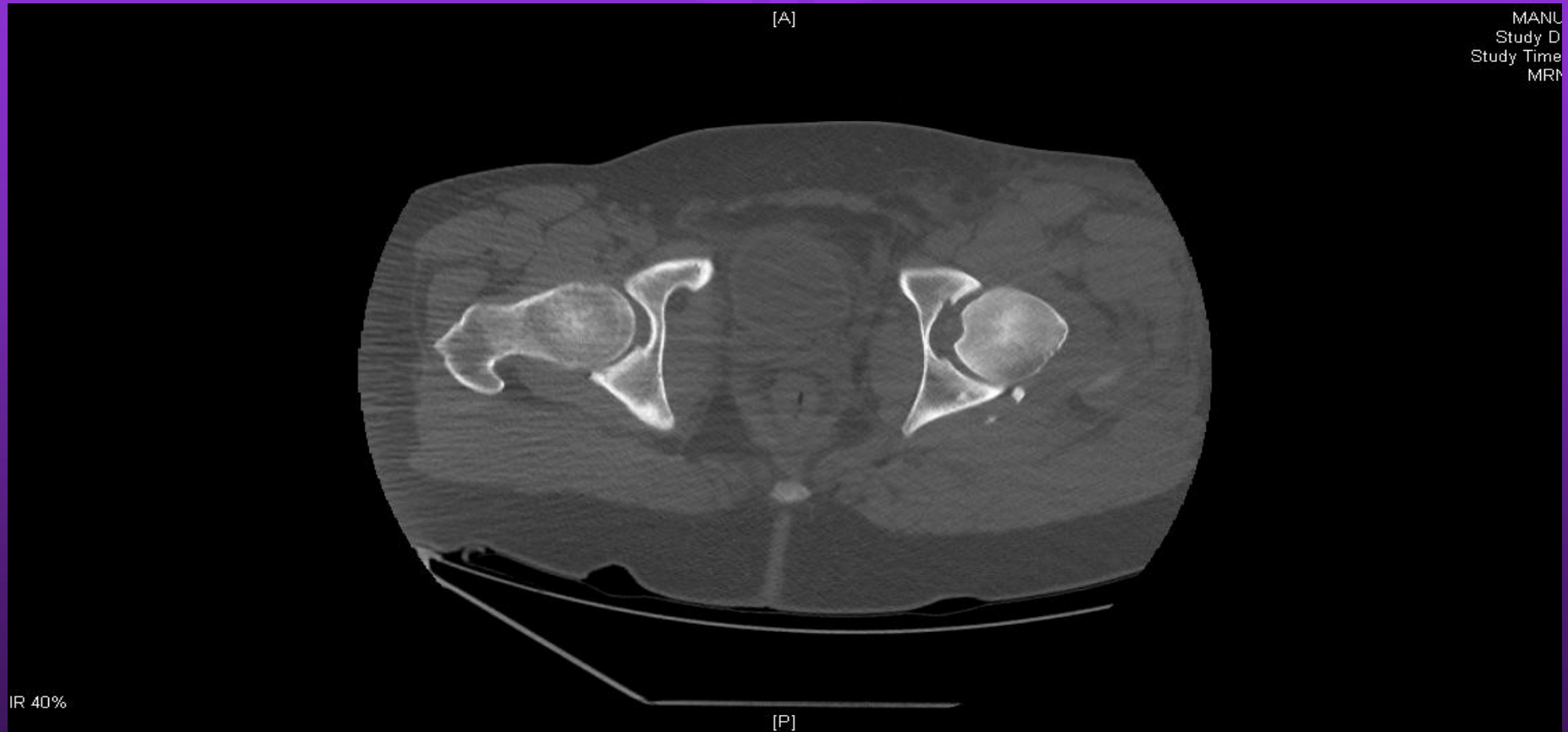
BM

- 21 yo healthy male, s/p MVA (passenger)
- Posterior hip dislocation, closed reduced at outside hospital and transferred
- Left femoral head fracture with posterior wall fracture

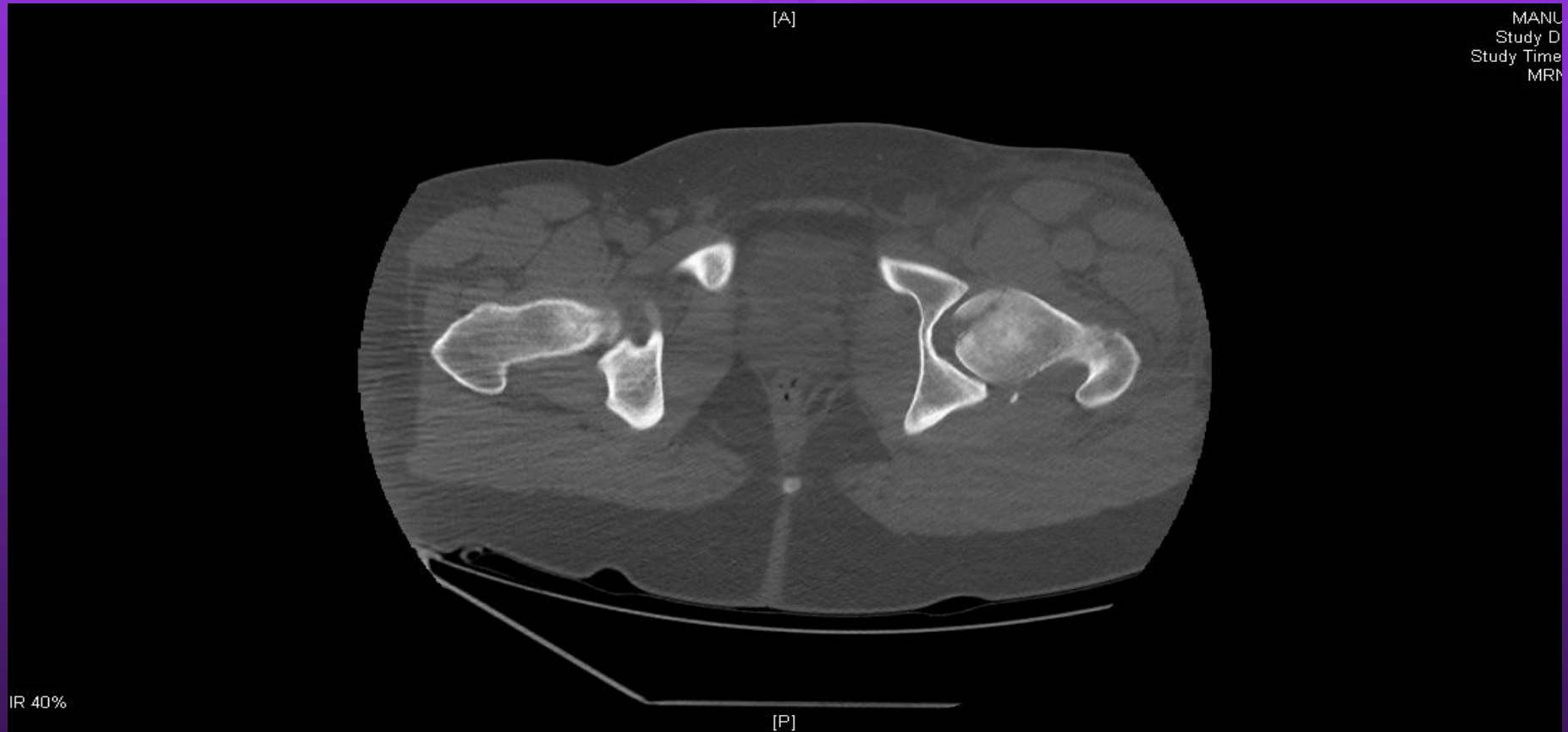
Post-Reduction CT



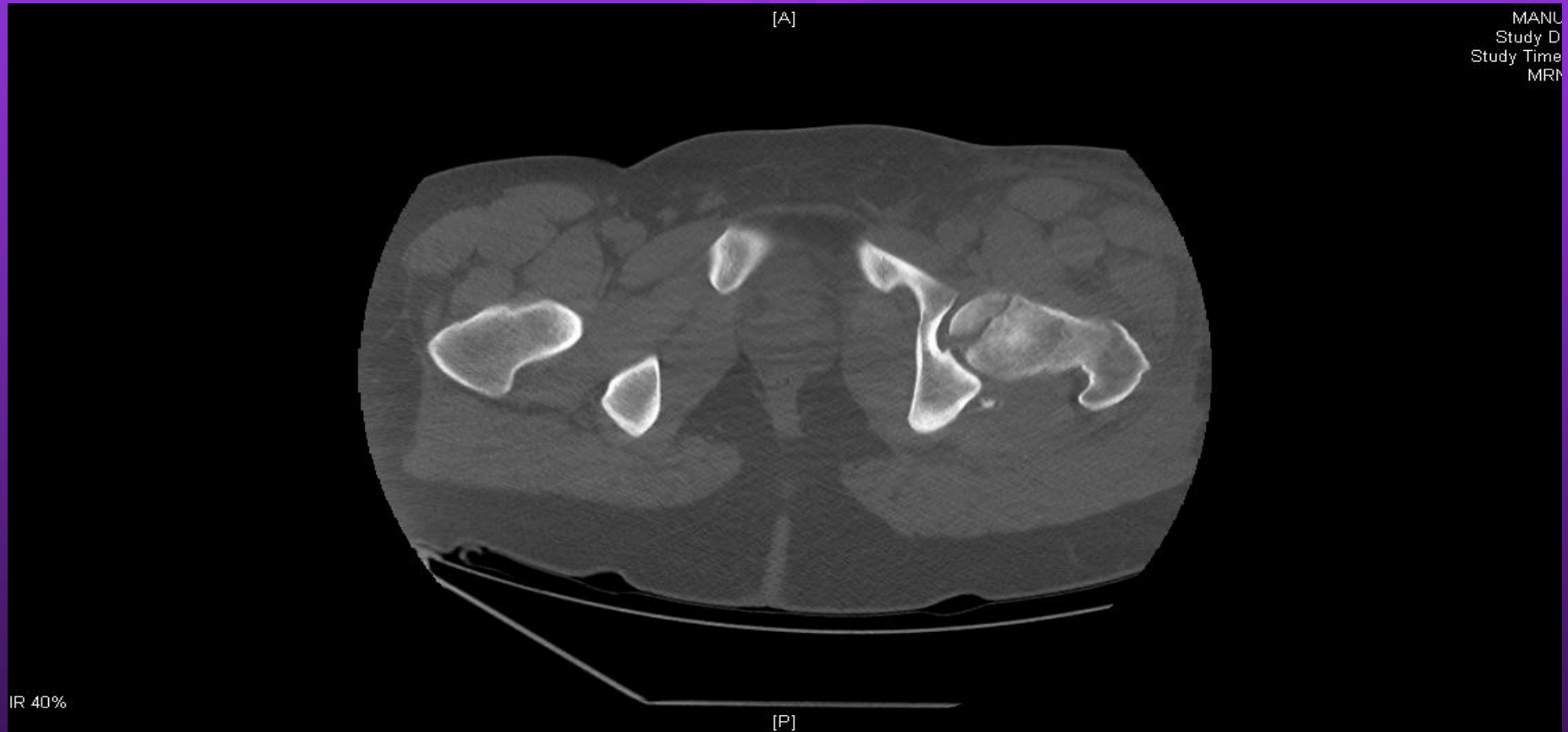
Post-Reduction CT



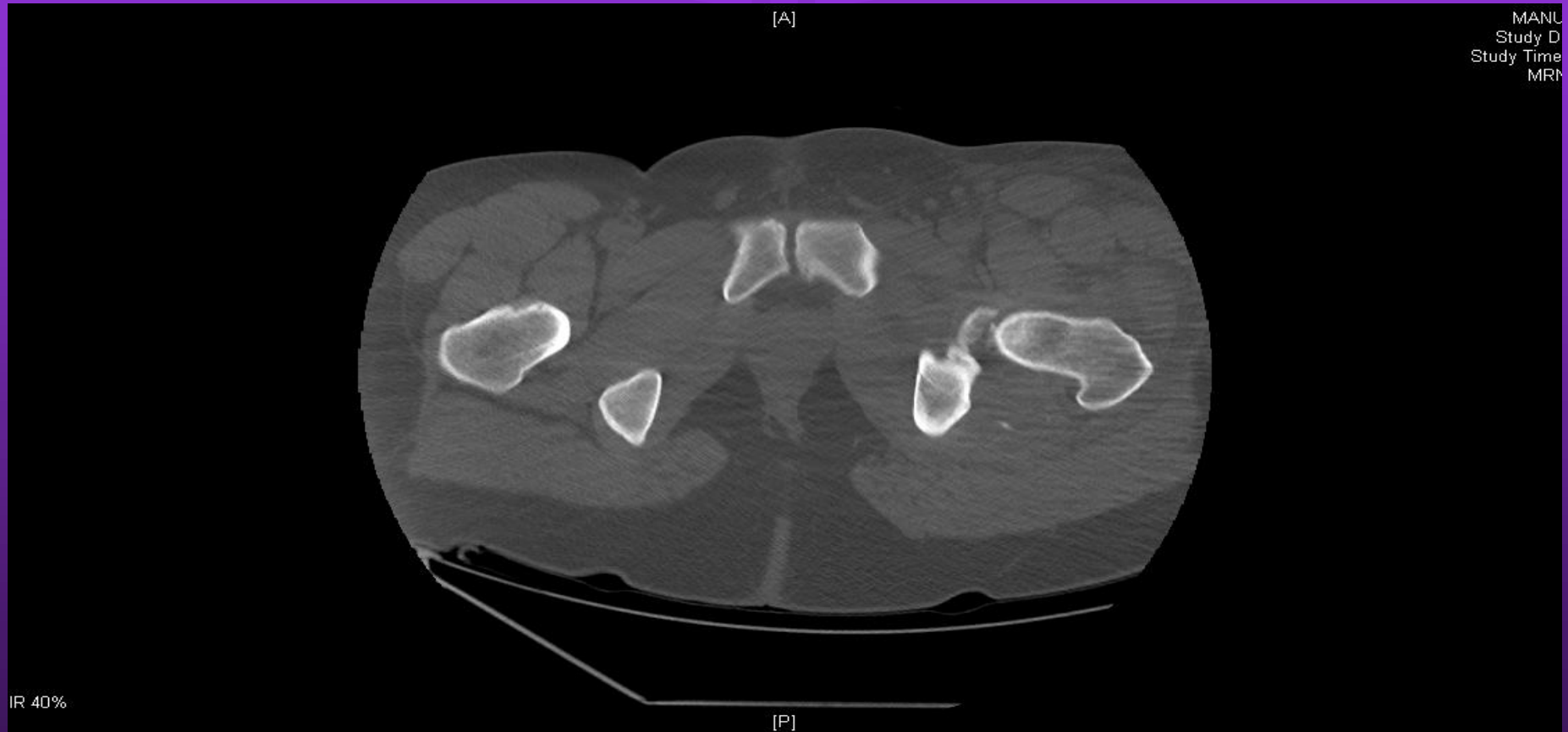
Post-Reduction CT



Post-Reduction CT



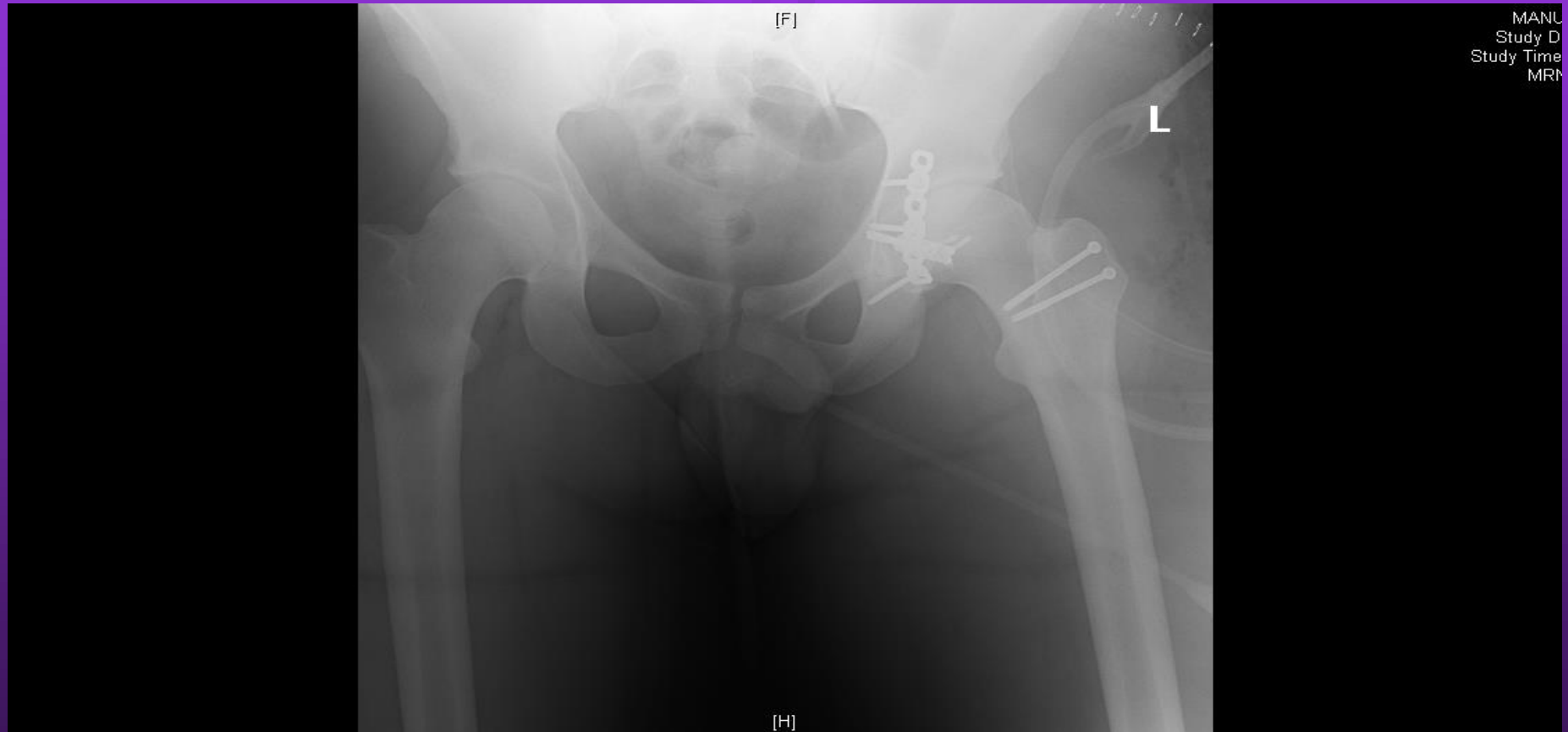
Post-Reduction CT

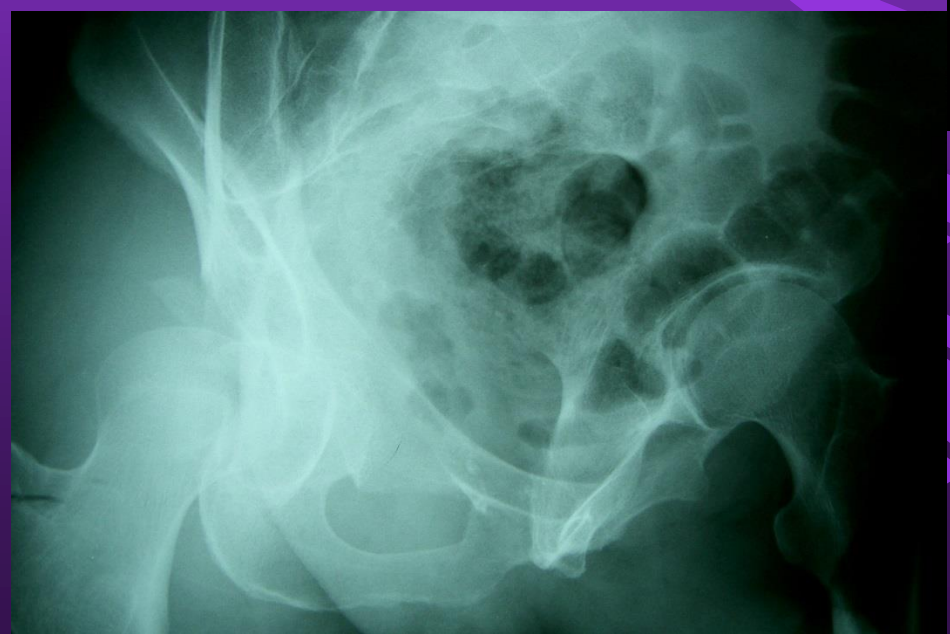
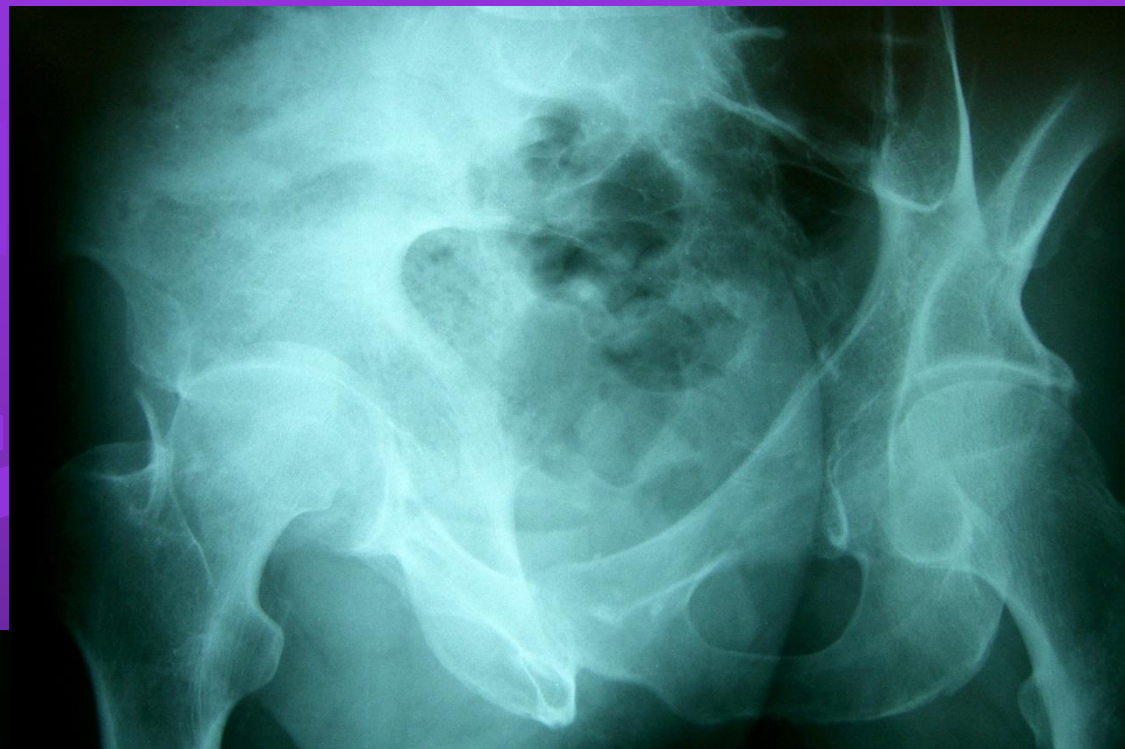
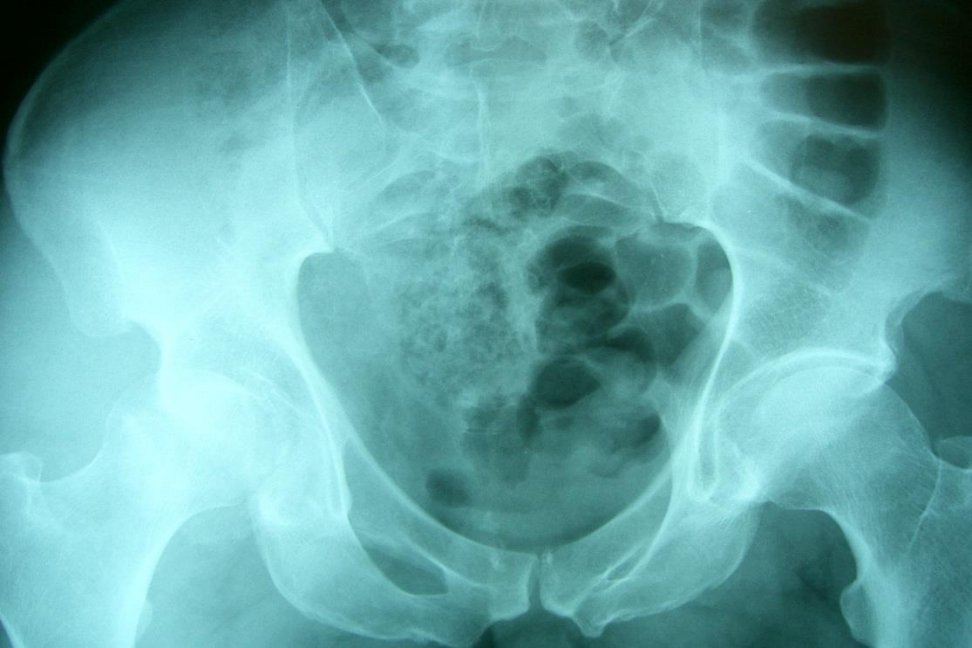OR

- Kocher-Langenbeck approach with greater trochanteric osteotomy and surgical dislocation
- Fixation with 3.0 cannulated screws followed by fixation of posterior wall with spring plate and 5-hole recon plate

Post-Op

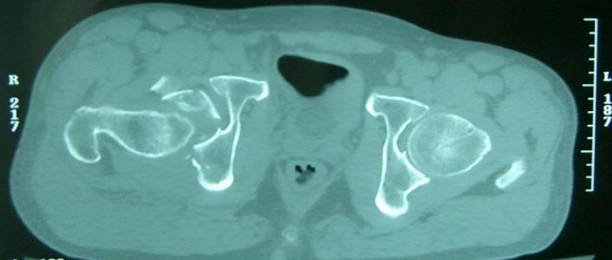



AP
Lateral
Oblique

Large
2.500mm/3.75 0.75:1
Tilt: 0.0
1.0s /HE 12:59:49/42.56
W:2000 L:300
P 150

LightSpeed Plus SYS#CT99_000 A 219 Tulane Univ. Medical Center
Ex: 25146
Se: 2
IC 1338.29
Im: 89
DOB: Jan 11 1960
Dec 30 2004
512
DFOV 42.0cm
BONE



kv 120
mA 275

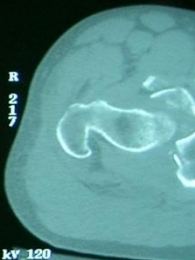
Large
2.500mm/3.75 0.75:1
Tilt: 0.0
1.0s /HE 12:59:49/44.59
W:2000 L:300
P 167

LightSpeed Plus SYS#CT99_000 A 219 Tulane Univ. Medical Center
Ex: 25146
Se: 2
IC 1345.89
Im: 93
DOB: Jan 11 1960
Dec 30 2004
512
DFOV 42.0cm
BONE

LightSpeed Plus SYS#CT99_000 A 219 Tulane Univ. Medical Center

Large
2.500mm/3.75 0.75:1
Tilt: 0.0
1.0s /HE 12:59:49/43.07
W:2000 L:300

LightSpeed Plus SYS#CT99_000 A 219 Tulane Univ. Medical Center
Ex: 25146
Se: 2
IC 1340.19
Im: 90
DOB: Jan 11 1960
Dec 30 2004
512
DFOV 42.0cm
BONE



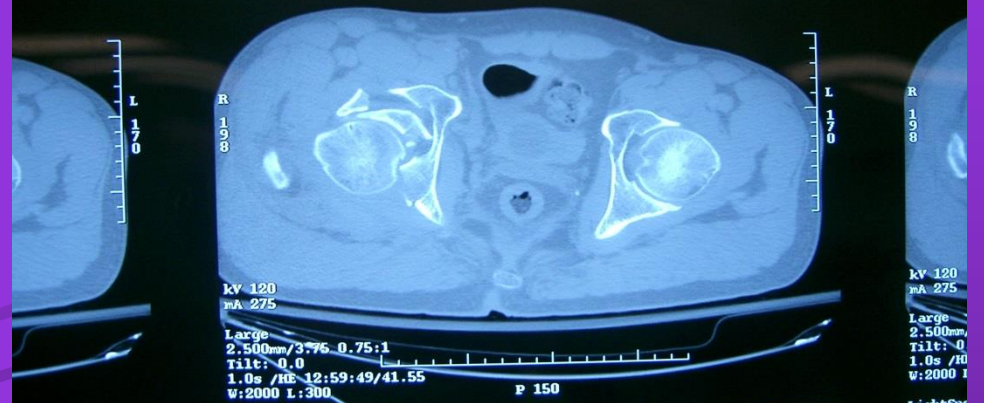kv 120
mA 275

Large
2.500mm/3.75 0.75:1
Tilt: 0.0
1.0s /HE 12:59:49/45.10
W:2000 L:300

LightSpeed Plus SYS#CT99_000 A 219 Tulane Univ. Medical Center
Ex: 25146
Se: 2
IC 1347.79
Im: 94
DOB: Jan 11 1960
Dec 30 2004
512
DFOV 42.0cm
BONE

LightSpeed Plus SYS#CT99_000 A 219 Tulane Univ. Medical Center

Medical Center LightSpeed Plus SYS#CT99_000 A 218 Tulane Univ. Medical Center LightSpeed Plus
Ex: 25146 Ex: 25146 Ex: 25146
Se: 2 Se: 2 Se: 2
IC 1326.89 IC 1328.7 IC 1328.7
Im: 83 Im: 84 Im: 84
DOB: Jan 11 1960 DOB: Jan 11 1960 DOB: Jan 11 1960
Dec 30 2004 Dec 30 2004 Dec 30 2004
512 512 512
DFOV 42.0cm DFOV 42.0cm DFOV 42.0cm
BONE BONE BONE
MF:1.1 MF:1.1 MF:1.1

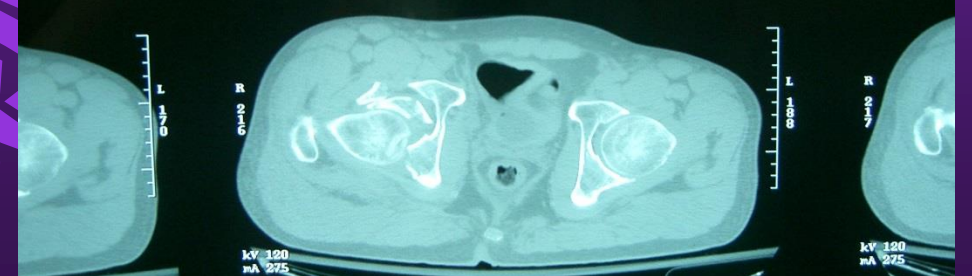

Medical Center
HALE, LARRY
M 44 D880084
DOB: Jan 11 1960
Dec 30 2004
512
DFOV 42.0cm
BONE

LightSpeed Plus SYS#CT99_000 A 219 Tulane Univ. Medical Center
Ex: 25146
Se: 2
IC 1334.49
Im: 88

Large
2.500mm/3.75 0.75:1
Tilt: 0.0
1.0s /HE 12:59:49/41.04
W:2000 L:300
P 150

LightSpeed Plus SYS#CT99_000 A 219 Tulane Univ. Medical Center
Ex: 25146
Se: 2
IC 1332.59
Im: 86
DOB: Jan 11 1960
Dec 30 2004
512
DFOV 42.0cm
BONE




kv 120
mA 275

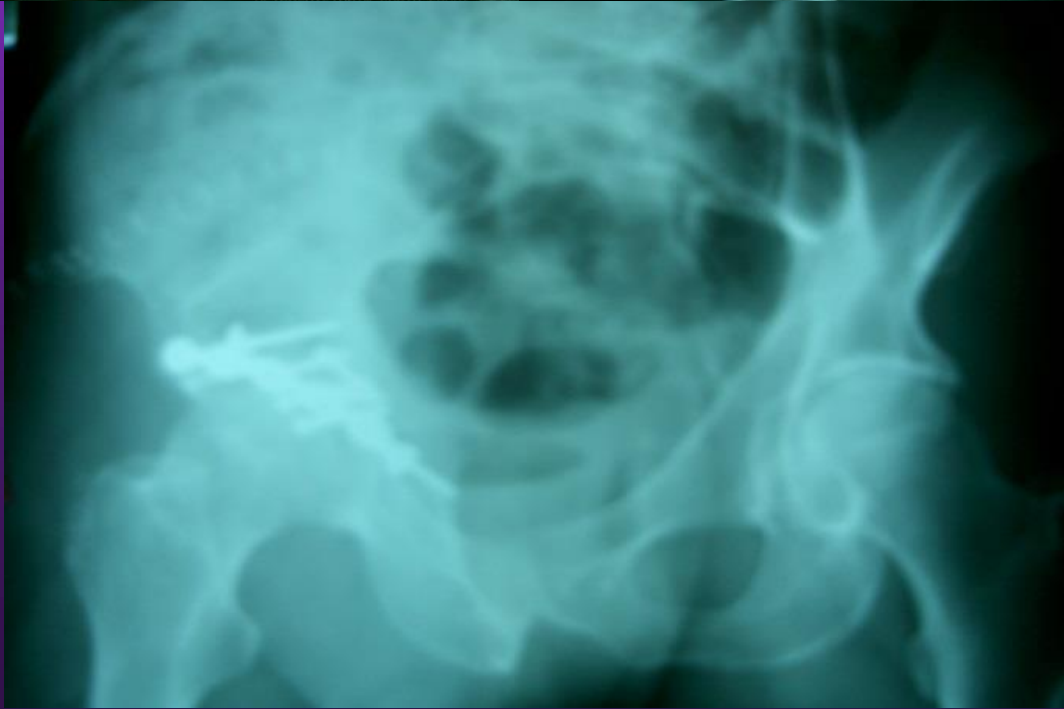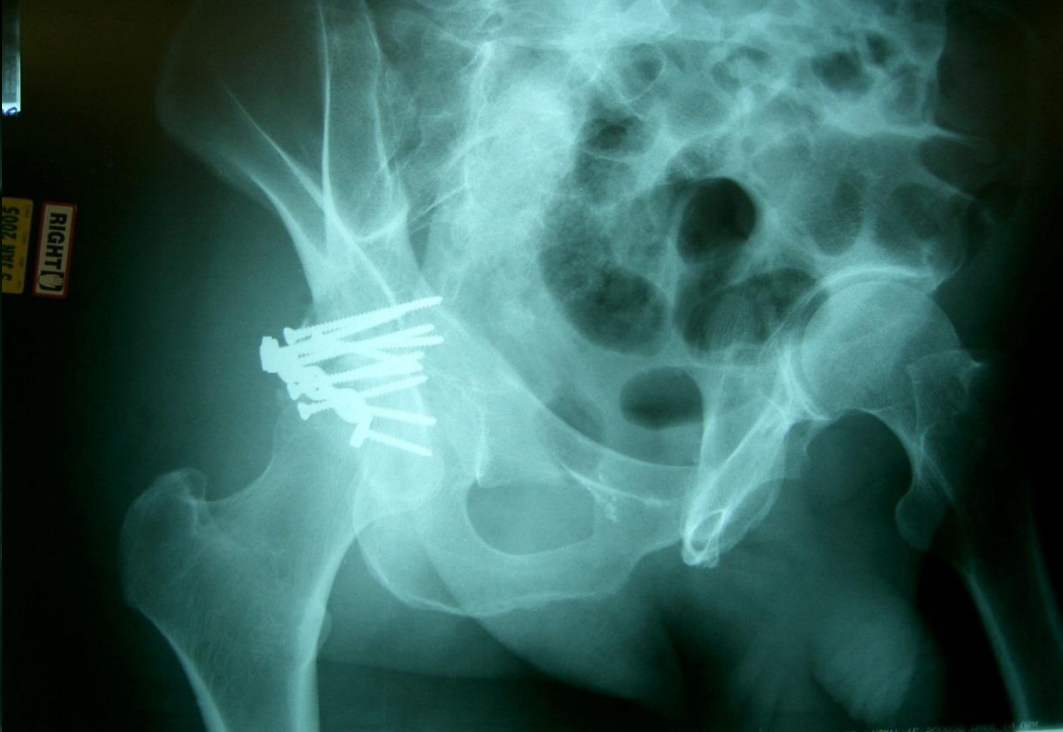
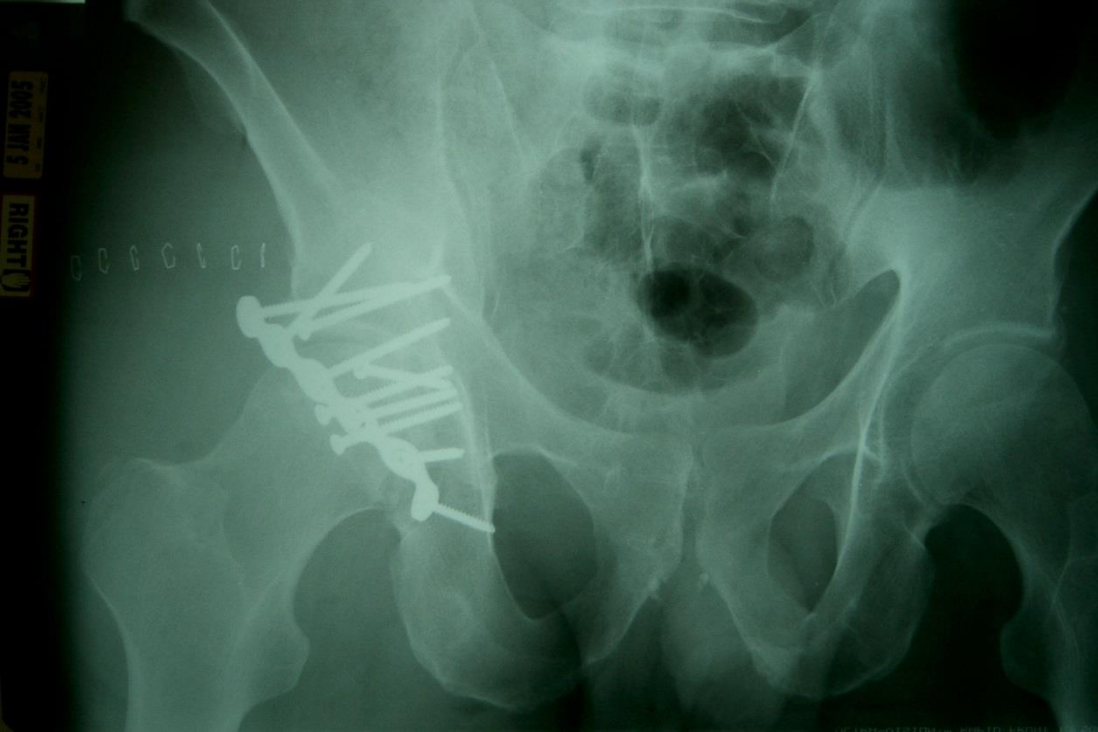
Large
2.500mm/3.75 0.75:1
Tilt: 0.0
1.0s /HE 12:59:49/43.07
W:2000 L:300
P 168

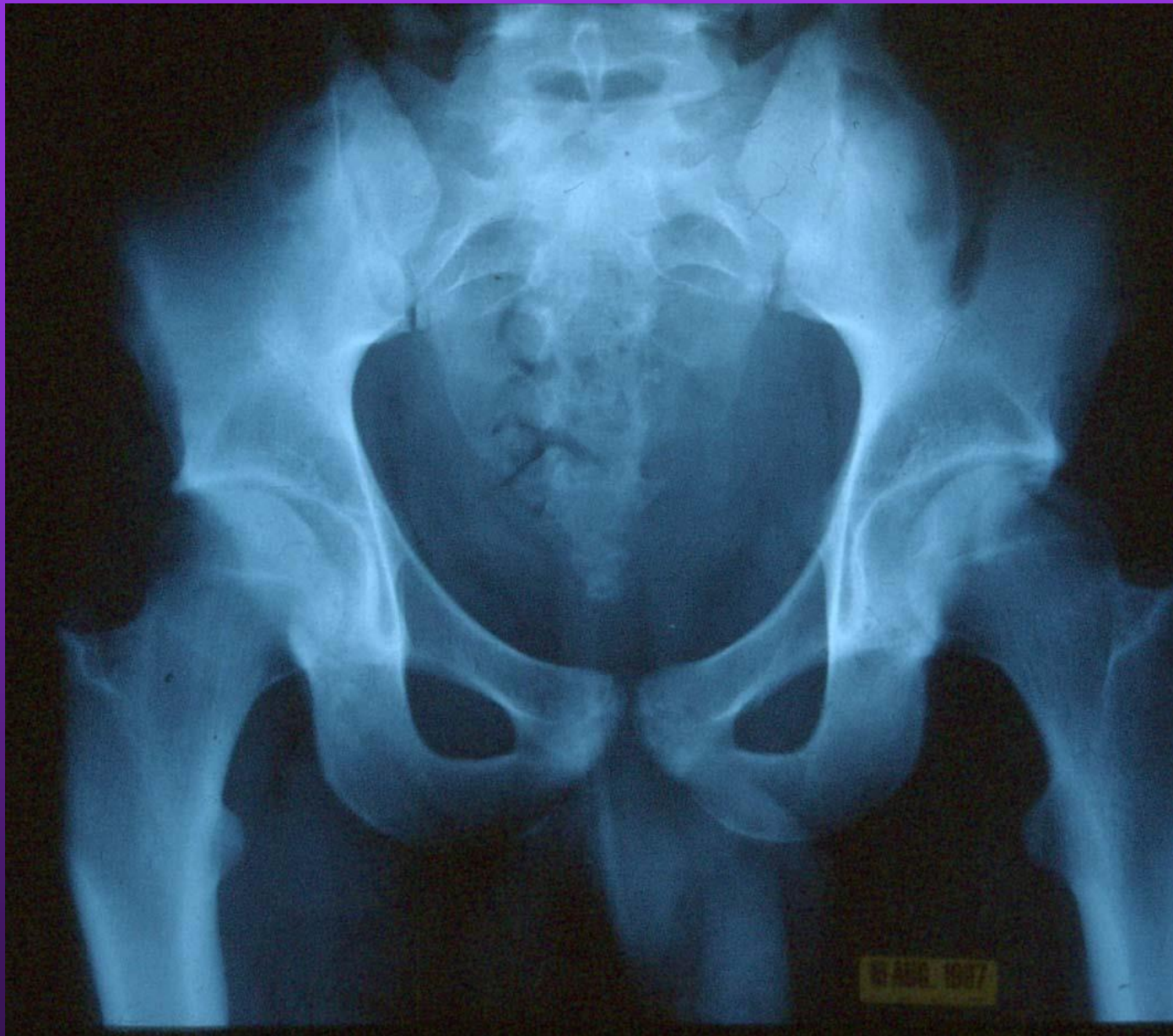LightSpeed Plus SYS#CT99_000 A 219 Tulane Univ. Medical Center
Ex: 25146
Se: 2
IC 1336.49
Im: 88

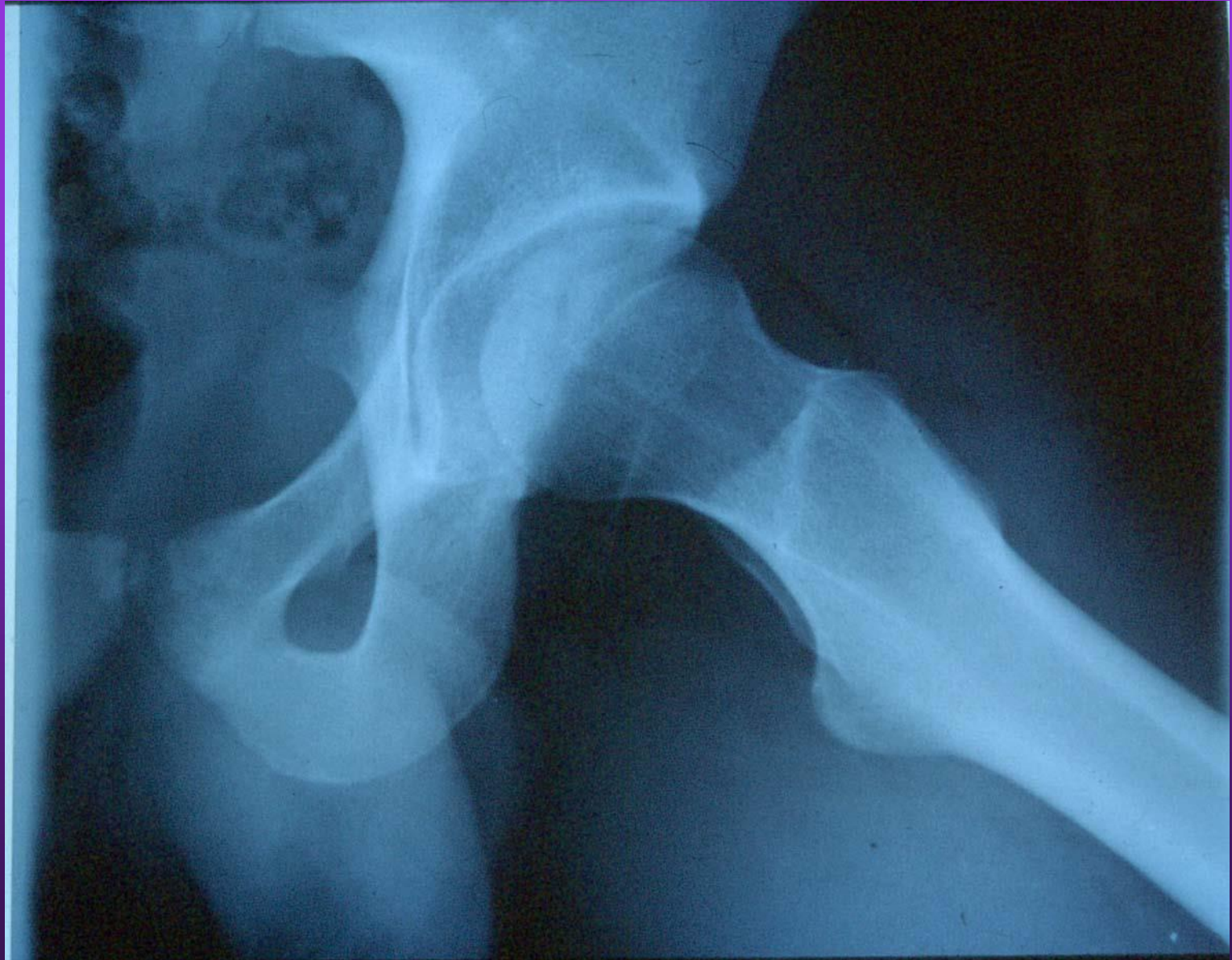Treatment

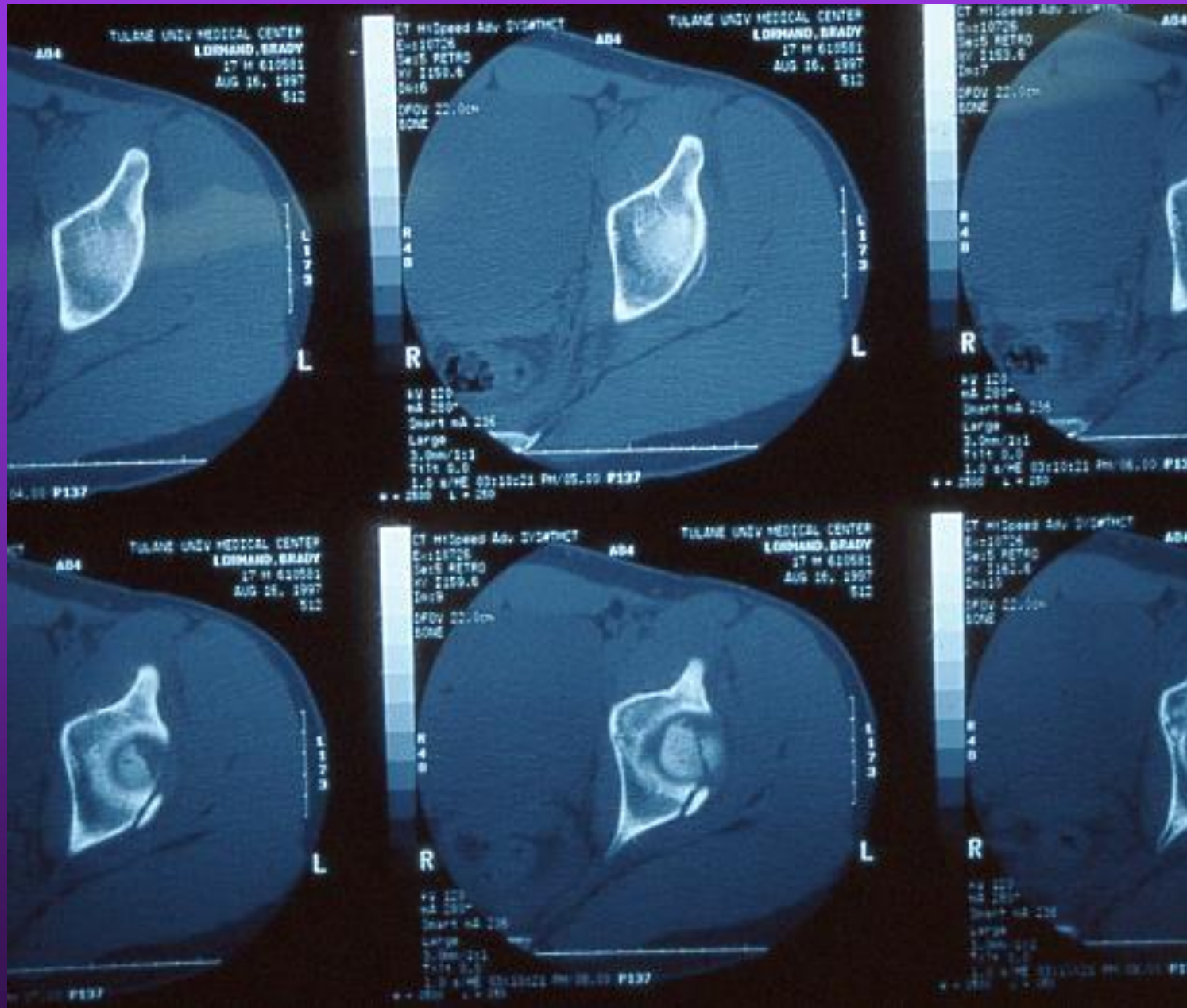
- KL followed by SP

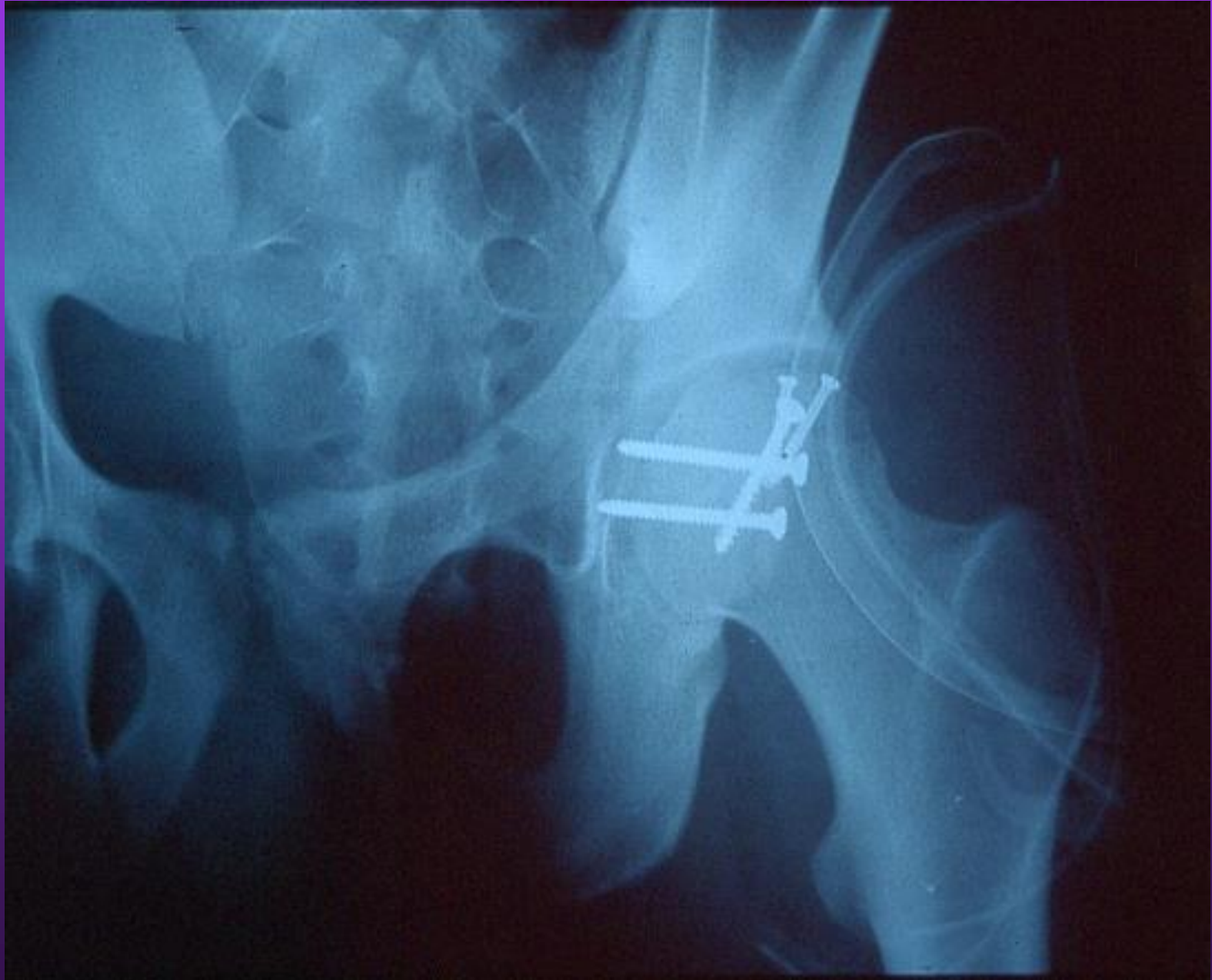




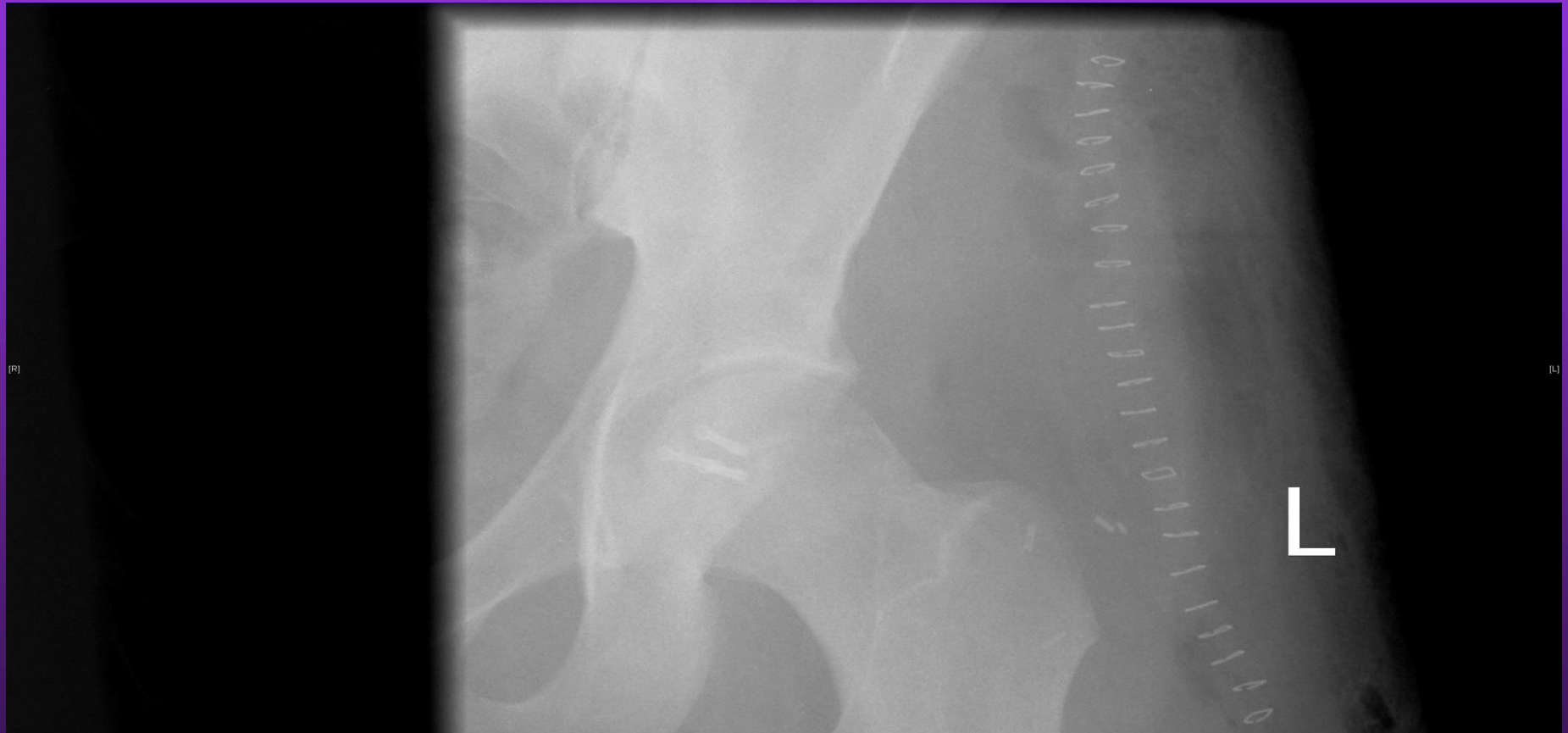



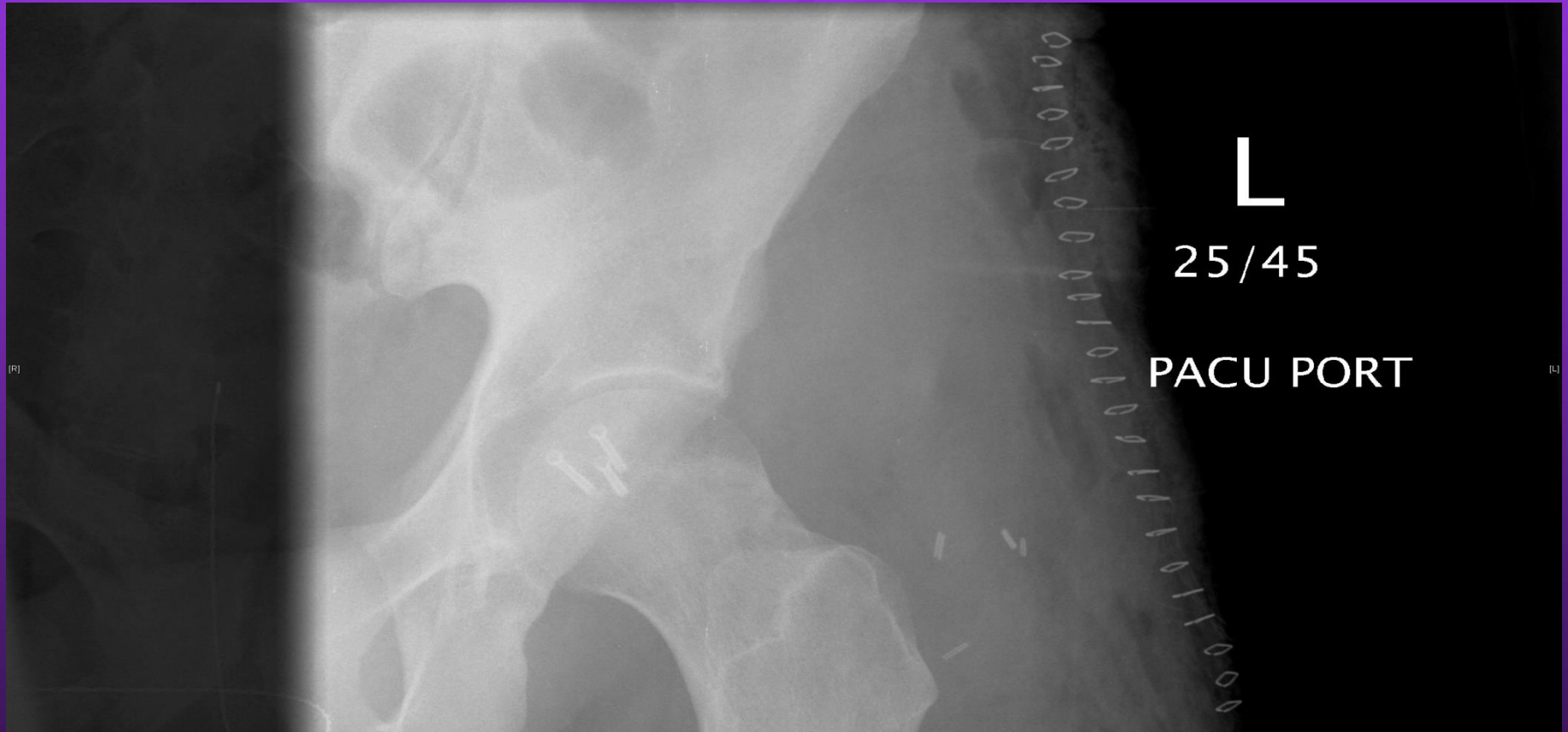




MC Post-Op



MC Post-Op



Treatment

- Pipkin 1- conservative (<2mm displaced after closed reduction posterior dislocation, >2mm excise)
- Pipkin 2- conservative (<1mm) most orif usually anterior
 - Always check femoral neck before reducing posterior hip dislocation

Treatment cont.

- Pipkin 3- conservative (<1mm) most orif of femoral neck and head through anterior approach
- Pipkin 4- orif of acetabular fracture and femoral head with KL, trochanteric slide, and surgical dislocation

