

Acetabulum Fractures

TIPS – Lessons Learned Over a Career

Steven A. Olson, MD

Goldner- Jones Distinguished Professor

Department of Orthopaedic Surgery

Duke University Health System

Acetabulum Fractures

TIPS – Lessons Learned Over a Career

HALF

Saam Morshed
UCSF

~~Steven A. Olson, MD
Goldner- Jones Distinguished Professor
Department of Orthopaedic Surgery
Duke University Health System~~

Disclosures

No Disclosures relevant to this presentation

Acknowledgement – mentors and patients that taught me.

Acetabular Fractures – Tips From a Career

Get good quality radiographs

Learn to read plain films

Look for reasons not to operate

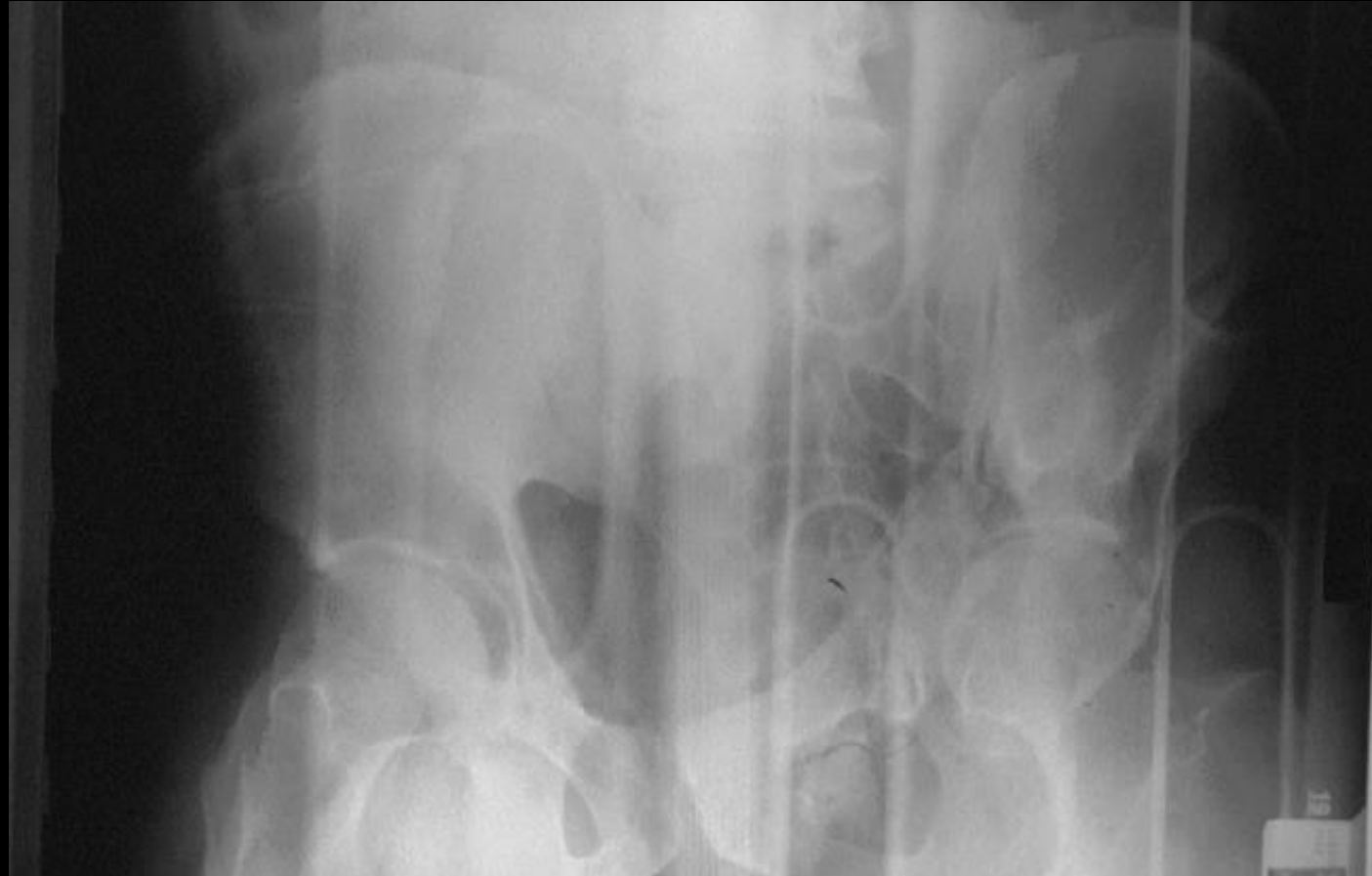The surgical approach is for reduction!

Predetermine when joint access is needed in surgery

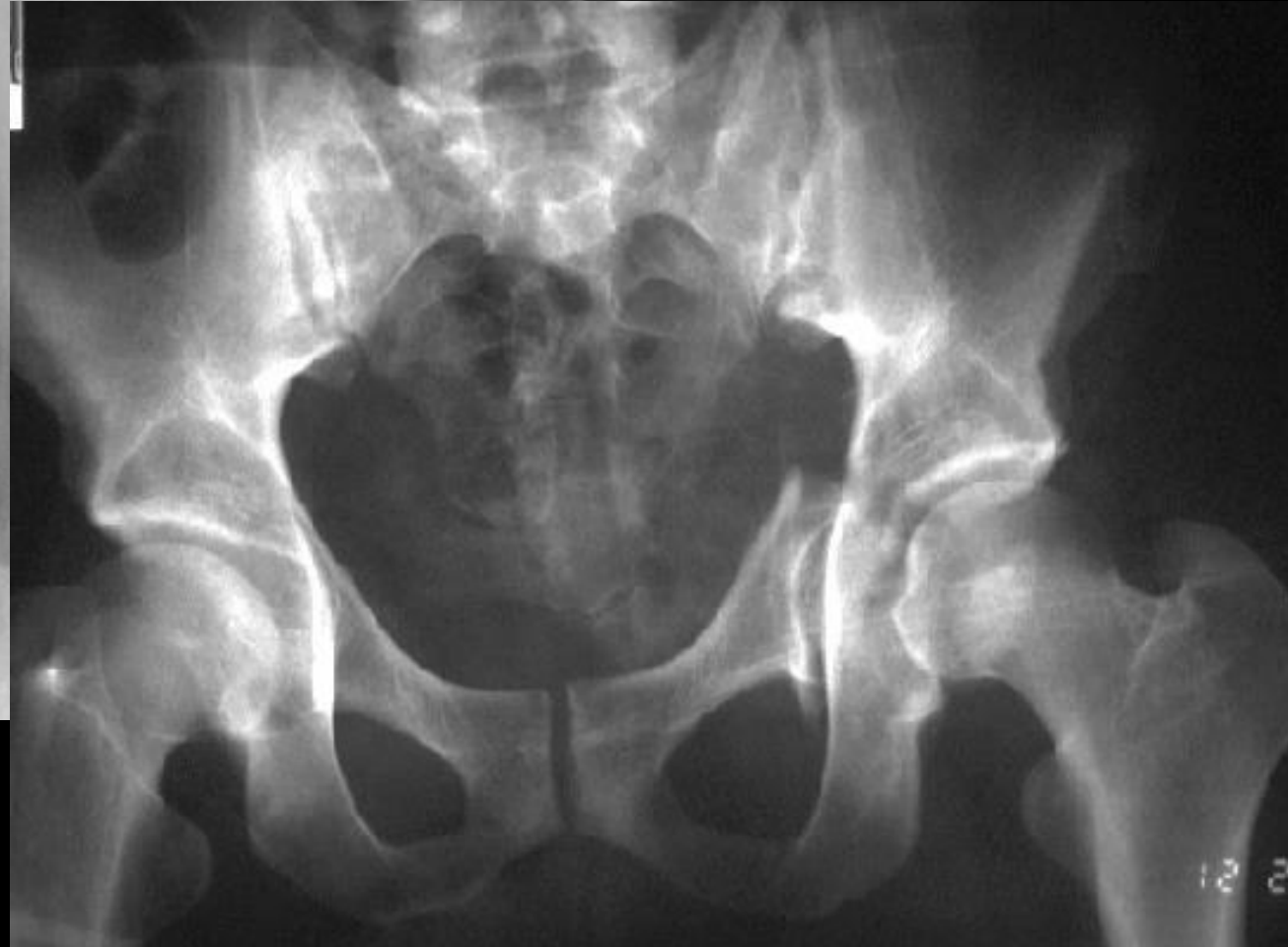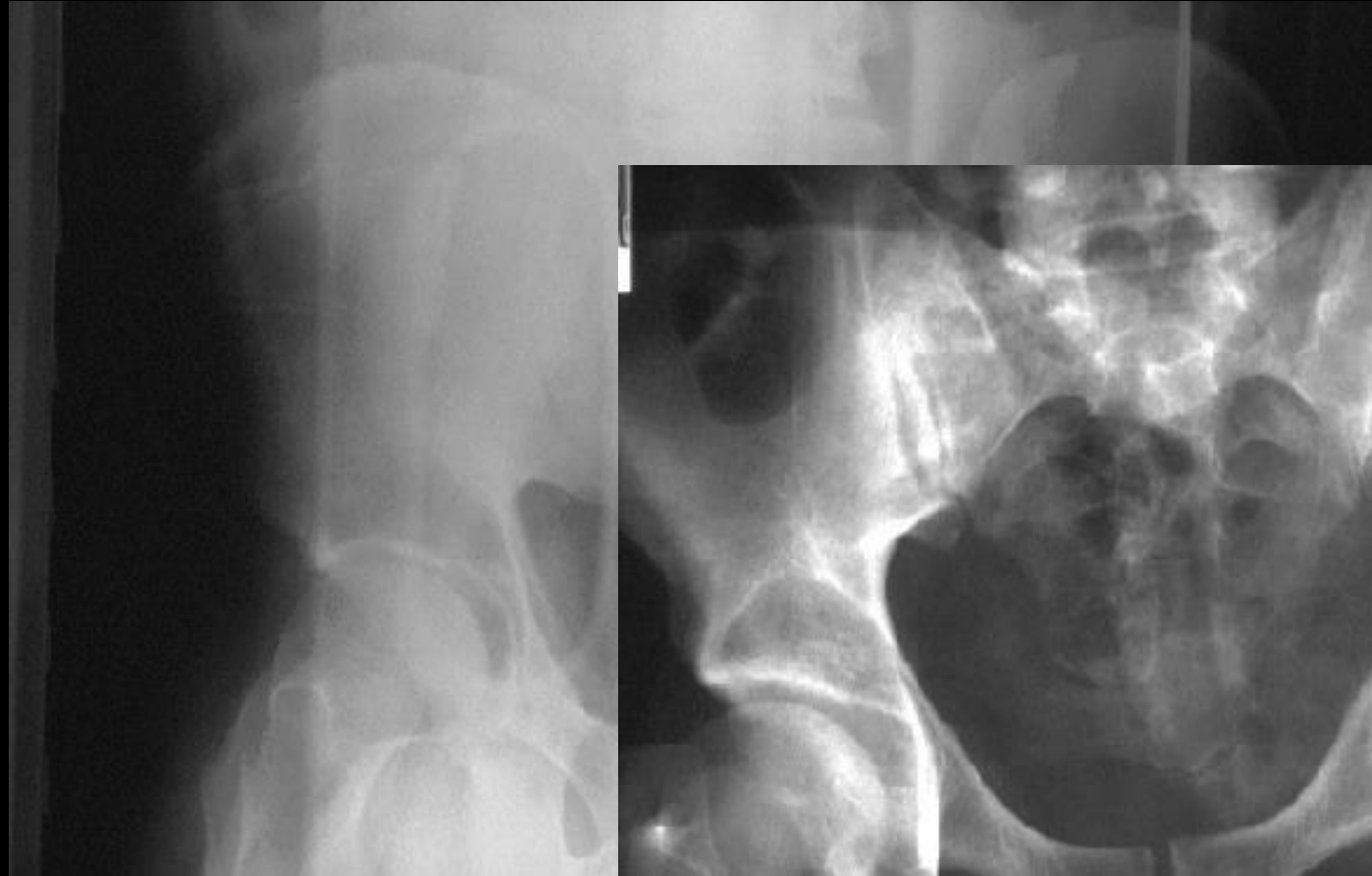Be willing to consider changing a poor reduction

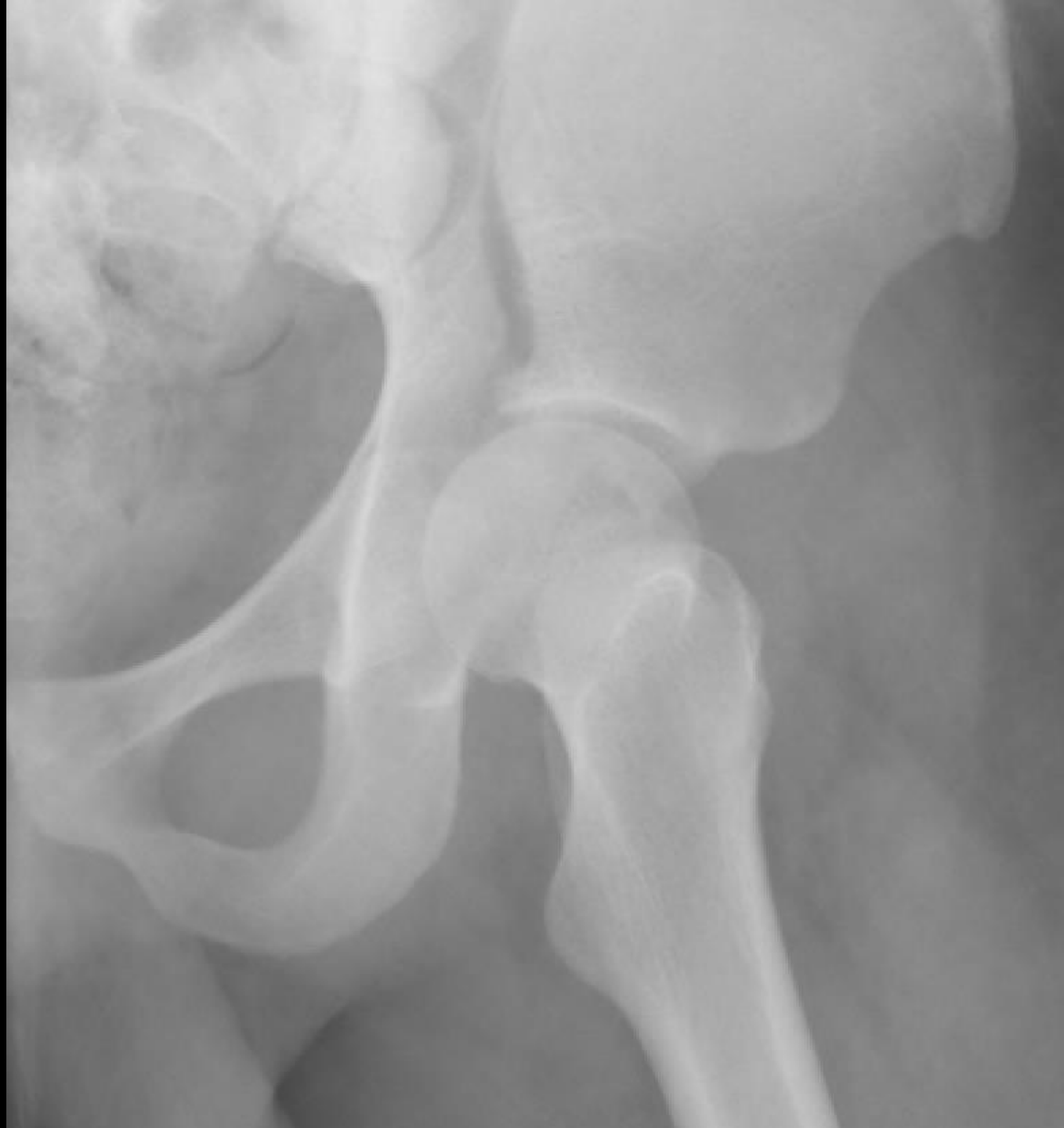Be Open to when ORIF is NOT the patient's best option

Get Good Quality Radiographs



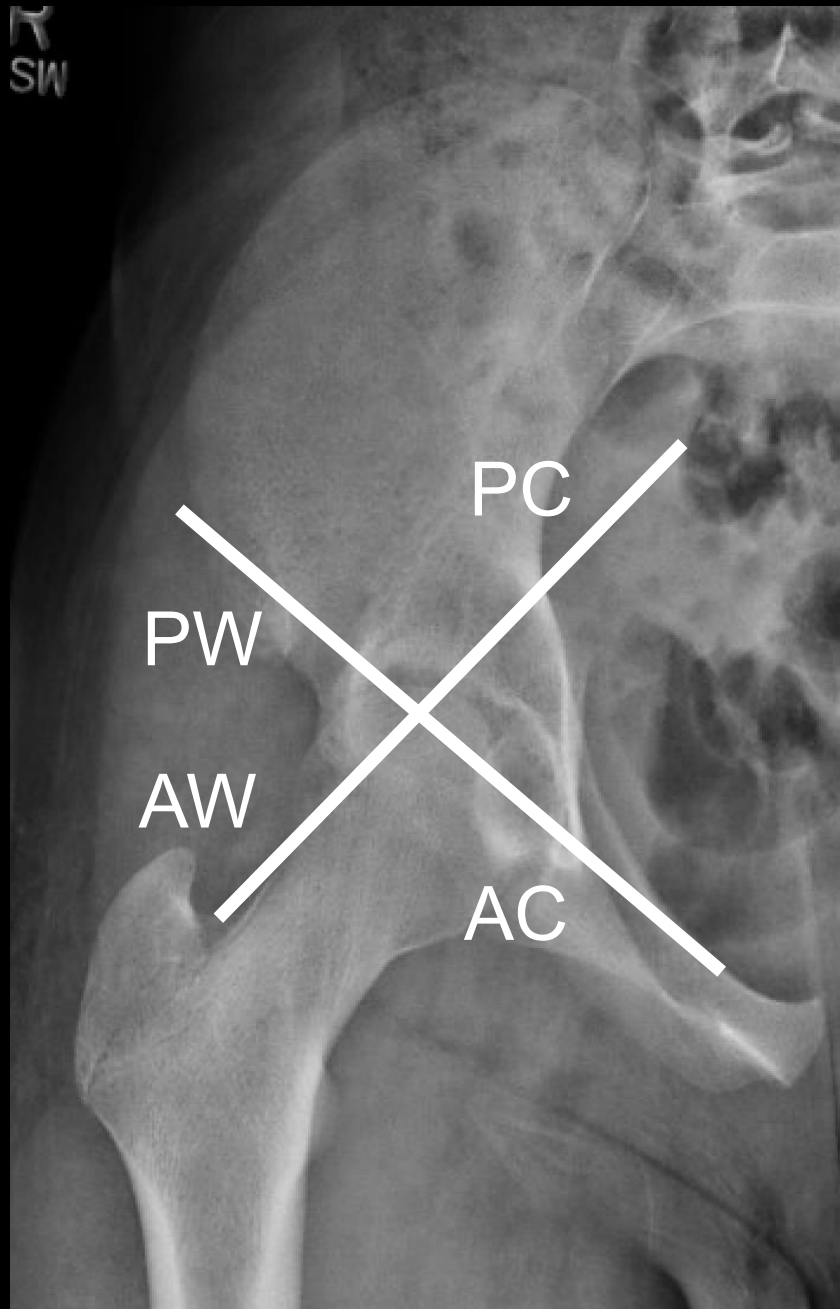


Get Good Quality Radiographs

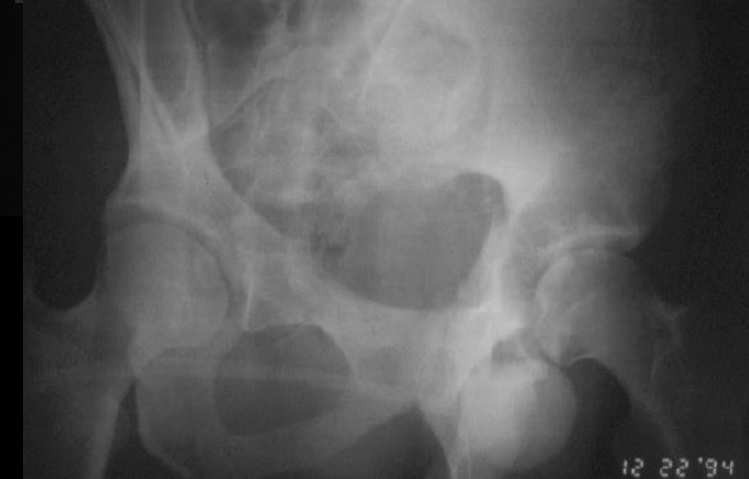
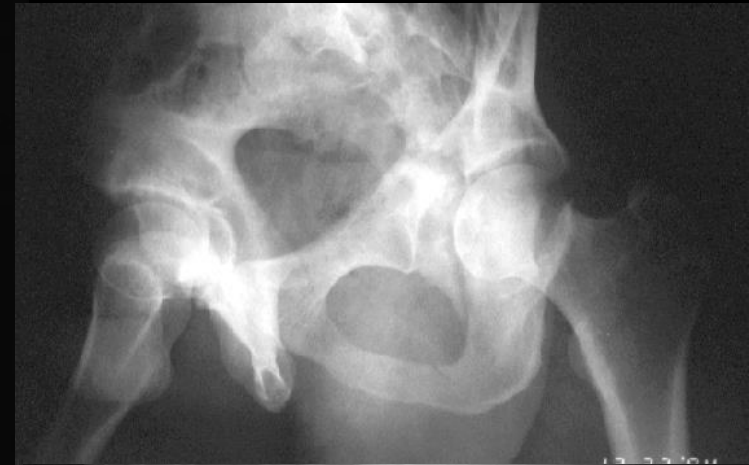
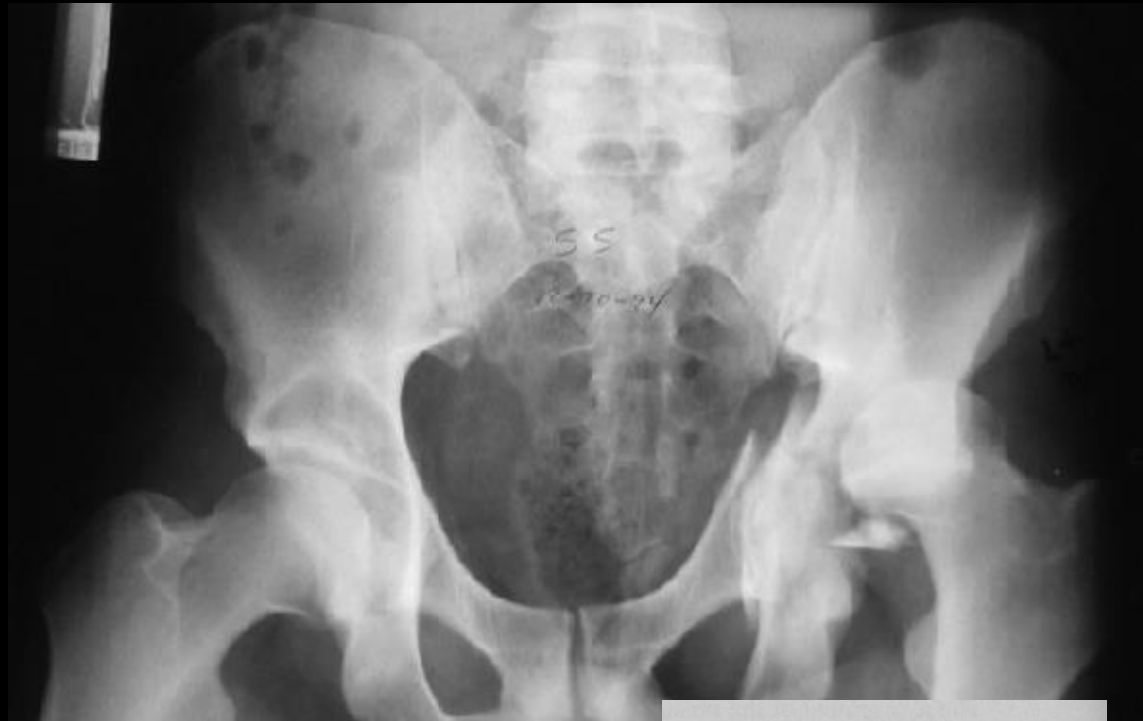

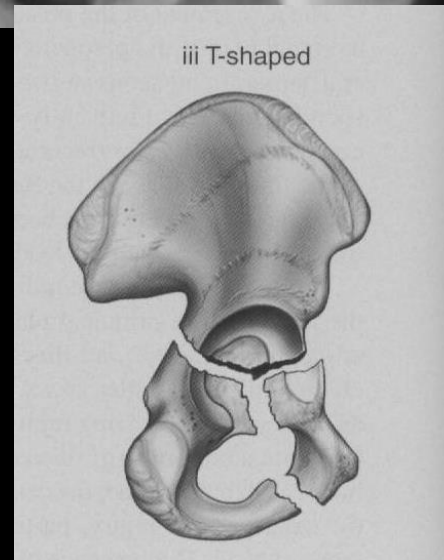
R
SW



Learn to Read Plain Films



Fracture
Classification

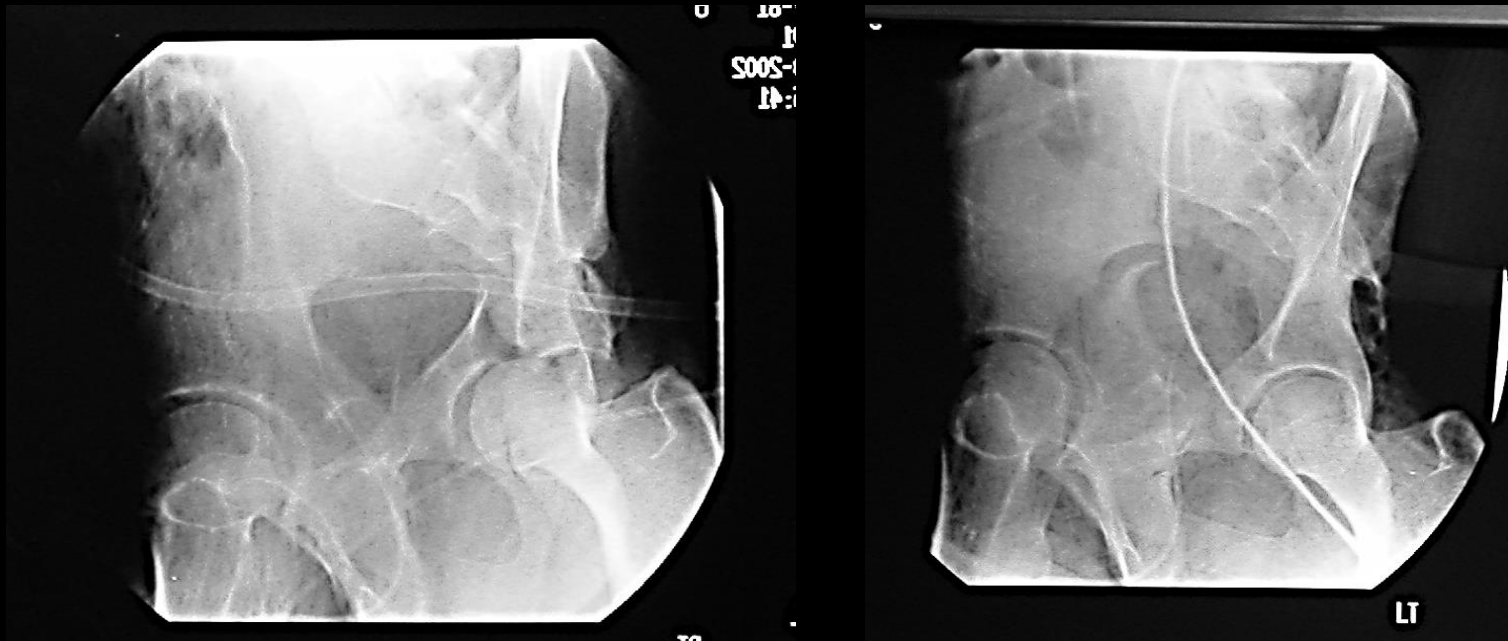

Learn to Read Plain Films

In the OR Intra-op CT or 3D CT not always available

Fluoroscopy is the primary option

Interpreting a fluoroscopy image is a vital skill



Look for a Reason NOT to Operate

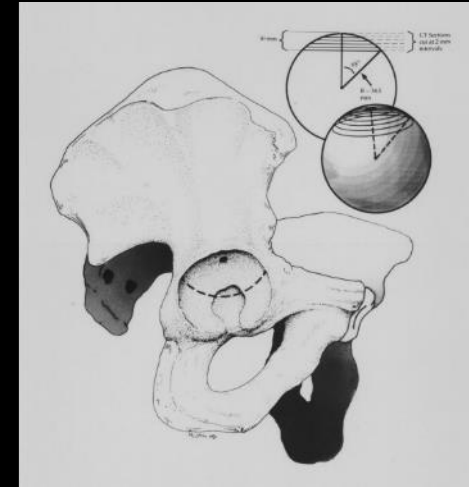
Criteria to be Met to Treat Non-Operatively:

- CT Arc intact through the superior 10mm of the acetabulum
- Femoral head remains congruent with the acetabulum on all three plain radiographic views taken out of traction
- No associated posterior instability of the hip

Olson & Matta JOT 1993

- No displacement / stable with EUA

Tornetta JBJS(Br) 1999



Look for a Reason NOT to Operate

Non-Operative Treatment



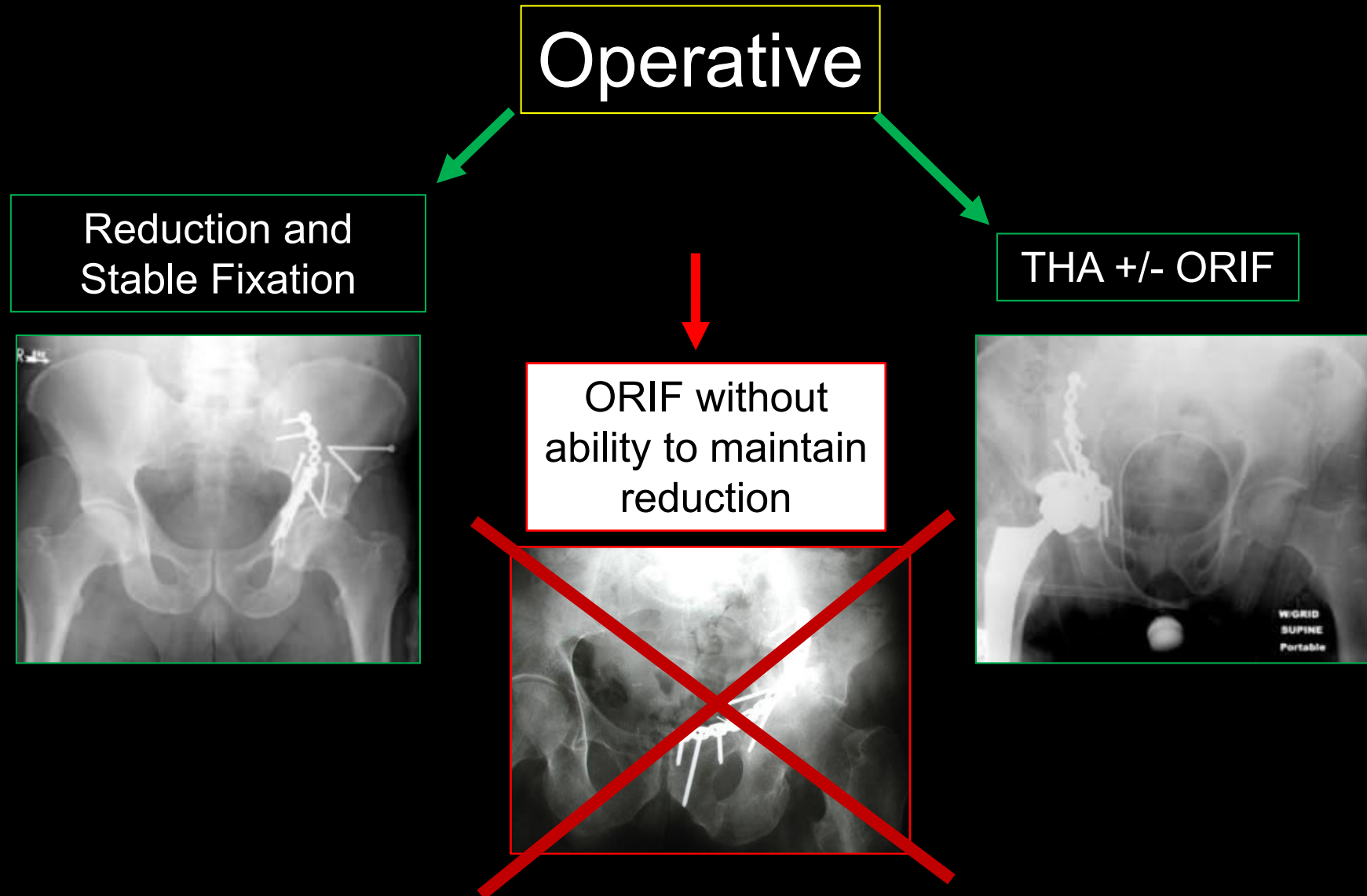
Non-Displaced Injury
Patient able to mobilize
comfortably

Potentially viable strategy

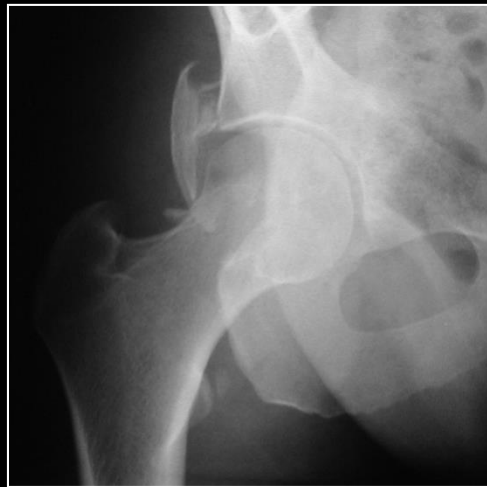
Unable to mobilize
Traction required to
reduce hip
Medically Unstable

High risk of M&M

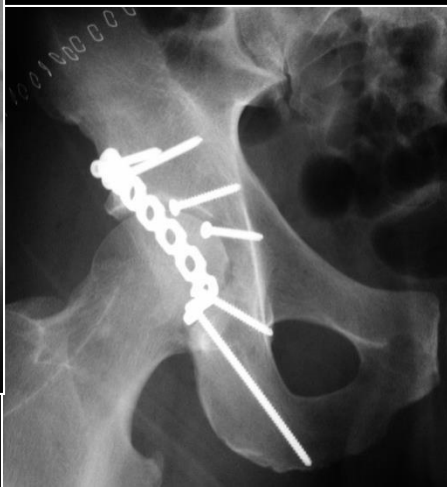
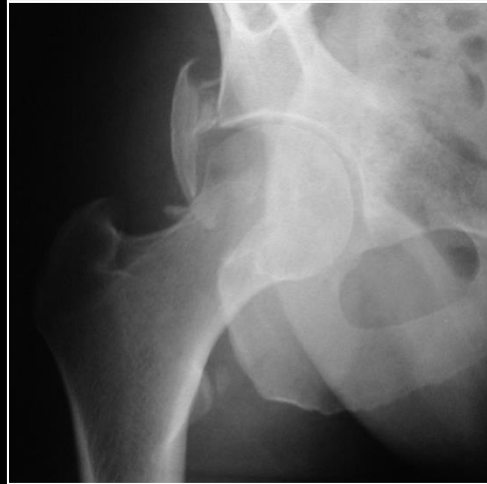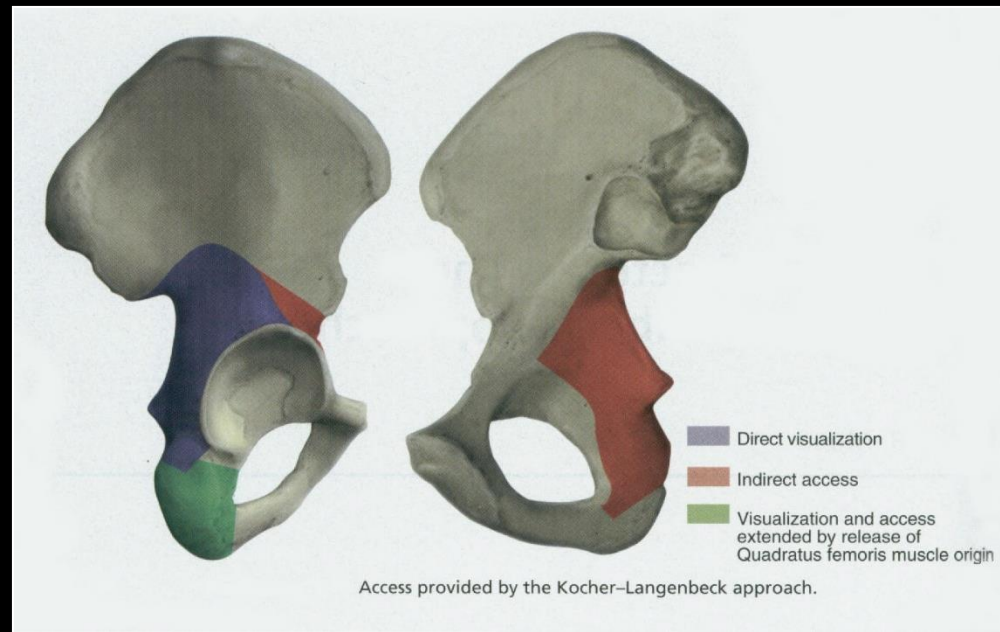
Look for a Reason NOT to Operate



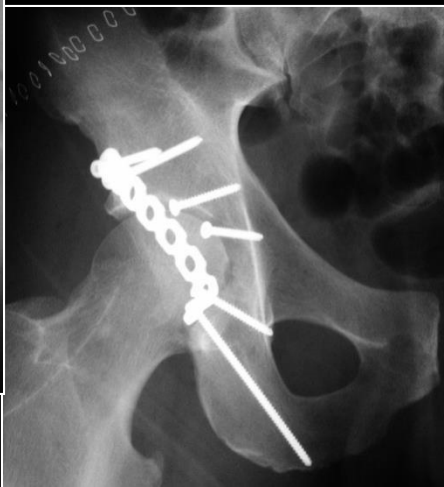
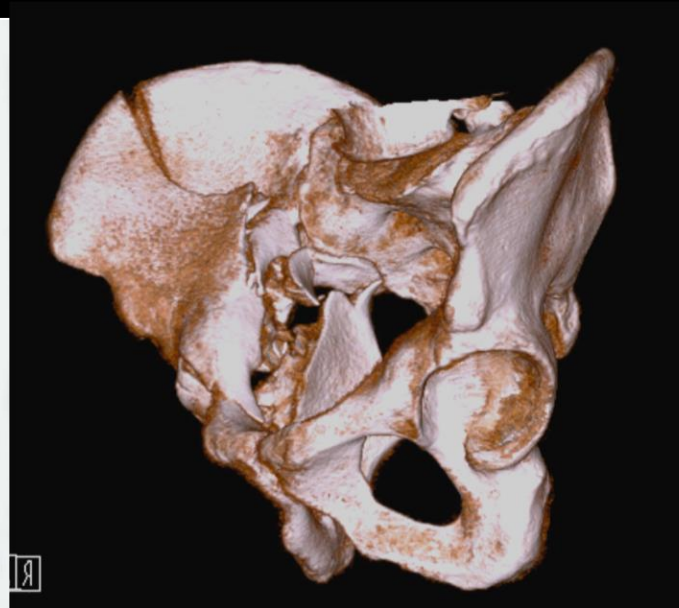
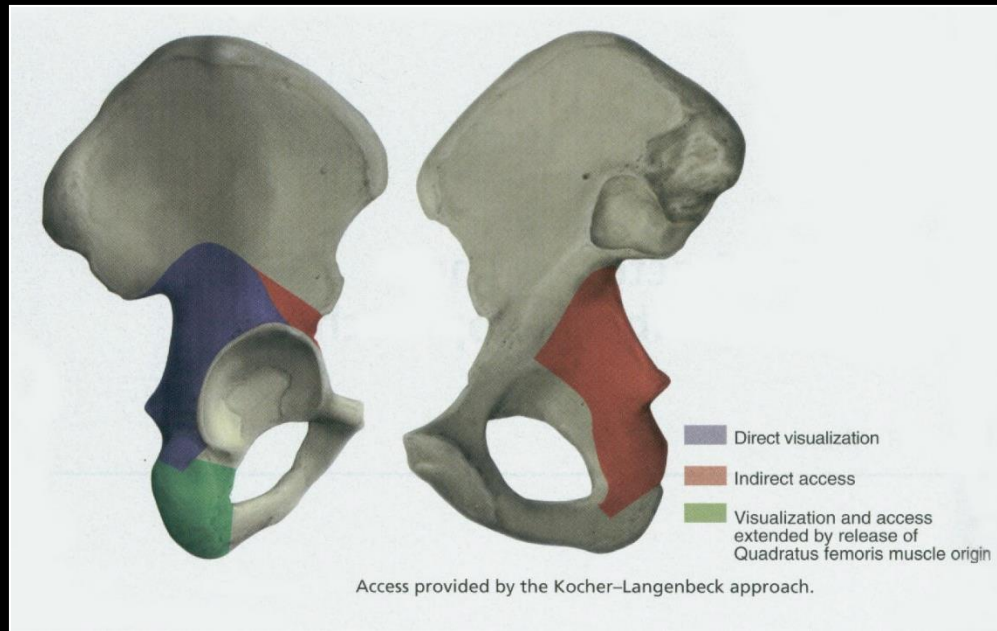
Surgical Approach is for Reduction – Fixation is 2nd-ary



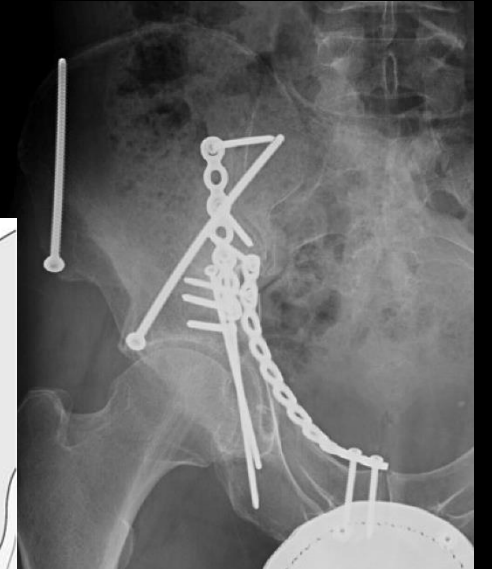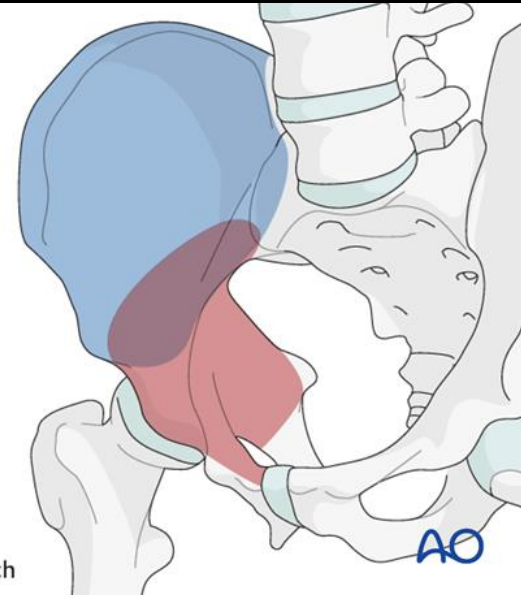
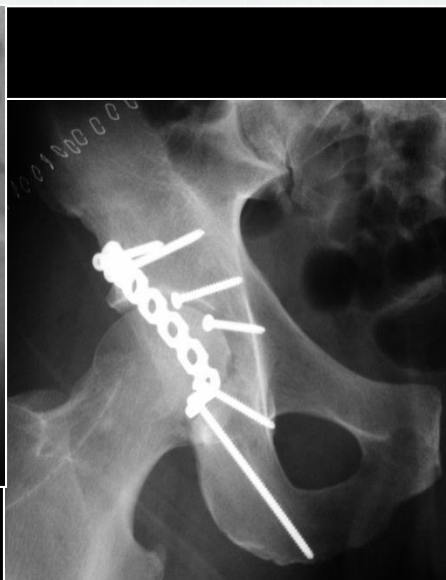
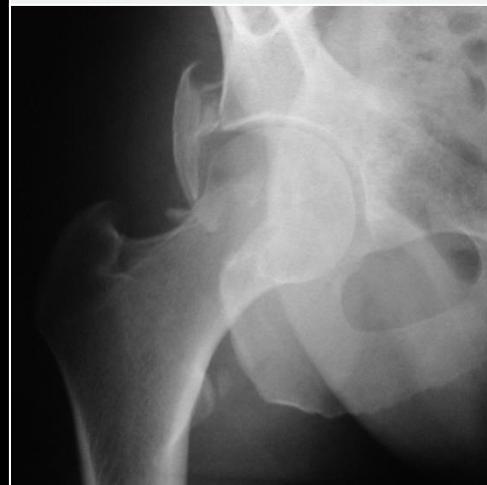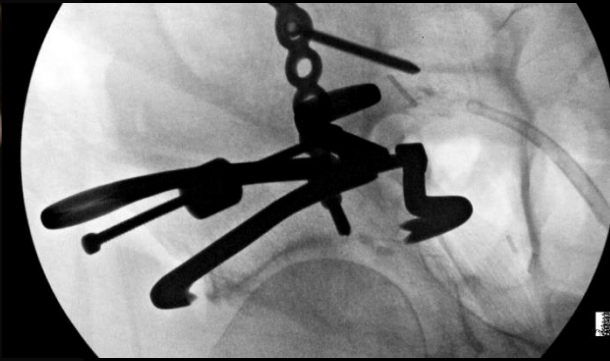
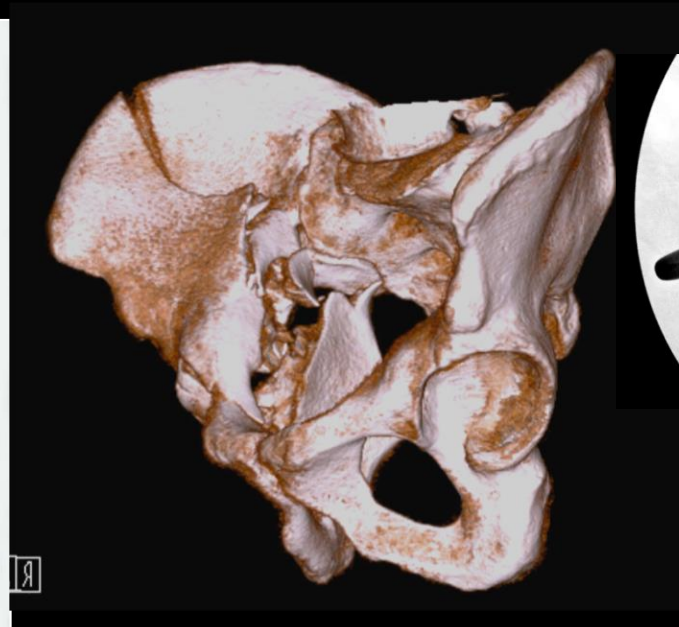
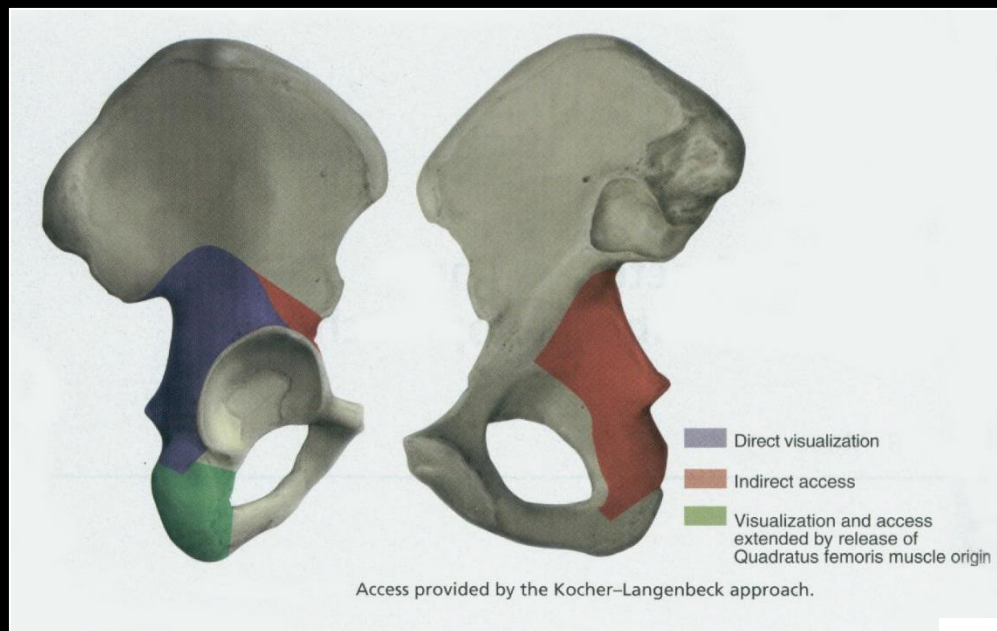
Surgical Approach is for Reduction – Fixation is 2nd-ary



Surgical Approach is for Reduction – Fixation is 2nd-ary



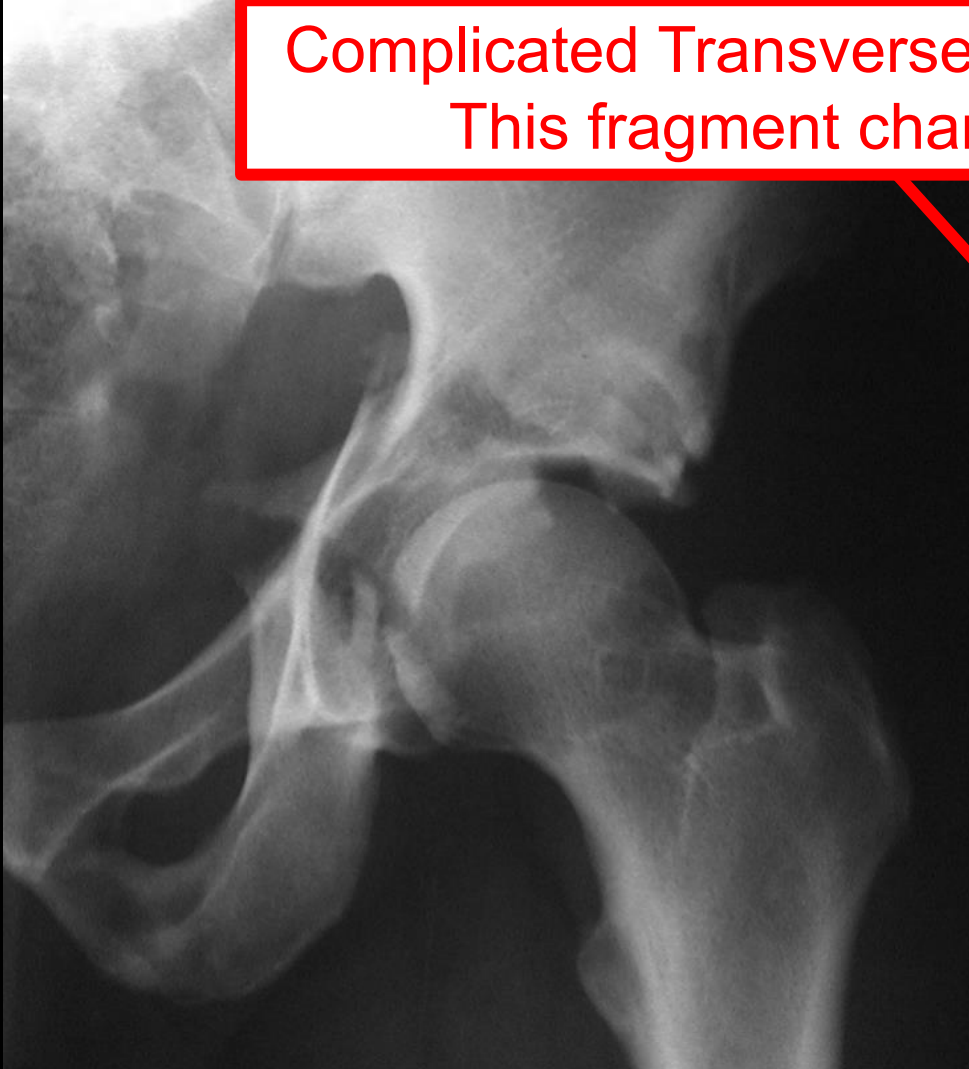
Surgical Approach is for Reduction – Fixation is 2nd-ary



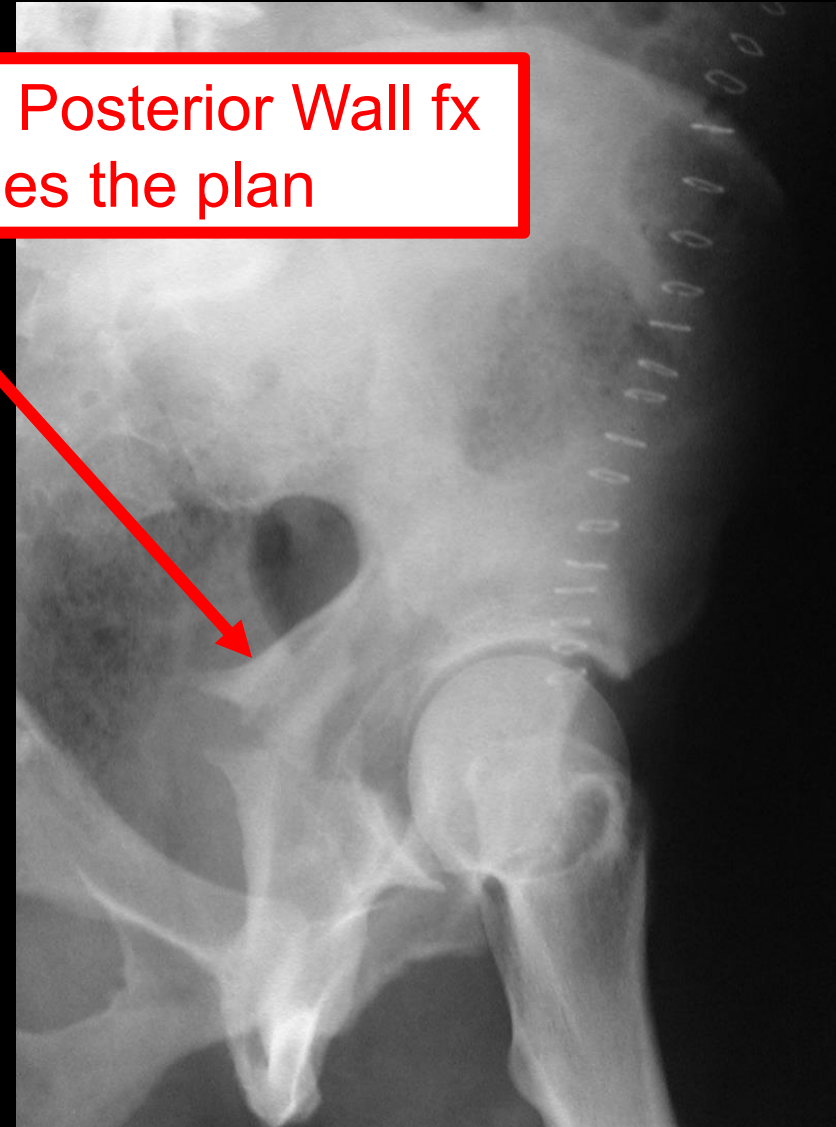
Legend:

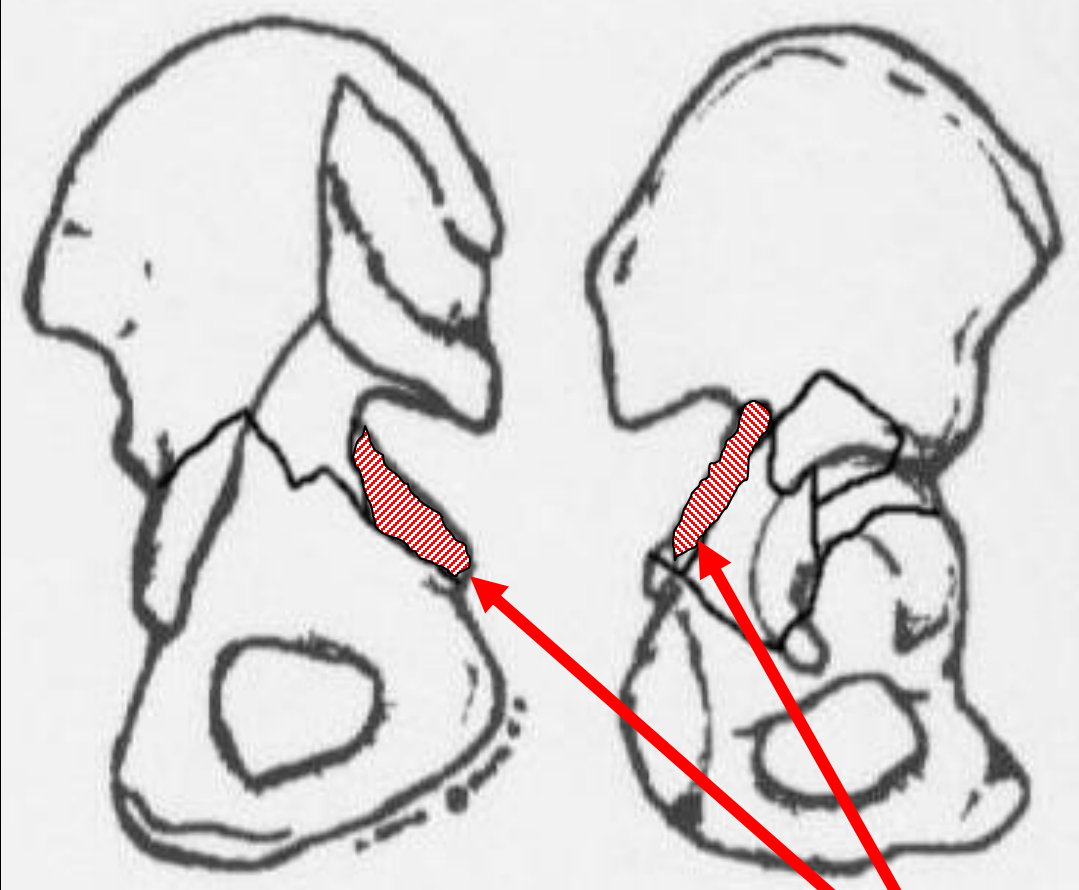
- Lateral window
- Intrapelvic approach

Predetermine when joint access is needed for fracture care



Complicated Transverse – Posterior Wall fx
This fragment changes the plan



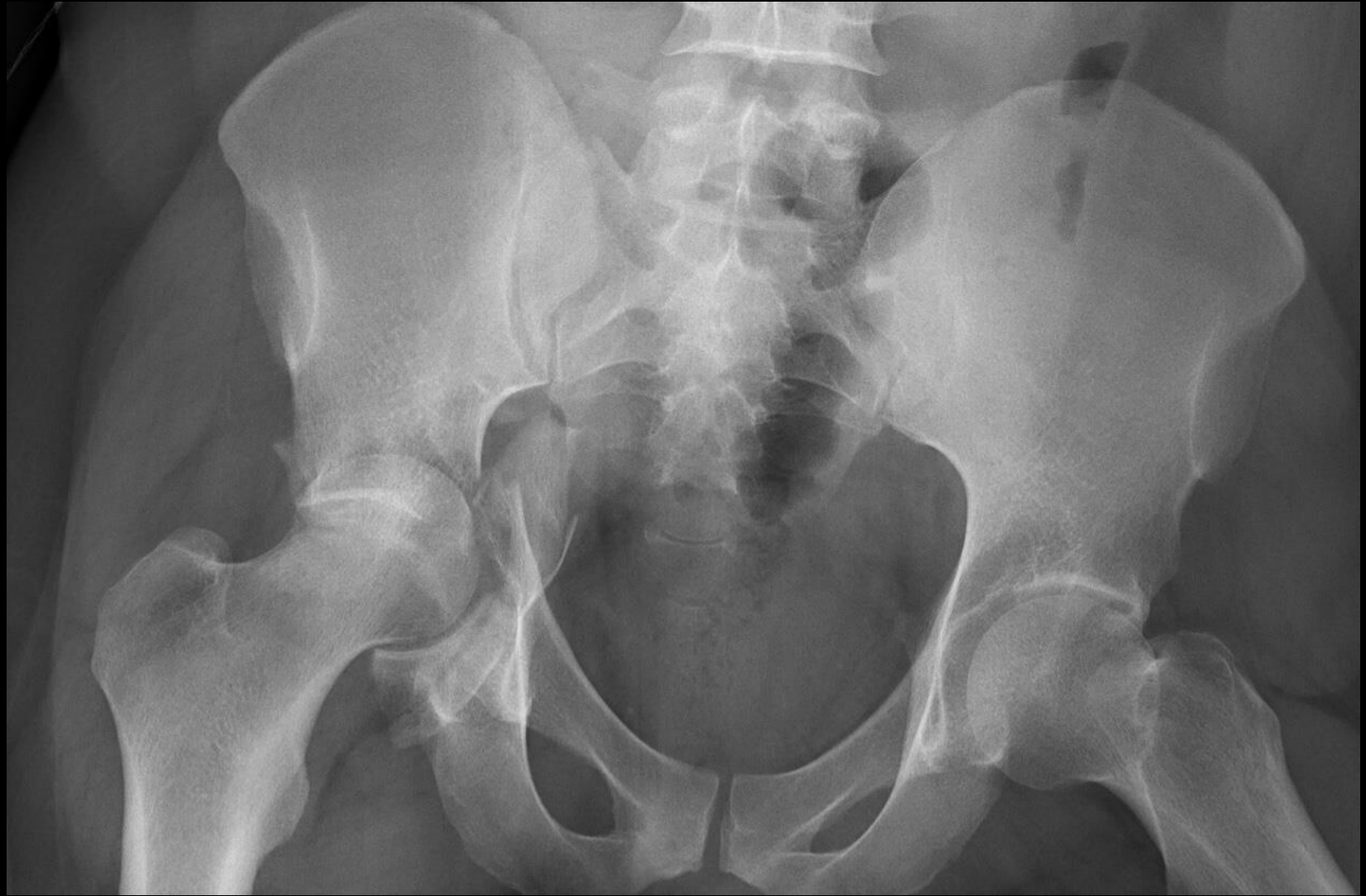


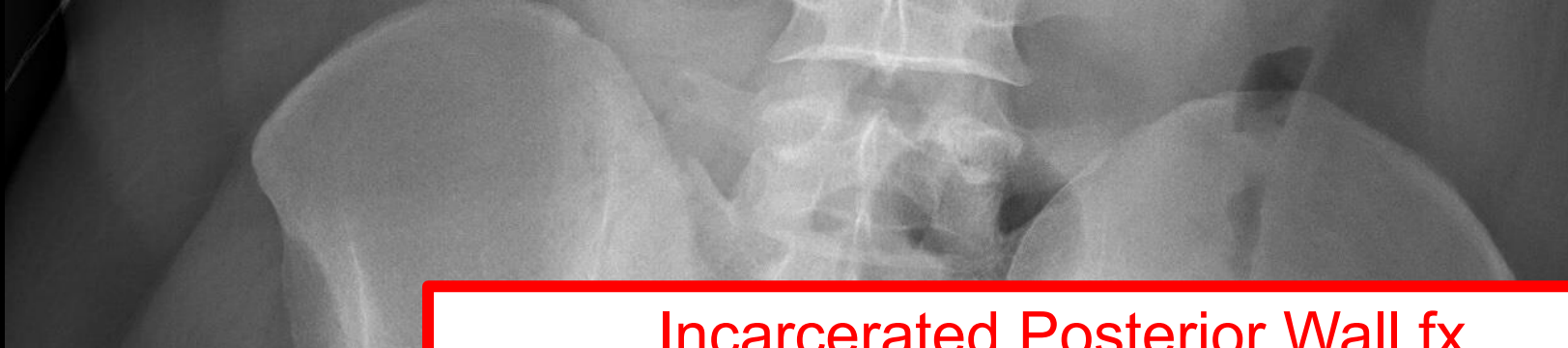Approach Choice

Kocher-Langenbeck
with Trochanteric Flip

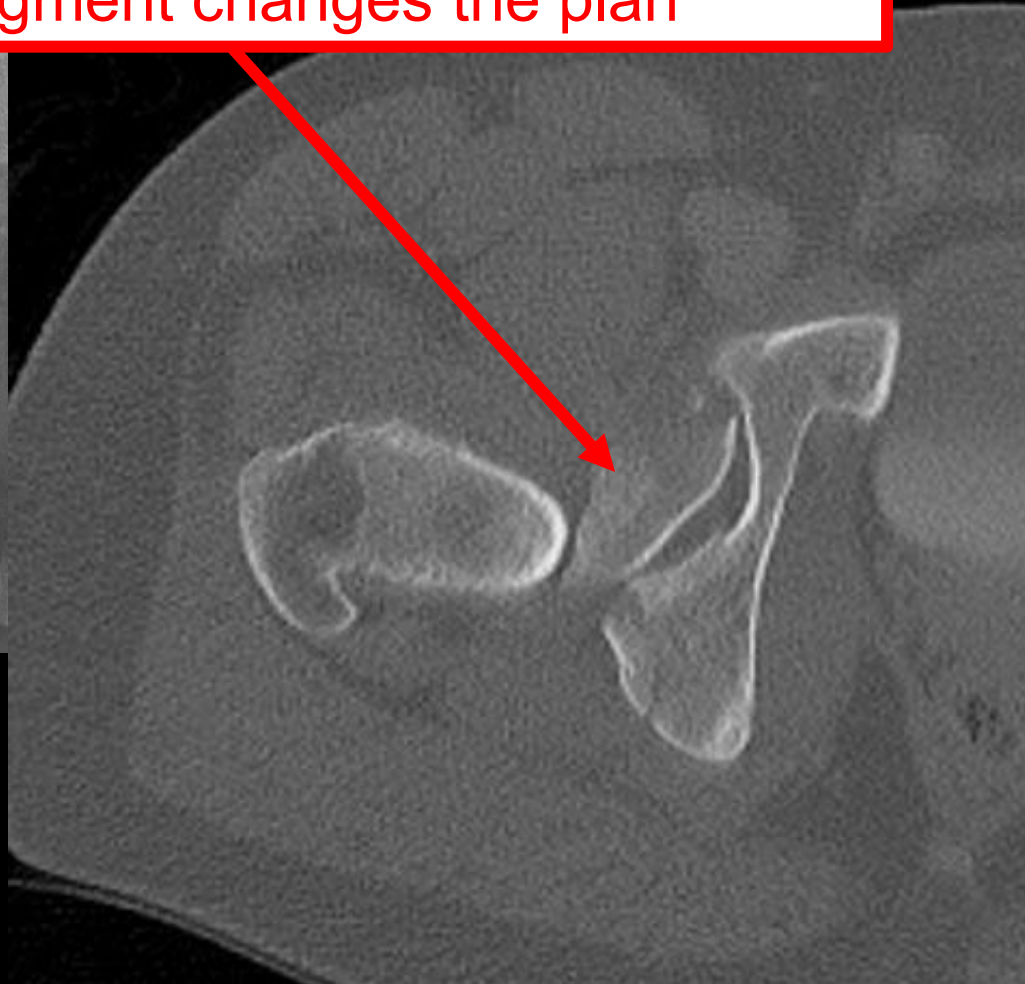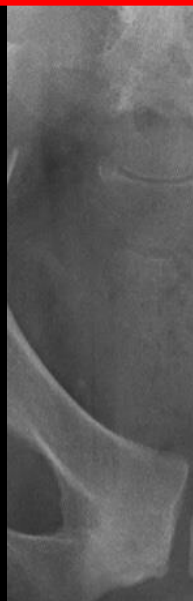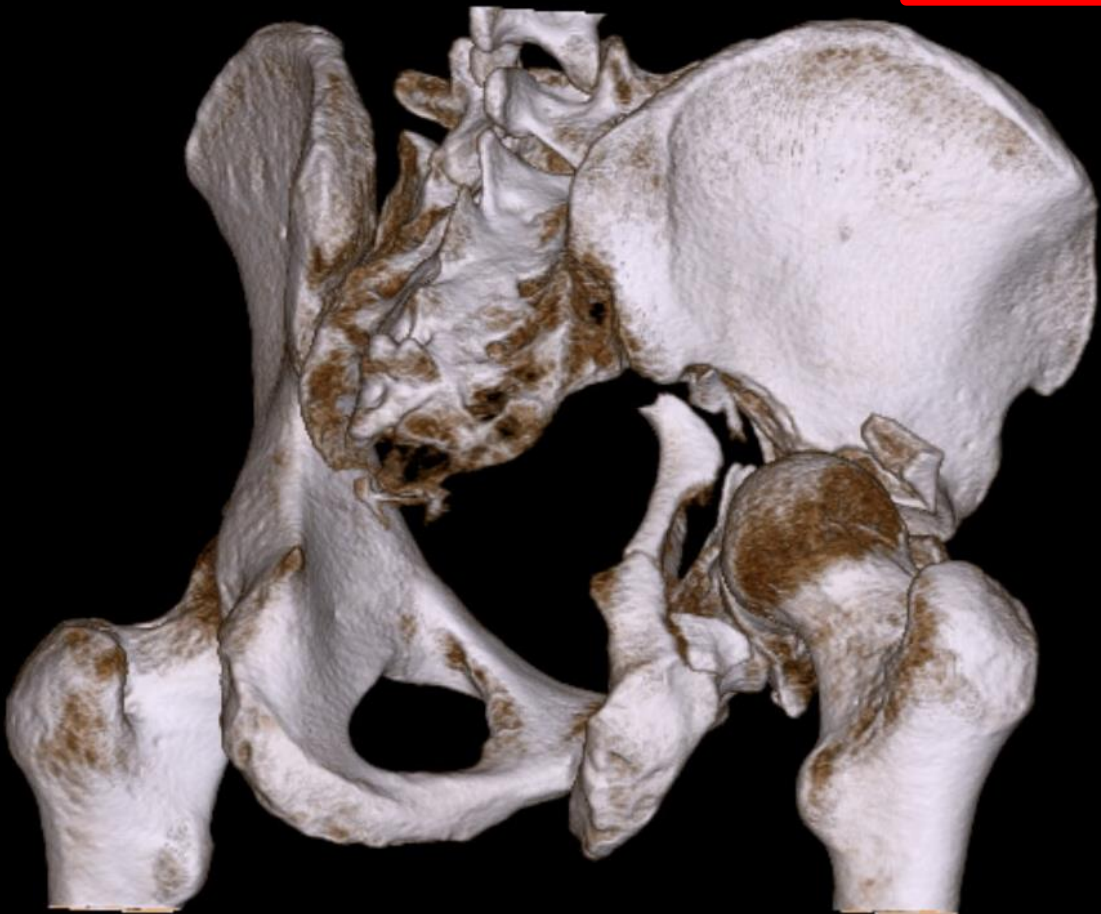Sublux femoral head
to assess reduction

Transverse + PW pattern with separate fragment of the greater sciatic notch
Visualization of the joint is necessary for reduction assessment





Incarcerated Posterior Wall fx
This fragment changes the plan

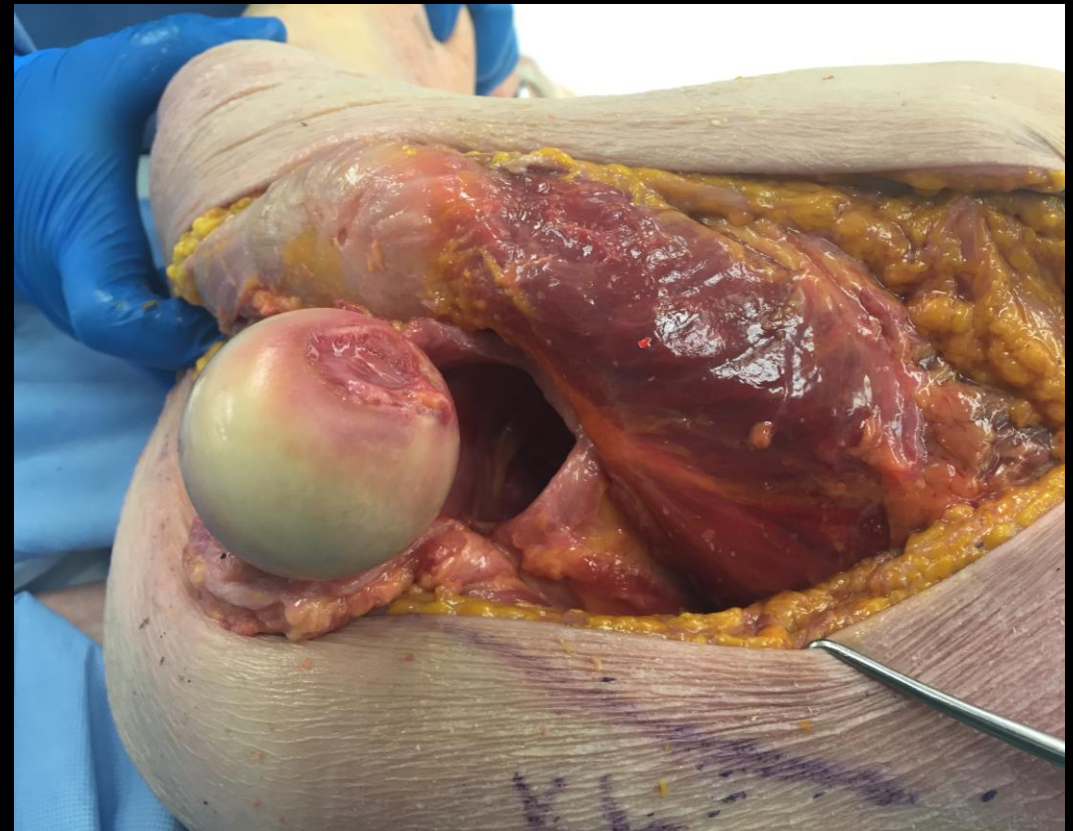


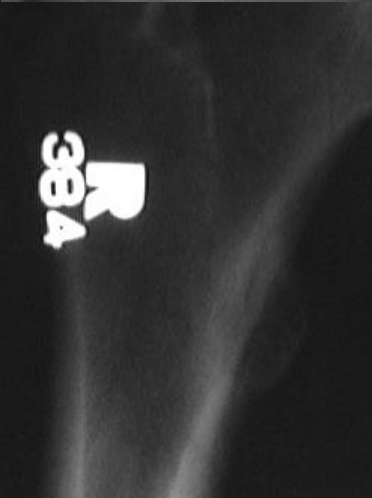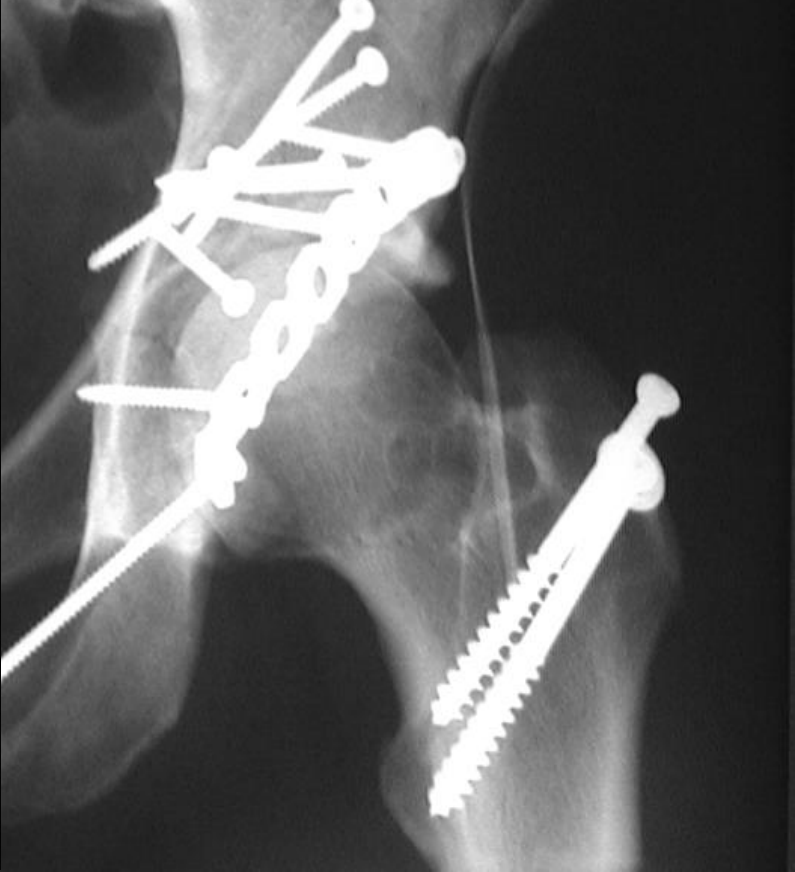
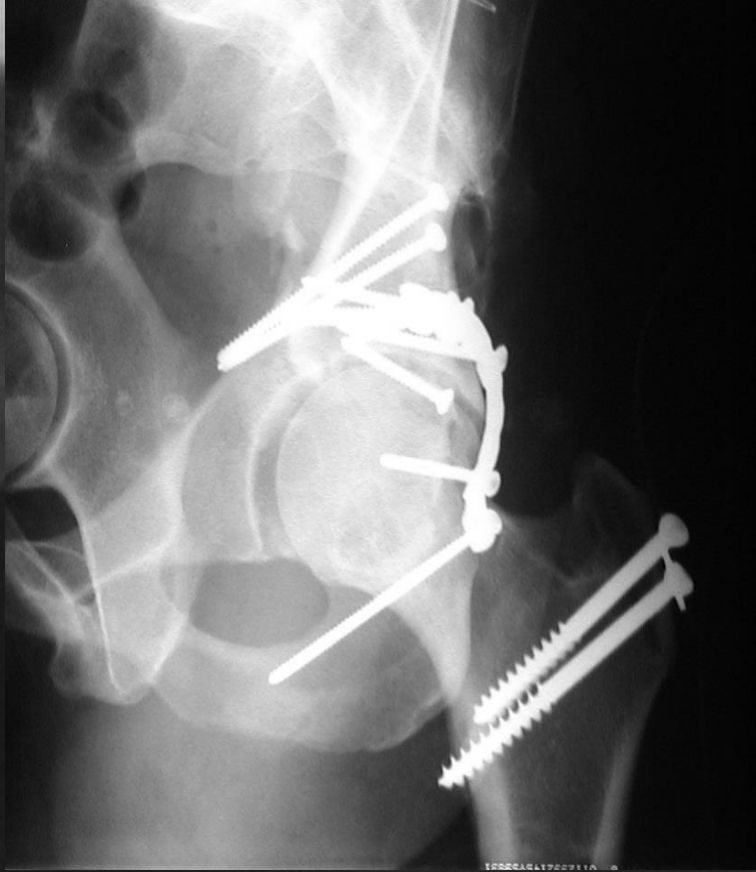
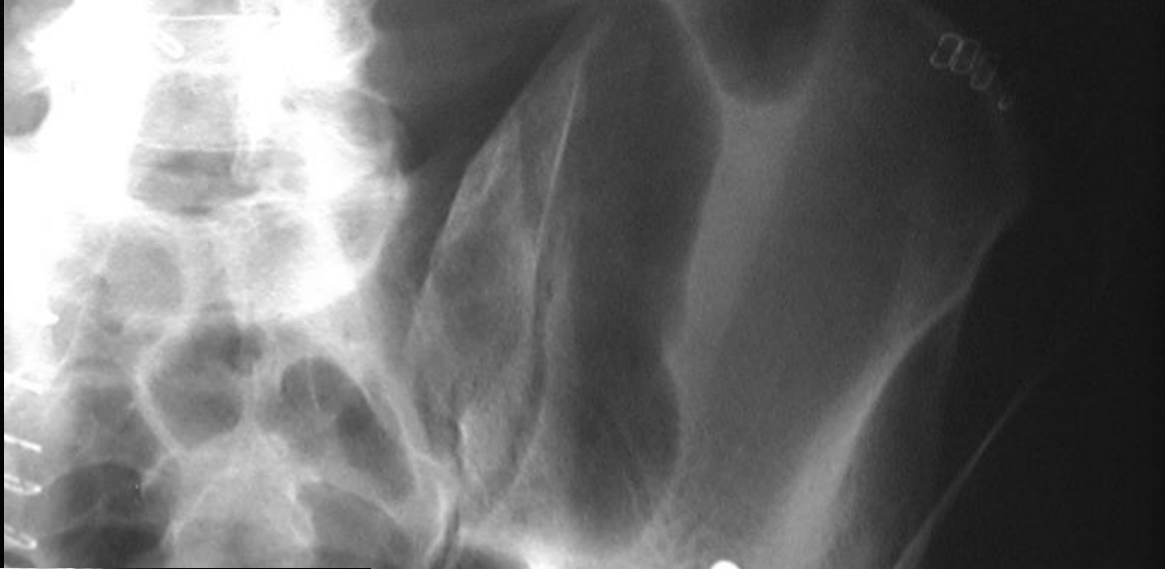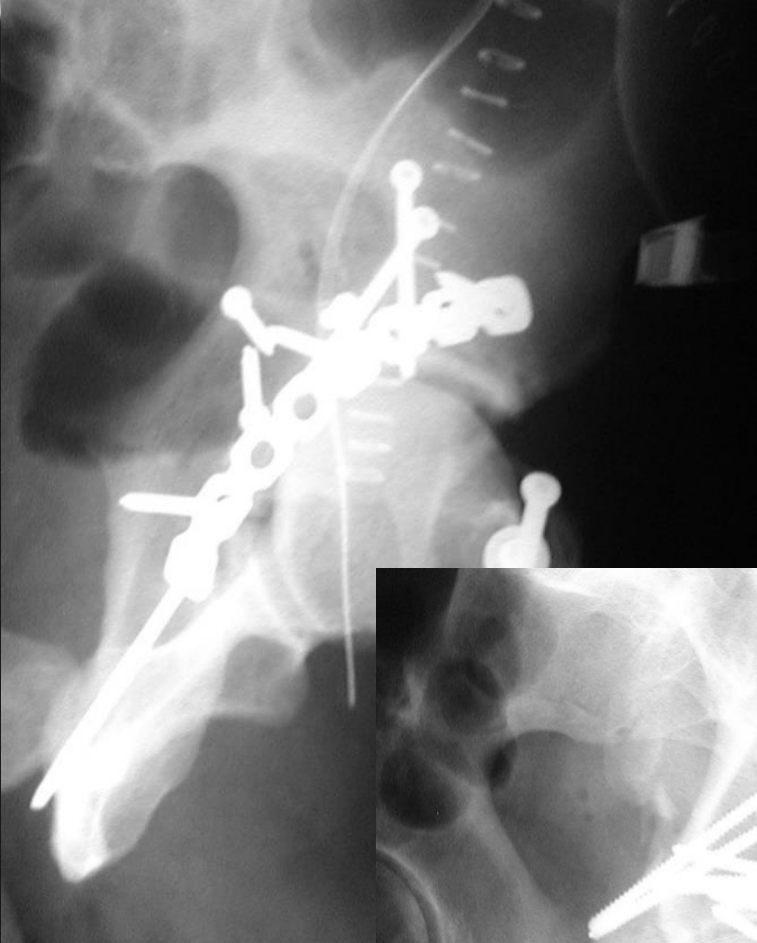
Digastric Osteotomy with Surgical Dislocation

Access to both columns of the acetabulum

Certain Transverse + PW, T-shaped, ABC

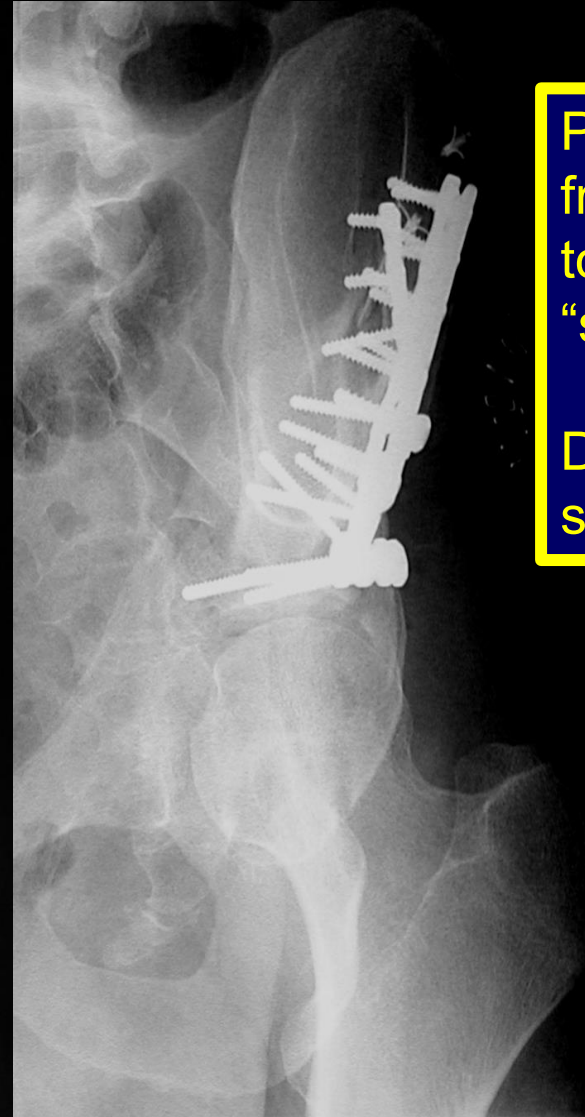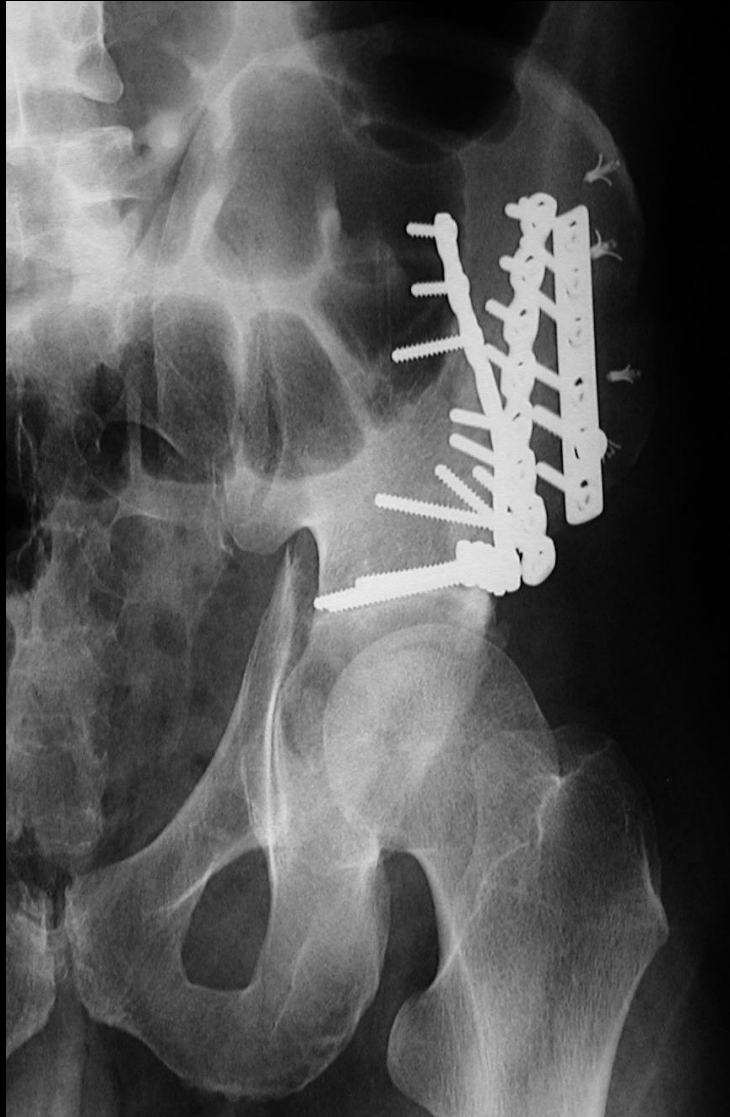
Direct visualization of the articular surface





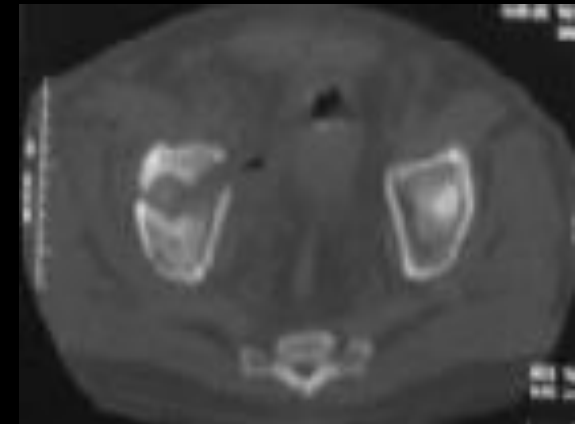
384

Be Willing to Consider Changing a Poor Reduction



Patient transferred
from OSH – Surgeon
told him the
“surgery went well”

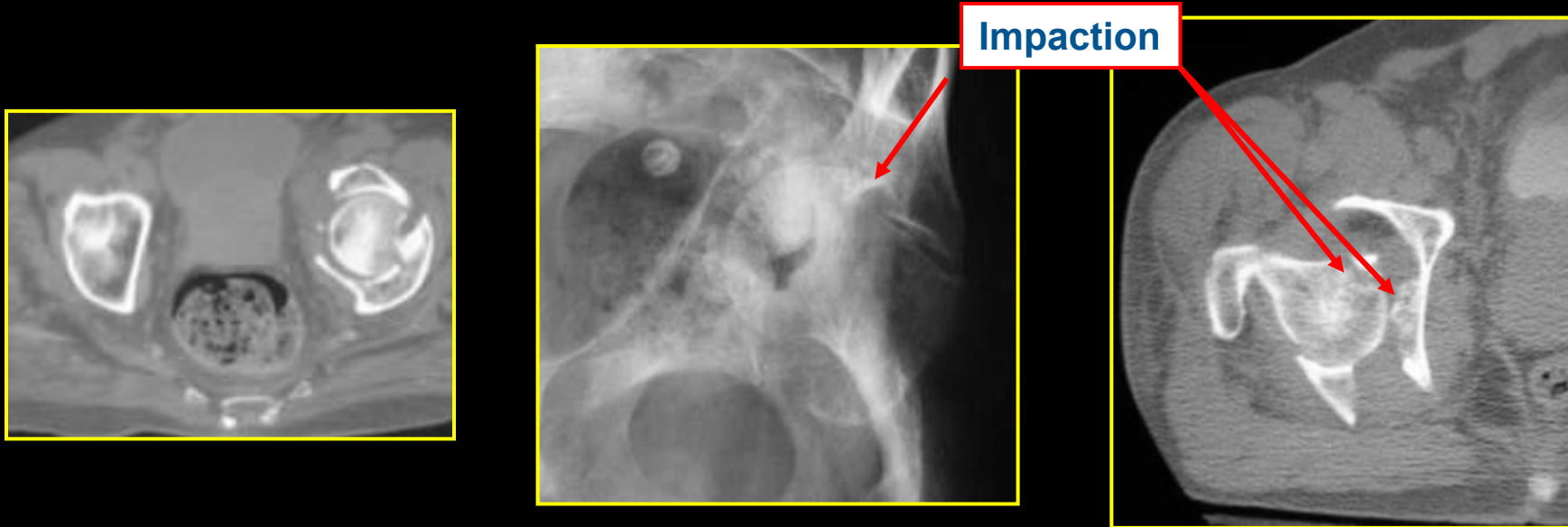
Difficult conversation,
sharing imaging helps



Be Open to When ORIF is NOT the best option for the Patient

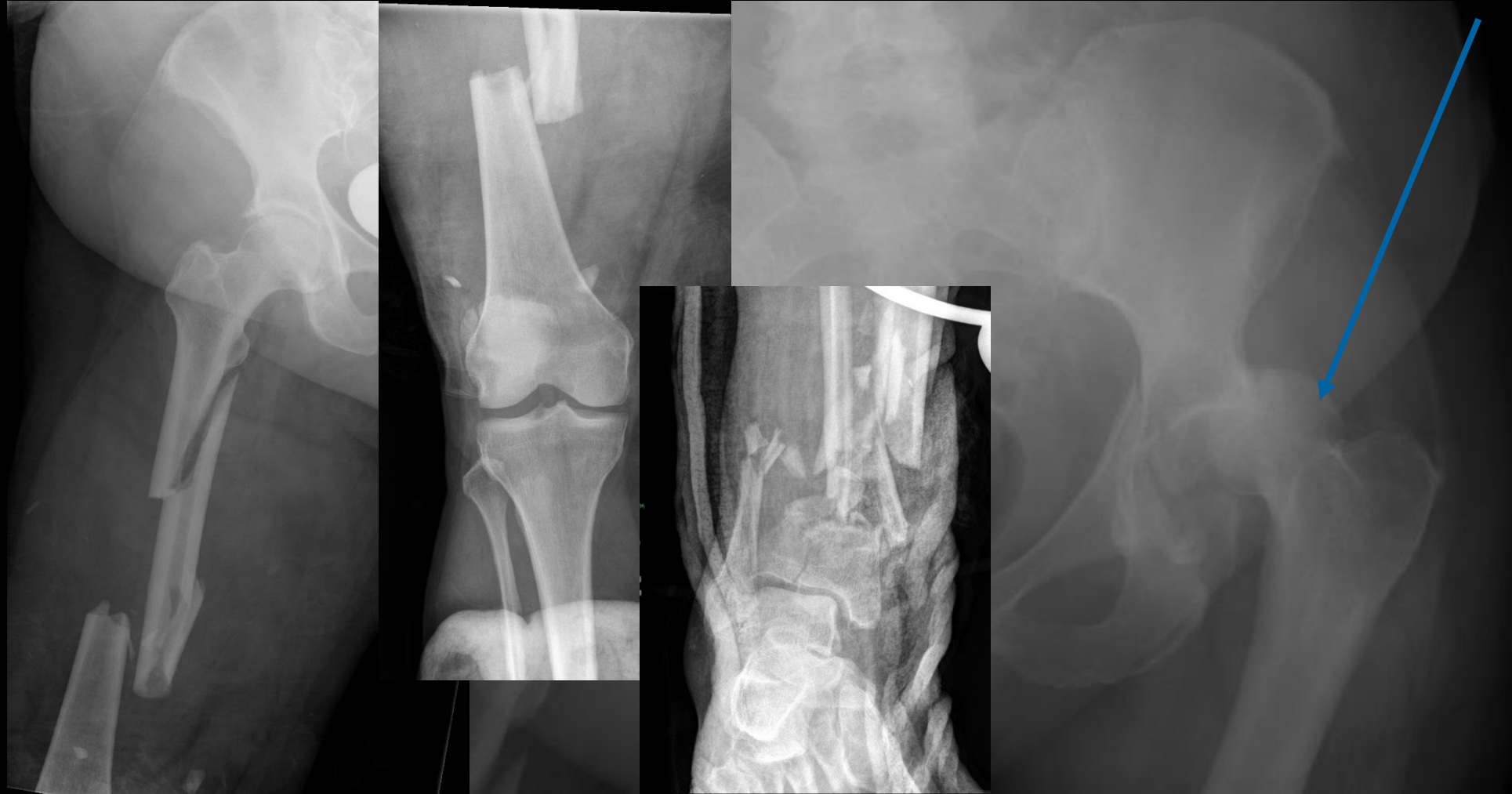Indications for acute THA for acetabular fracture

1. Posterior wall morphology
2. Impaction injuries to the femoral head or acetabulum
3. Consider fitness and frailty of patient



A 65 yo female – MVC – Left hip fracture
dislocation and right leg injuries

The left leg is now her “good leg”

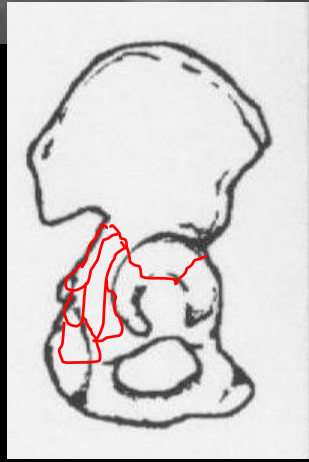
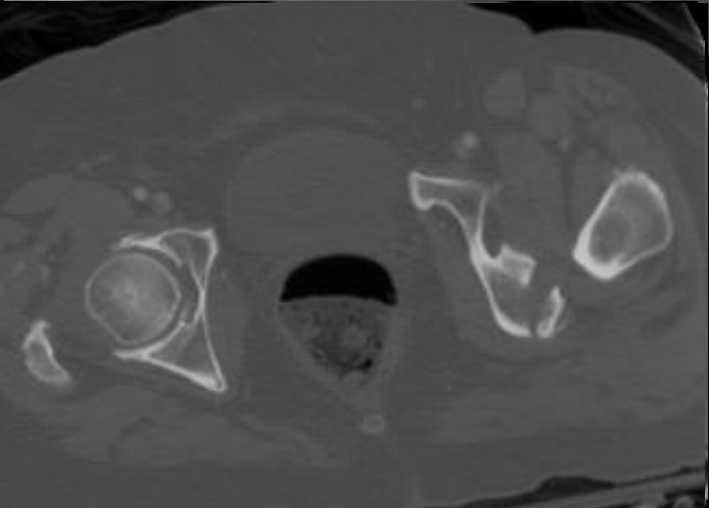
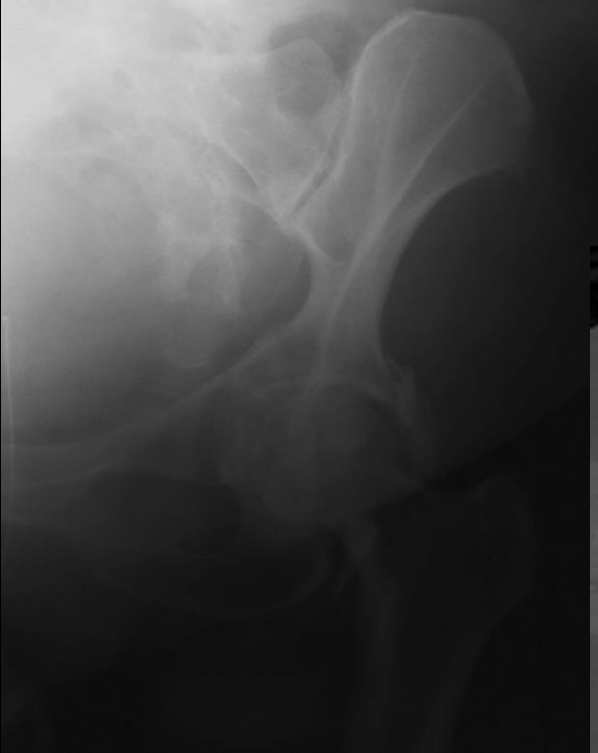
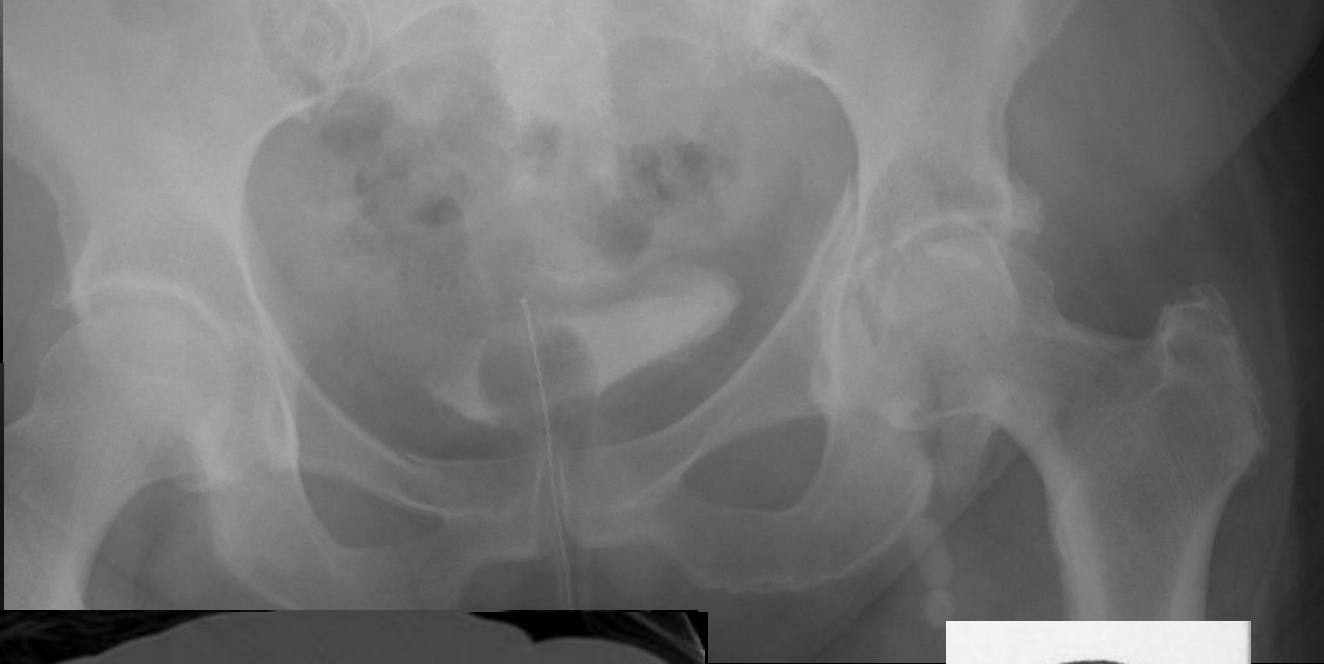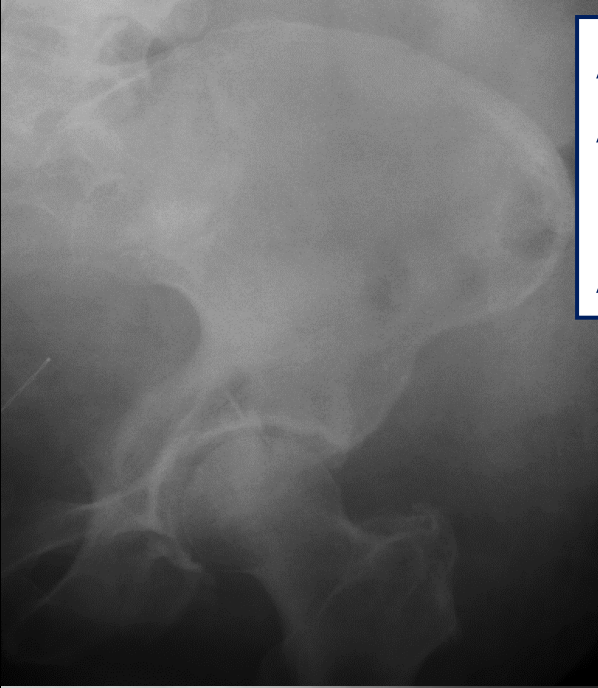


A Transverse with posterior wall pattern

A very comminuted posterior wall

Mild pre-existing OA

A relative indication for Acute ORIF and Primary THR



Kocher Langenbeck Approach

Femoral neck cut

Femoral head used as template for
posterior wall

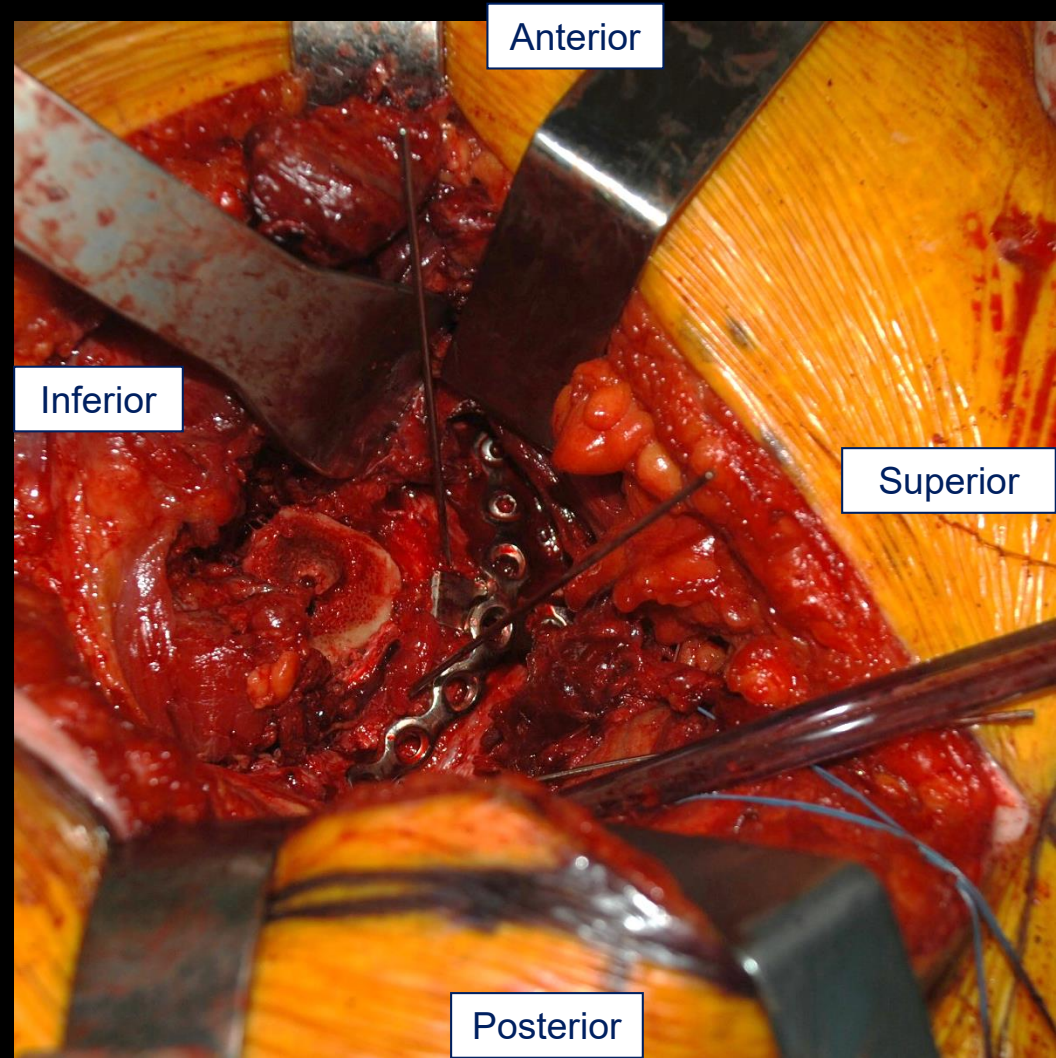
Fixation of Transverse fx

K-wire cage for wall fx

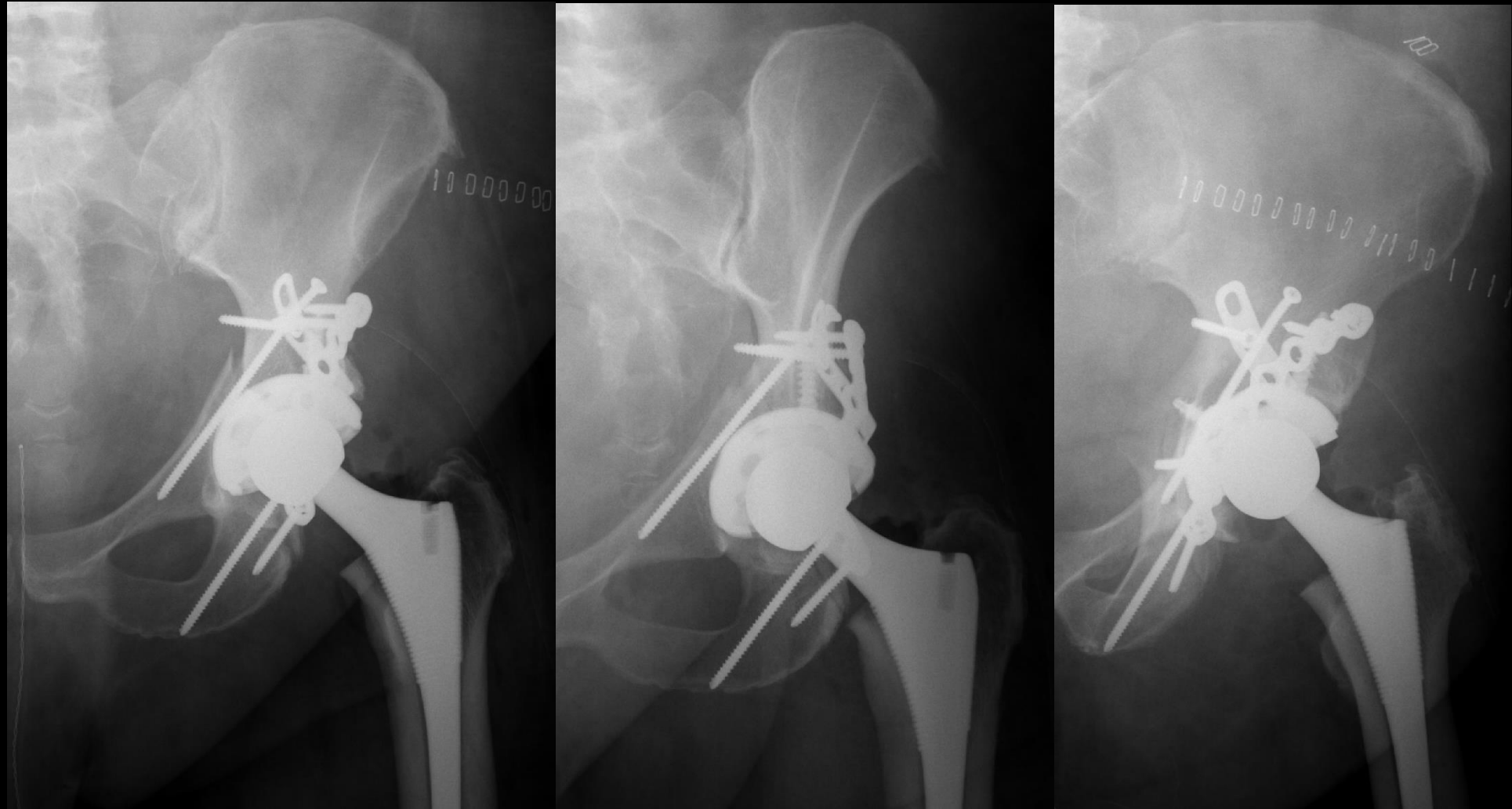
Substitute fixation for
k-wires

Place Acetabulum cup

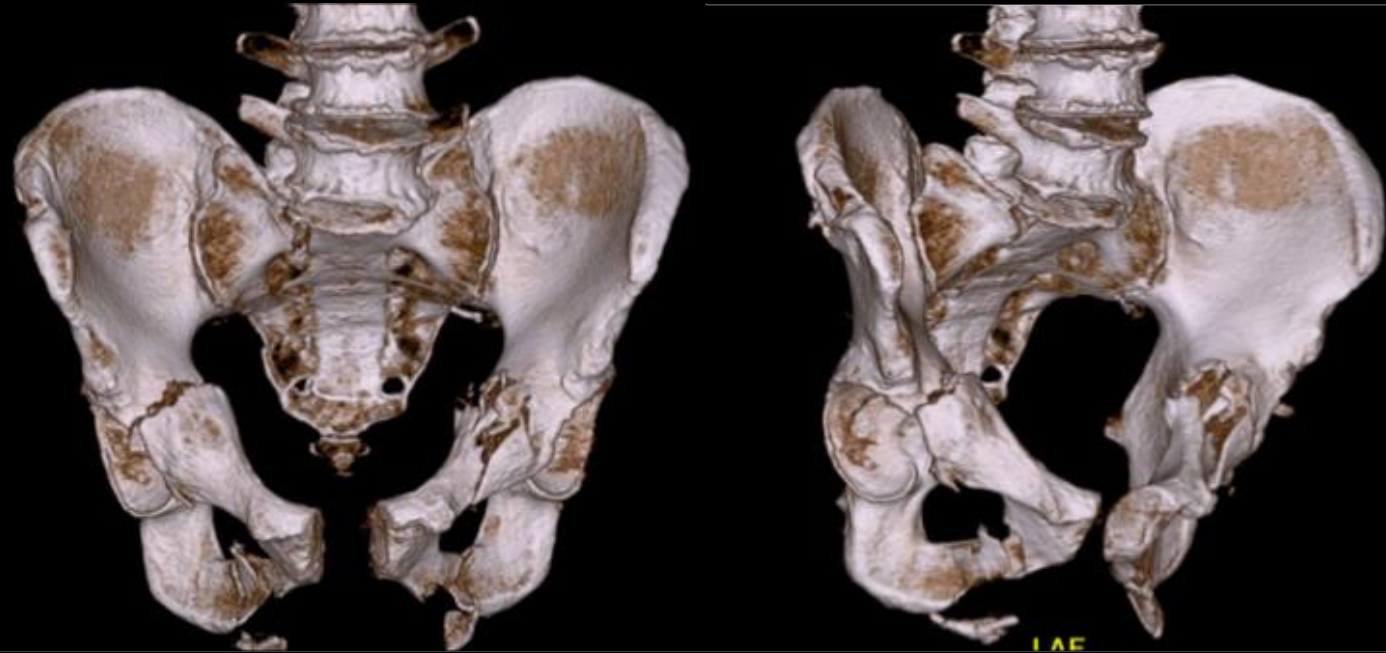Femoral stem



Post-Op Images



Percutaneous fixation my suffice

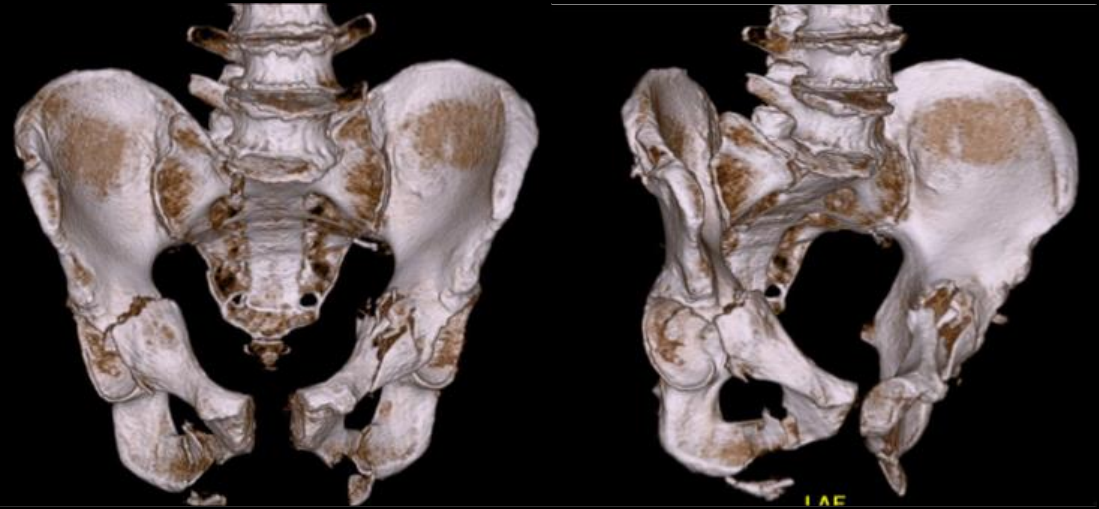


69 yo man, HSMVC, spleen and
bladder injuries

Percutaneous fixation may suffice

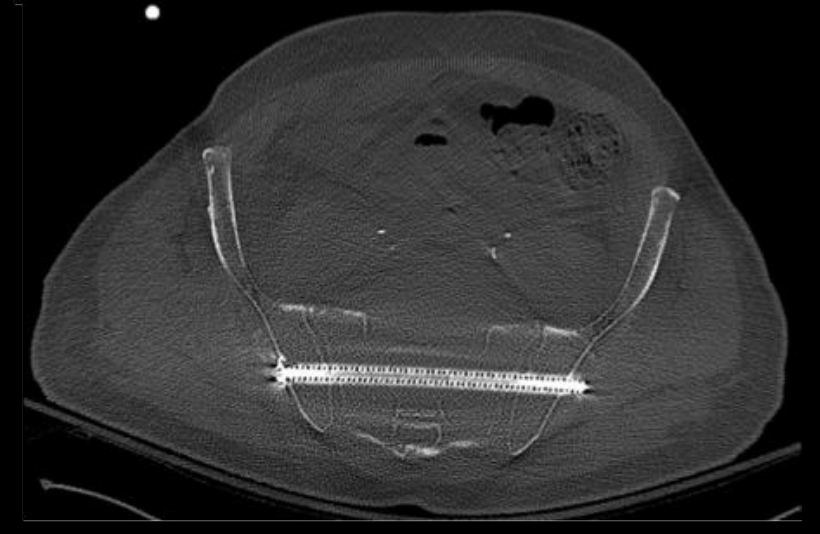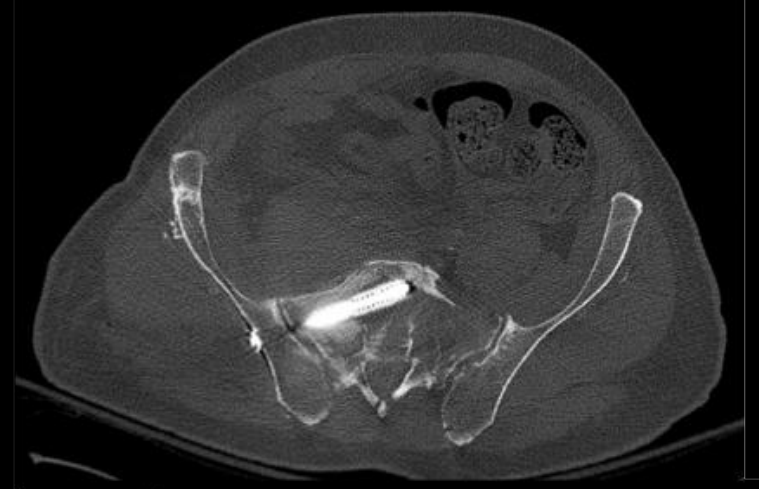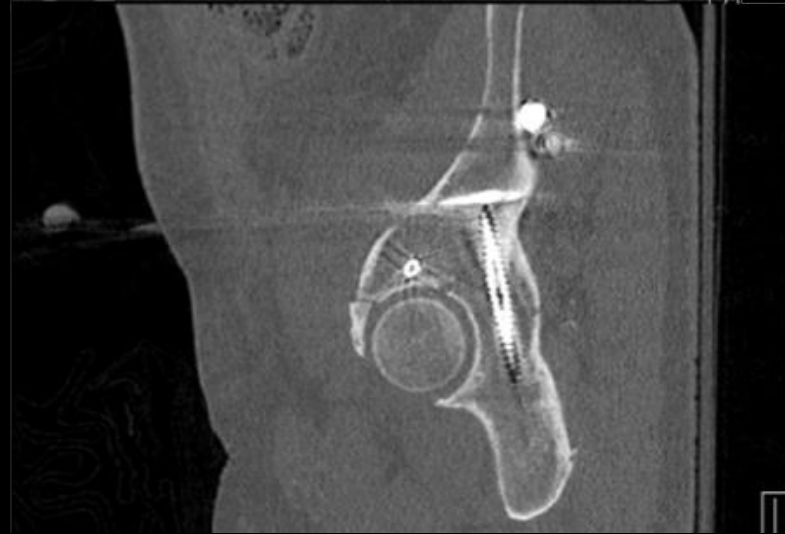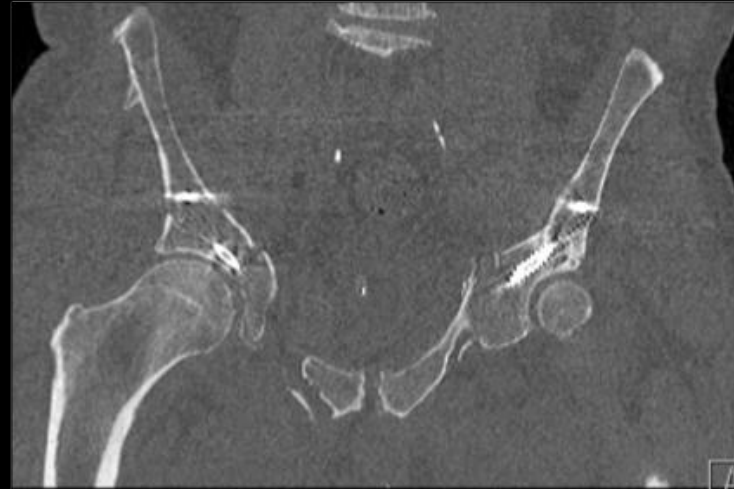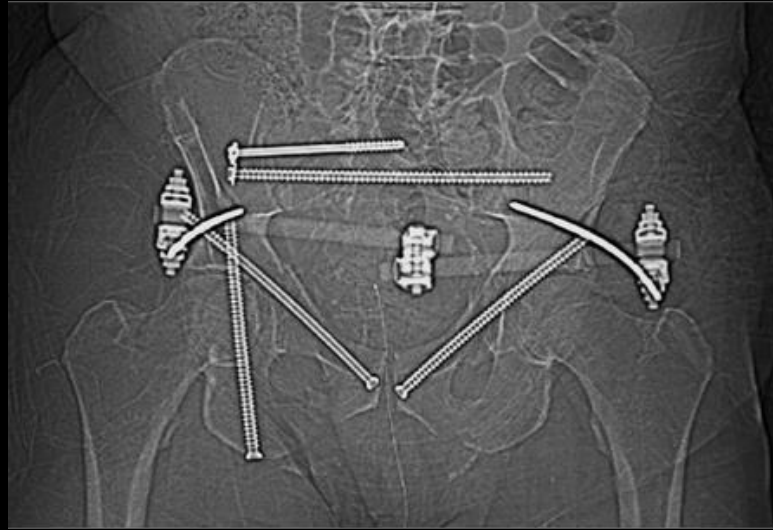
Closed Reduction and Percutaneous fixation when:

- Indirect reduction of joint possible
- Columns can be percutaneously stabilized
- Geriatric and/or multiply injured patients where surgical burden of an ORIF is to be avoided



69 yo man, HSMVC, spleen and bladder injuries

Post-Op Images



Summary Lessons from *HALF* a Career

Get good quality radiographs

Learn to read plain films

Look for reasons NOT to operate

The surgical approach is for reduction!

Predetermine when joint access is needed in surgery

Be willing to consider changing a poor reduction

Be open to when ORIF is NOT the patient's best option

Saam.morshed@ucsf.edu