

Knee and Tibia

The Top Tips and Tricks I Learned in My Career

Christian Krettek, Hannover Germany

No conflict of interest



Associate Editor
J Bone Joint Surgery



Leitthemenherausgeber Der Unfallchirurg
(Springer)



Co-Editor
Skeletal Trauma
(Elsevier)



Medizinischer Leiter OTUpdate
(medUpdate)



National or international patents

Top Tips I Learned in My Career

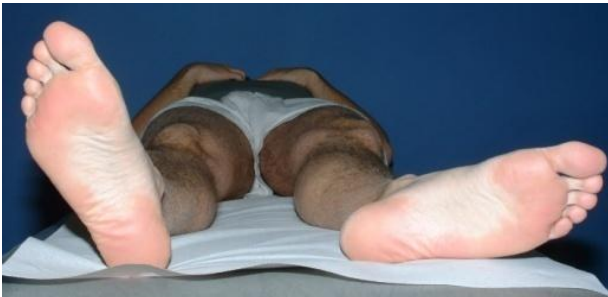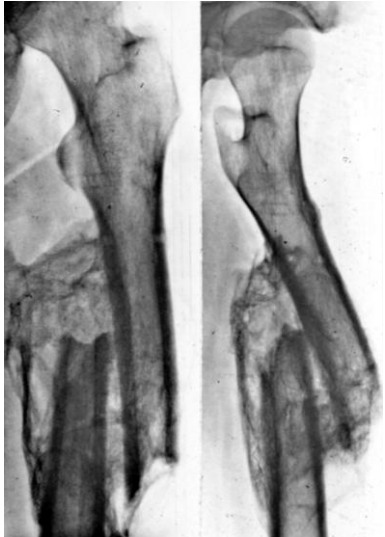1. Better intraop control
2. Reducing iatrogenic trauma
3. Learning from others



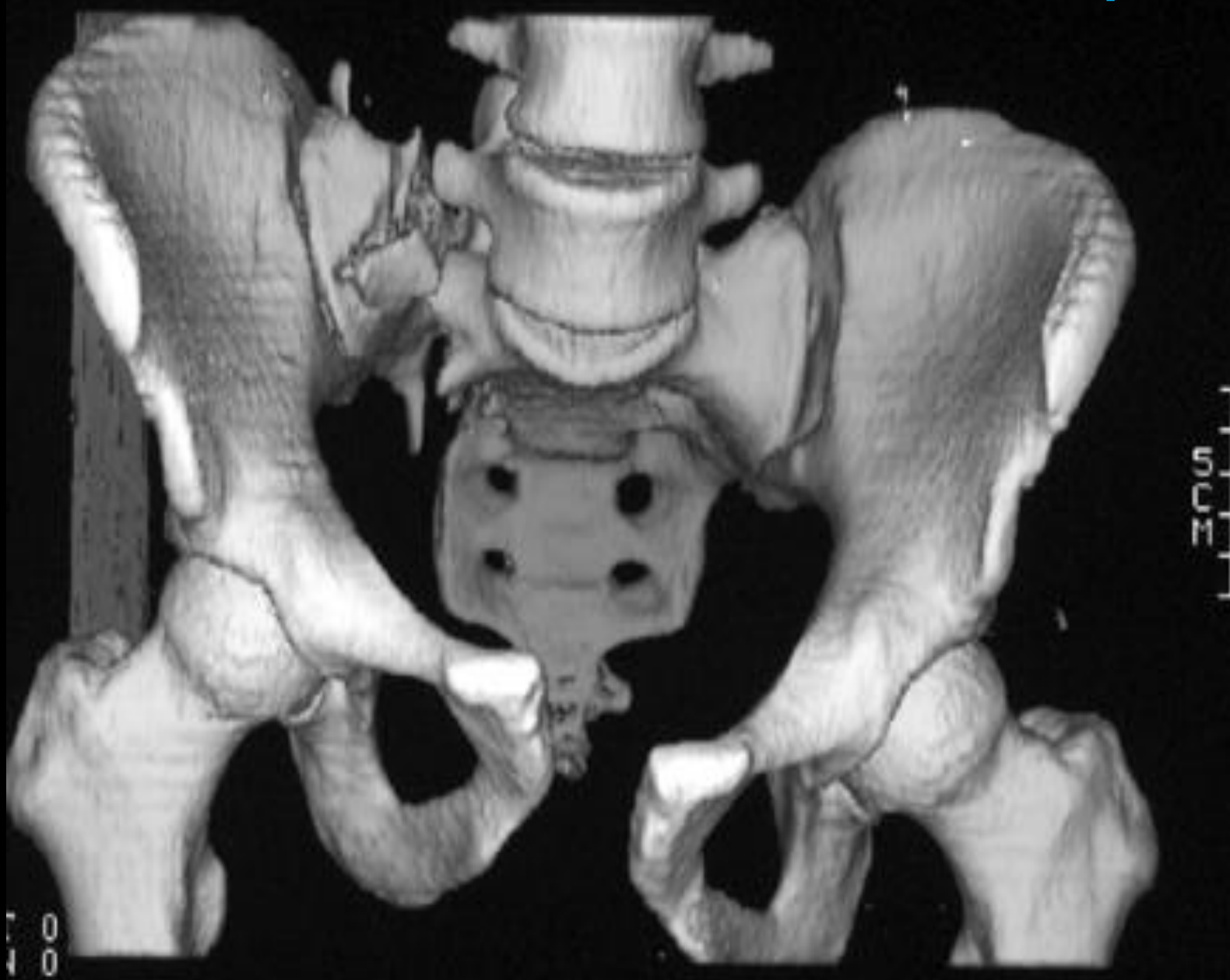1. How to get control intraoperatively

Problem:
Deformity

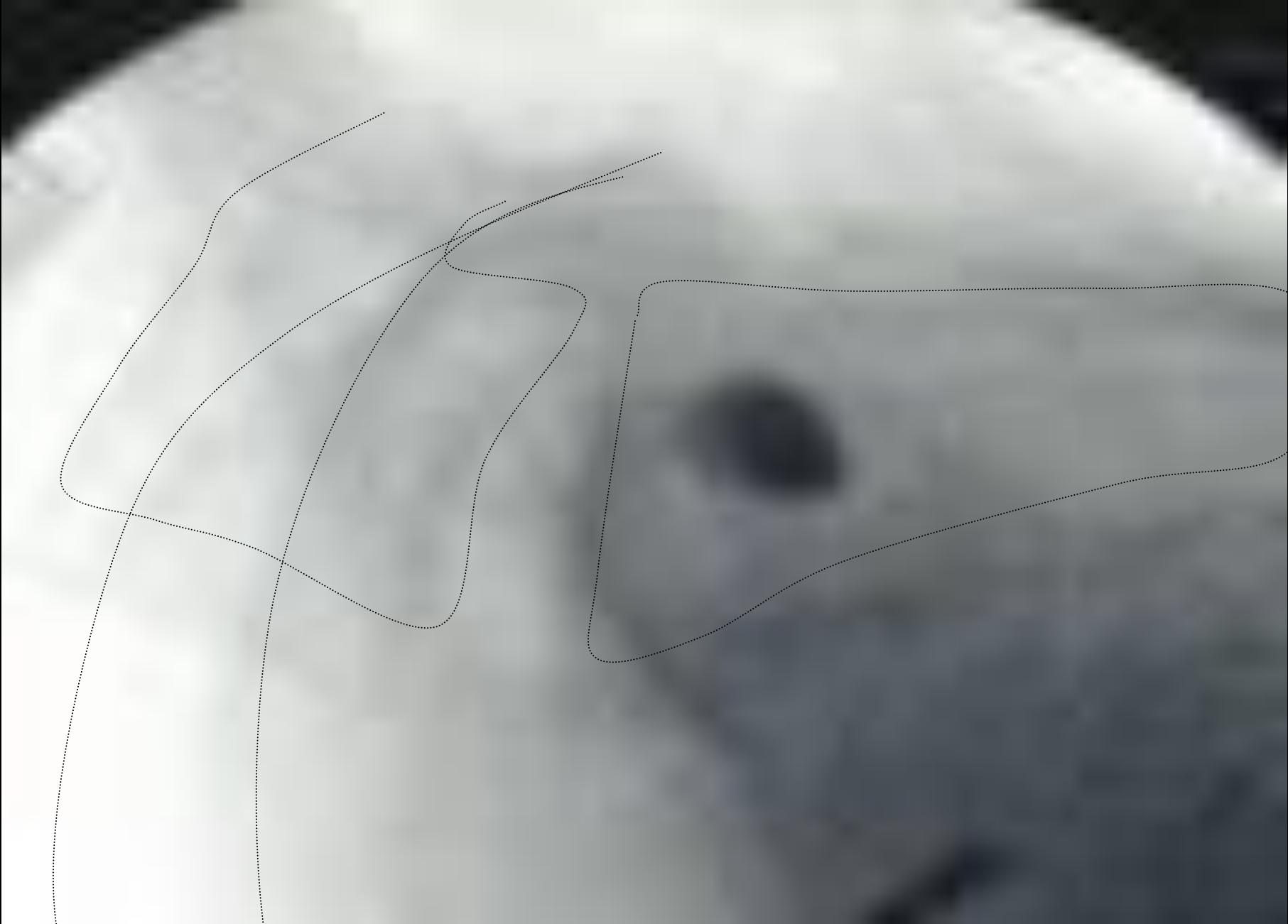
healing alone is
not enough






Surgeons dream ... unlimited intraop imaging



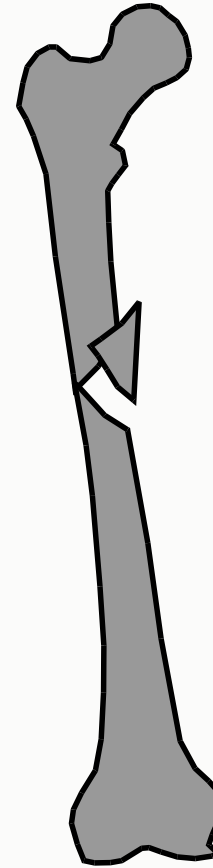

surgeons reality



Surgeon's Reality: Intraoperative Problems with Judgement of Alignment: C-arm has Limited field of view

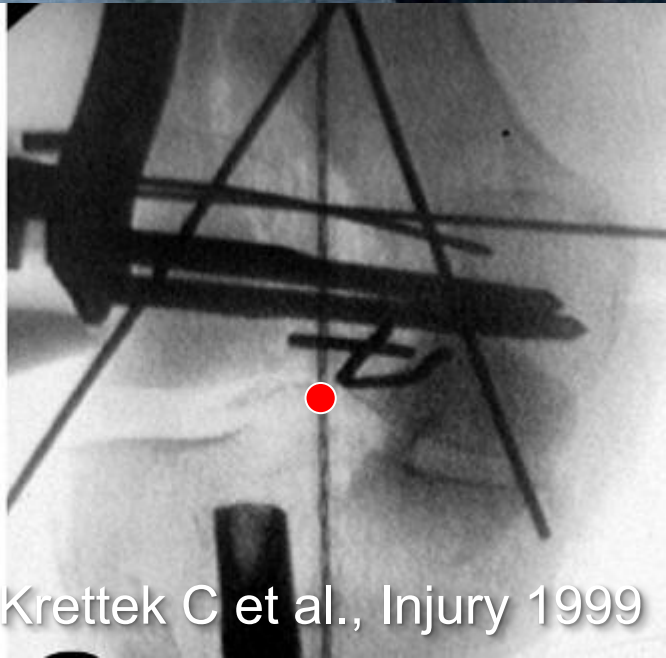
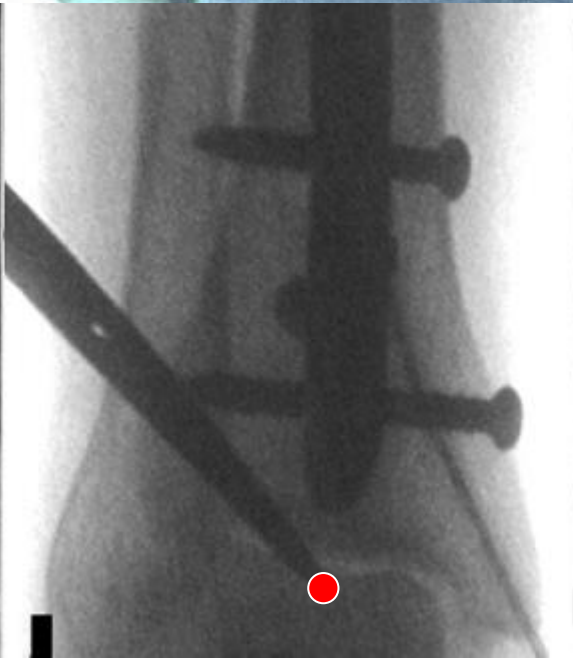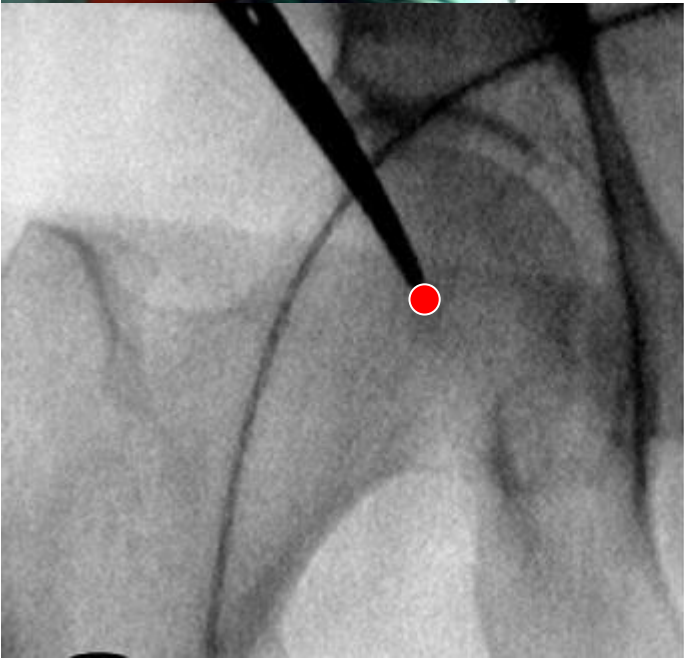
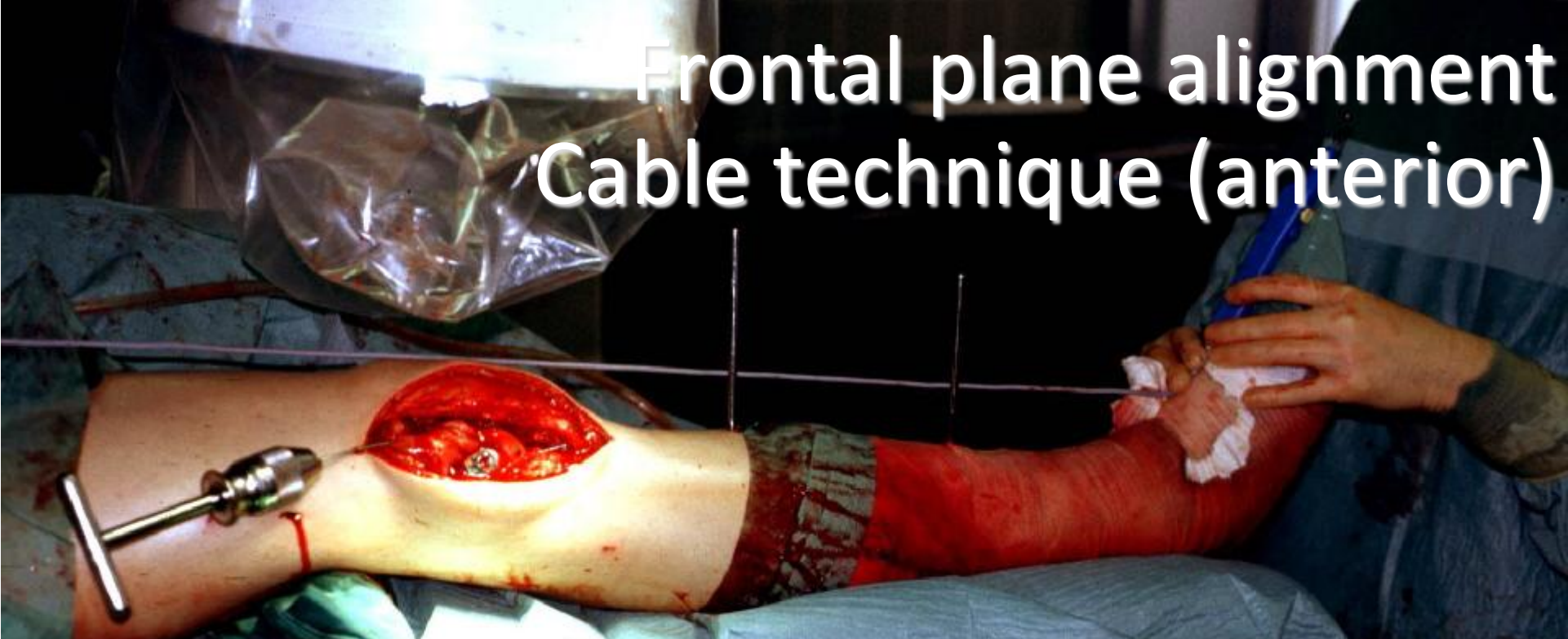


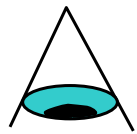problem 1
only small
segment visible



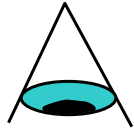
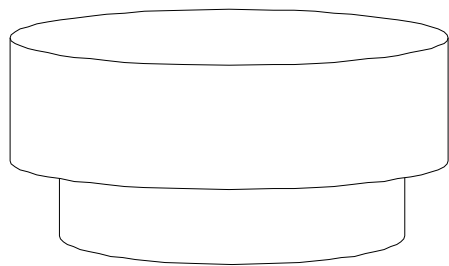
problem 2
no reference

Frontal plane alignment Cable technique (anterior)

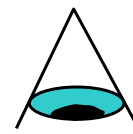
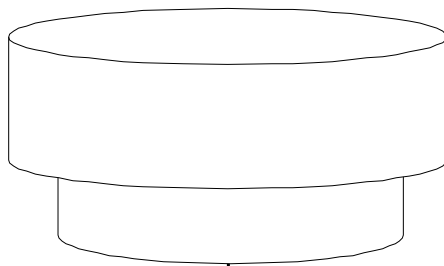




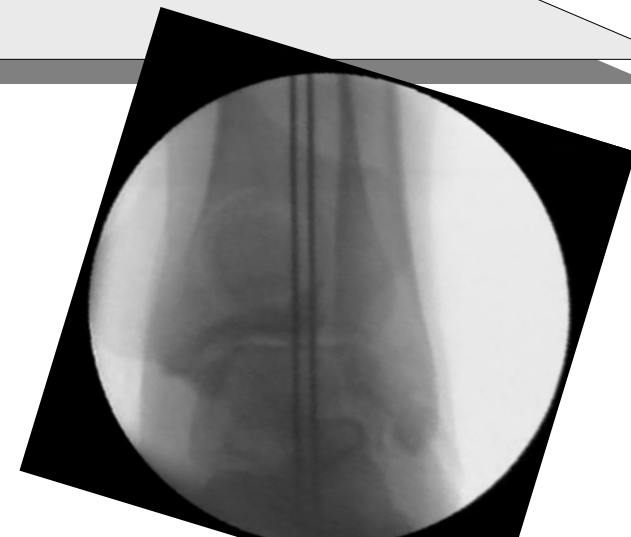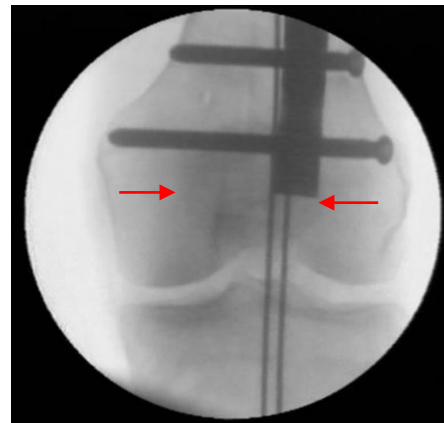
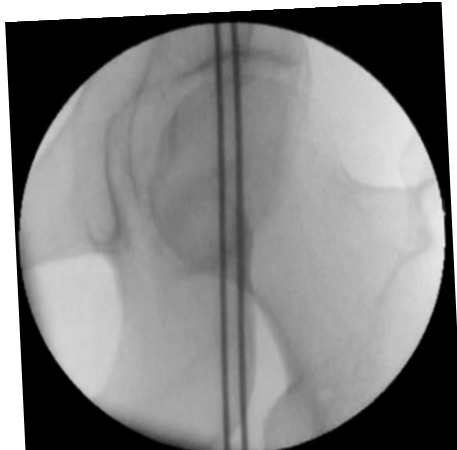
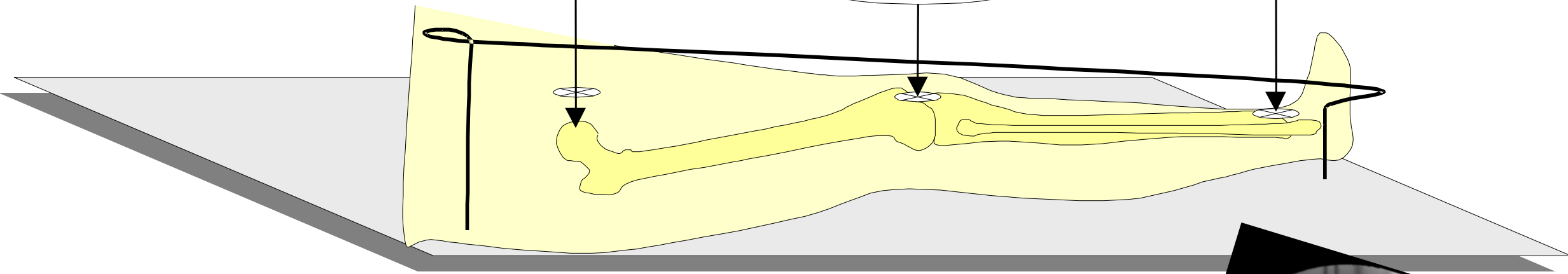
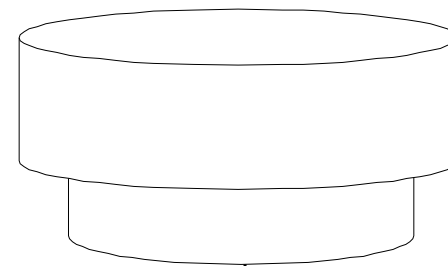
#2 femoral head centered?

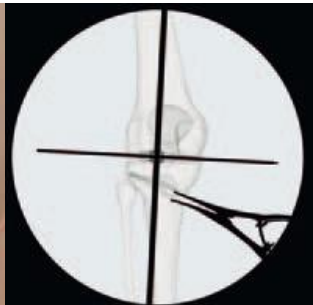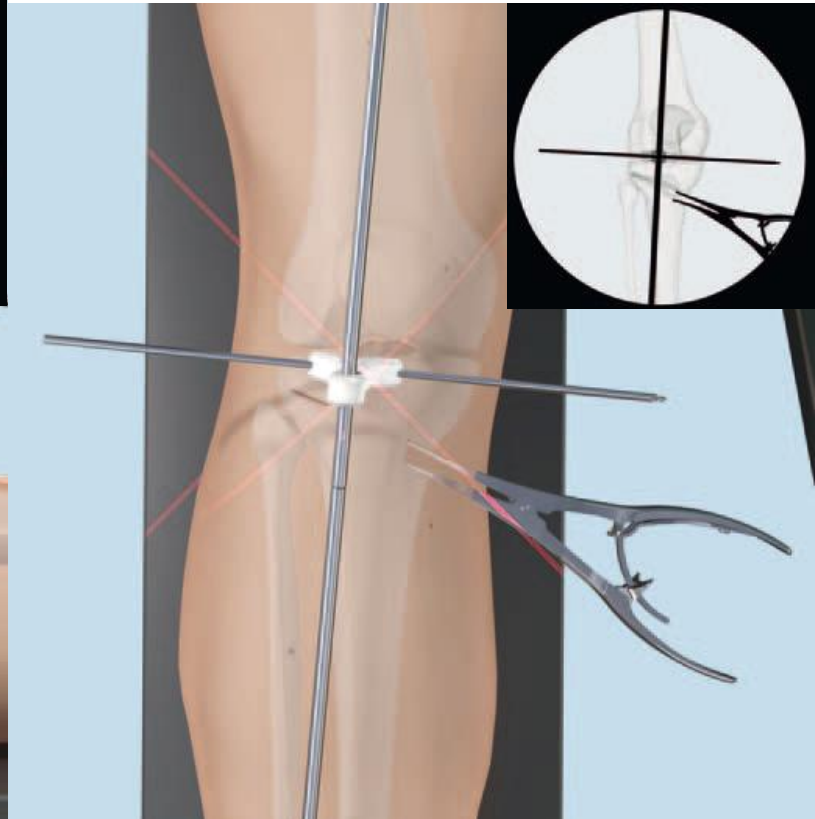
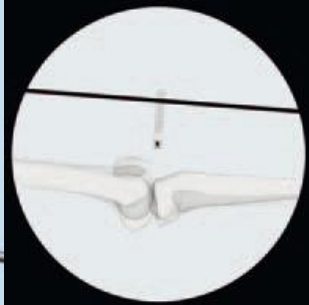
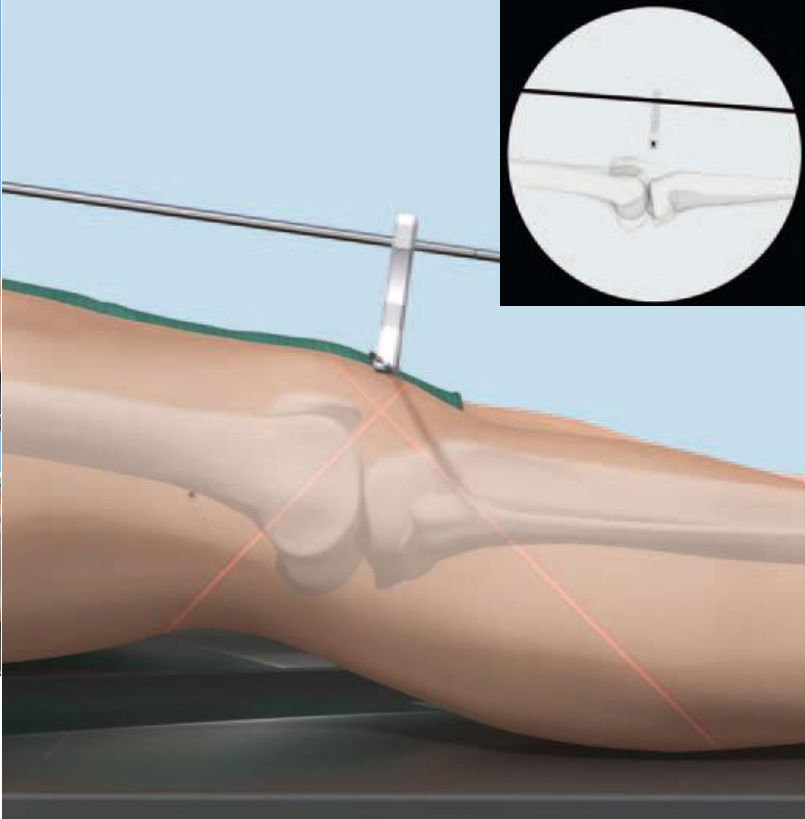
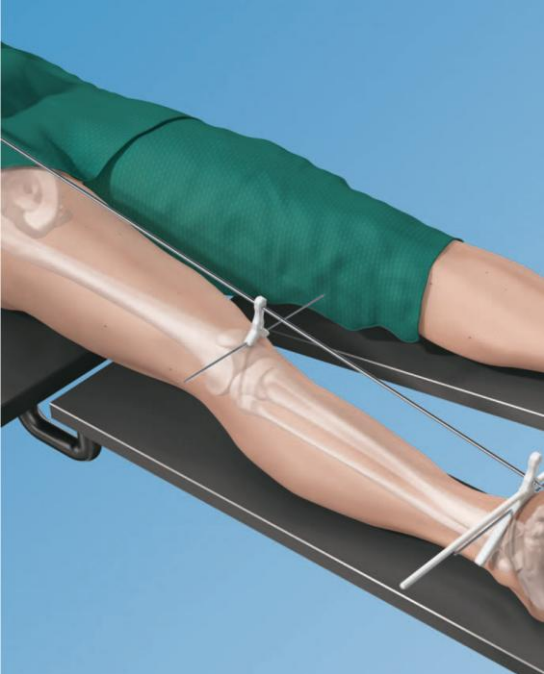
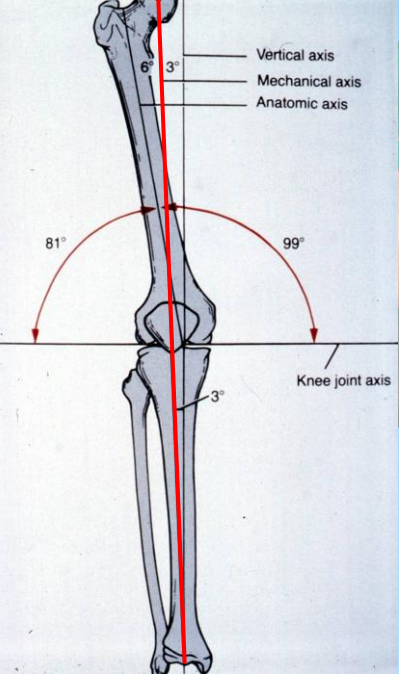


#1 patella centered?



#3 talus centered?






hip



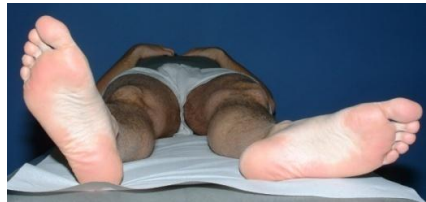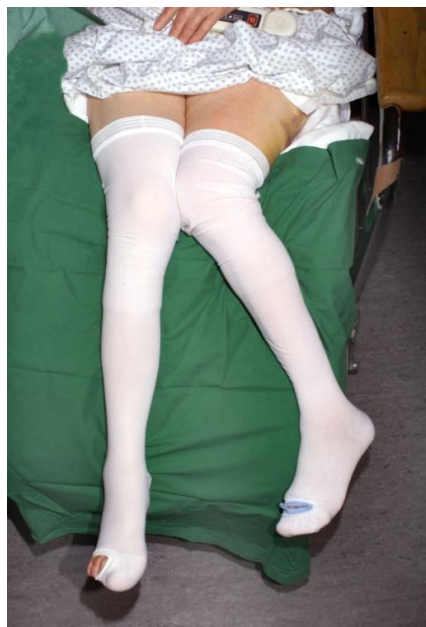ankle



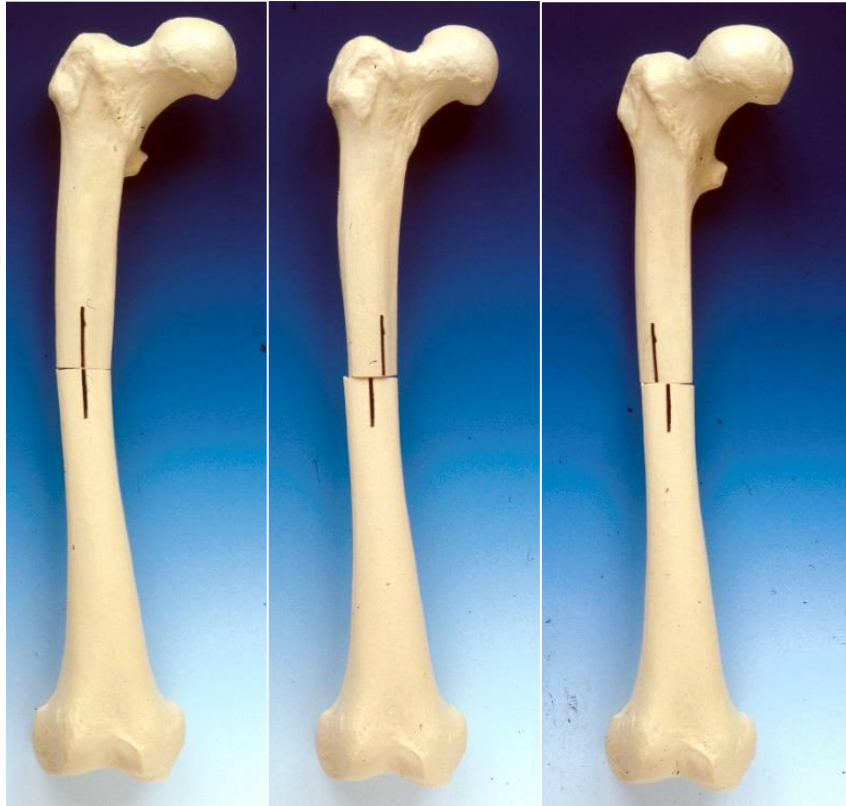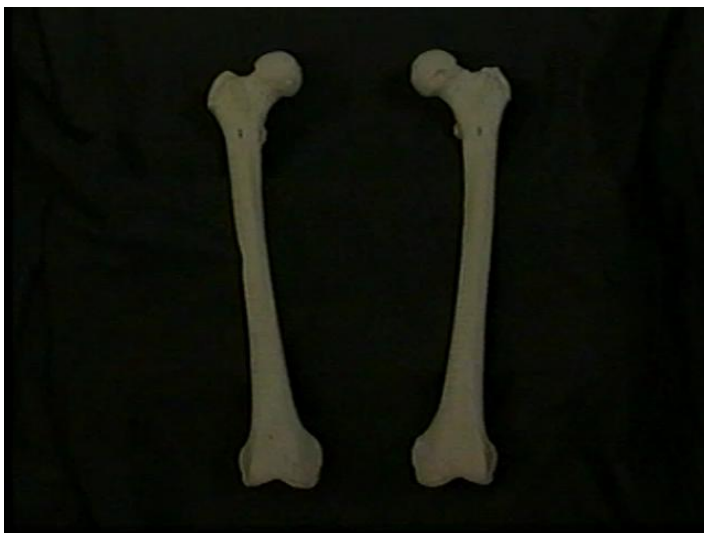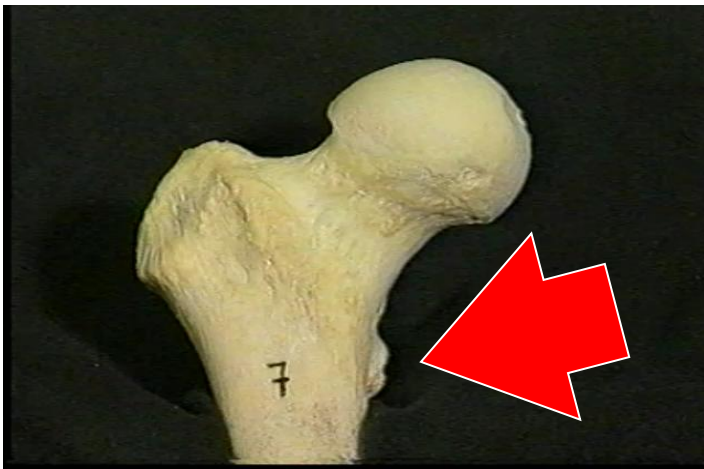
Alignment Stick with 90° reference
 +++helpful in floating knee
 situations

Peri-Prosthetic fracture
Healing is only one task
Alignment matters

Torsion malalignment
major risk for
falls in the elderly



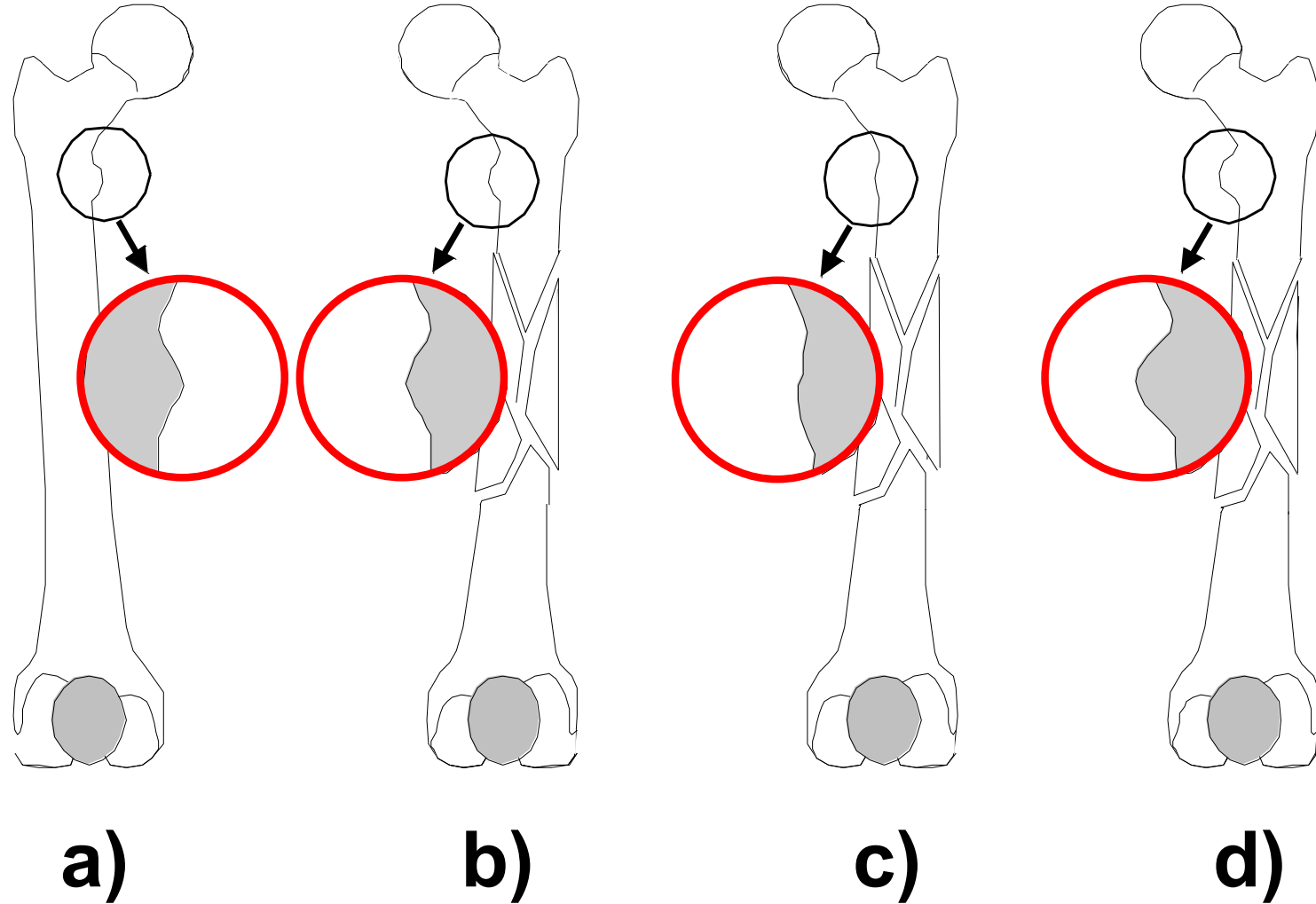
Lesser trochanter shape sign



comparison contra-lateral

Krettek et al (1999) Injury 29, Sup 3

Lesser trochanter shape sign



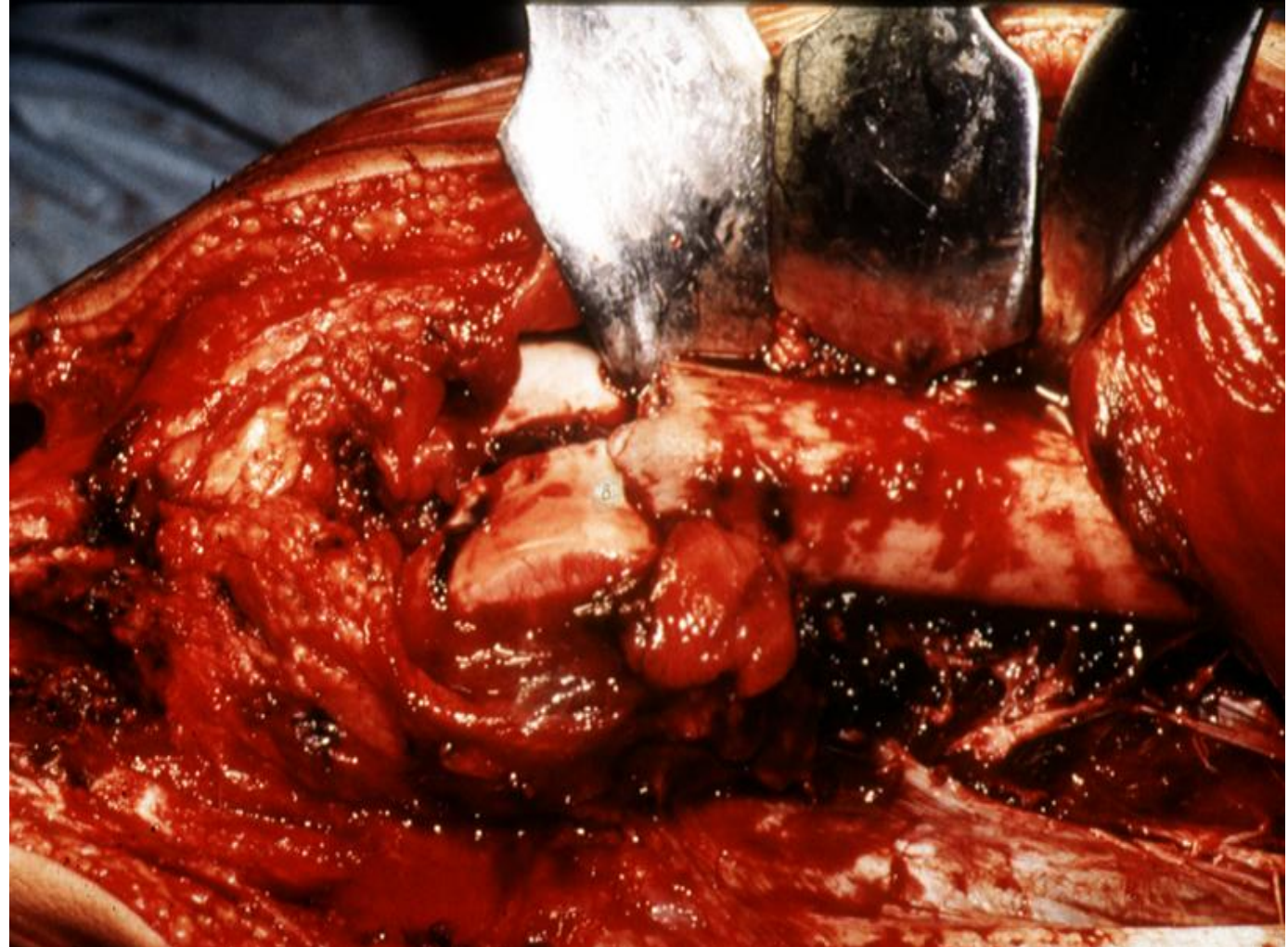
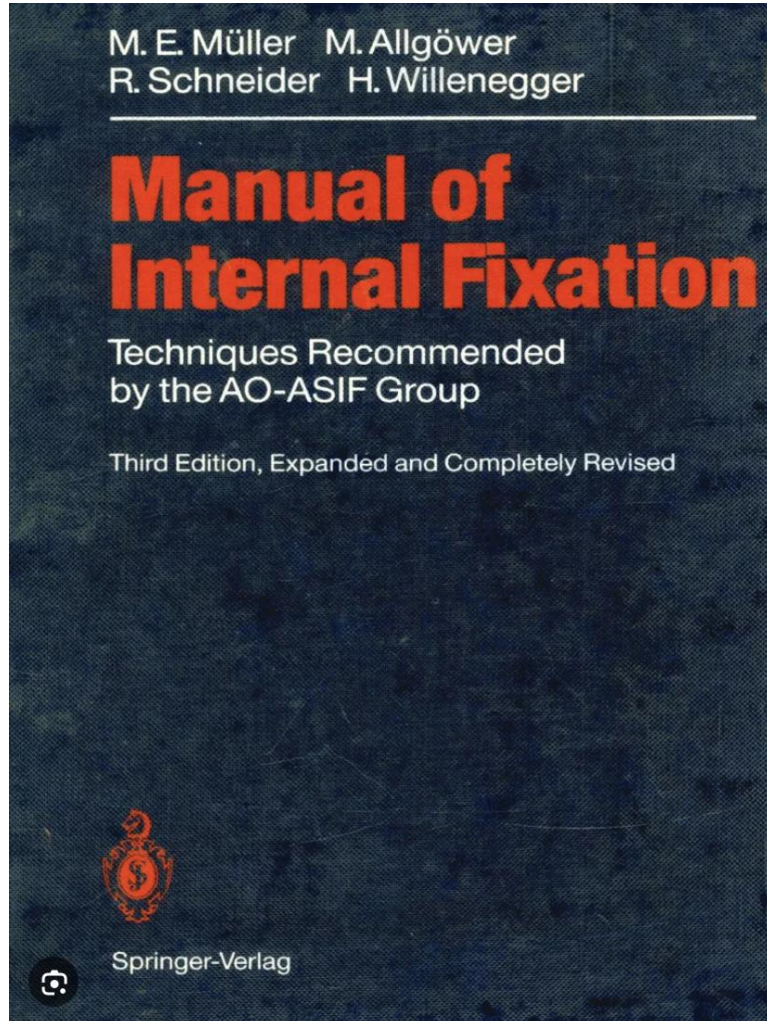
Kim JJ, Kim E, Kim KY
(2001) Predicting the
rotationally neutral
state of the femur by
comparing the shape
of the contralateral
lesser trochanter.
Ortho- pedics 24:
1069

Krettek et al (1999) Injury 29, Sup 3

2. How to avoid additional iatrogenic damage

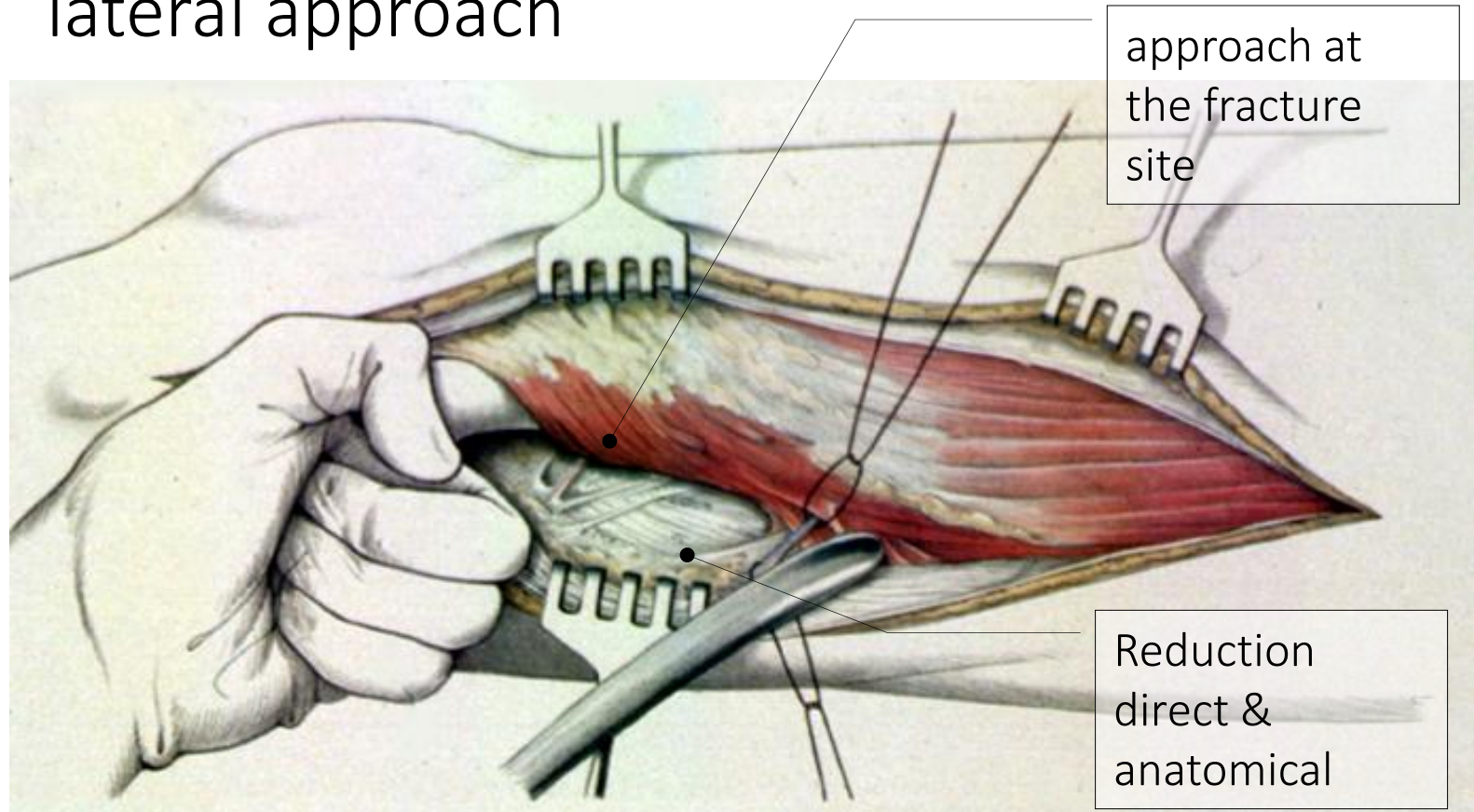
AO Teaching in 1990
... preserve the soft tissue ...

AO Reality in 1990

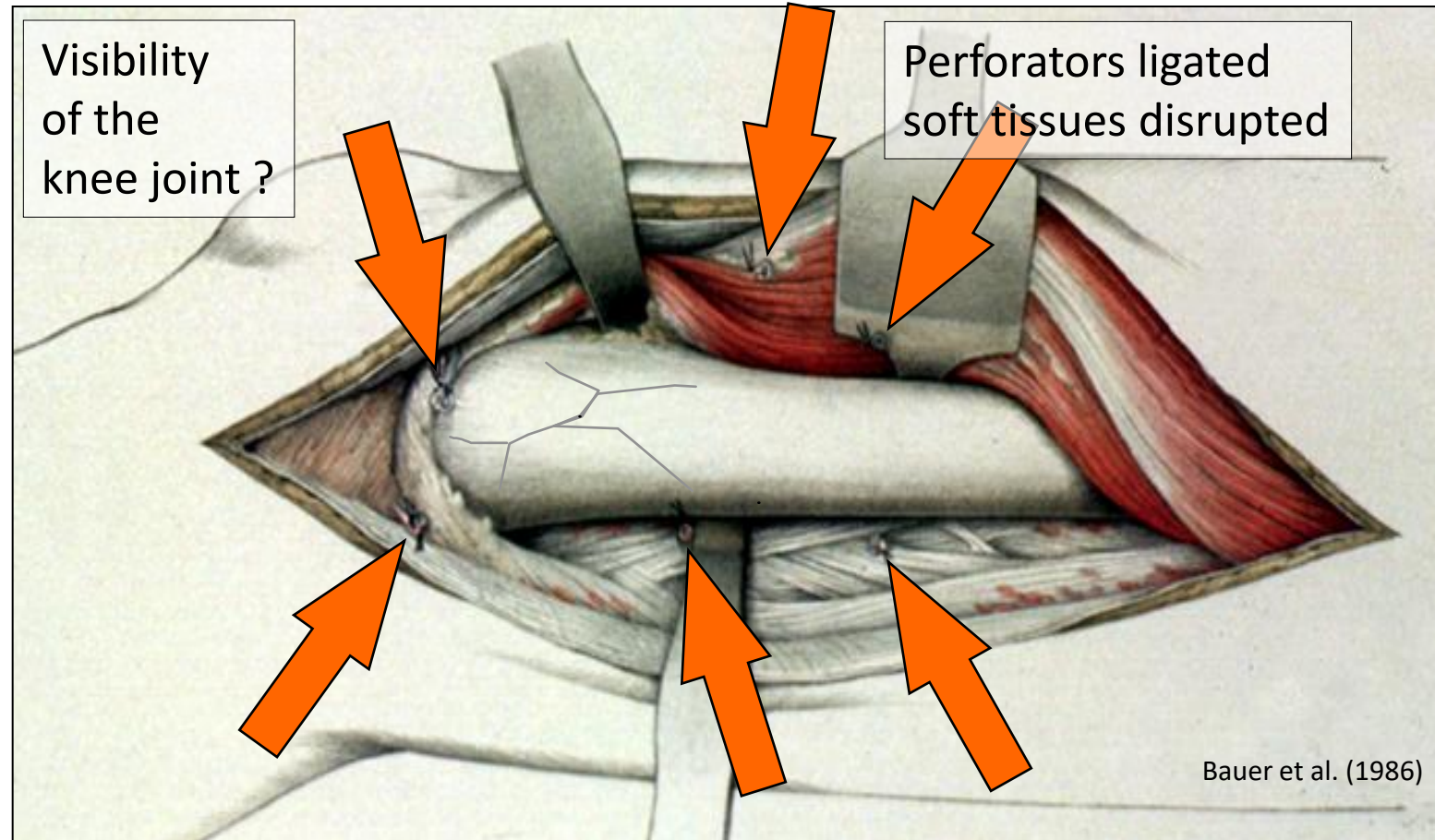


Official statements ... and reality often different

Approach for plating
distal femoral fracture
lateral approach



Approach for plating example: distal femoral fracture lateral approach

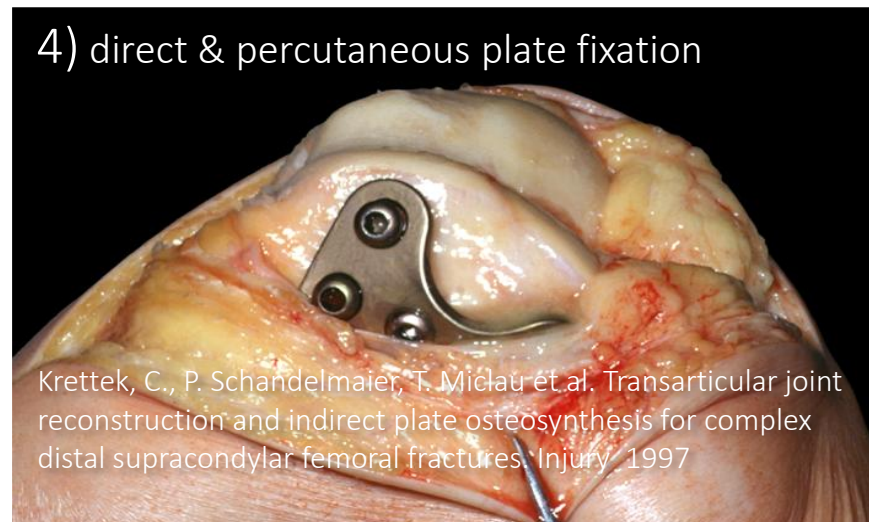
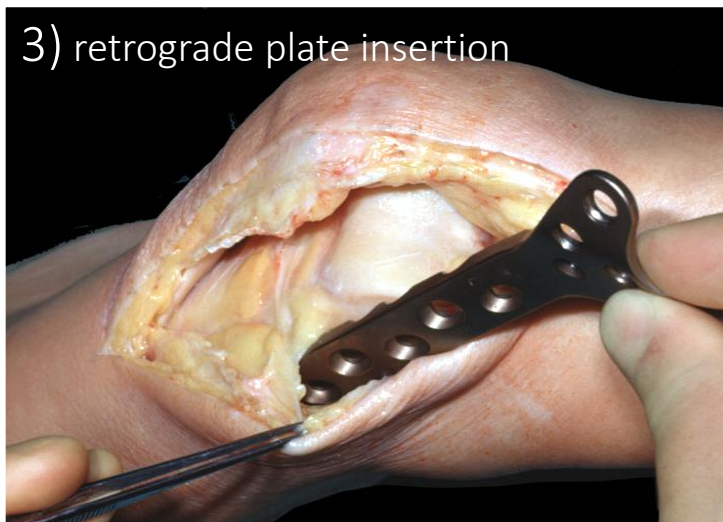
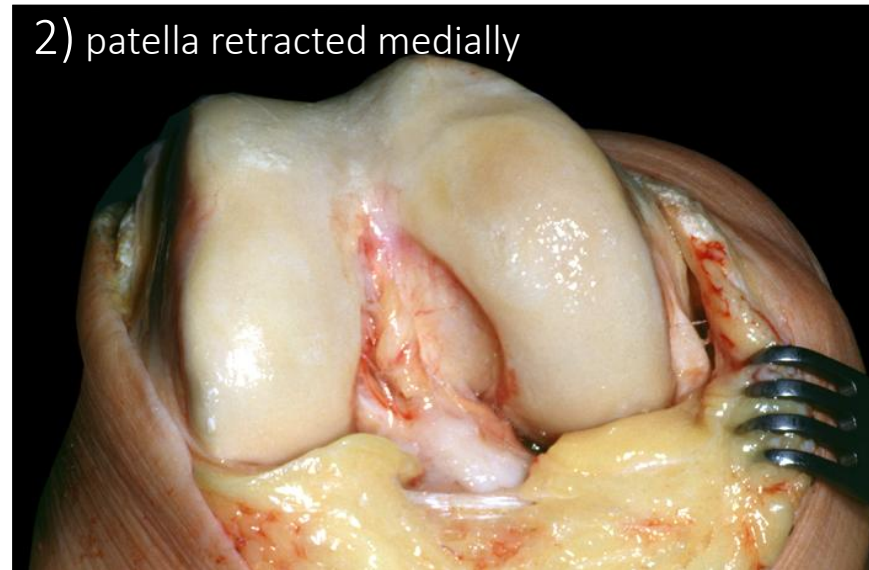
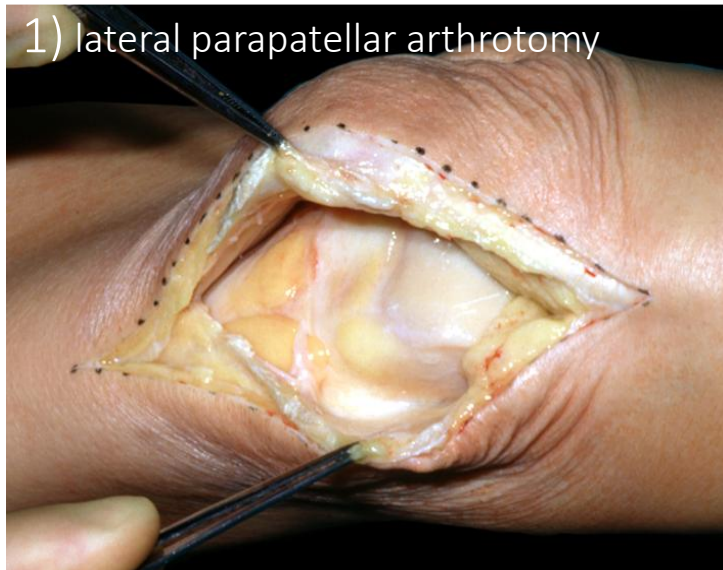



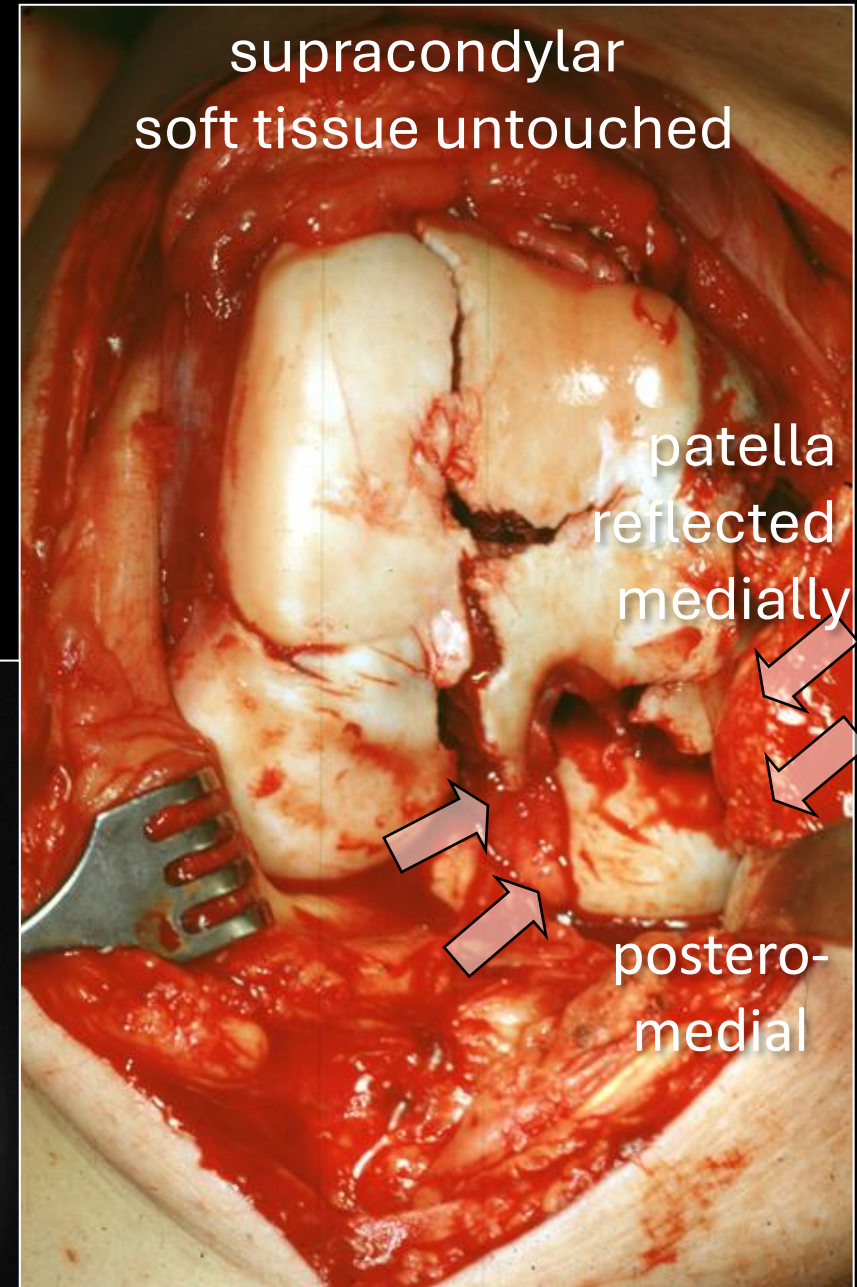
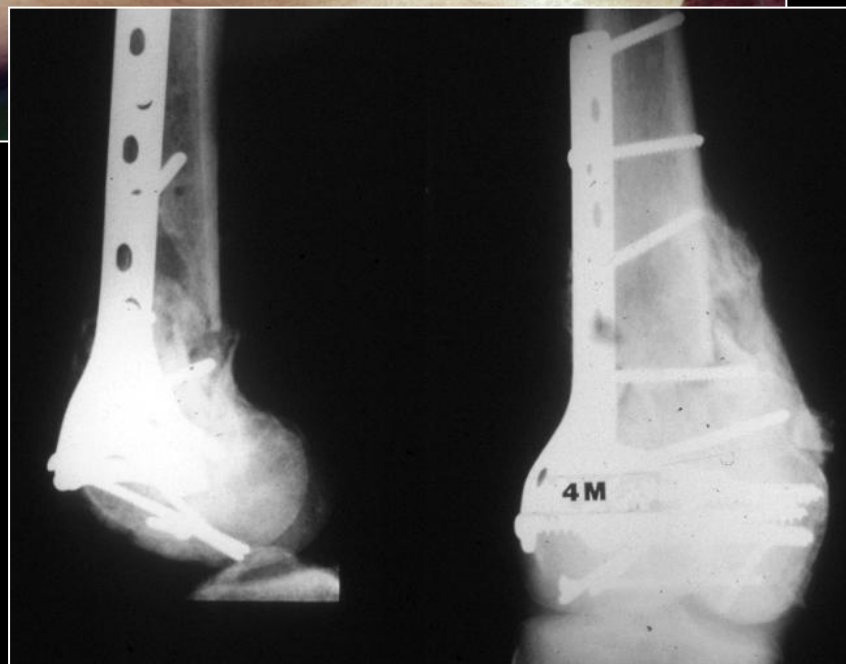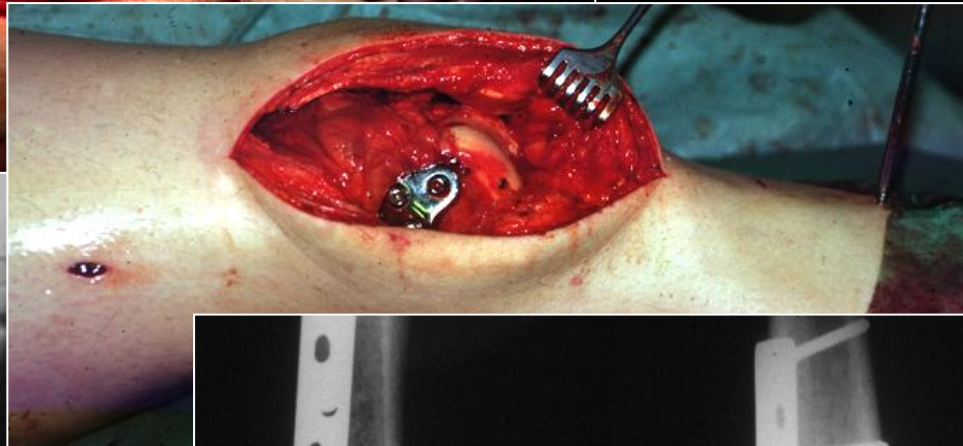
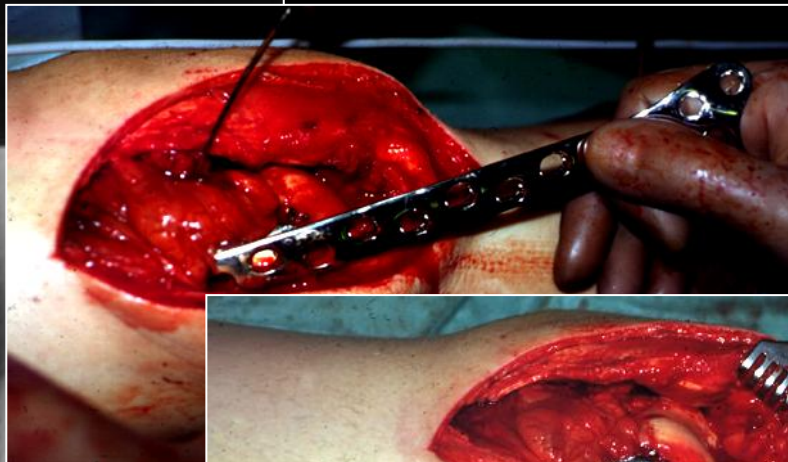
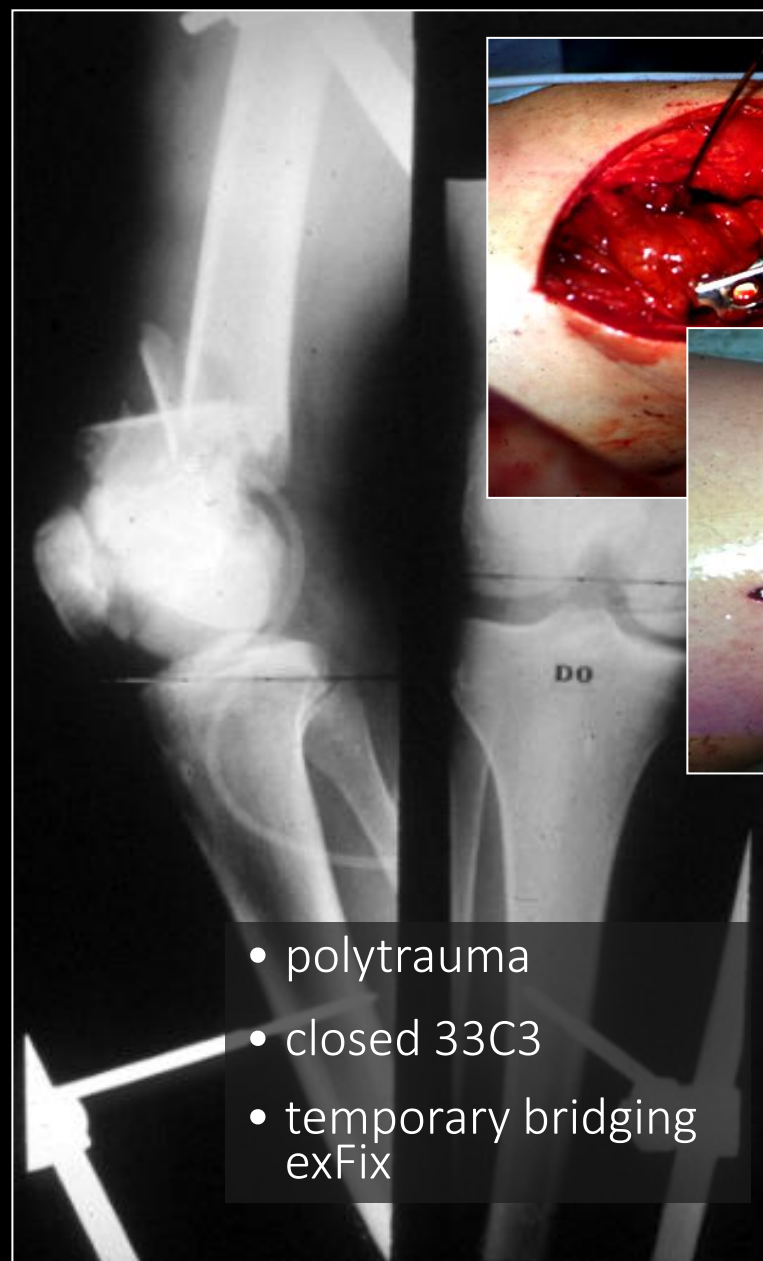new approach: TARPO

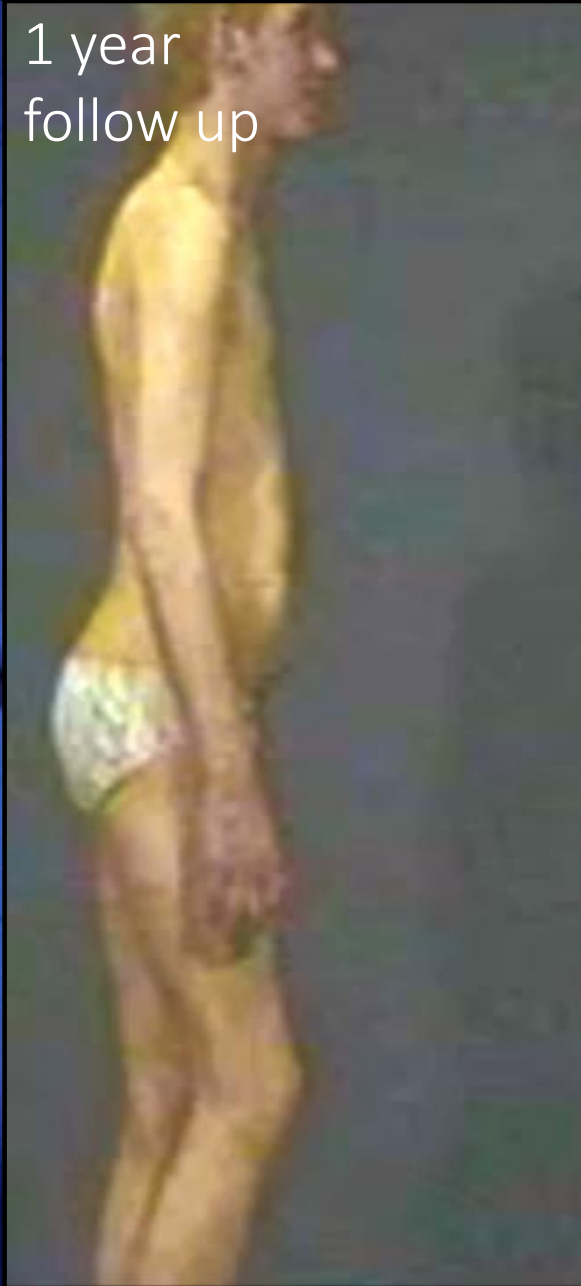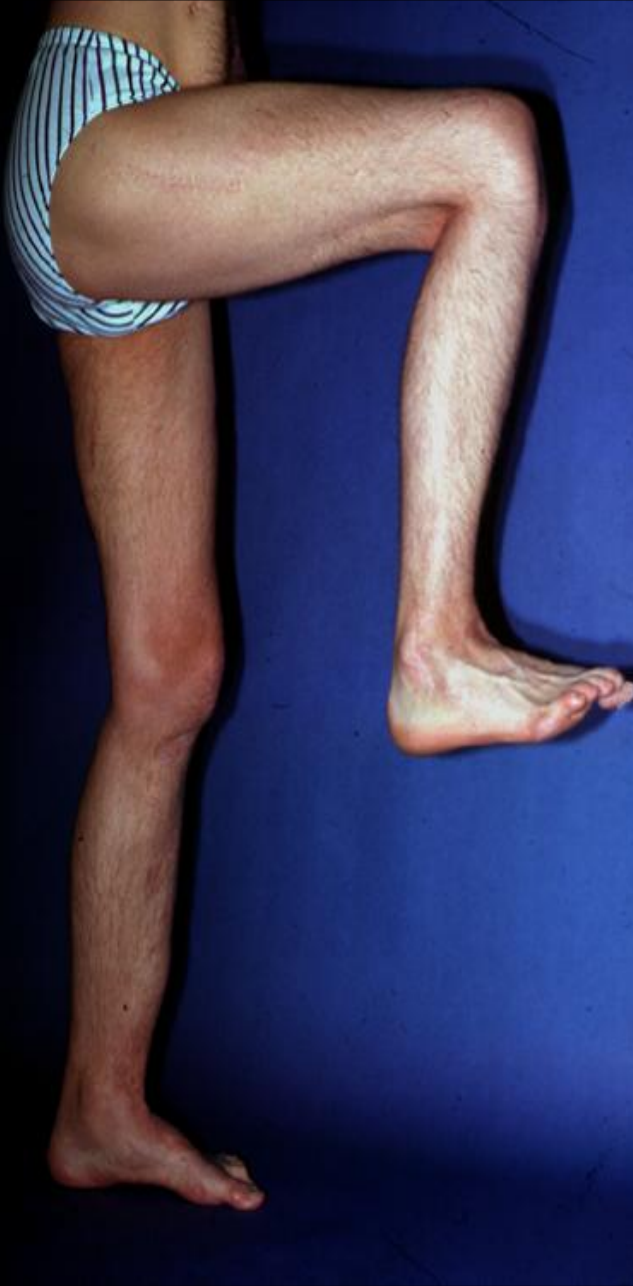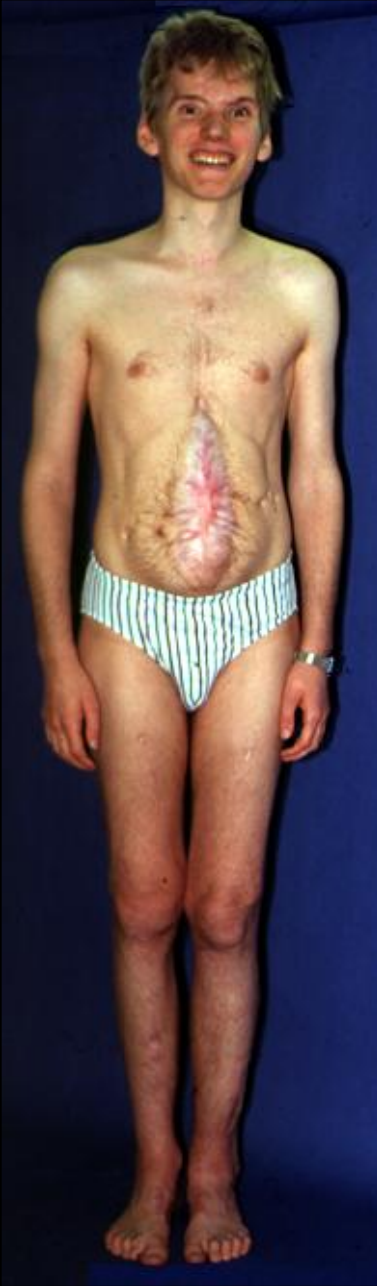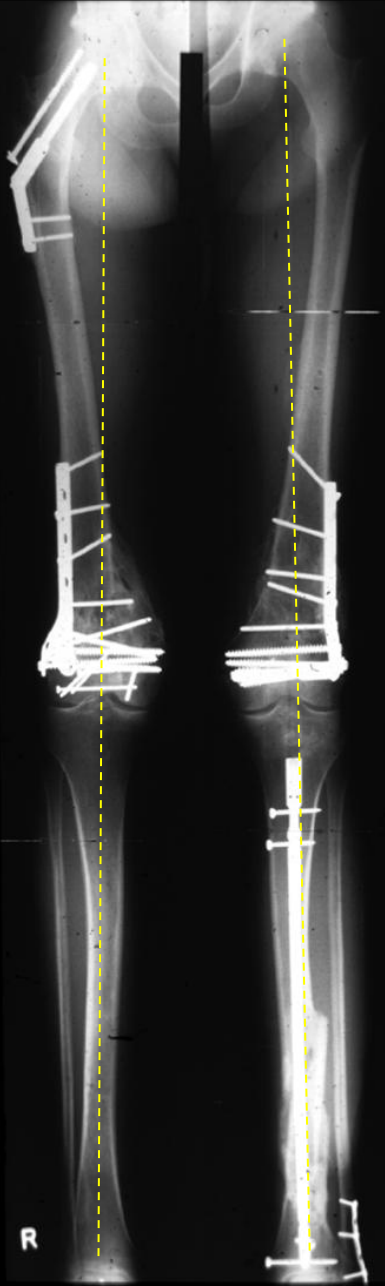
Transarticular approach & retrograde Plate Osteosynthesis

W: why not
approaching it
in a way that
addresses both
...
articular
visibility
&
soft tissue
preservation?

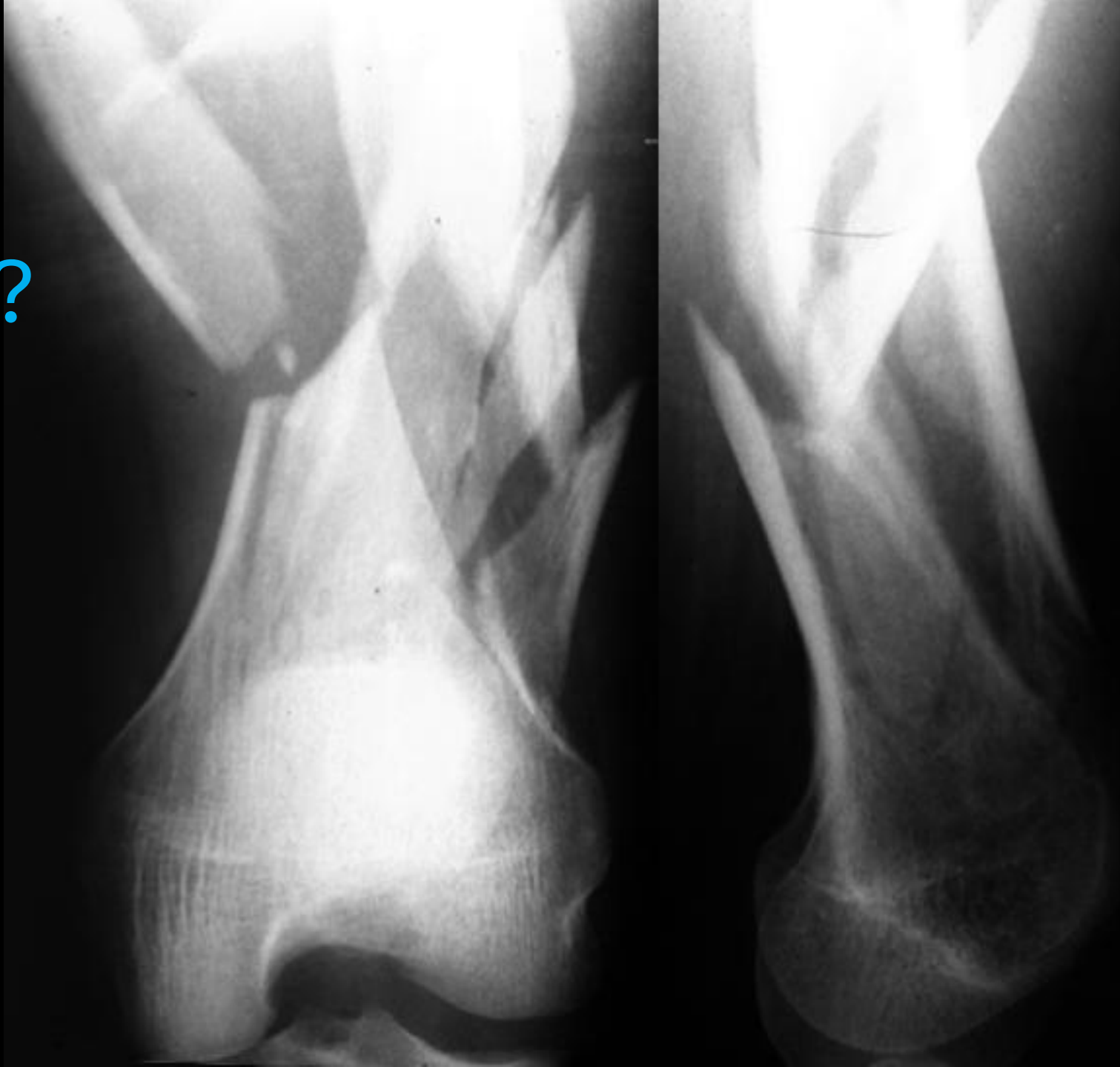

Krettek, C., P. Schandelmaier, T. Midaoui et al. Transarticular joint reconstruction and indirect plate osteosynthesis for complex distal supracondylar femoral fractures. Injury. 1997

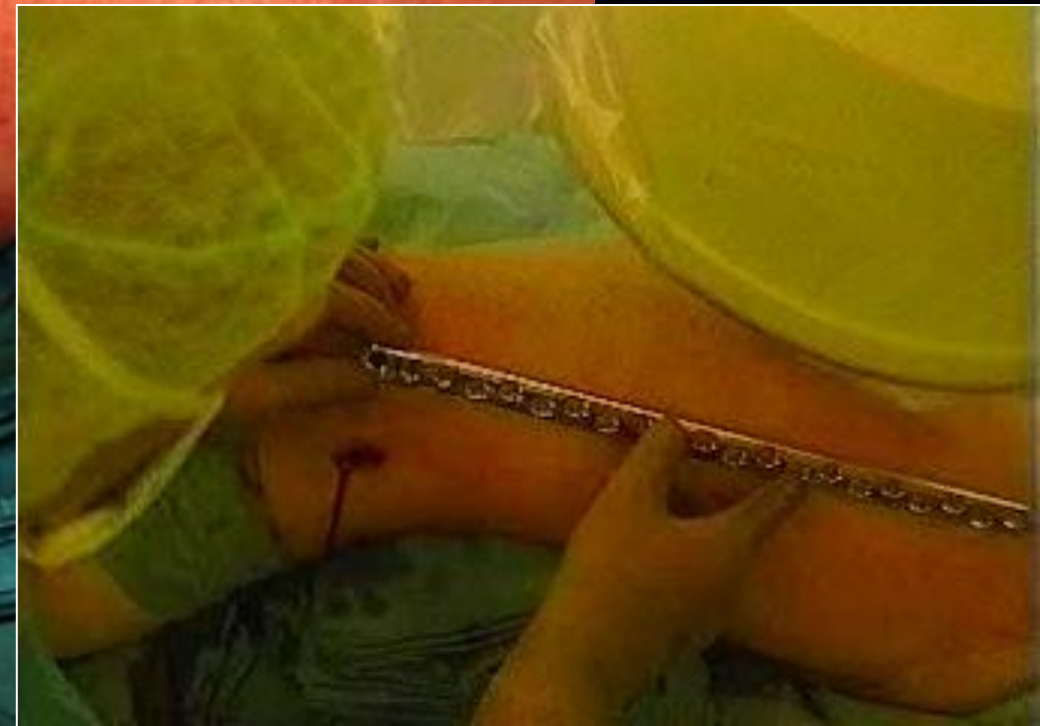
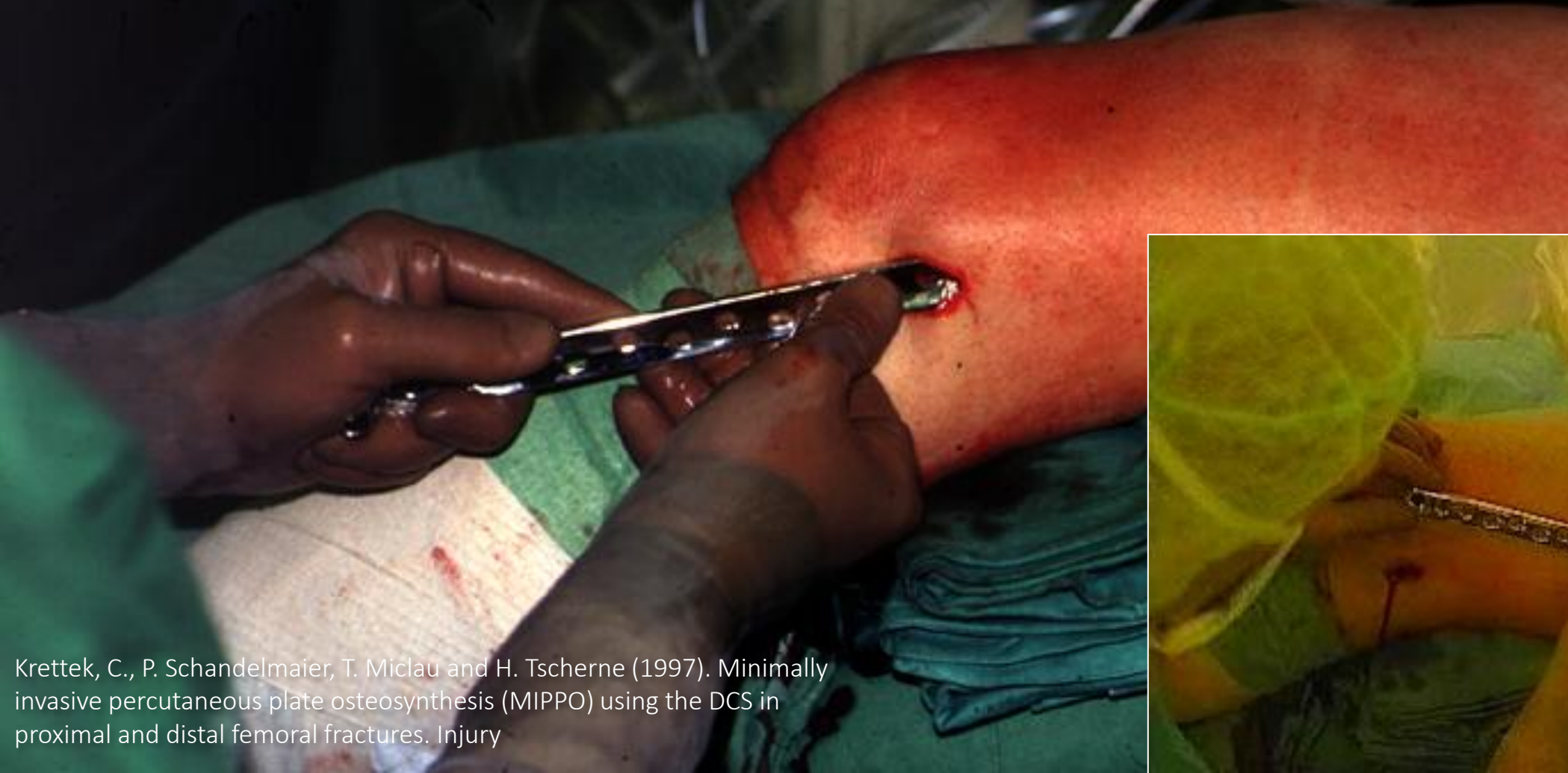


Extraarticular Fractures Why arthrotomy?



Minimal-Invasive Percutaneous Plate Osteosynthesis (MIPPO)



Krettek, C., P. Schandelmaier, T. Miclau and H. Tscherne (1997). Minimally invasive percutaneous plate osteosynthesis (MIPPO) using the DCS in proximal and distal femoral fractures. *Injury*

3. Learn from others



Kerf Spacing Calculator for Bending Wood

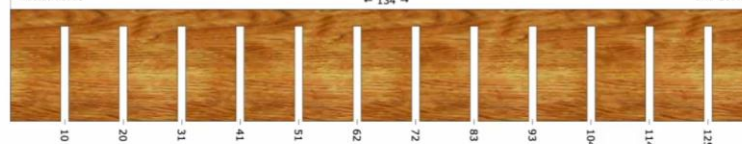
Curve Radius (outside)
Curve Sweep Angle
Kerf Width
Wood Thickness
 Min Thickness
 Curve in Longer Board Video
 Curve End to End
 Router Tapered Dims
Colour

Curve Radius
Sweep Angle
Kerf Width
Scale

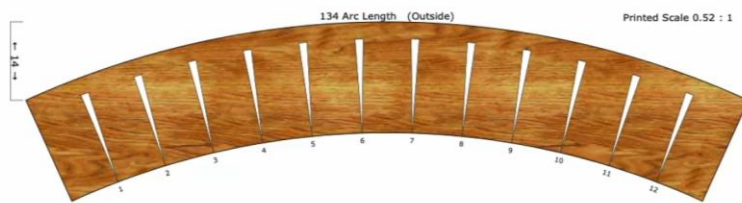
12 Cuts of 1.47 mm @ 10.4 mm centres with 9 mm wood width between cuts

Curve Radius 157 - Sweep Angle 49° - Wood Thick 20 - Kerf Width 1.47 Printed Scale 0.52 : 1

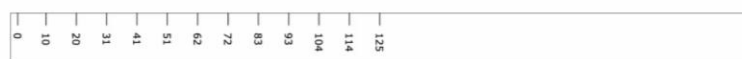
← Start Curve → ← 134 → End Curve →



134 Arc Length (Outside) Printed Scale 0.52 : 1



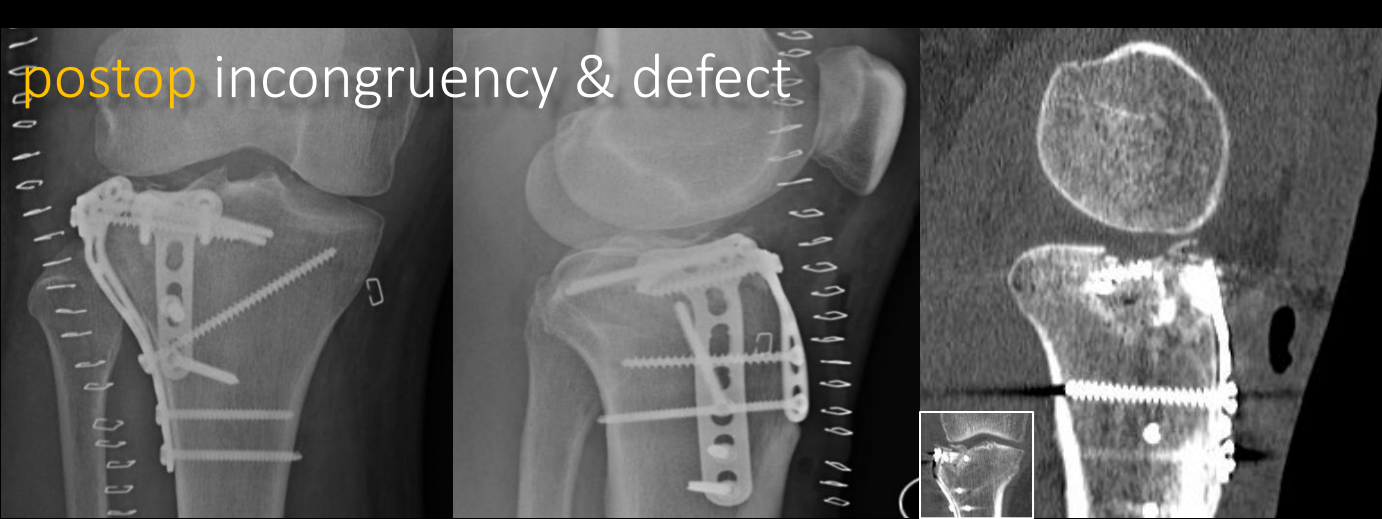
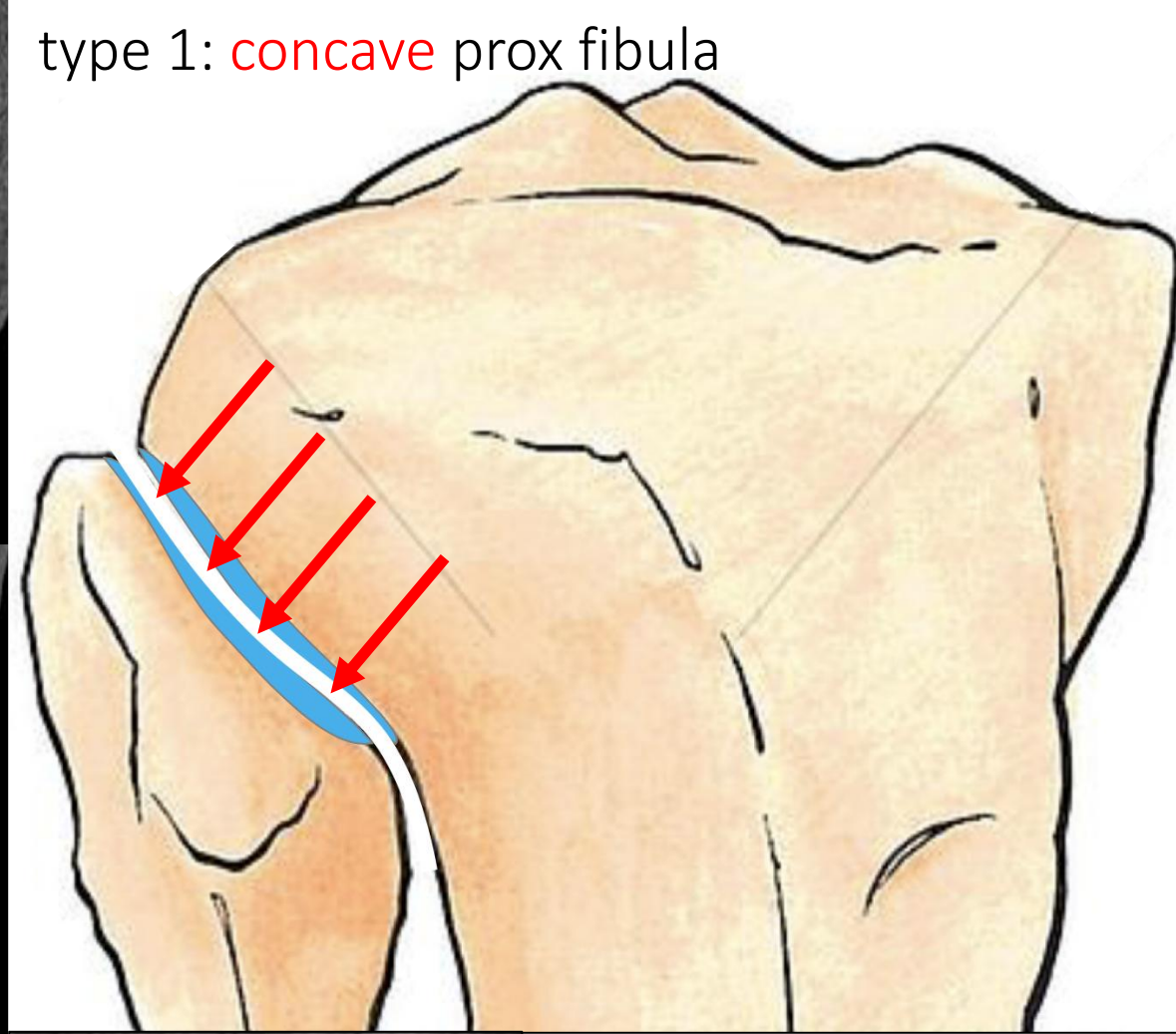
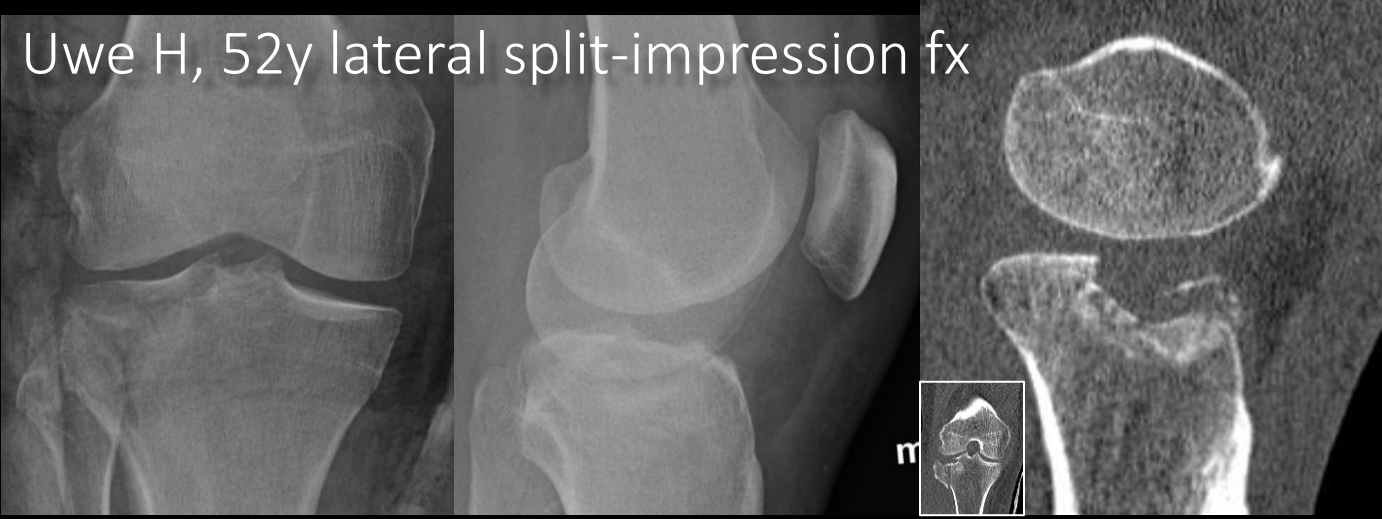
Curve Radius 157 - Sweep Angle 49° - Wood Thick 20 - Kerf Width 1.47



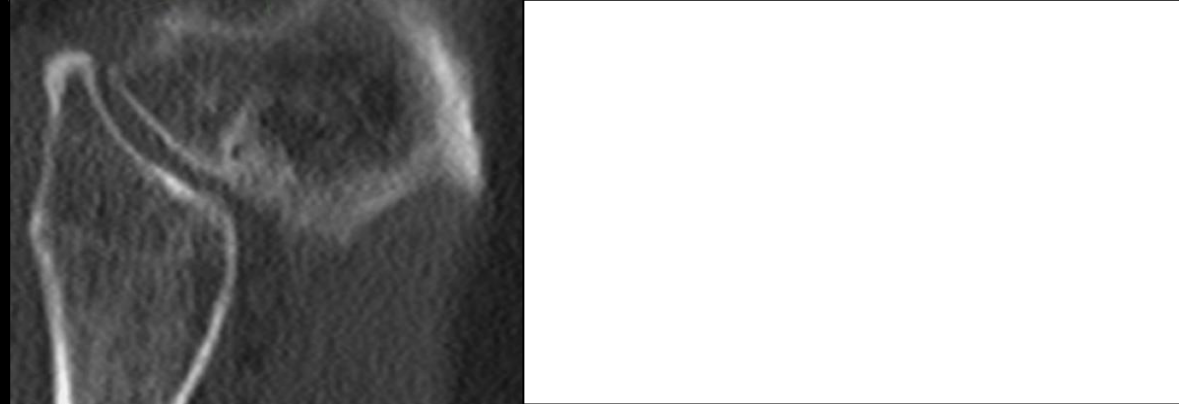
Print and cut this Full Scale Template to mark out Kerf Cut Centres (repeat if short) Printed Scale 1 : 1



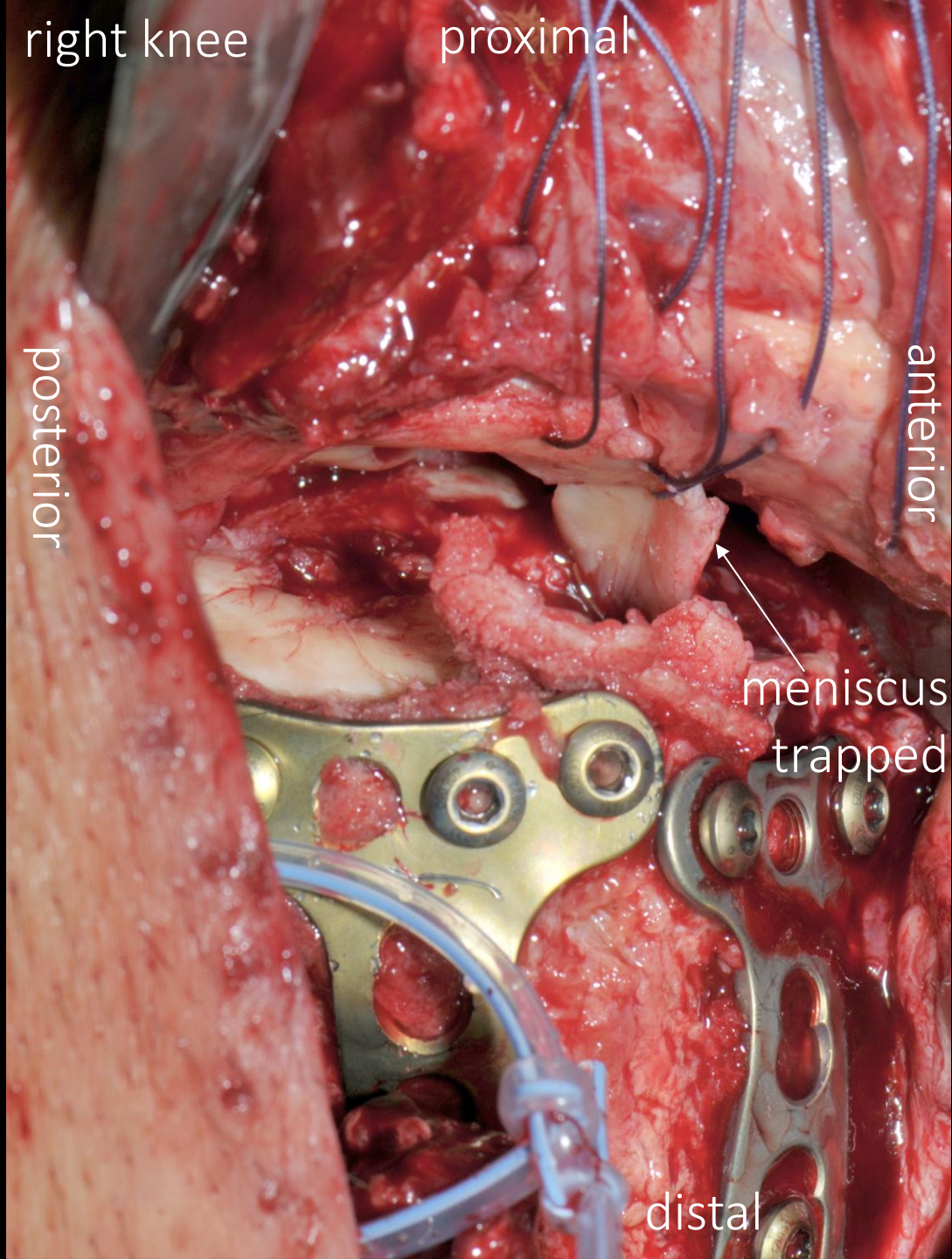
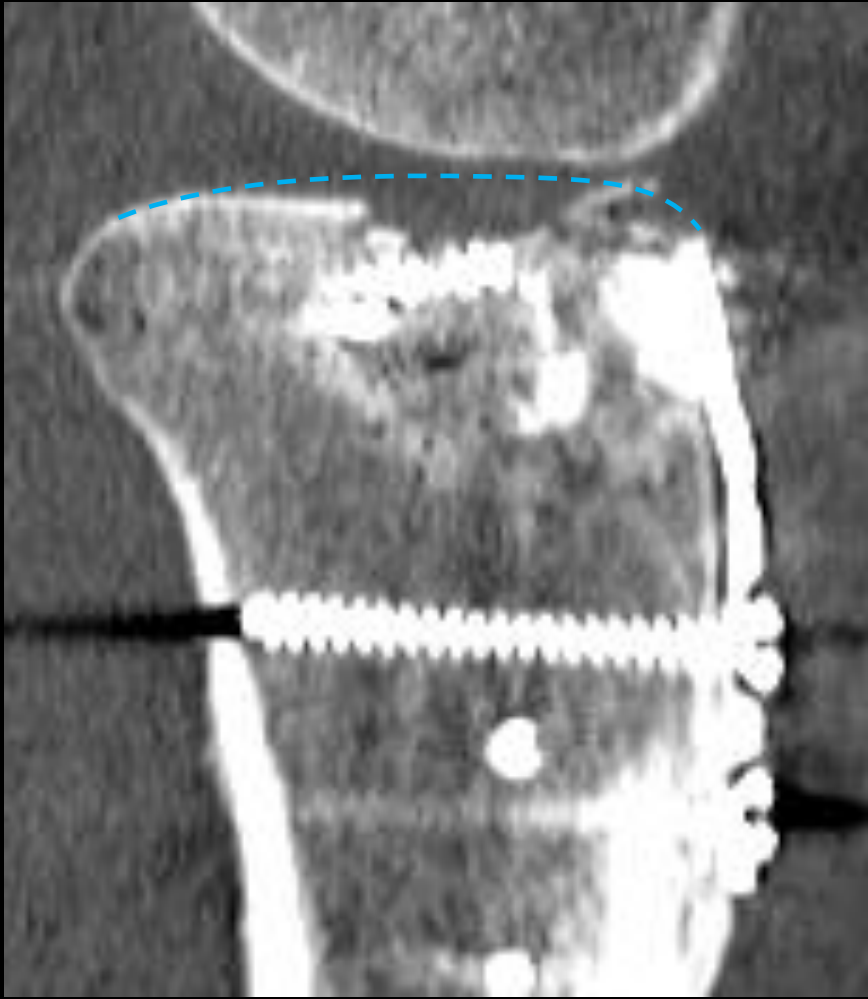
Running Centres:



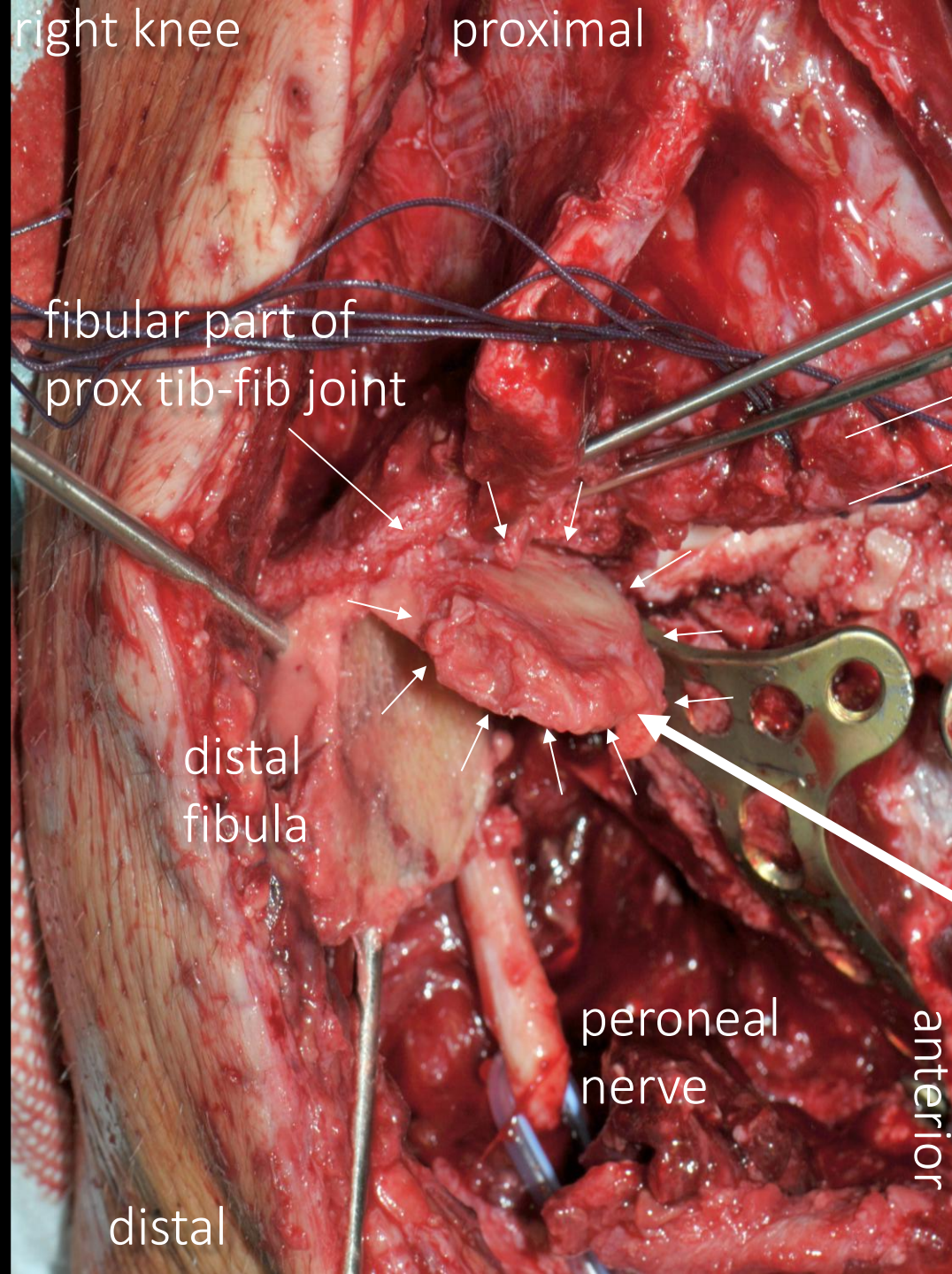
Q1: leave it or revise it?
Q2: Can we address the articular comminution?
Q3: How do we fill the defect?
Q4: Which approach?
Q5: prox tib-fib joint an option?



identify articular defect
identify articular depression
consider original jointline
(contralateral side)



osteo-chondral graft
from proximal
tibio-fibular joint



right knee

proximal

fibular part of
prox tib-fib joint

distal
fibula

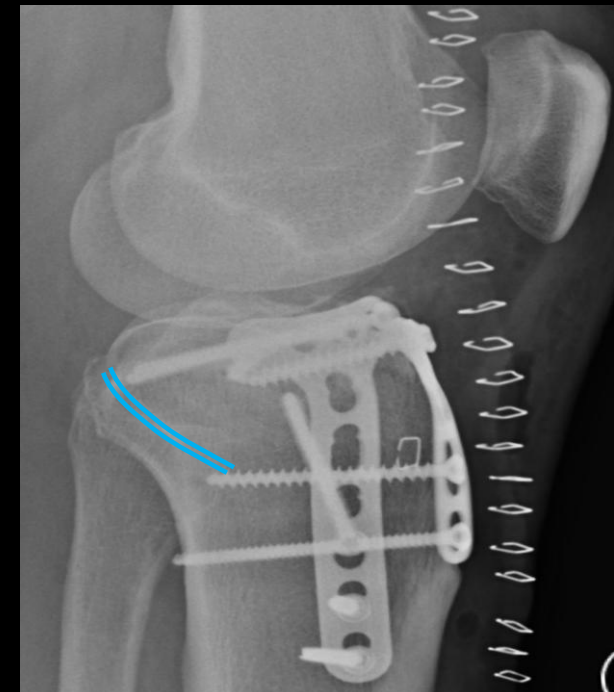
peroneal
nerve

anterior

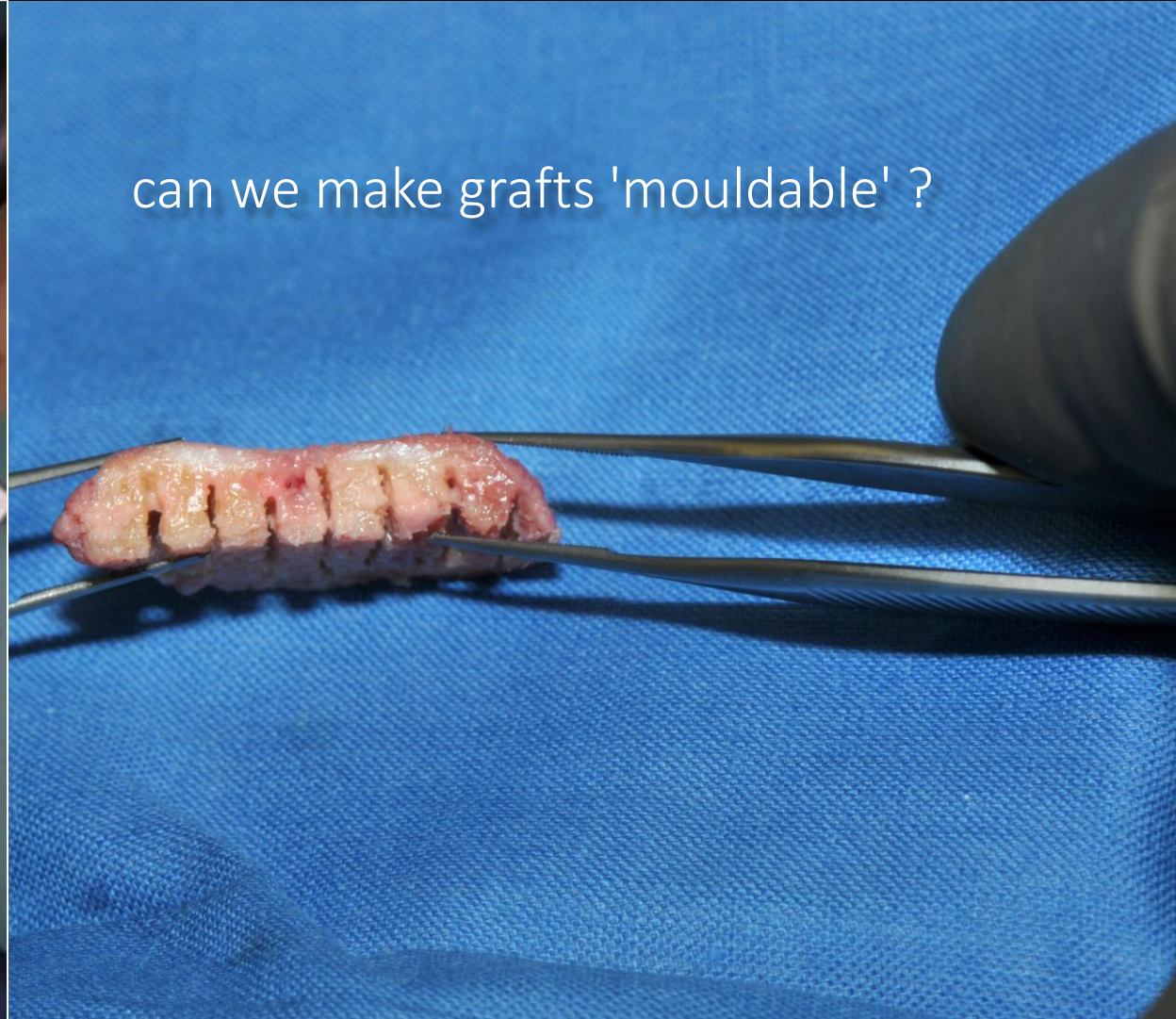distal

meniscus
articular surface tibia

osteo-chondral
graft

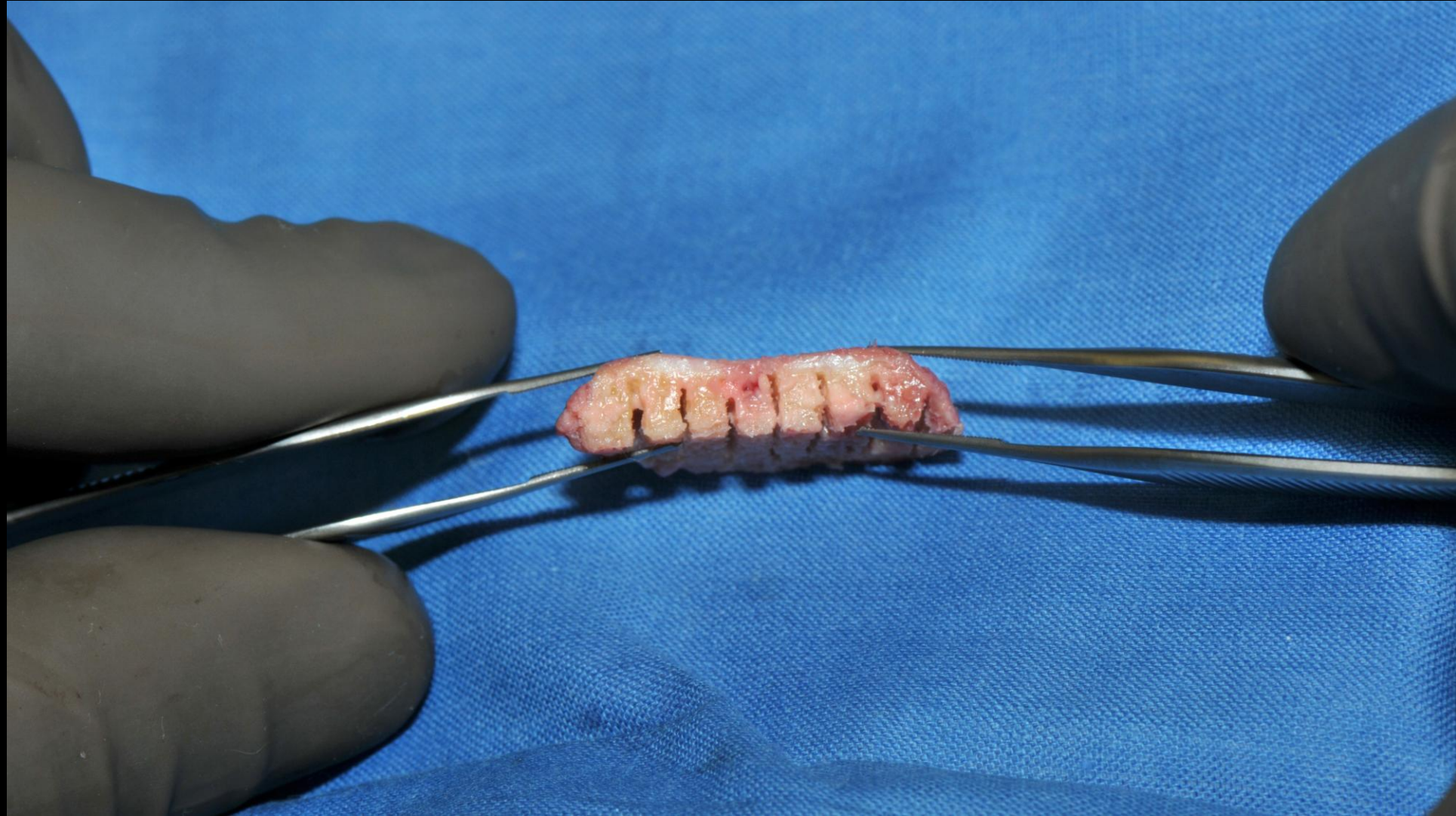


Osteo-chondral mango slice bending with multiple incomplete mini osteotomies

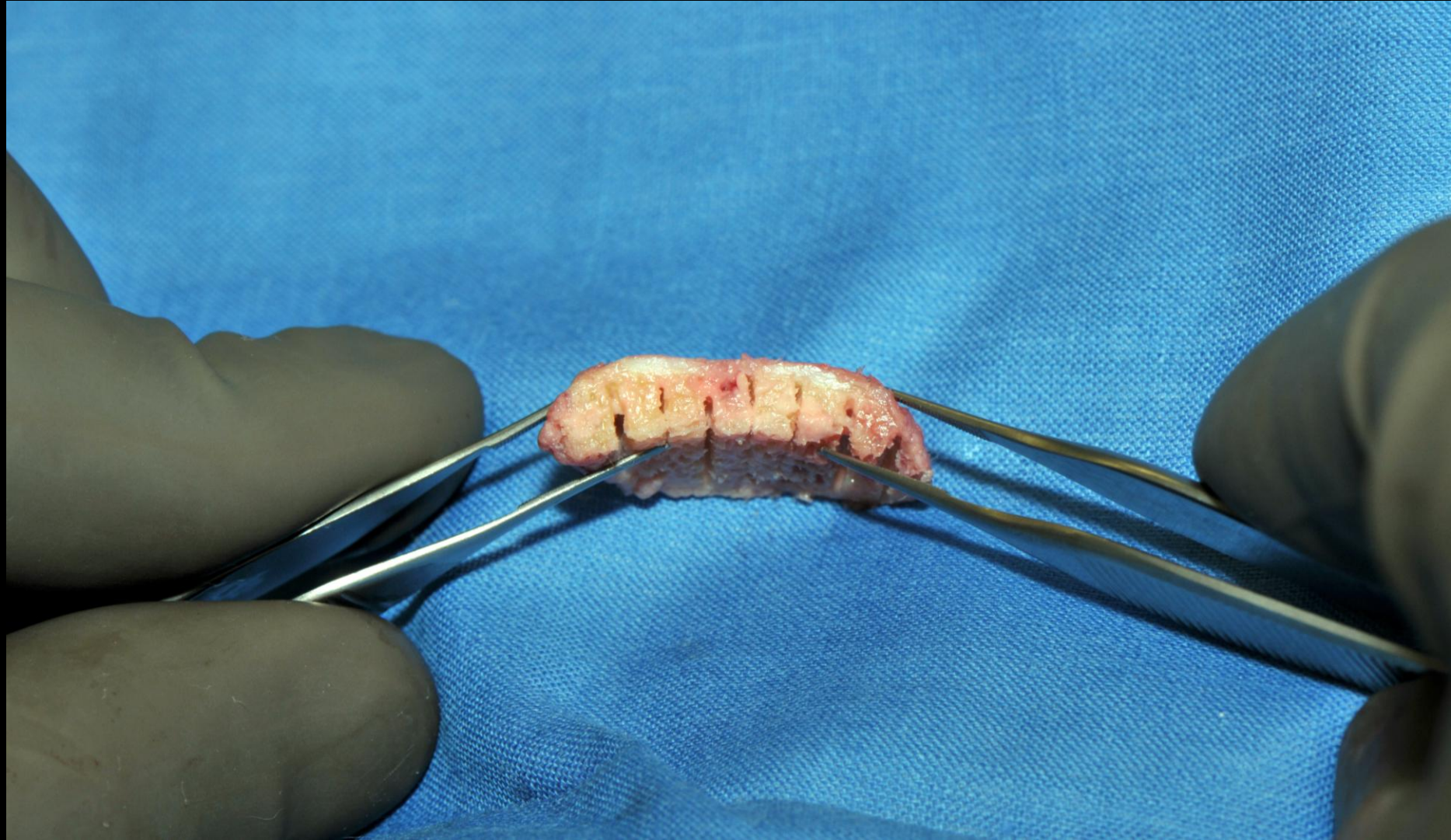

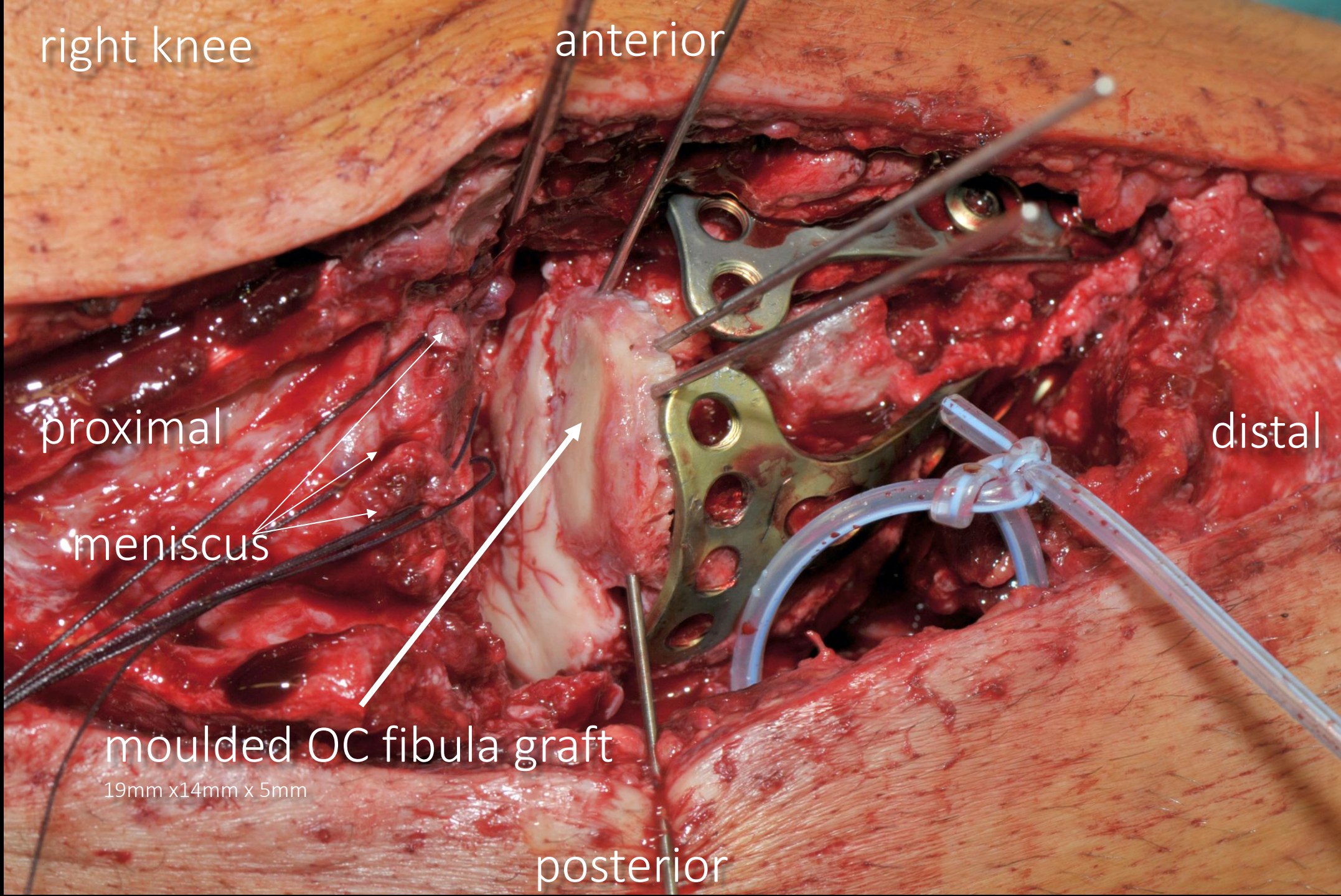
can we make grafts 'mouldable' ?

Osteo-chondral mango slice bending with multiple incomplete mini osteotomies



Osteo-chondral mango slice bending with multiple incomplete mini osteotomies





right knee

anterior

proximal

distal

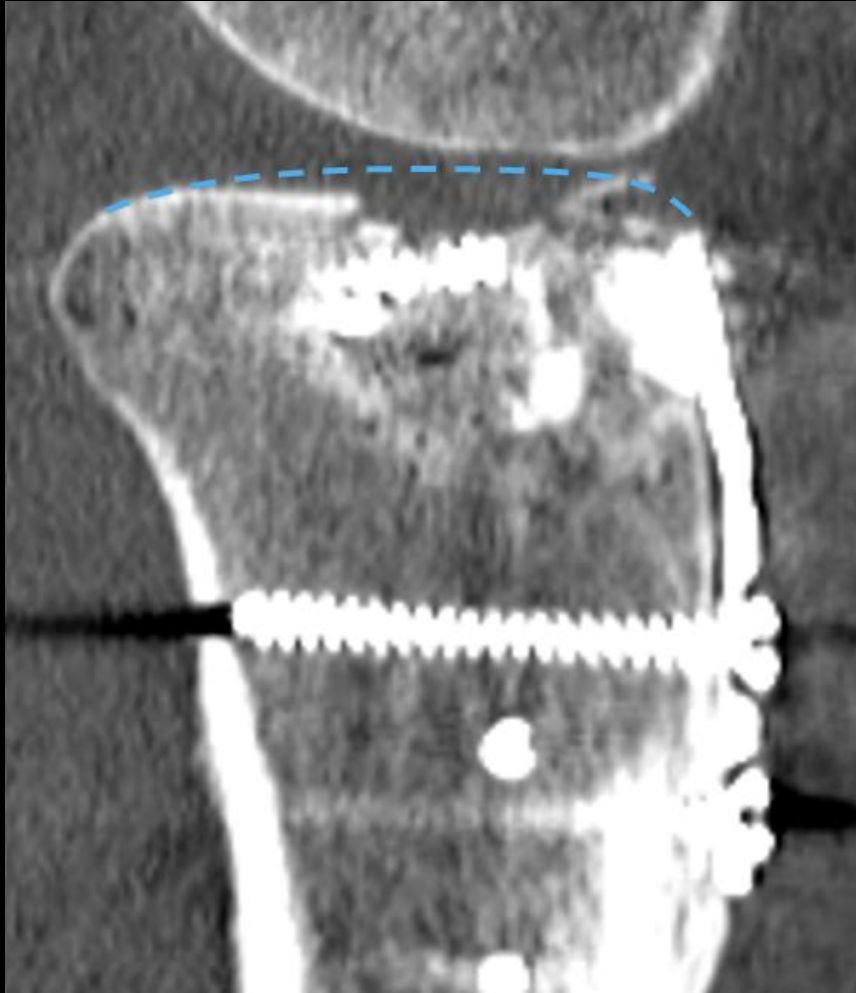
meniscus

moulded OC fibula graft

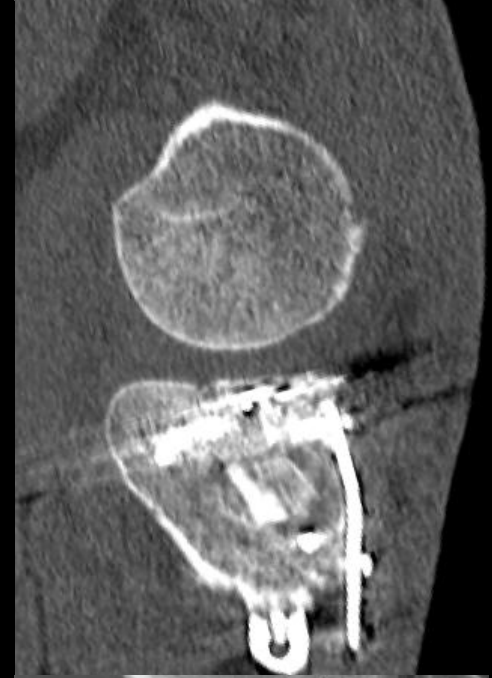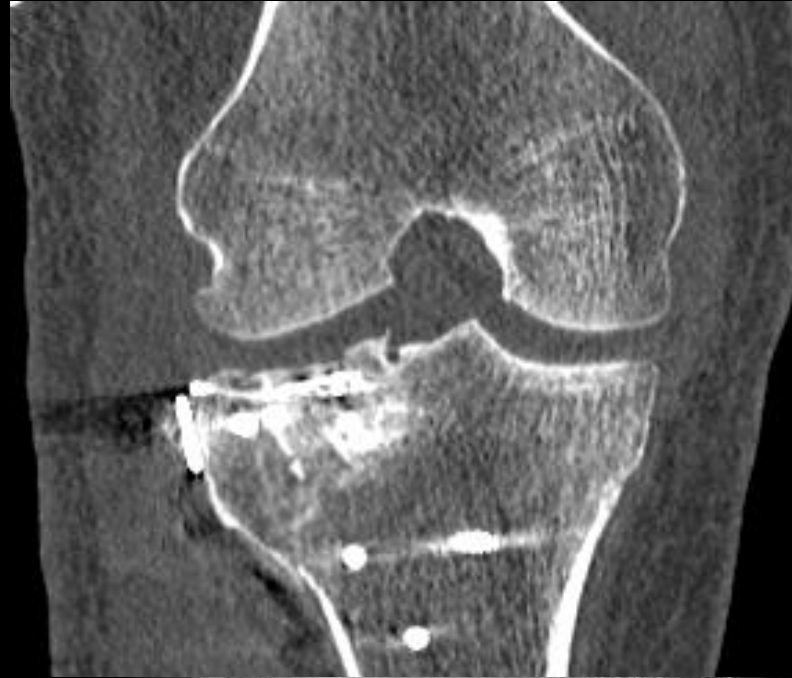19mm x 14mm x 5mm

posterior

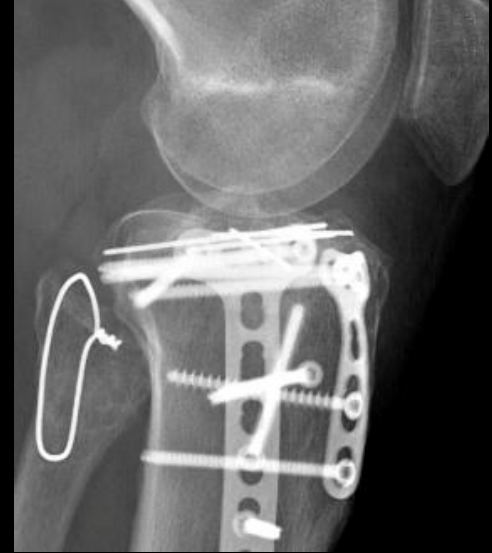
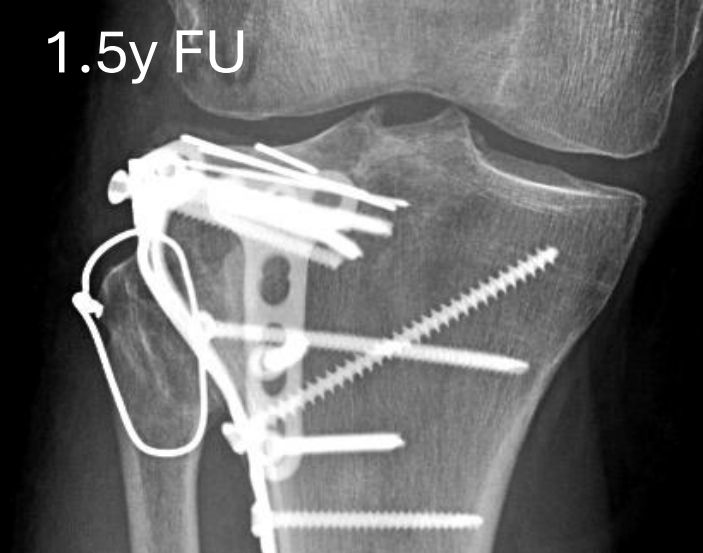pre-op



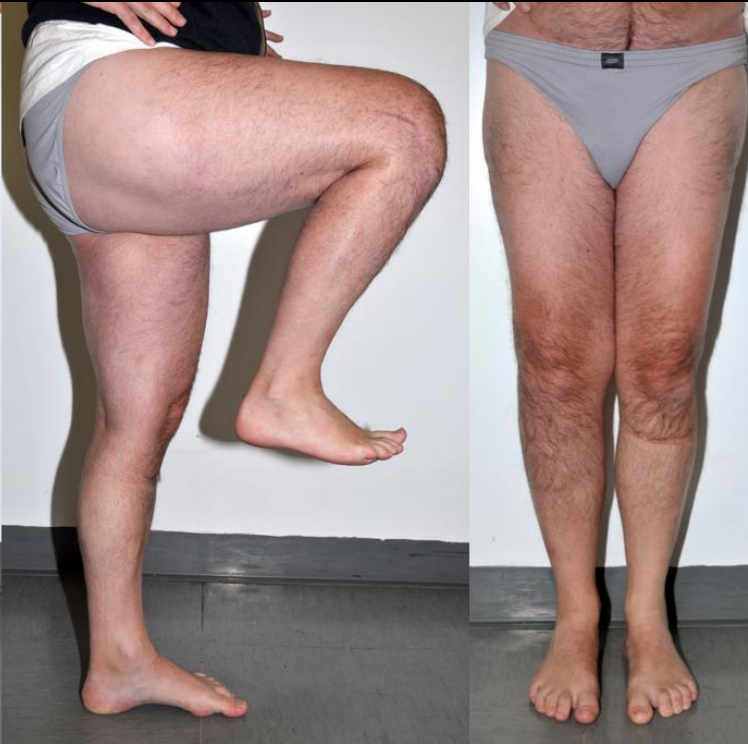post-op



1.5y FU

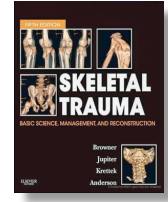
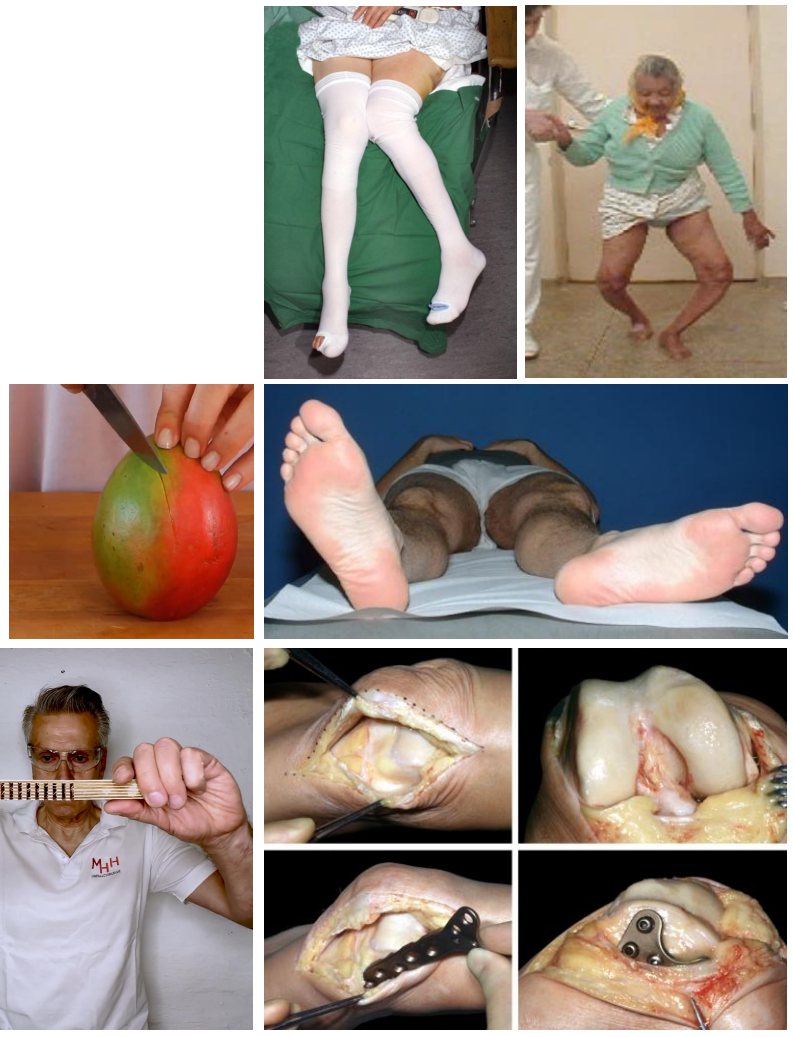

Uwe H, 52y
4y postop
Lysholm 96/100
EQ5D3L 15
Tegner Score 5



3 picks I learned in my Career

- **Intra-op alignment** ... use the simple geometry and symmetry concepts ... cable or stick, lesser troch etc.
- **Approaches** ... avoid additional harm ... not only on the paper
- **Learn from others** ... technology transfer ... Kerf Spacing, 3D printing, AI ...
- **If there is no good solution** ... develop a better one



Krettek C Fractures of the Distal Femur.
In: Skeletal Trauma.
Editors Browner BD, Jupiter JB, Krettek C, Anderson P
5th ed: Saunders Elsevier; 2015

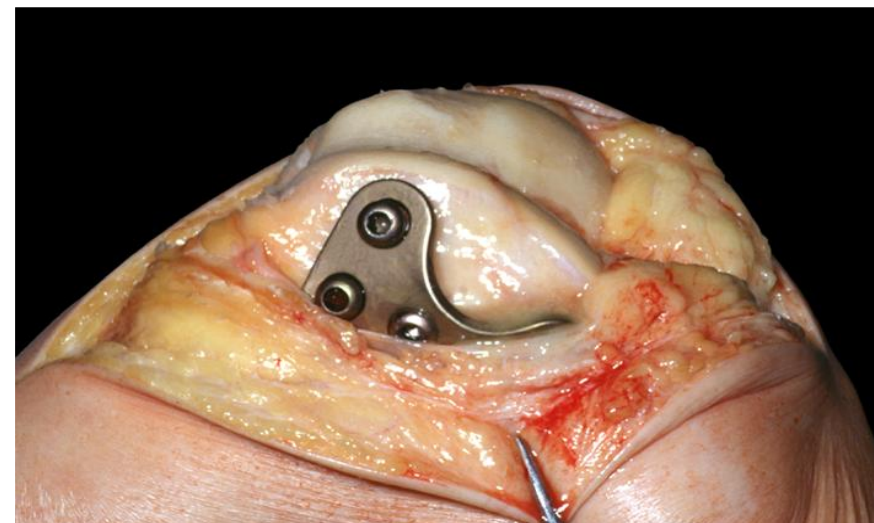
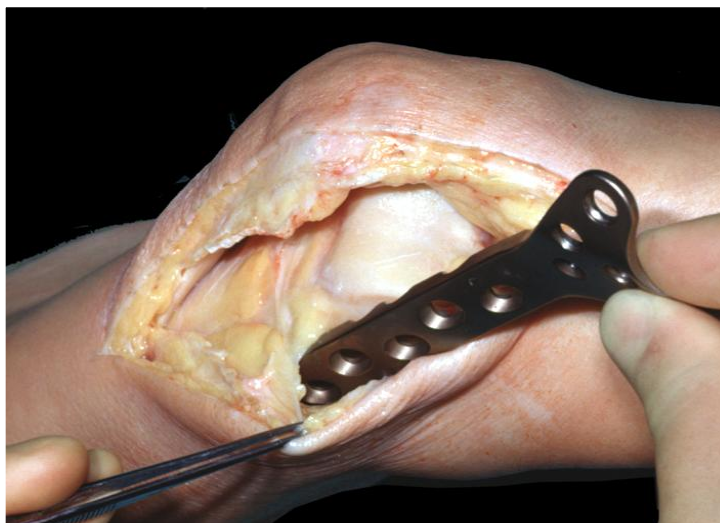
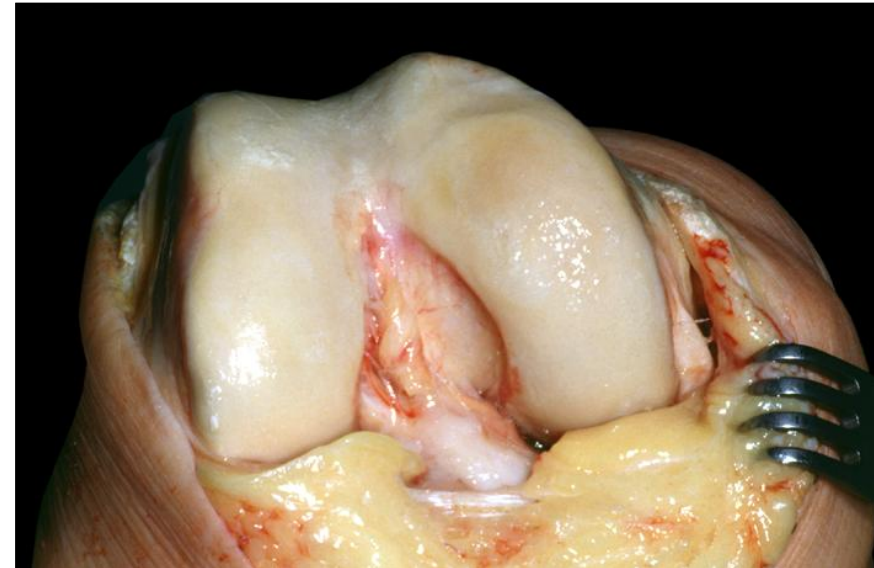
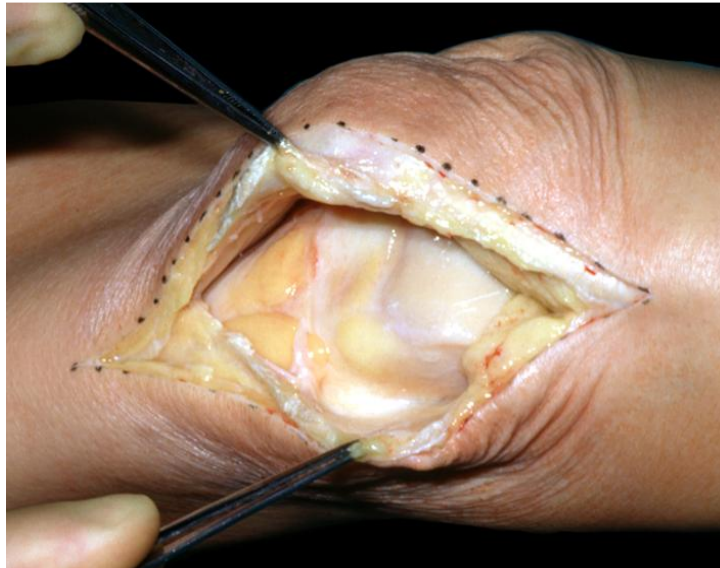

new approach: TARPO

Transarticular approach & retrograde Plate Osteosynthesis

W: why not
approaching it
in a way that
addresses both
...
articular
visibility
&
soft tissue
preservation?



Plan your operation ... operate your plan

- write it down, step by step
Planning is not a sign of weakness
- nothing is so simple that it isn't worth thinking about it
... where do I stand ...?
... which side is the image intensifier
... develop plansegments A, B ... or C if there are problems
- share your plan with you team
- used power point, had it on an I-Pad ...
opportunity to re-check

- Beispiel 3D Print Korrektur

Decision Matrix

- Define your targets (include patient & relatives)
 - Collect Options including the non obvious or strange ones
 - Make a table with pro's, con's and likely outcome
 - Share & discuss it with patient and team
-
- Beispiel Rotationplasty

Preserve what you have

- and avoid harm as much as possible zB vertebral body Melbourne in distal Tibia, amputated limb ... take bone, skin graft,
- Beispiel Schweikler
Moments where entire Orthopaedic Literature doesn't help you

Use the Symmetry concept of nature

- Use thy symmetry concept of nature:
copy the other side
clinical
radiographical
physical

length, rotation, lesser troch shape, ante- or recurvatum

Example physically check overextension on the contralateral side

Intramedullary Nailing starts with positioning

- Operation starts with positioning
positioning limits ... draping ...
draping limits soft tissue approach
soft tissue approach limits starting point
starting point defines alignment

Get exposed and actively train the use of
Technologies like 3D imaging, 3D print, smart
implants and AI

- “Most disability that occurs following a fracture is related to the treatment and not to the pathology.”
- “I believe prolonged immobilization is harmful. The patient should be encouraged to move his diseased joints in spite of pain and discomfort”



G. Perkins. Rest and Movement. JBJS(B), 1953

Sammlung

1. Complications force you to back to reality better decisions
2. Very carefully plan your surgical approach in MIPO
Optimize approach for reduction not for implant placement
3. In everything bad is something good ... try to find it out
4. Use the power of nature ... tested in the last 200 Mio years
tissue wants to heal
5. Get exposed and actively train the use of Technologies like
3D imaging, 3D print, smart implants and AI

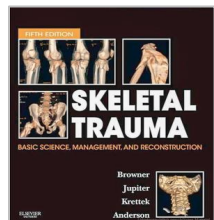
Knee and Tibia: The Top Tips and Tricks I Learned in My Career

- We cannot change the patient and the trauma ... but we can change the soft tissue management



G. Perkins. Rest and Movement. JBJS(B), 1953

“...Most disability that occurs following a fracture is related to the treatment and not to the pathology.”



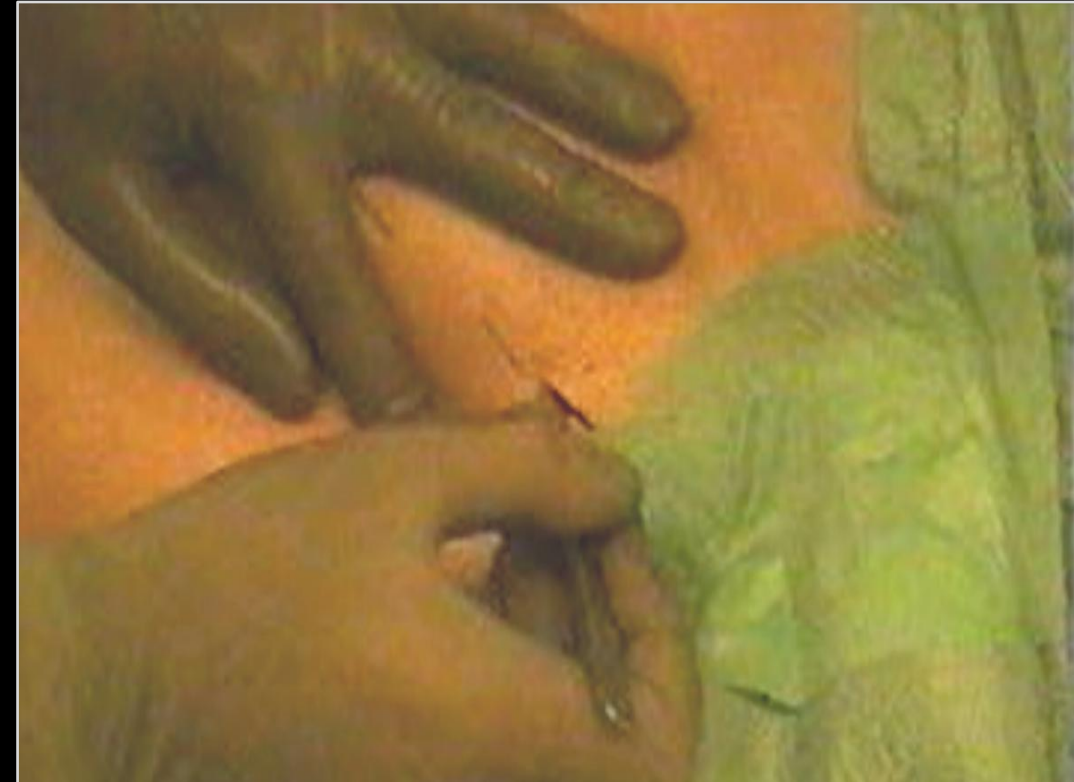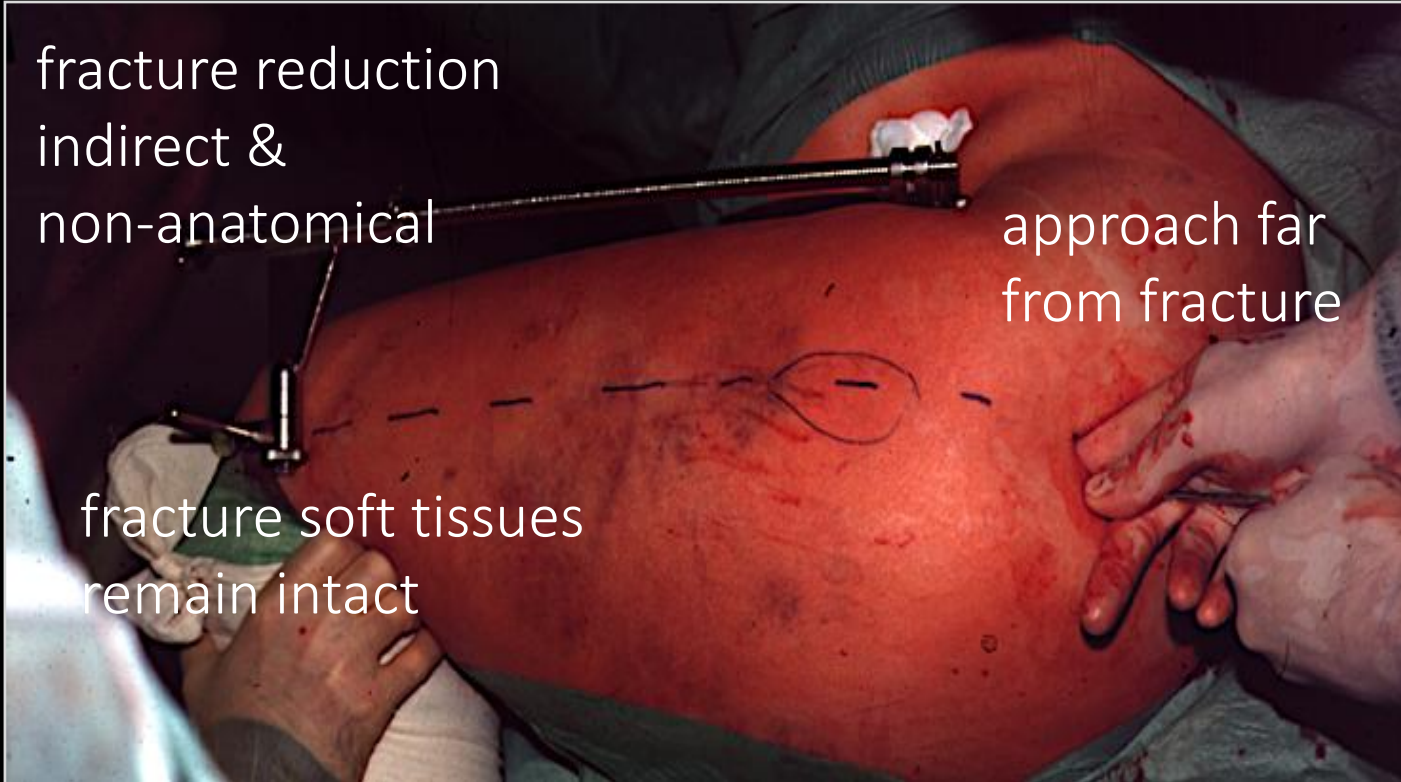
Approach for Nailing ...

example: femoral shaft fracture

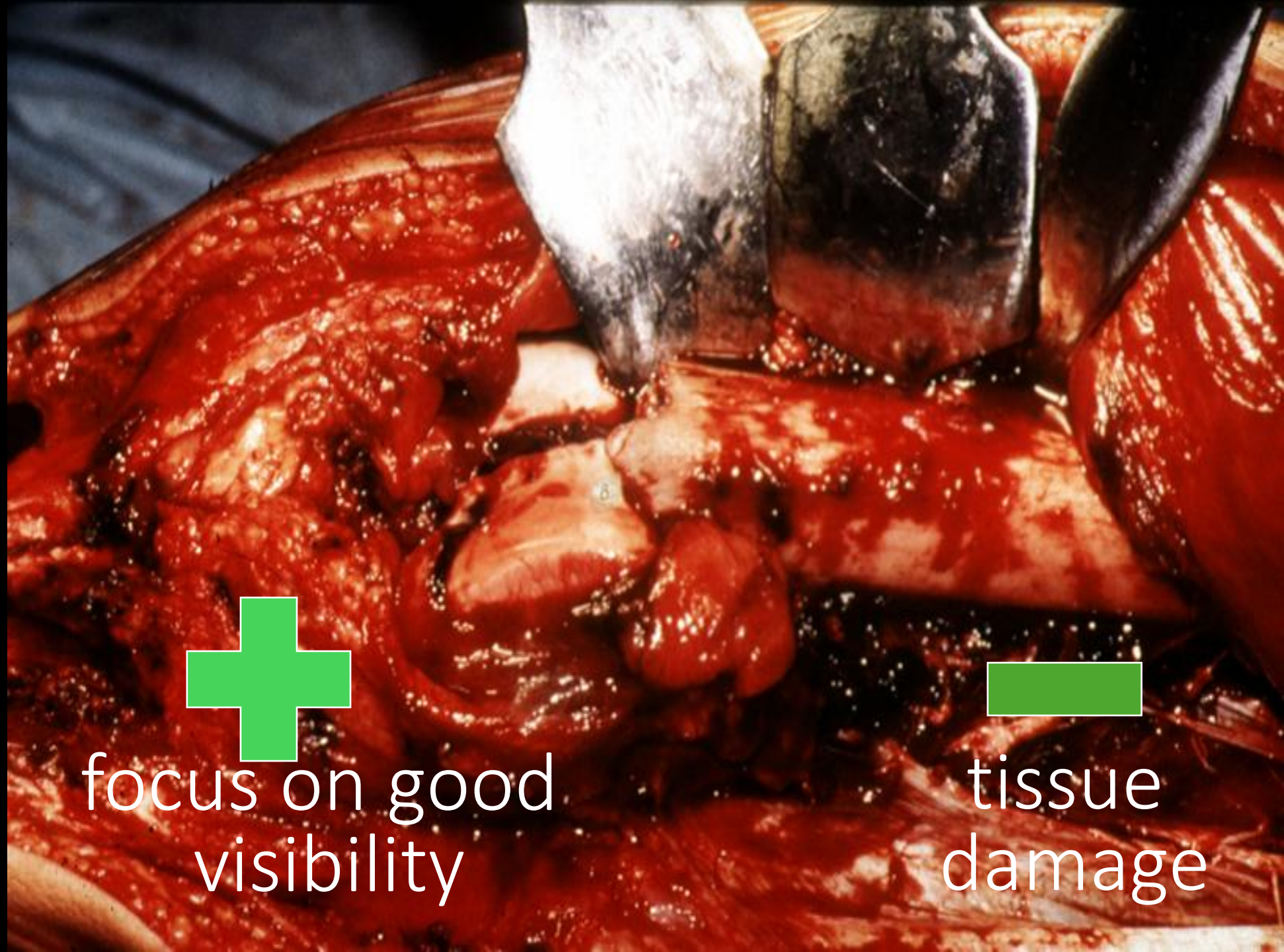
fracture reduction
indirect &
non-anatomical

approach far
from fracture


fracture soft tissues
remain intact



Conflict

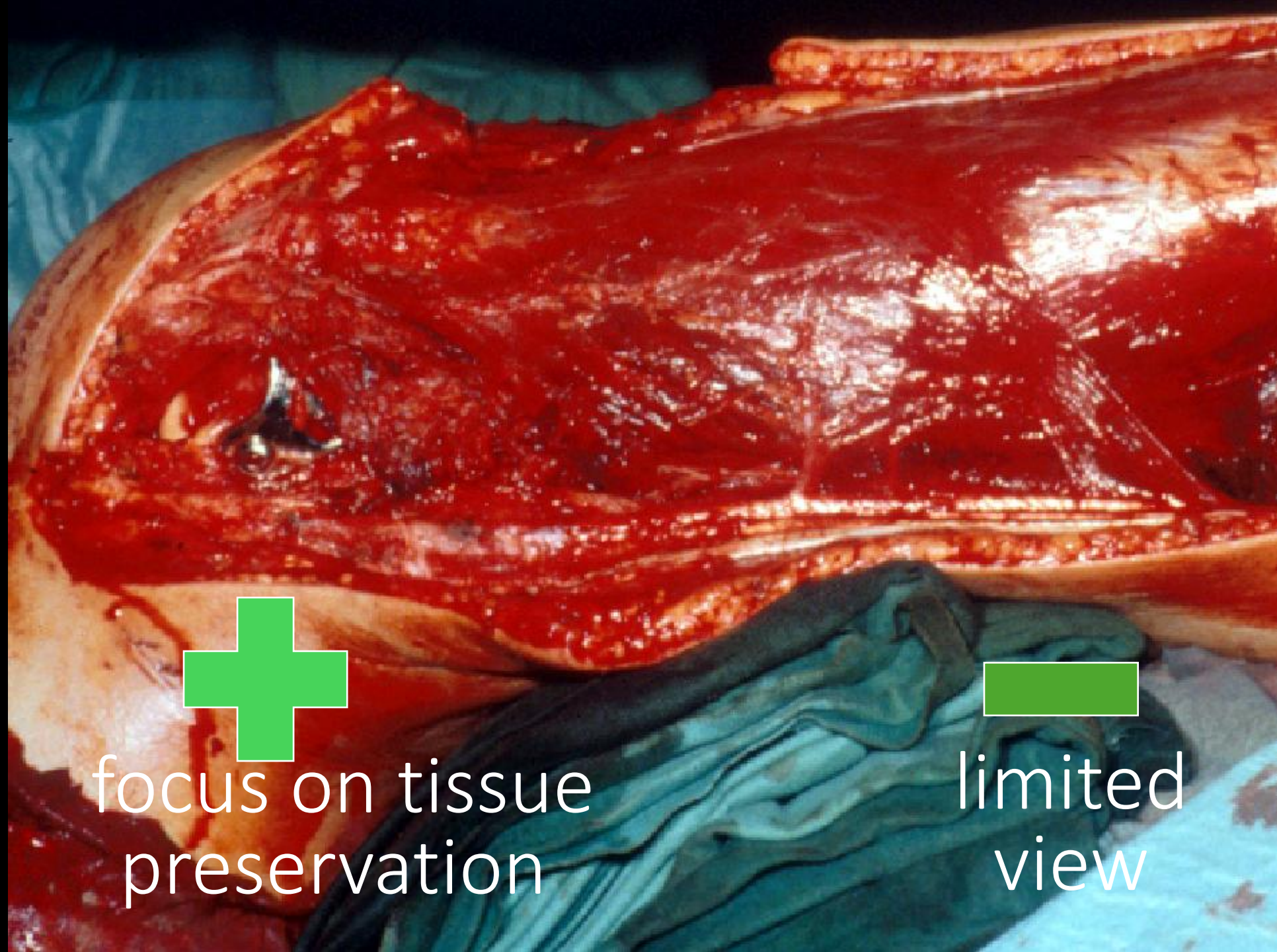


focus on good
visibility



tissue
damage

Conflict



+

focus on tissue
preservation


▬

limited
view


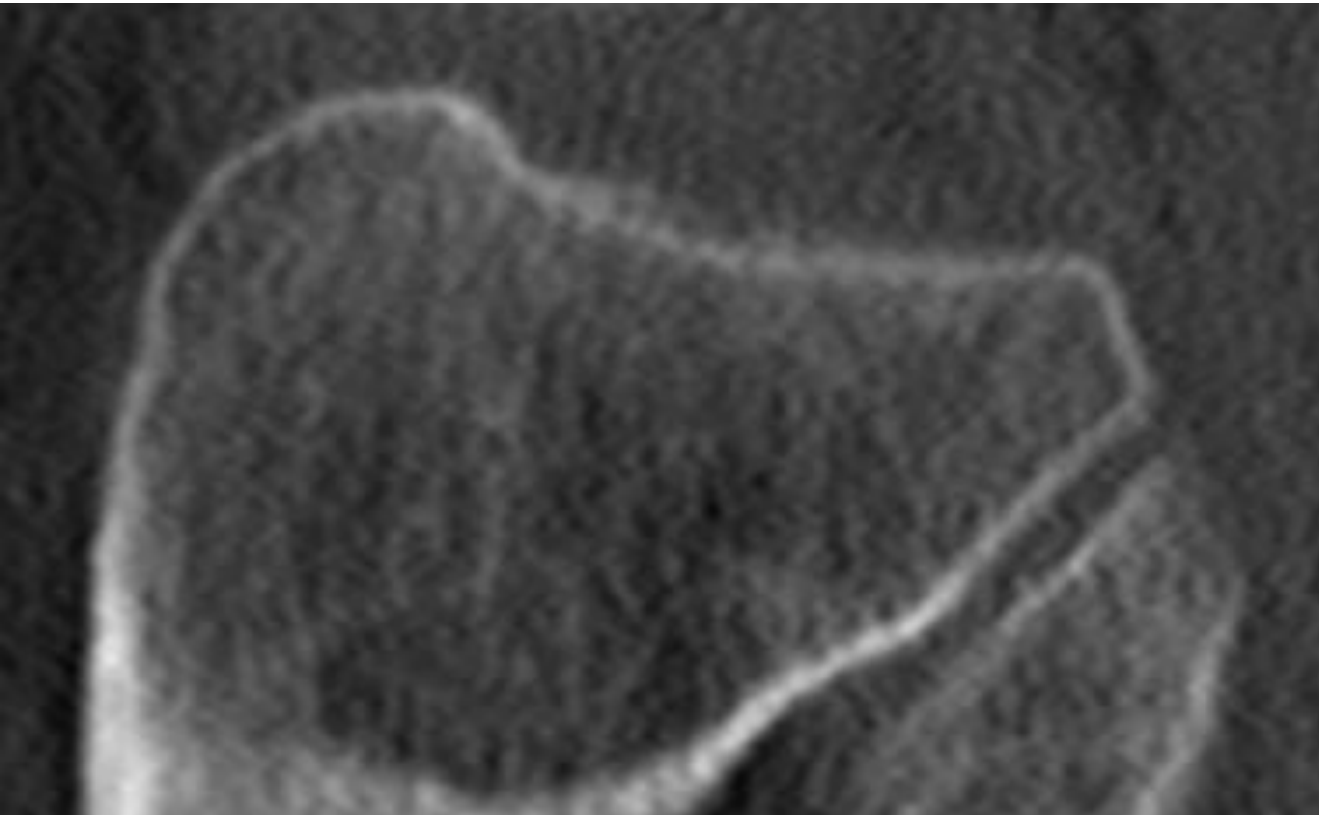
Can this principle be applied to articular bone ?

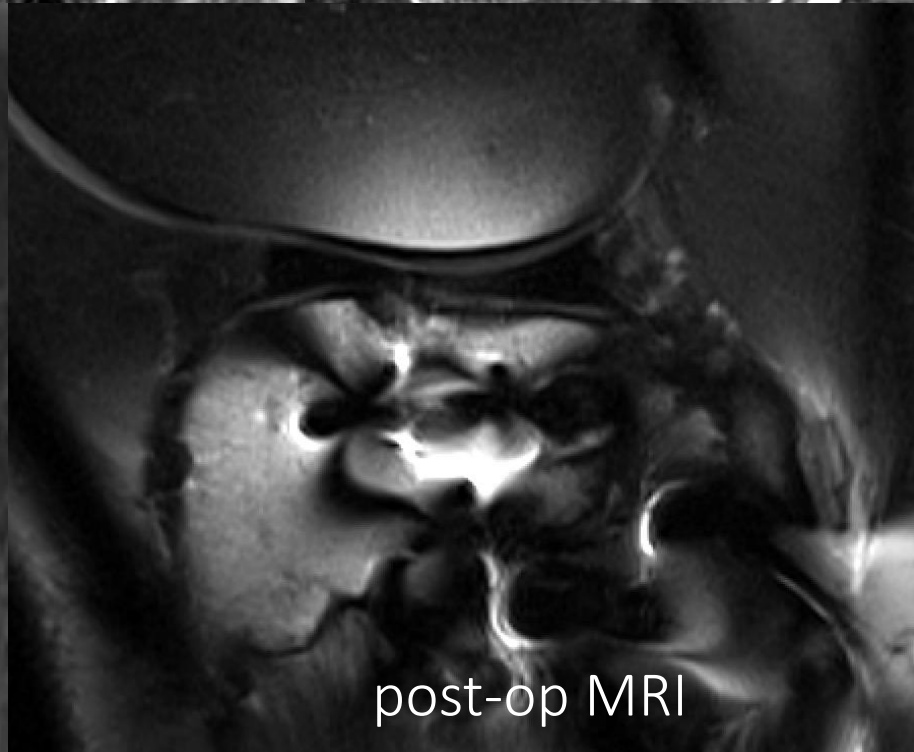
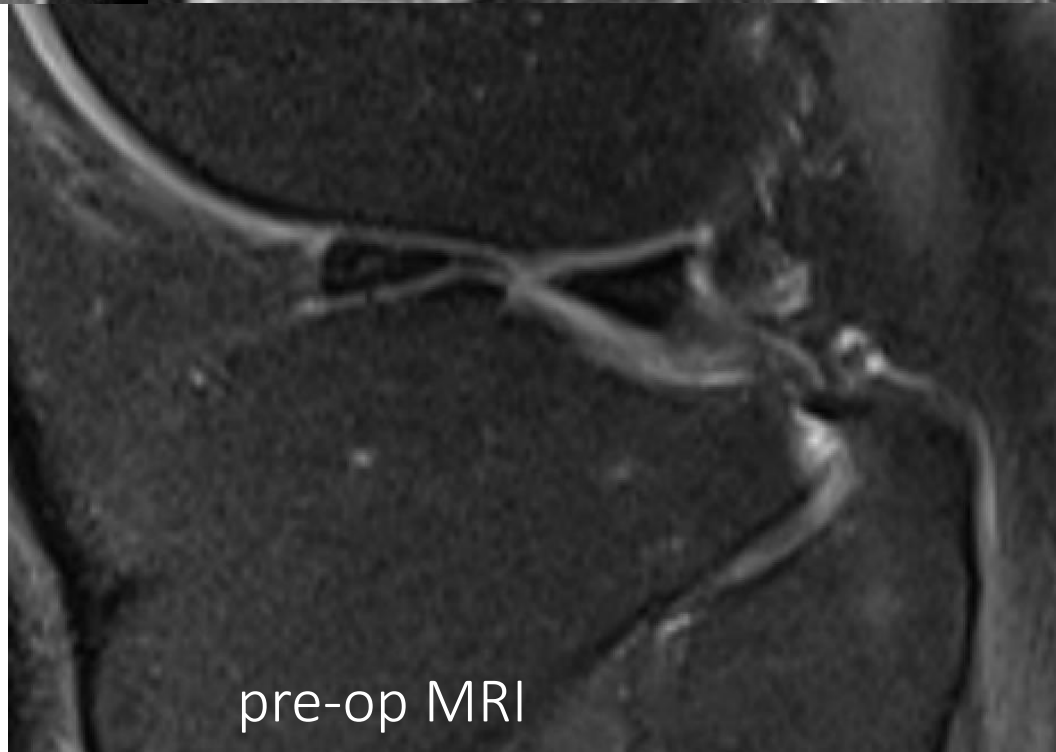
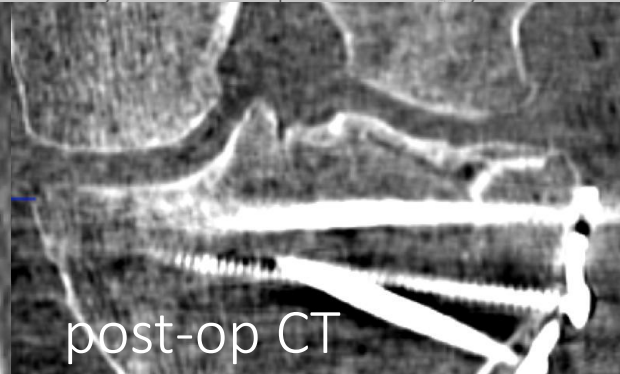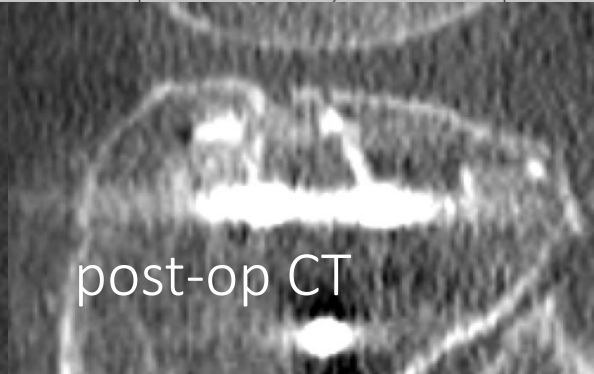
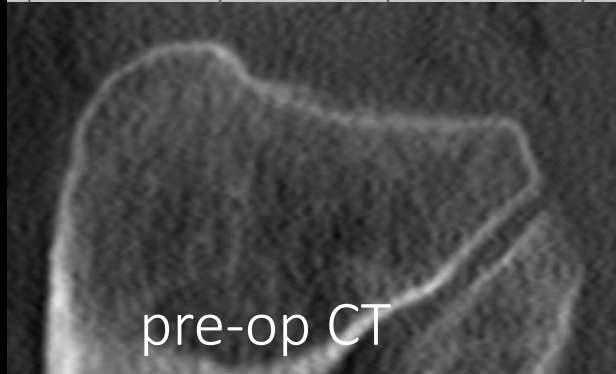
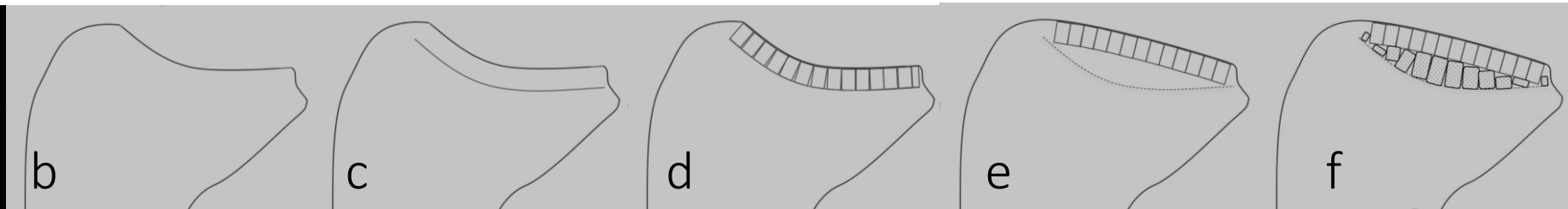
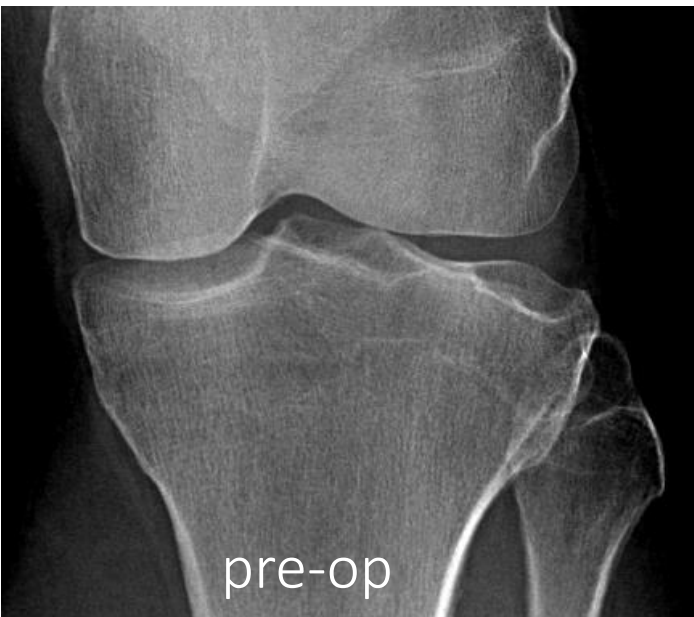Osteo-Chondral mango slice bending

- special cutting technique
- reciprocating saw
- multiple coherent segments

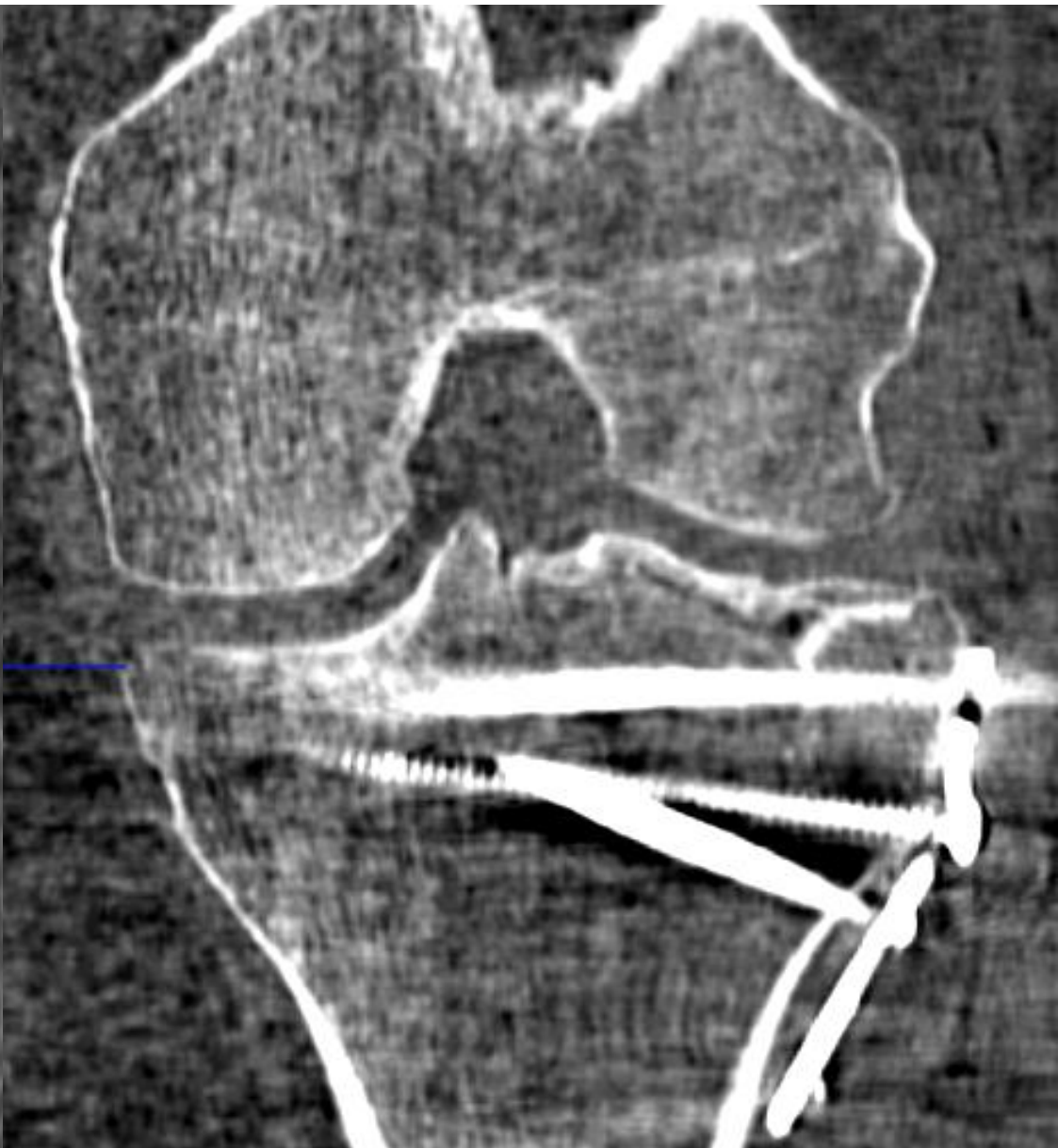
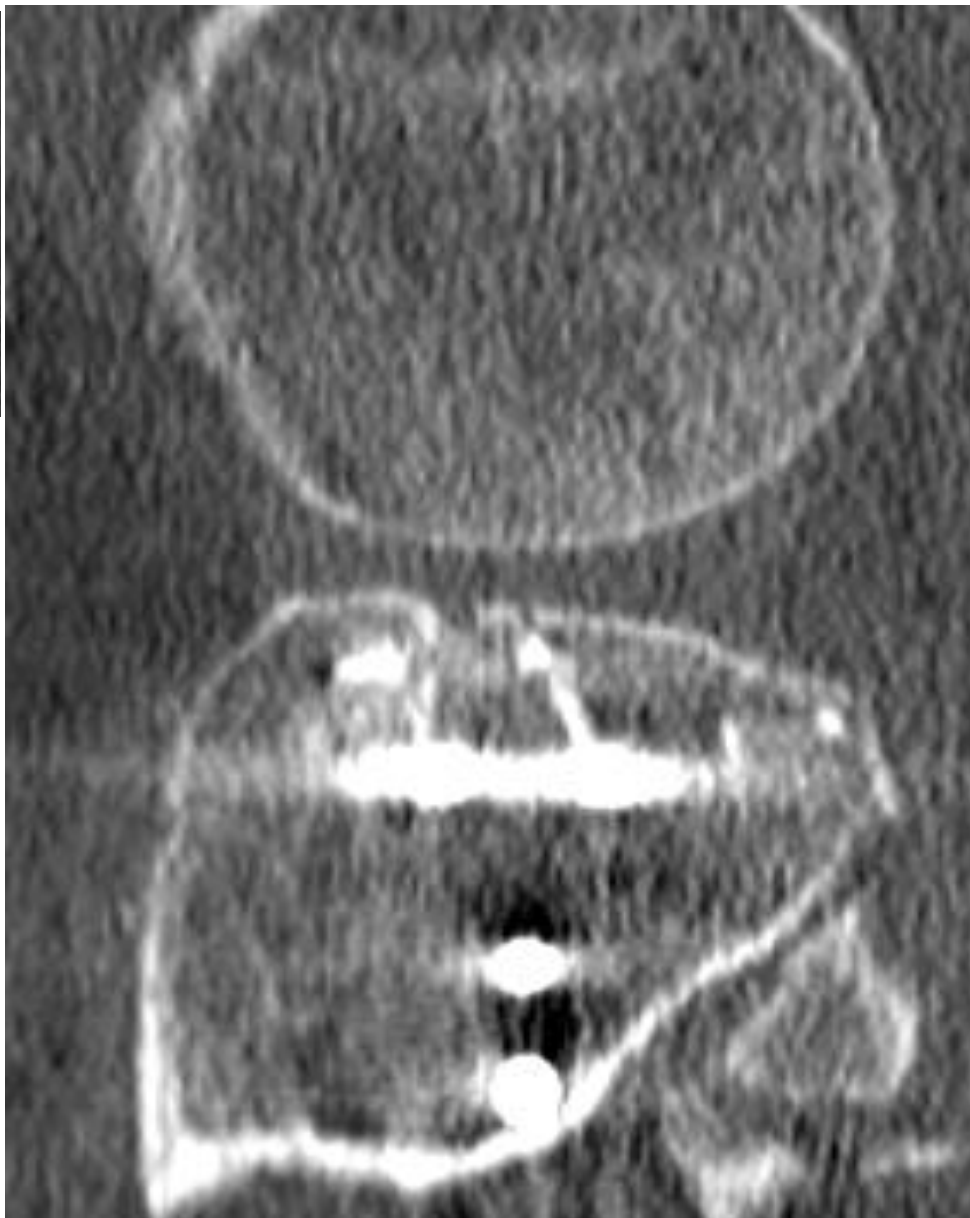
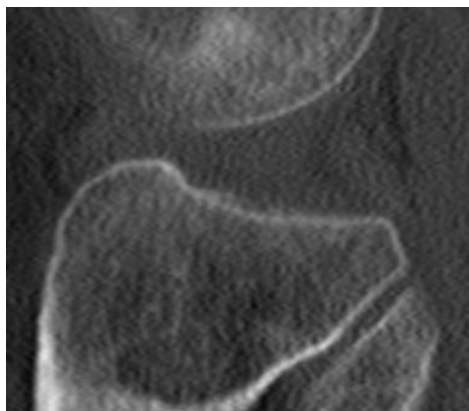


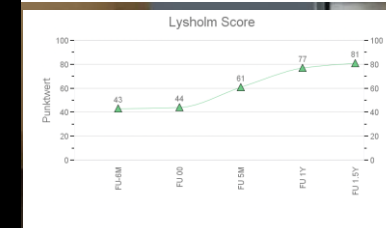
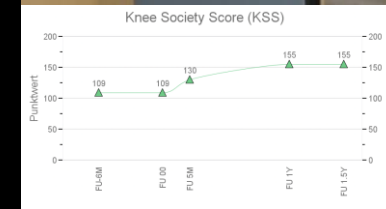
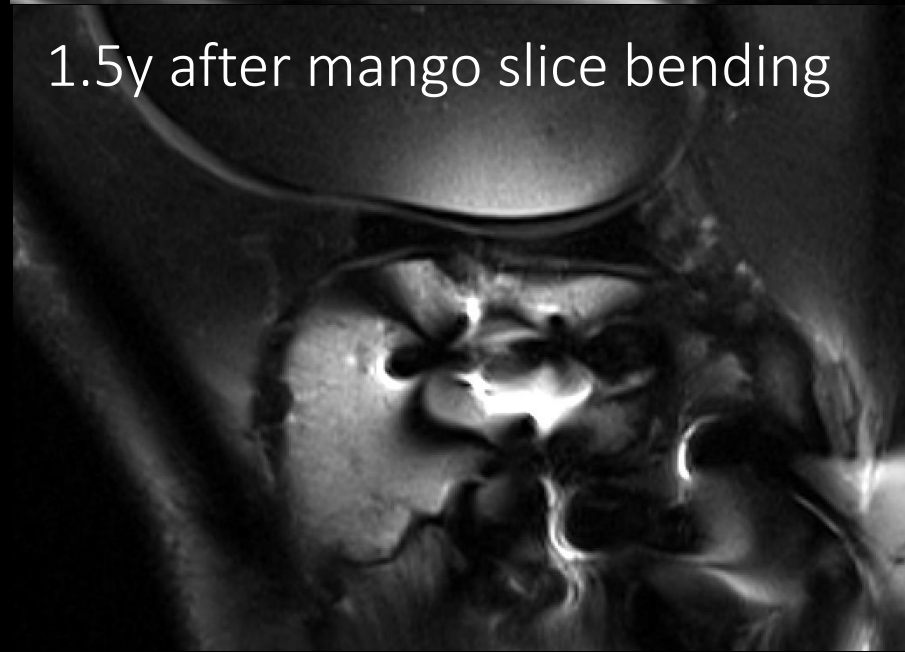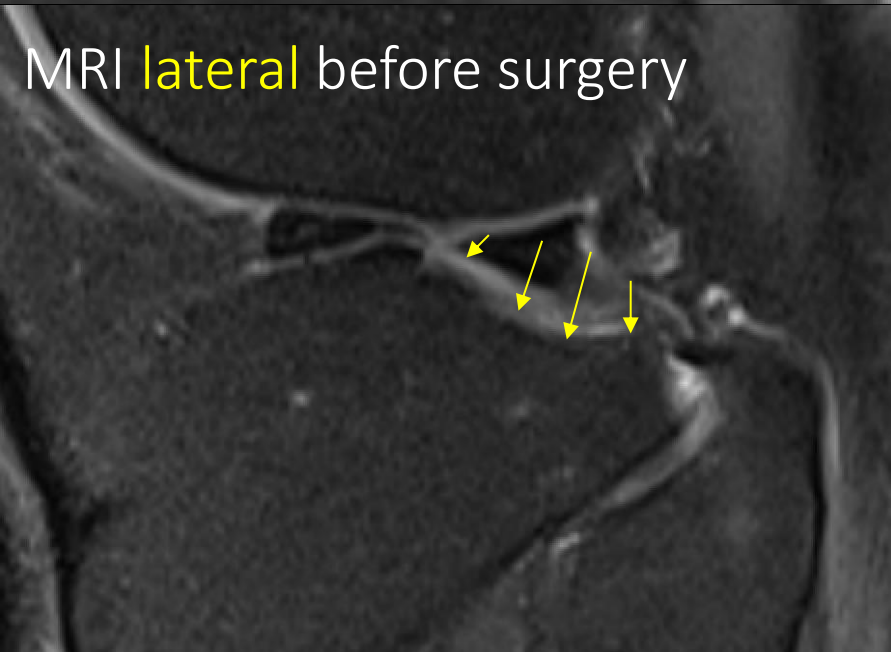
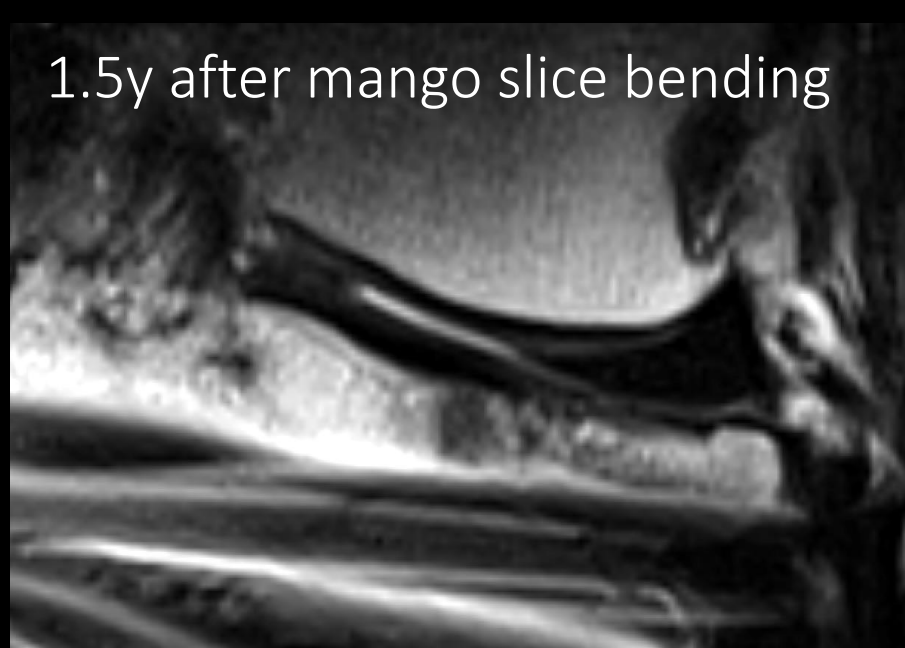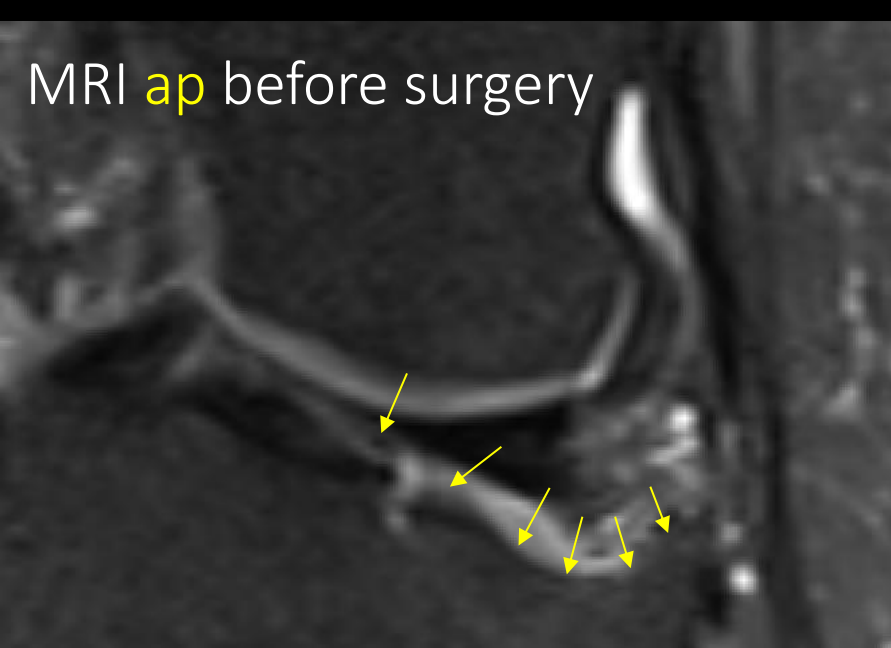
reciprocating saw





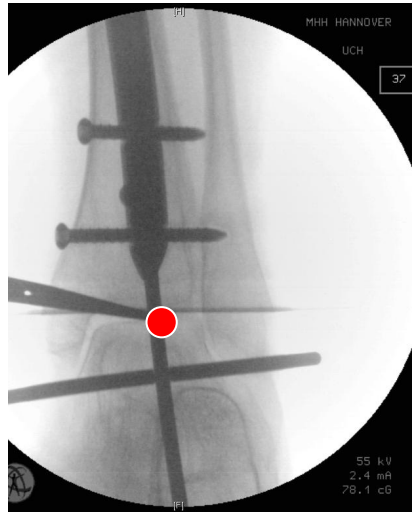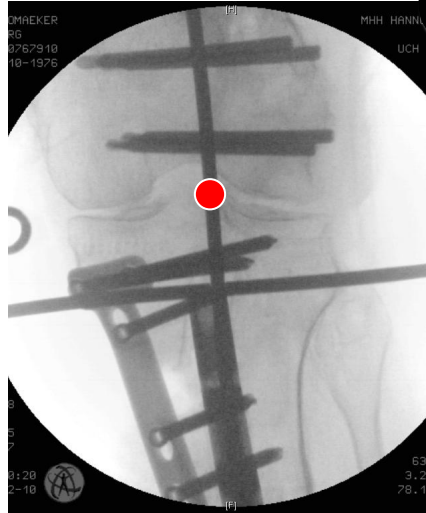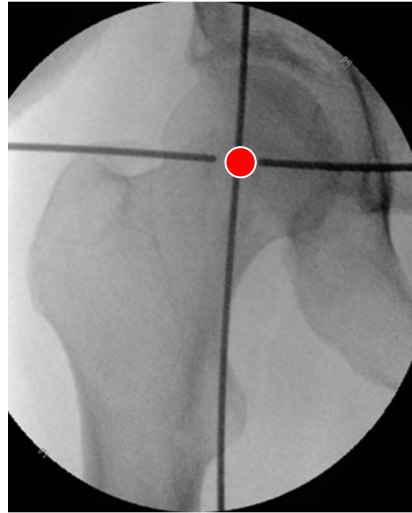
Jaqueline Z 50y





How is this applicable to the acute trauma situation?

Frontal plane alignment Alignment Grid (posterior)



underneath patient
underneath padding

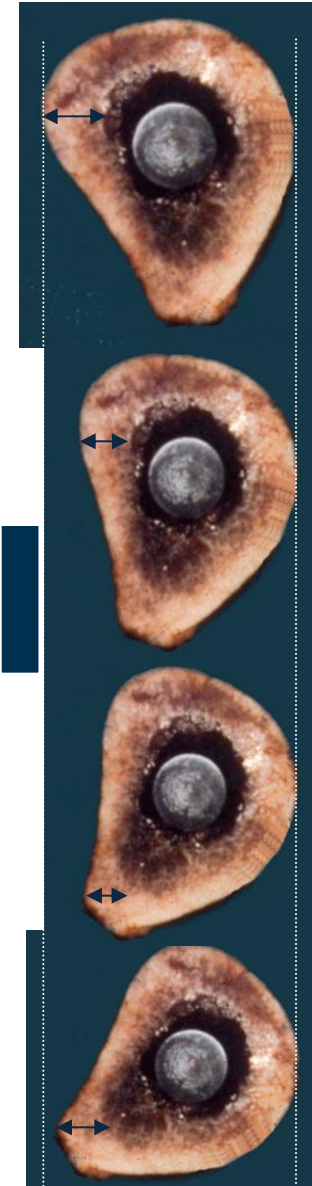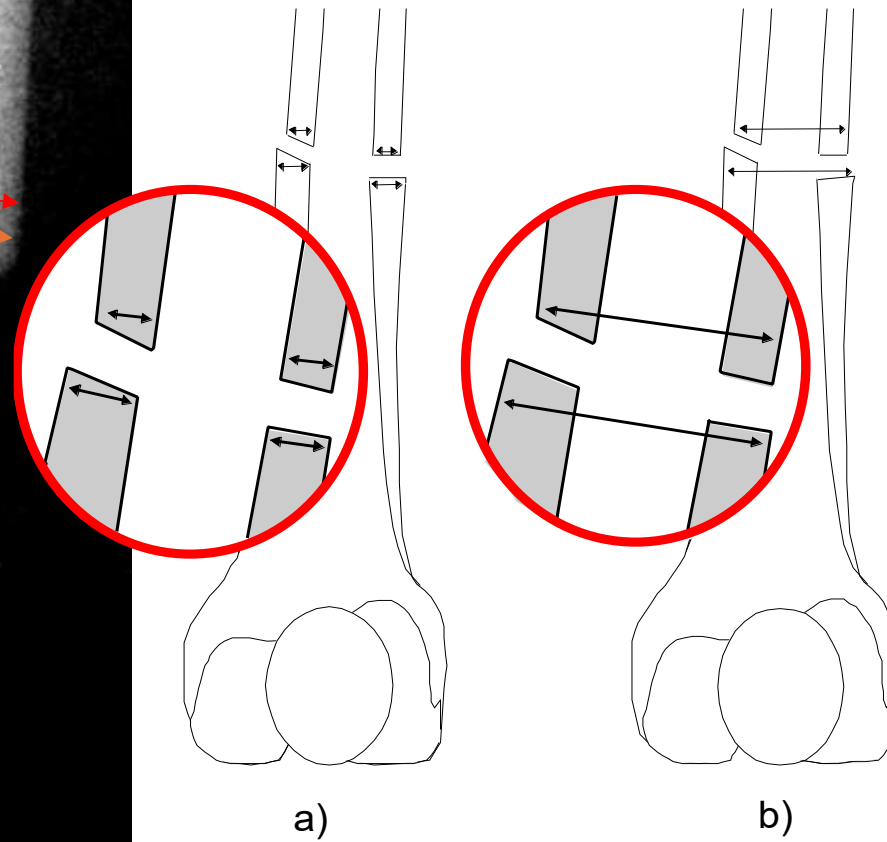
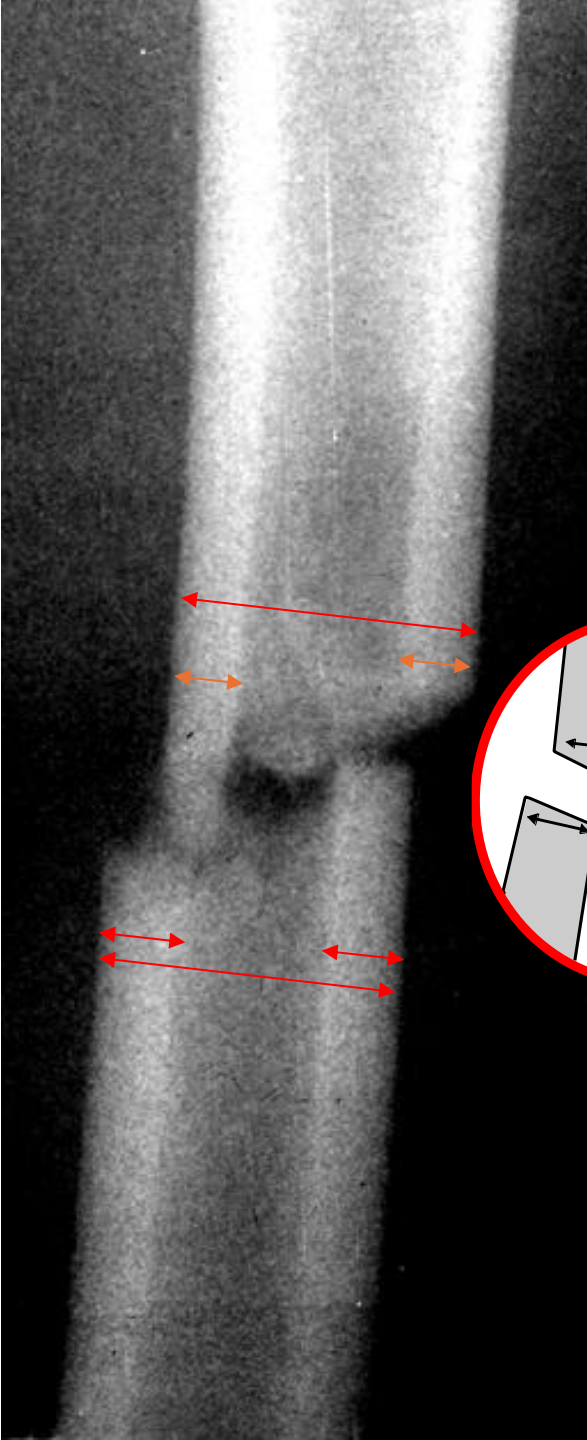
- good precision
(close to navigation)
- cheap
- flexible

disadvantage

- radiation exposure
- only 2D

Liodakis E, Tech Health Care 2010
Krettek C, Injury 1999

Cortical step sign & Diameter difference sign



Q1 How to make something rigid like hard wood
... flexible like a multisegment toy fish?



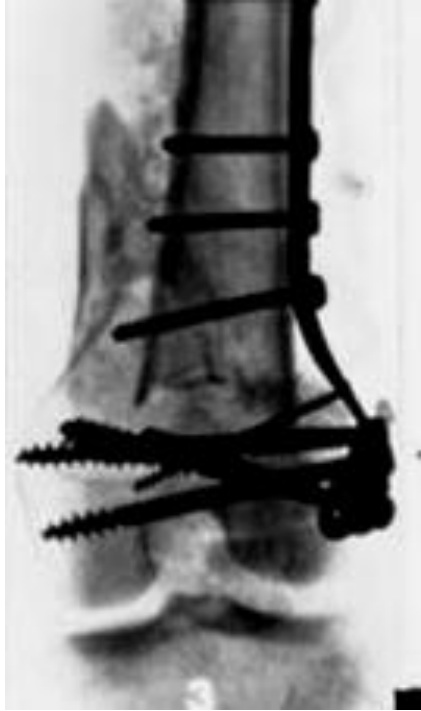Q2 How to transform
concave ... to convex ?



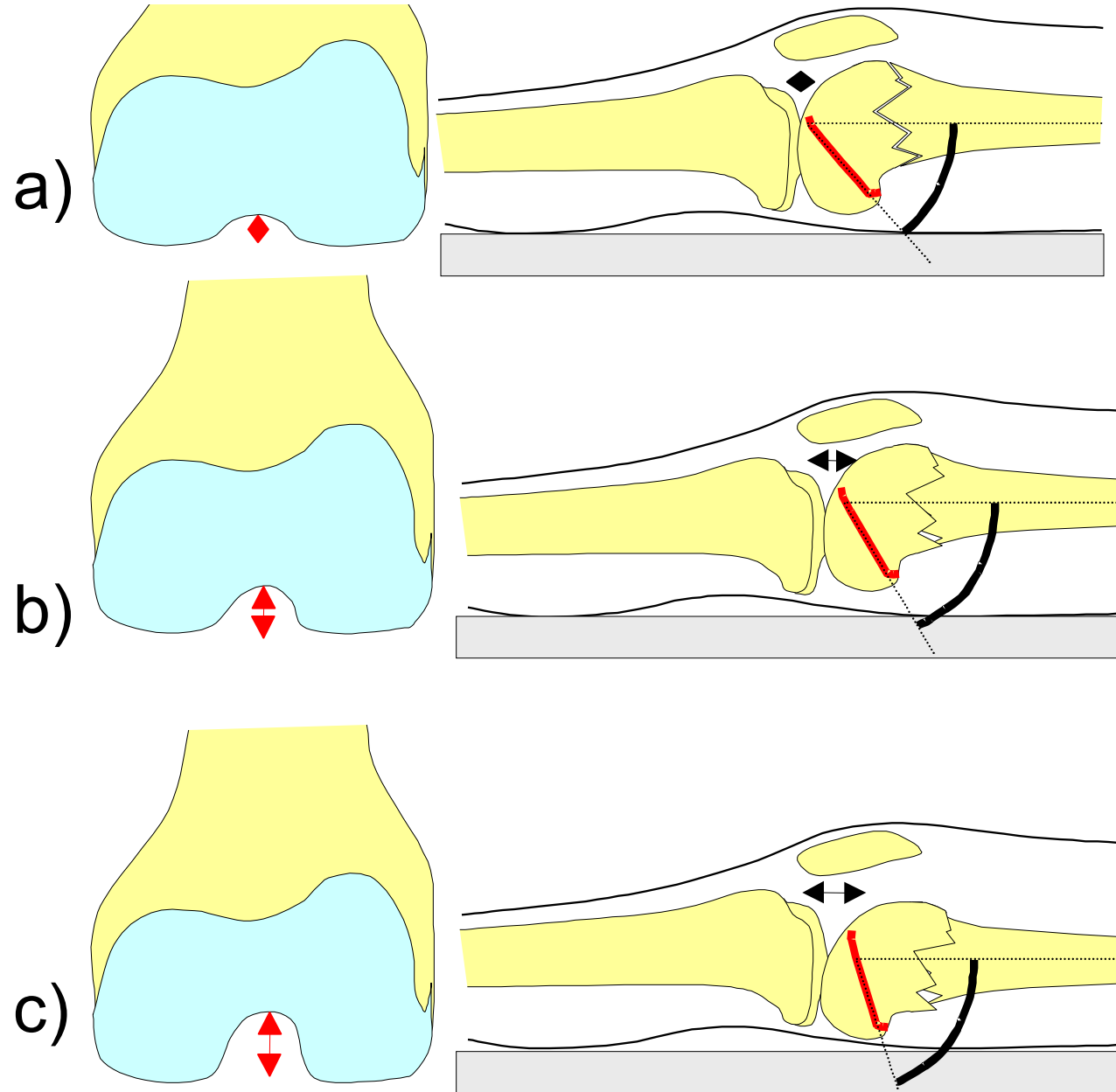
Q1 How to make something rigid like hard wood
... flexible like a multisegment toy fish?



genu recurvatum: notch sign

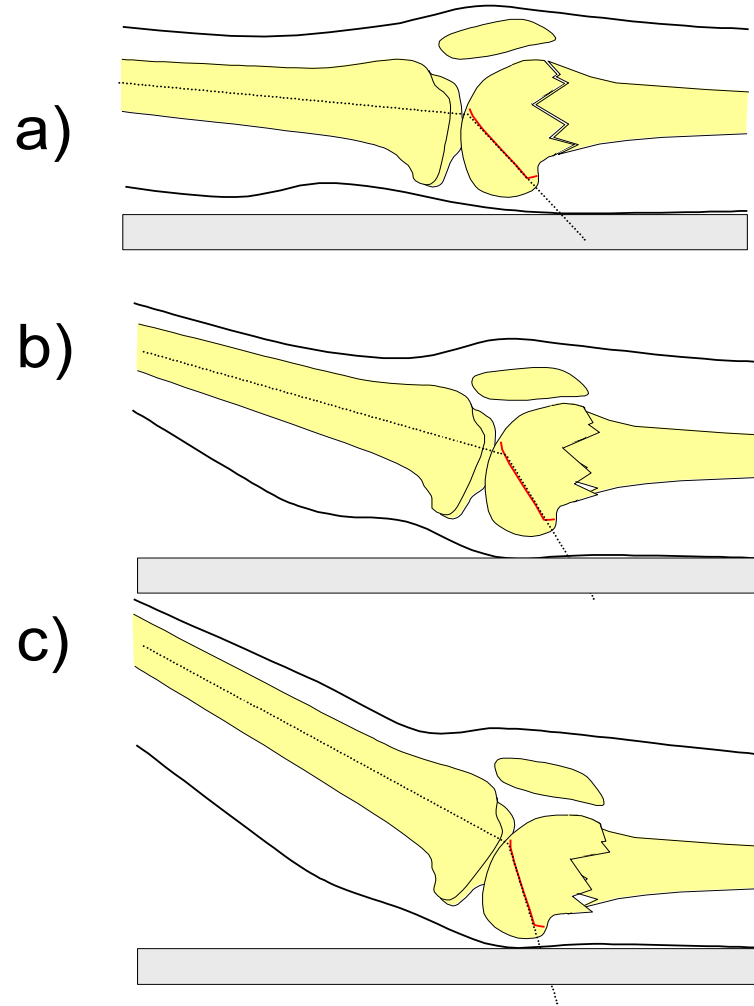


positive notch sign
if you see a notch like
this, the distal main
fragment is in
overextended position



genu recurvatum: hyperextension test

... Full extension necessary for ante-recurvatum check



„Hyperextensions Test“

1999

Starr AJ, Jones AL,
Reinert CM. The
swashbuckler: a
modified anterior
approach for fractures of
the distal femur.

J Orthop Trauma

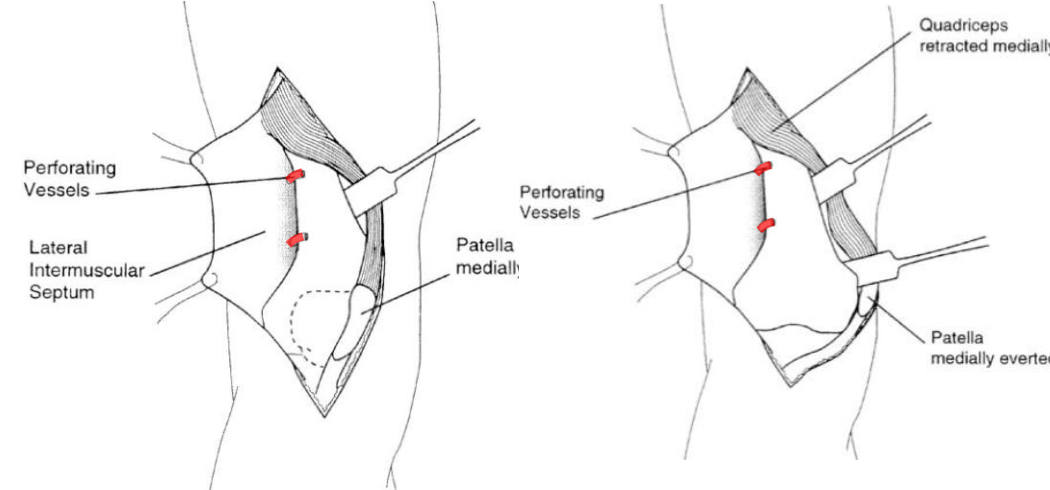
Journal of Orthopaedic Trauma
Issue: Volume 13(2), February 1999, pp 138-140
Copyright: © 1999 Lippincott Williams & Wilkins, Inc.
Publication Type: [Technical Tricks]
ISSN: 0890-5339
Accession: 00005131-199902000-00012
Keywords: Surgical exposures, Distal femur


[Technical Tricks] [< Previous Article](#) | [Table of Contents](#) | [Next Article >](#)

The "Swashbuckler": A Modified Anterior Approach for Fractures of the Distal Femur

Starr, Adam J.; Jones, Alan L.; Reinert, Charles M.

Author Information
Department of Orthopaedic Surgery, University of Texas Southwestern Medical Center, Dallas, Texas, U.S.A.
Accepted November 19, 1998.
Address correspondence and reprint requests to Dr. Adam J. Starr, Department of Orthopaedic Surgery,
University of Texas Southwestern Medical Center, 5323 Harry Hines Boulevard, Dallas, TX 75235-8883, U.S.A.
No financial project support of this research project has occurred. The authors have received nothing of value.
This manuscript does not contain information about medical devices.



 1997
ELSEVIER

Injury Vol. 28, Suppl. No. 1, pp. S-A31-S-A41, 1997
© 1997 Elsevier Science Ltd. All rights reserved
Printed in Great Britain
0020-1383/97 \$17.00+0.00

PII: S0020-1383(97)00076-4

Transarticular joint reconstruction and indirect plate osteosynthesis for complex distal supracondylar femoral fractures

C. Krettek¹, P. Schandelmaier¹, T. Miclau², R. Bertram¹, W. Holmes², H. Tscherne¹

¹Trauma Department, Hannover Medical School, D-30623 Hannover, Germany
²University of California, San Francisco, San Francisco General Hospital, Department of Orthopaedic Surgery, 1001 Potrero Avenue 3A36, San Francisco, CA 94110, USA

