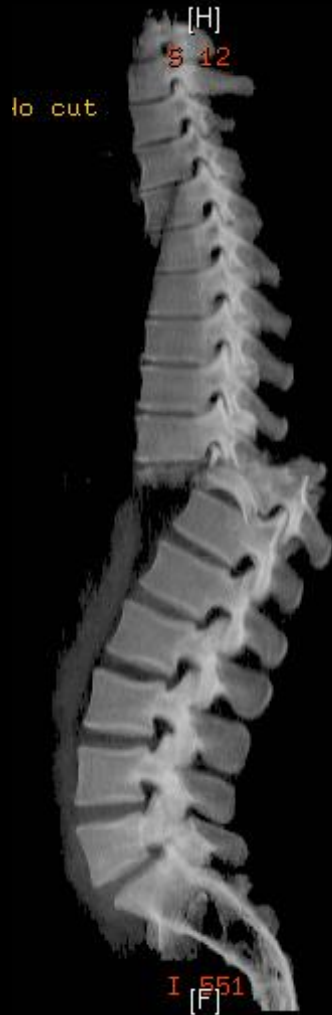

Spine Fractures: Identifying Unstable Injuries

Thoracic and Lumbar Spine



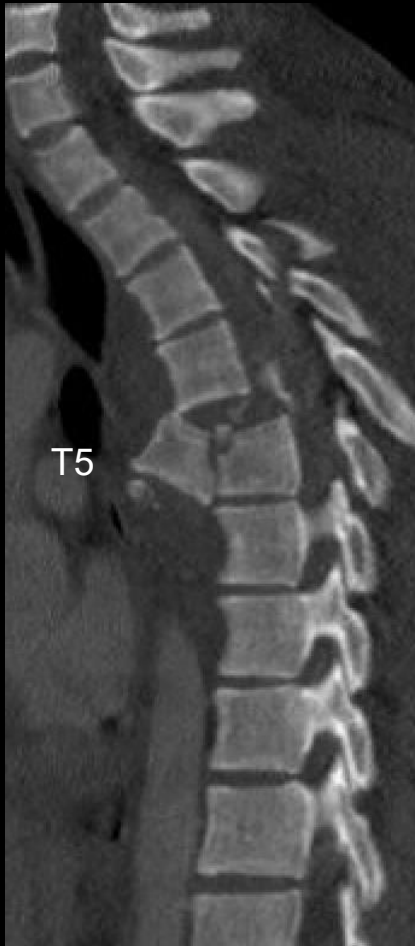Mark Xu, MD

*Orthopedic Trauma and Spine Surgeon
Assistant Clinical Professor, UCSF
OTI - Orthopedic Trauma Institute*

Annual International SF Orthopedic Trauma Course
2026

Spine Fractures: Identifying Unstable Injuries

Thoracic and Lumbar Spine

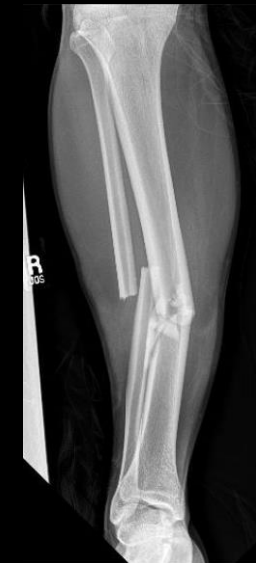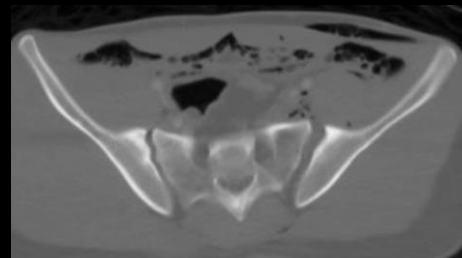


45M MVC – motorcycle accident on highway

T5 fracture-dislocation with paraplegia

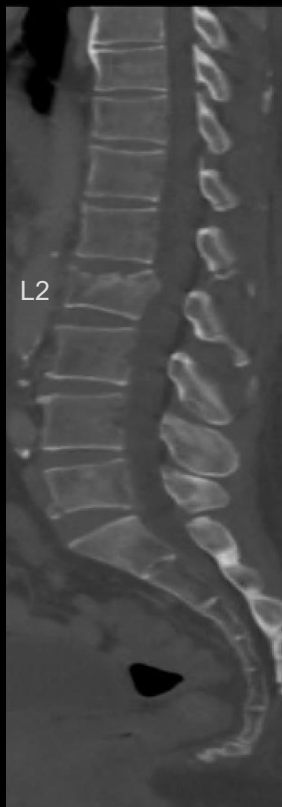Orthopedic injuries:

- *Pelvic fracture*
- *R tibial shaft fracture*

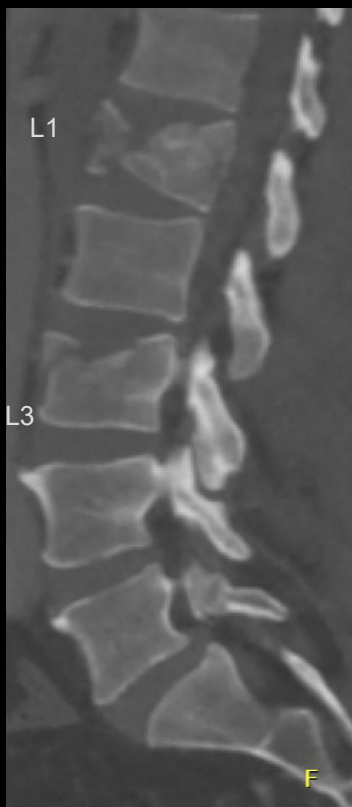

Spine Fractures: Identifying Unstable Injuries

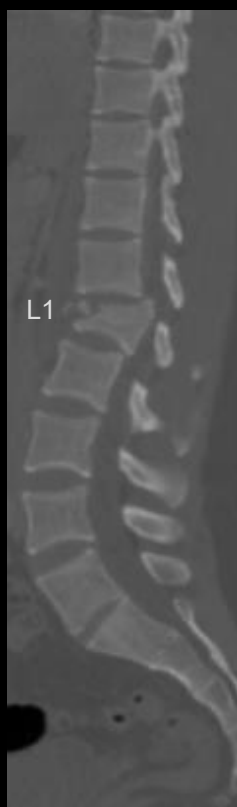Thoracic and Lumbar Spine



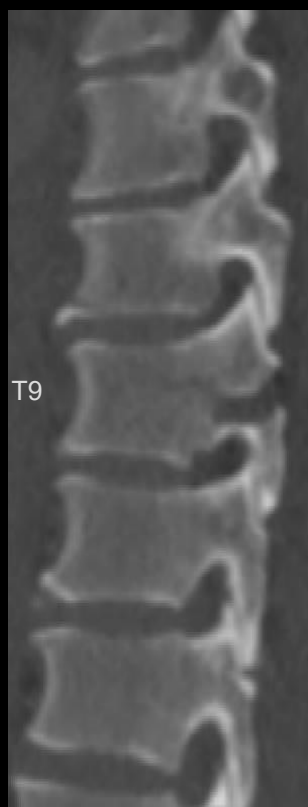70M GLF



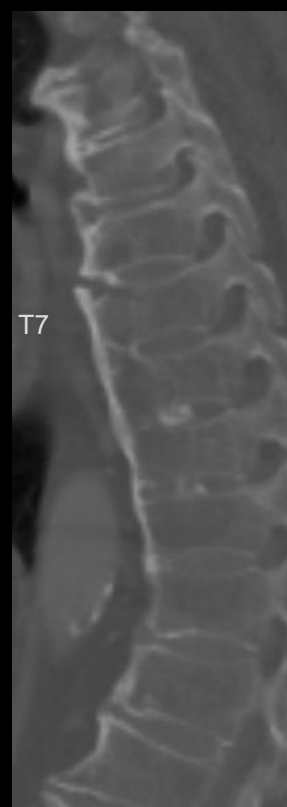38M MVC



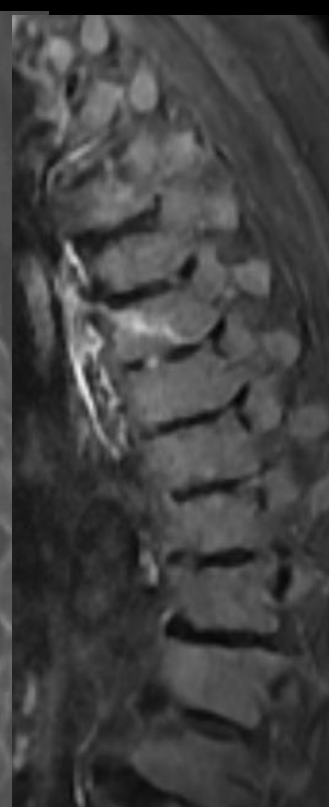
20M MVC



40M MVC



84F GLF

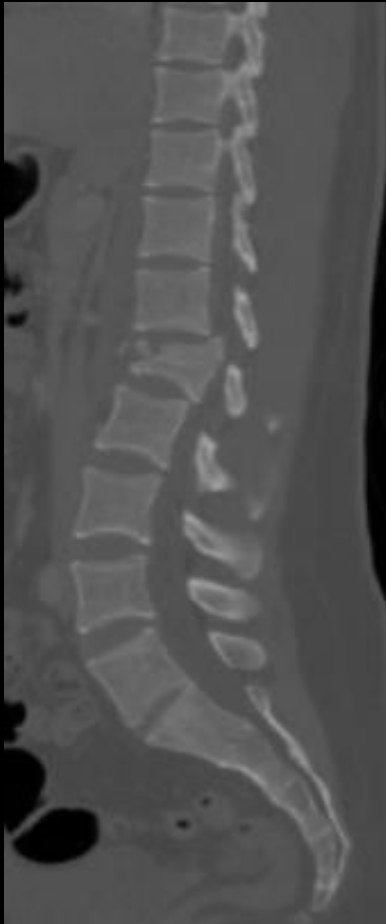

R leg weakness

Objectives

1. Background
2. Classification
3. Defining and assessing for instability

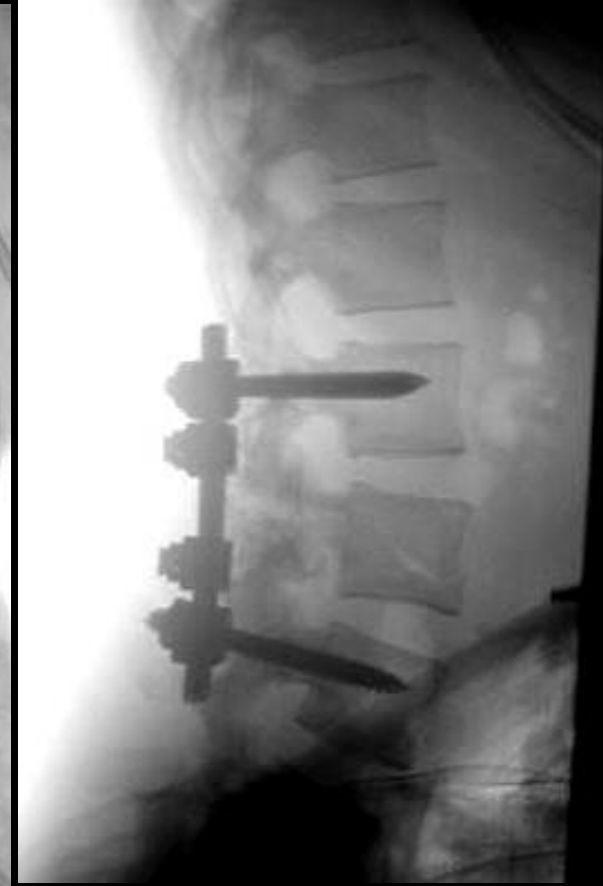
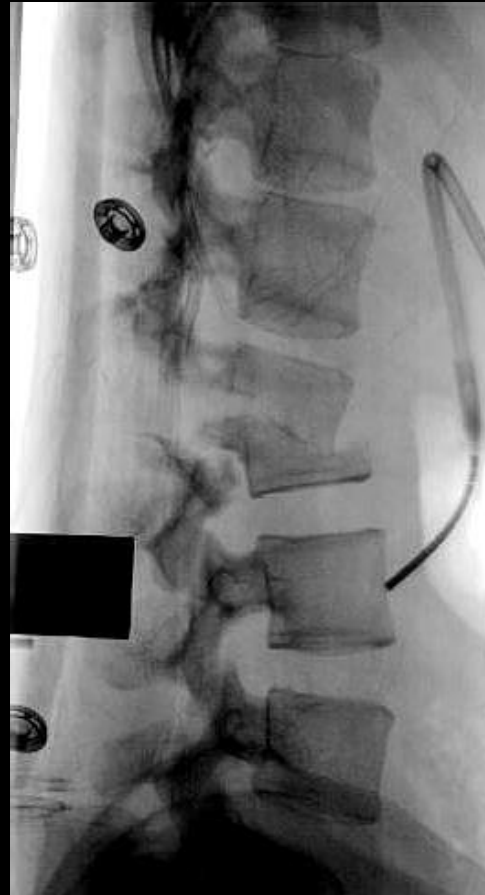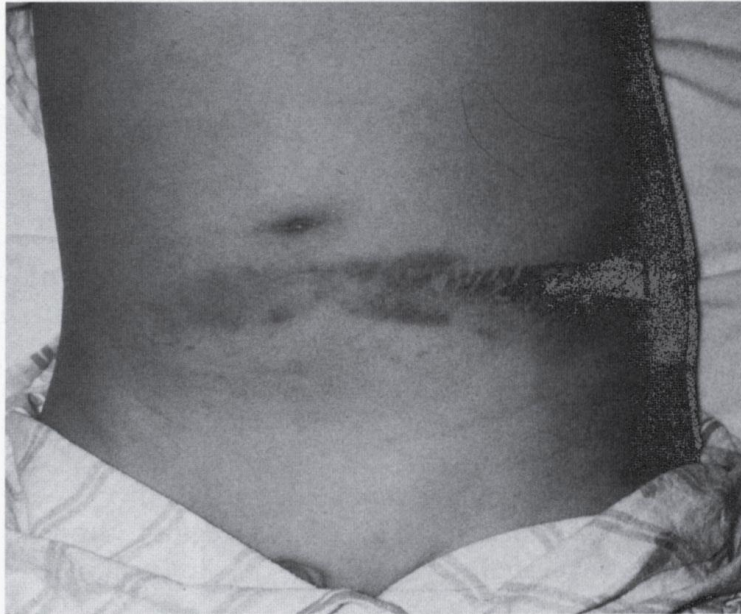Introduction



- TL fractures occur in **~7% of all blunt trauma pts**
 - Comprise **~ 50-90%** of the 160,000 annual traumatic spinal fractures in North America
- Two different patient populations:
 - High-energy trauma**
 - MVC, fall from height
 - Neurologic risk
 - Low-energy trauma**
 - Fragility, osteoporotic injuries

Associated Injuries

- 50 % of cases
- 20 % pulmonary injury
- Intra-abdominal injury
- Lower extremity fractures

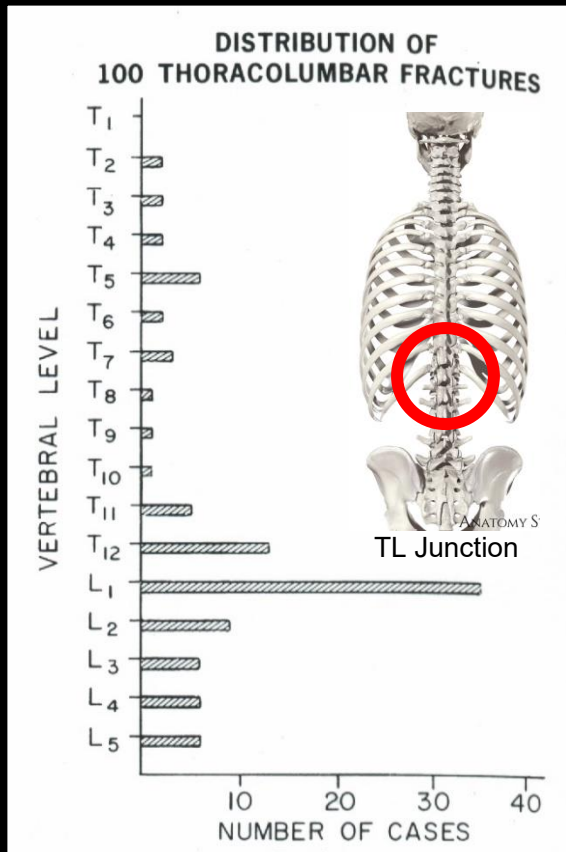


Associated Injuries

Multiple noncontiguous spine fractures occur in 6 - 15 % cases

If one spine fracture is identified, must image entire spine

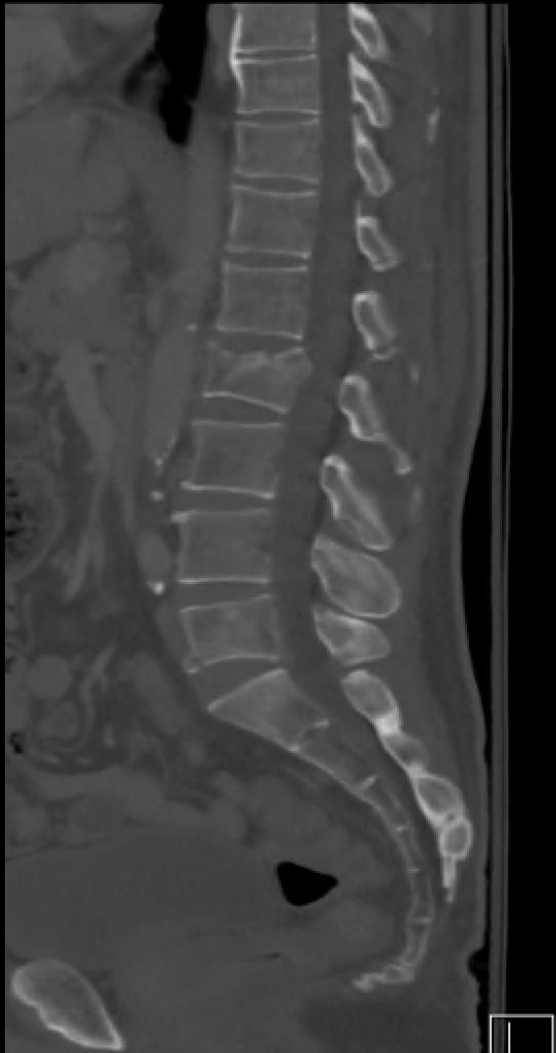Fracture distribution



T10 - L2 Transitional zone accounts for > 50 % vertebral body fractures and 40 % SCI

- T 1 - T 10 16 %
- T 11 - L 1 52 %
- L 2 - L 5 32 %

Defining Instability



- “the loss of the ability of the spine under **physiologic loads** to maintain its patterns of displacement so there is no initial or additional **neurologic deficit**, no major **deformity**, and no **incapacitating pain**”

-White and Panjabi

Assessing Instability

- **Mechanical**

- **Neurologic status**

Assessing Instability

- **Mechanical**
 - Fracture morphology
 - Posterior tension band
 - *PLC: Posterior ligamentous complex*
- **Neurologic status**

Assessing Instability

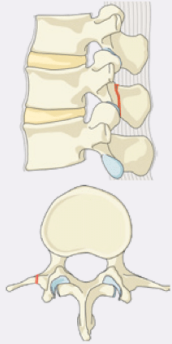
- **Mechanical**
 - Fracture morphology
 - Posterior tension band
 - *PLC: Posterior ligamentous complex*
- **Neurologic status**

TLICS: Thoracolumbar Injury Classification and Severity Scale

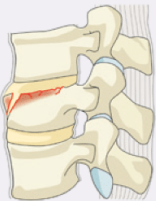TLICS		3 independent predictors		
1	Morphology immediate stability	- Compression - Burst - Translation/rotation - Distraction	1 2 3 4	- Radiographs - CT
2	Integrity of PLC longterm stability	- Intact - Suspected - Injured	0 2 3	- MRI
3	Neurological status	- Intact - Nerve root - Complete cord - Incomplete cord - Cauda equina	0 2 2 3 3	- Physical examination
Predicts		- Need for surgery	0 – 3 4 > 4	- nonsurgical - surgeon's choice - surgical

Type A Compression Injuries

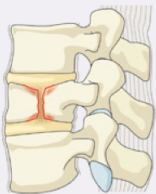
A0 Minor, nonstructural fractures



A1 Wedge-compression

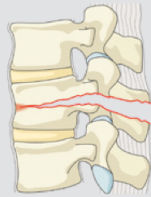

A2 Split

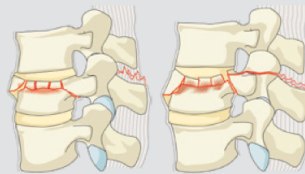


Type B Distraction Injuries

B1 Transosseous tension band disruption
Chance fracture

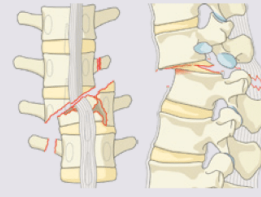


B2 Posterior tension band disruption

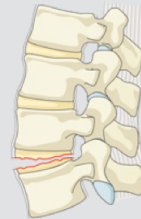

Type C Translation Injuries

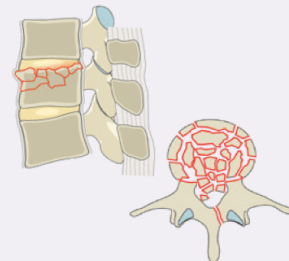
C Displacement or dislocation



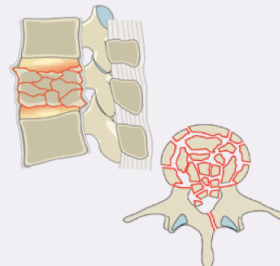
B3 Hyperextension



A3 Incomplete burst



A4 Complete burst



3 Types

A – Compression

B – Distraction

C – Translation

Stable



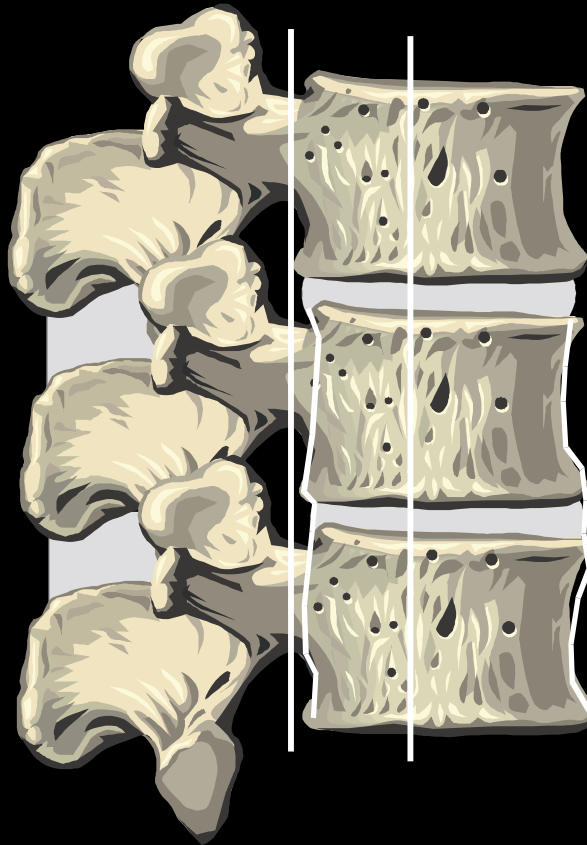
Unstable

Spine Biomechanics

*3 columns to the
T and L spine*

Posterior ligamentous complex:

- Tension band that **resists forward flexion** or kyphosis



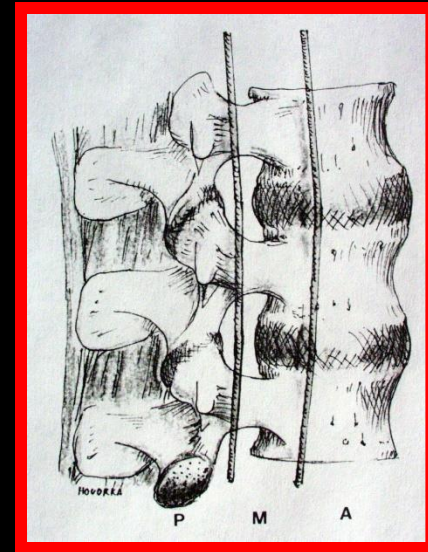
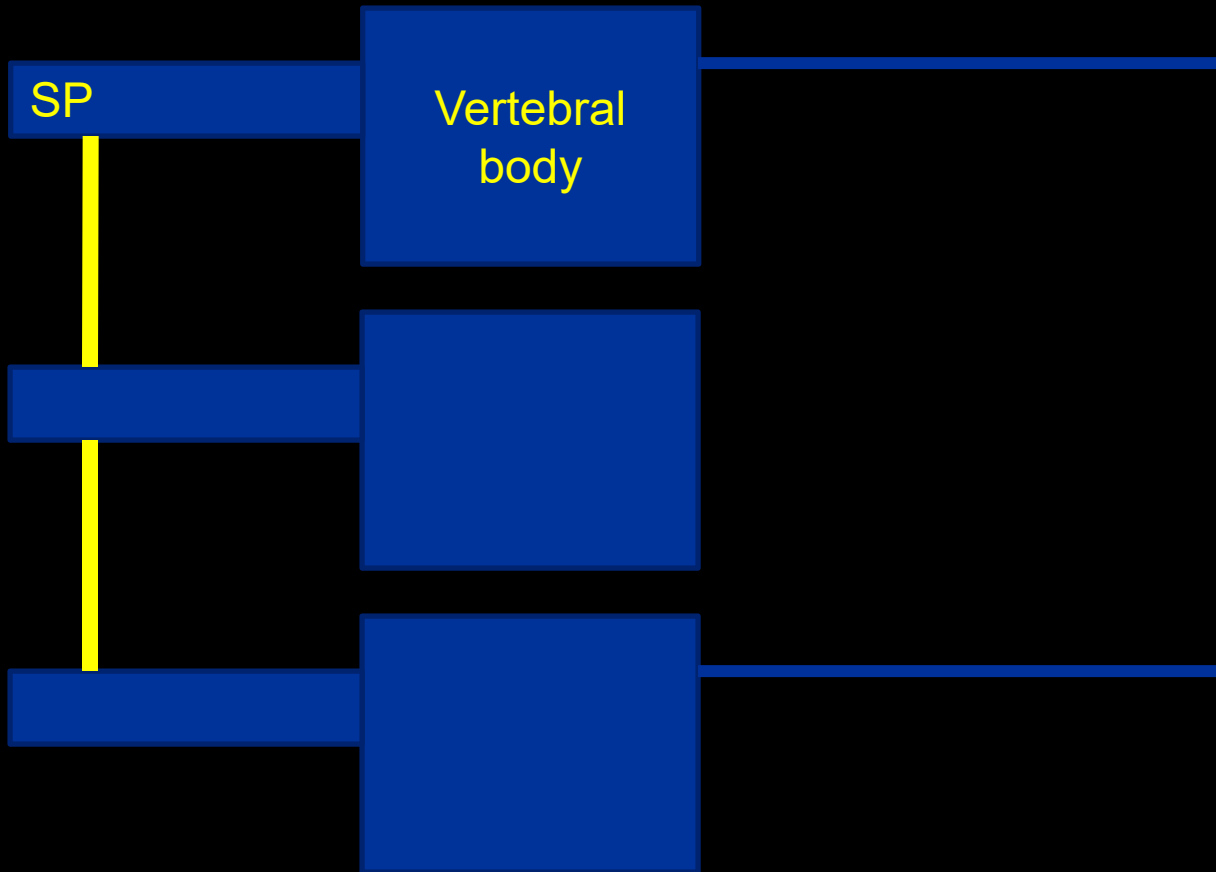
Anterior vertebral body withstands:

- **Axial load** and compression

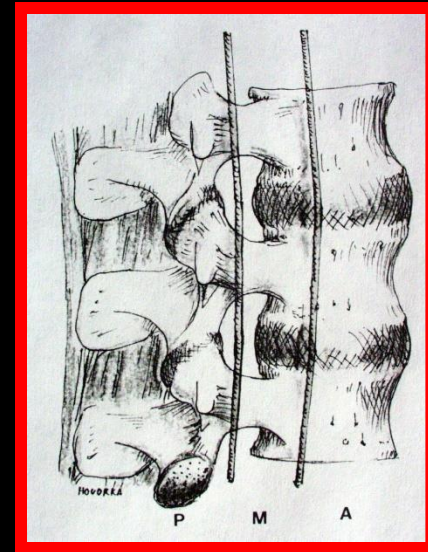
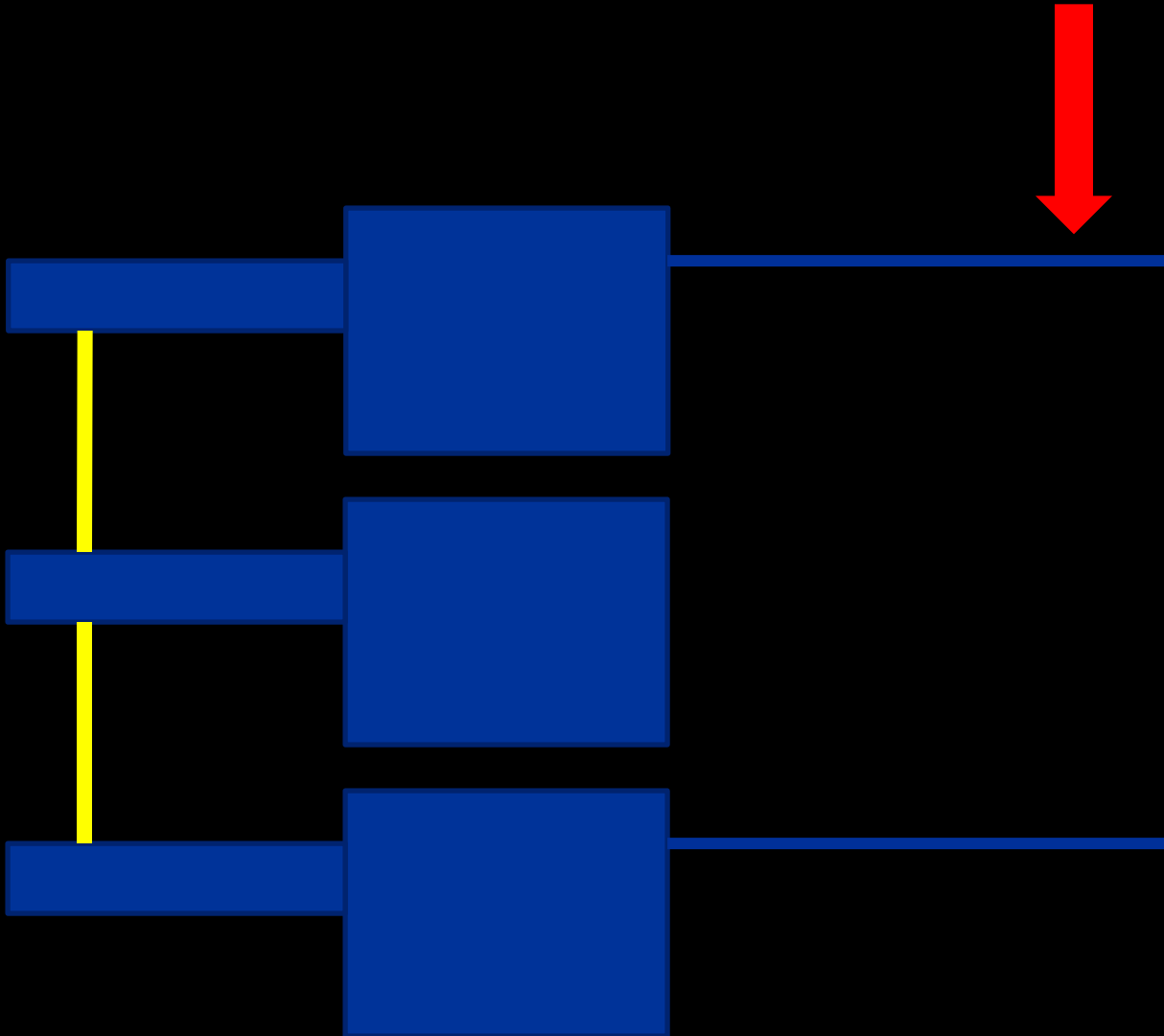
Type A Compression Injuries

posterior


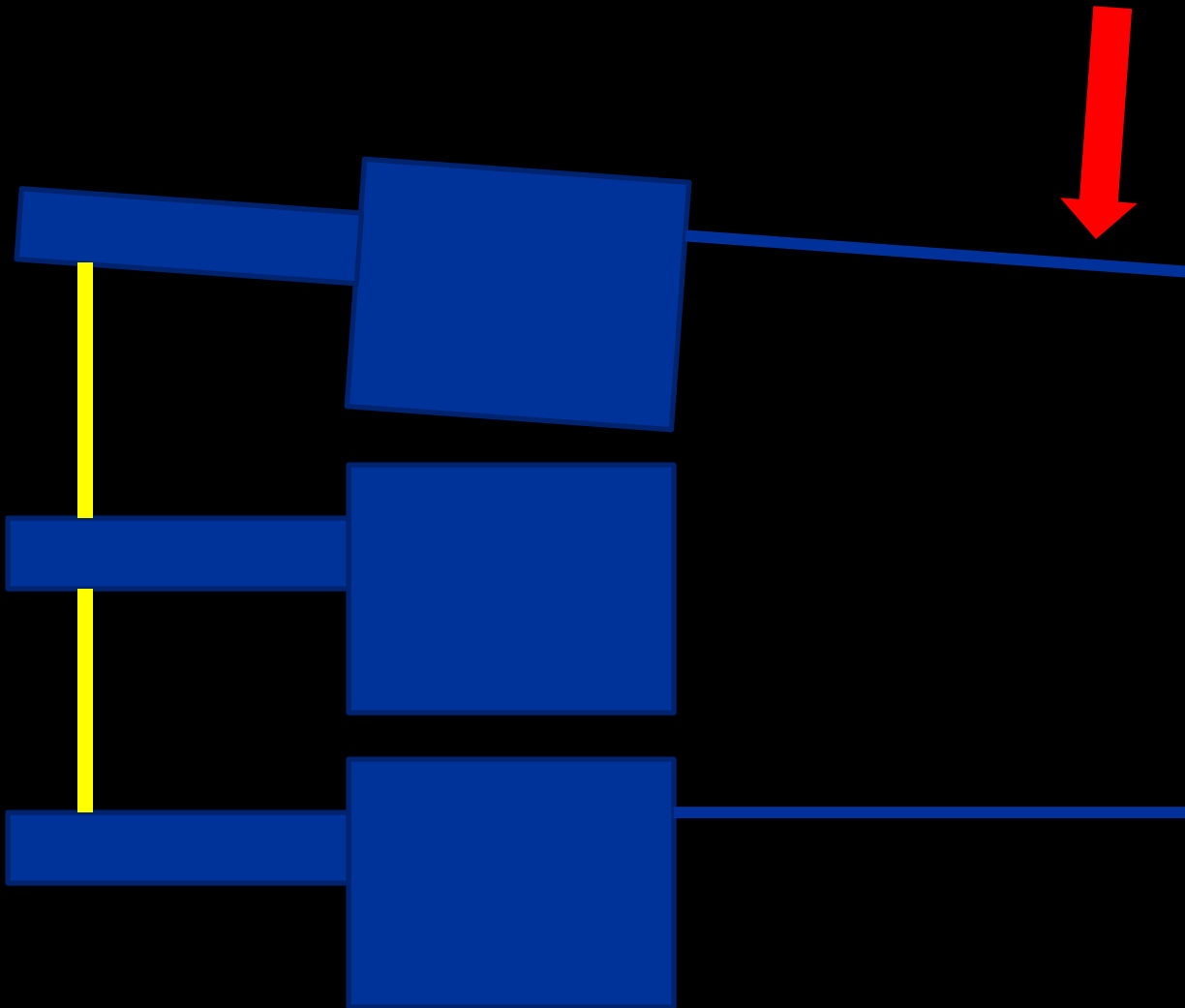
anterior



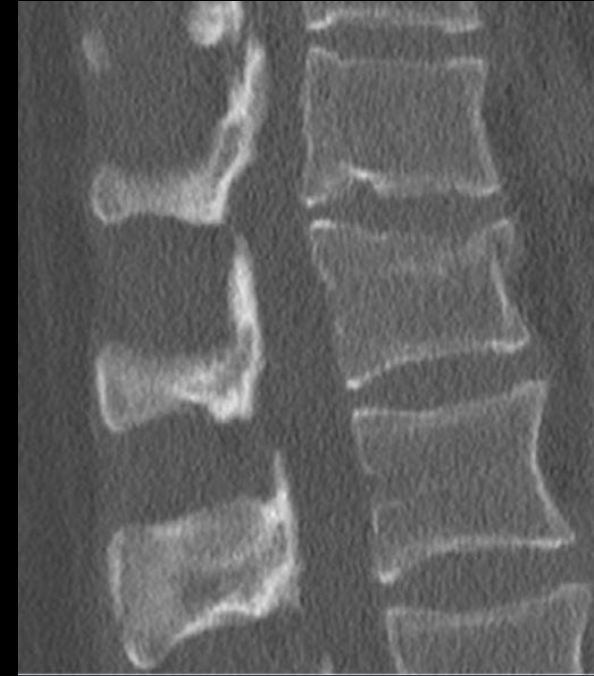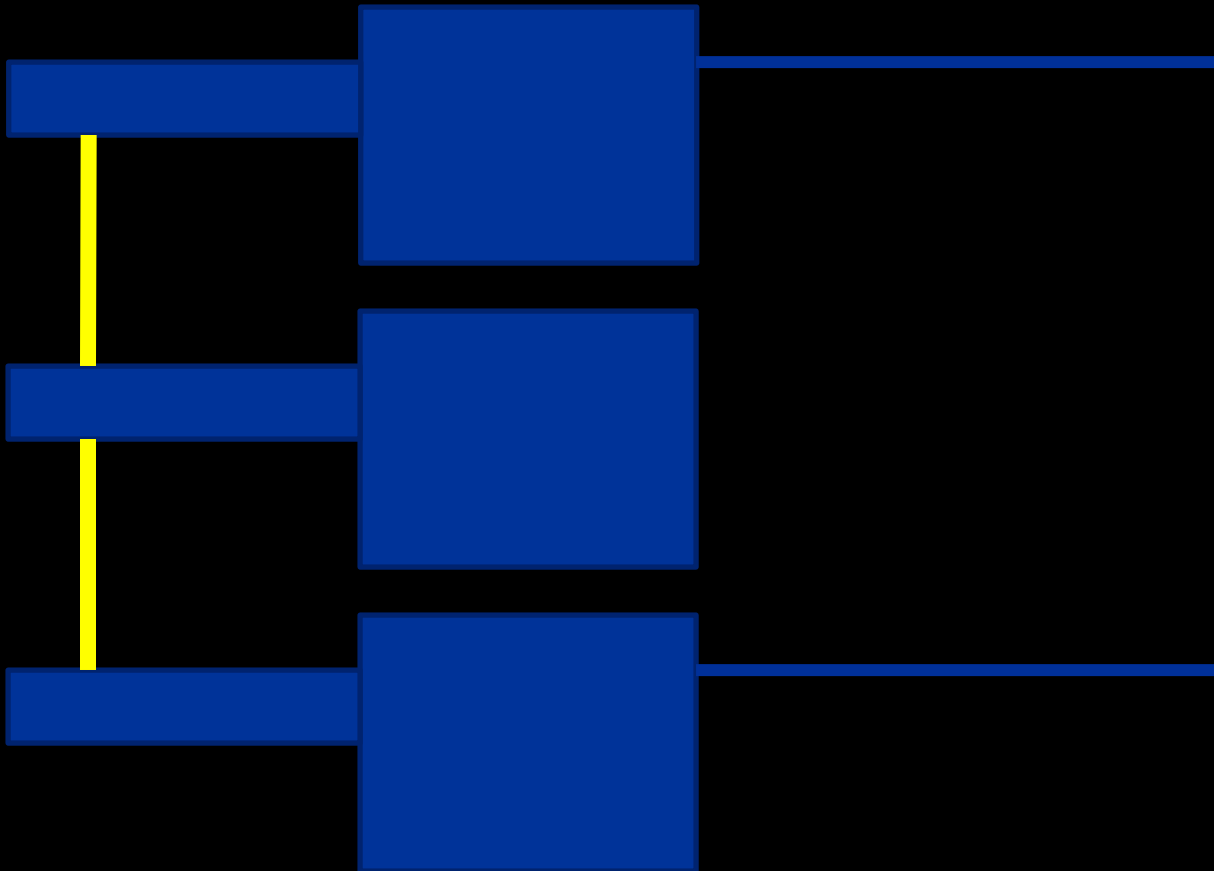
Type A Compression Injuries



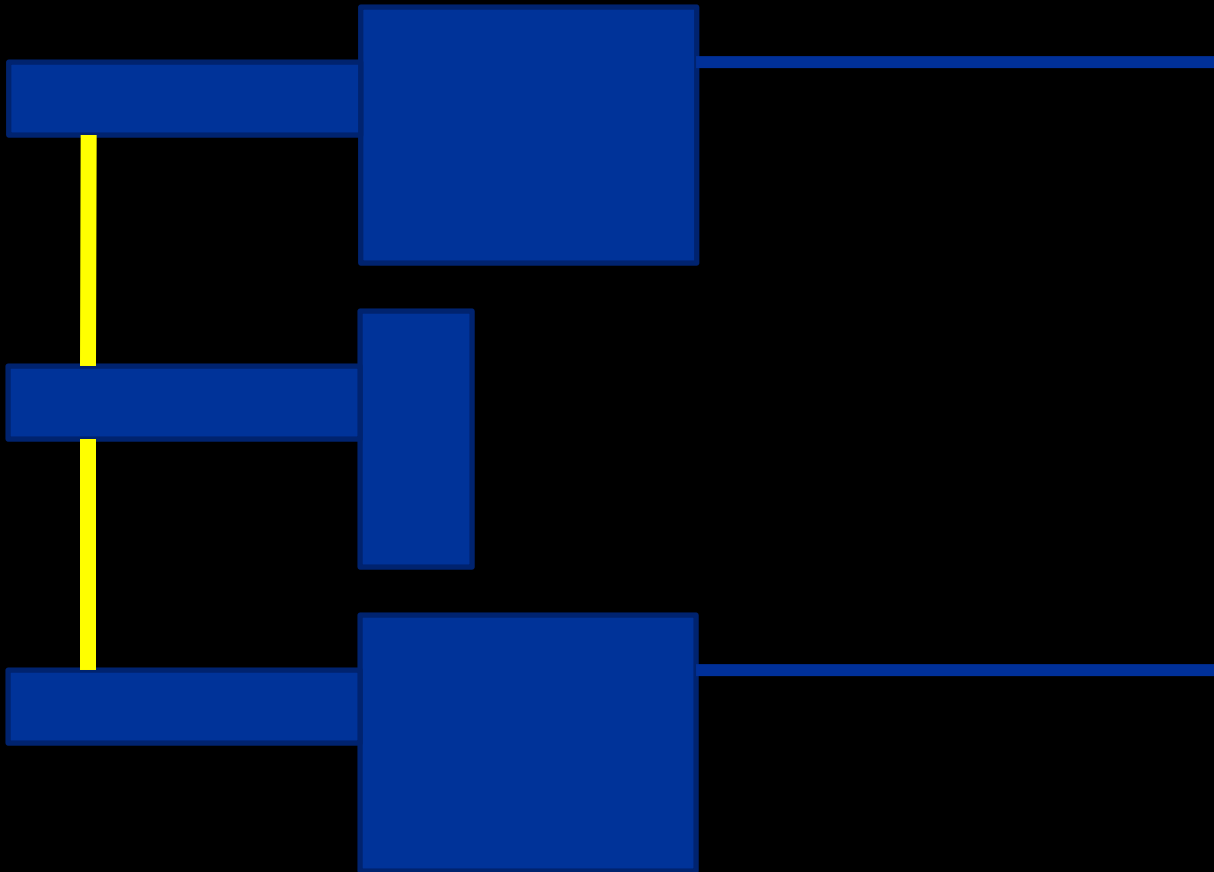
Type A Compression Injuries



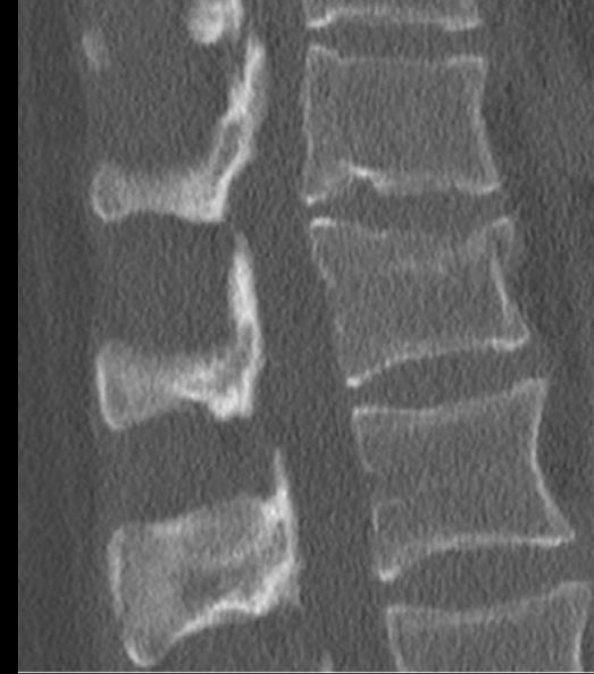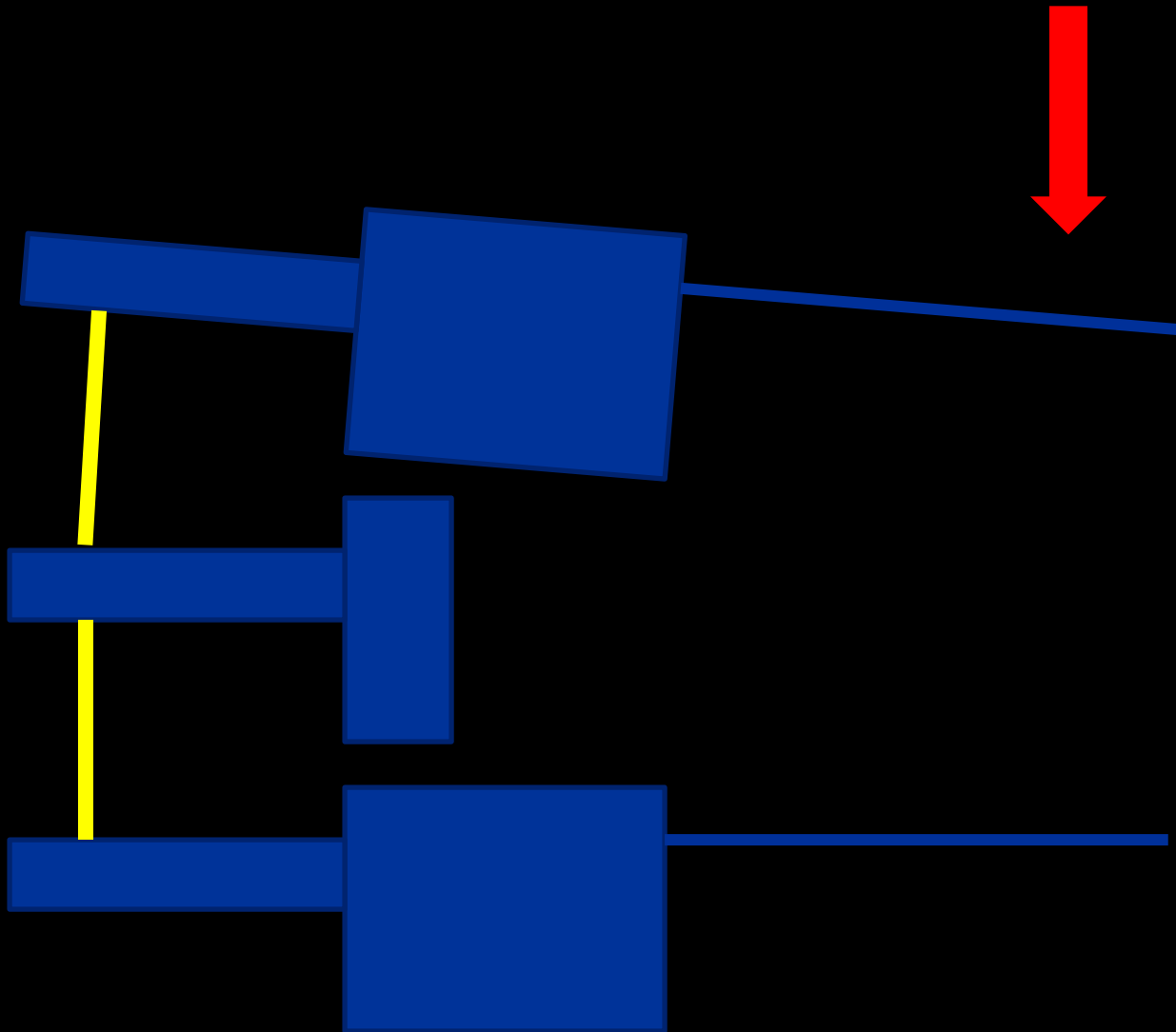
Type A Compression Injuries



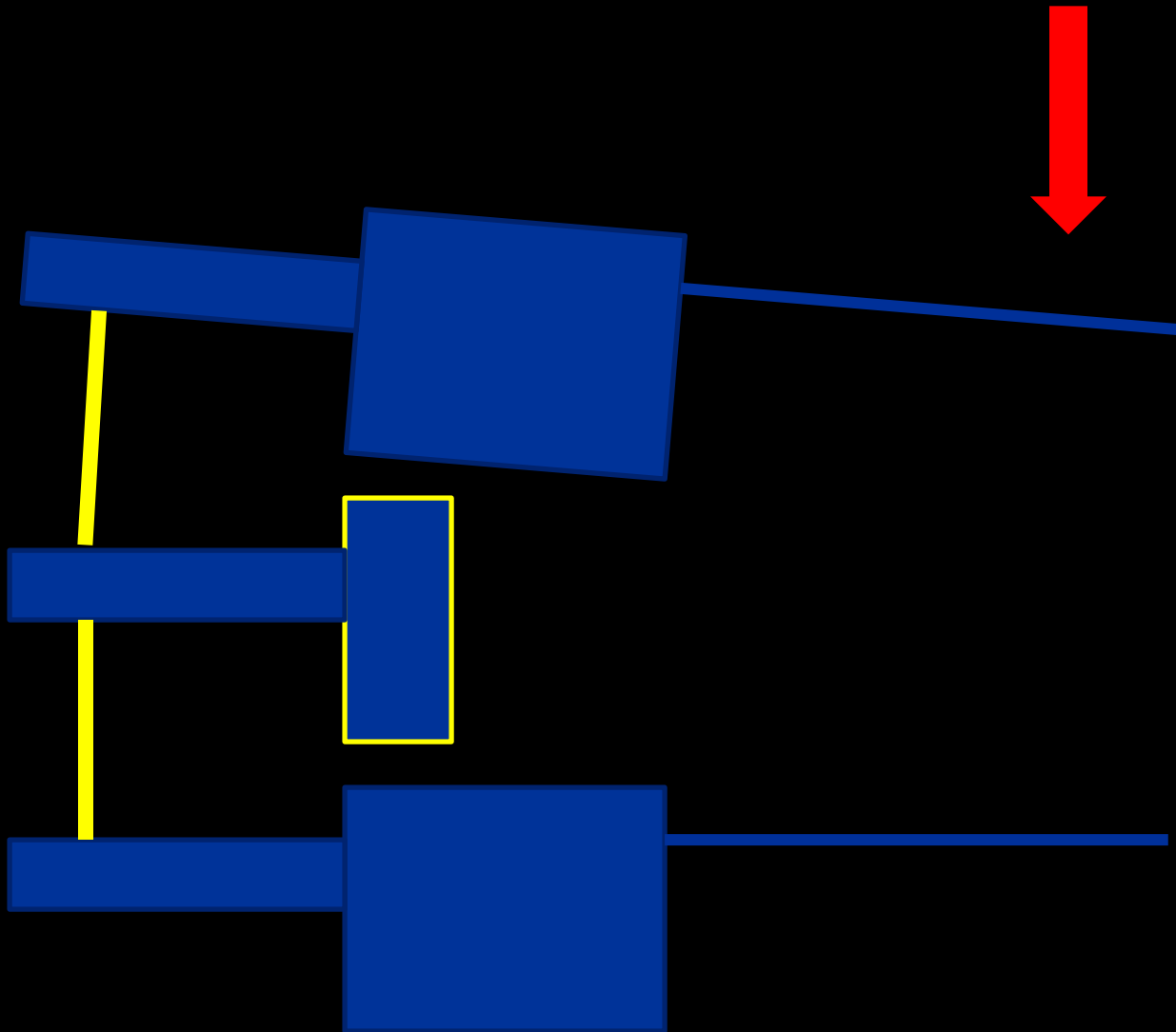
Type A
Compression Injuries



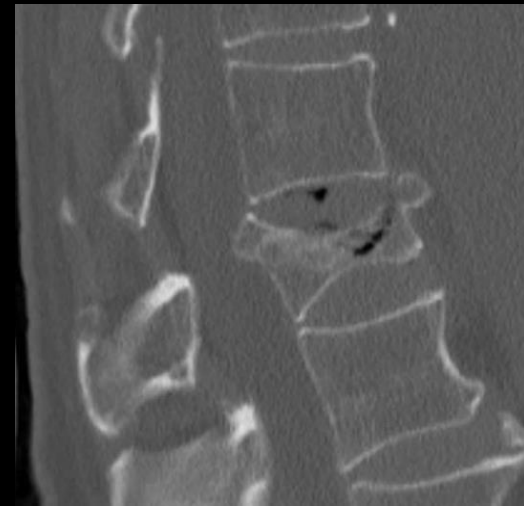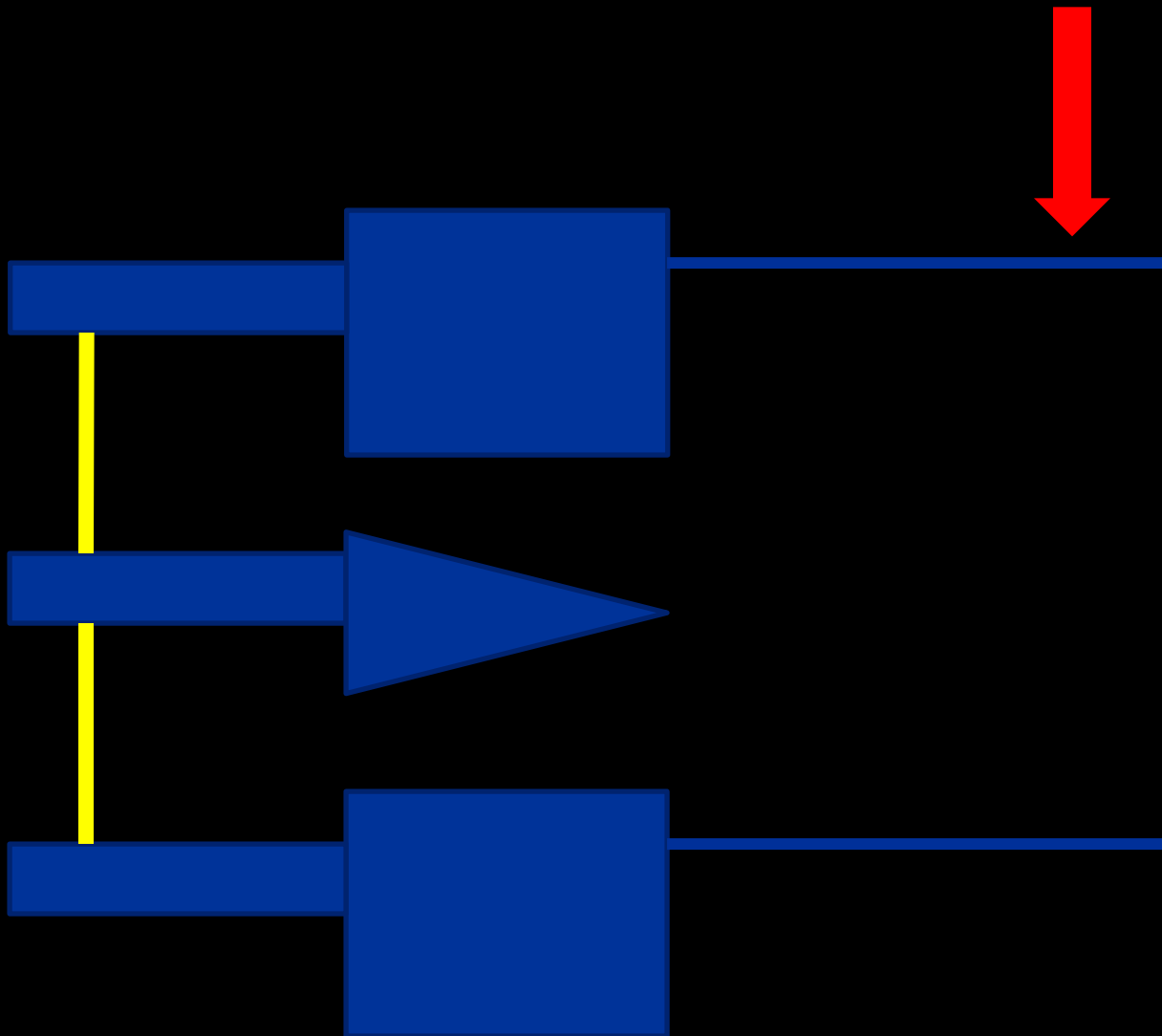
Type A
Compression Injuries



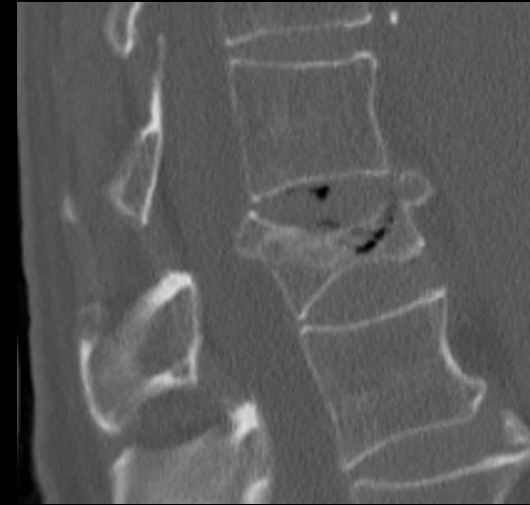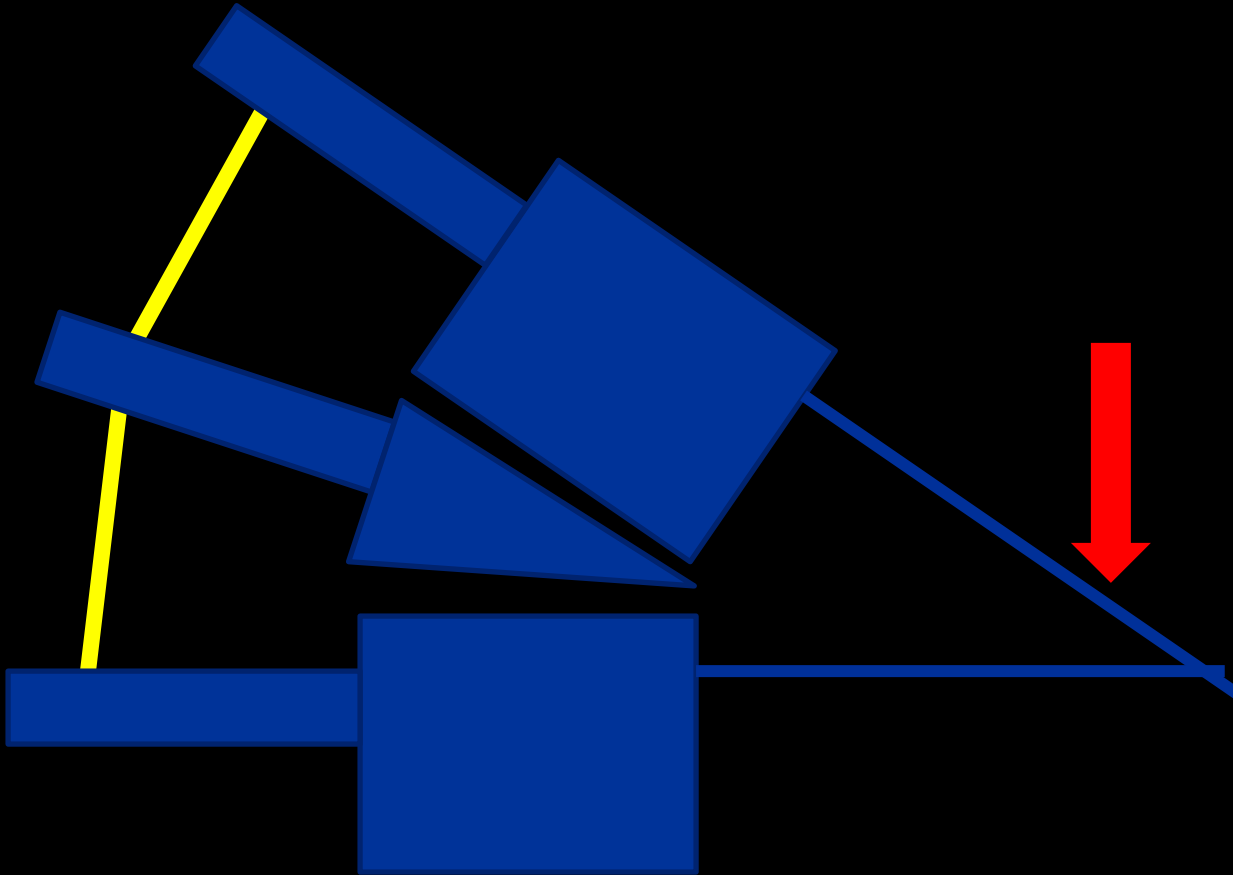
Type A
Compression Injuries



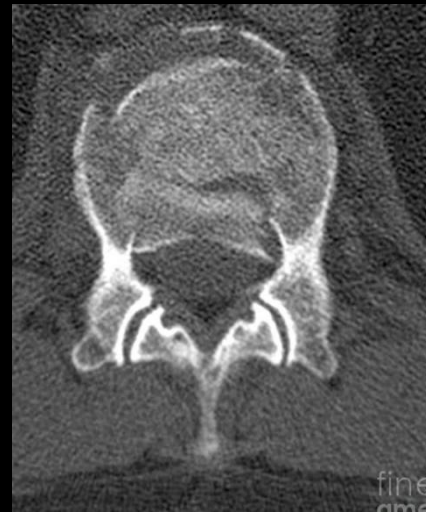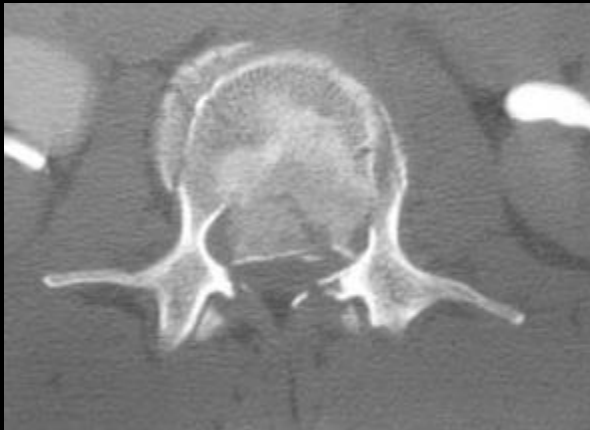
Type A
Compression Injuries



Type A
Compression Injuries



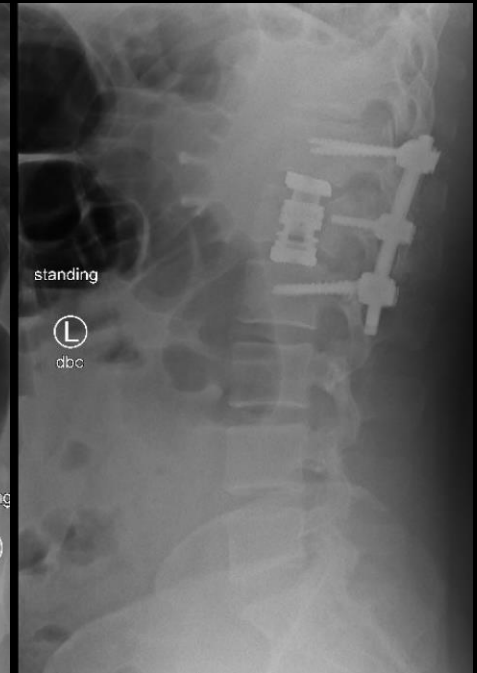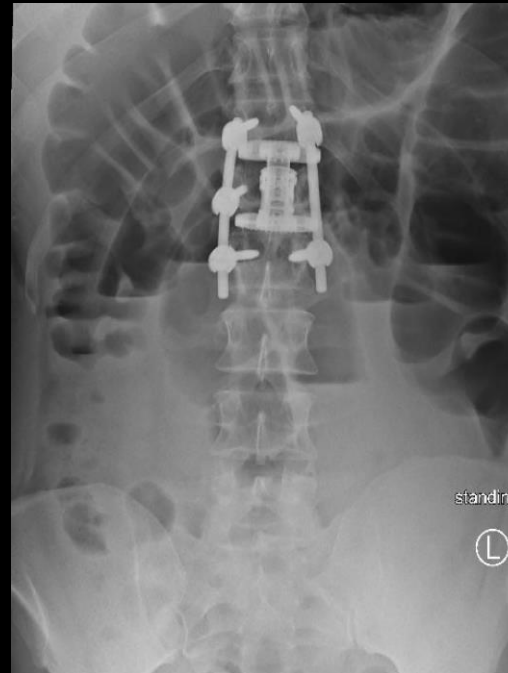
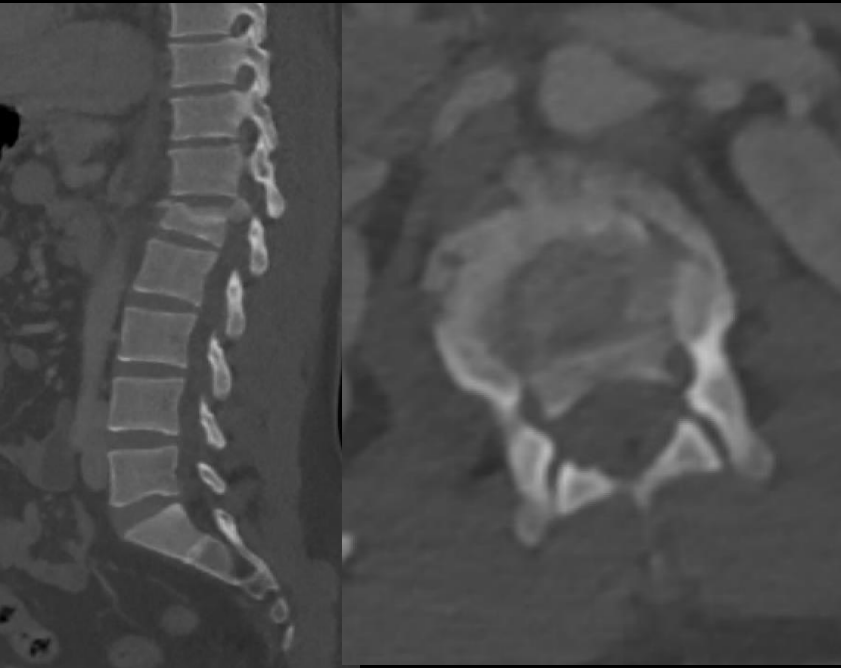
Burst fractures



Varying amounts of **retropulsion**

Important to assess for **neurologic deficit**

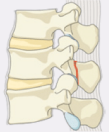L1 Burst Fracture



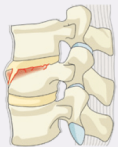35M MVC
Bowel/bladder dysfunction

Type A: Compression Injuries

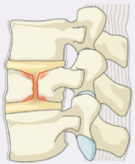
A0 Minor, nonstructural fractures



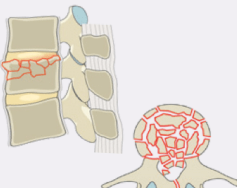
A1 Wedge-compression



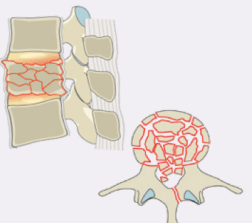
A2 Split



A3 Incomplete burst



A4 Complete burst



Signs of instability:

PLC injury

Alignment - Kyphosis

Neurologic deficit

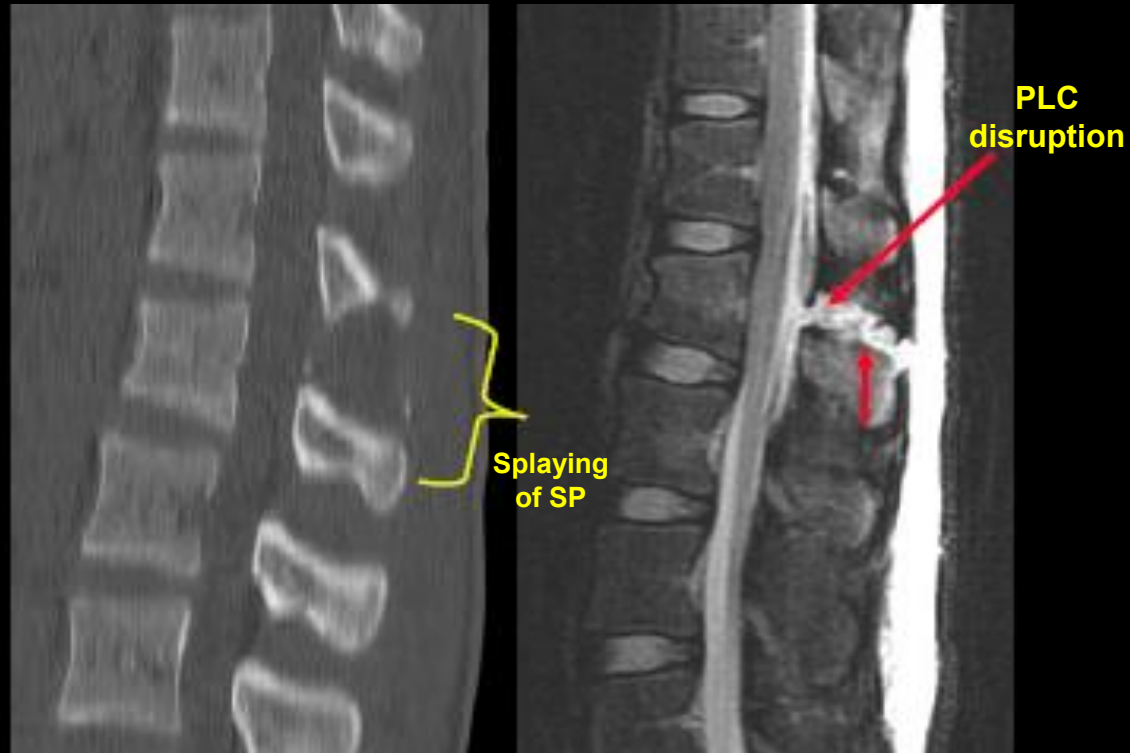
MRI to assess PLC

Upright X-ray to assess kyphosis

MRI

Indications:

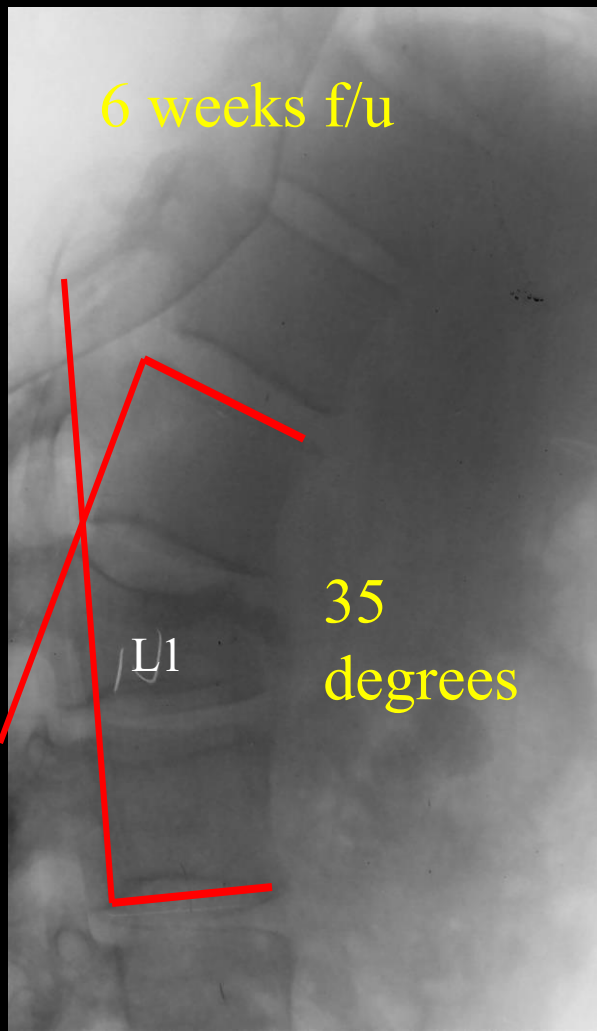
- Neurologic deficit
 - Neural element compression
 - Epidural hematoma
- Suspected ligamentous injury
 - PLC evaluation



L1 Burst Fracture

Upright X-ray

6 weeks f/u



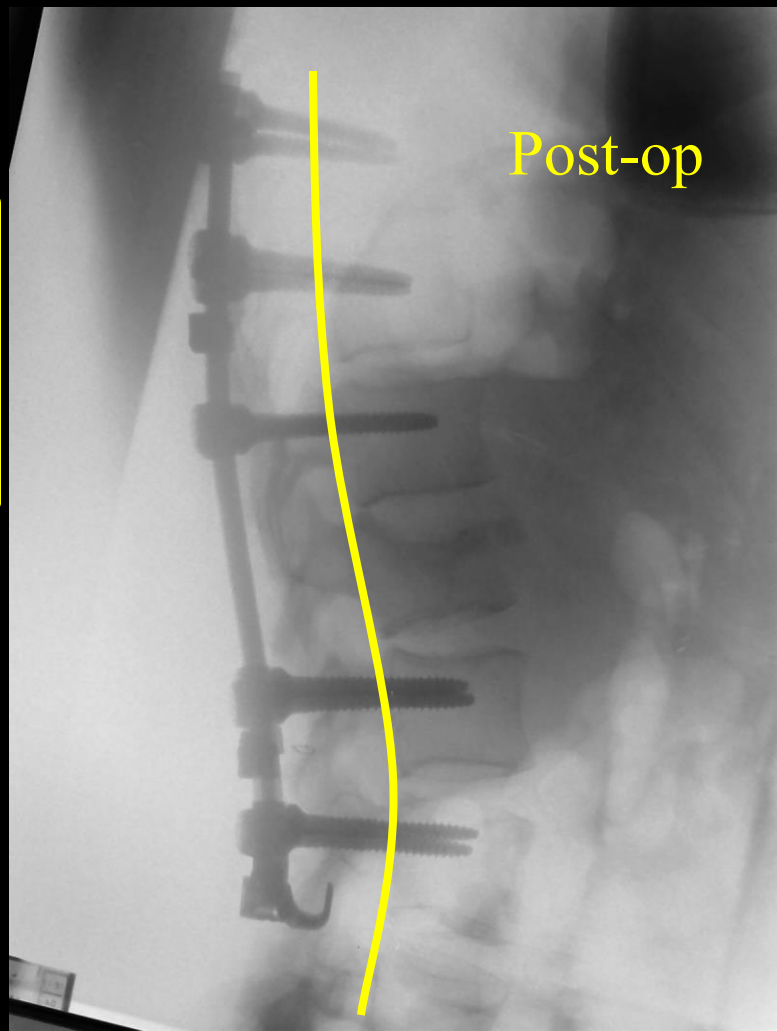
Treatment?

A3 and A4 burst fractures

- Neurologically intact
- + height loss (?)
- + kyphosis (?)

Progressive kyphosis
Pain

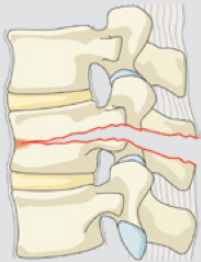
Post-op



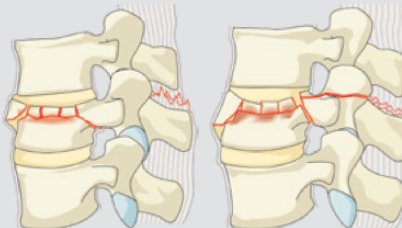
B Type – Distraction injuries

Type B Distraction Injuries

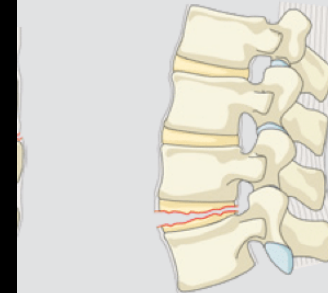
B1 Transosseous tension band disruption
Chance fracture



B2 Posterior tension band disruption



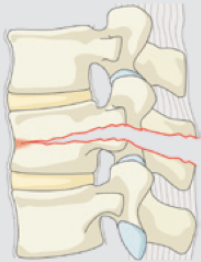
B3 Hyperextension



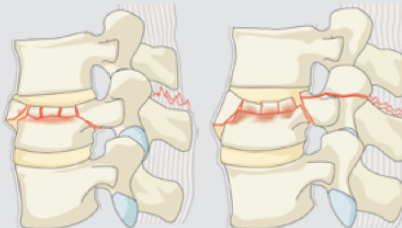
B Type – Distraction injuries

Type B Distraction Injuries

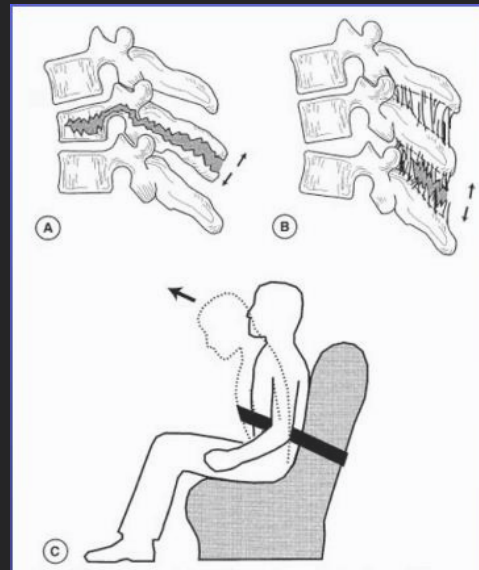
B1 Transosseous tension band disruption
Chance fracture



B2 Posterior tension band disruption


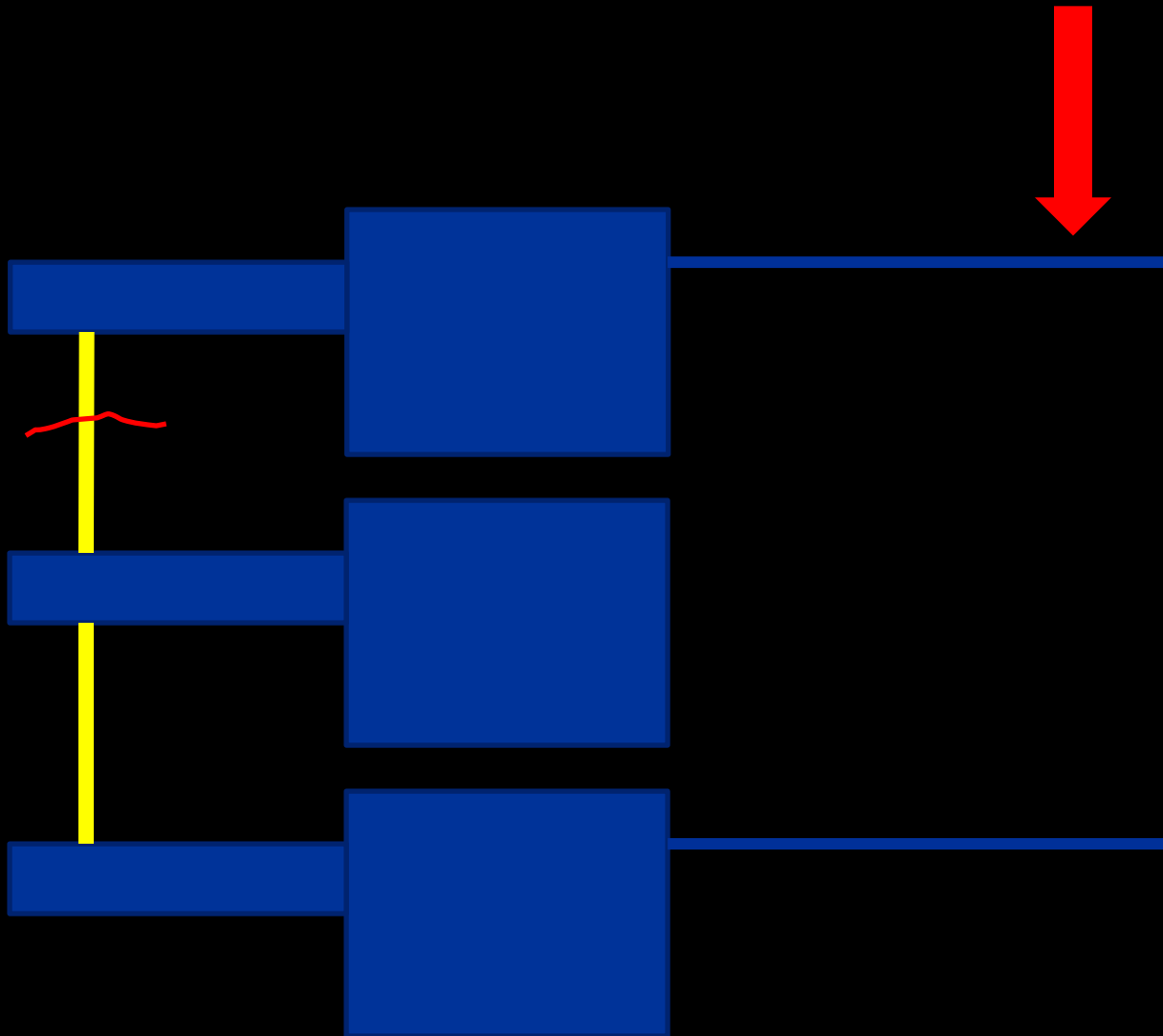


Flexion-distraction injury


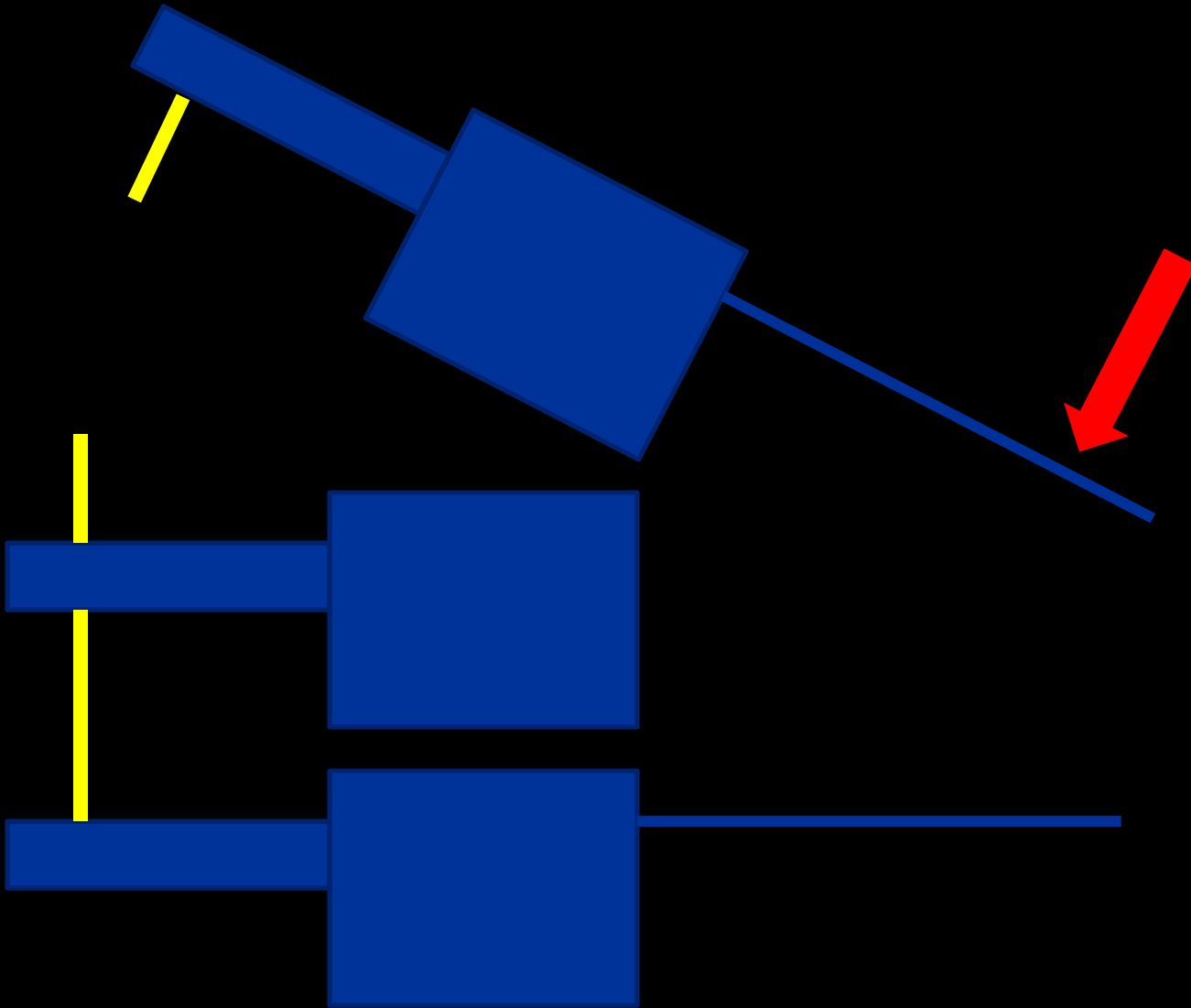


Sudden flexion over
an anterior fulcrum

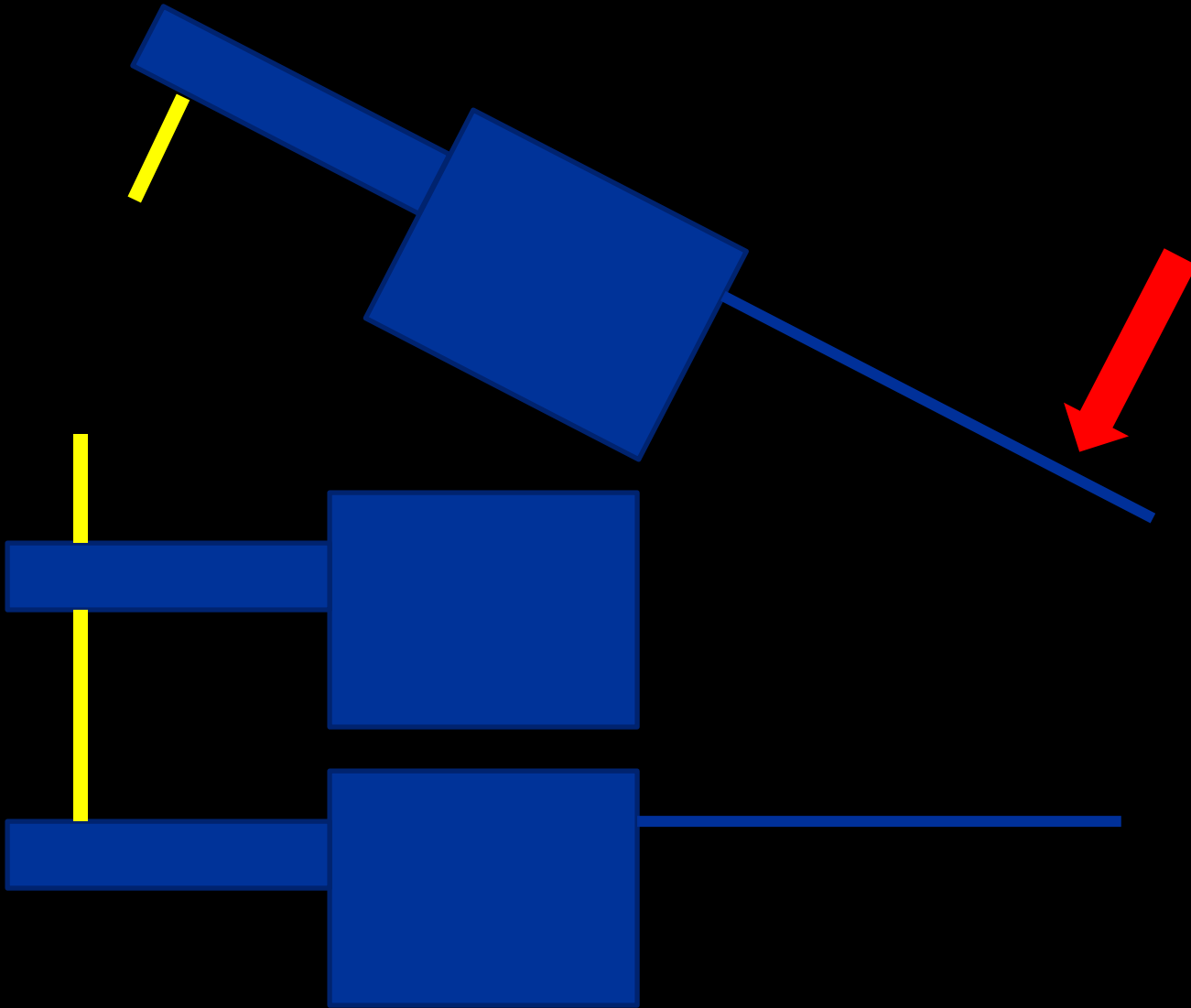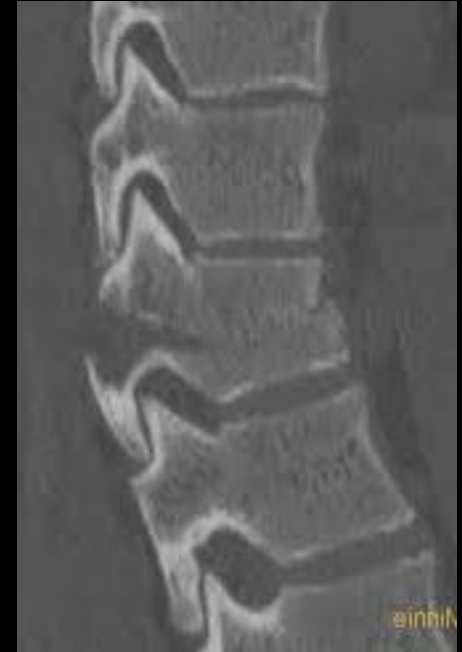
Type B Distraction Injuries



Type B Distraction Injuries



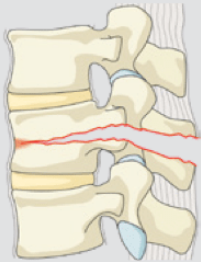
Type B
Distraction Injuries



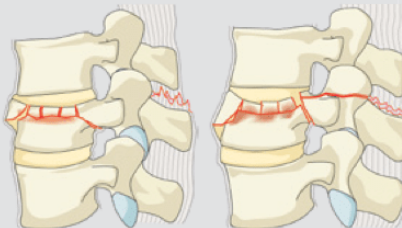
B Type – Distraction injuries

Type B Distraction Injuries

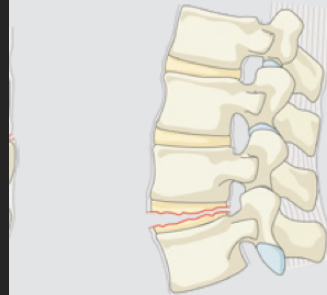
B1 Transosseous tension band disruption
Chance fracture



B2 Posterior tension band disruption



B3 Hyperextension

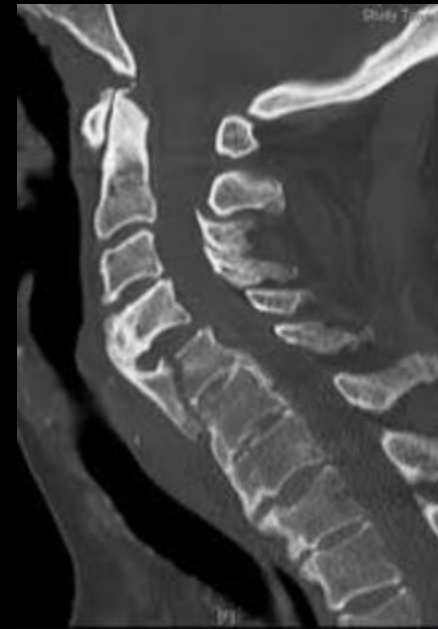
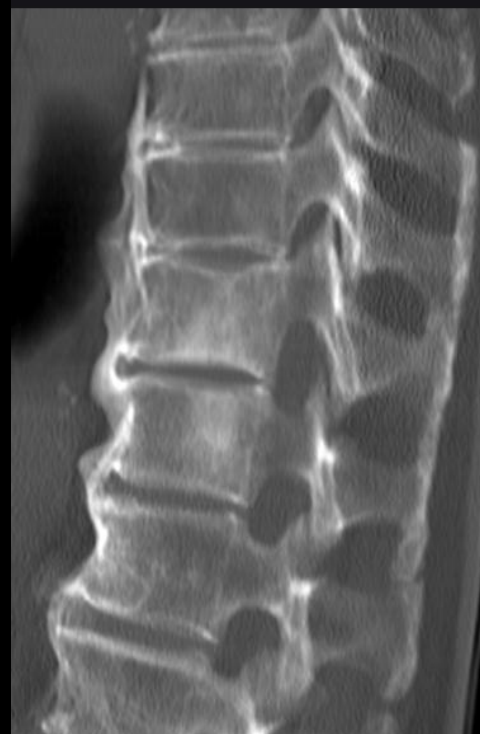
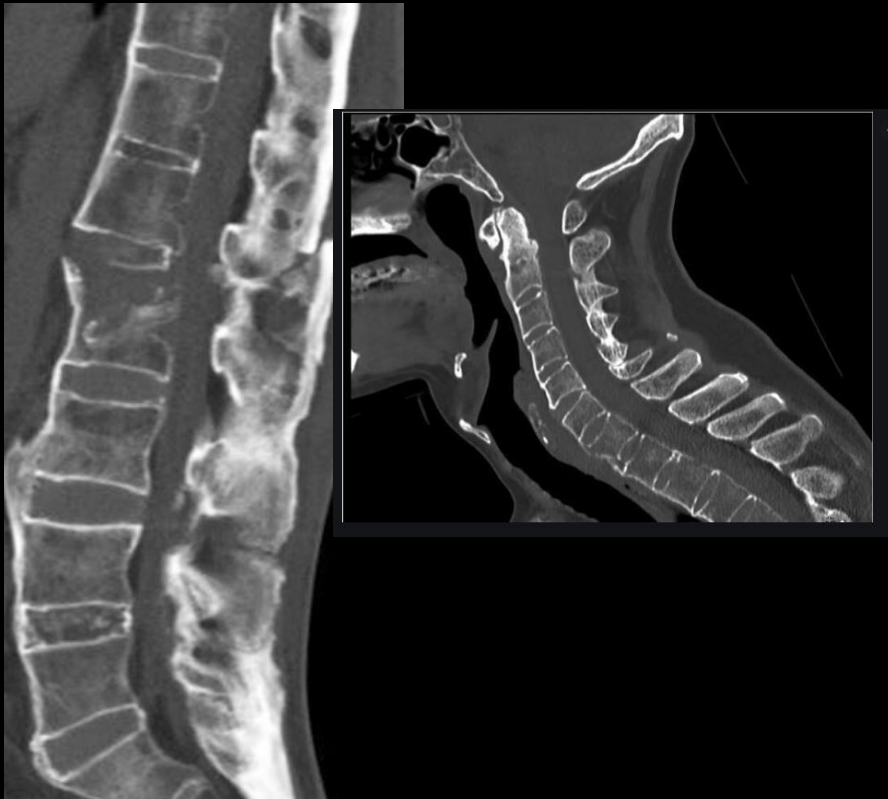
Hyperextension injury

Ankylosed spine

Subset of patient who present with ankylosed spines

- Ankylosing Spondylitis
- Diffuse idiopathic skeletal hyperostosis

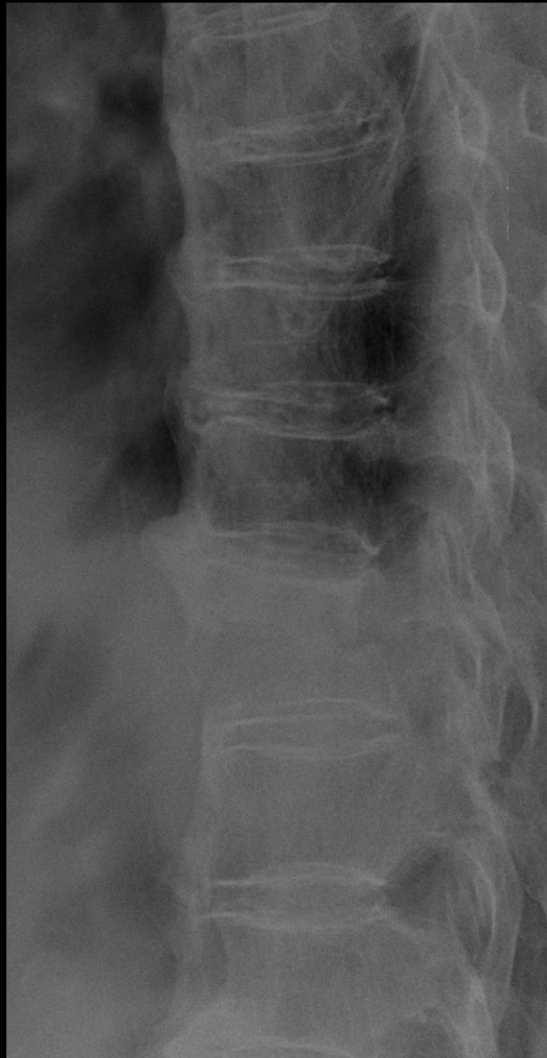
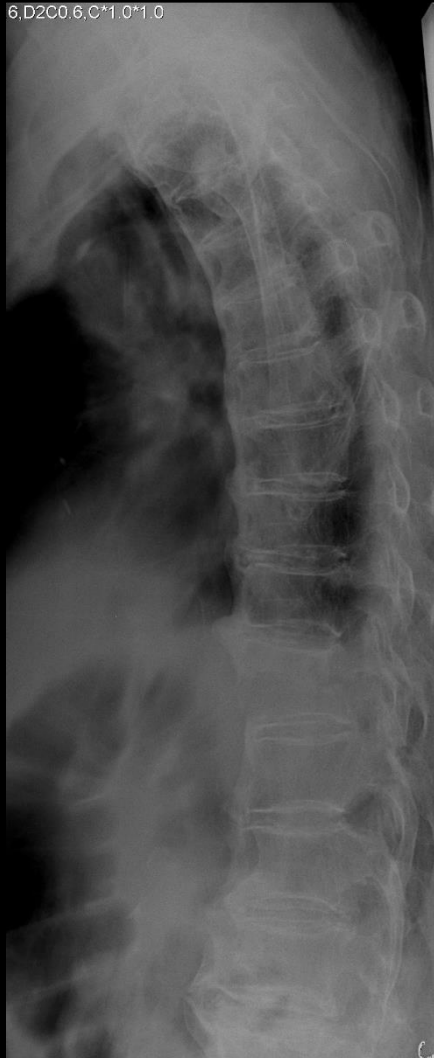

R 2012 / C-2294 / Pictorial review of

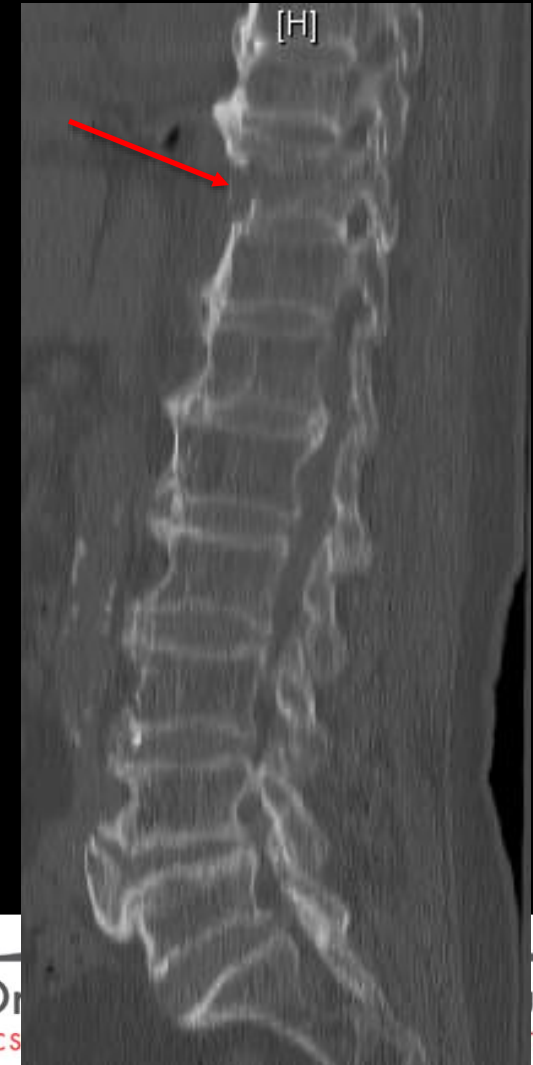Ankylosed spine

85 yo F

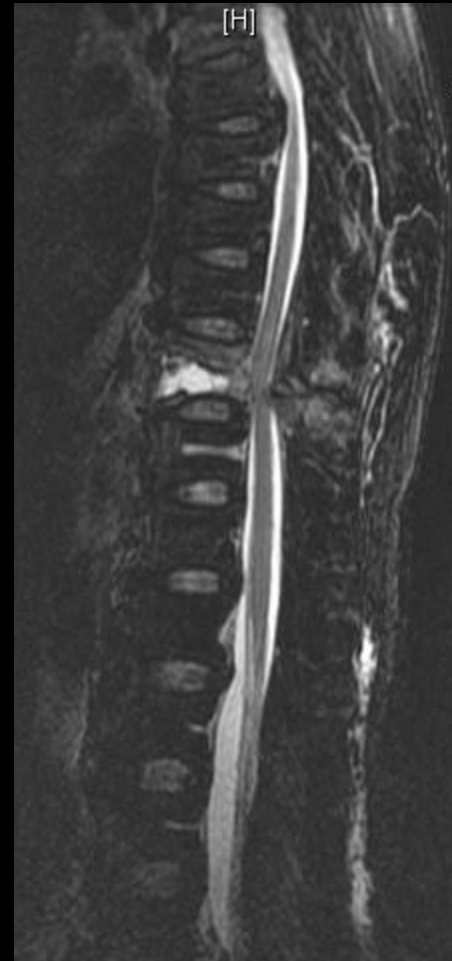
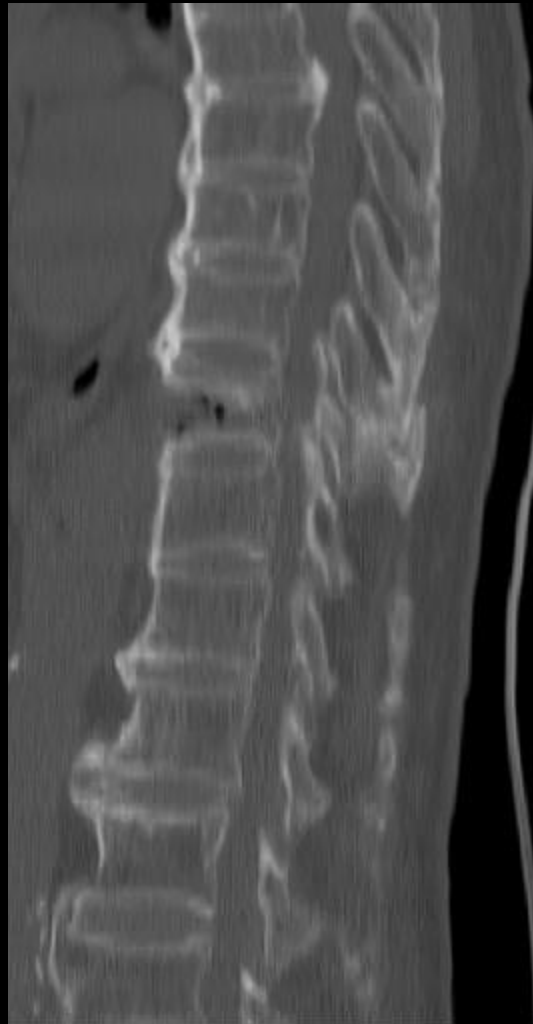6.D2C0.6.C*1.0*1.0



Stiff spine with long lever arm

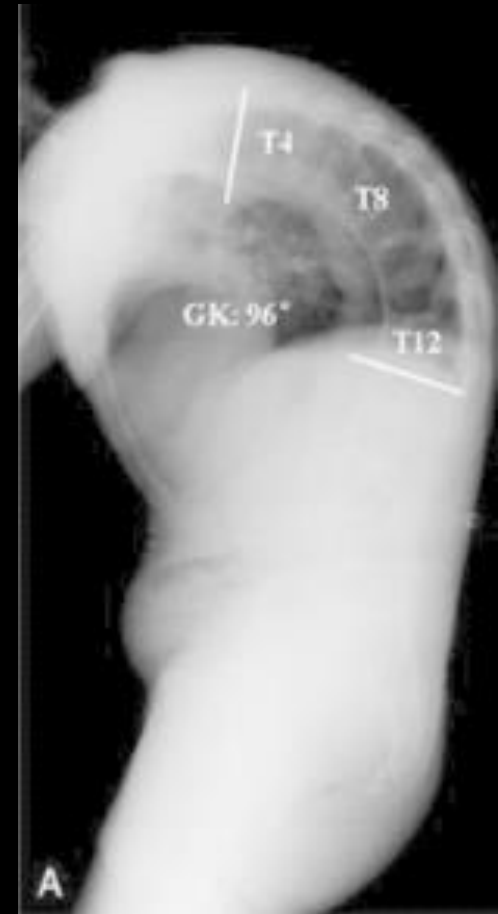


Ankylosed spine



Ankylosed spine

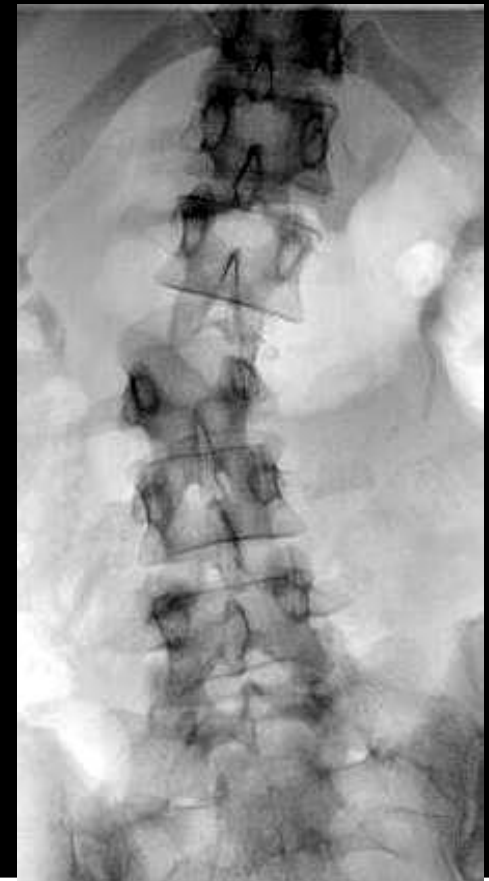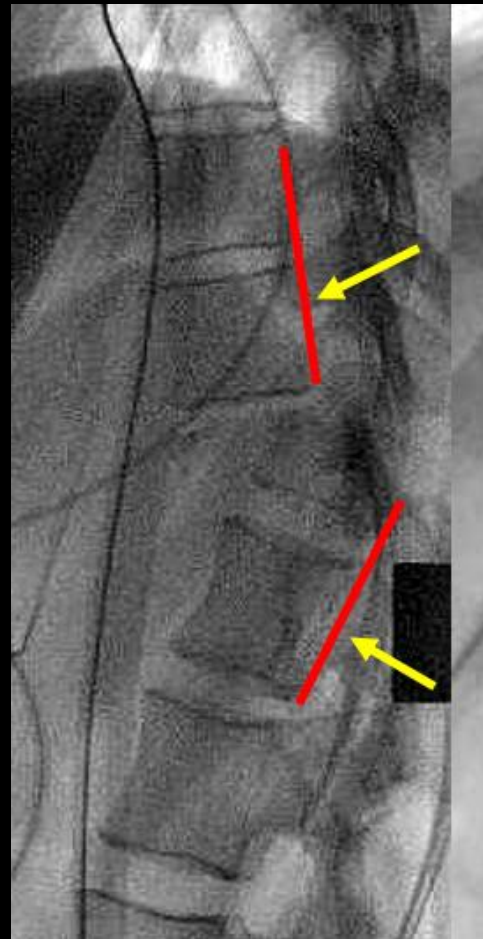
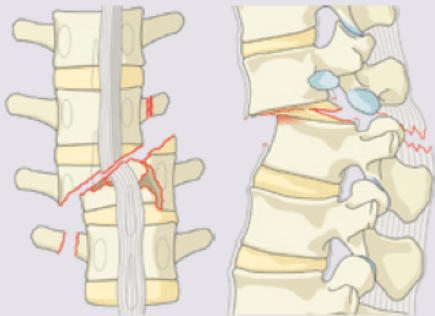
- If presenting with neck or back pain, they have a **fracture until proven otherwise**
- If no fracture seen on CT, obtain **MRI** (so long as they can fit in the MRI scanner)
 - Careful with positioning**
 - These are the patients who go to the MRI intact and come out paraplegic



C-type: Translation Injuries

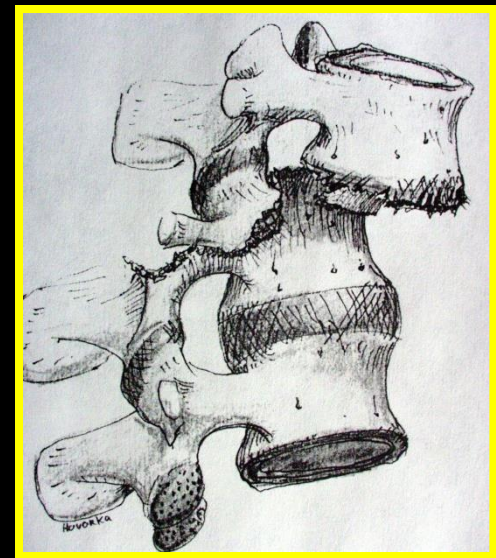
Type C Translation Injuries

C Displacement or dislocation



C-type: Translation Injuries

- Fracture dislocations (rotation or shear)
 - Disruption of all three columns
 - High incidence of **neurologic deficits**
 - Require surgery
 - Long segment fixation



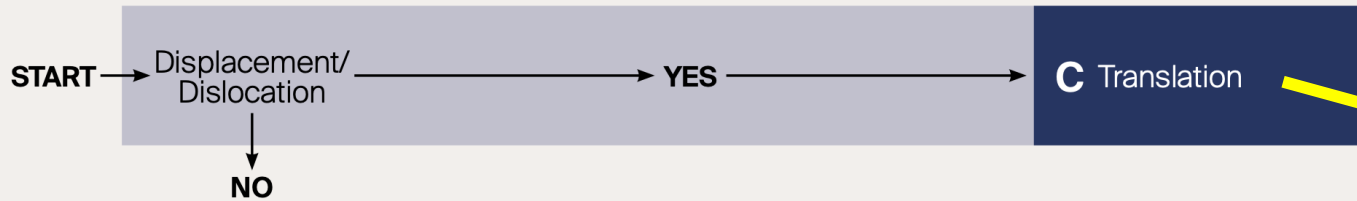
Spinal cord injury

- Reference to injuries above **conus**
- MAPs > 85
- **“Time is spine”**

Neurology

Type	Neurological
N0	Neurology intact
N1	Transient neurologic deficit
N2	Radicular symptoms
N3	Incomplete spinal cord injury or any degree of cauda equina injury
N4	Complete spinal cord injury
NX	Cannot be examined
+	Continued spinal cord compression

Algorithm for morphologic classification

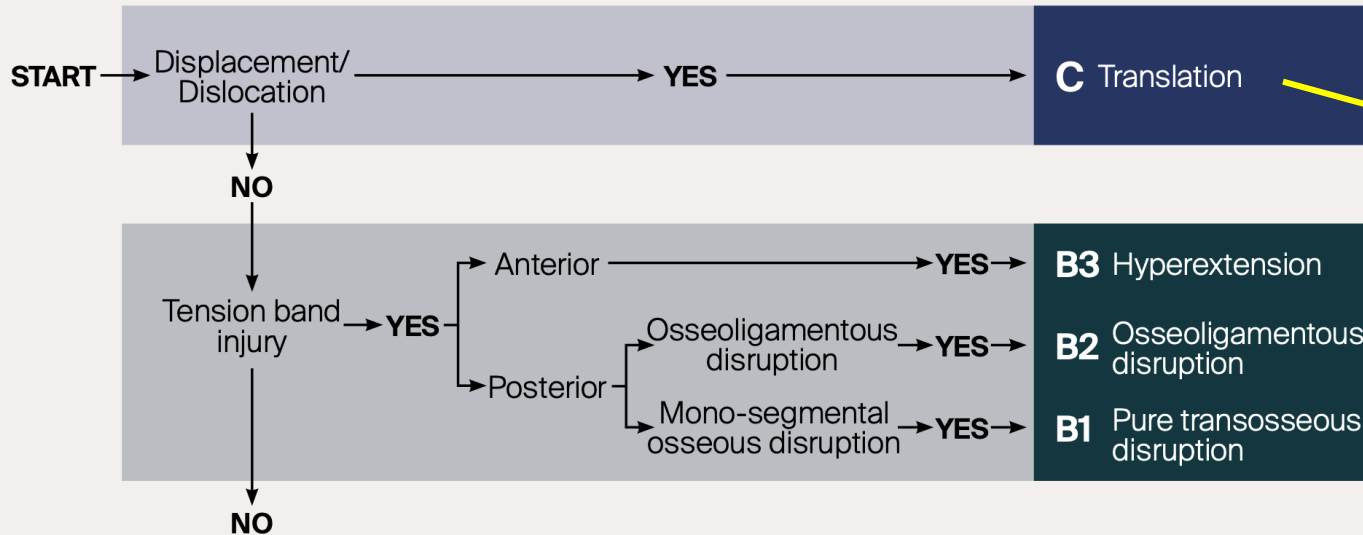


3 Types

- A – Compression
- B – Distraction
- C – Translation

Unstable

Algorithm for morphologic classification



3 Types

A – Compression

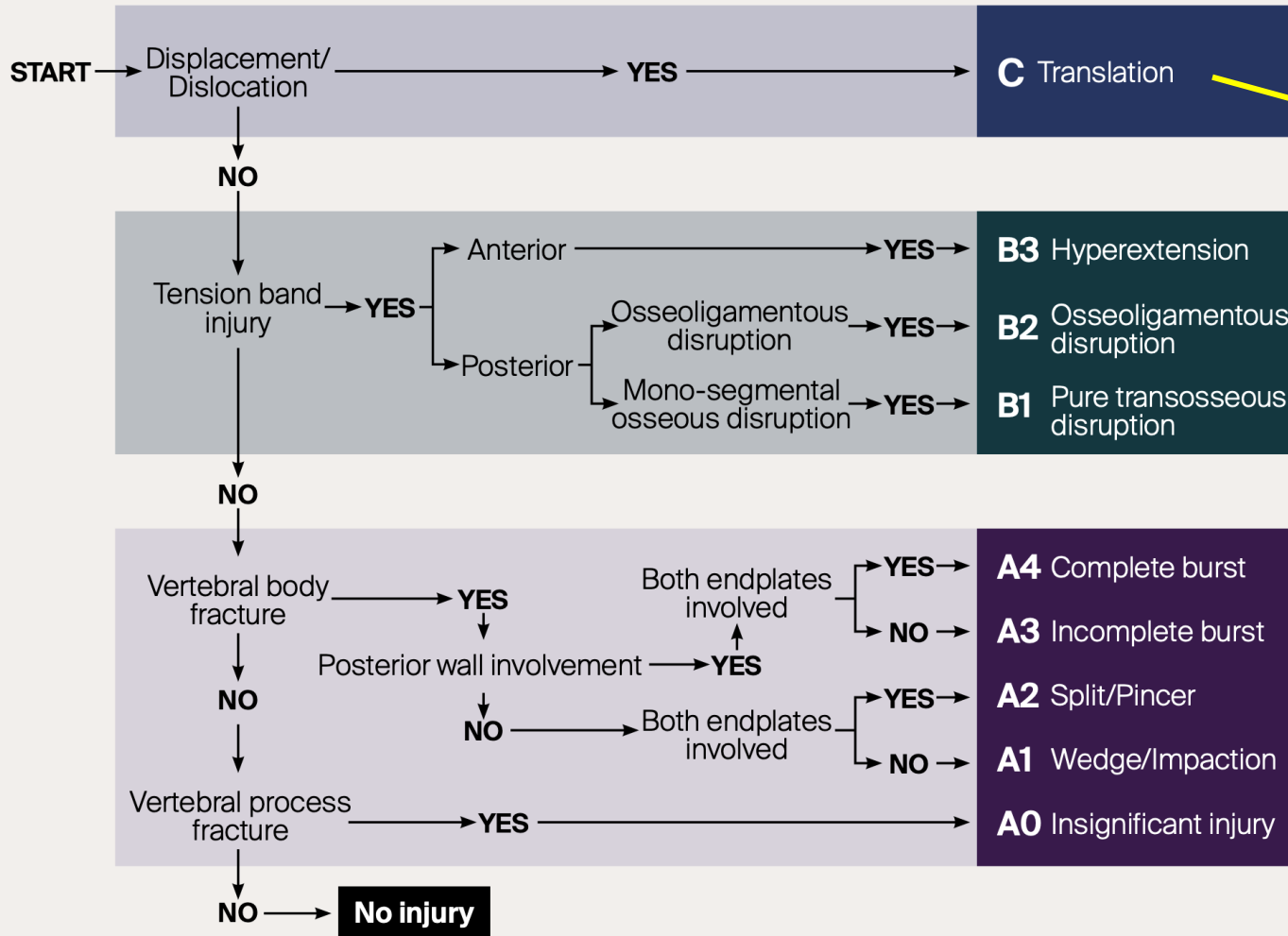
B – Distraction

C – Translation

Unstable

Unstable

Algorithm for morphologic classification



3 Types

- A – Compression
- B – Distraction
- C – Translation

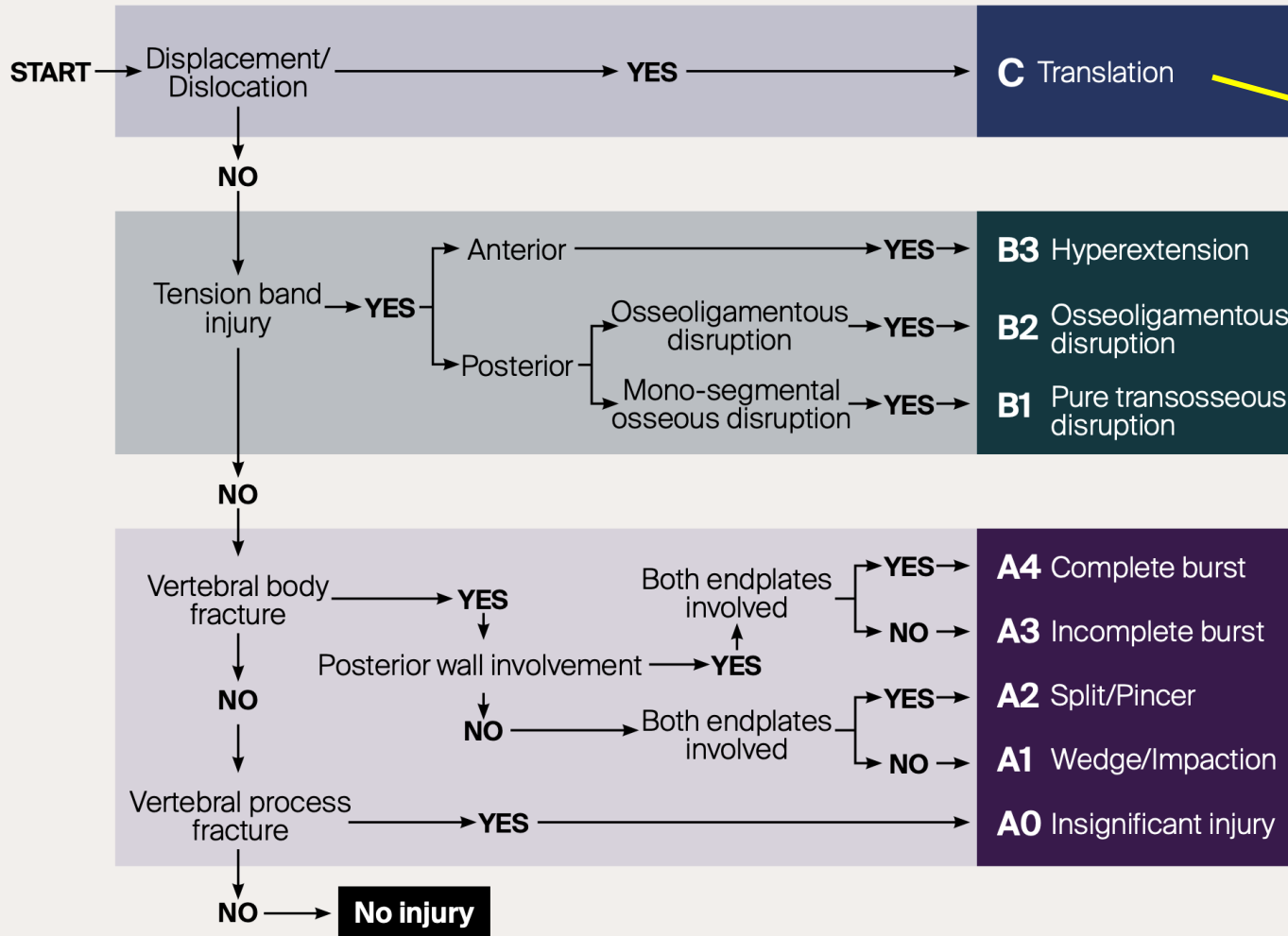
Unstable

Unstable

? Unstable

PLC, alignment/kyphosis, neurologic status

Algorithm for morphologic classification



3 Types

- A – Compression
- B – Distraction
- C – Translation

Unstable

Unstable

? Unstable

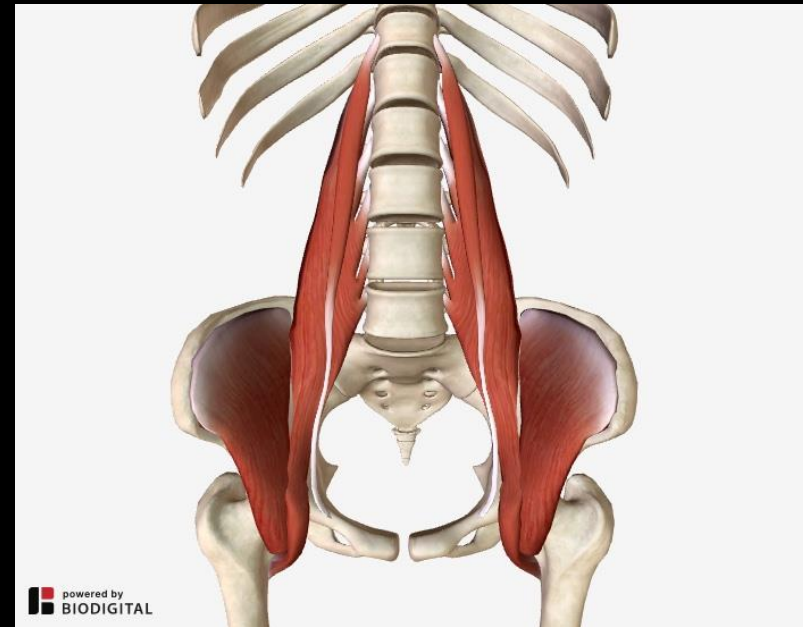
PLC, alignment/kyphosis, neurologic status

Stable*

PLC, alignment/kyphosis, neurologic status

Isolated Transverse Process Fractures

- Inconsequential
- Reminder to look for associated injuries
 - Pelvic ring disruption, visceral injury

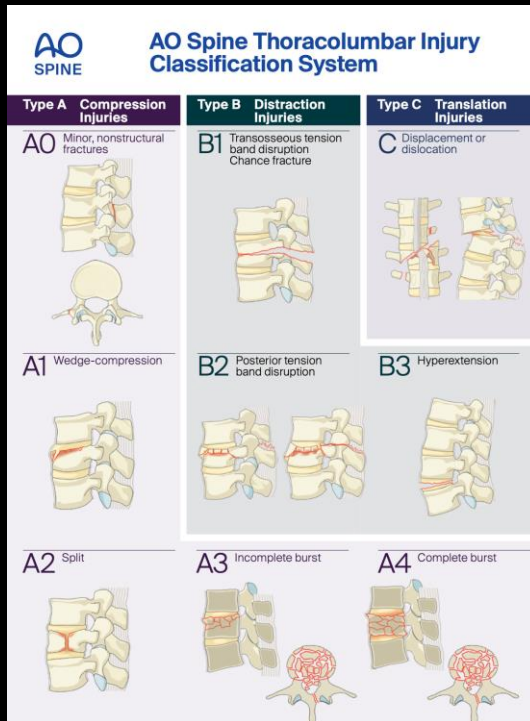


Operative Principles

- **Decompress** what is **compressed**
- **Stabilize** what is **unstable** *Immediate stability*
Prevent late deformity

Operative Principles

- Decompress what is compressed
- Stabilize what is unstable



TLICS 3 independent predictors			
1	Morphology immediate stability	- Compression - Burst - Translation/rotation - Distraction	1 2 3 4 - Radiographs - CT
2	Integrity of PLC longterm stability	- Intact - Suspected - Injured	0 2 3 - MRI
3	Neurological status	- Intact - Nerve root - Complete cord - Incomplete cord - Cauda equina	0 2 2 3 3 - Physical examination
Predicts		- Need for surgery	0-3 4 > 4 - nonsurgical - surgeon's choice - surgical

Thank You!