

Distal Femur Fractures: A Stepwise Approach to Fixation

Andrew H. Schmidt, M.D.

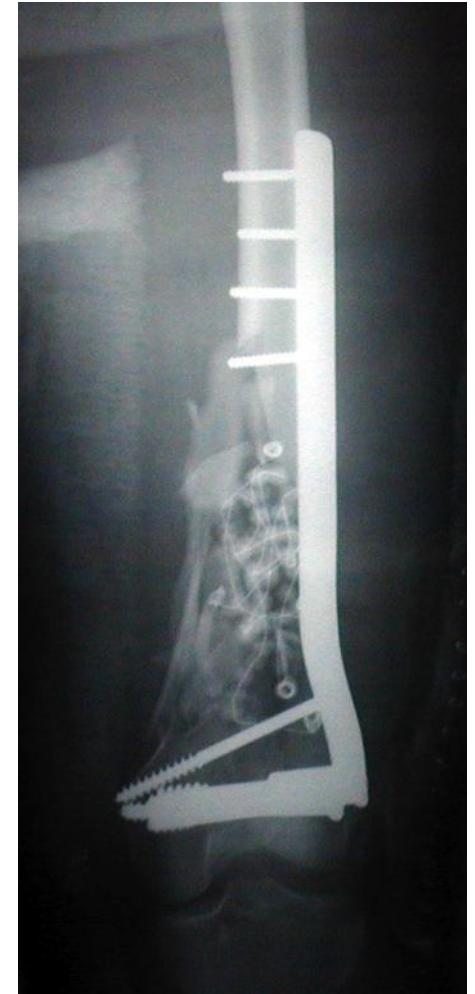Hennepin County Medical Center

University of Minnesota

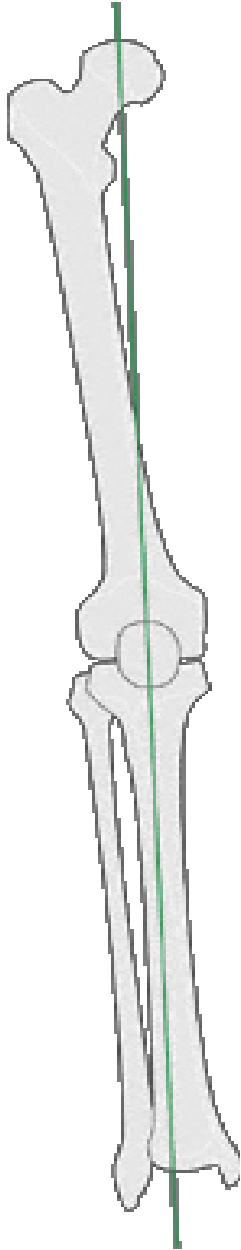


Distal Femur Fractures

- *Relatively non-controversial injury*
 - Well understood fracture patterns
 - Operative indications defined
 - Treatment principles straightforward




Goals



- Reconstruction of the articular surface
- Restoration of the mechanical axis
 - Length, alignment, rotation
- Stable fixation
- Early return of function

A Stepwise Approach

- 
- Assess the patient and the injury
 - Reconstruction of the articular surface
 - Simple to complex
 - What exposure is needed and how is that achieved?
 - Restoration of the mechanical axis
 - Length, alignment, rotation
 - Stable fixation
 - Of what type?
 - Rehab

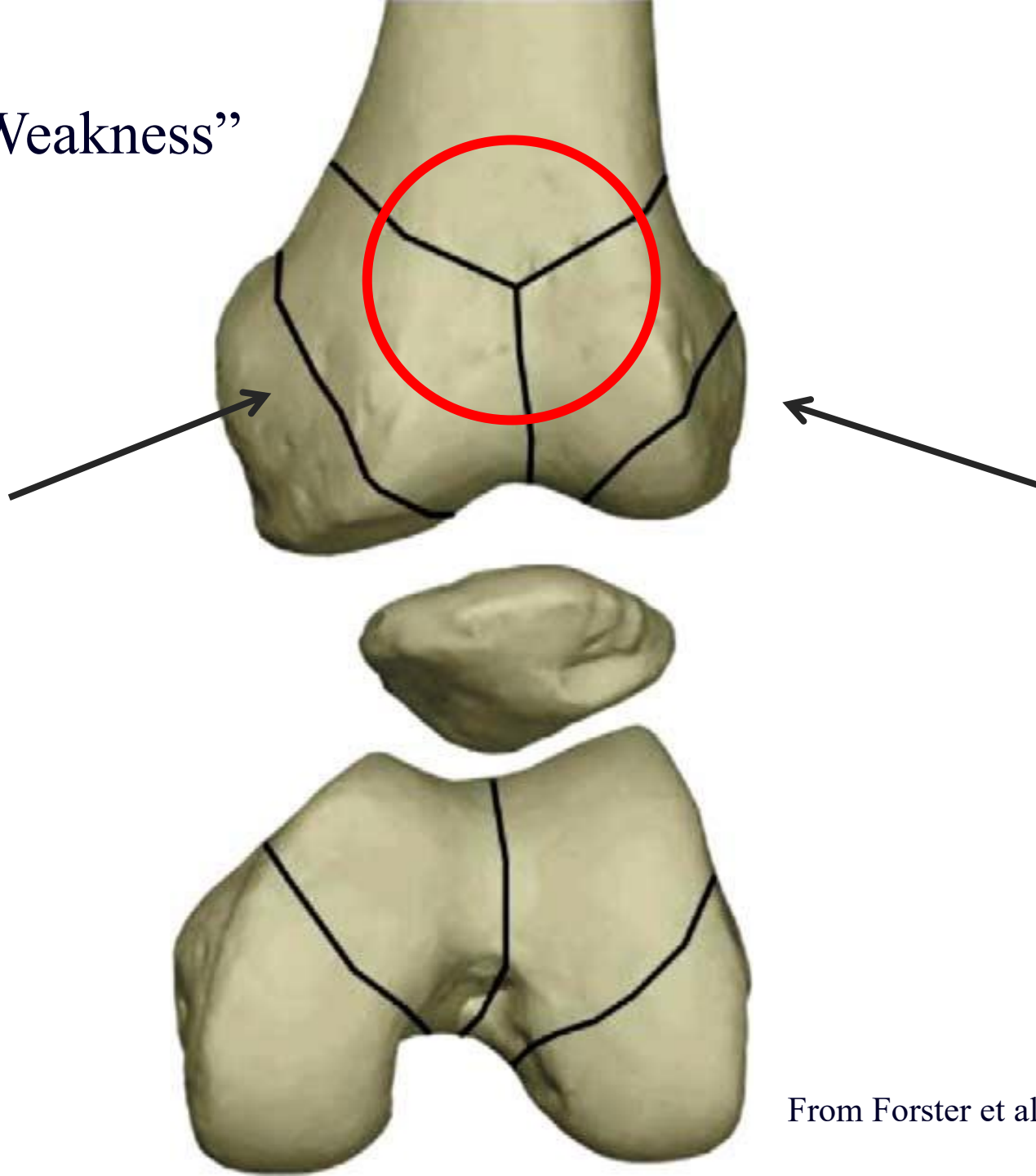
Initial Assessment

- AP & Lateral images of femur and tibia
- CT scan when articular injury
 - Define intra-articular component.

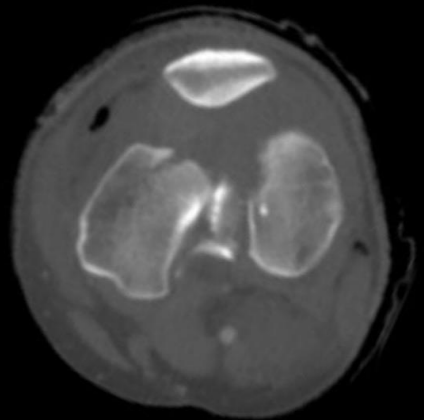
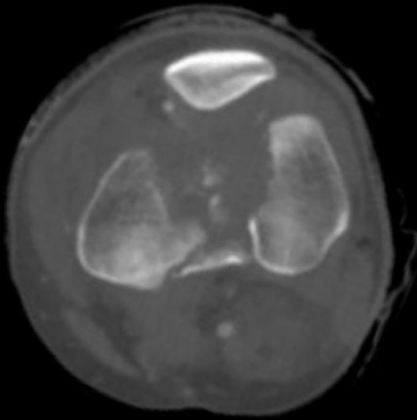
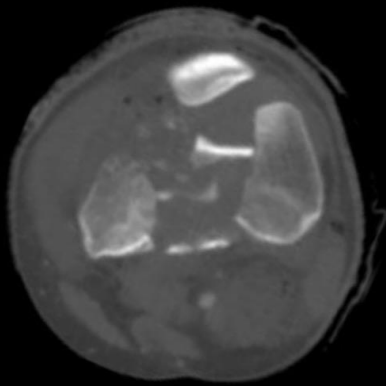
Be sure to note:

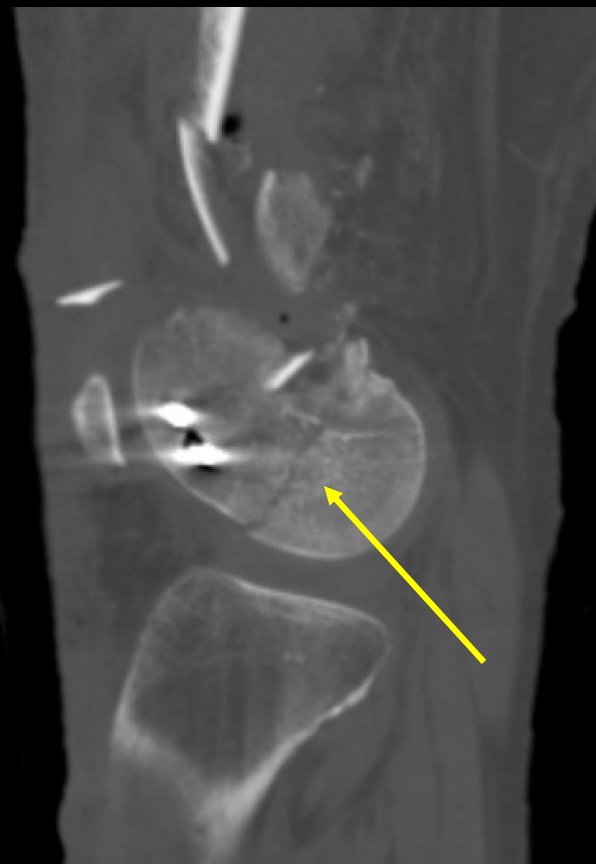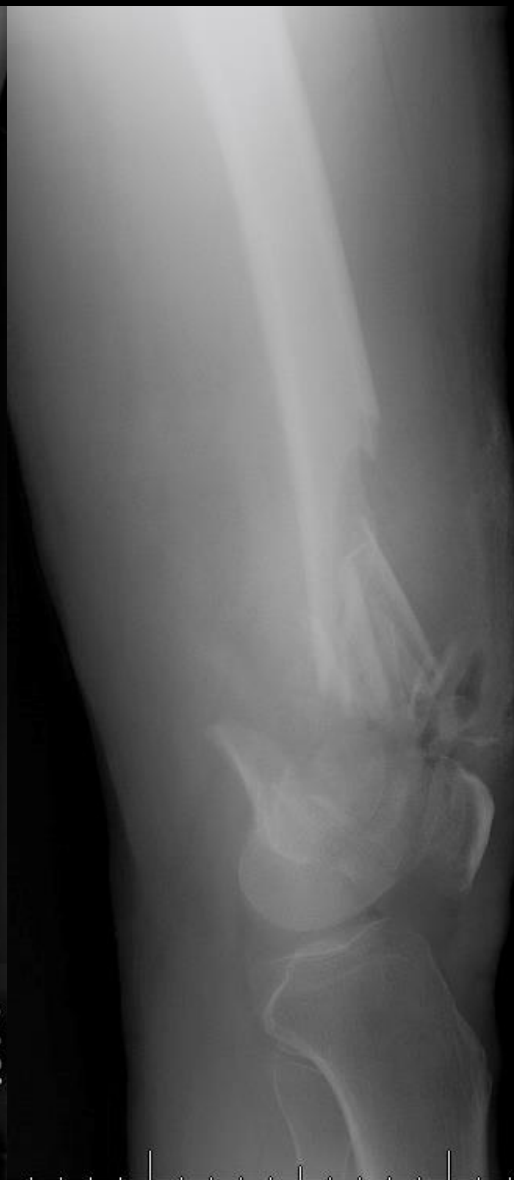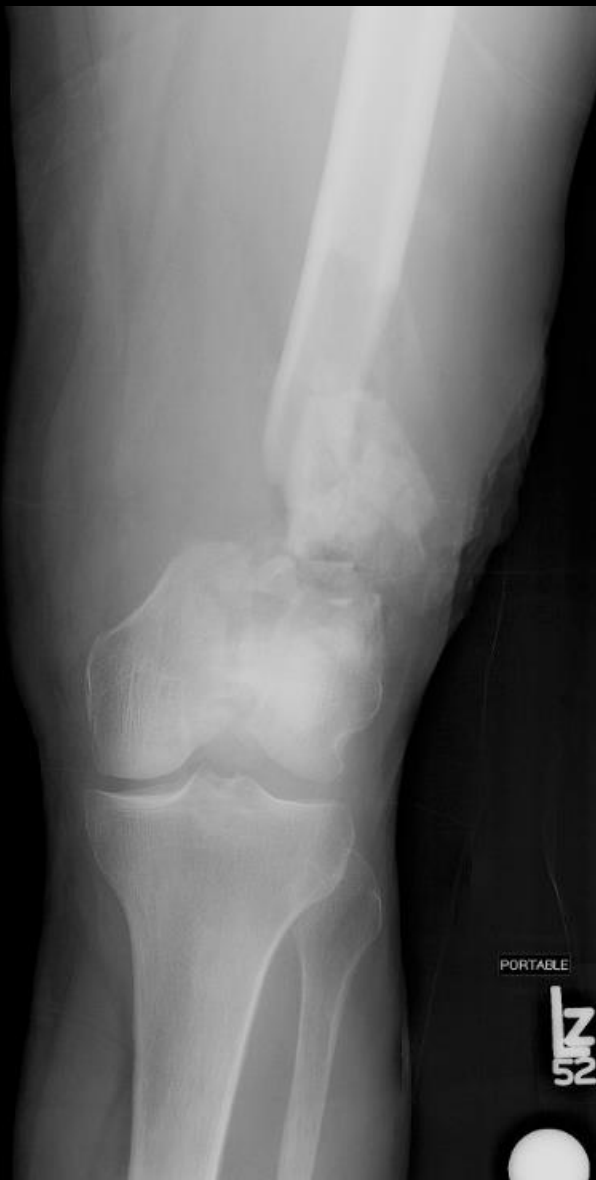- Is there a Hoffa fragment on either side?
- Is there comminution in the trochlea or intercondylar notch?

“Lines of Weakness”



From Forster et al, Injury, 2005



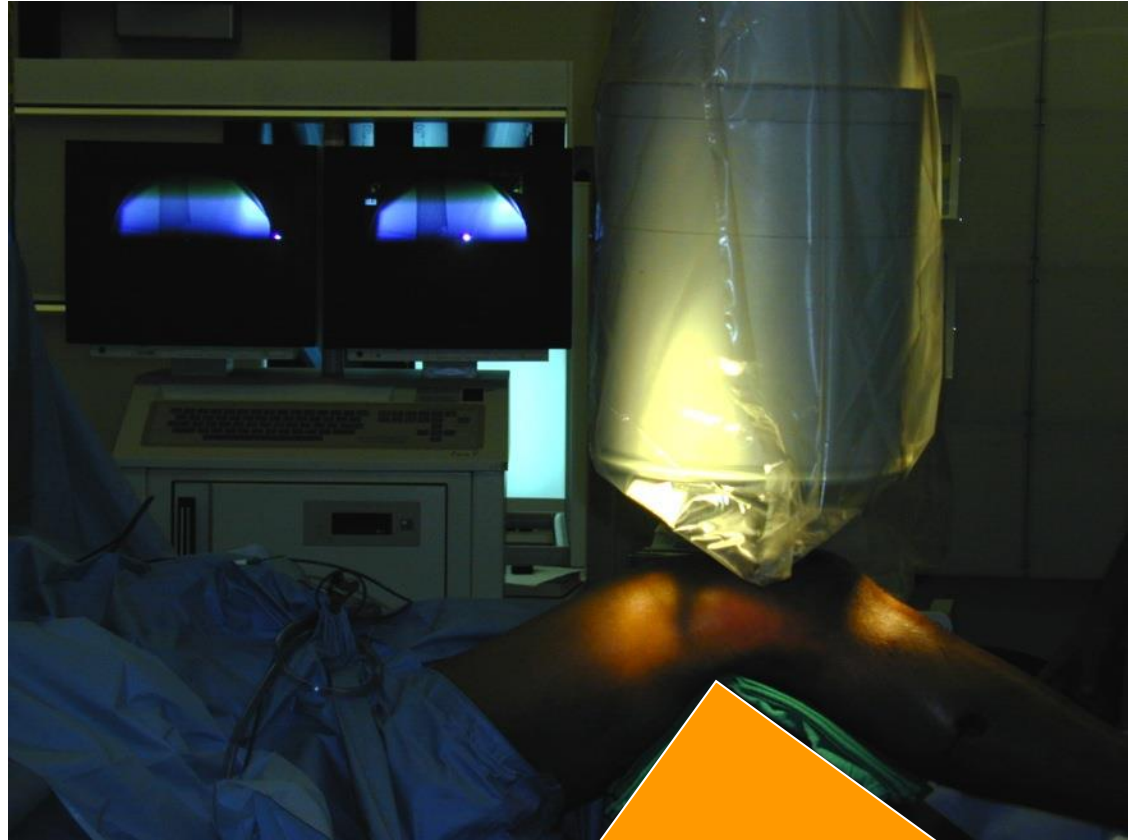


Restoring the “Knee”

- Fix the Articular Block
 - Reduce with Clamps or K-wires
 - Interfragmentary screws
 - One plane
 - Multiplanar

Surgical Technique

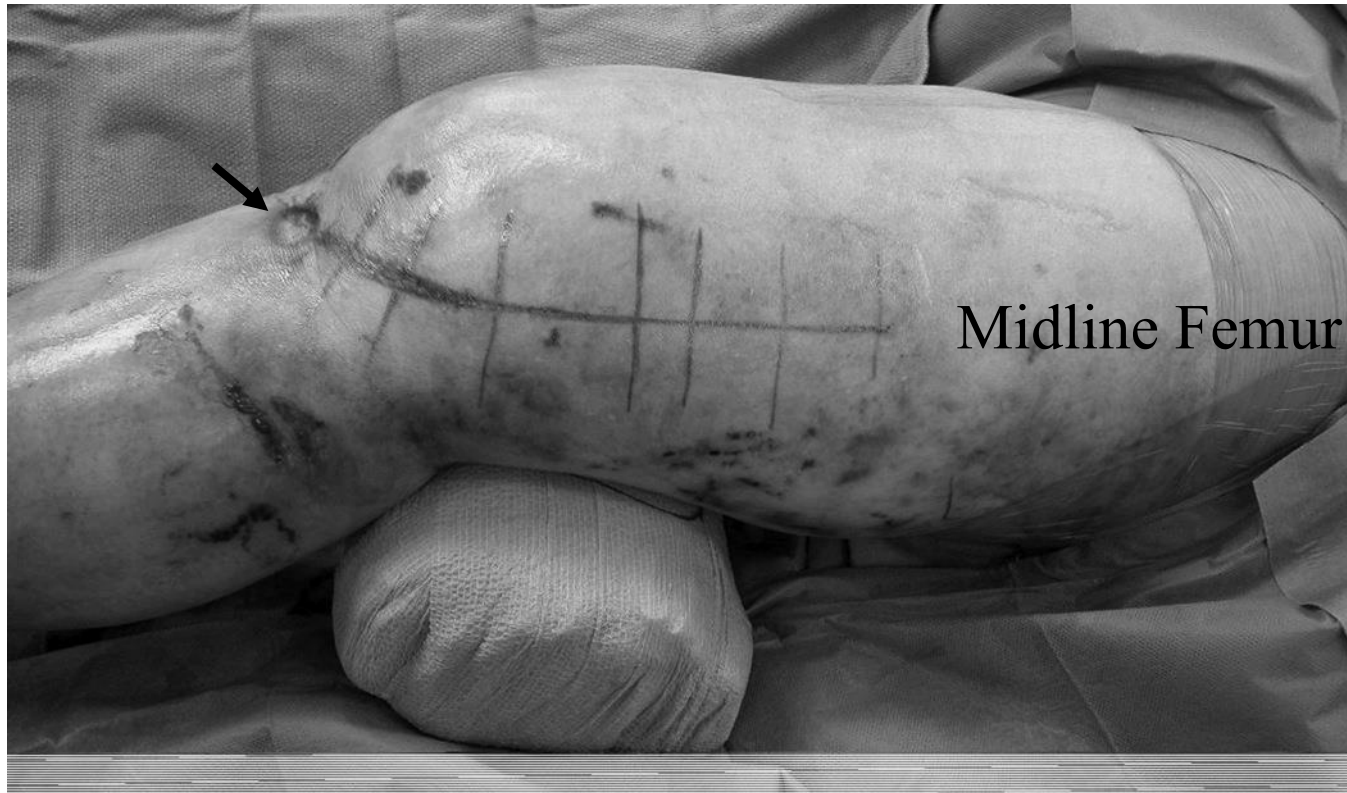- Radiolucent table, supine position.
- Triangle
- Femoral distractor.

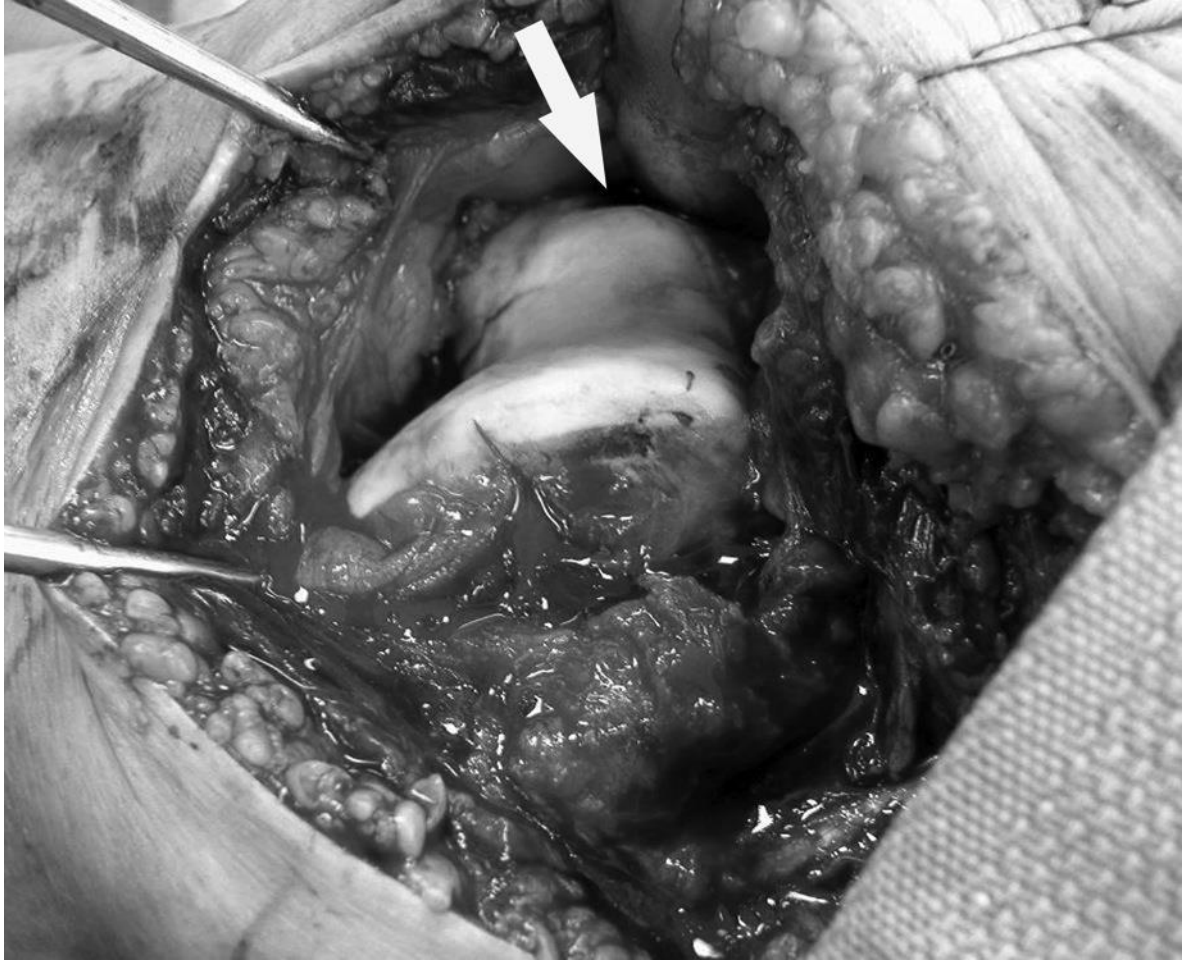

Surgical Approach

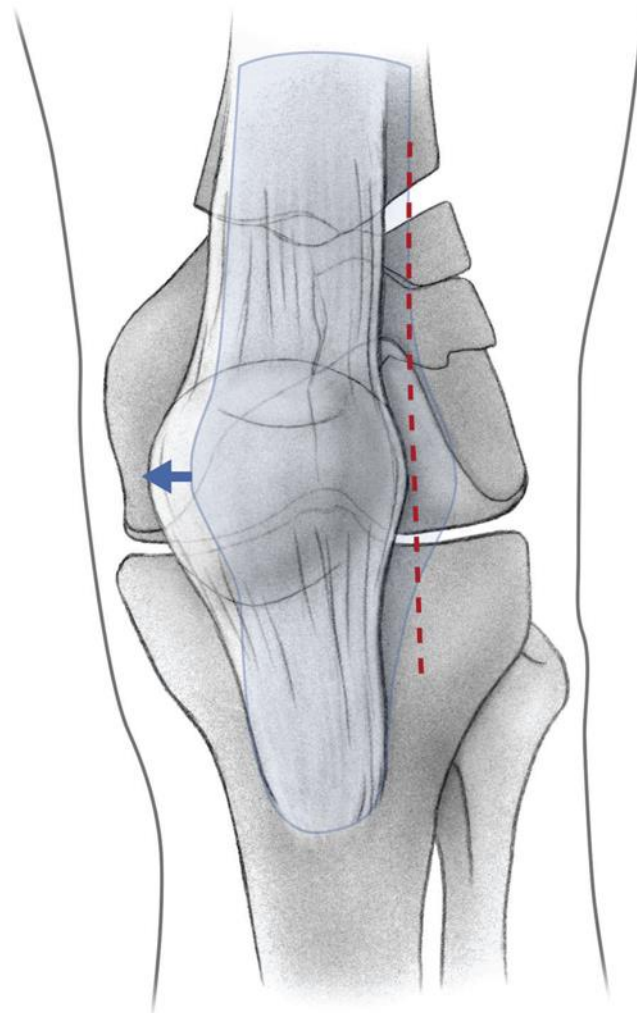
- 2 primary choices for incision
 - Lateral: Simple Fractures
 - Anterior / Lateral (peripatellar): Complex Fractures
 - Tubercle osteotomy (rarely needed)

Anterolateral Approach



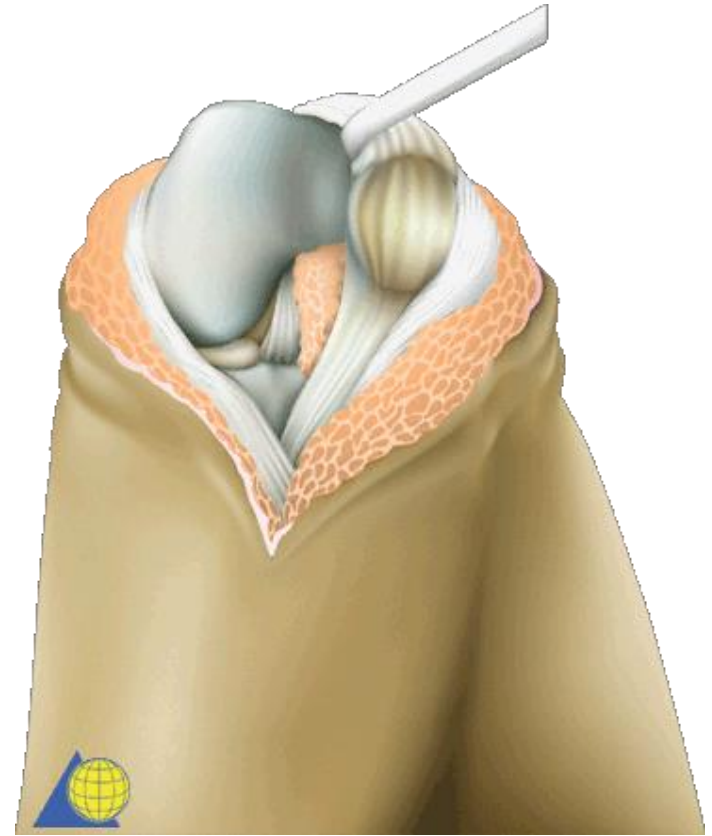
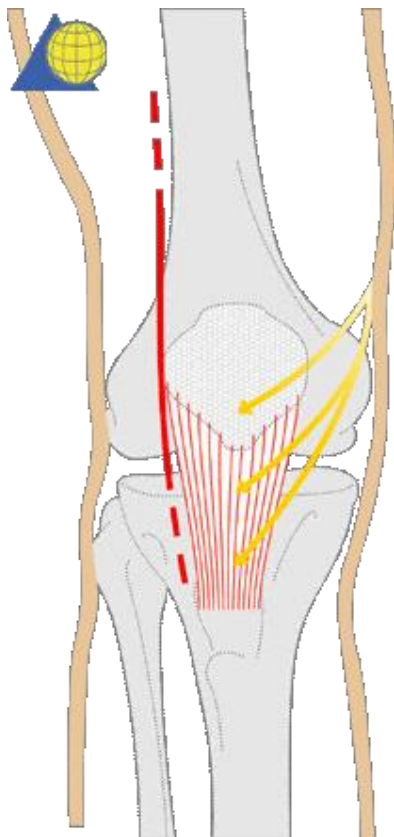


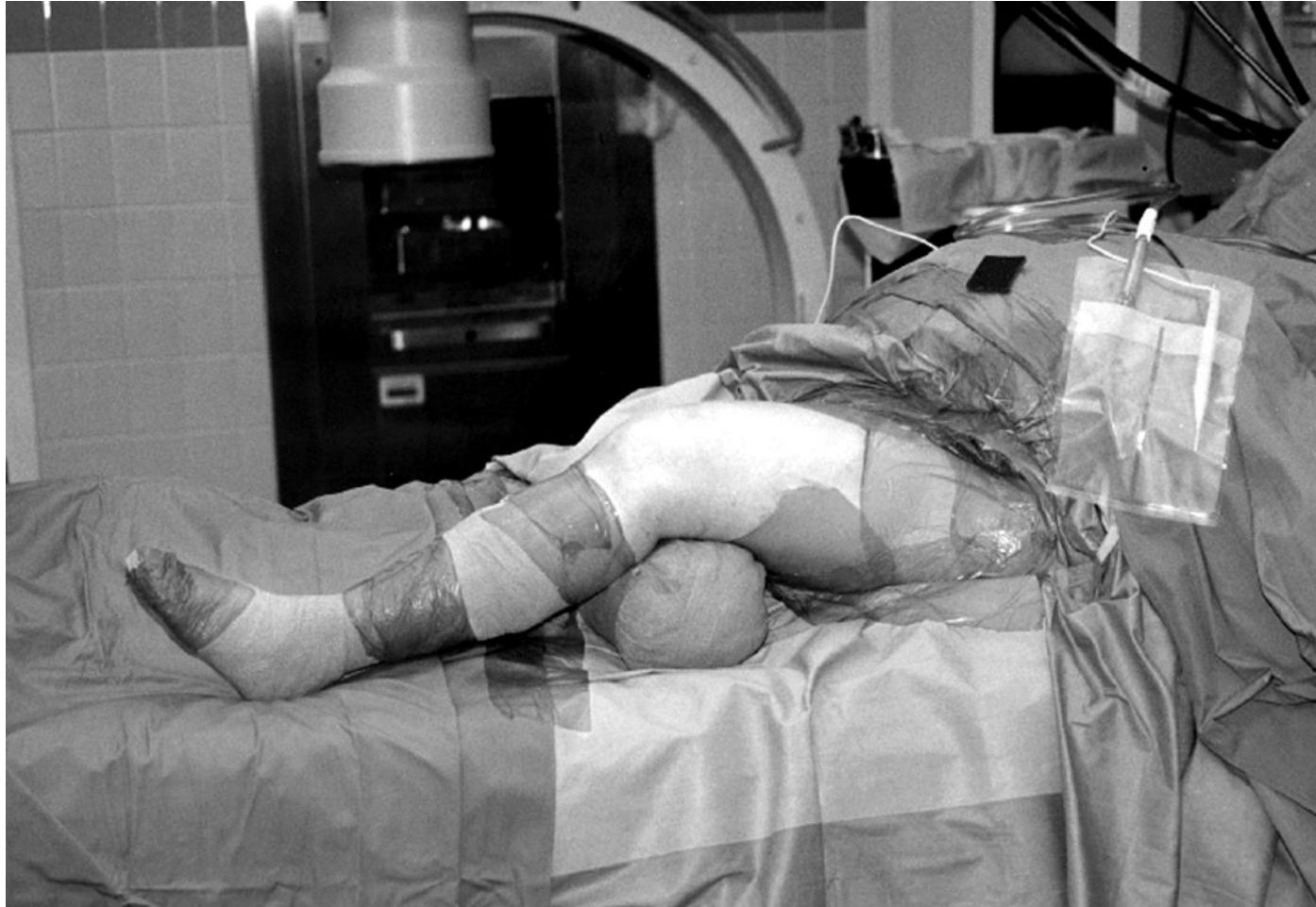
Lateral Peripatellar Approach

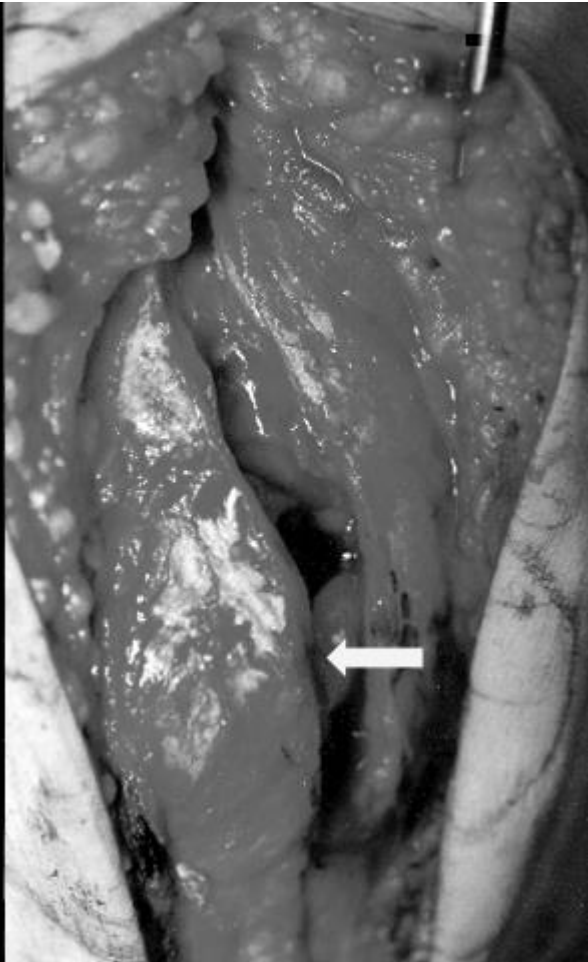
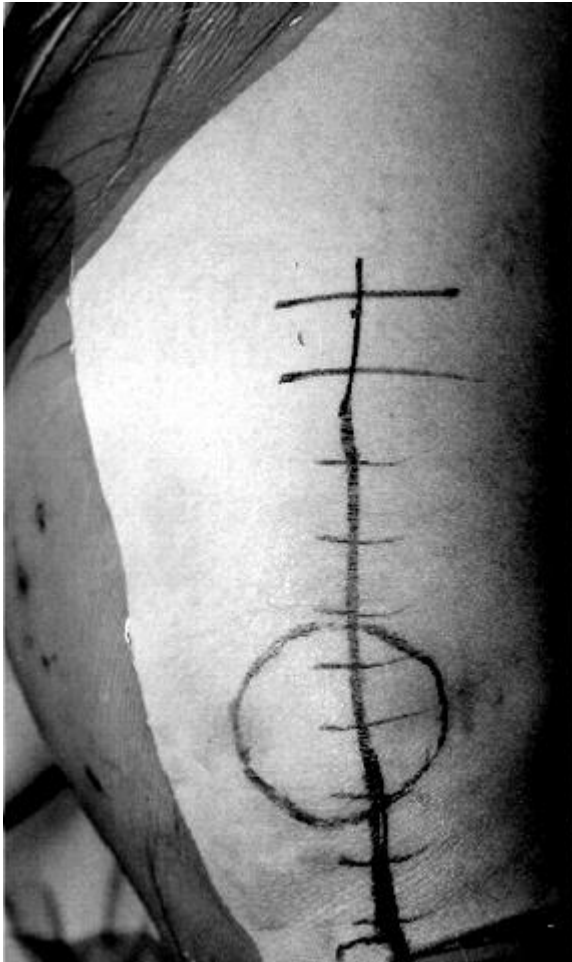

From Haidukewych et al, JBJS 2008 90A Suppl 2(1): 120

Lateral Peripatellar Approach

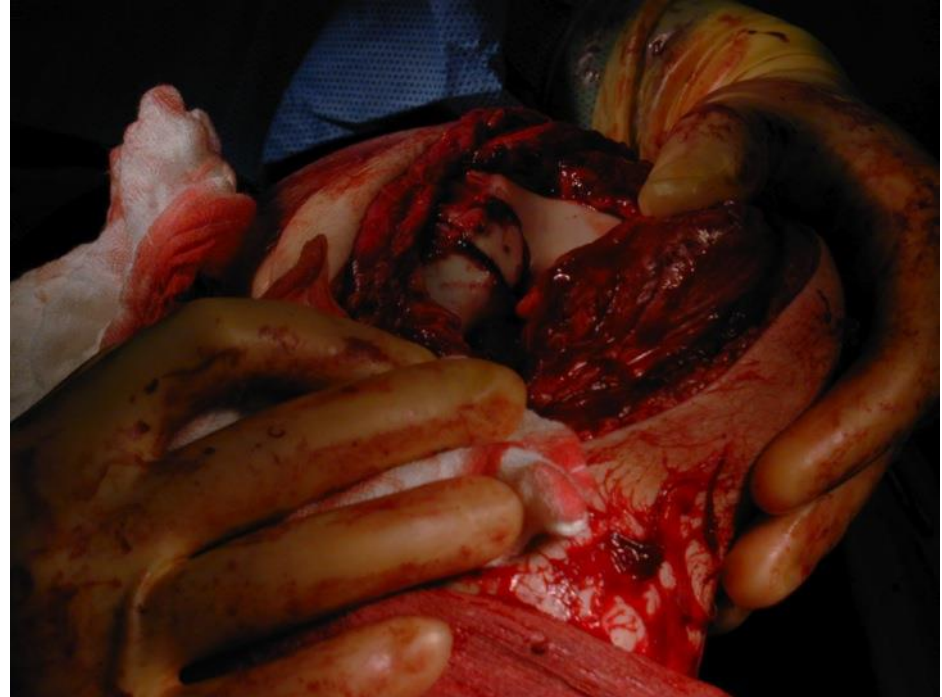



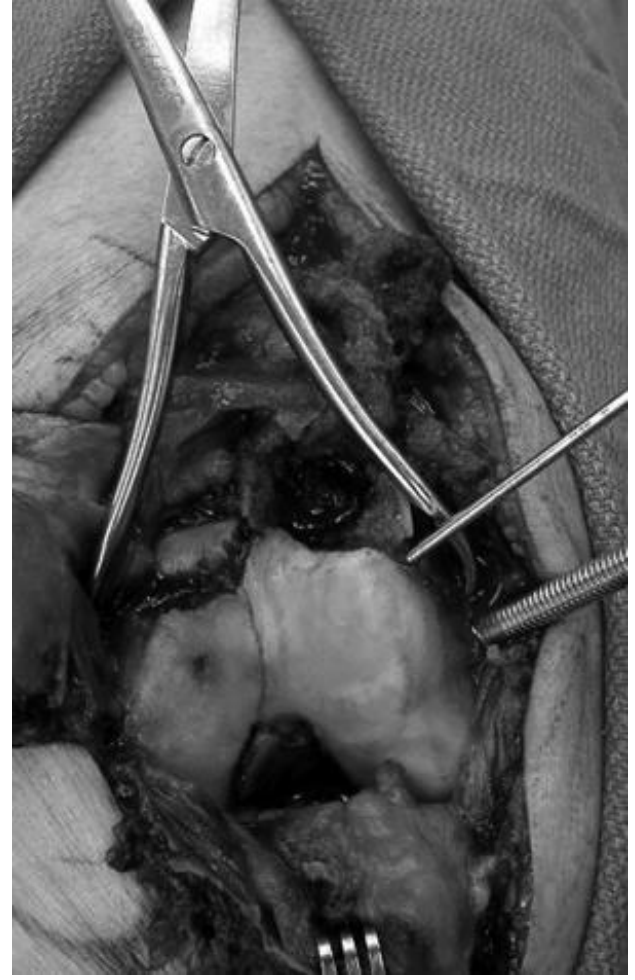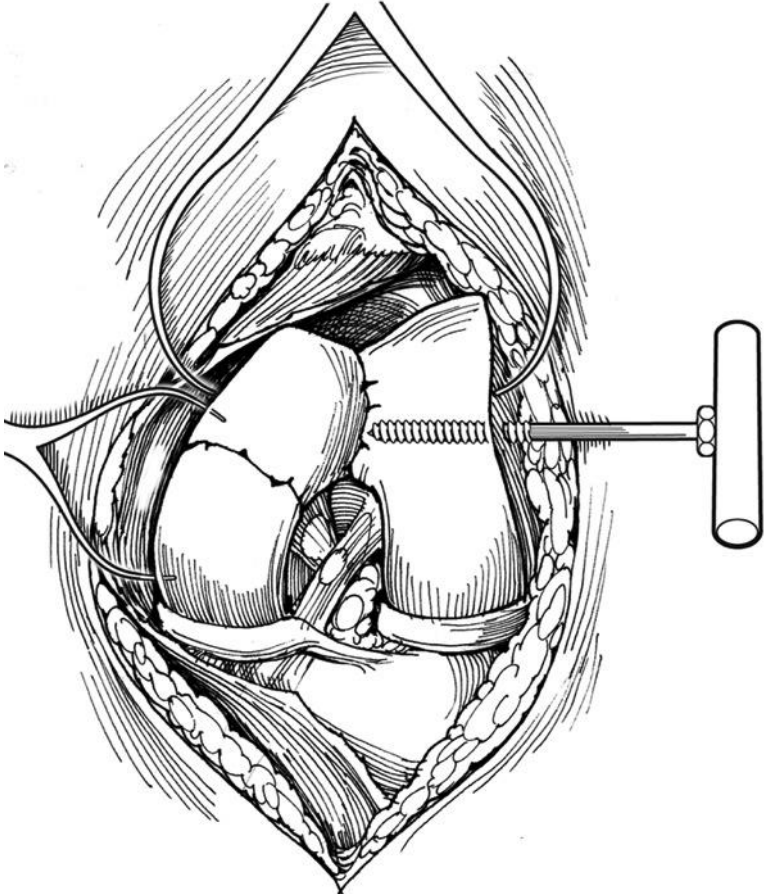


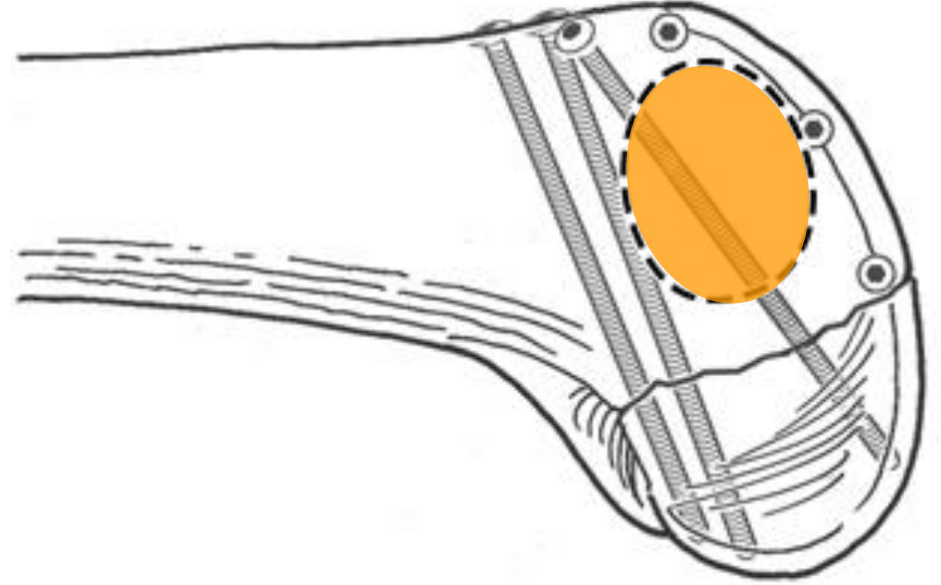
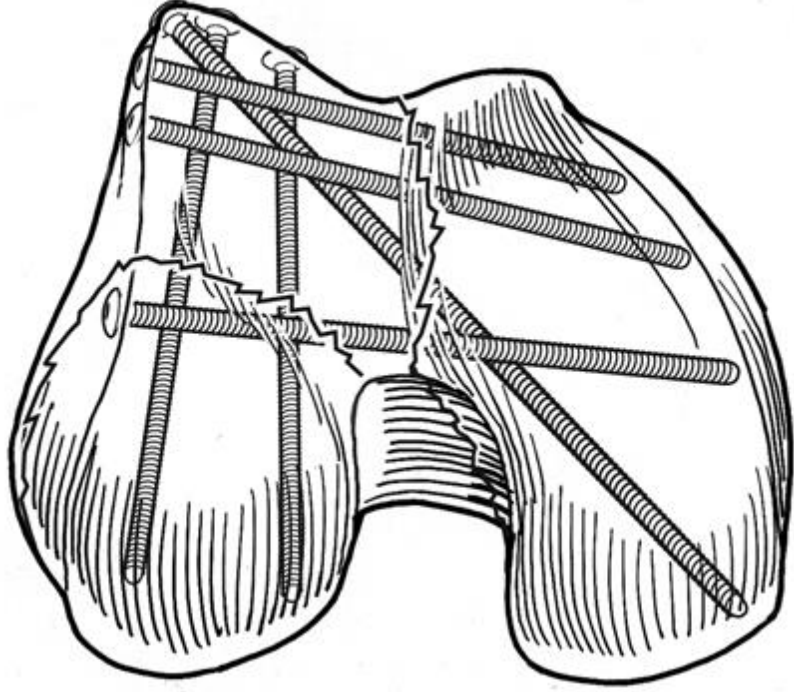
Step 1: Articular Reconstruction

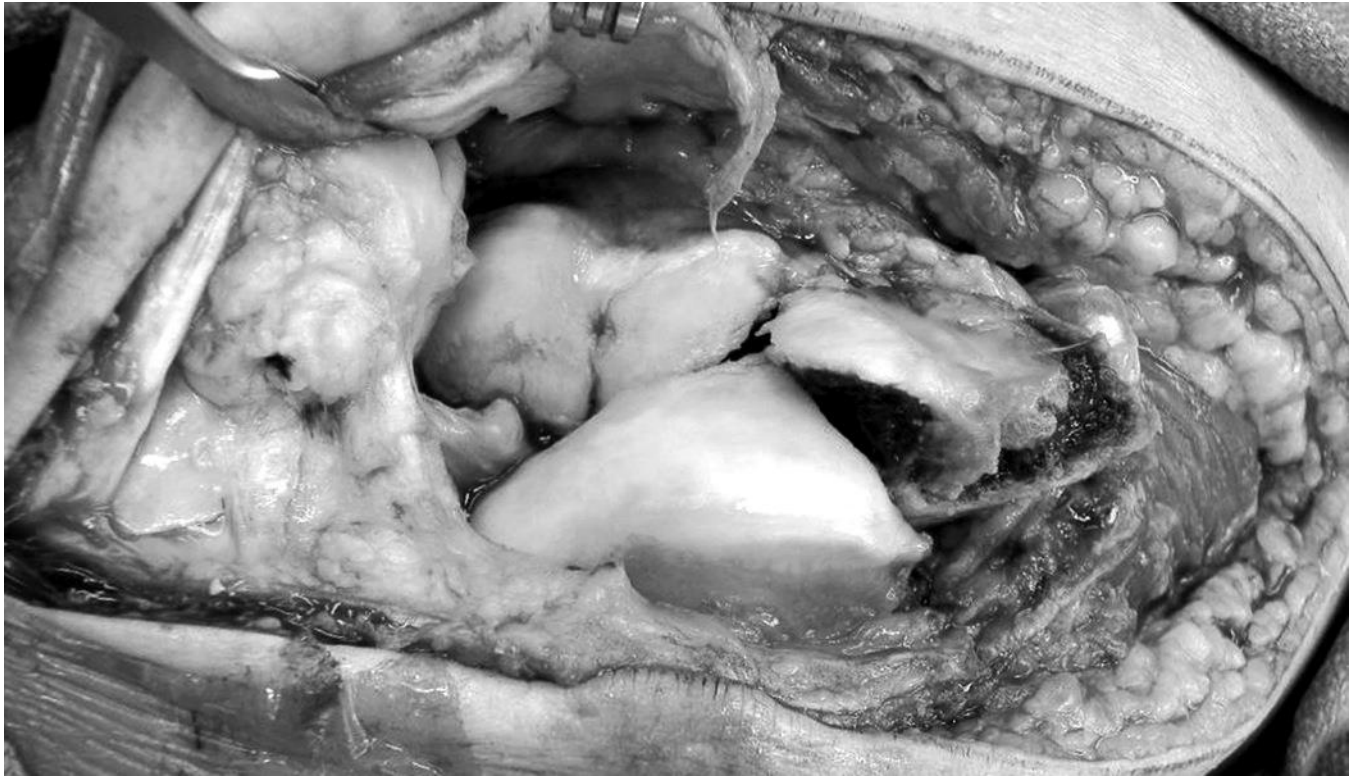- Goal is anatomic restoration of the articular surface

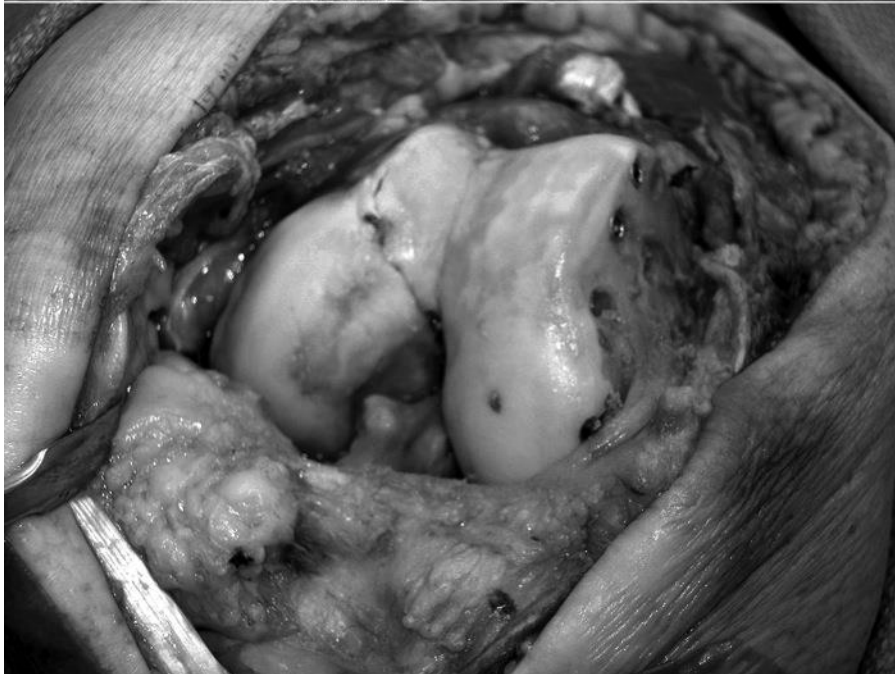
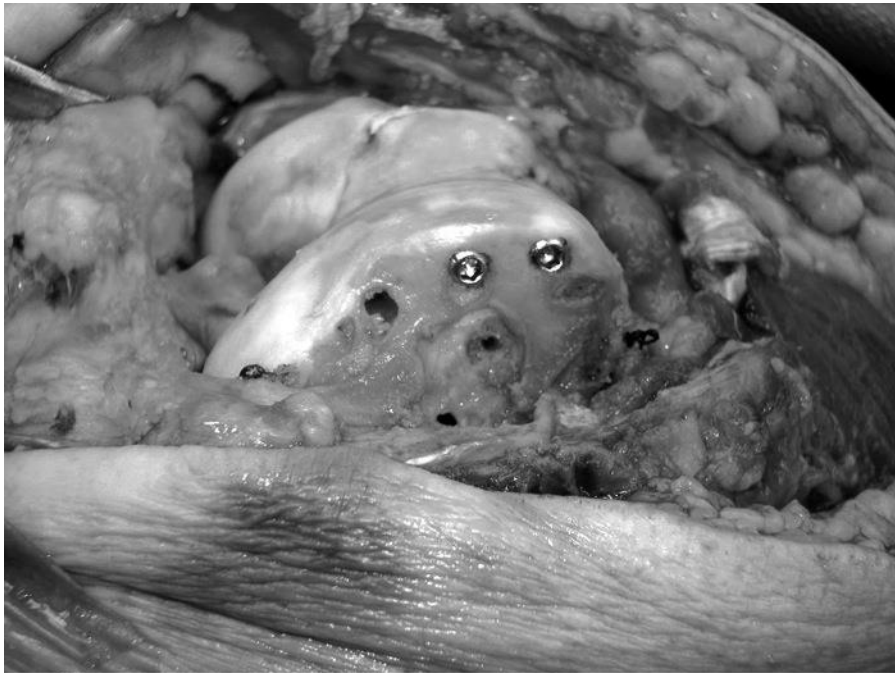
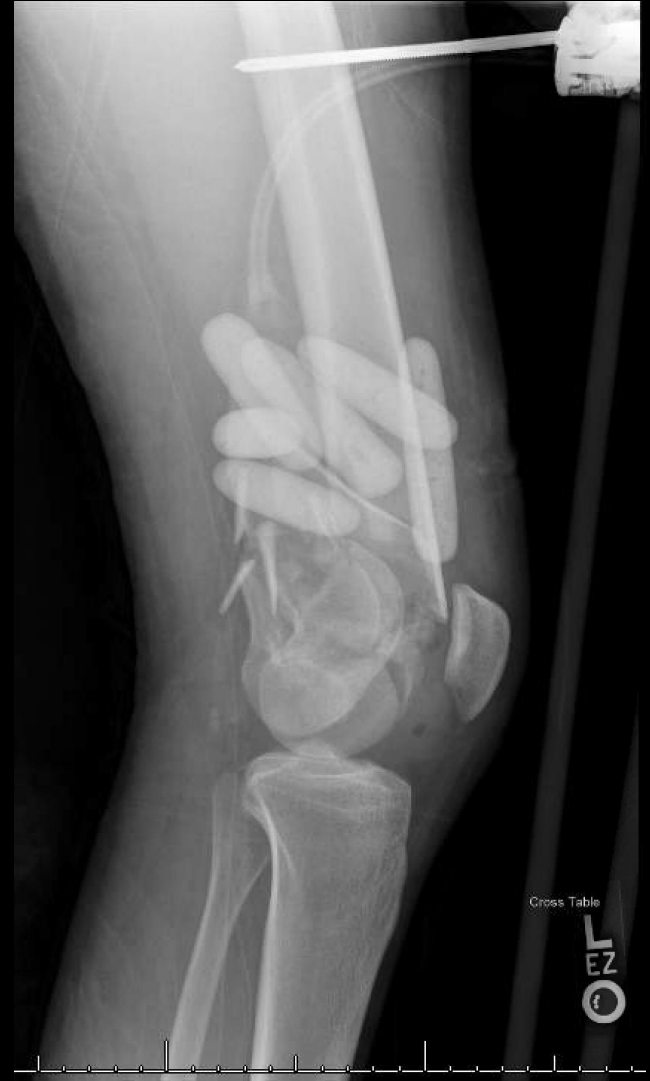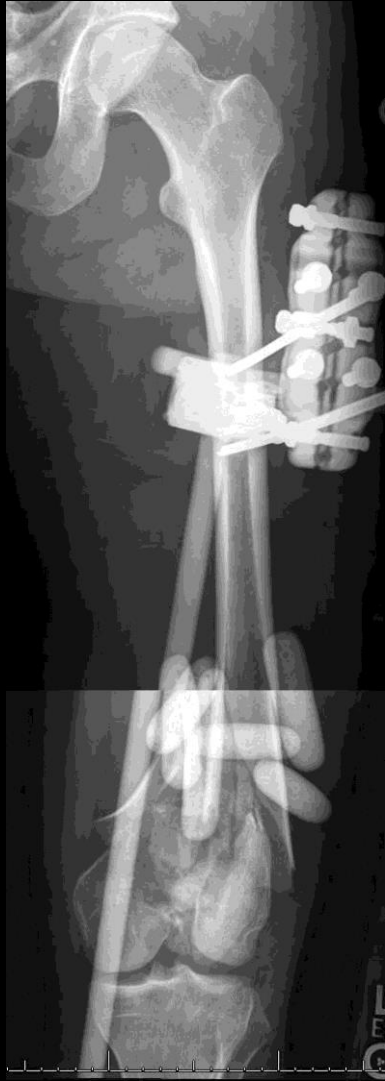Reduction Aids

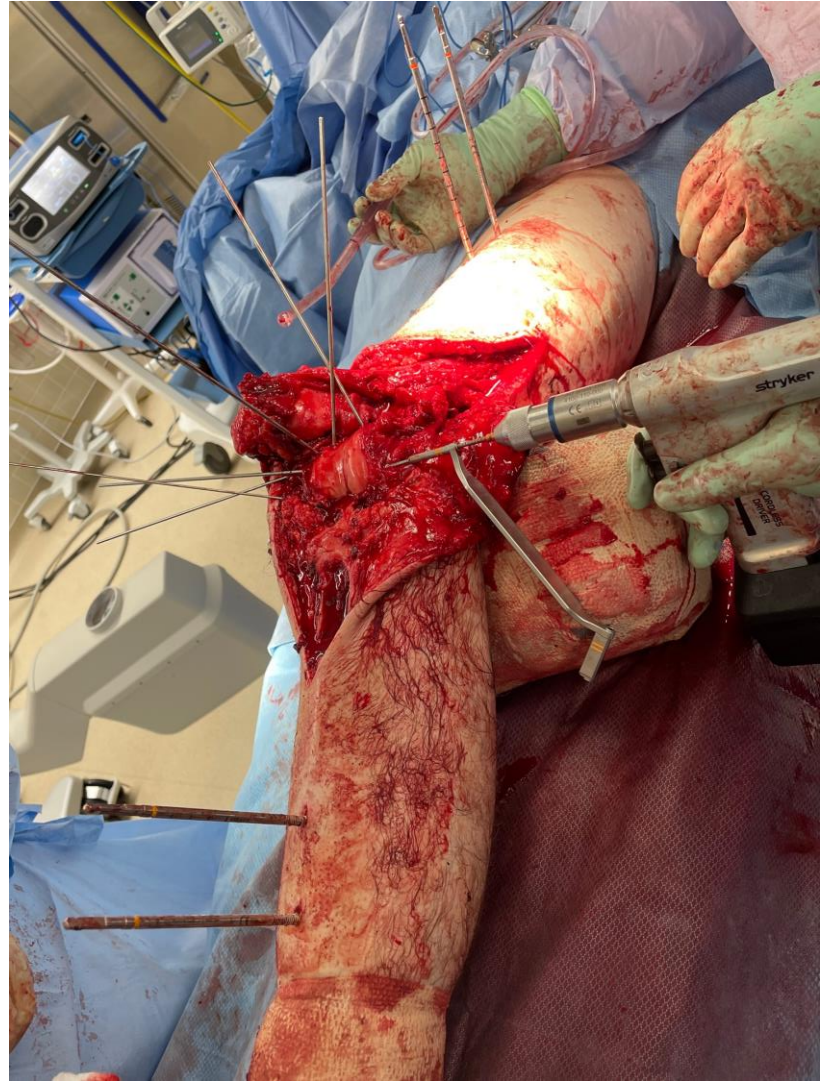
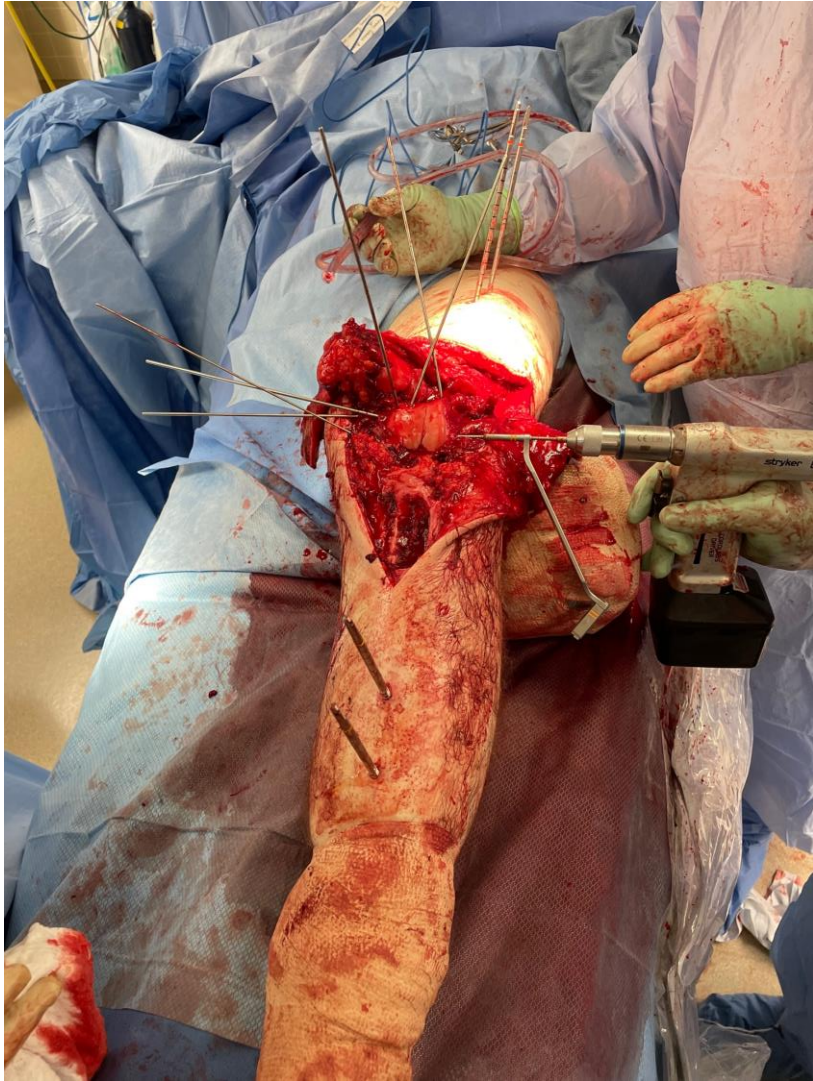


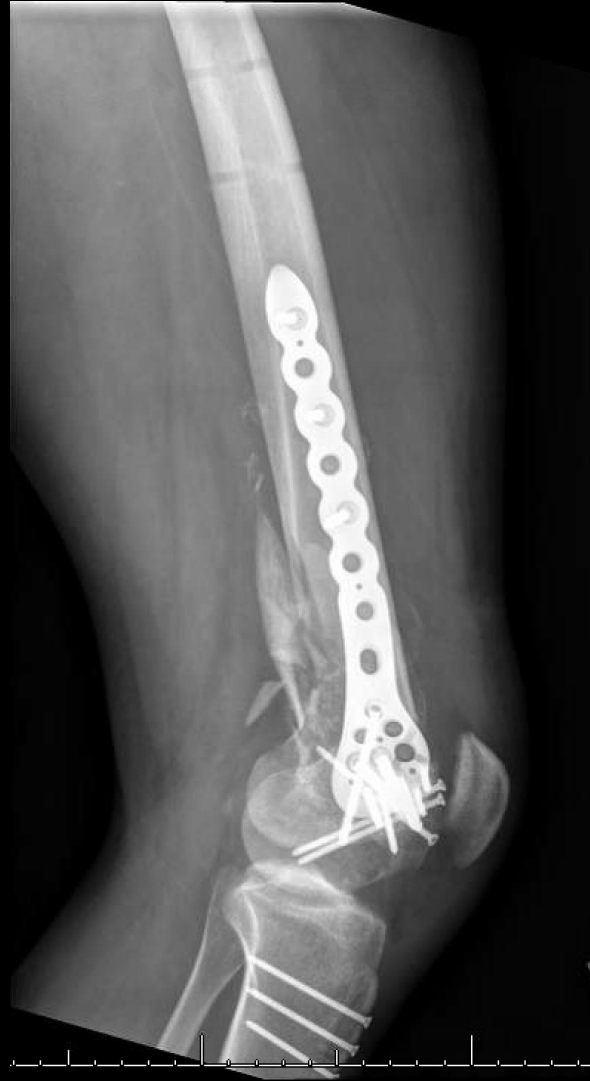
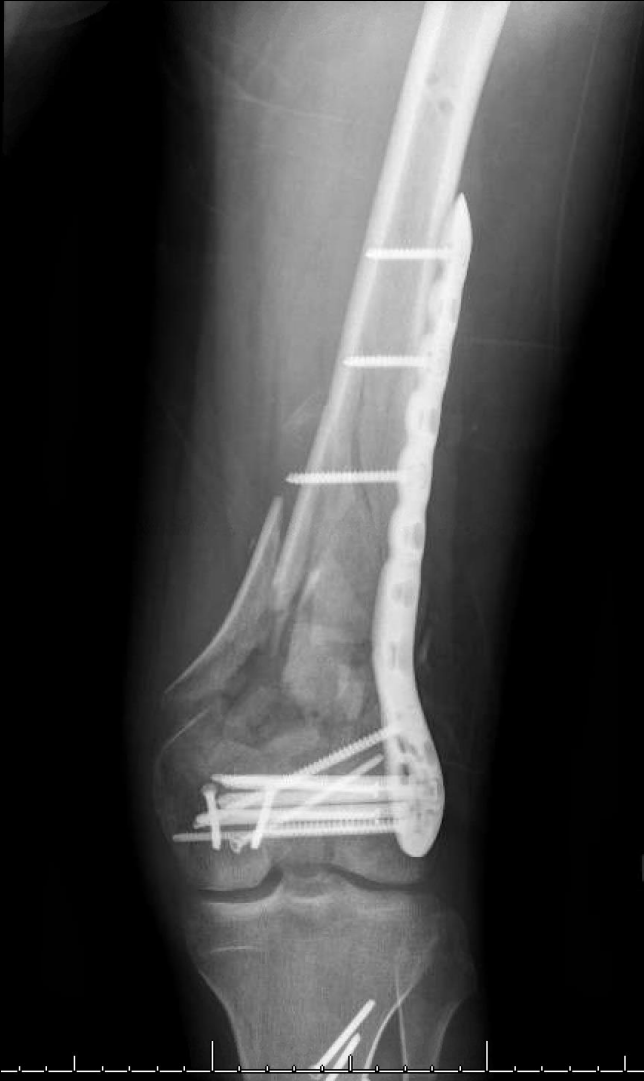


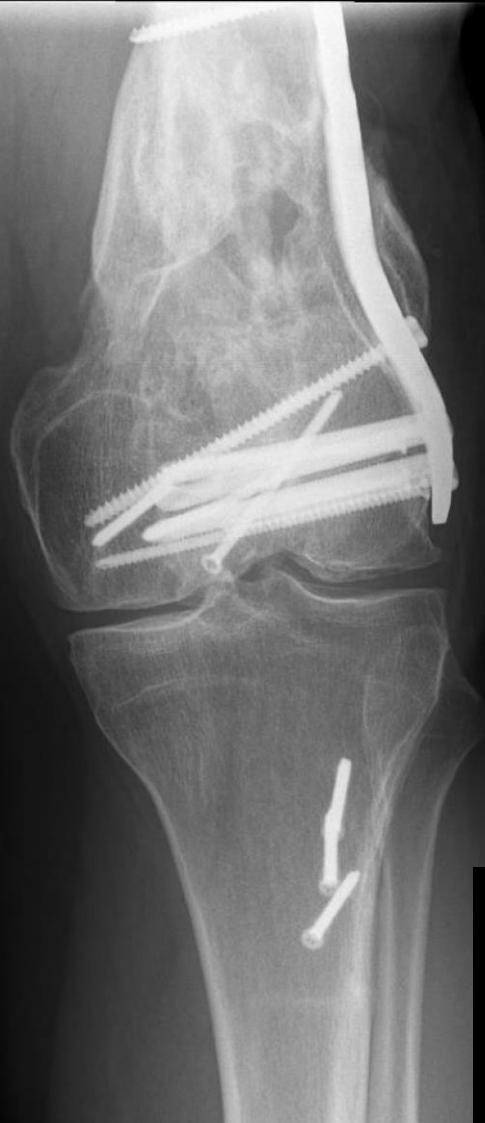




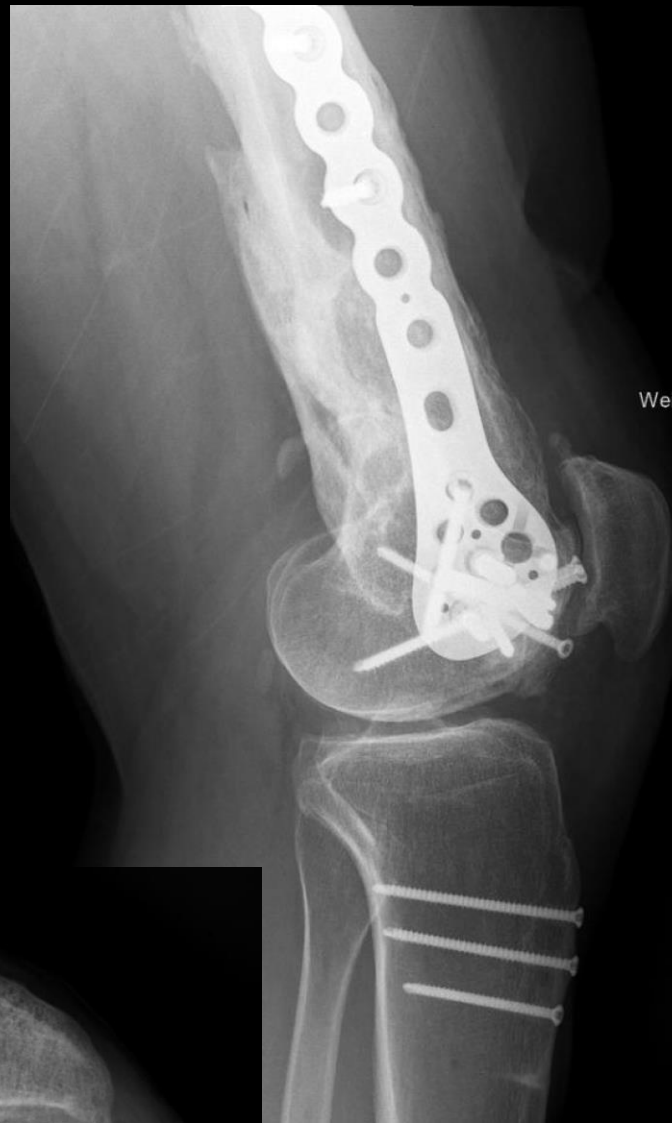
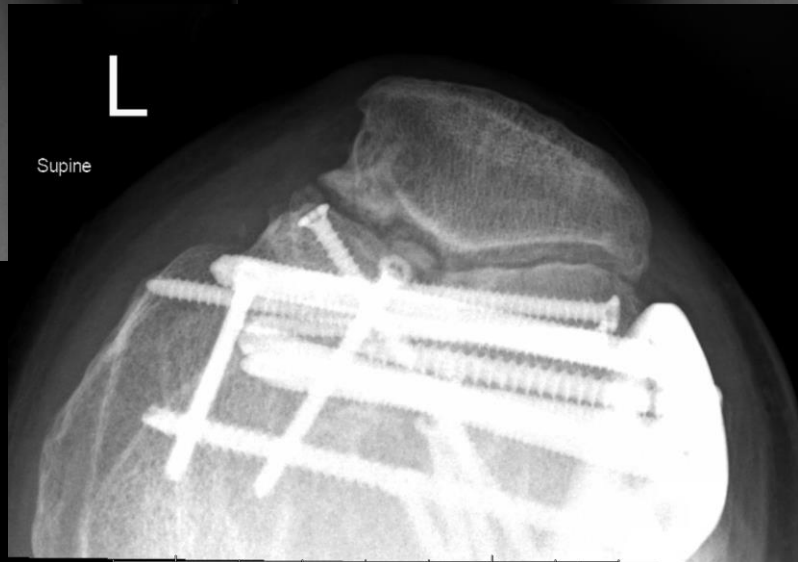




L
JLB
Weight Bearing



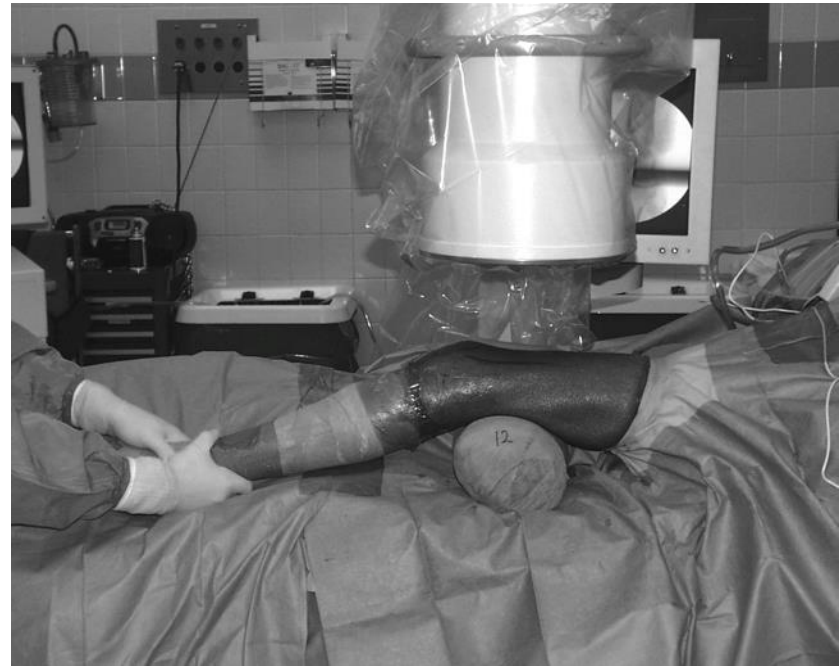L
JLB
Weight Bearing

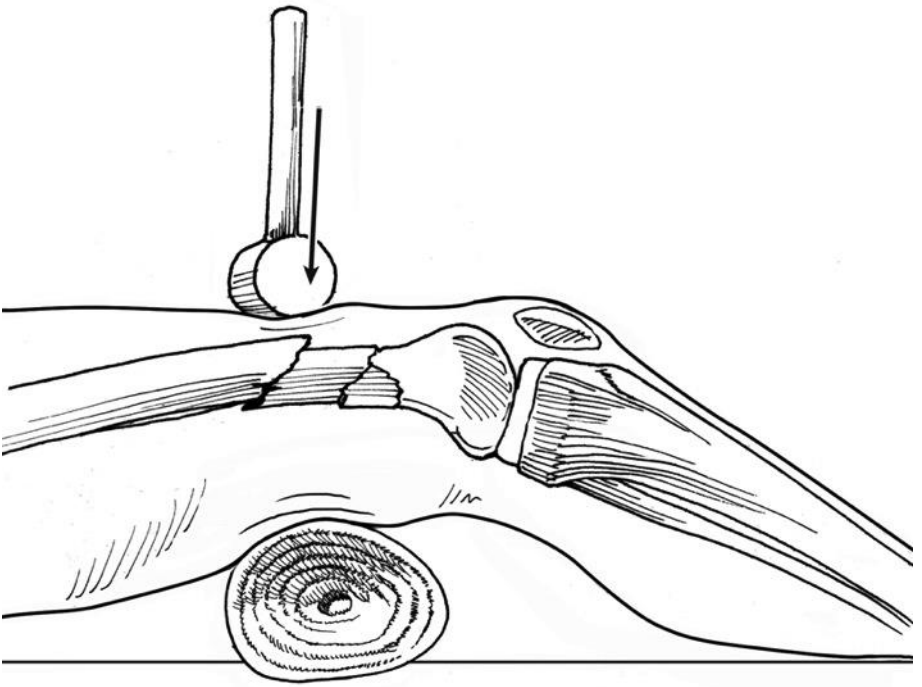
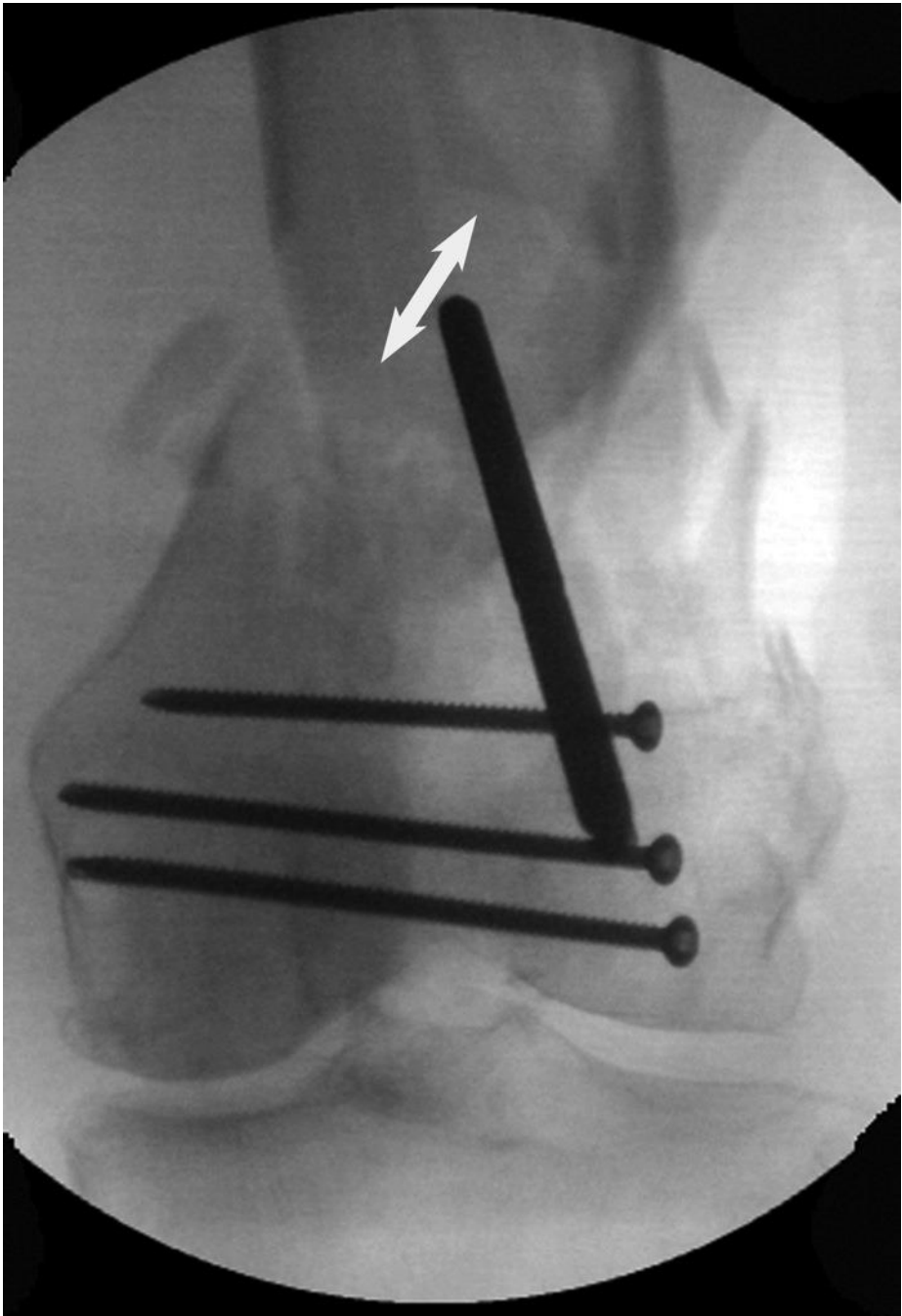


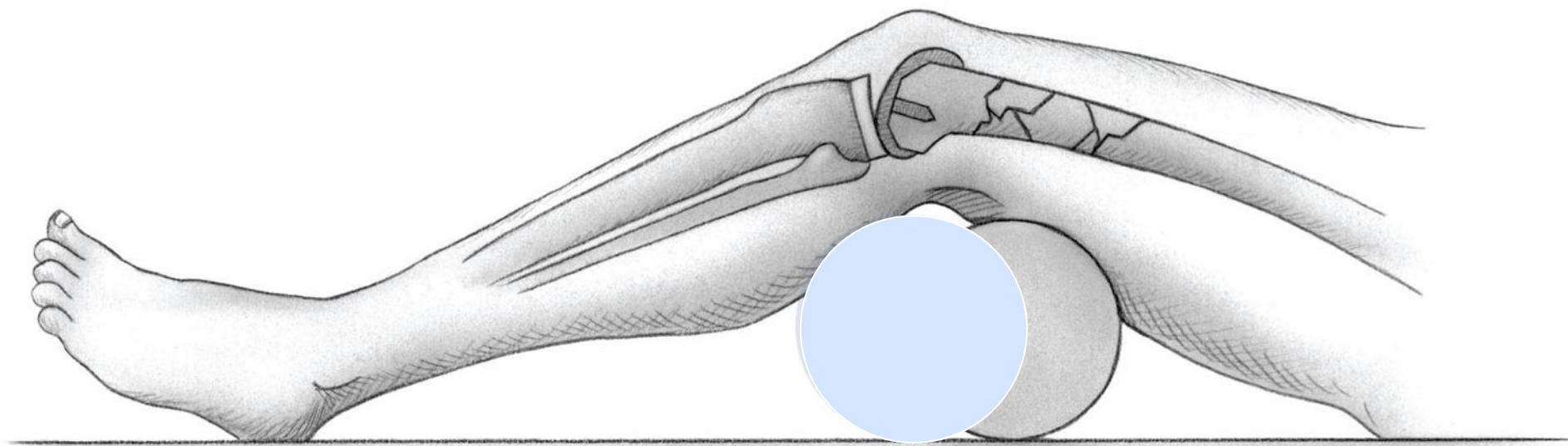
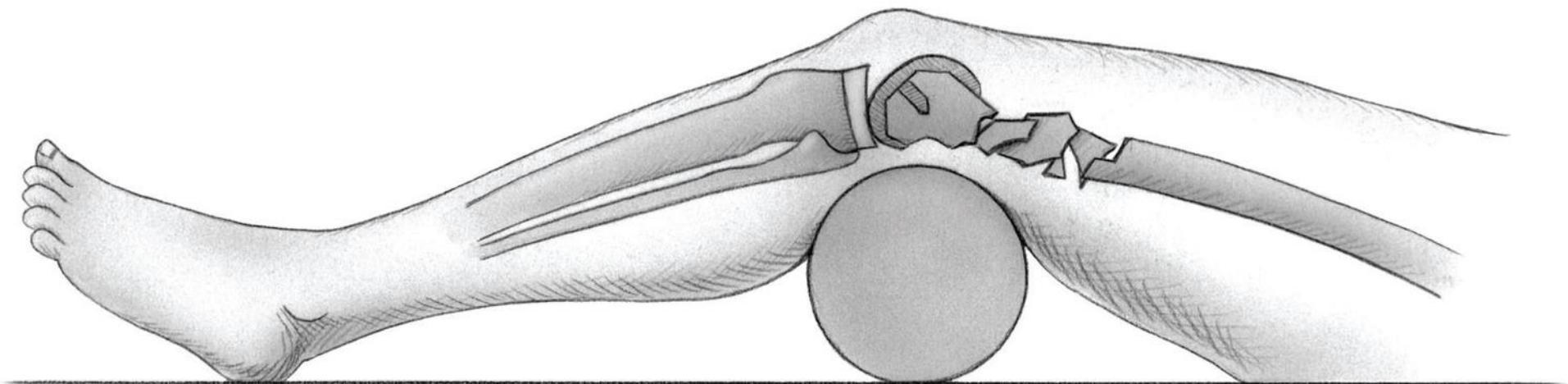
L
Supine

Step 2: Reduction of Condyles to Femoral Shaft

- Bumps / Triangle
- Mallet
- Joysticks
- Clamps

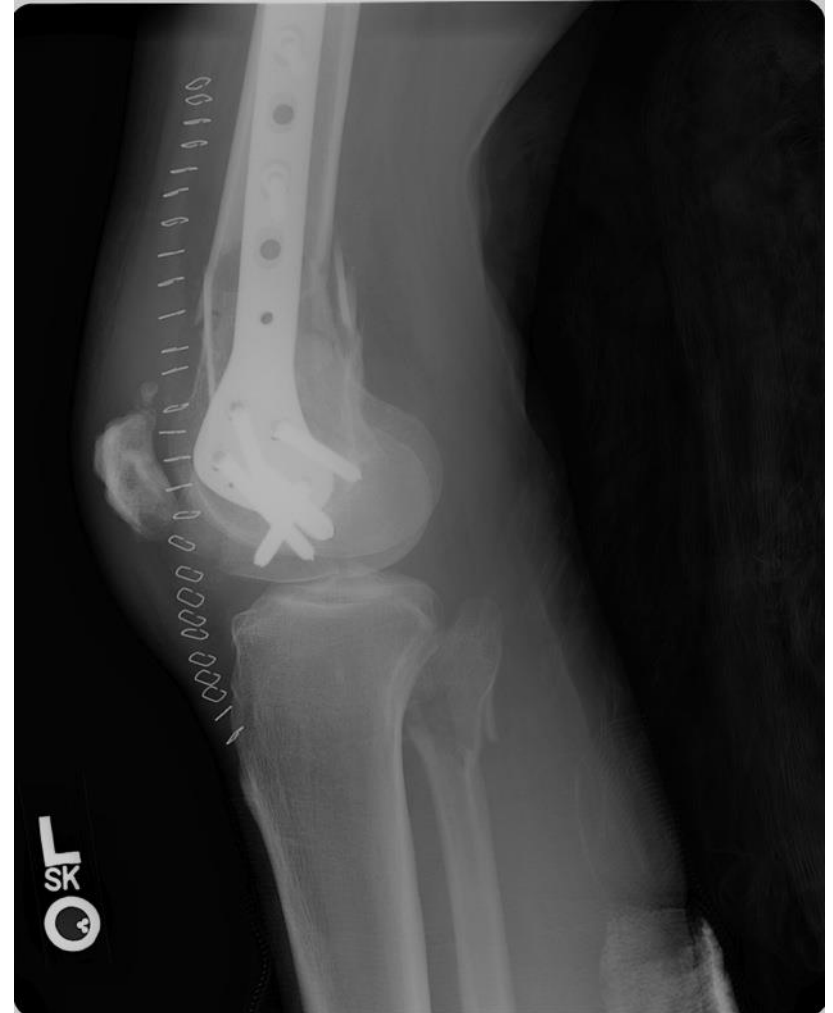
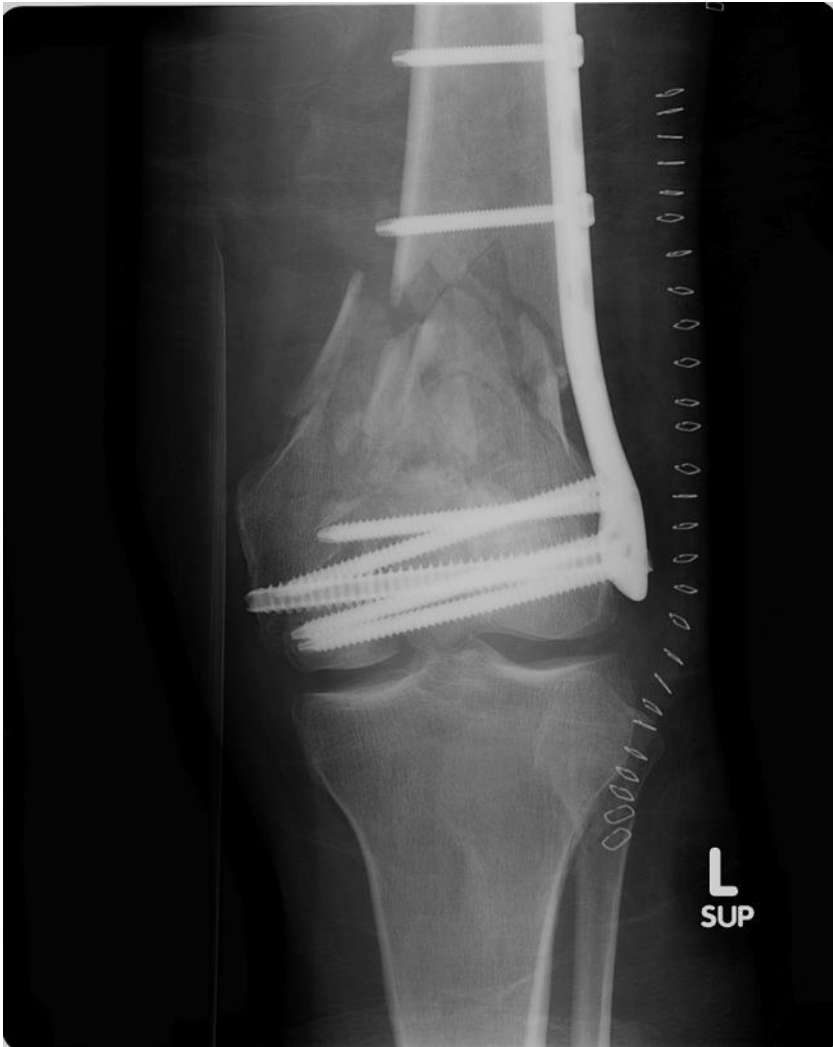


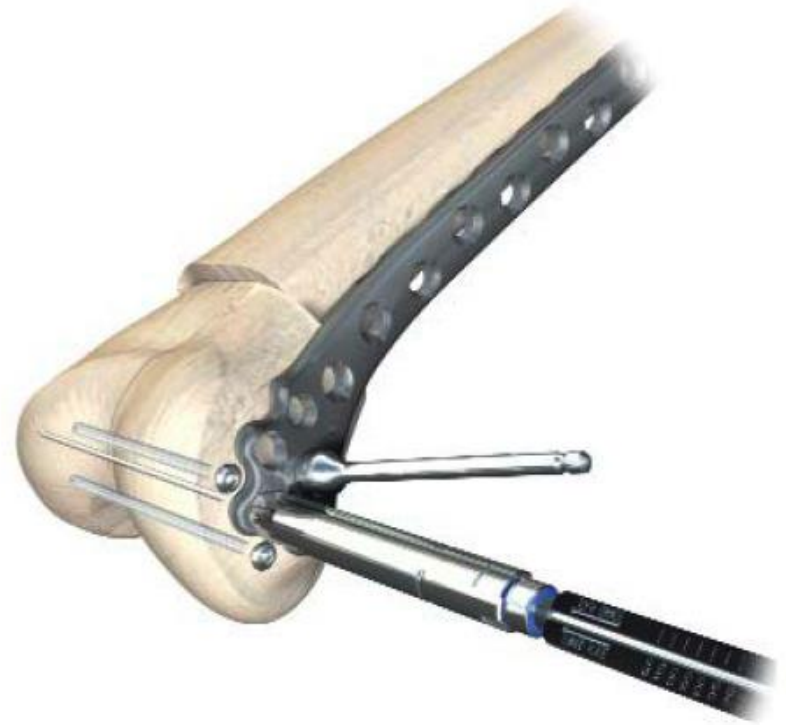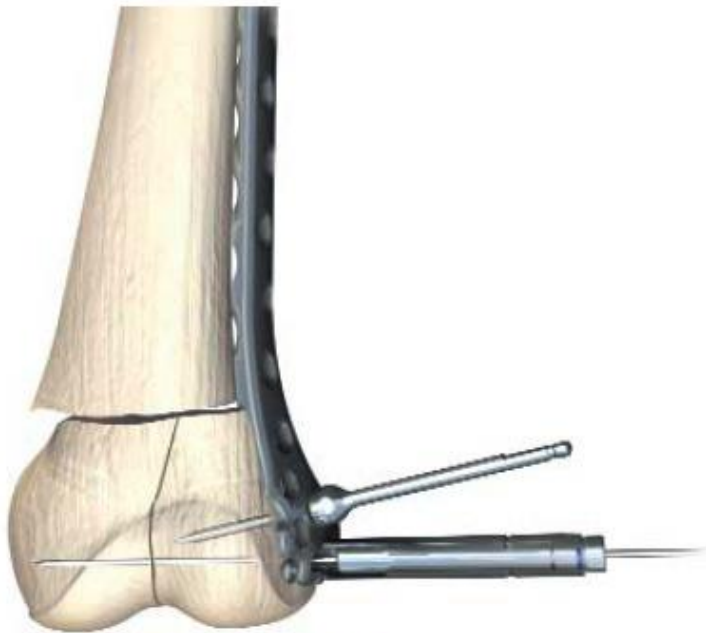


From Haidukewych et al, JBJS 2008 90A Suppl 2(1): 120

Step 3: Insertion of Final Fixation




Appropriate placement of plate on distal femur



For correct coronal alignment the K-Wire (guide wire) must be parallel to the joint in the AP view.

Check reduction and fix to proximal femur

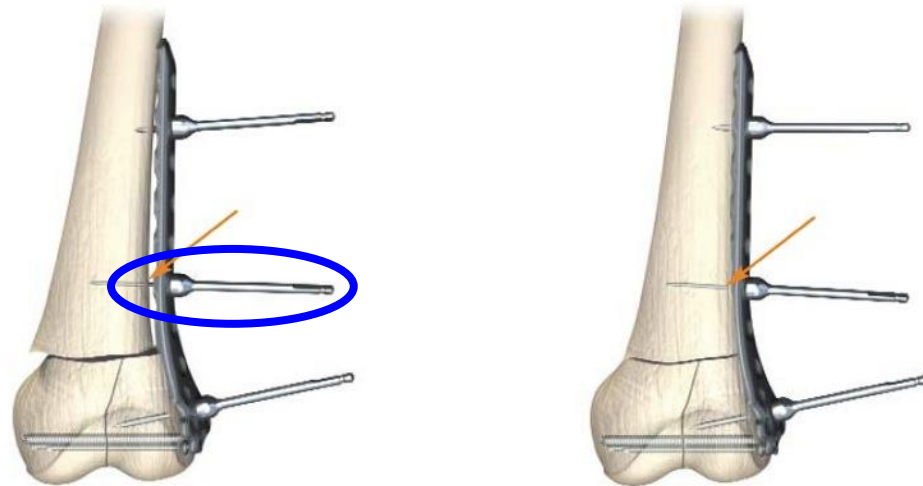


Correction of alignment

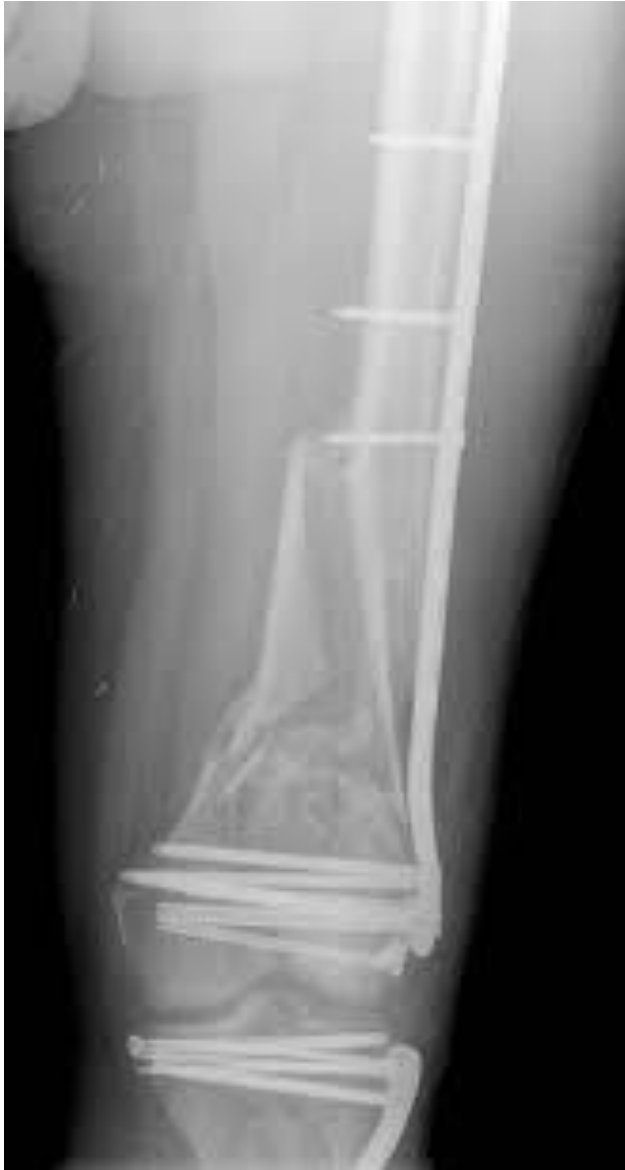LAG BEFORE LOCK

- Clamp

- P-Fix Pin

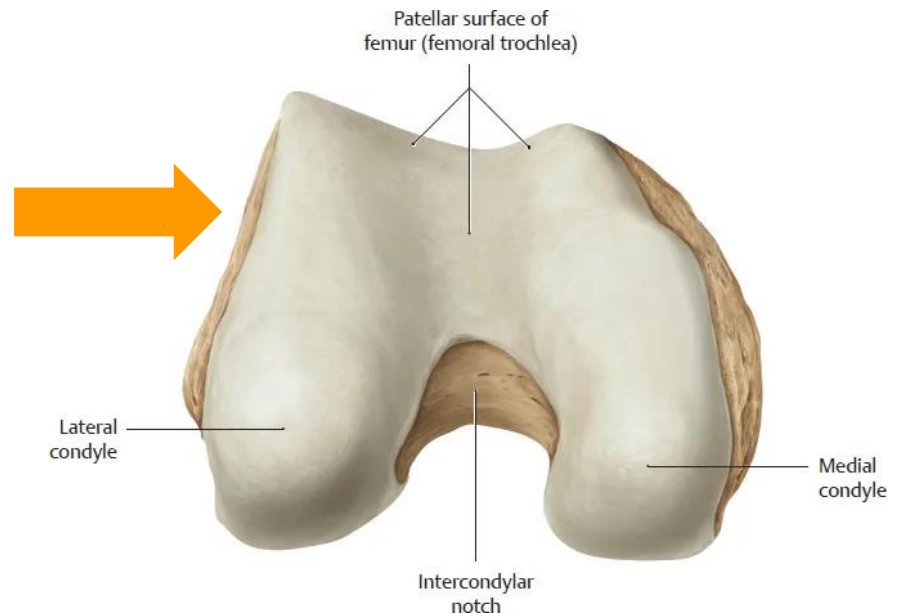


- Non-locking screw



“Golf-club” deformity

Plate too posterior
on distal femur



Place distal screws

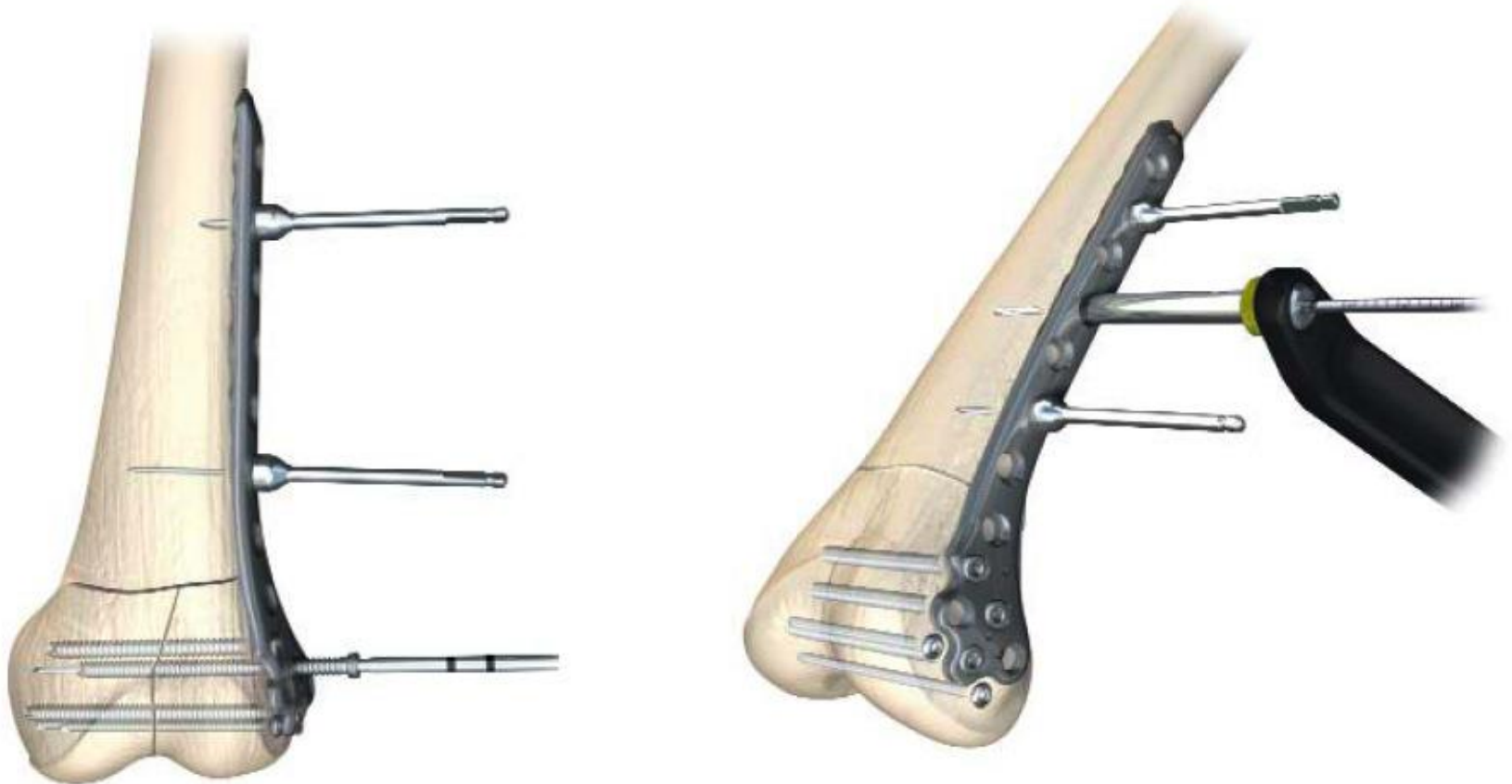
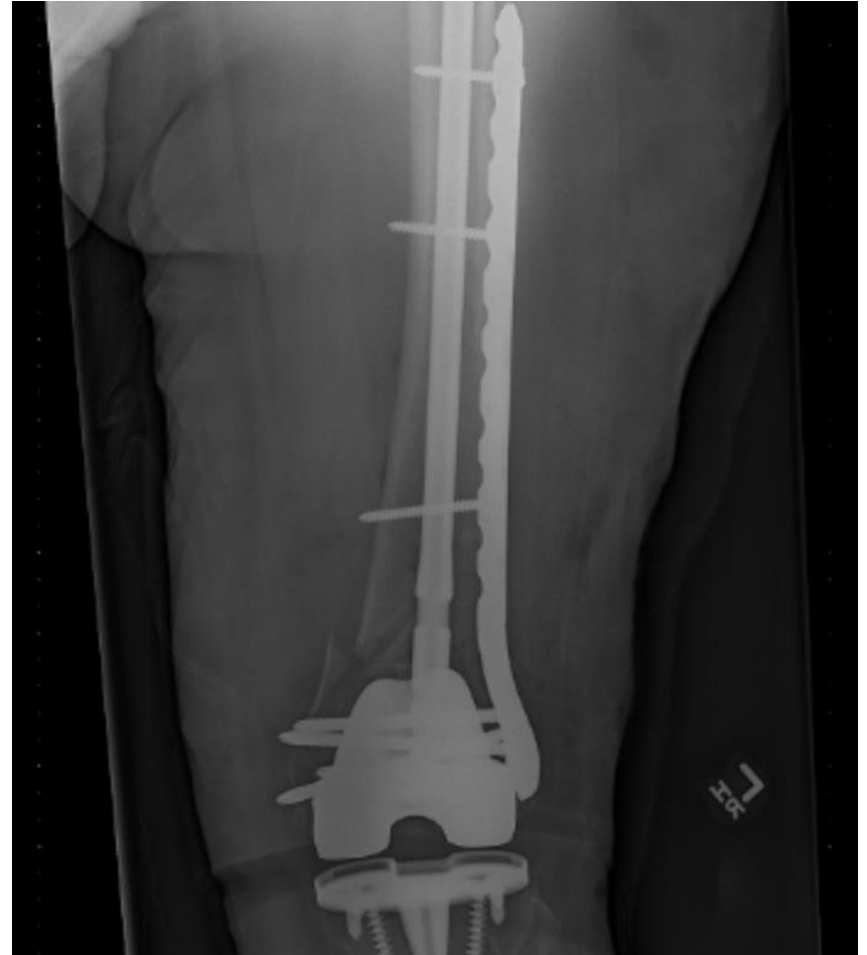
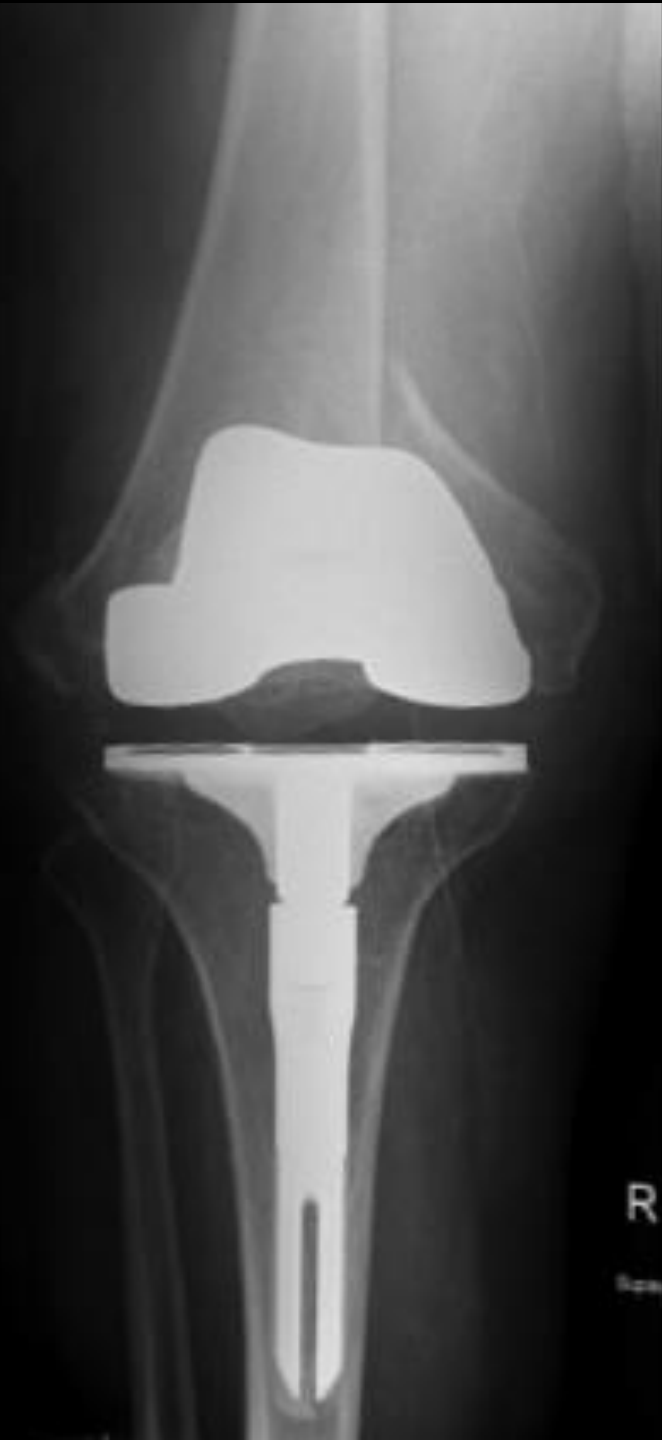Plate *and* Nail

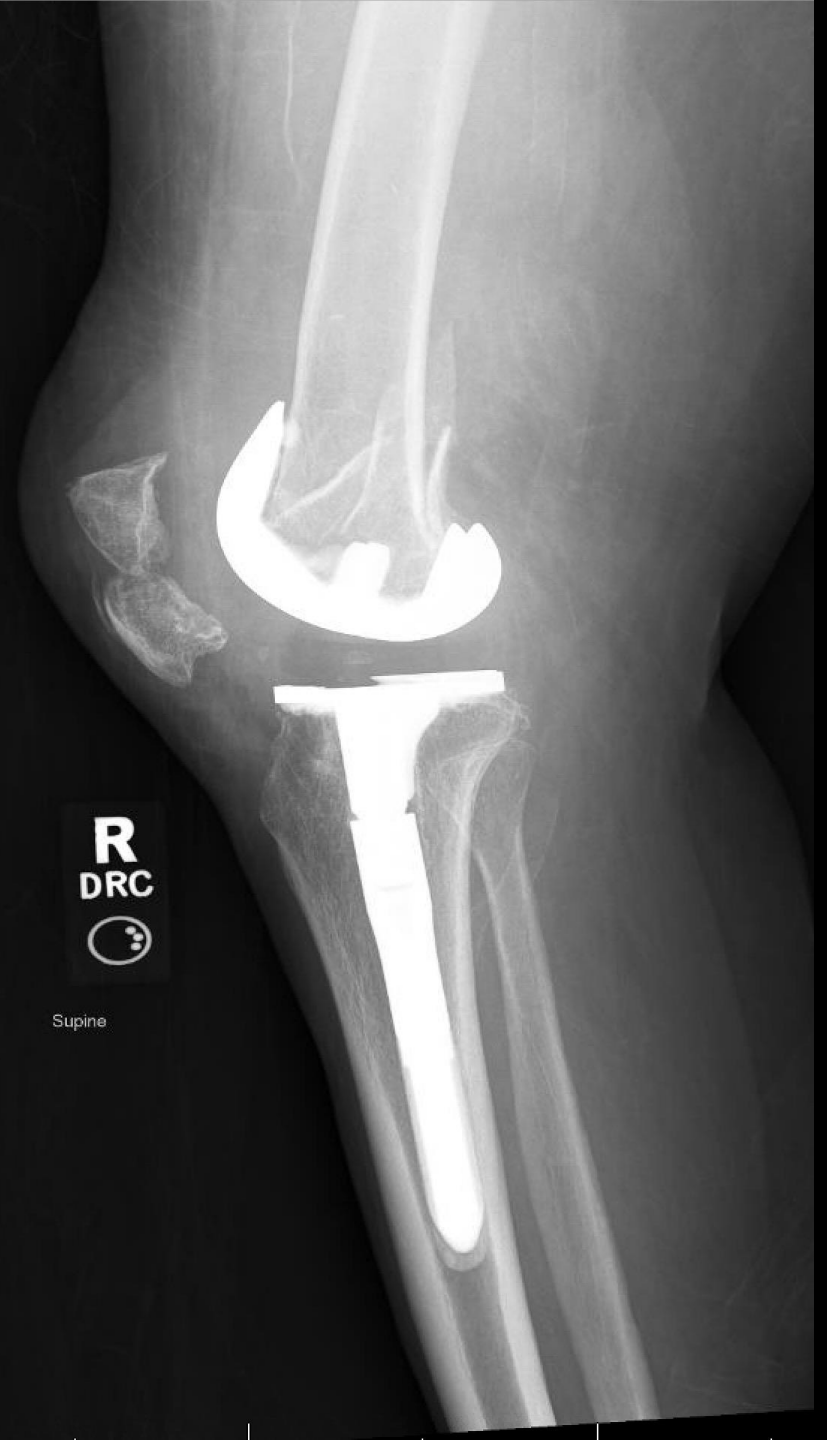- Newer technique
- Originally done in nonunion
- Has a role for acute fx fixation as well



Slide courtesy Dan Horwitz



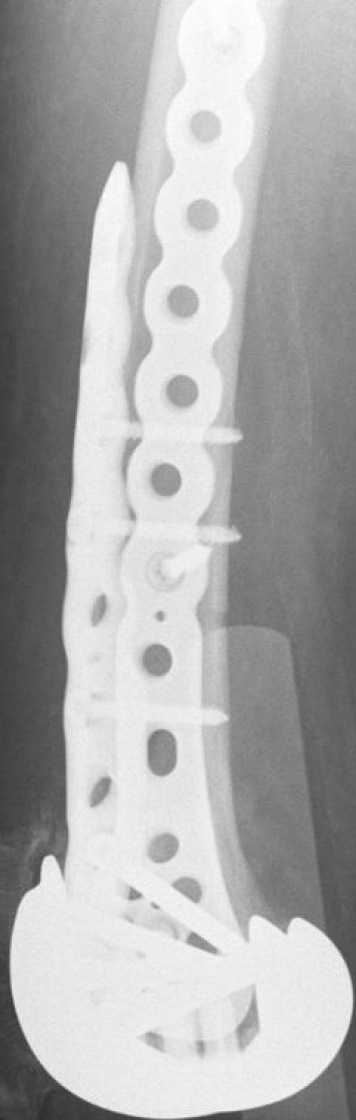R



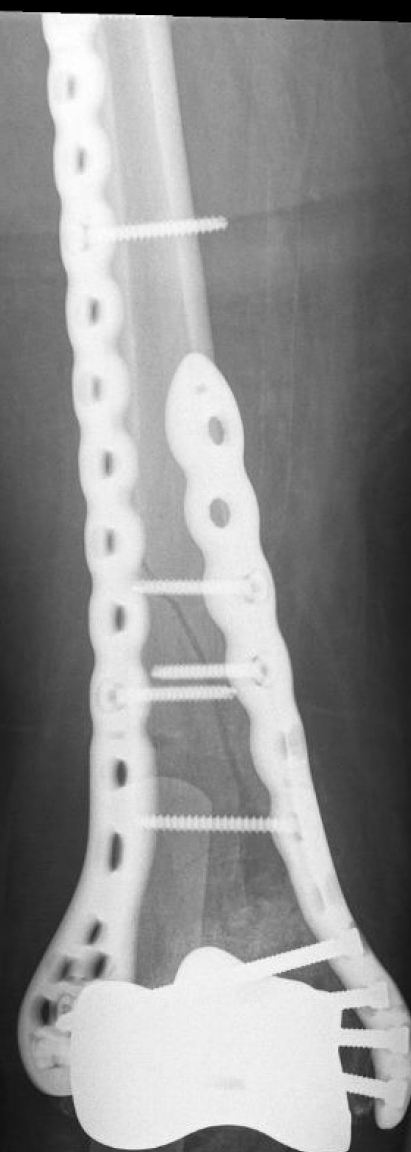
R
DRC
☺

Supine

R
Table



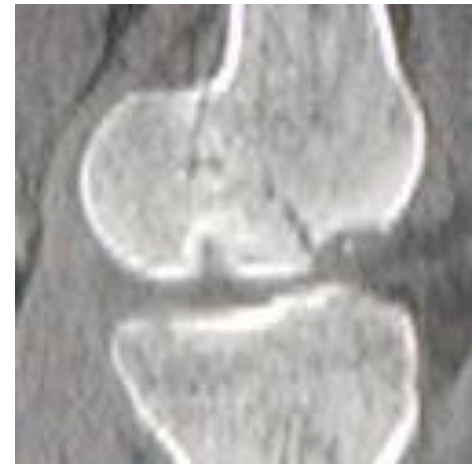R
Supine



Tips and Tricks

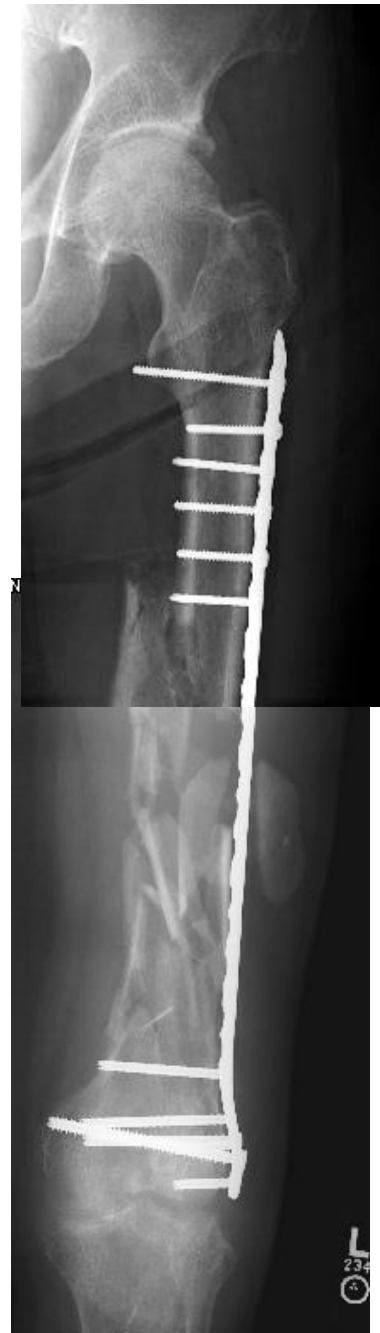- Understand articular anatomy *before* surgery.

- Medial Hoffa nearly impossible treat via lateral approach



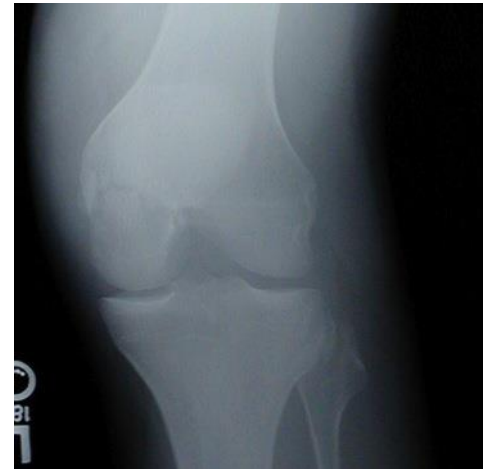Tips and Tricks

- Create a more flexible construct by using a long plate with fewer screws.



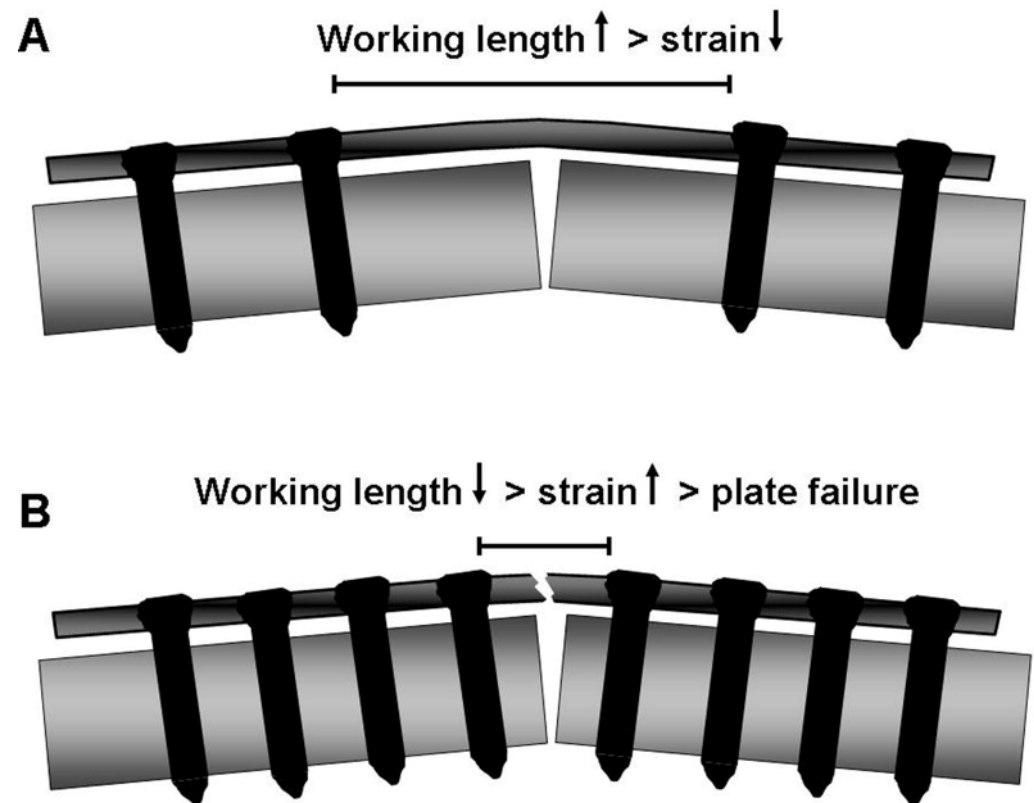
Tips and Tricks

- Common deformity is excess valgus, hyperextension of distal femur, and external rotation. Know how to correct these.
 - “Notch view” appearance of distal femur on AP x-ray

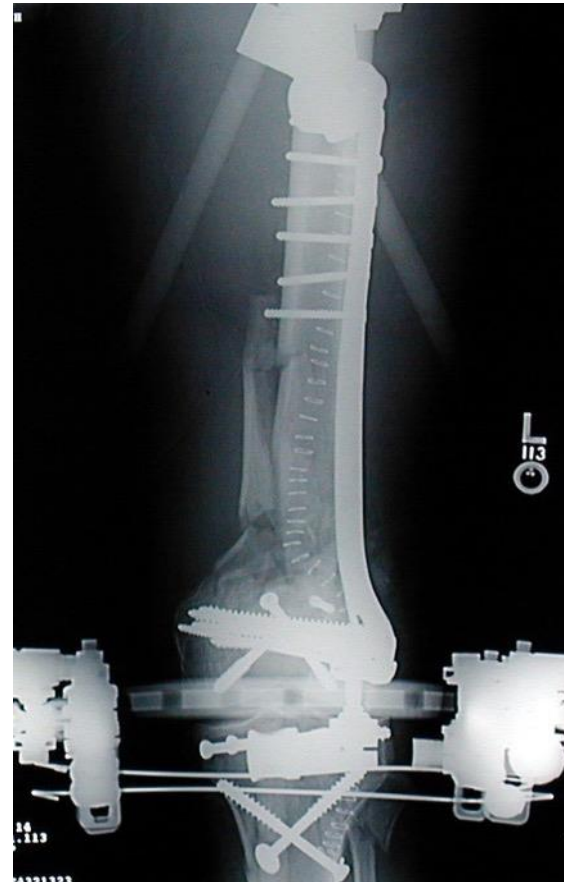
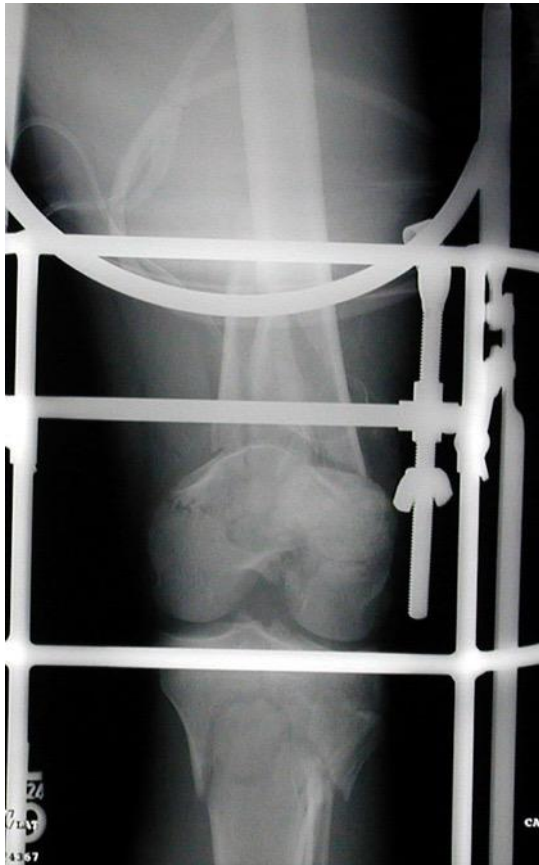
Tips and Tricks

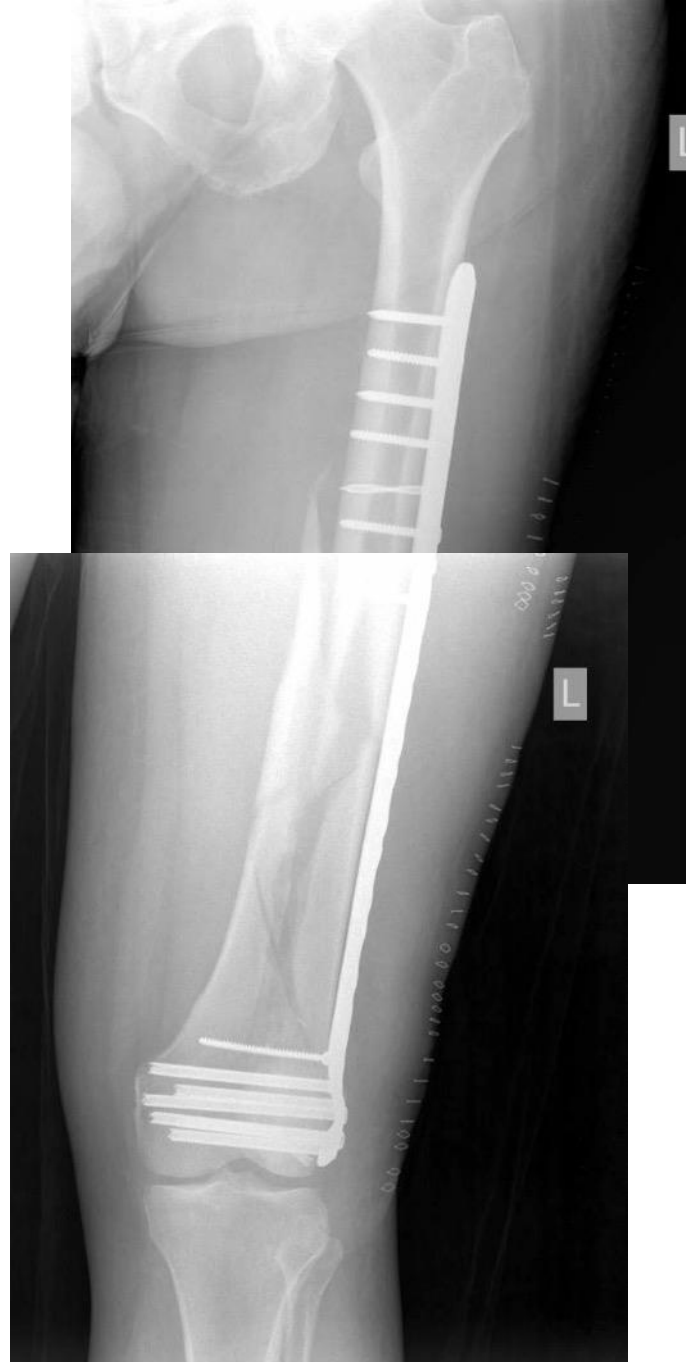- Create a more flexible construct by using a long plate with fewer screws.



For years, the main issue was coronal plane stability



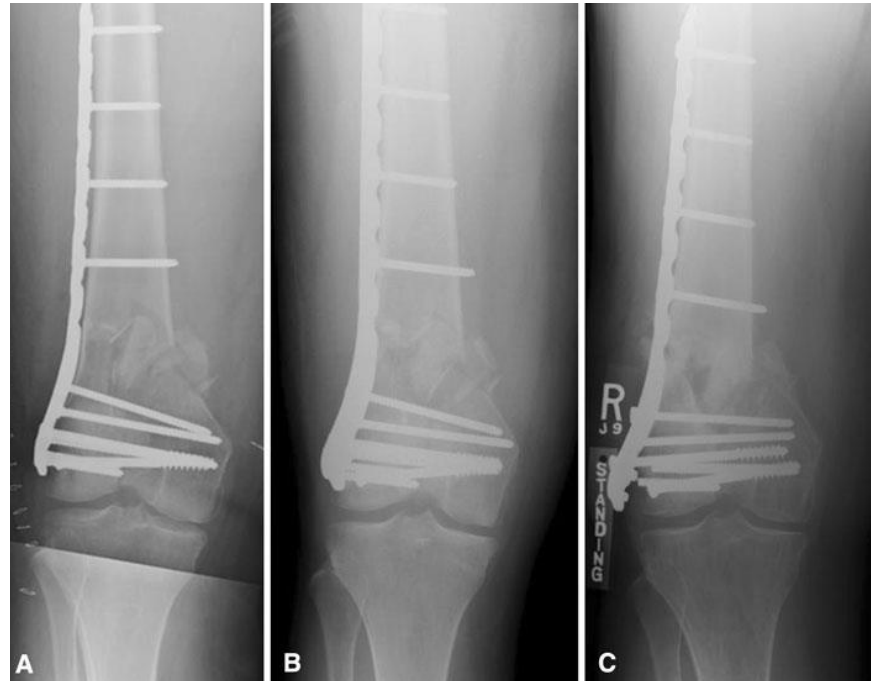Locking plates
solved that...



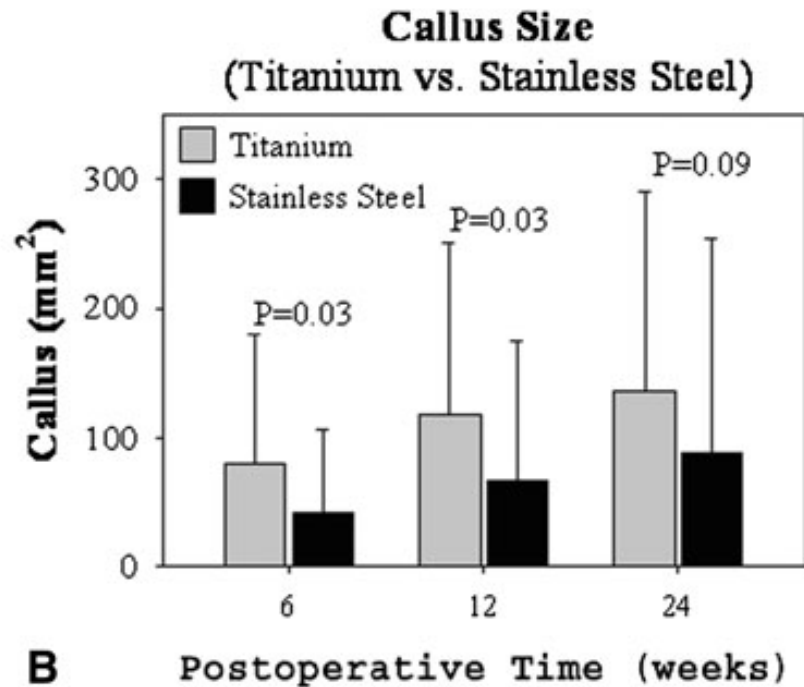
But gave
us a new
problem
instead...

**2010 Mid-America Orthopaedic Association Physician
in Training Award: Healing Complications Are Common
After Locked Plating for Distal Femur Fractures**

Christopher E. Henderson MD, Trevor J. Lujan PhD,
Lori L. Kuhl, Michael Bottlang PhD,
Daniel C. Fitzpatrick MD, John L. Marsh MD

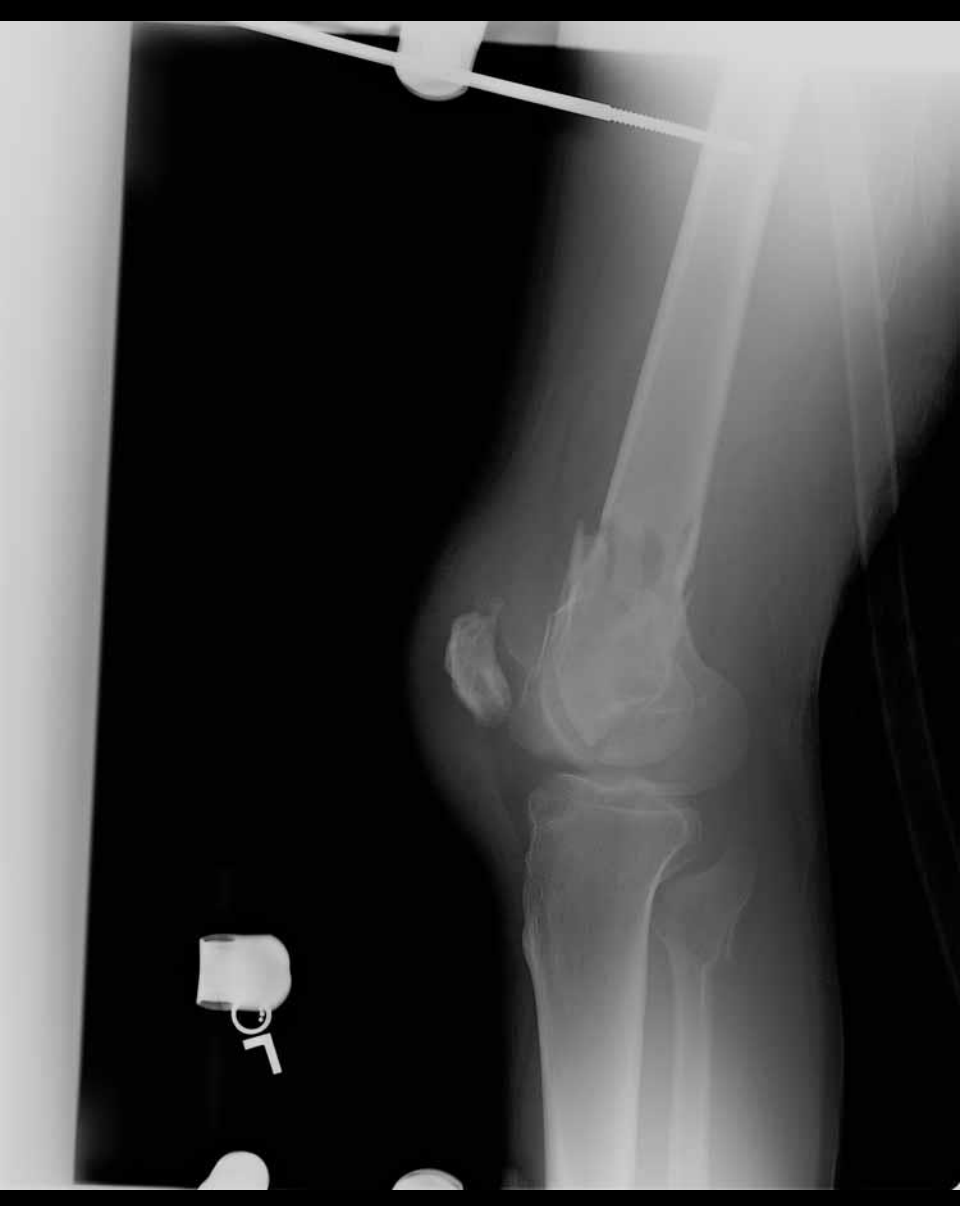
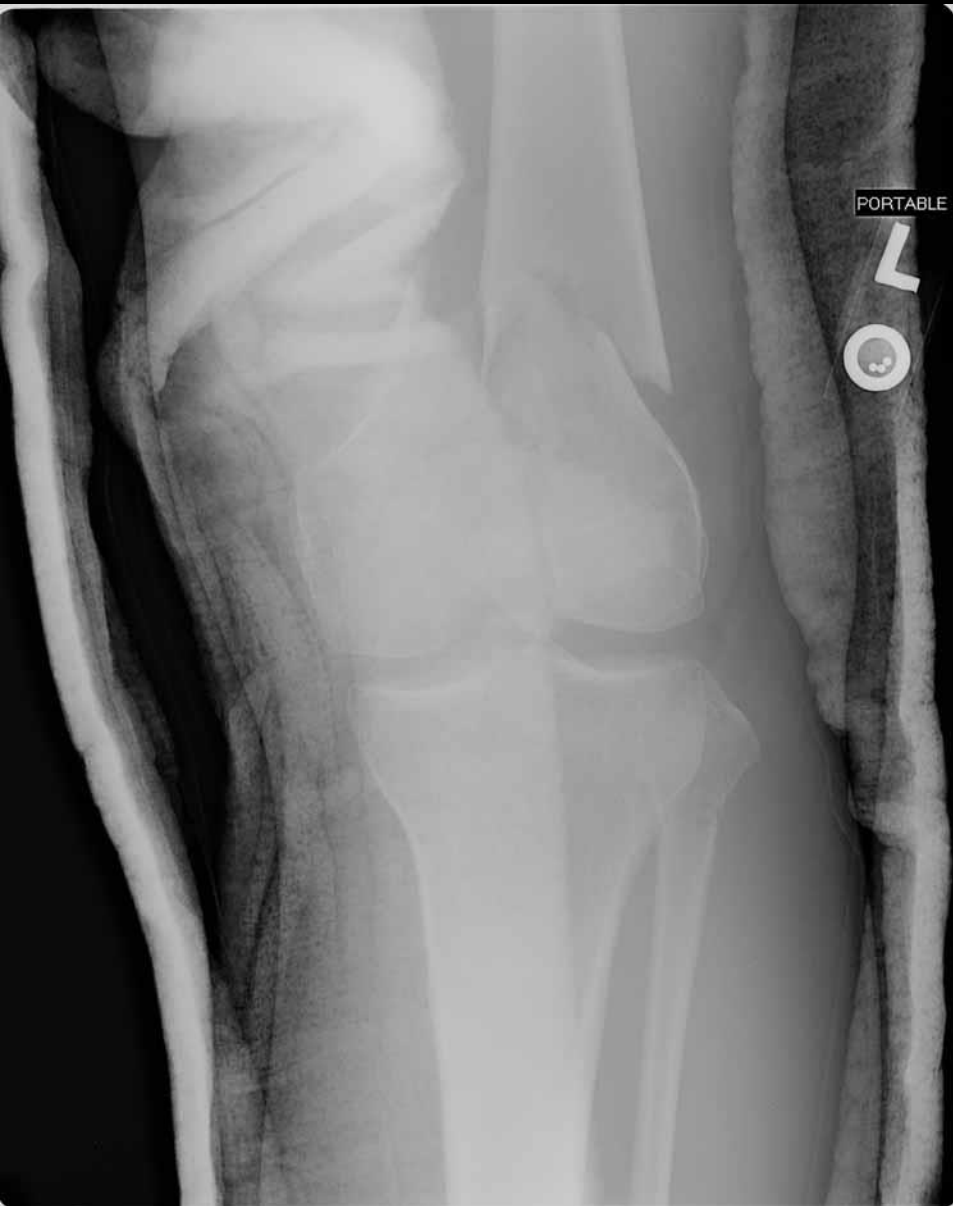
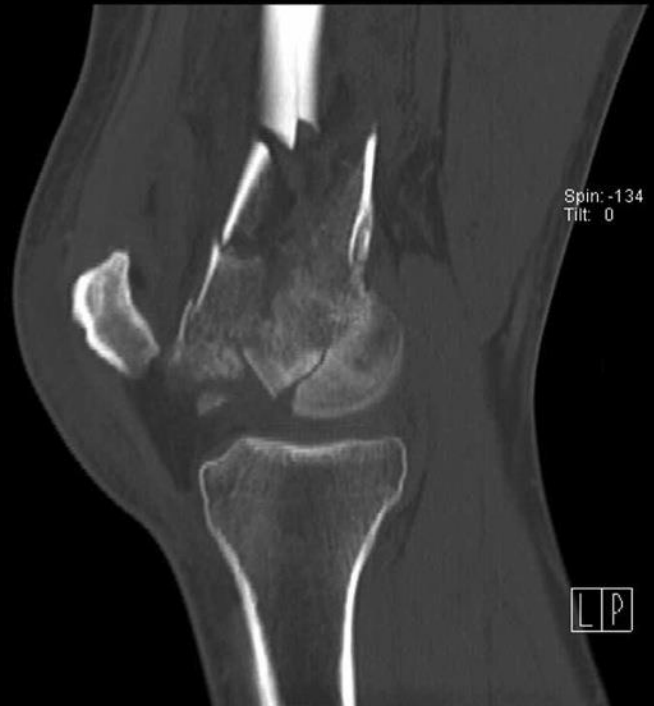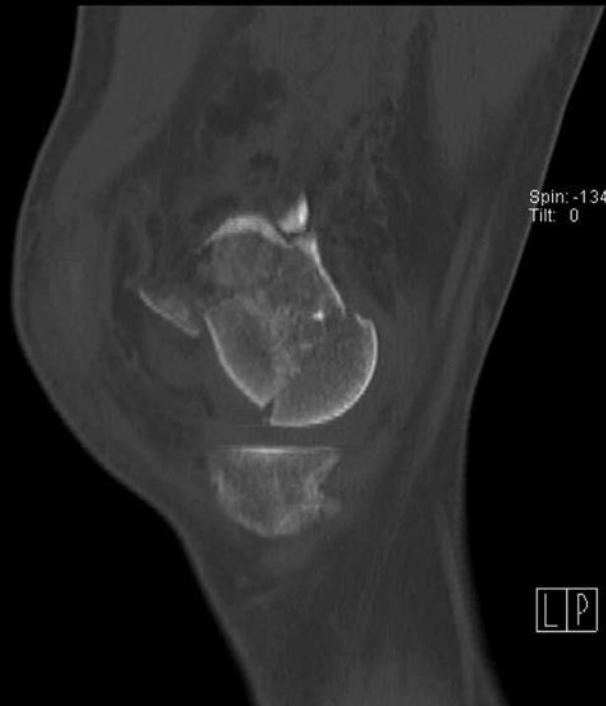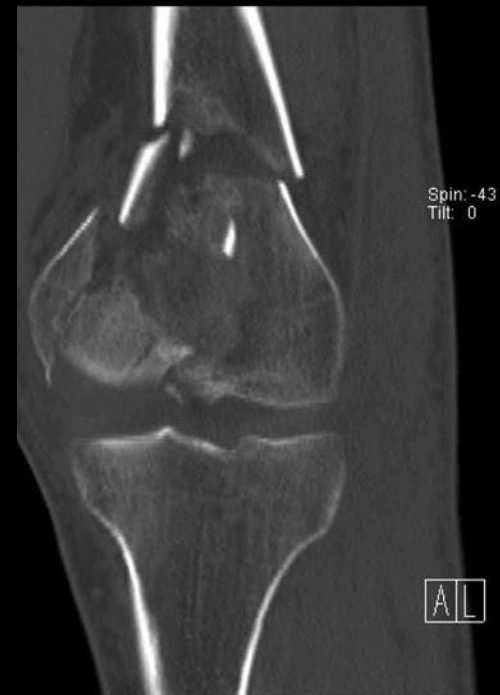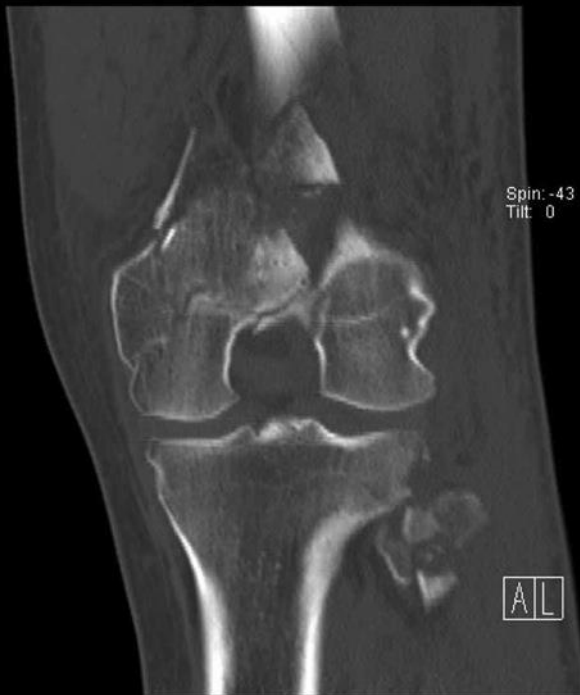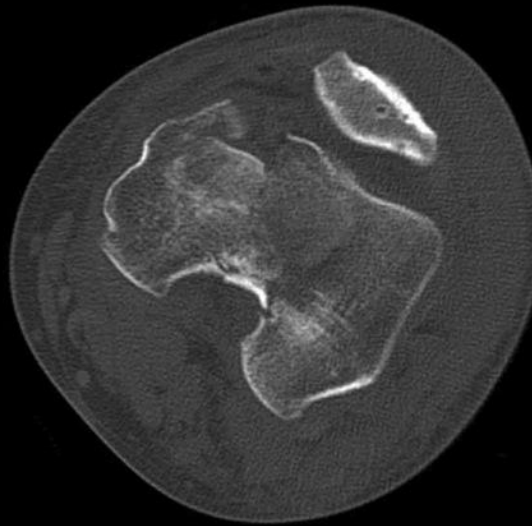
- 86 fractures
- 14% failed to unite
- More empty holes in the plate in those that healed
- Less callus in stainless compared to titanium

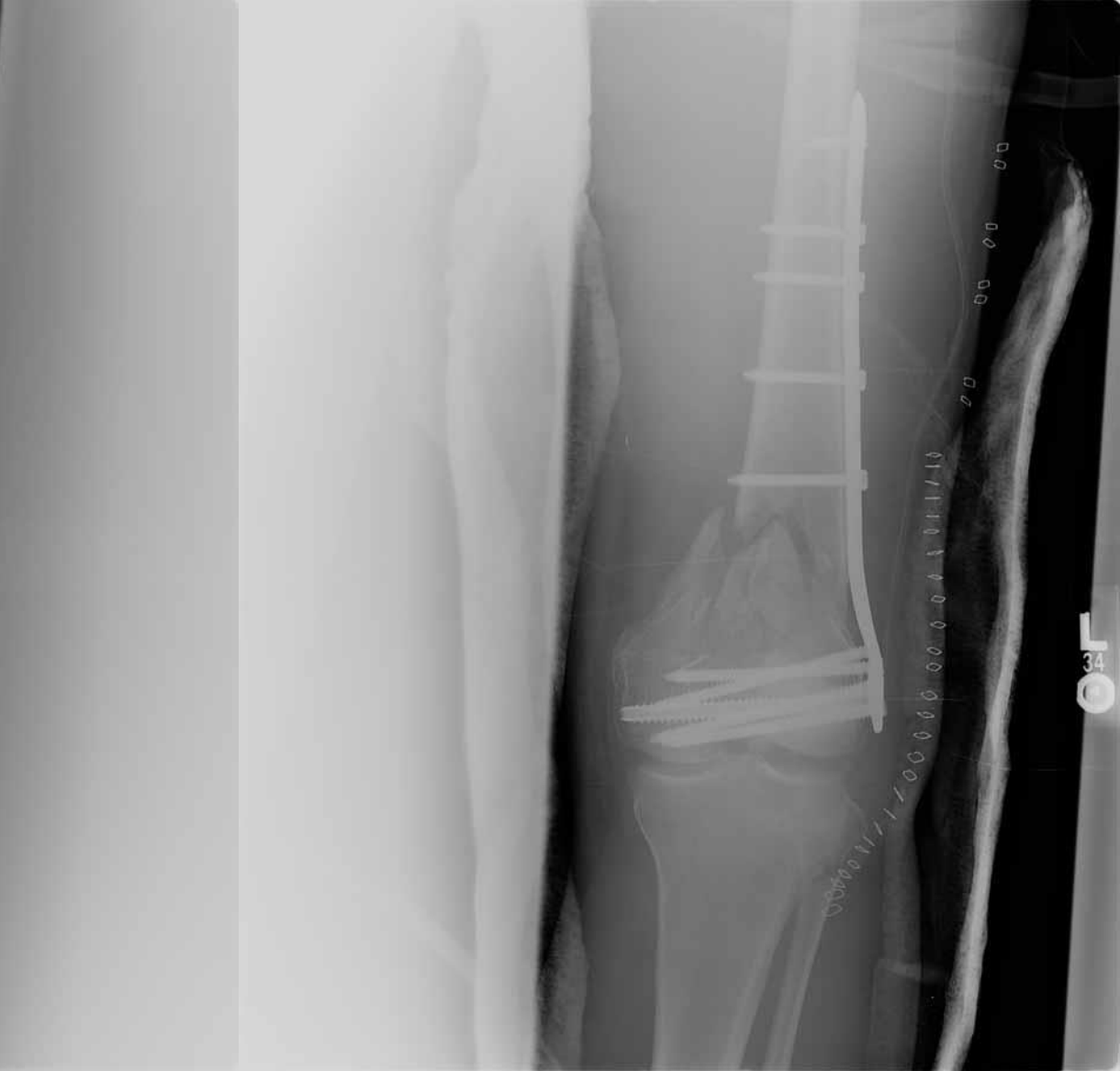
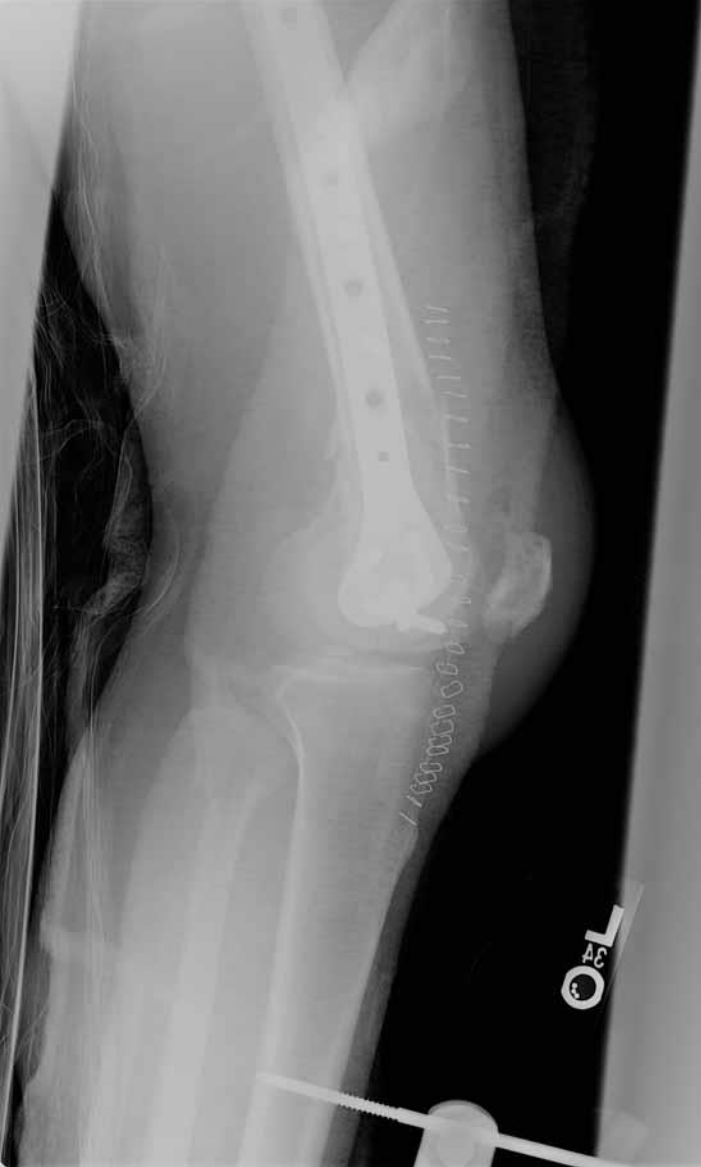
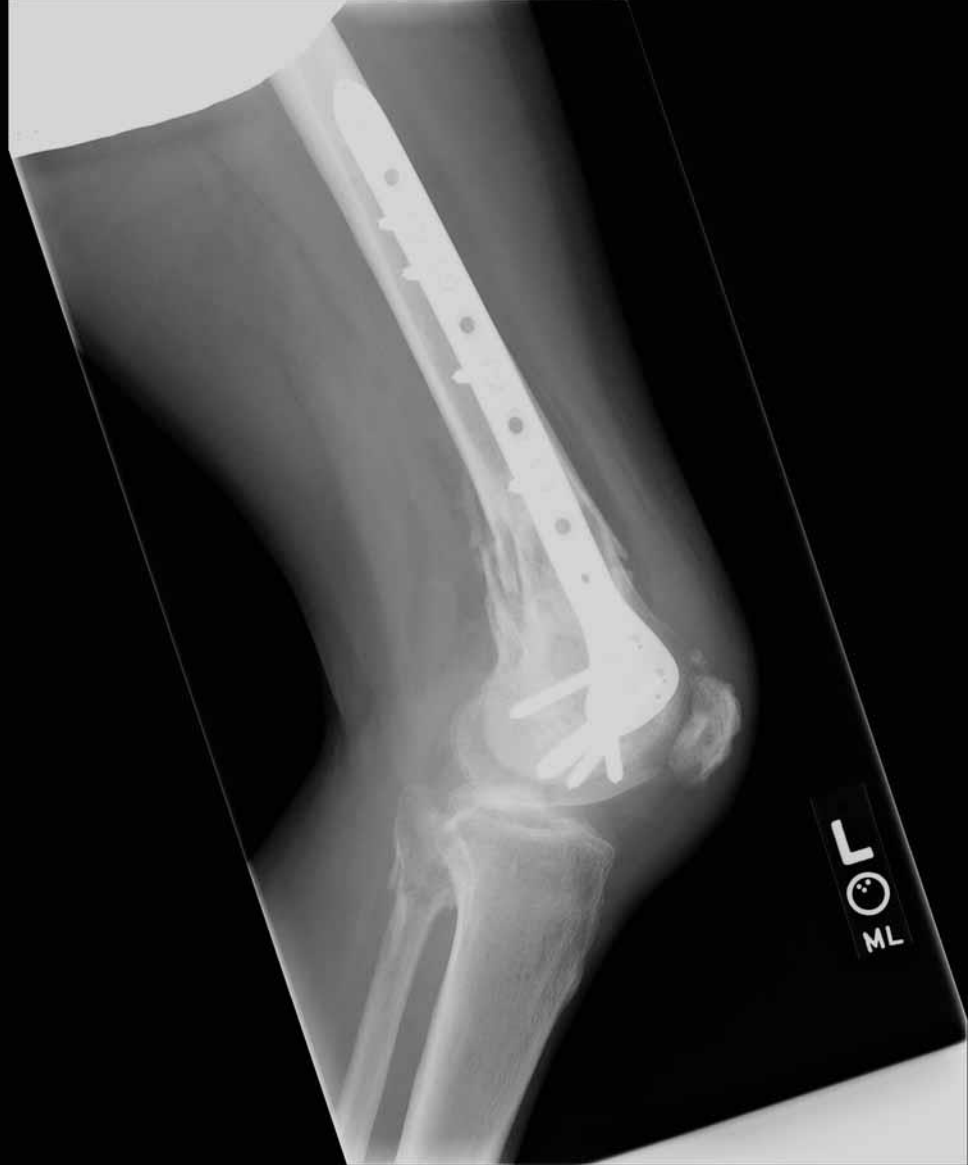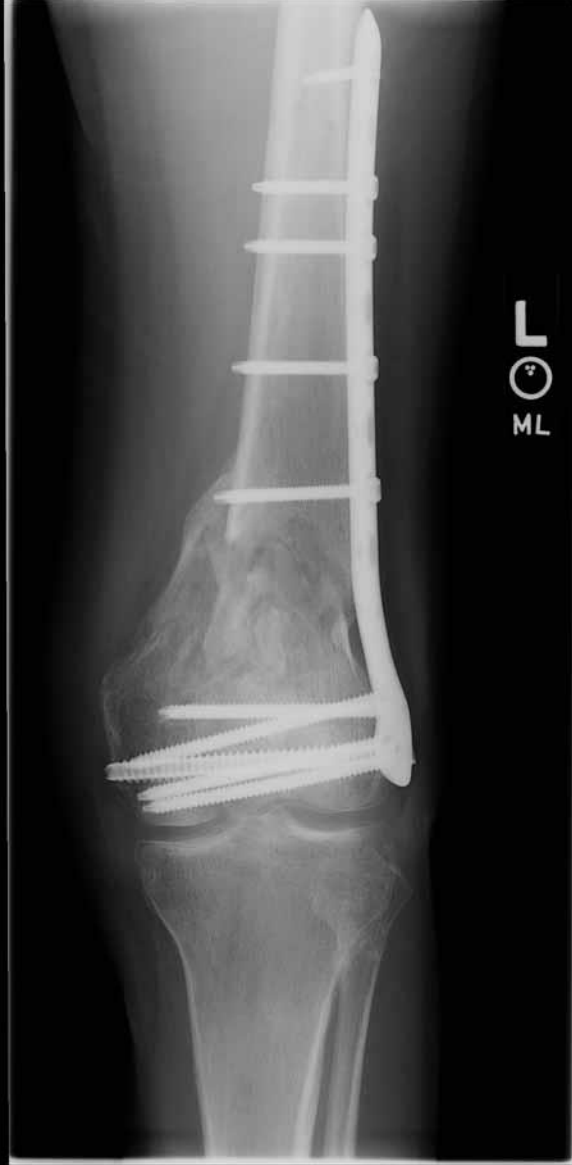What is the appropriate stiffness and how do you achieve it?

- Working length (do you fill every screw hole?)
- Over-drill the near cortex so the screw is only fixed in the far cortex.
- “Active” or “dynamic” locking.
- Titanium better than Stainless steel









A scenic sunset over a large body of water, likely a lake or wide river. The sun is low on the horizon, creating a bright orange and yellow glow that reflects on the water's surface. The sky is filled with soft, wispy clouds. In the foreground, the dark silhouette of a large tree with bare branches frames the right side of the image. A wooden structure, possibly a dock or pier, is visible near the water's edge. The overall mood is peaceful and serene.

Thank You