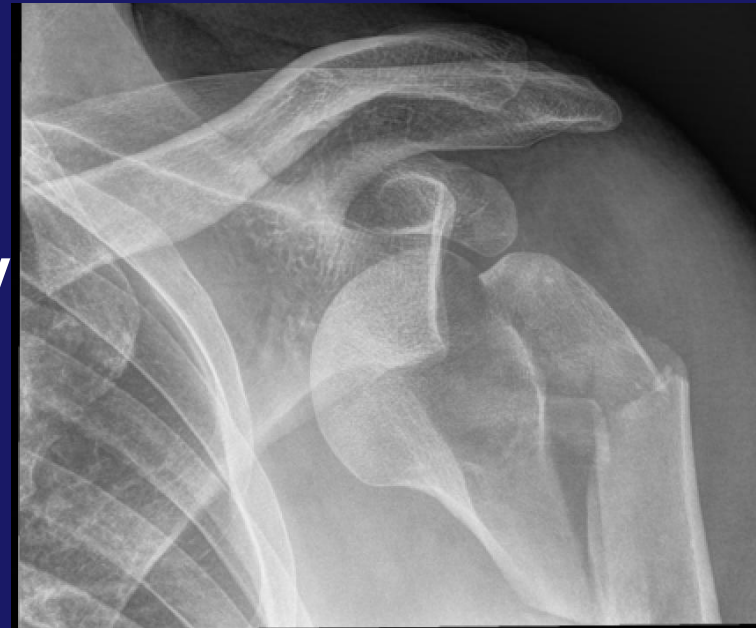

Proximal Humeral Fractures

Michael D. McKee, MD, FRCS(C)
Professor and Chair,
Department of Orthopaedic Surgery
University of Arizona - Phoenix,
Phoenix, Arizona



I (and/or my co-authors) have something to disclose.

Detailed disclosure information is available via:

“My Academy” app;

or

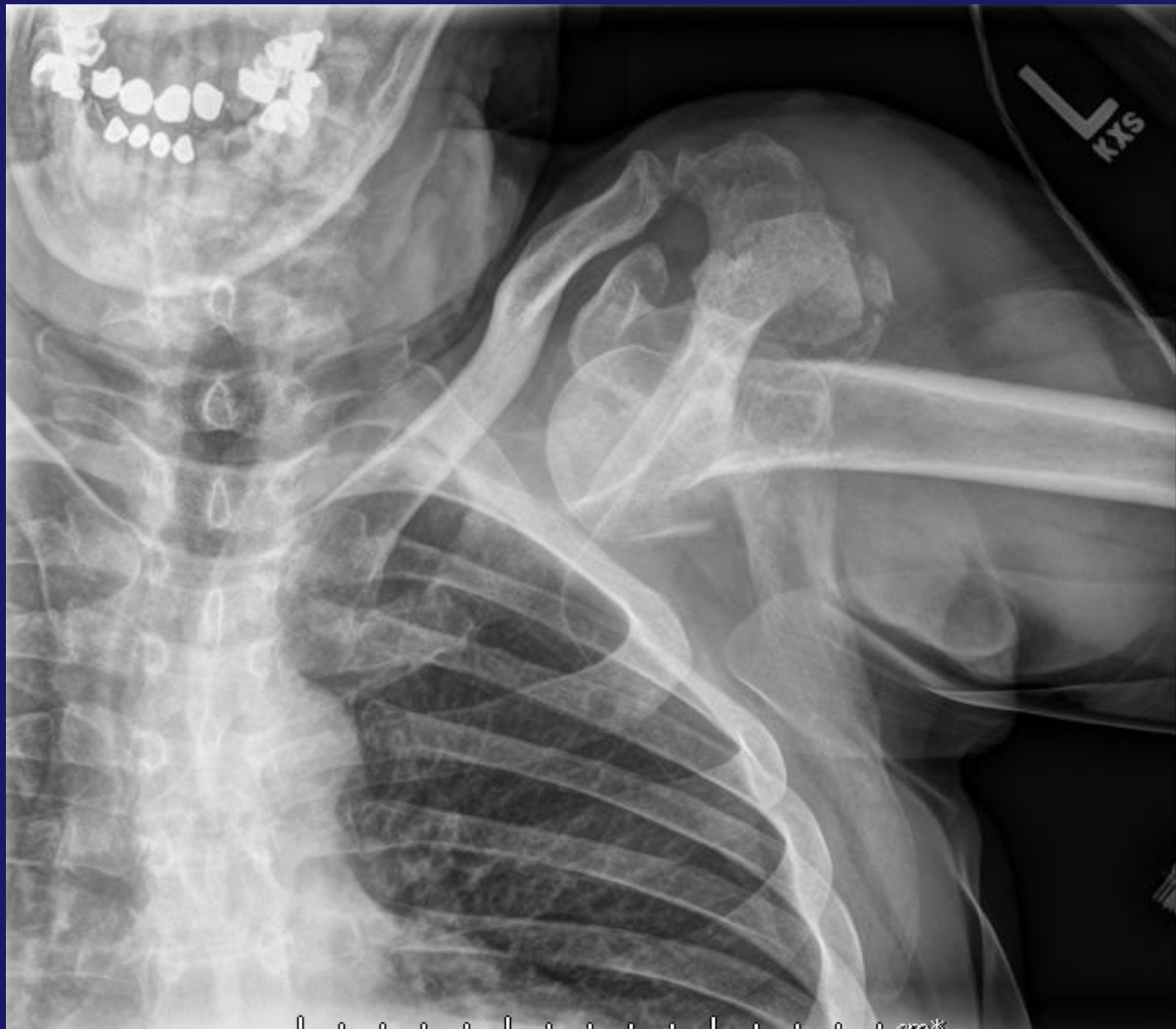

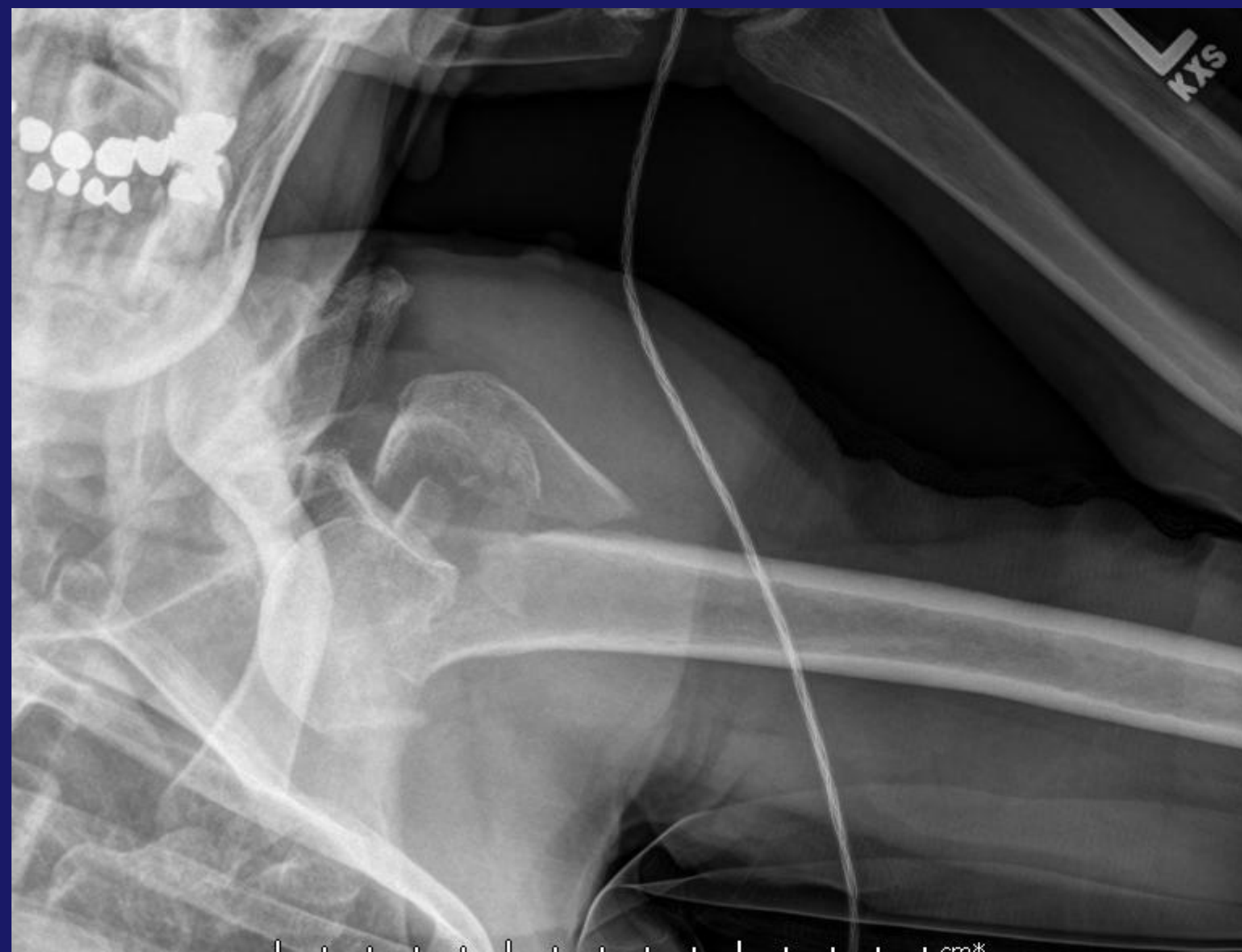AAOS Orthopaedic Disclosure Program on the AAOS website at

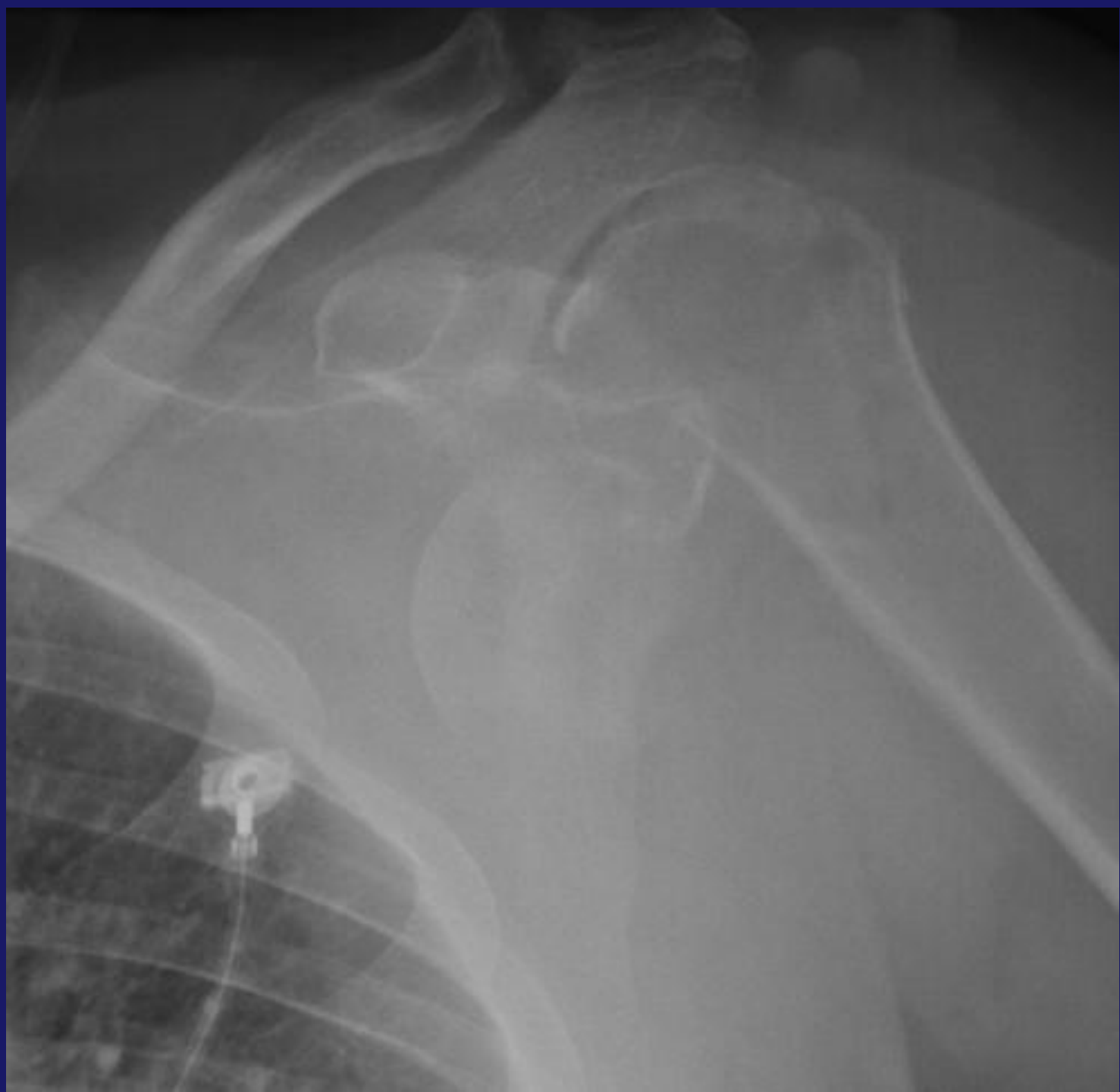<http://www.aaos.org/disclosure>

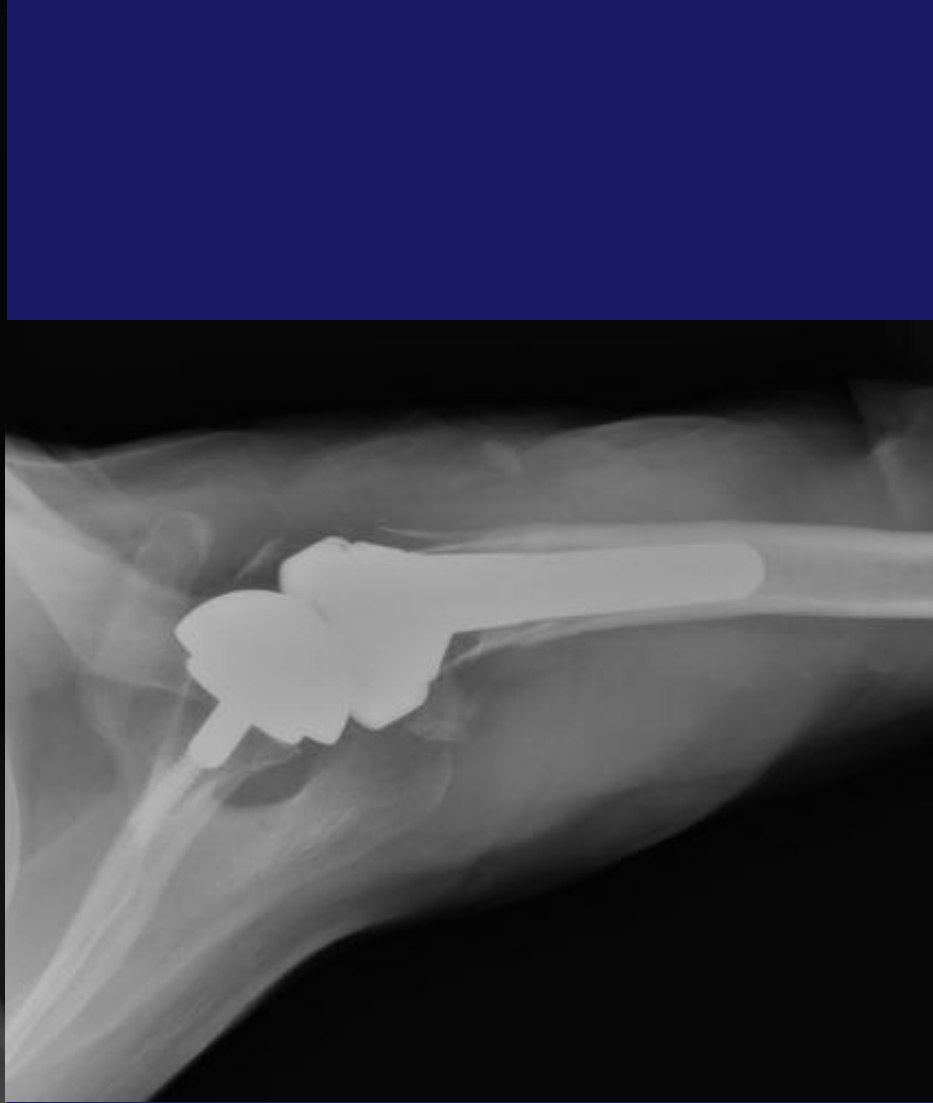
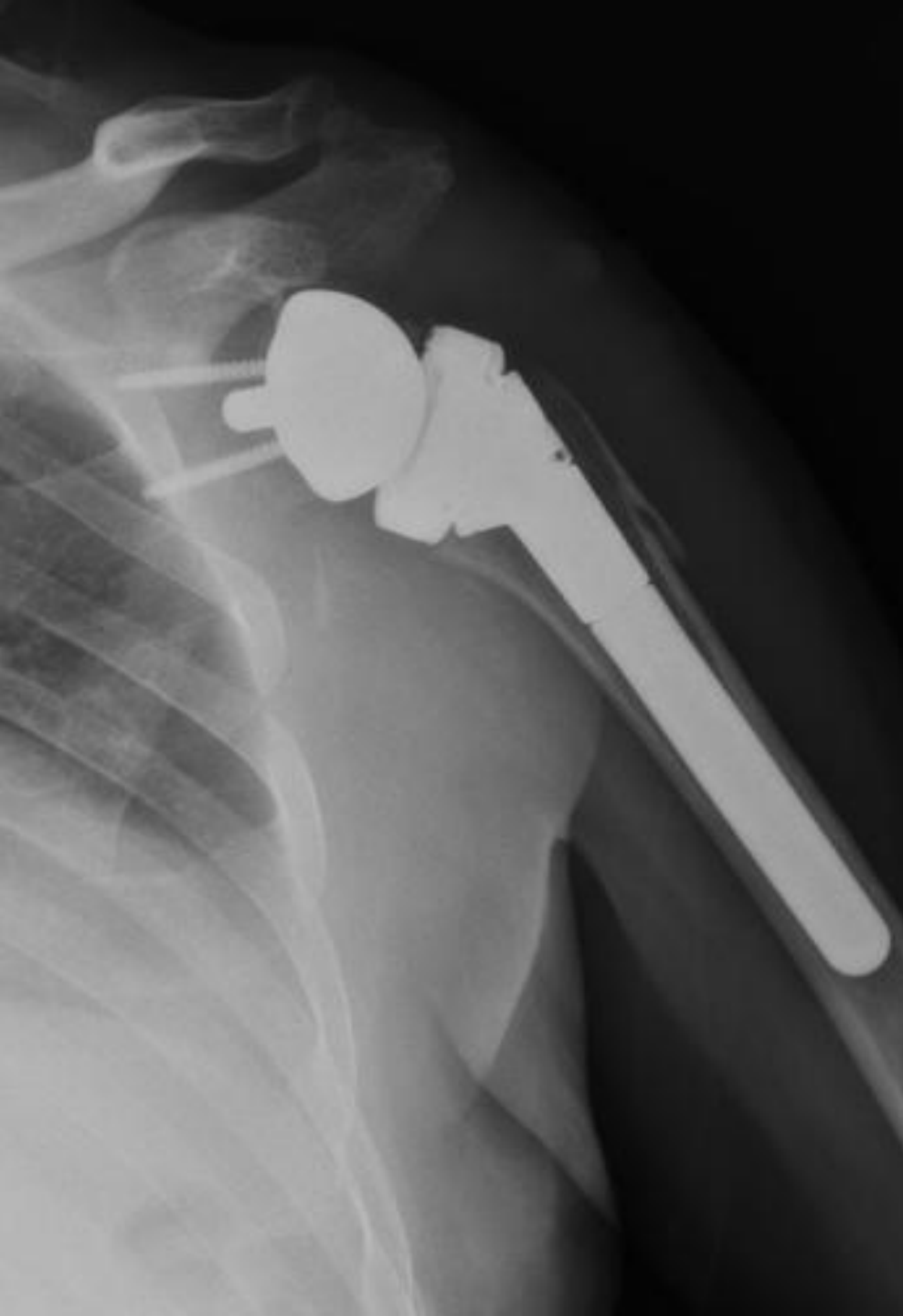
CASE

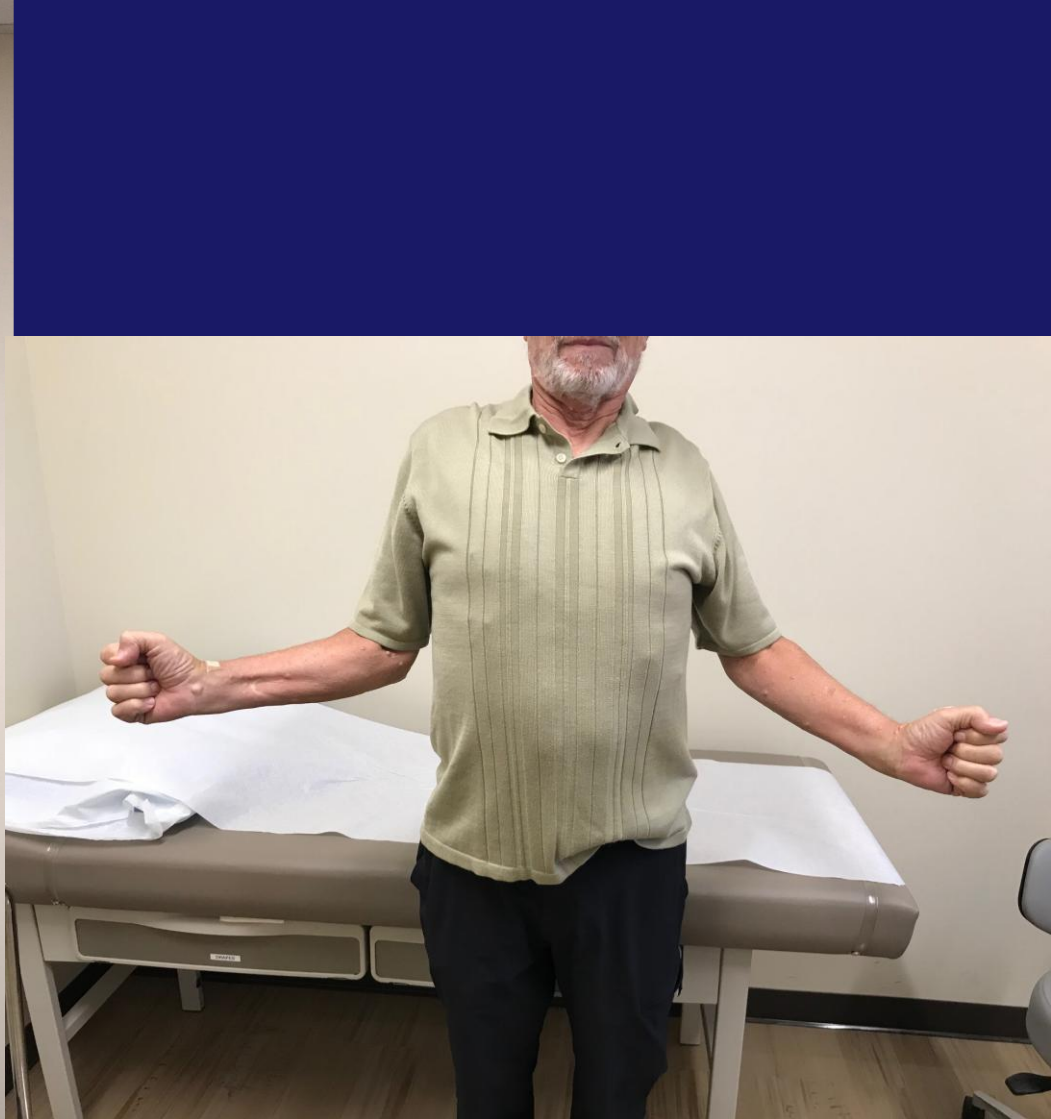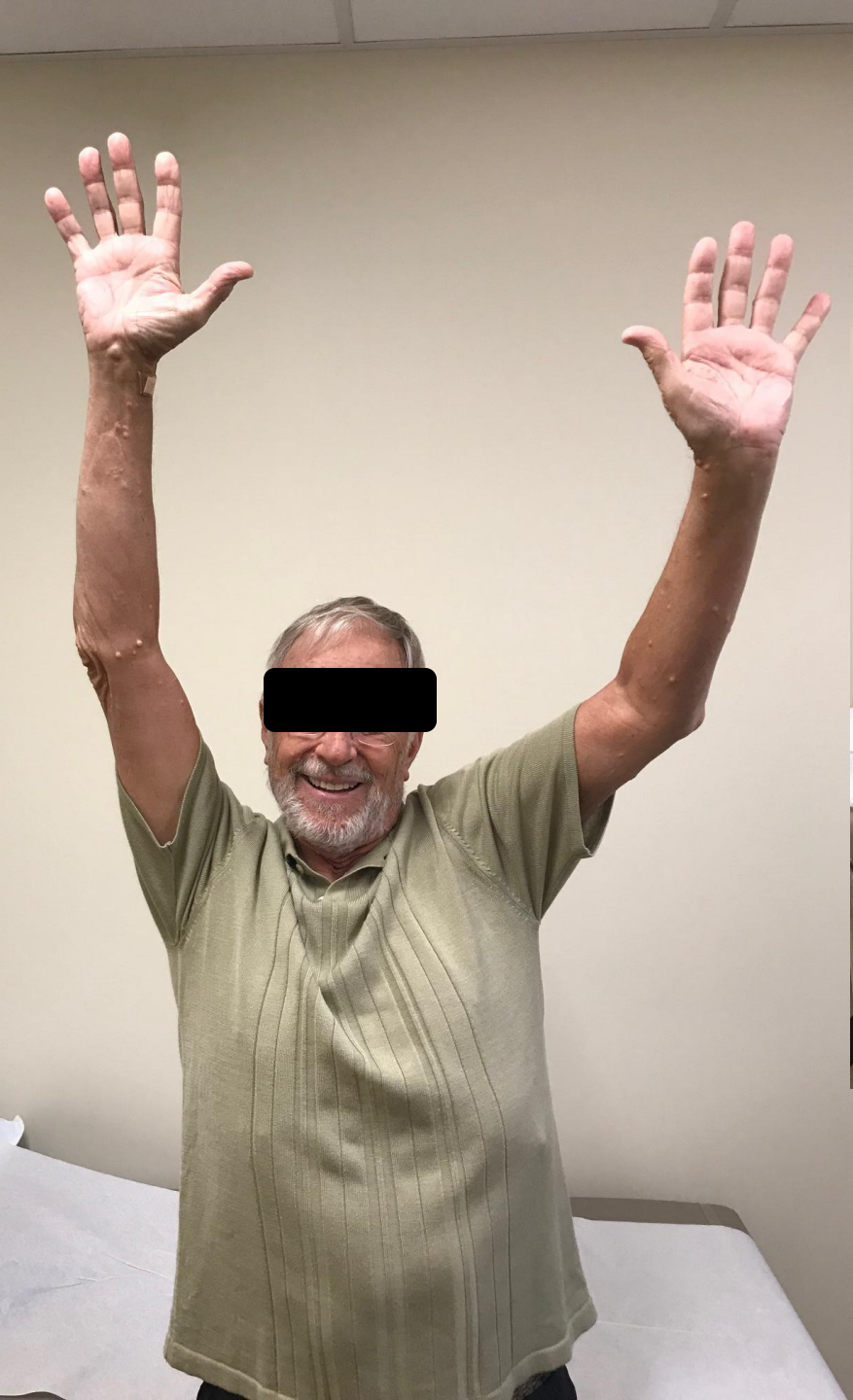
- **72 year old male**
- **Fall from roof, “caught L arm on way down”**
- **Closed, isolated, good pulses, diffuse numbness, motor weak but intact**
- **Neurofibromatosis Type I, hypertension**







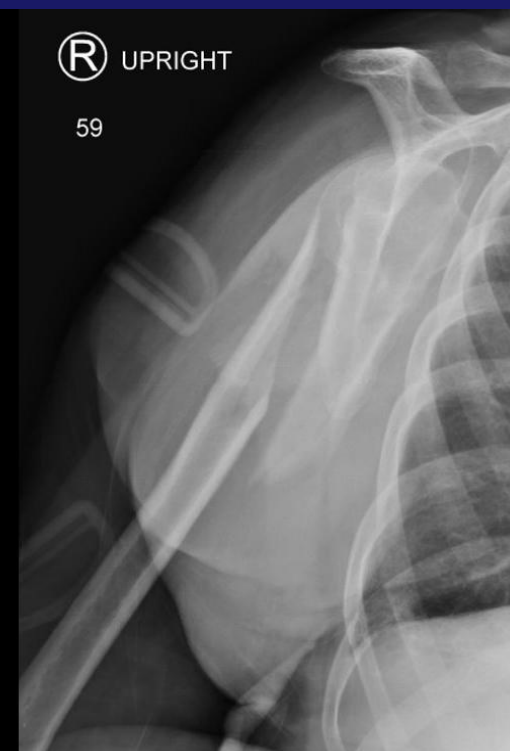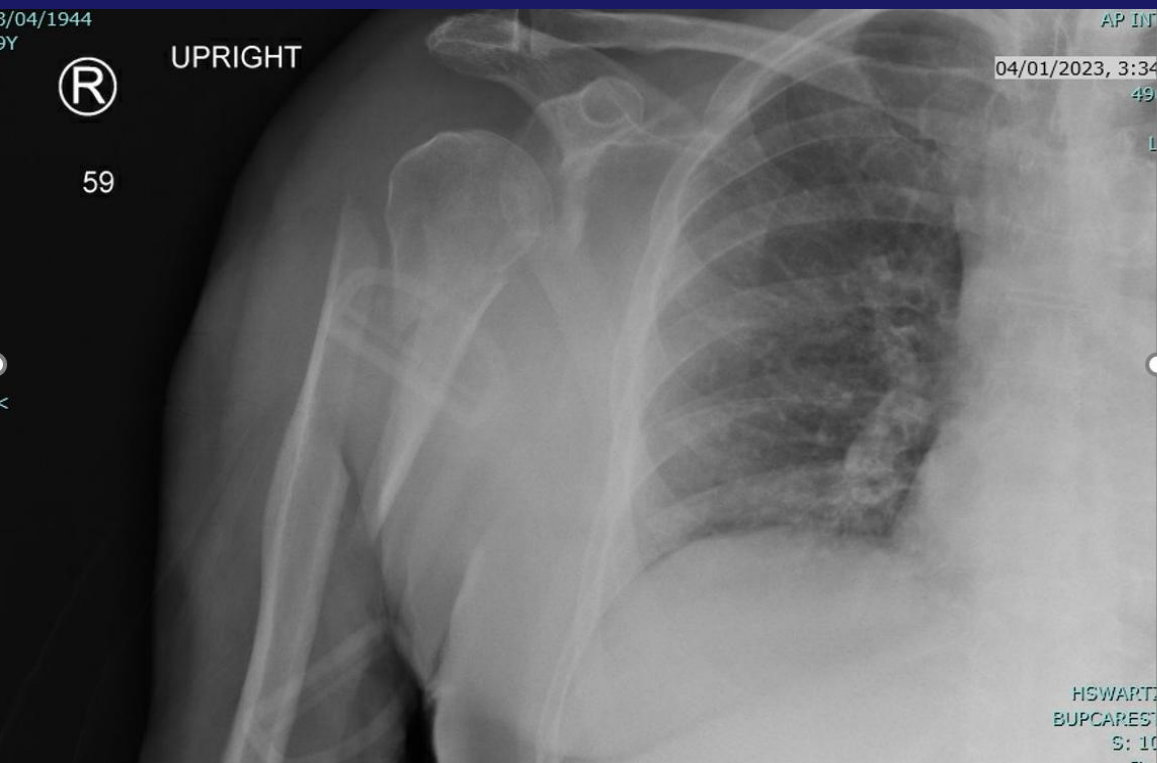




Atoun E, et. al. Management of first-time dislocations of the shoulder in patients older than 40 years: the prevalence of iatrogenic fracture J Orthop Trauma 2013 April;27(4):190-3

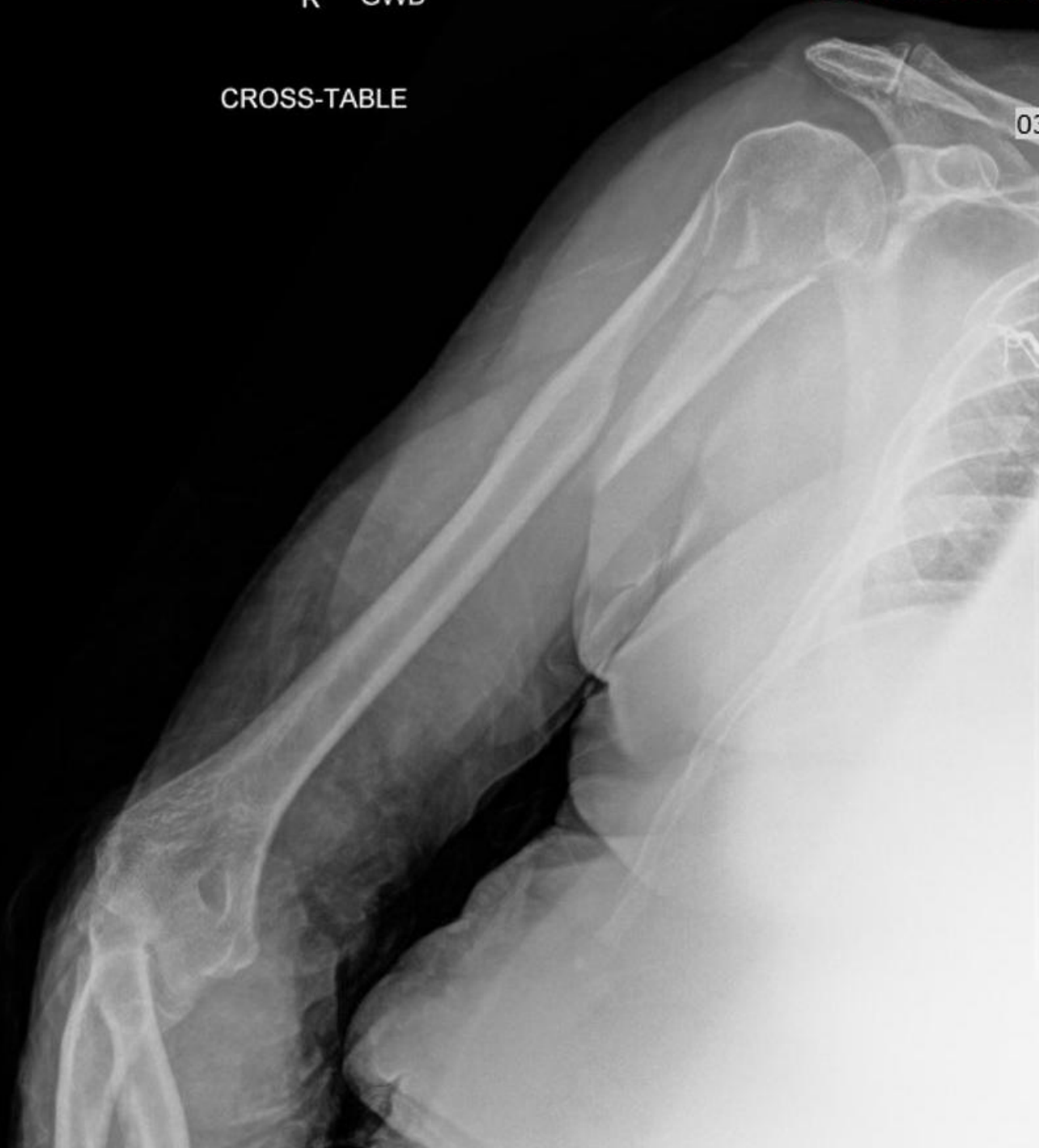- 90 patients**
- 19 associated GT fracture**
- 5 had humeral head sheared off with closed reduction**

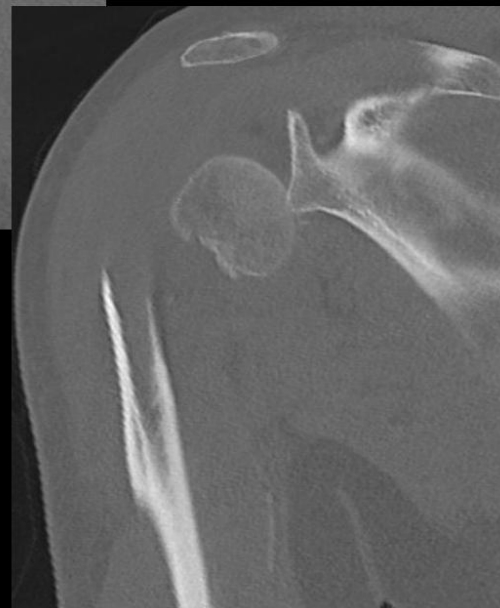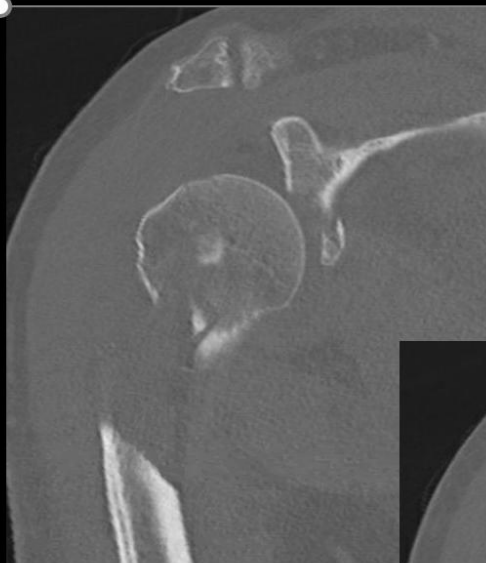
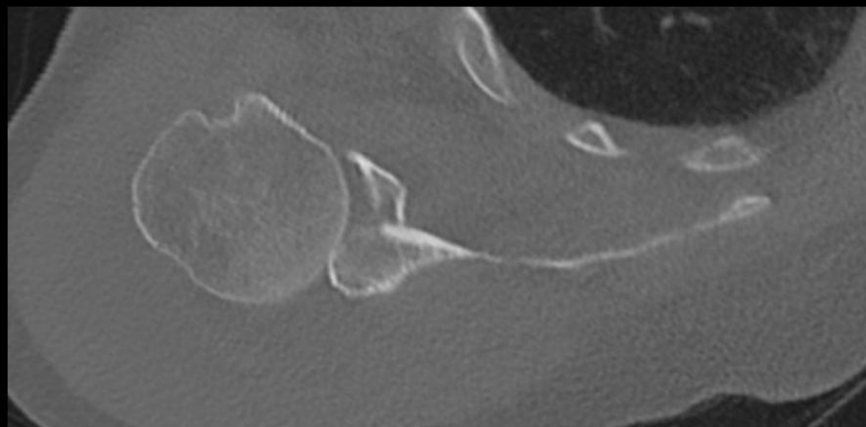
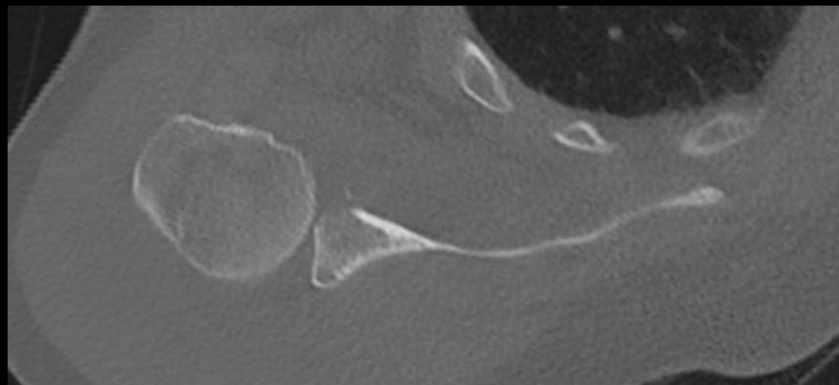
Imaging



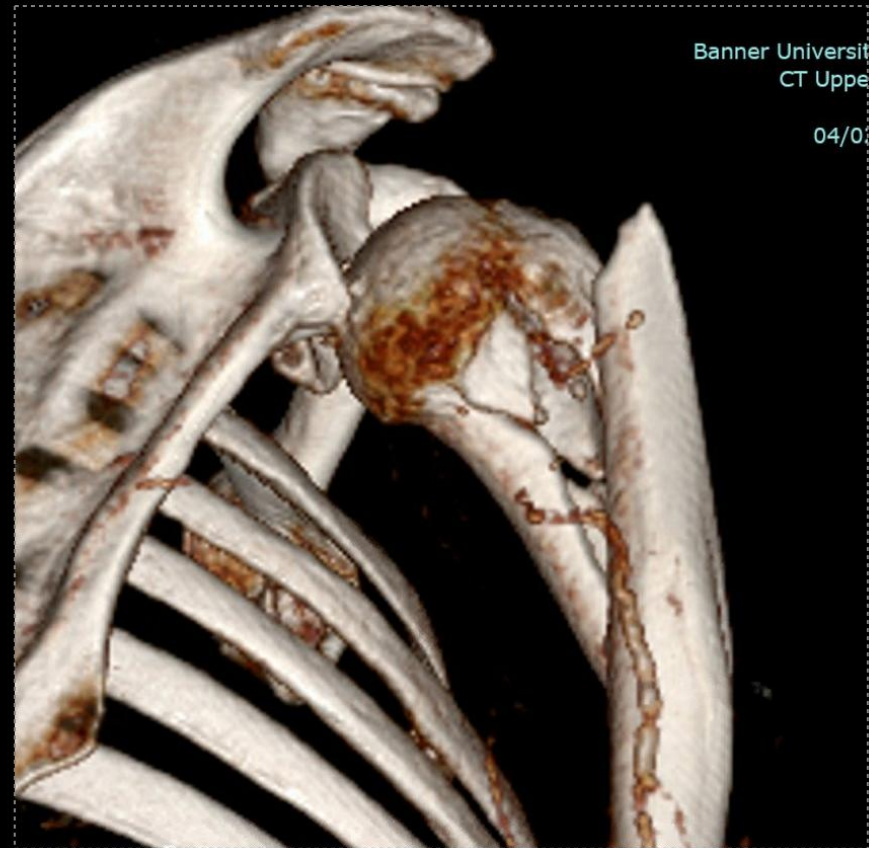
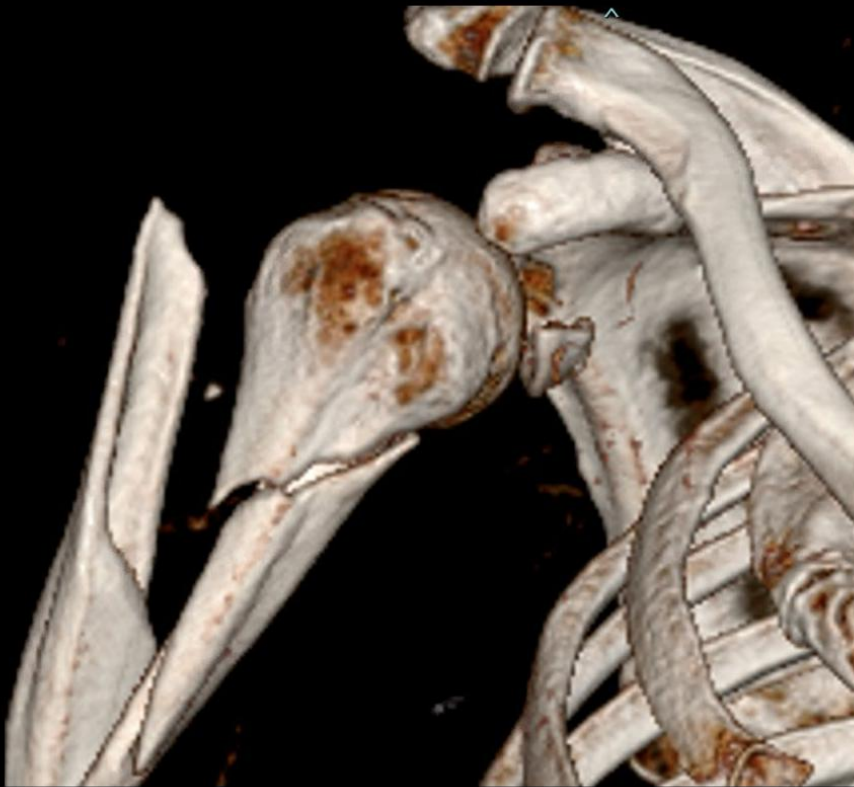
CROSS-TABLE

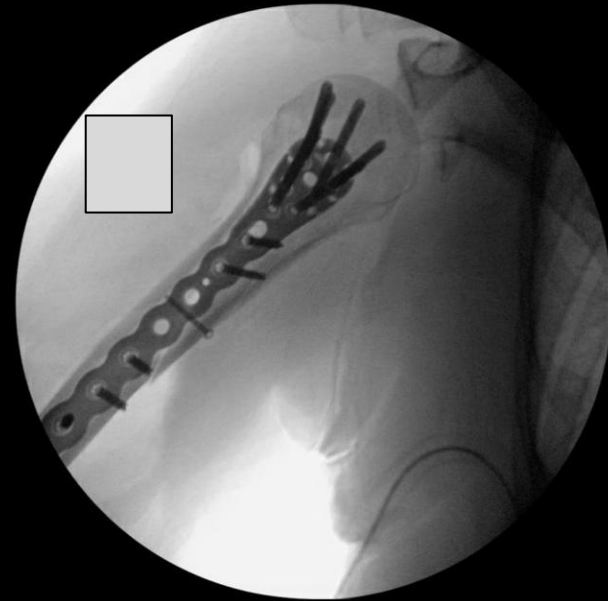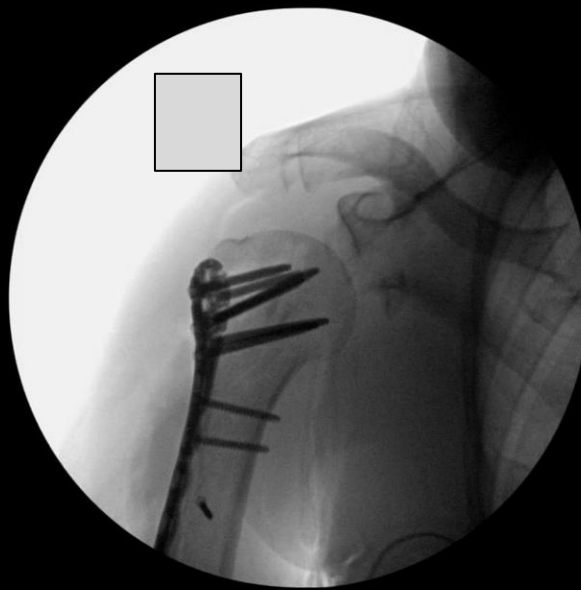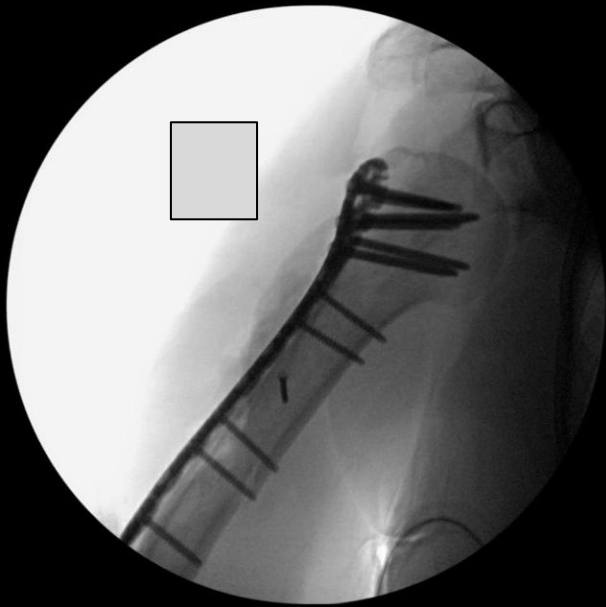03/2





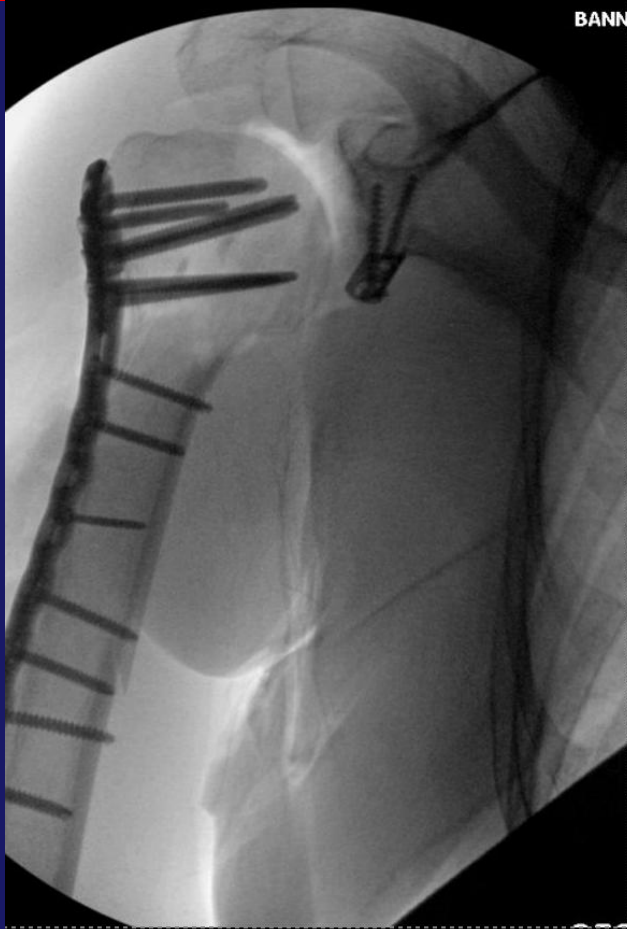3D CT Scan





- **Intraoperative radiograph following fixation of proximal fracture**

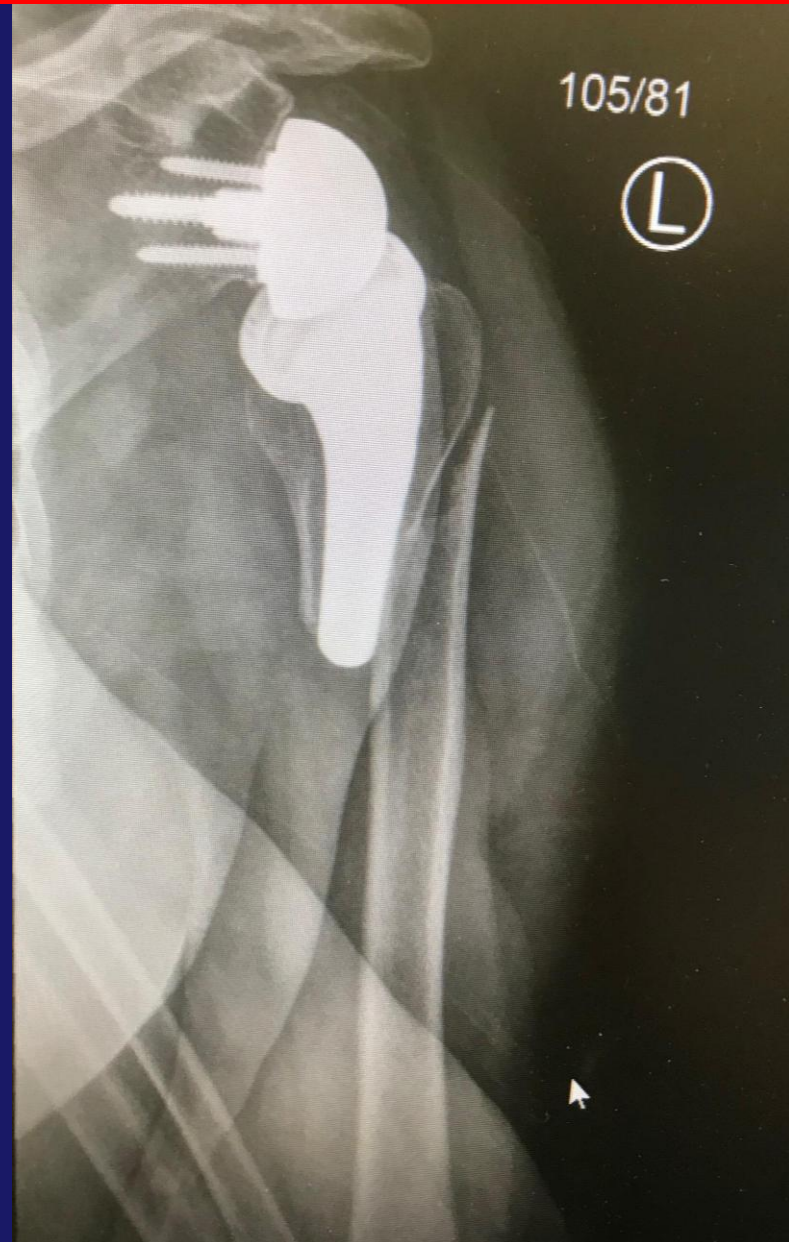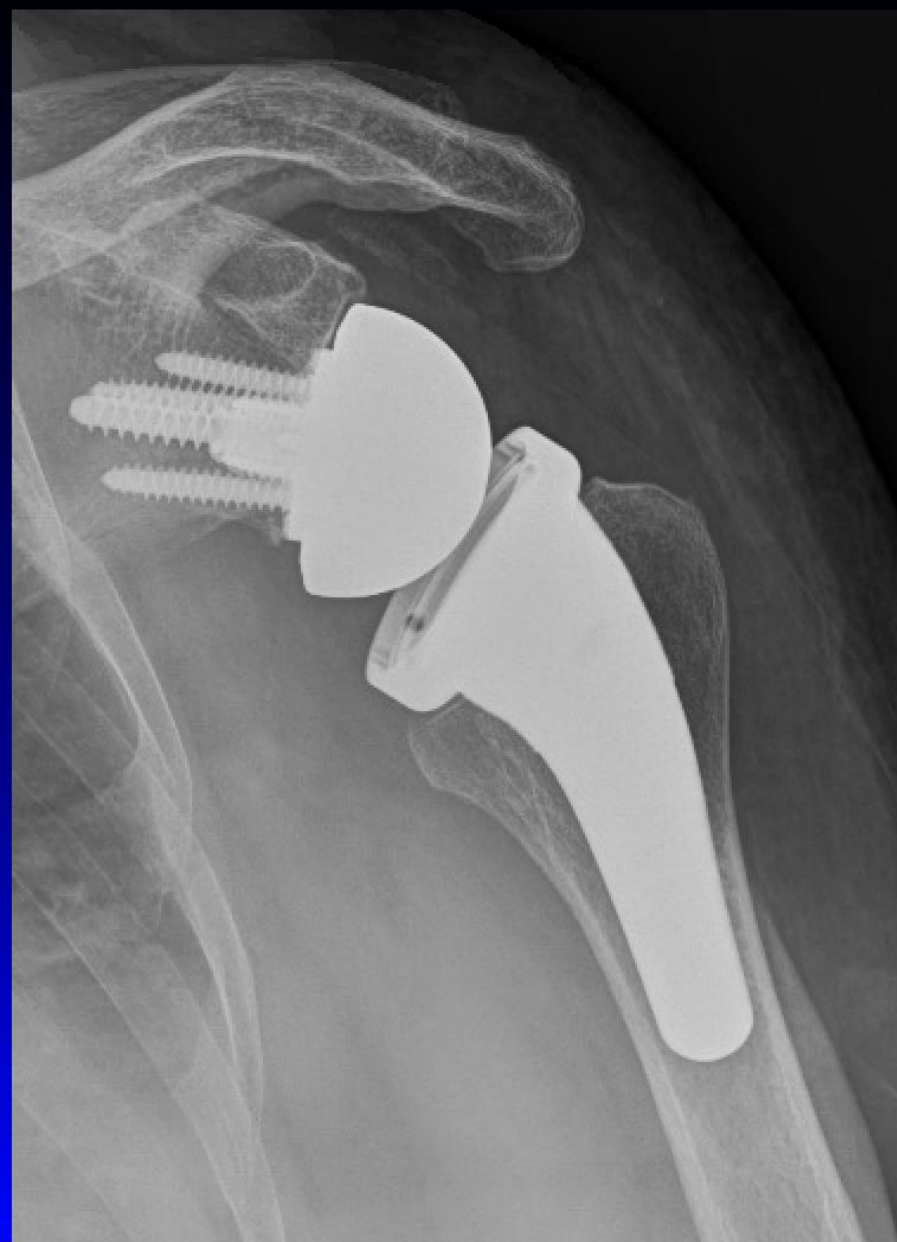Final



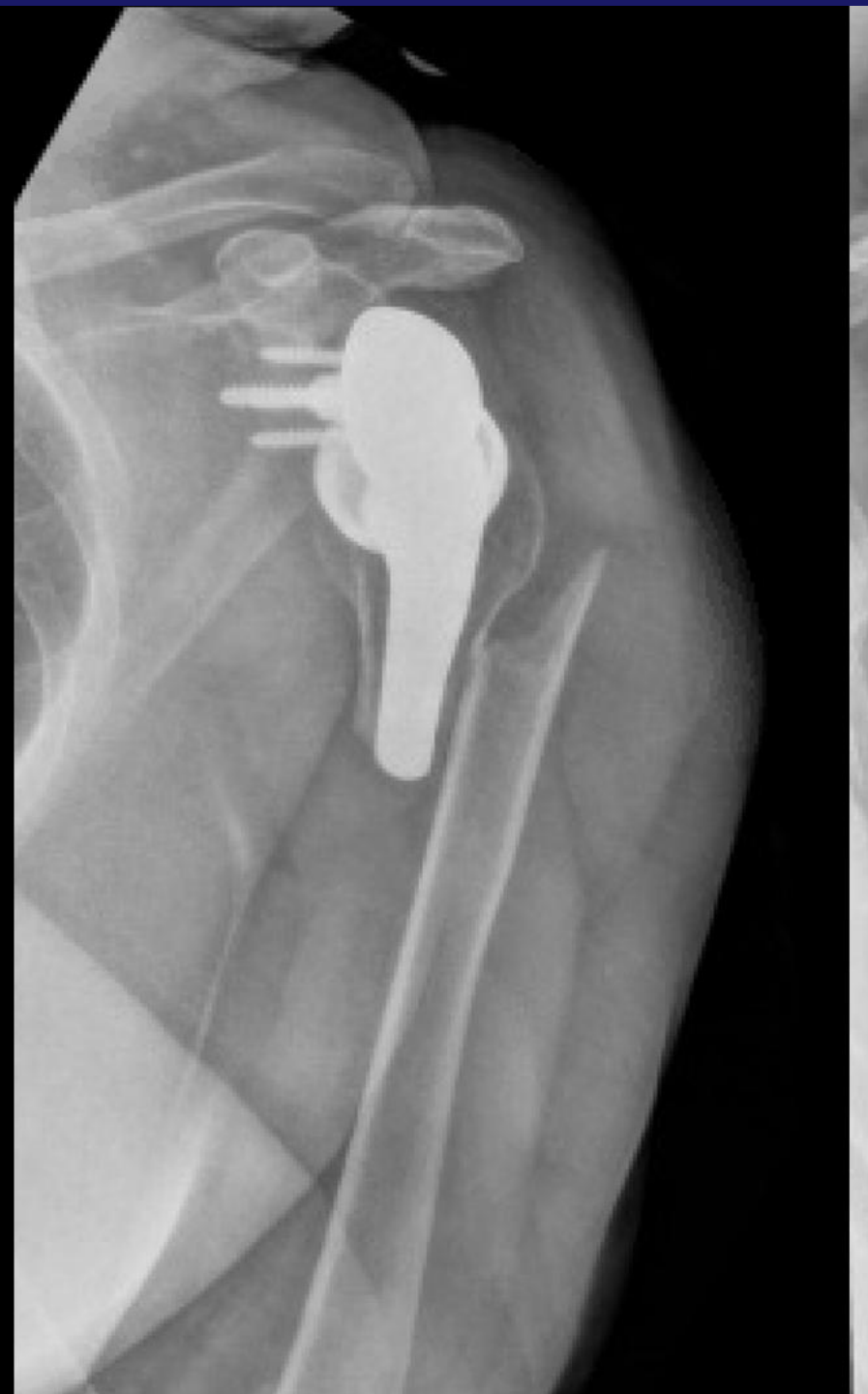CASE

- **77 year old female**
- **RTSA 2 years prior, functioning well**
- **Fall on left arm playing pickleball**
- **Closed, isolated, NV intact**
- **Healthy and active**

Preop Imaging

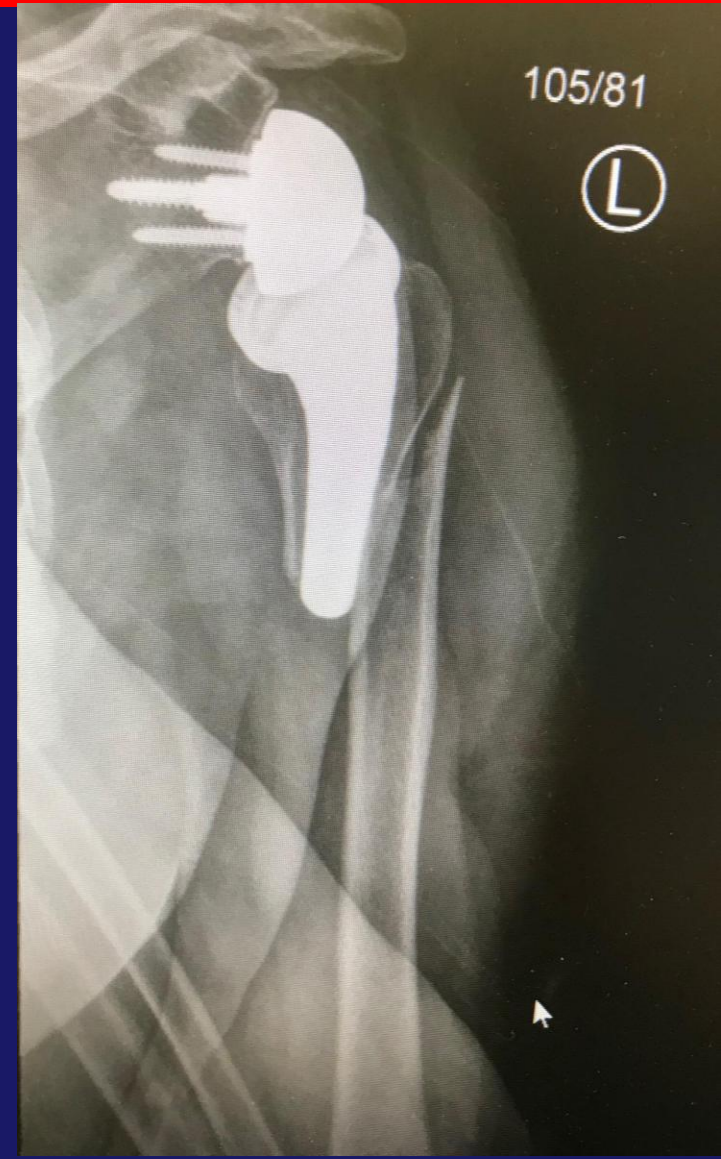

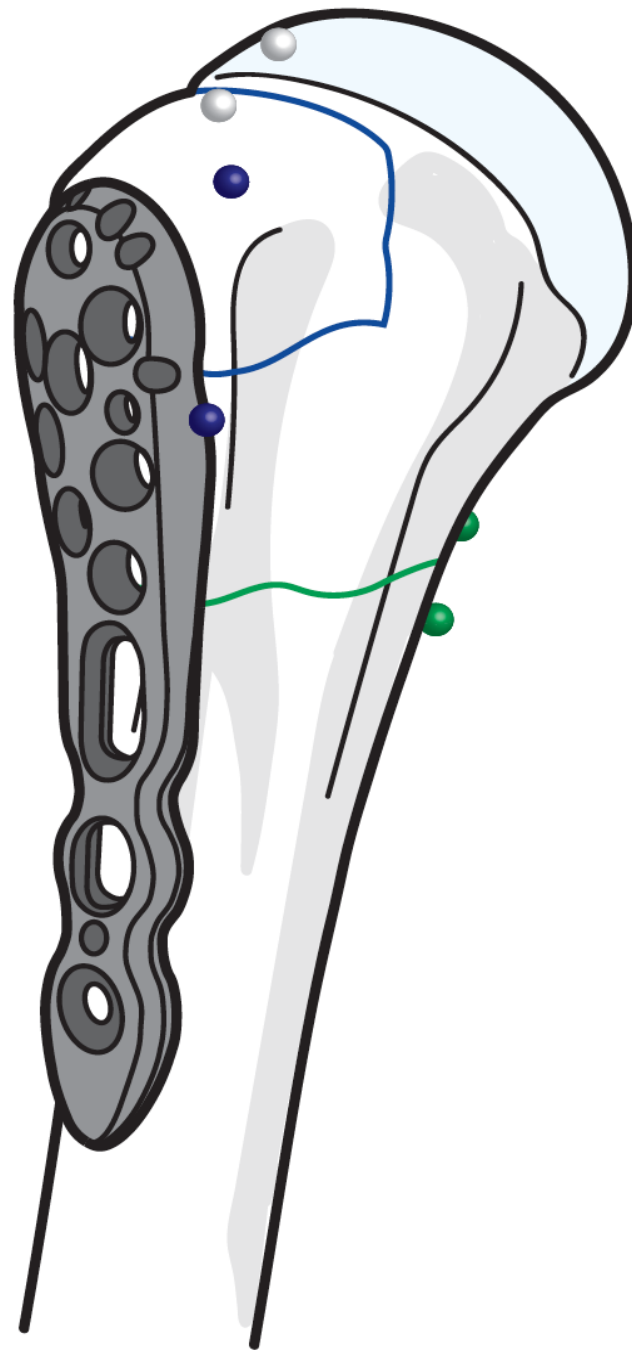
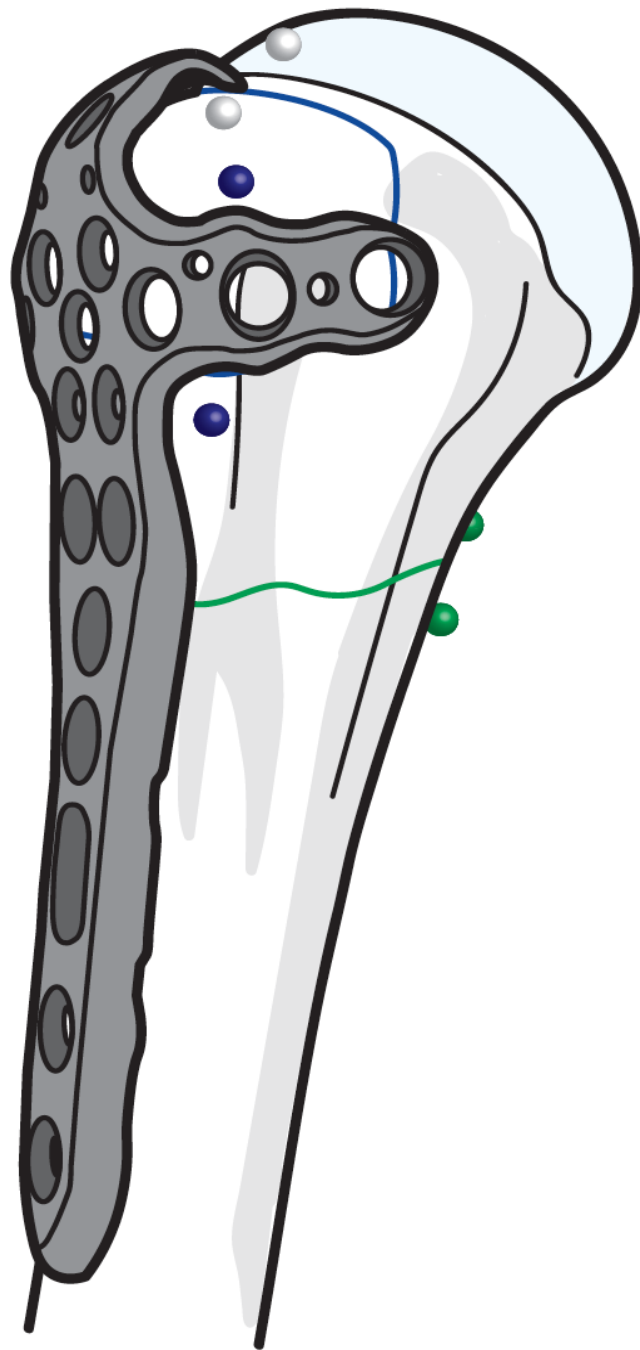
- **2 weeks later**
- **Pain and instability**
- **“wants something done”**



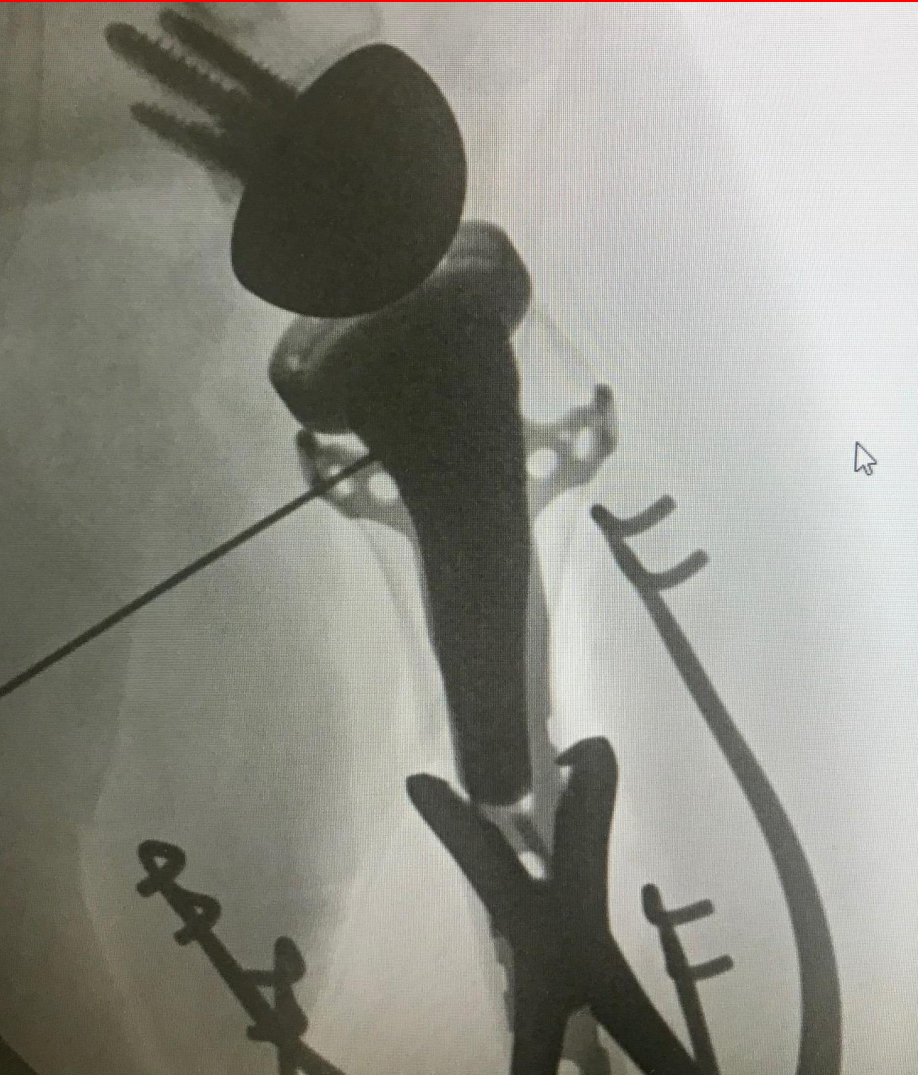
Decision making

- Shoulder function good
- Humeral stem solid
- Type B fracture
- Limited proximal bone
- Biology good



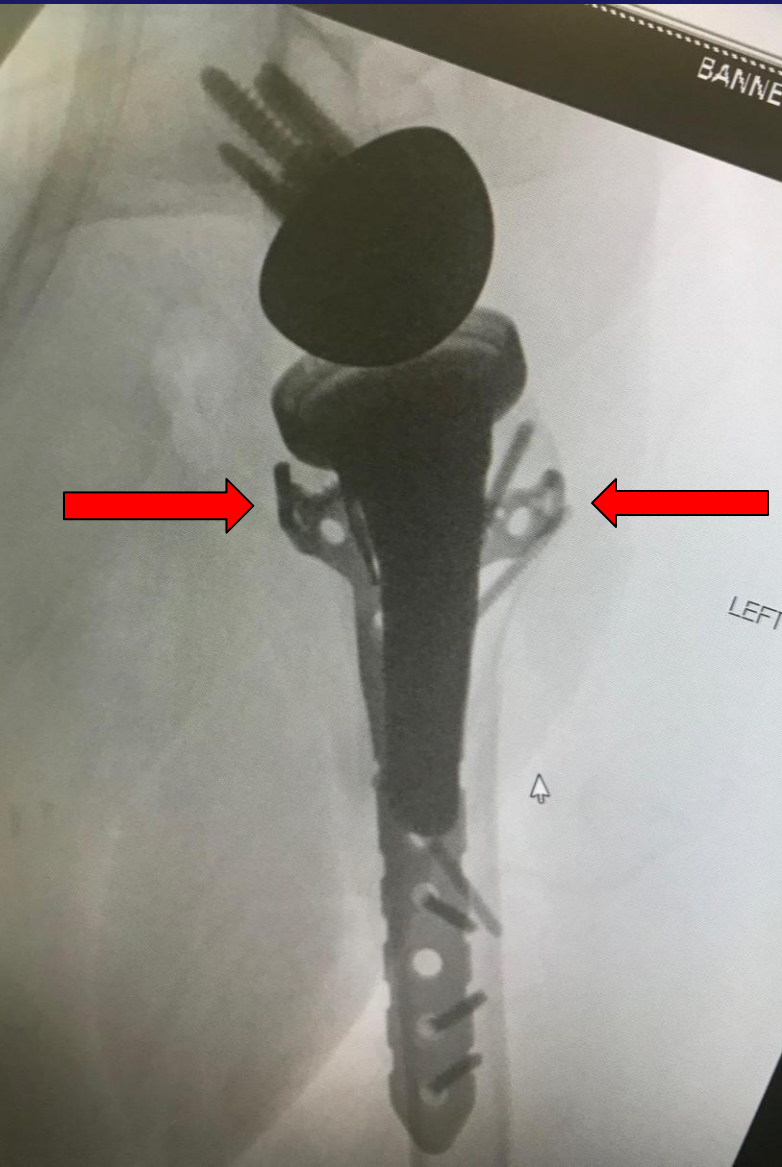


Intra-op radiographs

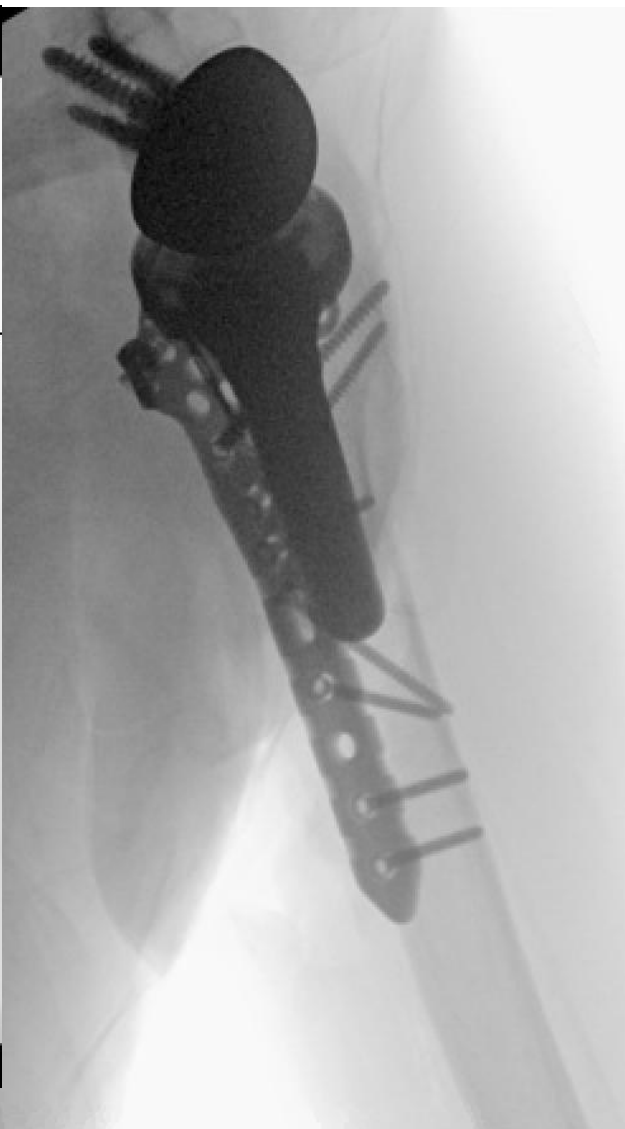
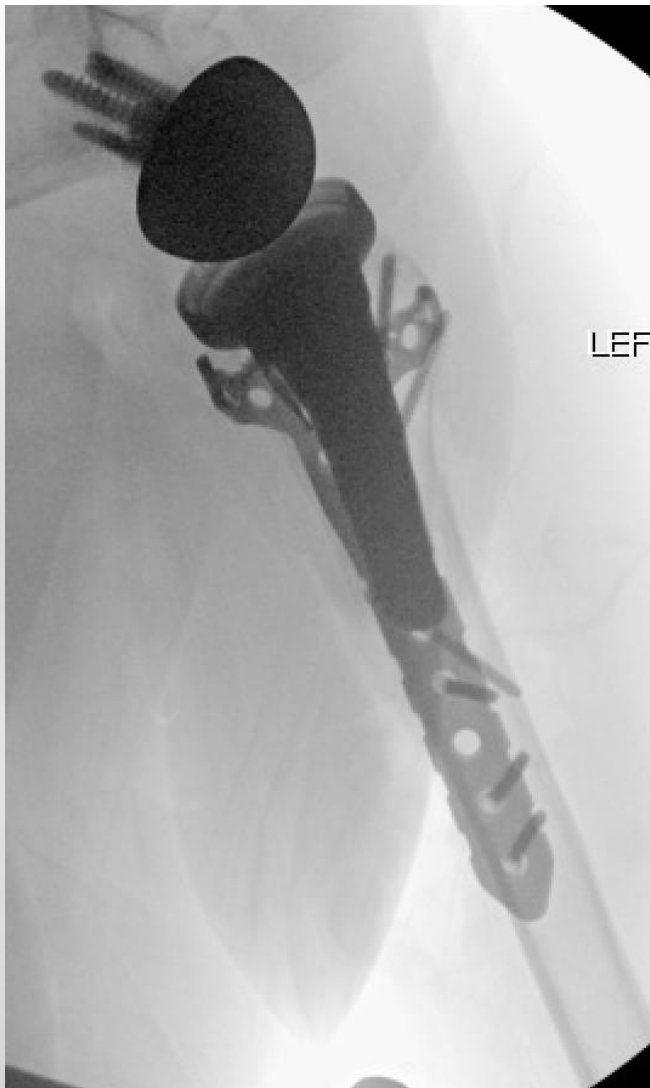
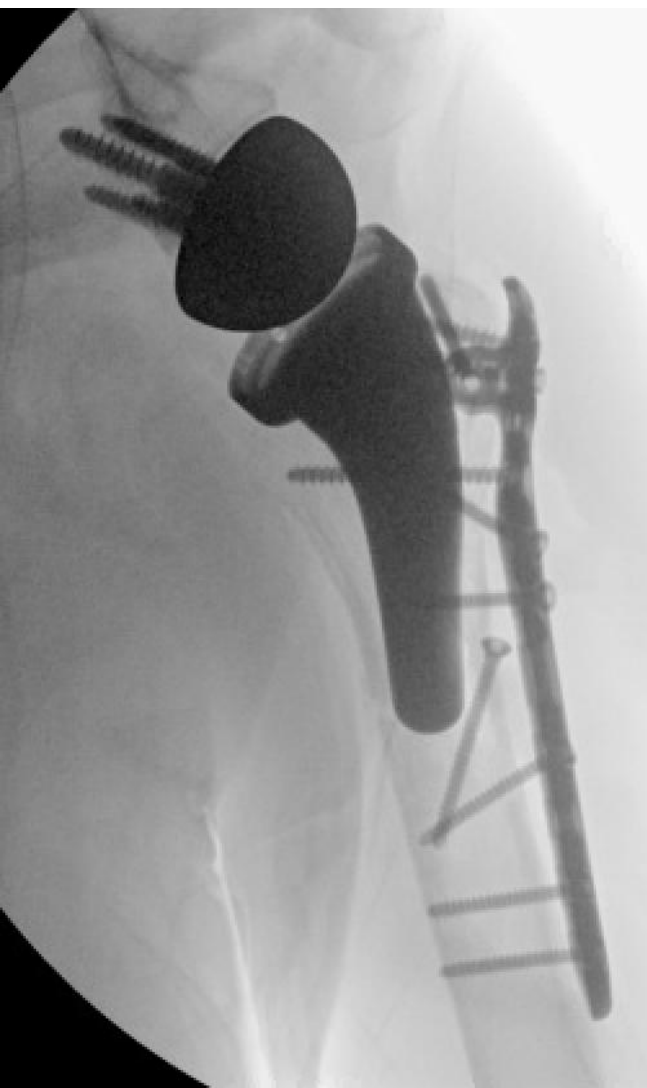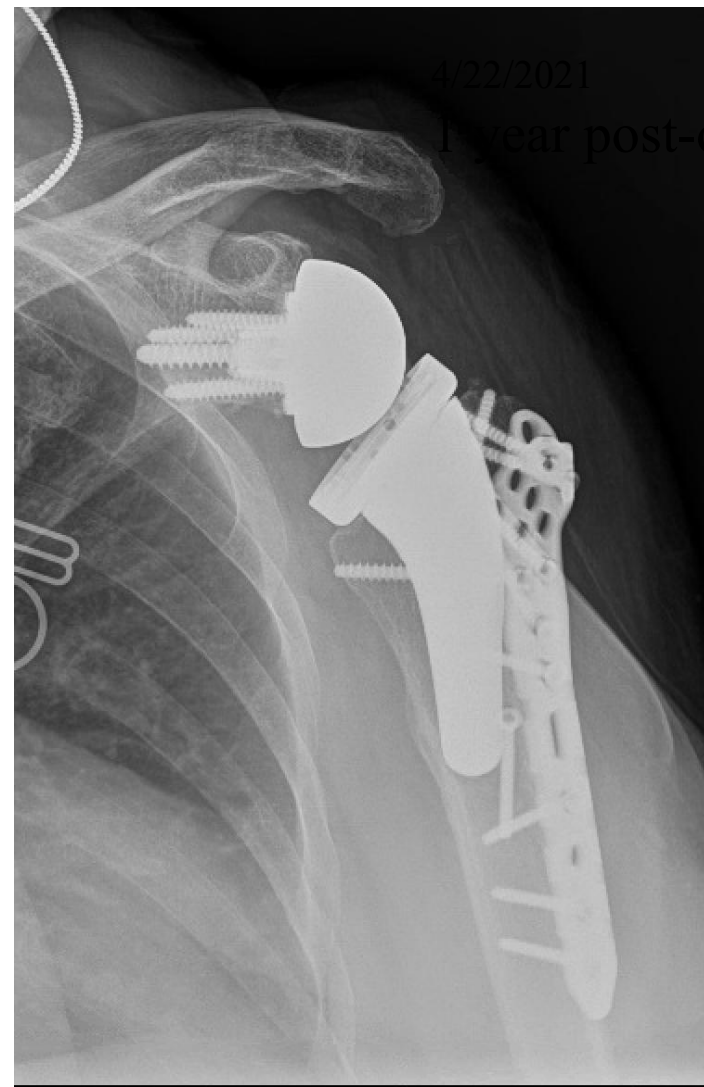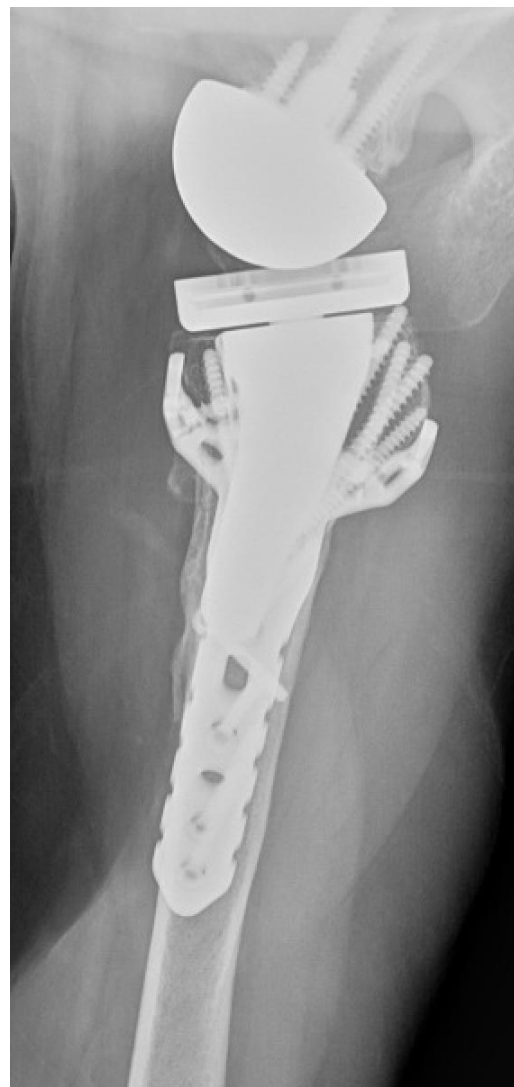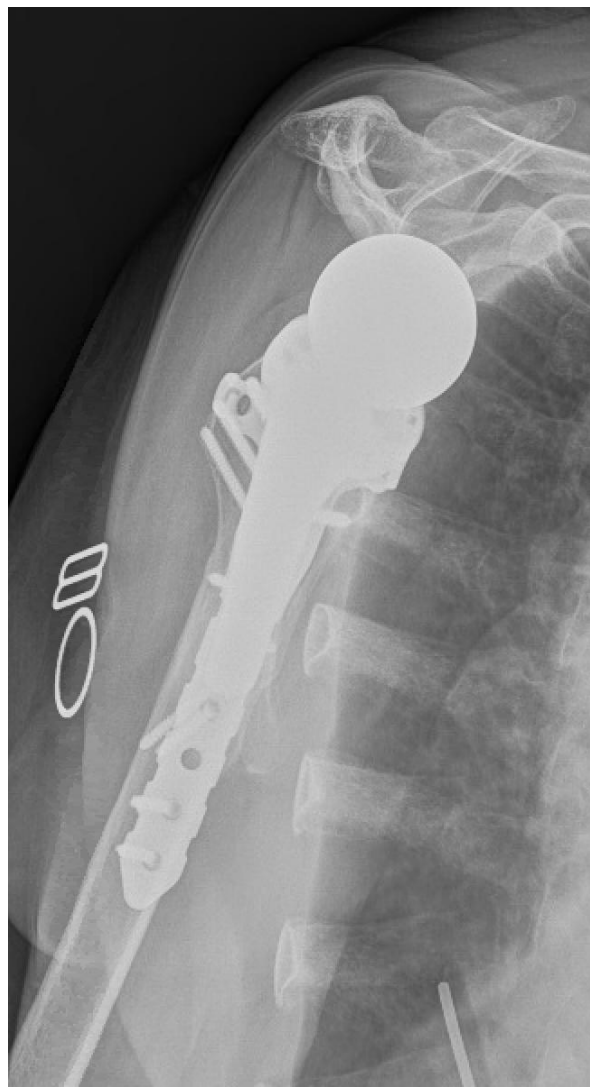- Deltpectoral approach
- No sign of infection
- Stem solid
- Fracture reduced
- Provisional pinning
- Plate application

Intra-op radiographs



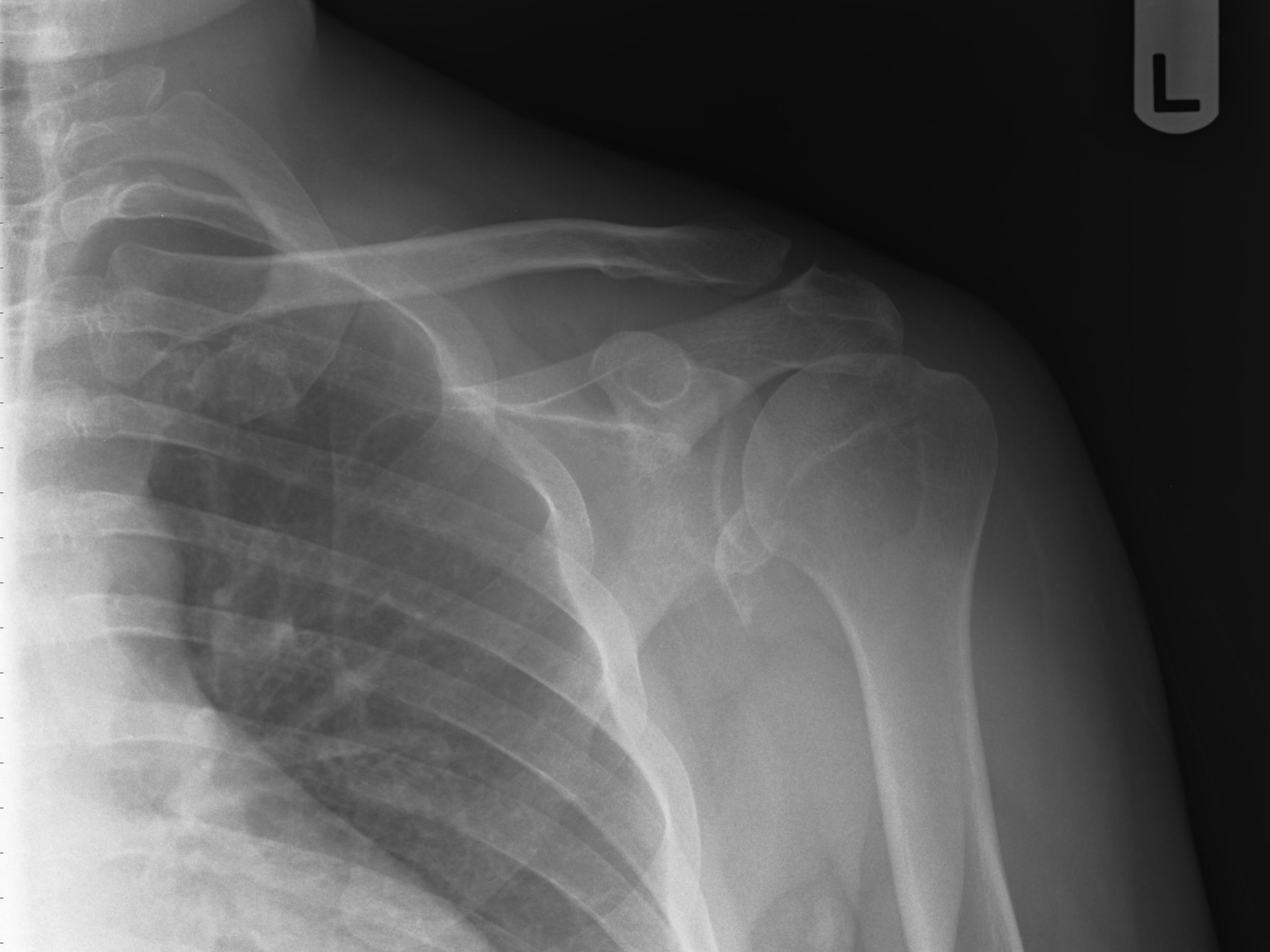
- Intra-operative contour of flanges to bone “embraces” proximal fragment
- Stabilizes proximal fragment where fixation is often limited





CASE 6

- 42 year old male
- Fall on stairs, caught L arm in staircase
- Dx “Rotator cuff strain”
- Referred for definitive care
- Painful, stiff shoulder
- Closed, isolated, NV intact



1989 Dec 03 M 36

Acc

Acq Tm: 1

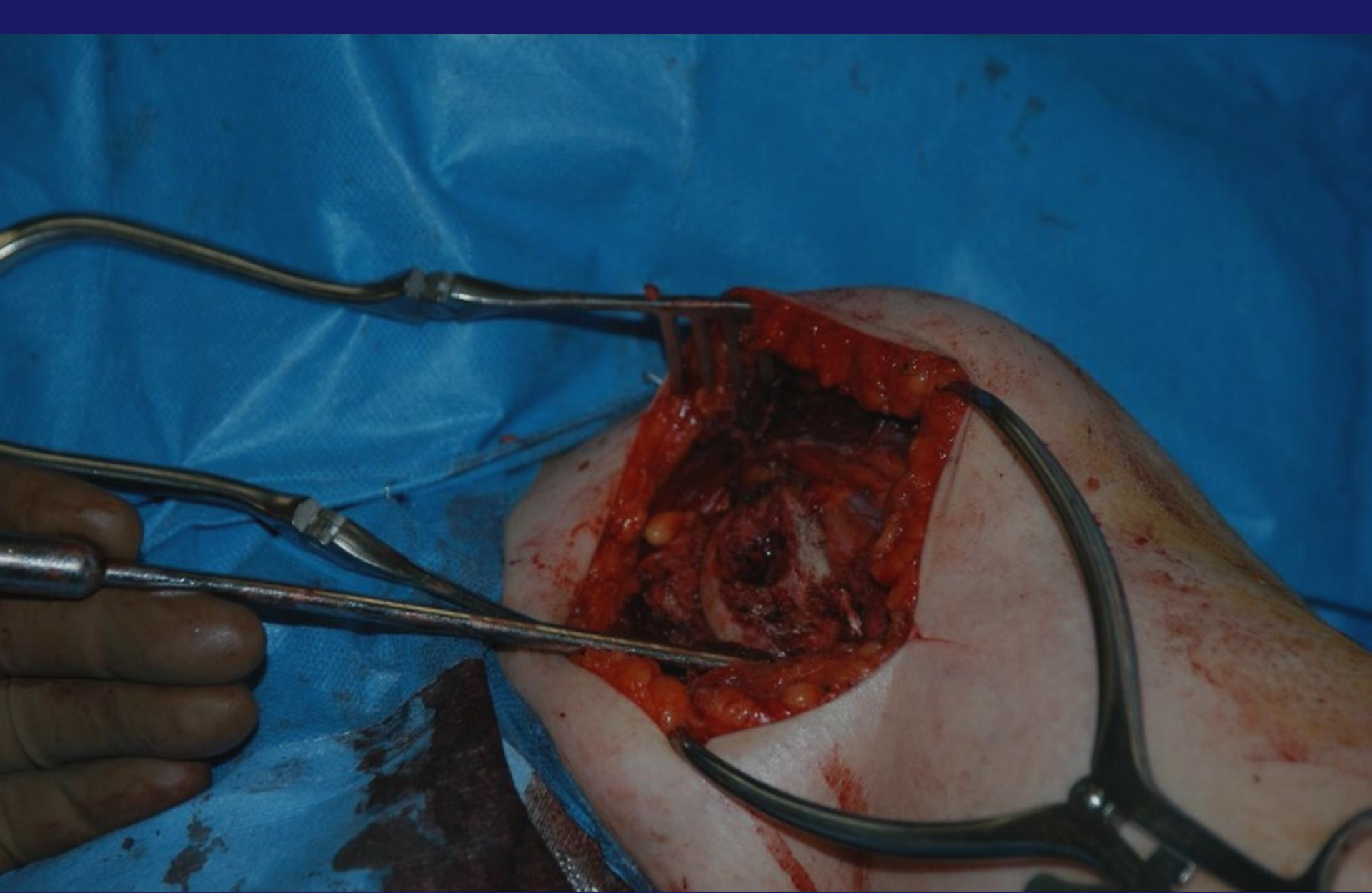DCM / Id:ID

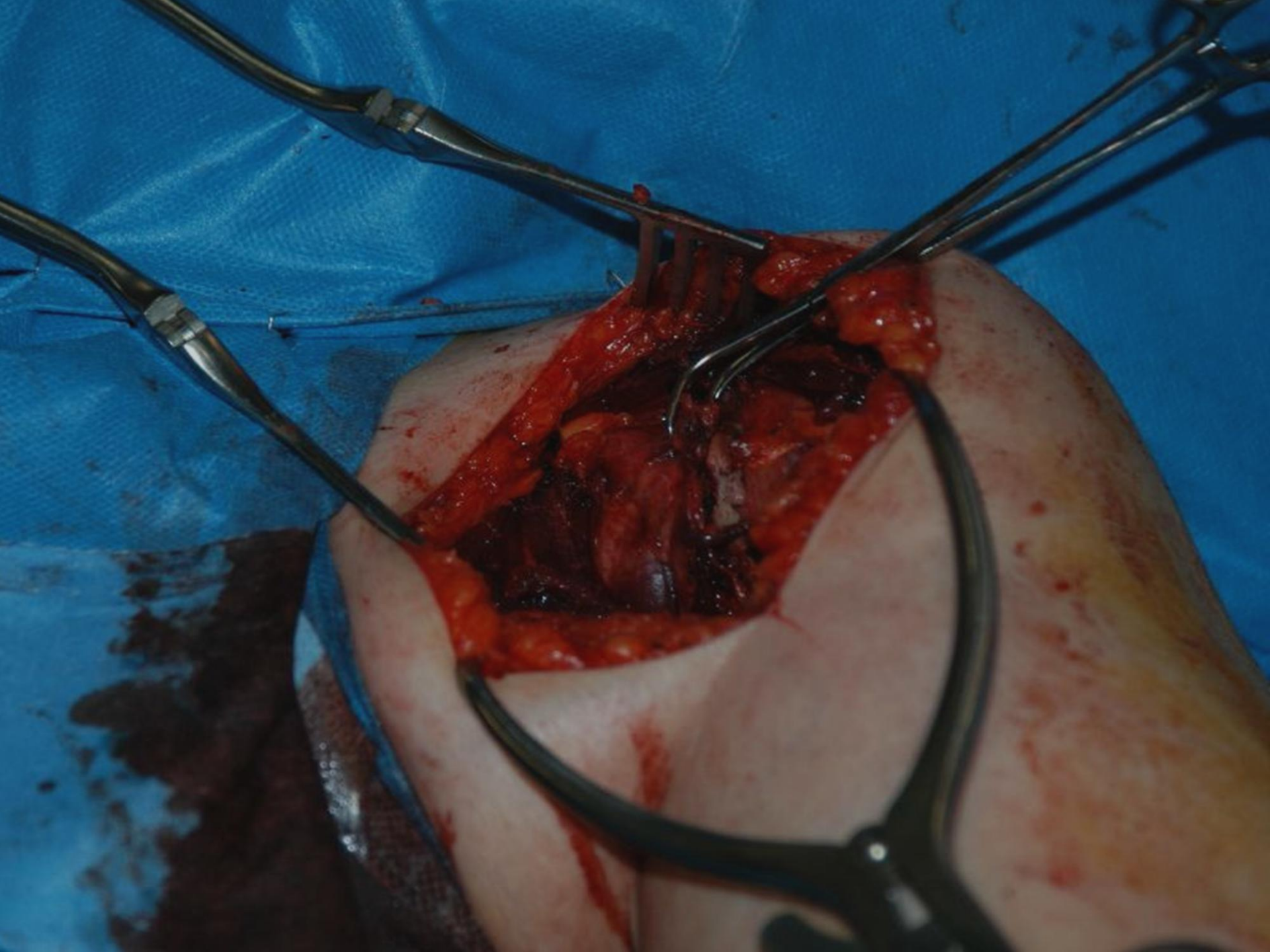
P

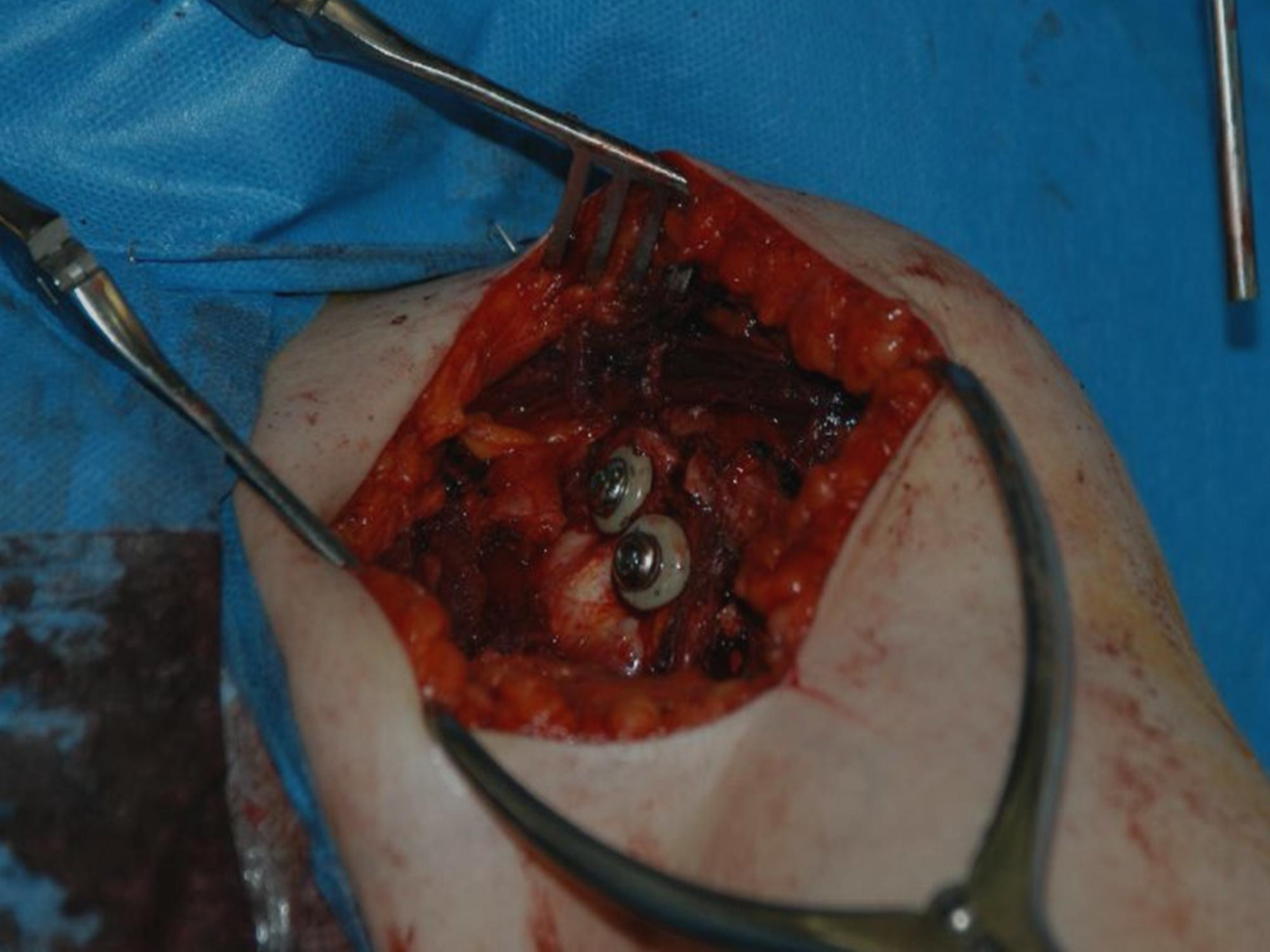
DFOV: 2 27

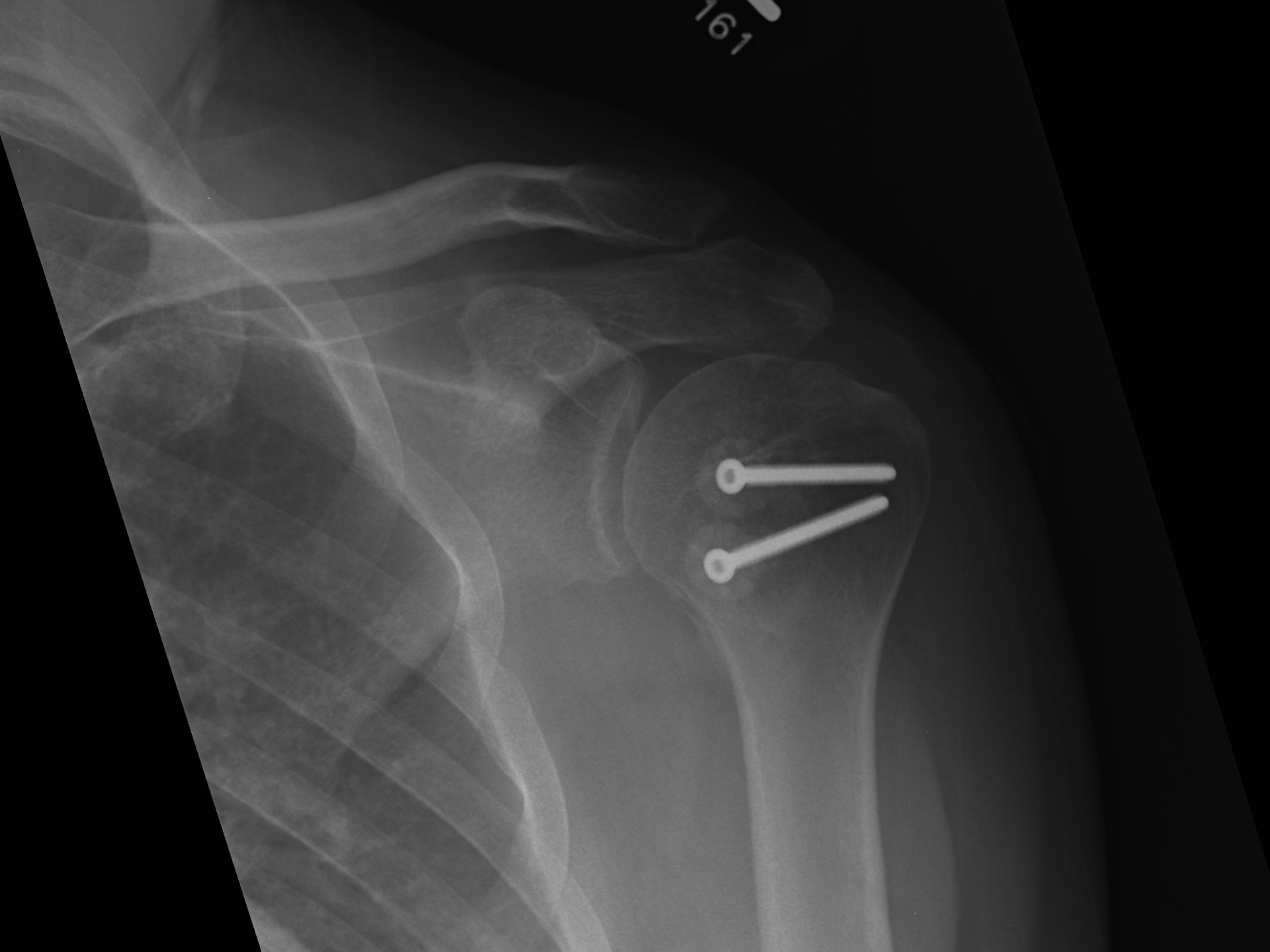
Lin:DCM / Id:ID

I





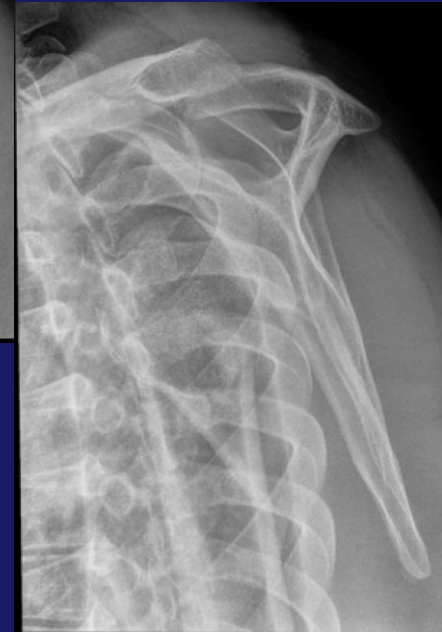
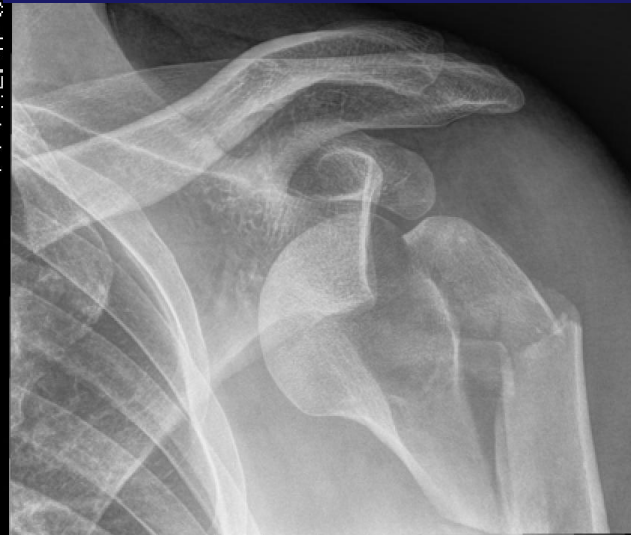
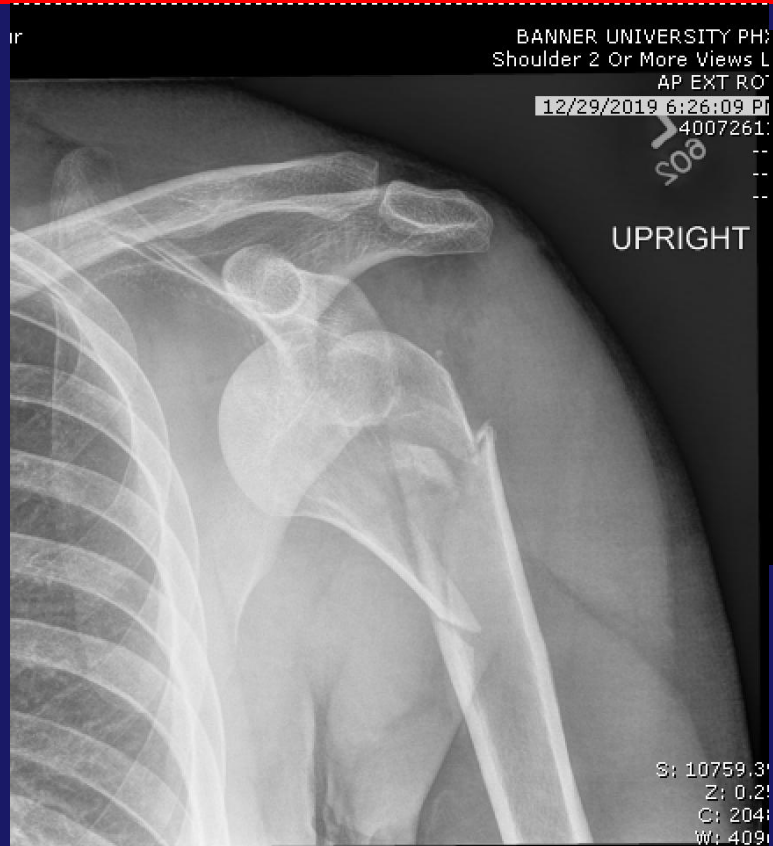


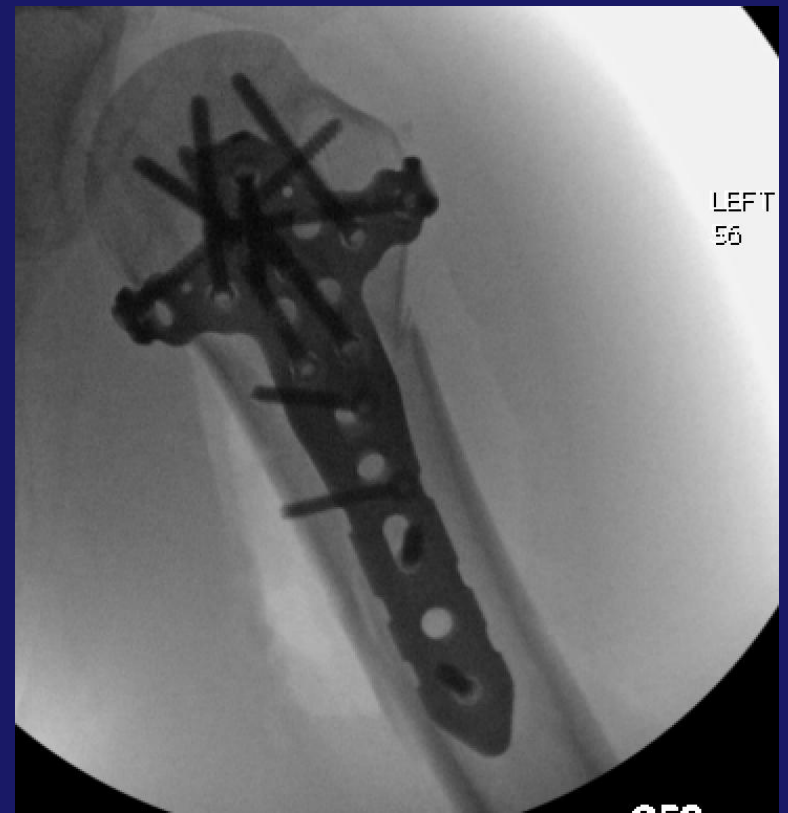
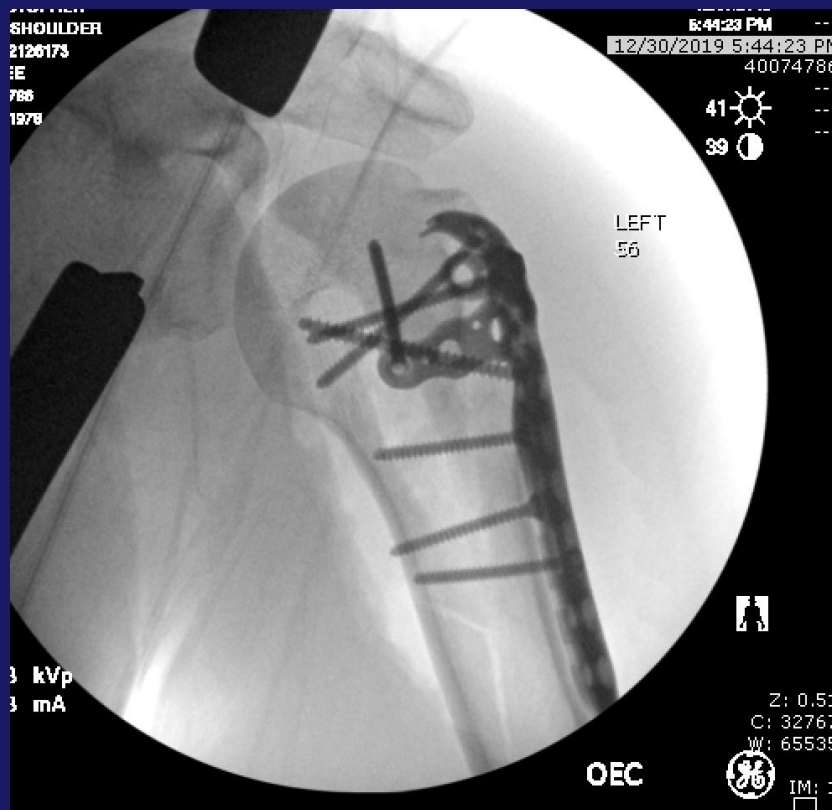41M, proximal humerus fracture-dislocation

- **Associated axillary nerve injury**
- **Biceps tendon laceration**
- **No significant past medical history**
- **Non-dominant side**
- **Mountain biking fall (3 hours prior to arrival at ER)**

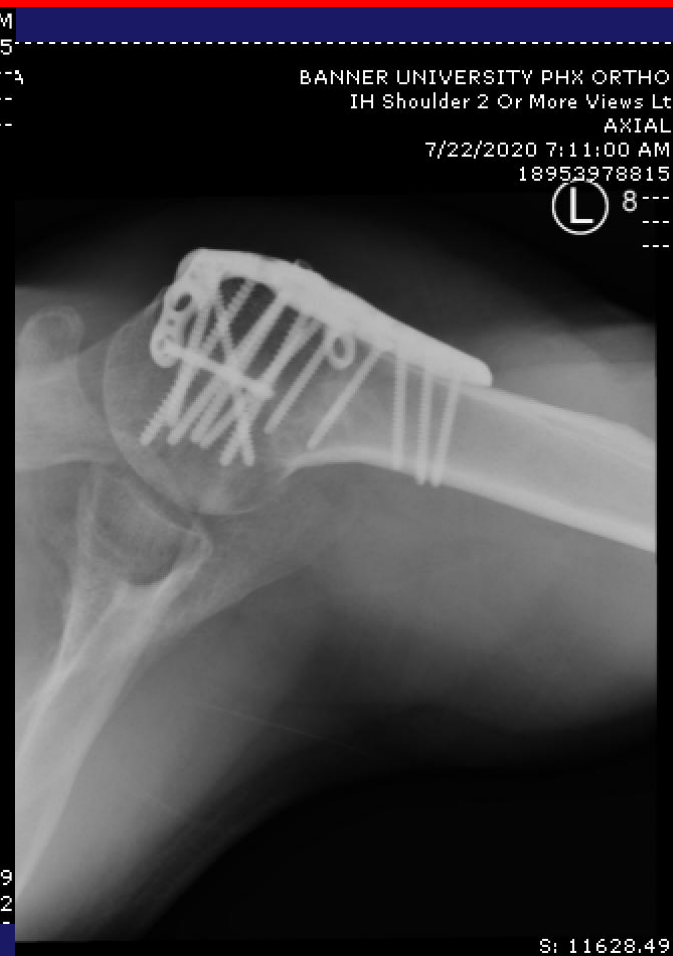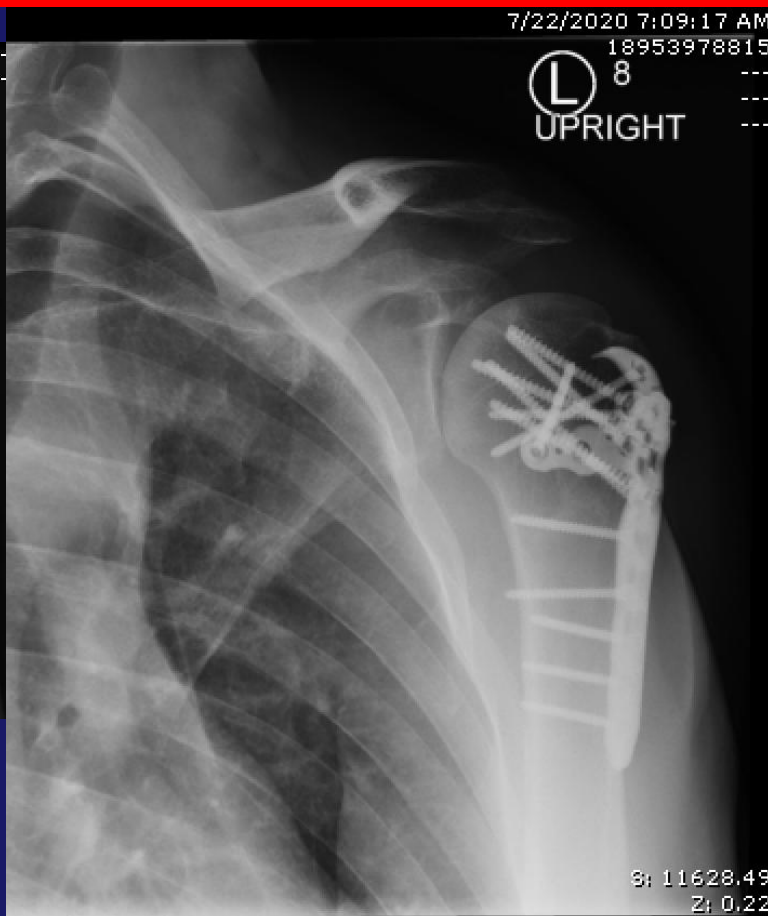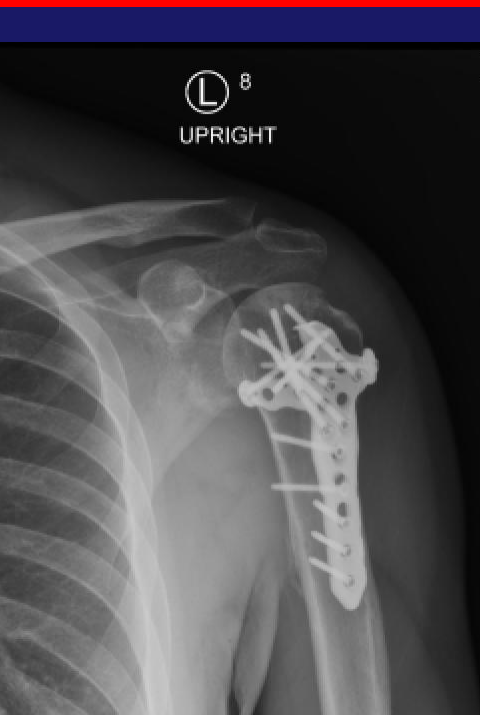12/29/19



OR on 12/30/19



7/22/20



Outcomes – 7/22/20

