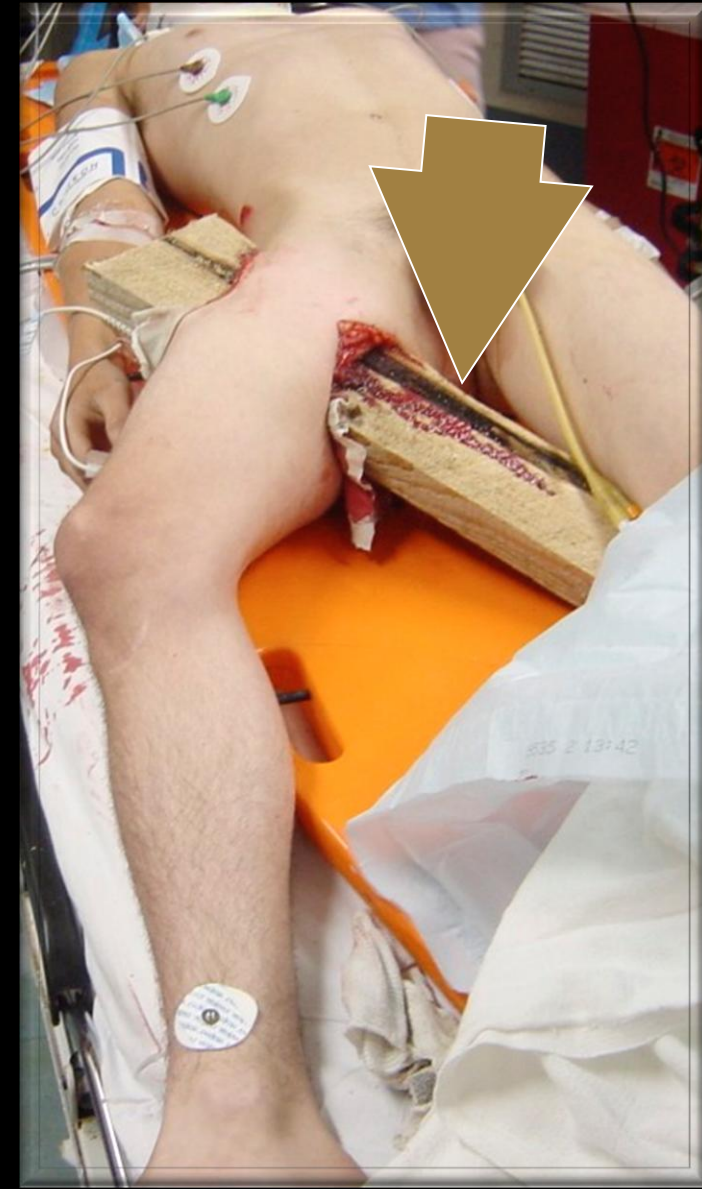

# Subtrochanteric Fractures

## Avoiding malalignment and loss of fixation

Amir Matityahu, MD

Professor of Orthopaedic Surgery  
UCSF and SFGH Departments of Orthopaedic Surgery

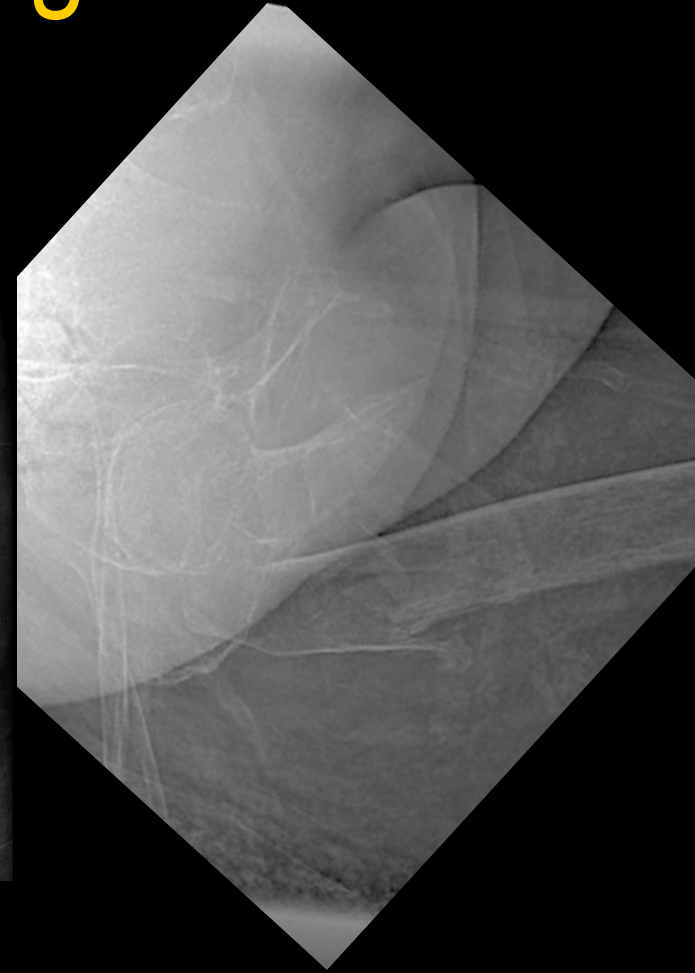
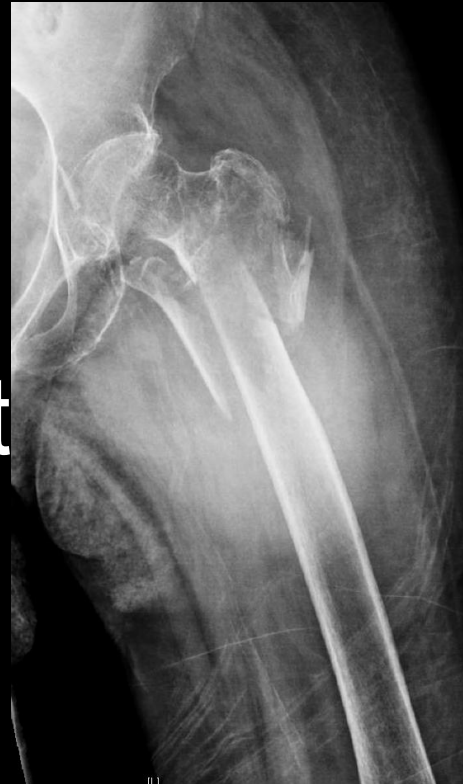

# Outline – Subtrochanteric Fractures

- What not to do
- Anatomy that has predisposition to varus and procurvatum
- Mechanical causes of malreduction
- Intraop technical causes of malreduction
- Treatment options and gold standard
- Tips for successful reduction

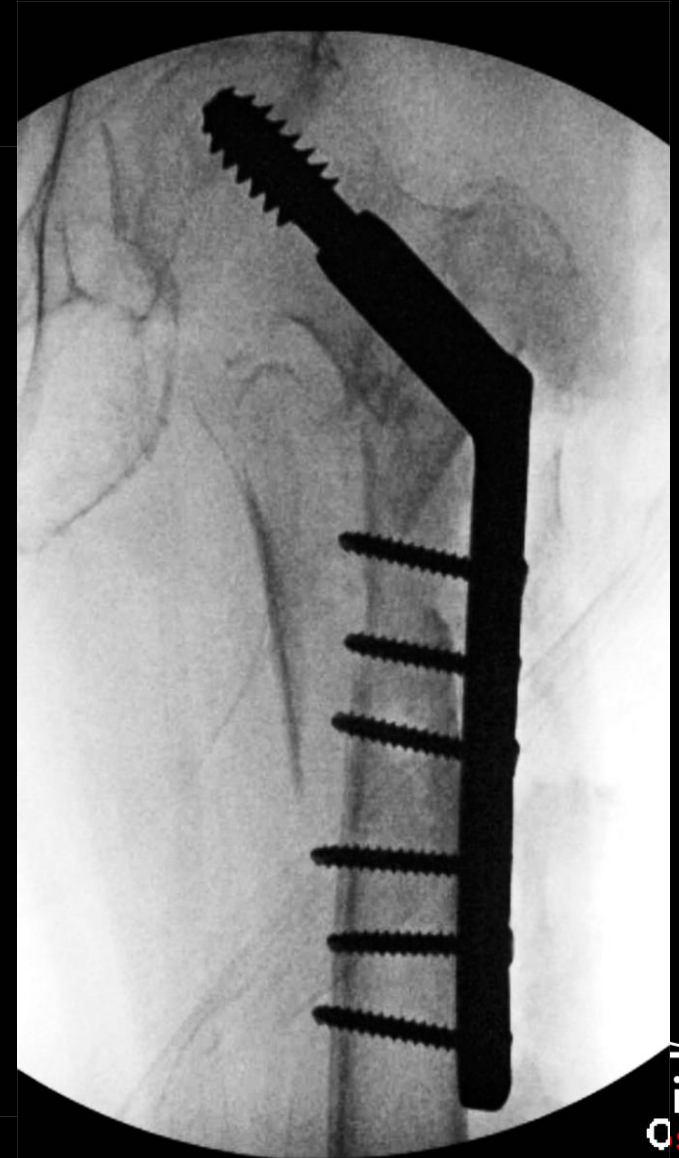
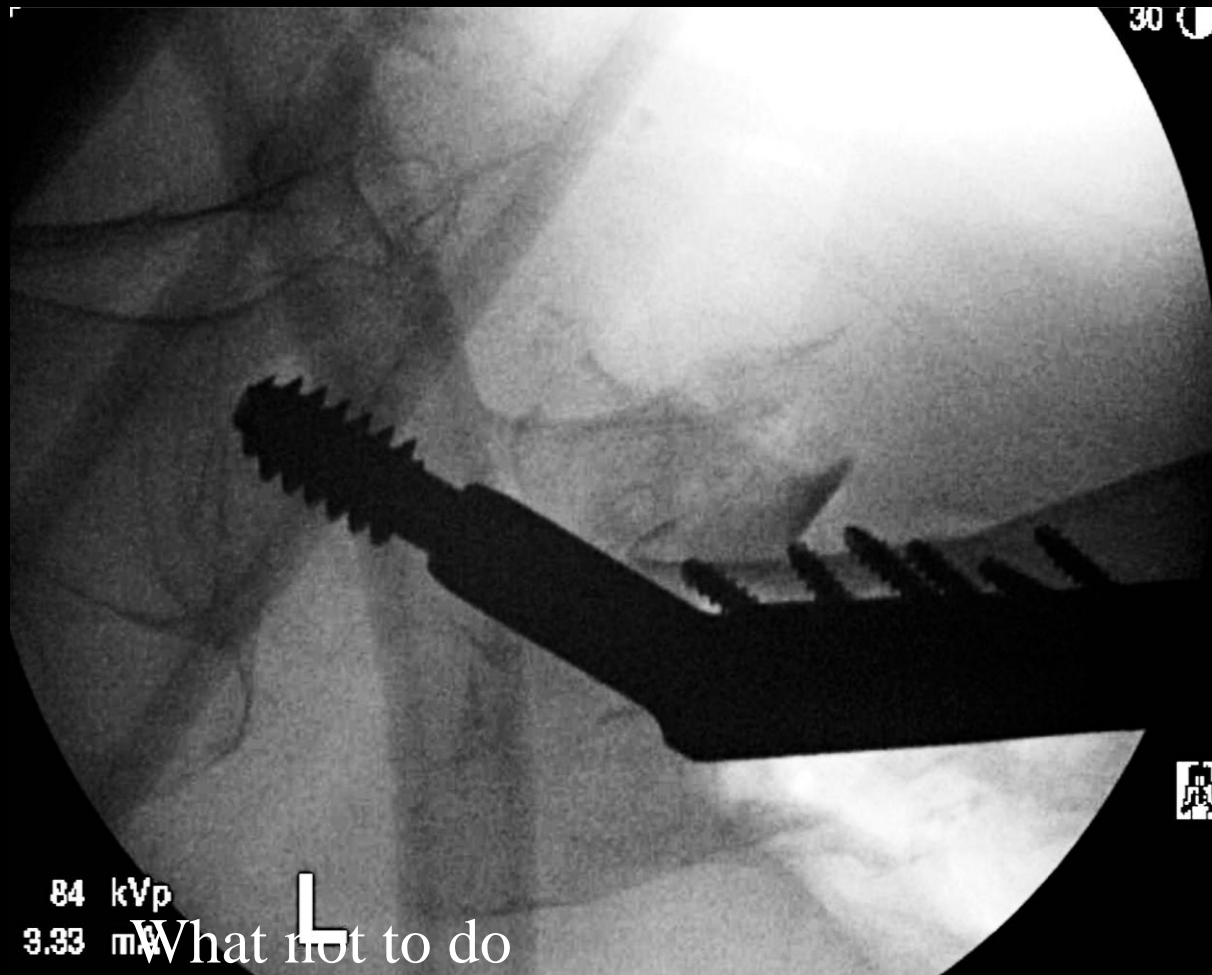
# 89 year old female post fall from standing – CHF, MI 6 months ago

- Reduction
- Implant Choice
- Implant Placement
- Postop Care



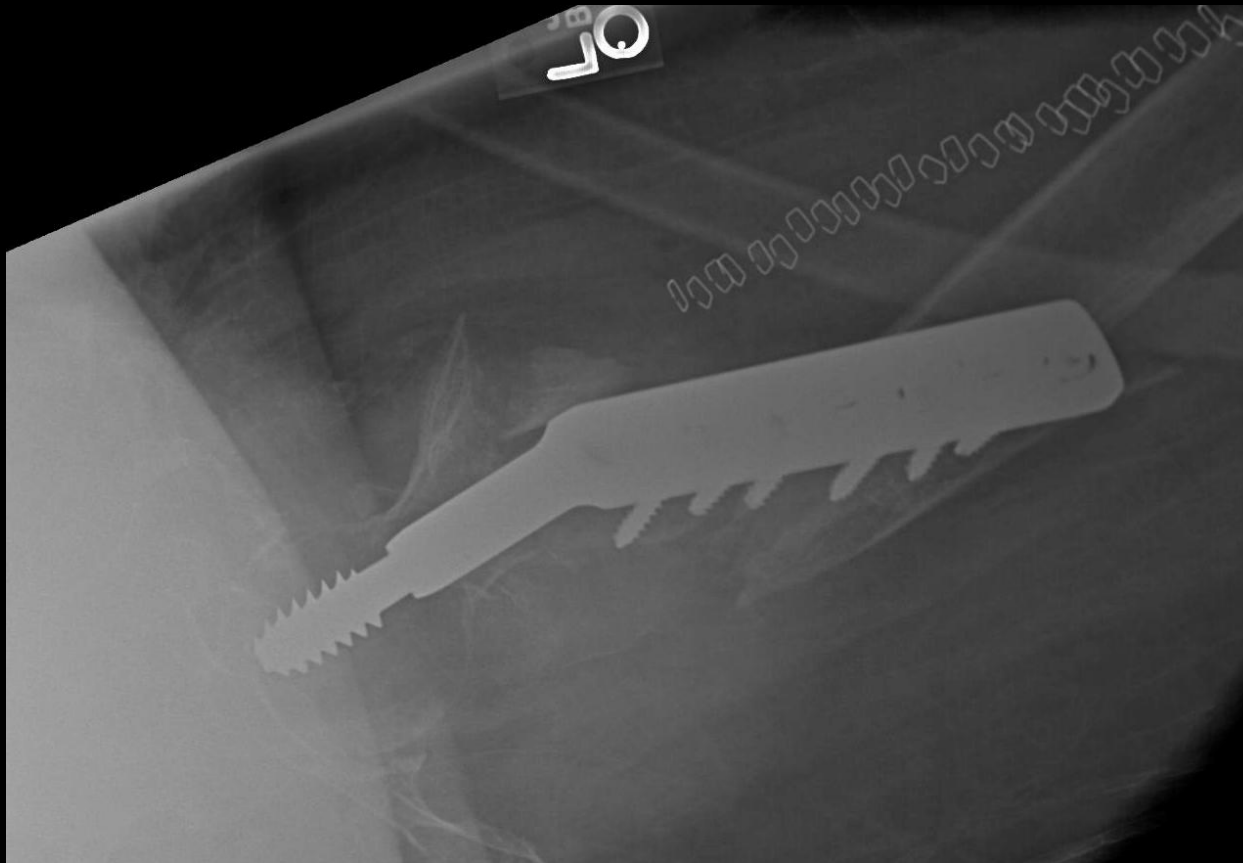
What not to do

# 89 year old female post fall from standing

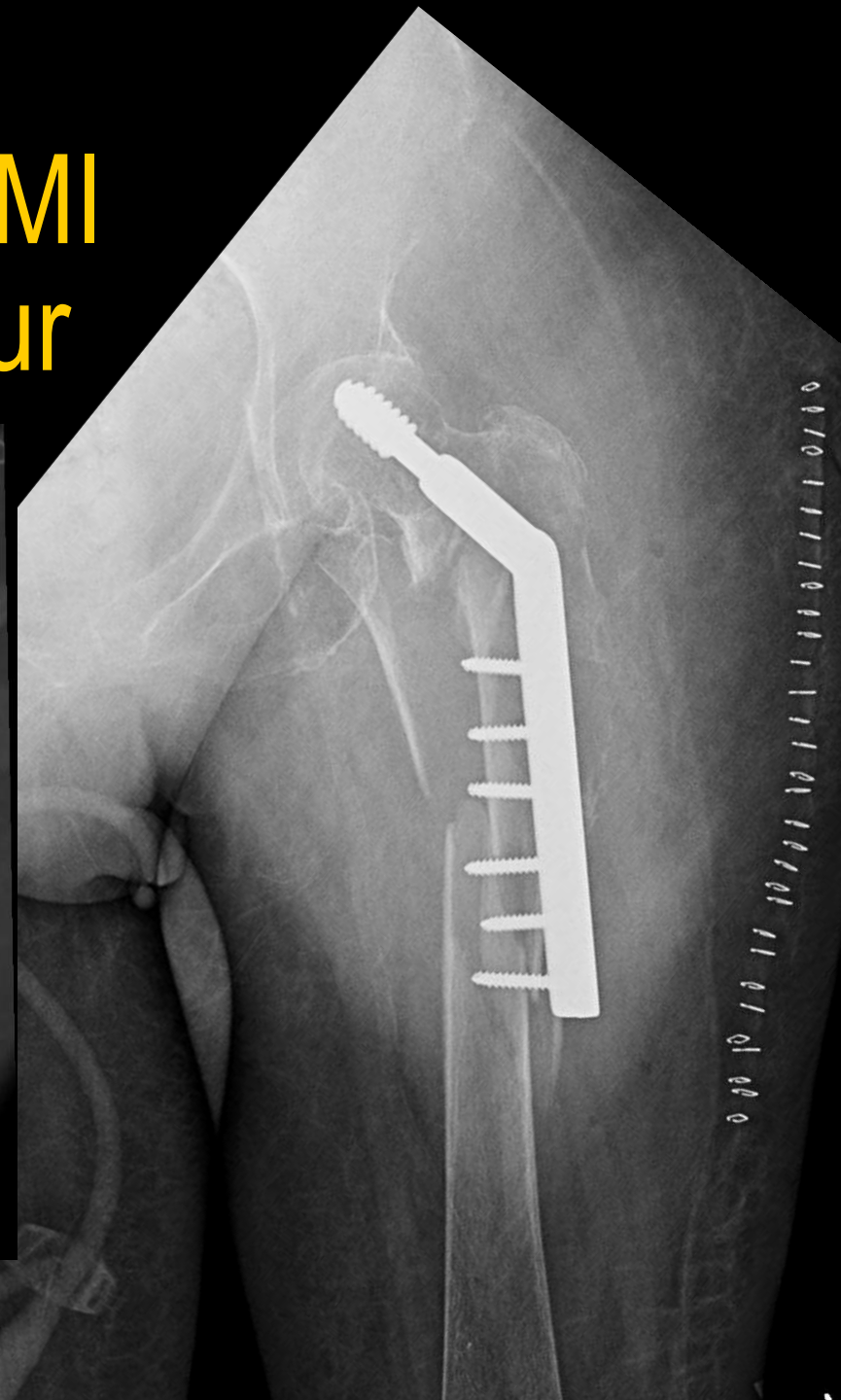




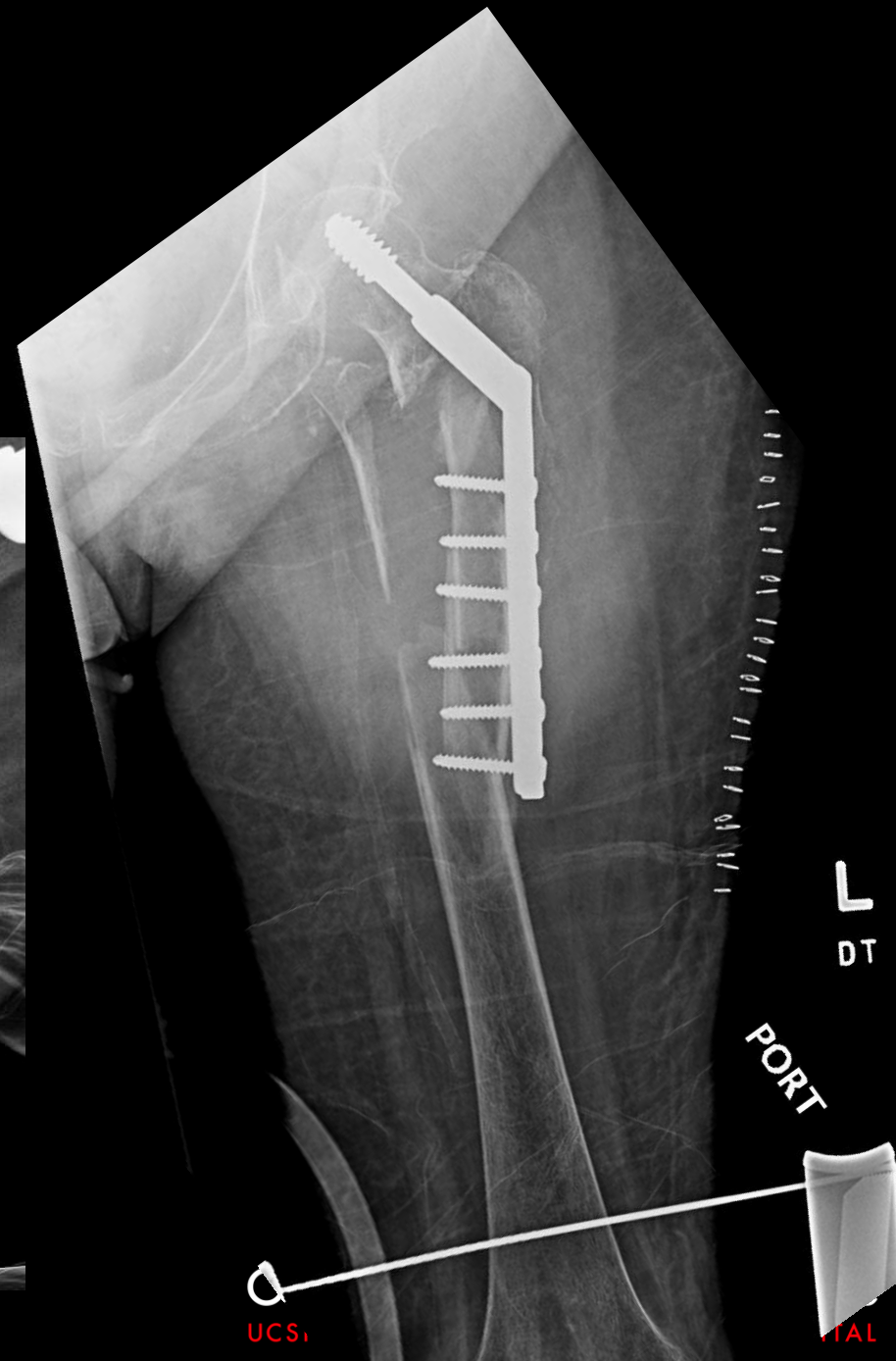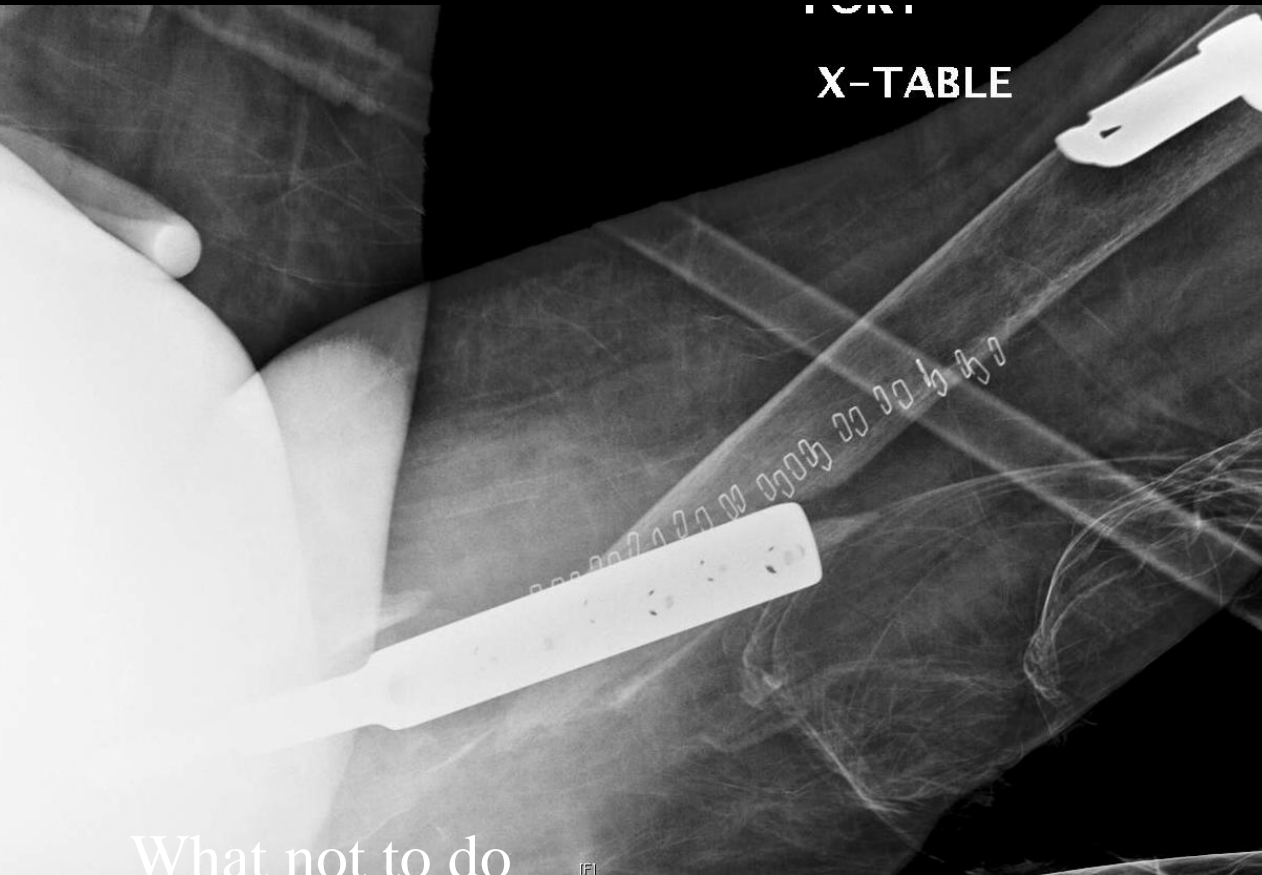# Post op Day 4 Patient Sustains another MI Images taken of the femur



What not to do



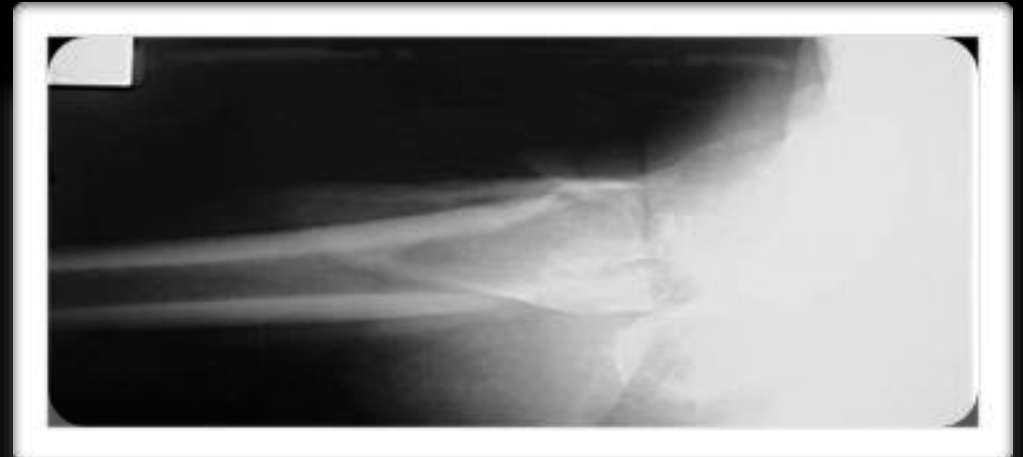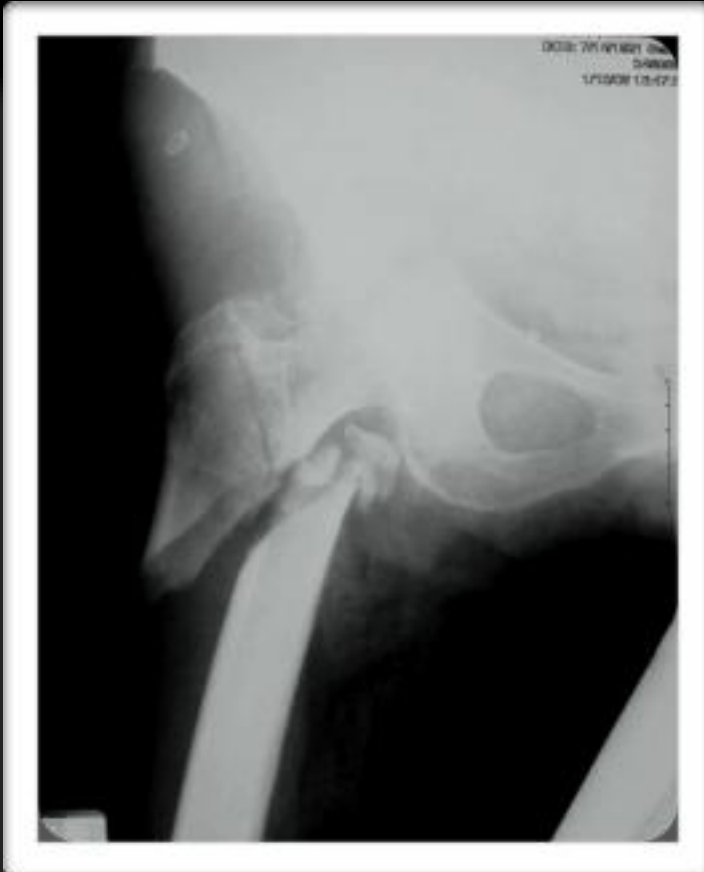# Post op Day 12 – patient deceased



What not to do

# 85-year-old female post PVA

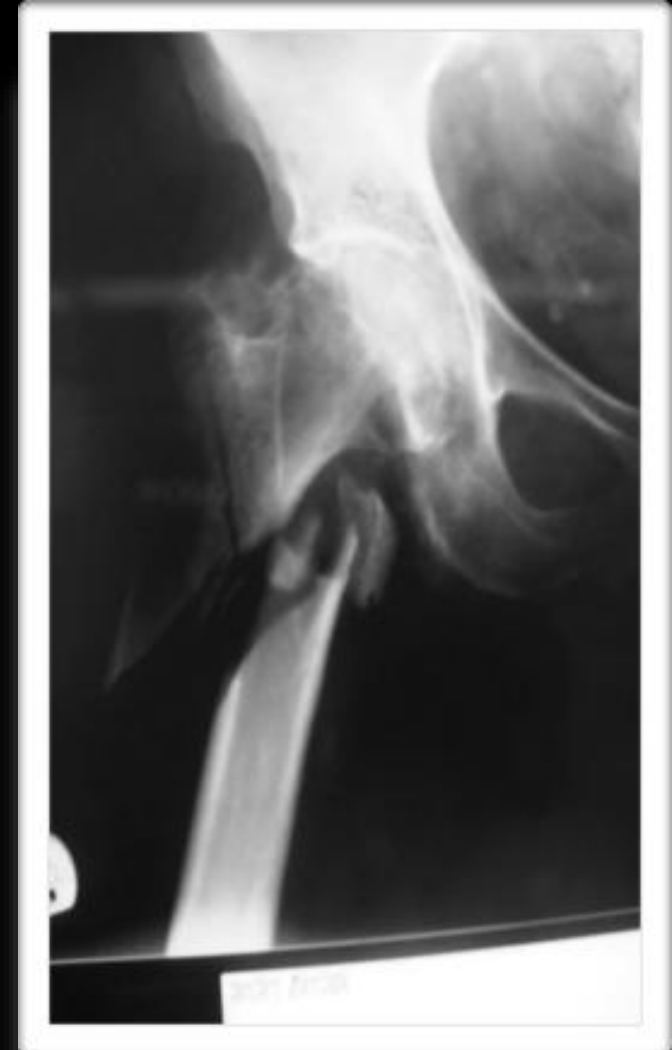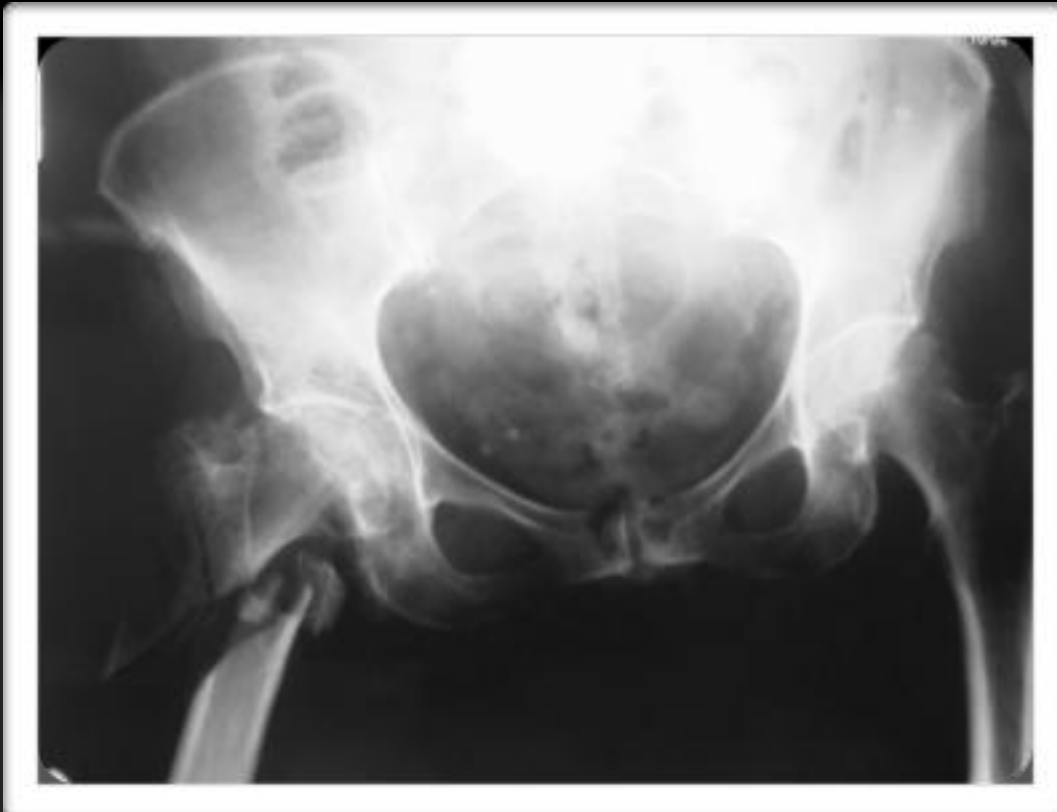Problematic subtrochanteric fracture  
Jan 2006



What not to do

# 85-year-old female post PVA

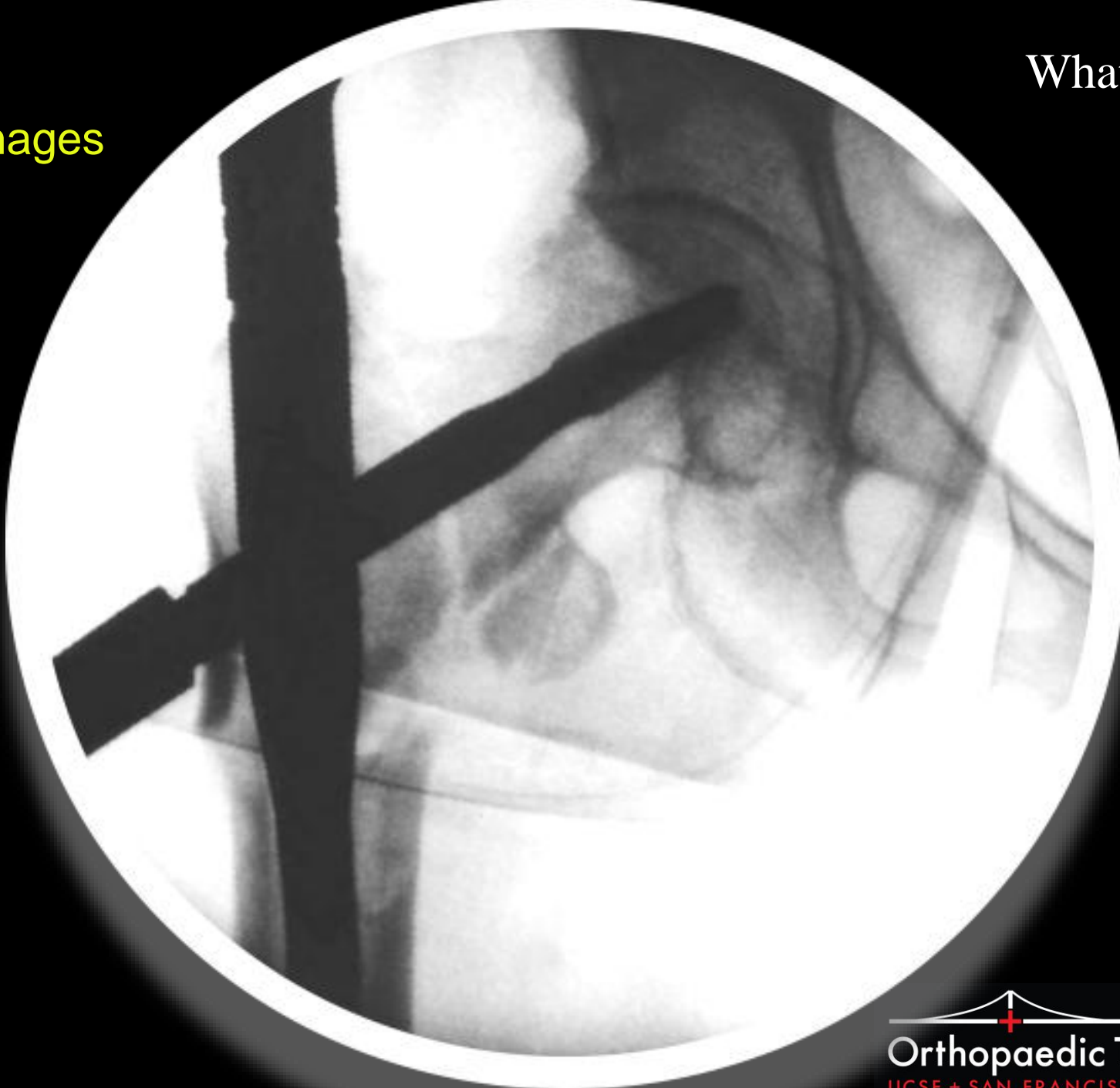
Problematic subtrochanteric fracture  
Jan 2006





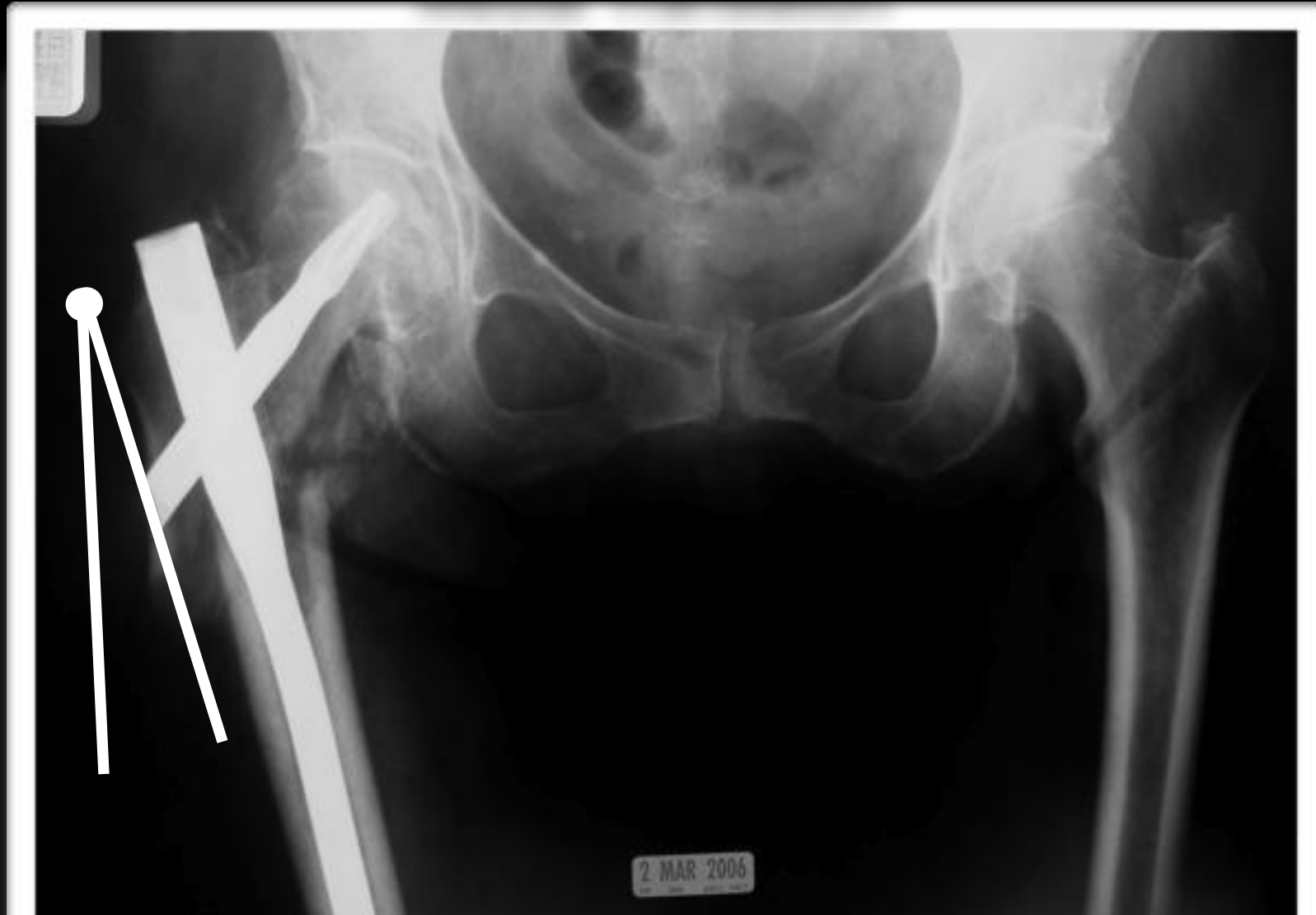What not to do

Intraop Images

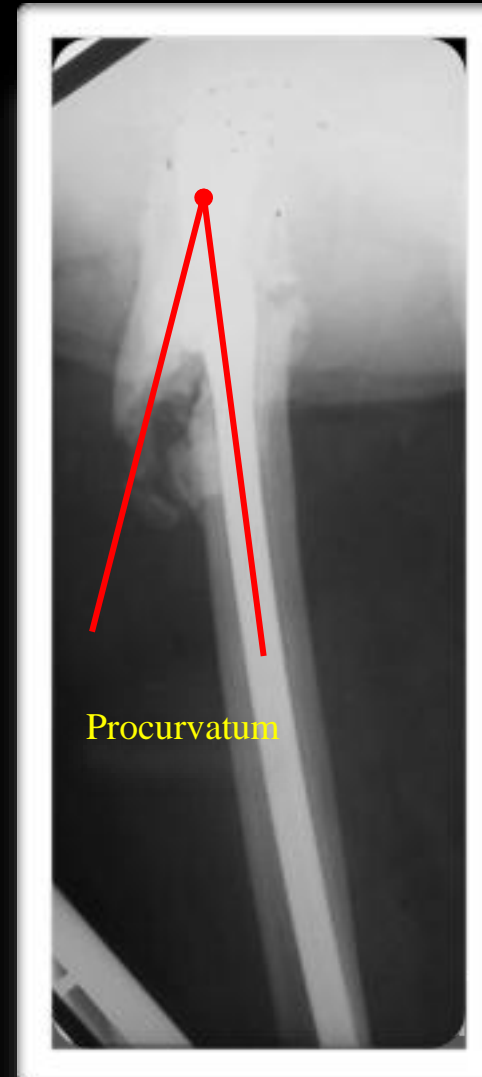
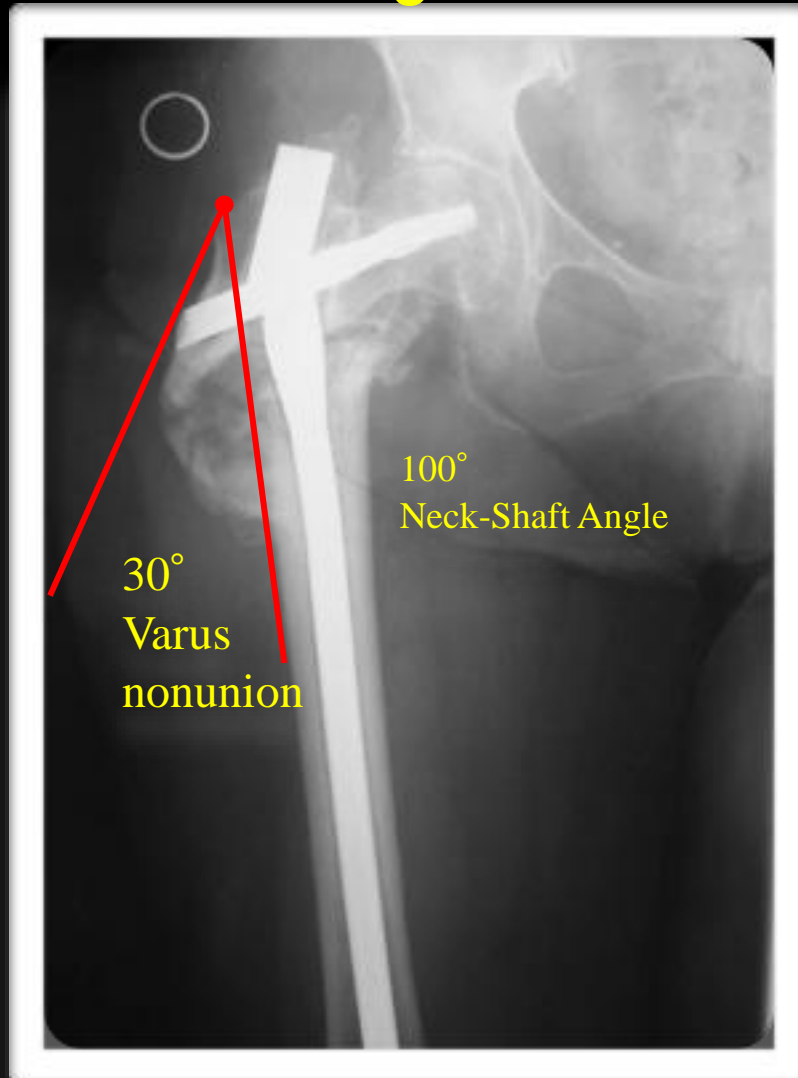


March 2006  
14° VARUS  
Medial Translation

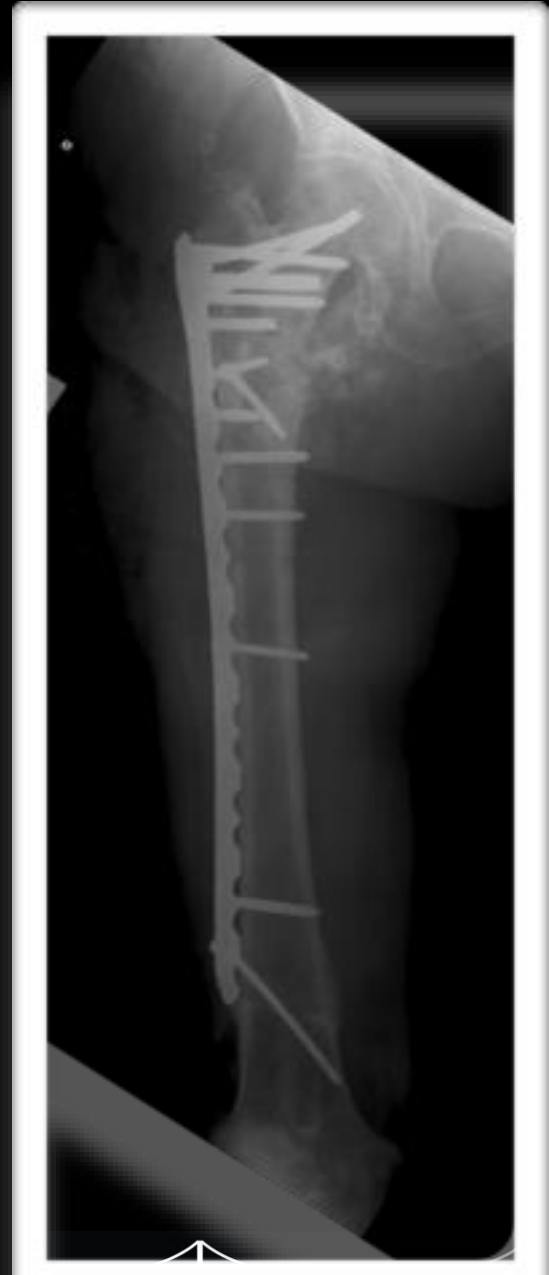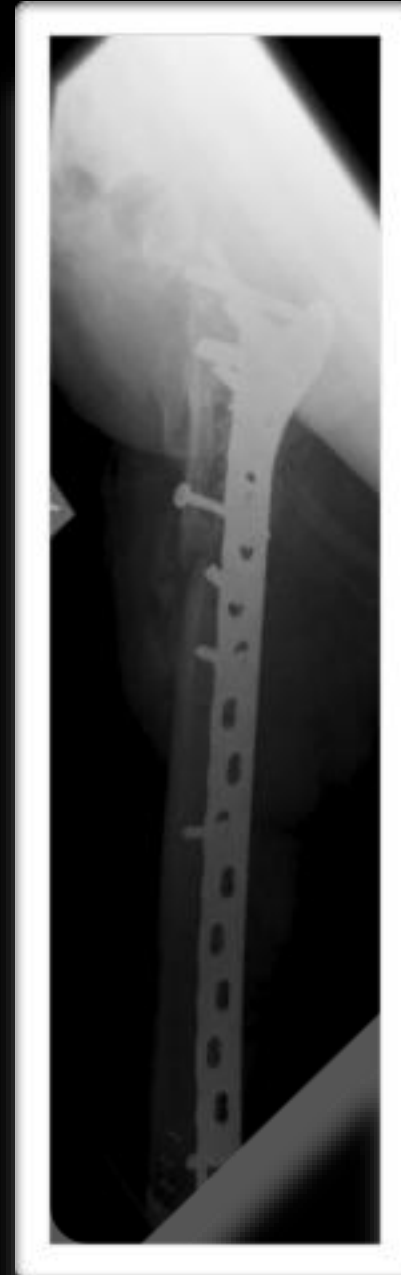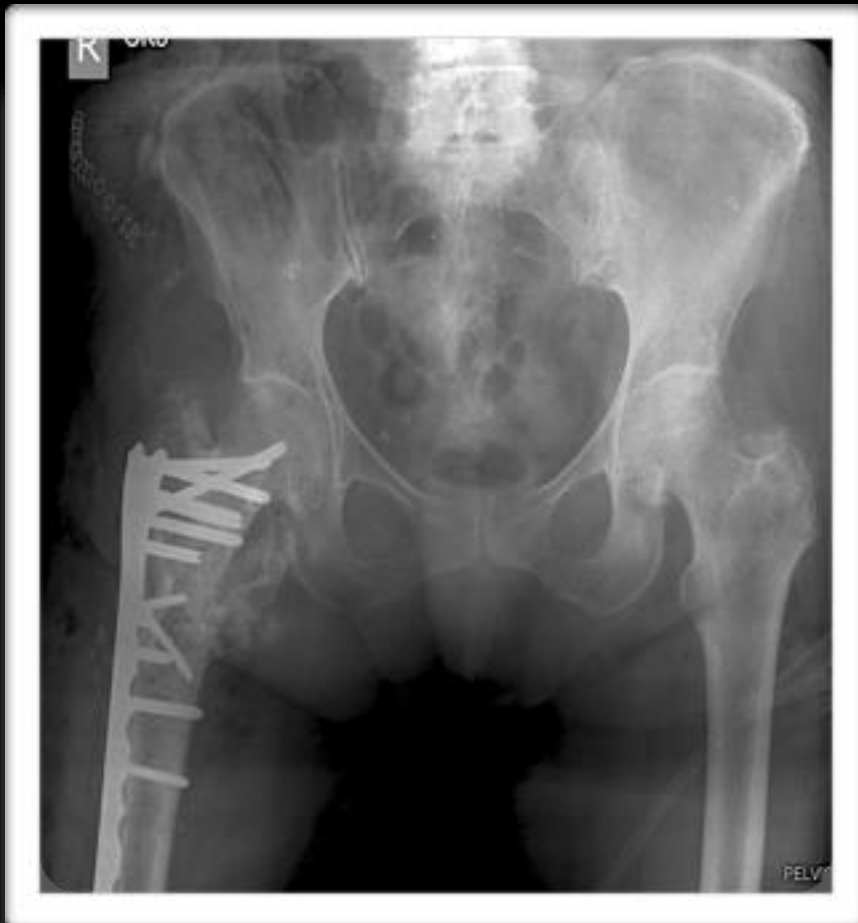What not to do



2008 – referred to my office  
Walks in with walker  
Short leg, nonunion, hardware failure



# Lateral Decubitus Position



# Subtroch Fractures

## Predisposition to varus and procurvatum

### □ Muscle Pull

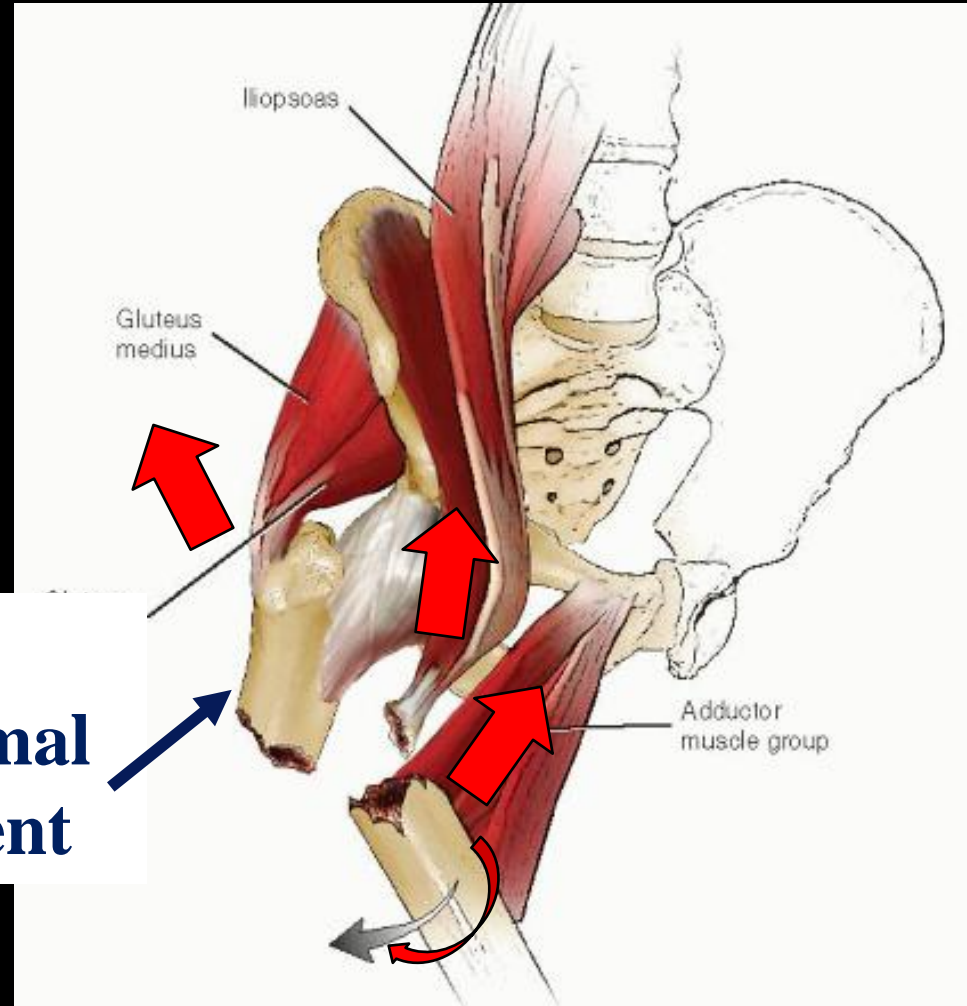
#### – Proximal

- Abduction
- Flexion
- External rotation

#### – Distal

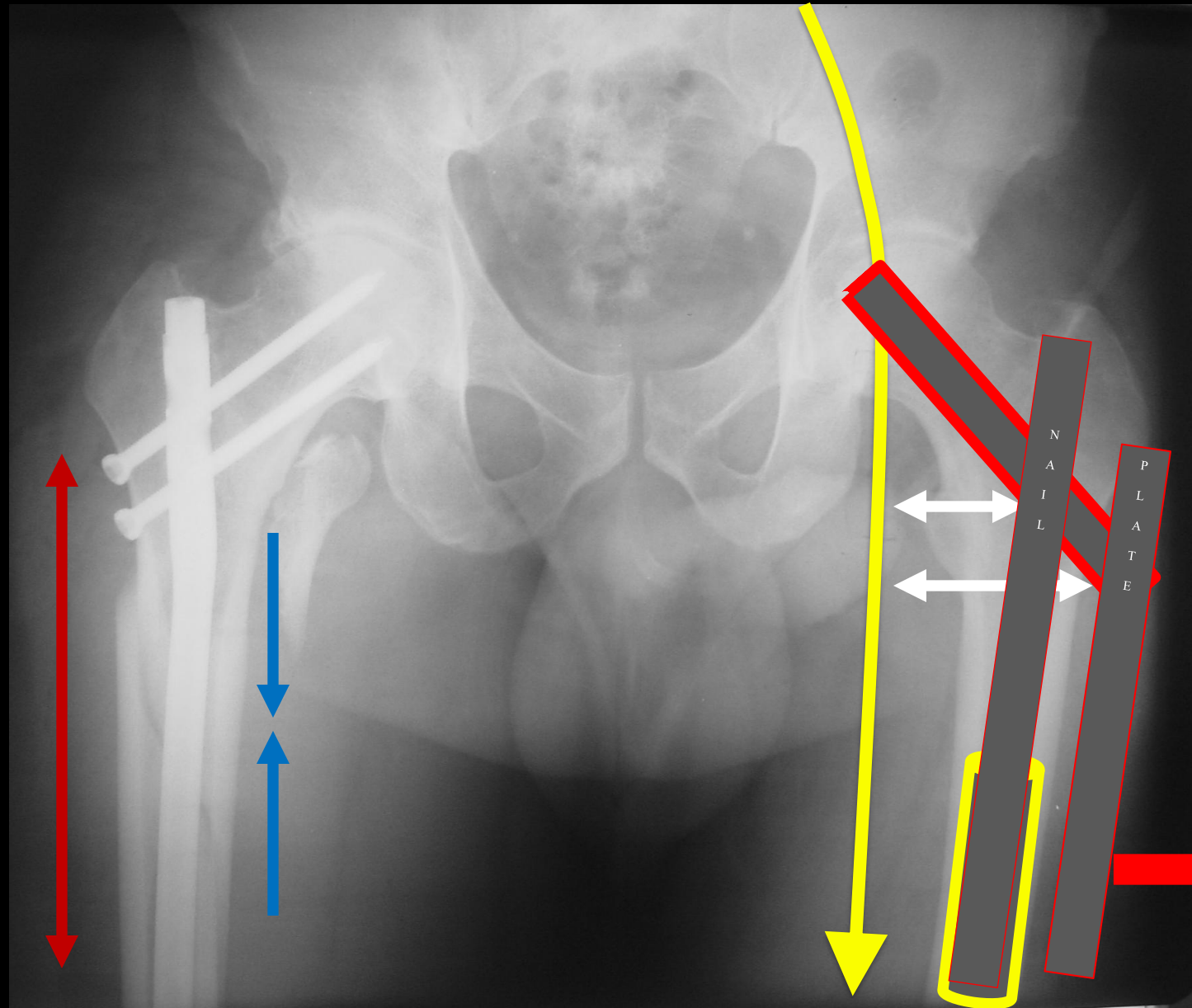
- Shortened
- Medialized
- External rotation

**Short  
Proximal  
Segment**



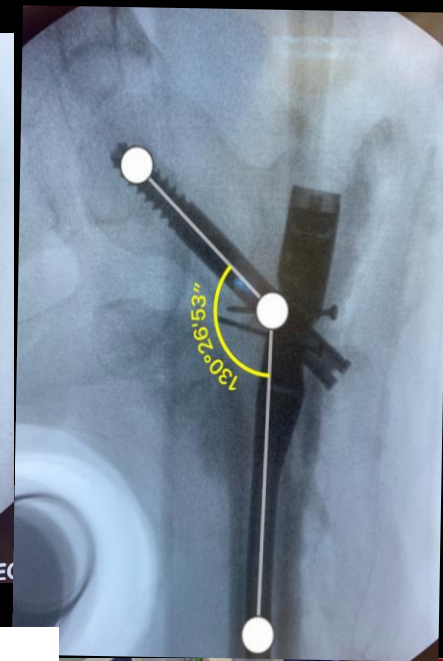
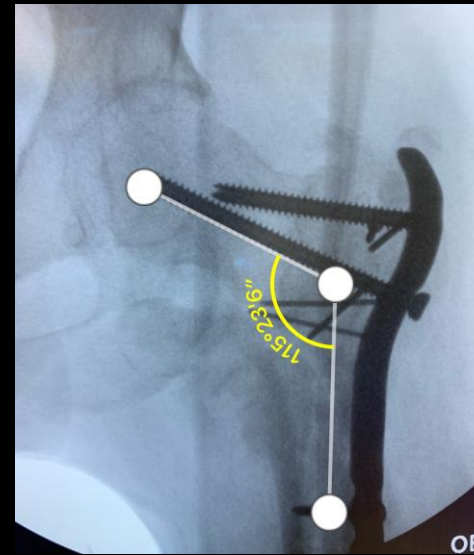


# Forces after fixation

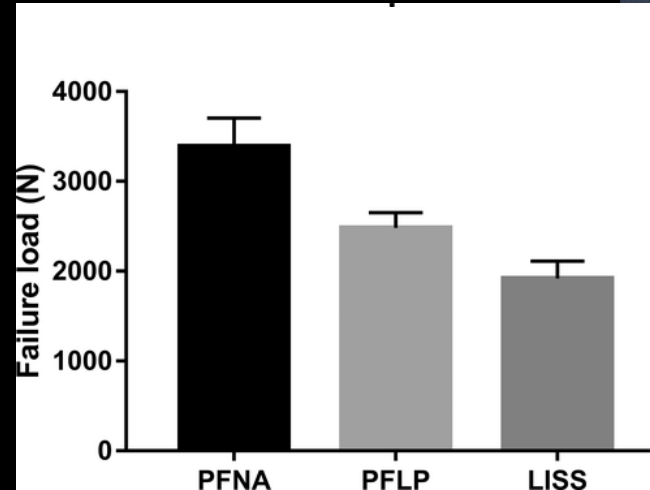


# Treatment options

- Cephalomedullary nail
  - Axially Stiff
  - Increased Load to failure
  - Increased Cycles to failure



- Fixed angle plate
  - More lateral position
    - Greater bending forces
    - Decreased load to failure
    - Decreased number of cycles to failure



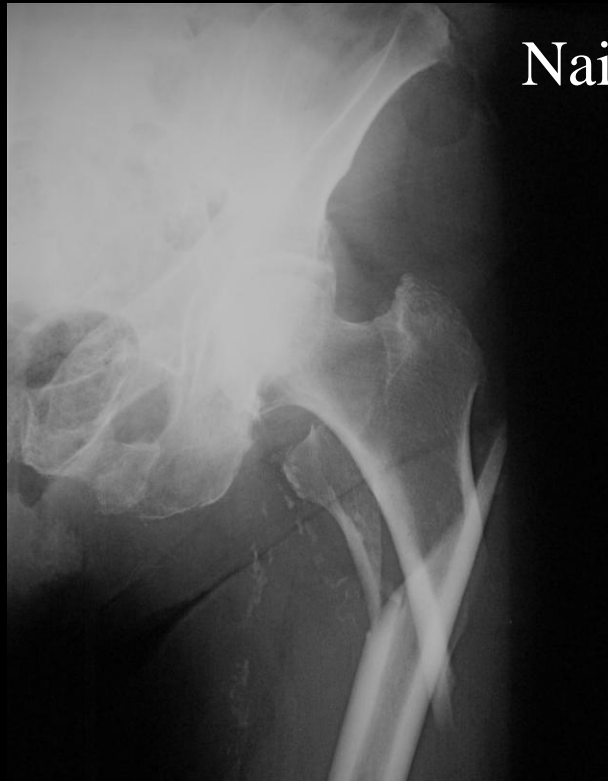Kuzyk, P et al. Intramedullary Versus Extramedullary Fixation for Subtrochanteric Femur Fractures. J Orthop Trauma. 2009;23(6):465-470

Biomechanical Study of Intramedullary Versus Extramedullary Implants for Four Types of Subtrochanteric Femoral Fracture

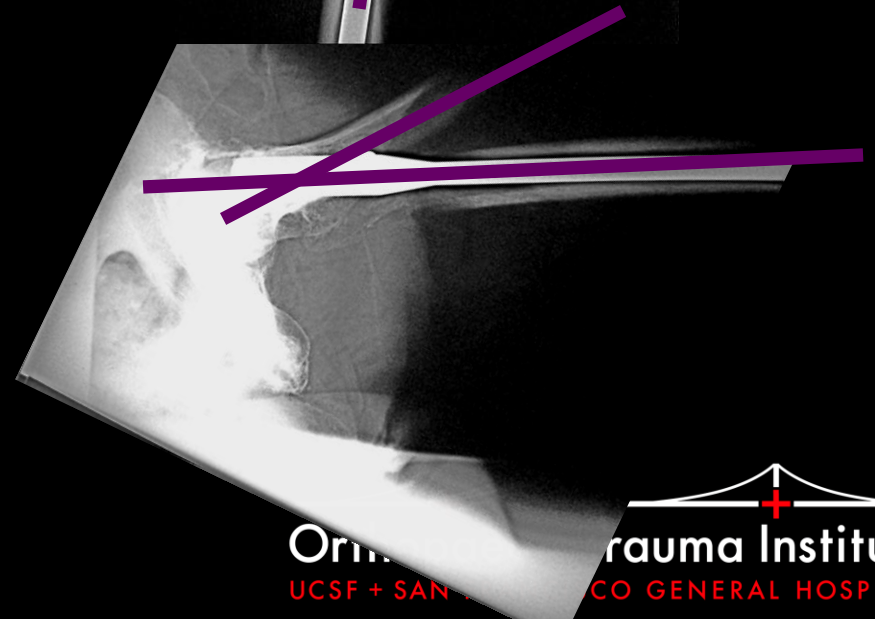
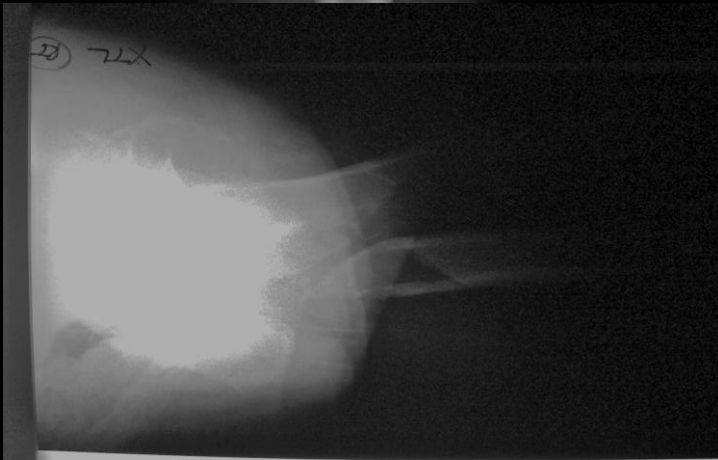
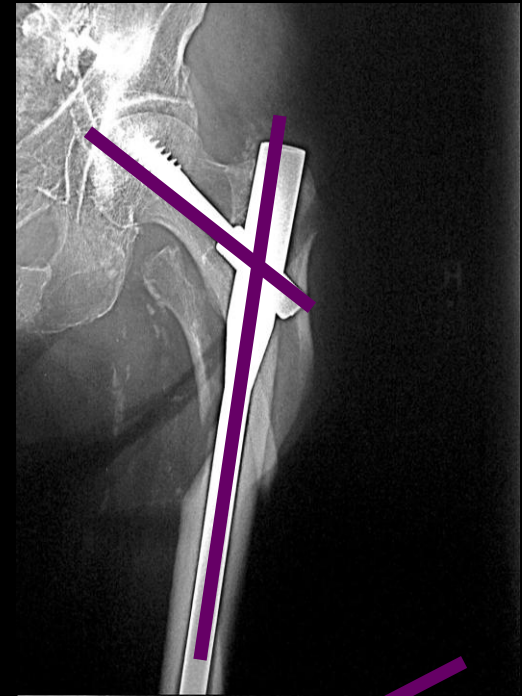Jie Wang MD, Haobo Jia MD, Xinlong Ma MD, Jianxiang Ma MD, Bin Lu MD, Haohao Bai MD, Ying Wang MD

Orthopaedic Surgery

# Malreductions occur in varus and procurvatum

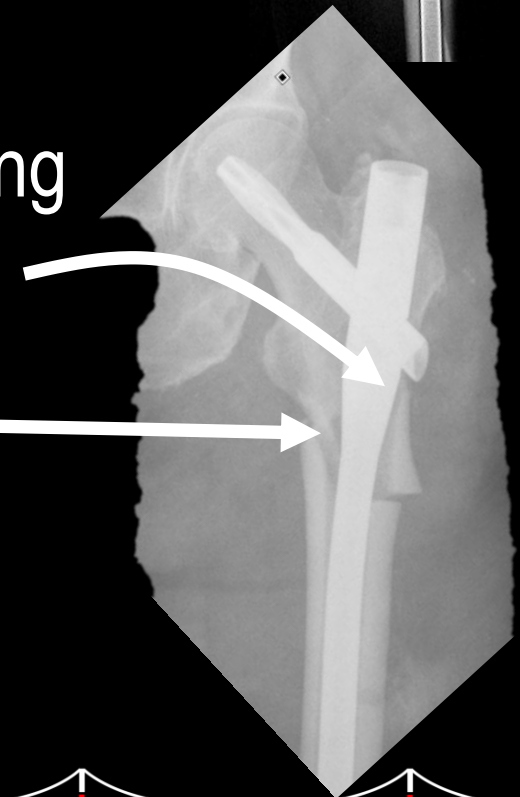
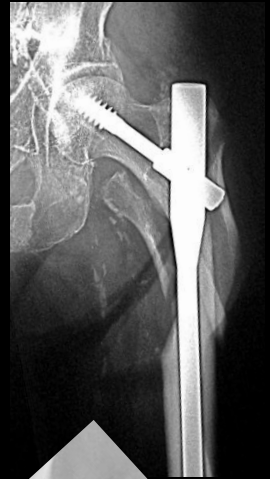

Nail without reduction



# Why Do You get Varus?

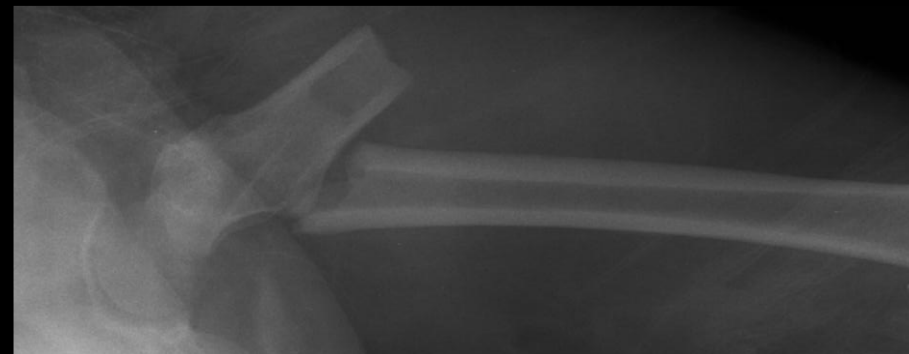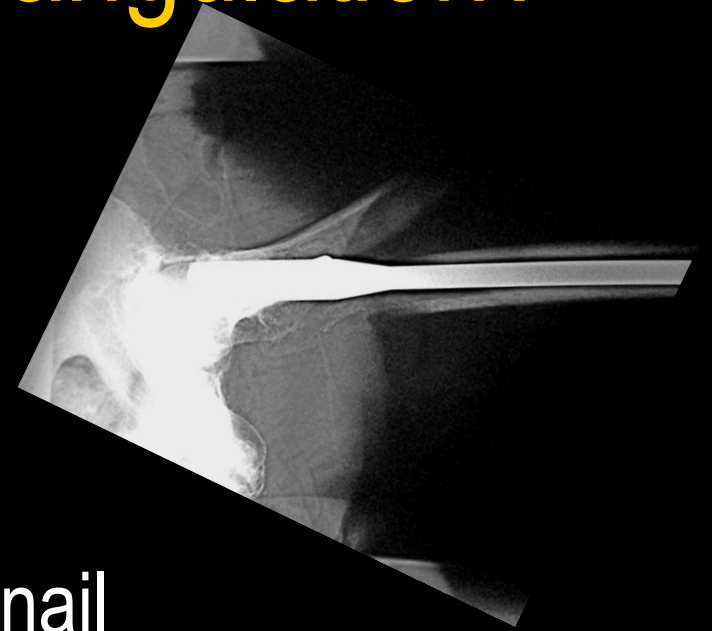
- Reduction
  - Fracture not reduced before reaming
  - Not holding reduction during reaming
  - Not holding reduction while inserting nail
  - Not holding reduction while proximal locking
- Lateral Proximal cortical nail abutment
- Medial Distal cortical nail abutment
- Ovalization of entry hole
- Not knowing proximal bend of nail
- Not enough or too much traction





# Why Do You get anterior angulation?

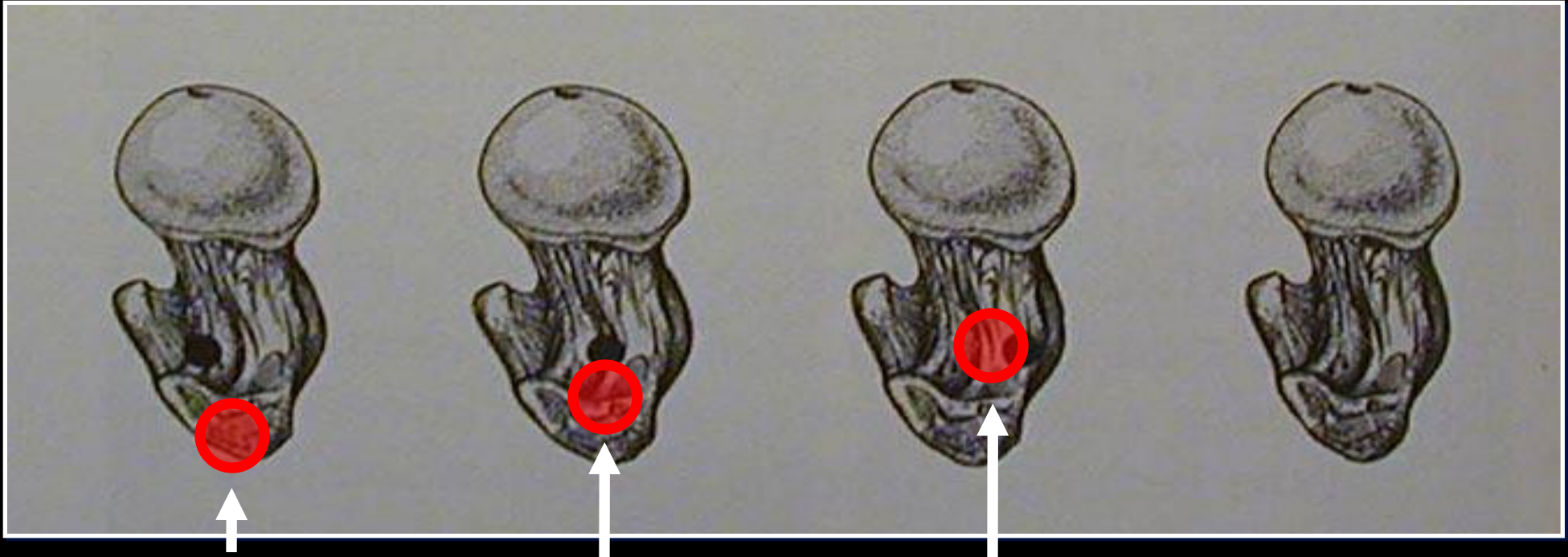
- Inadequate Imaging
- Reduction
  - Fracture not reduced before reaming
  - Not holding reduction during reaming
  - Not holding reduction while inserting nail
  - Not holding reduction while proximal locking
- Entry hole too anterior
- Too much traction





# Trochanteric Femoral Nailing

starting point



Too Lateral

Blow out or Varus

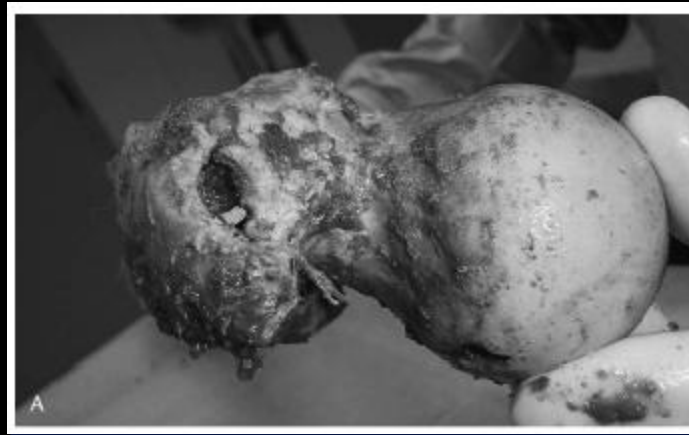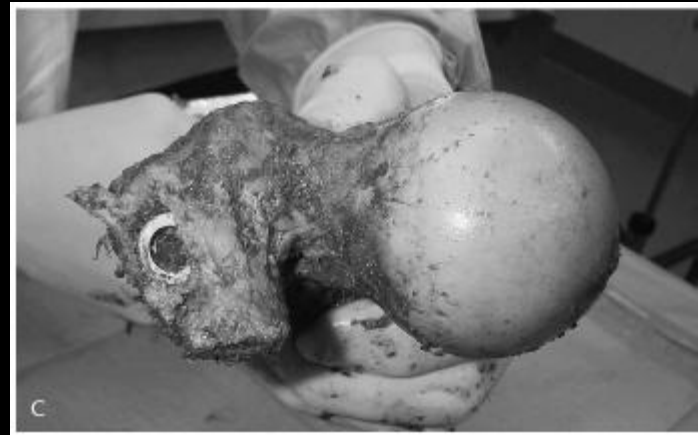Correct

Too Medial

Valgus, Increased  
leg length

Ostrum et al JOT 2005

# Trochanteric Start

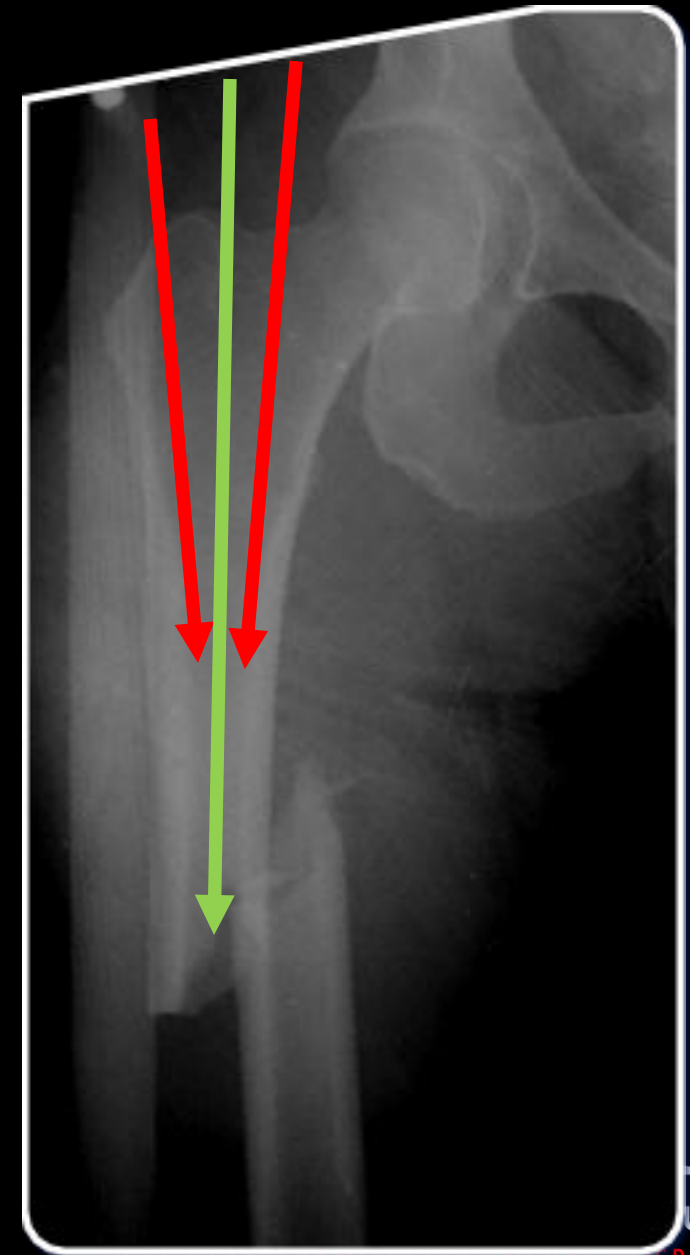


	Holland	TAN	TFN	Gamma 2	Gamma 3
<b>Proximal bend</b>	10	5	6	4	4
<b>Rad of Curv</b>	300mm	350mm	150mm	300mm	200mm

Ostrum et al JOT 2005

# Avoiding Varus

- Proper insertion point
  - Trochaformis start site



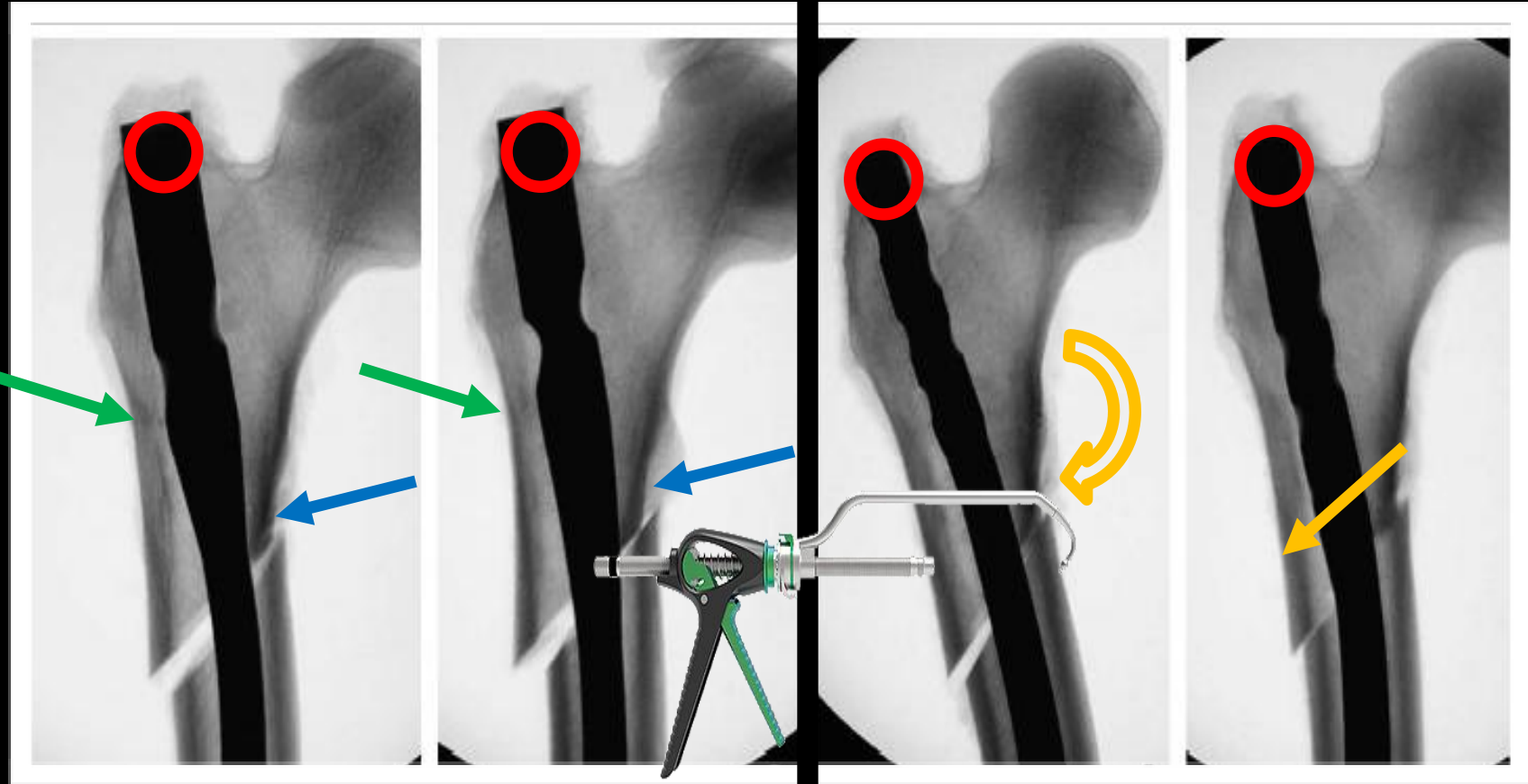
# Too Lateral Entry Site

Large Nail Head  
Proximal Fragment **Rotates into Varus** by  
**Implant Head**

Small Nail Head  
Proximal fragment **rotates into varus or translated** until the proximal fragment abuts medially

Lateral Proximal  
Cortical Abutment

Medial Distal  
Cortical Abutment

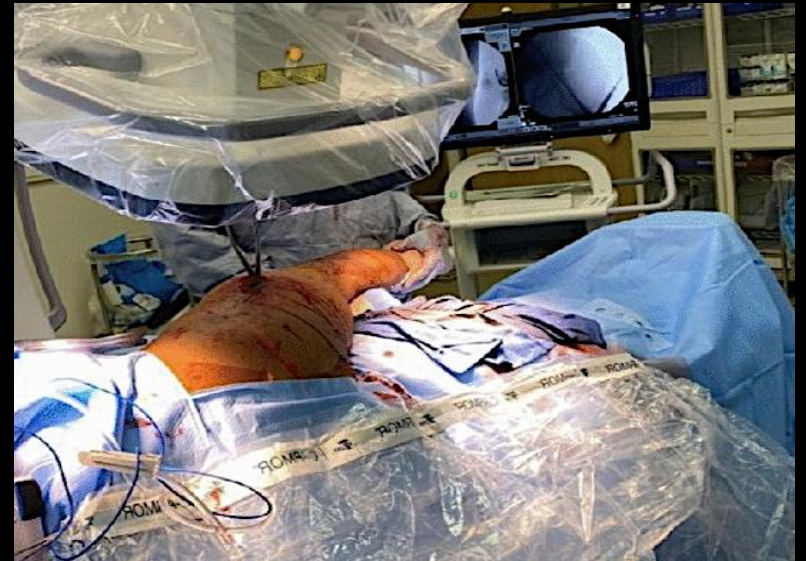
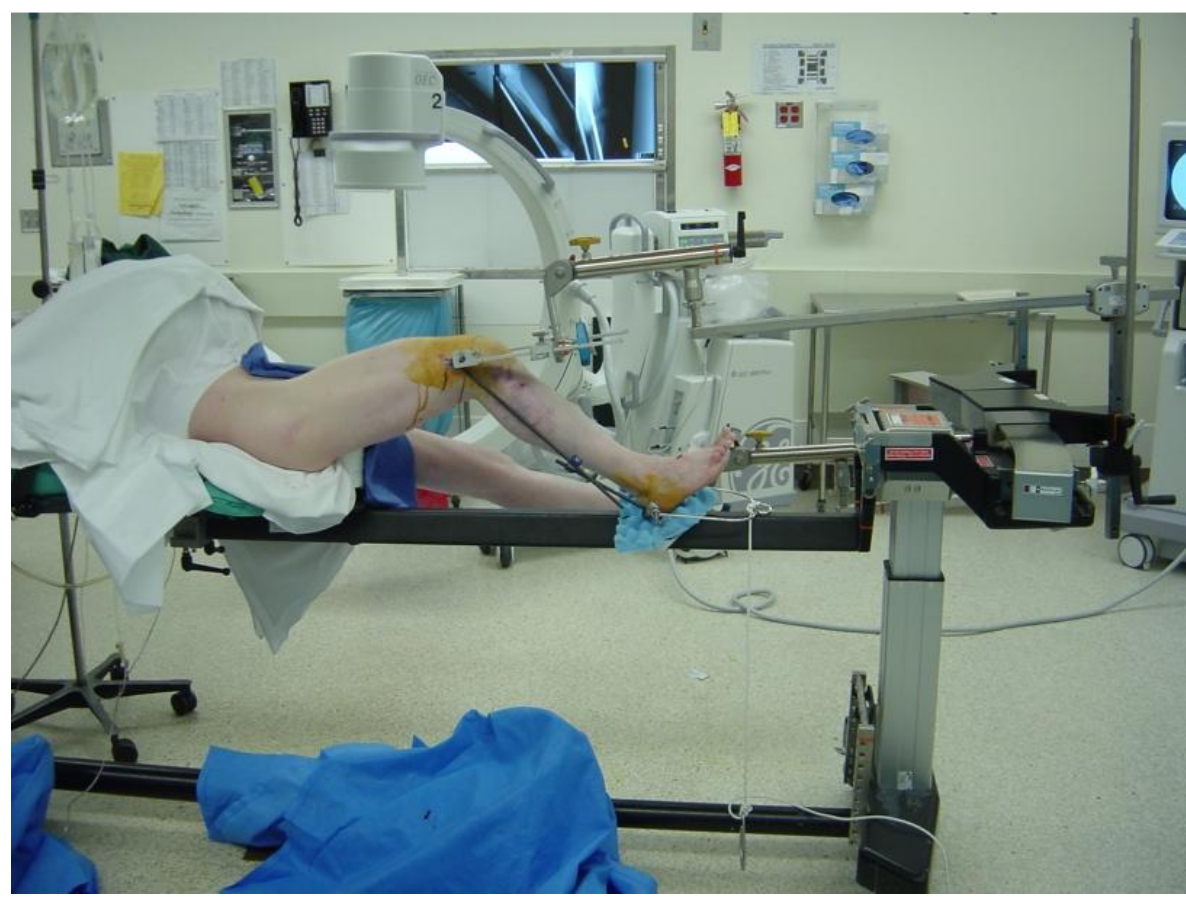
Ostrum et al JOT 2005



# OR Setup

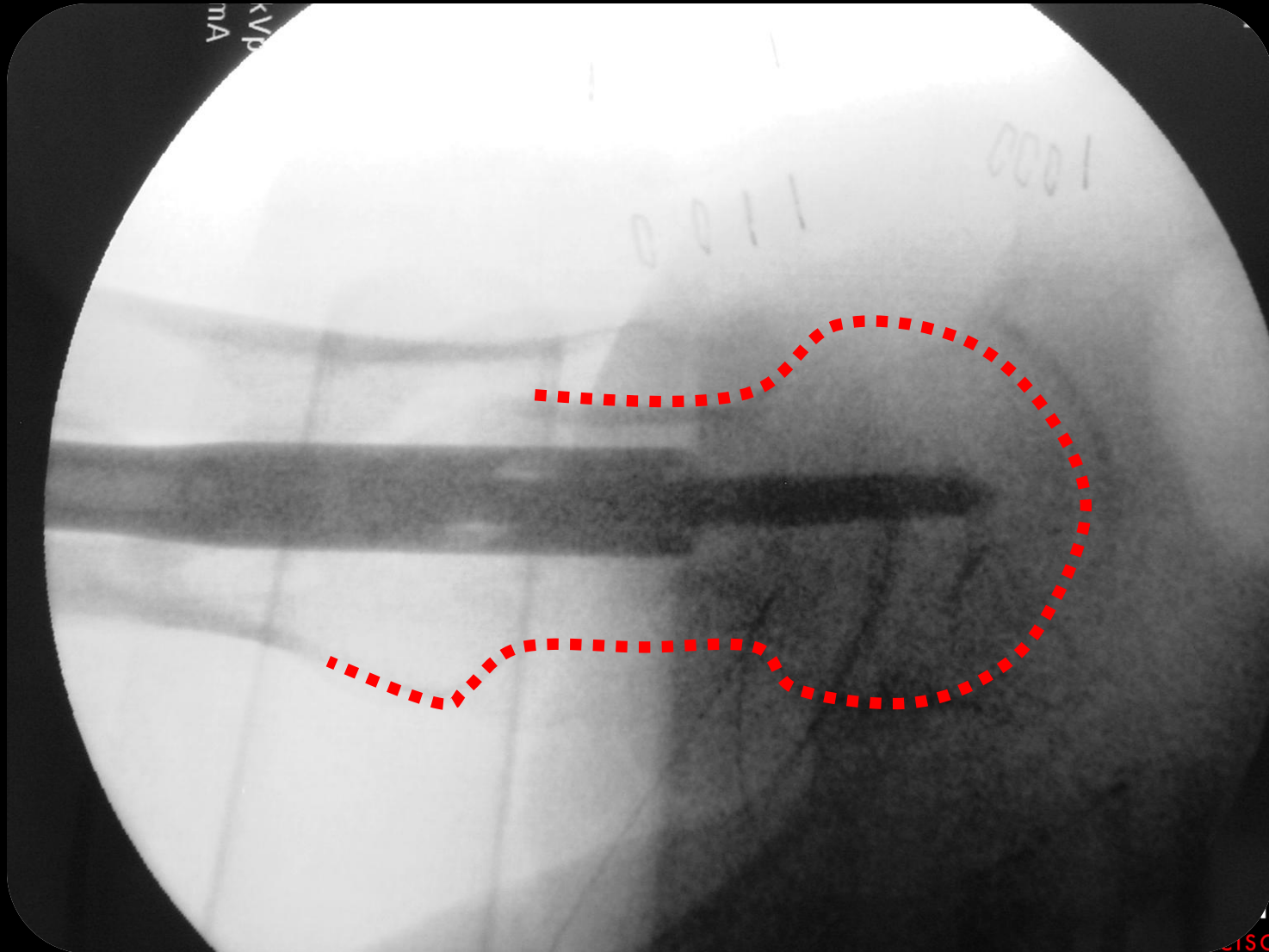
## Scissor Position or Lateral Decubitus



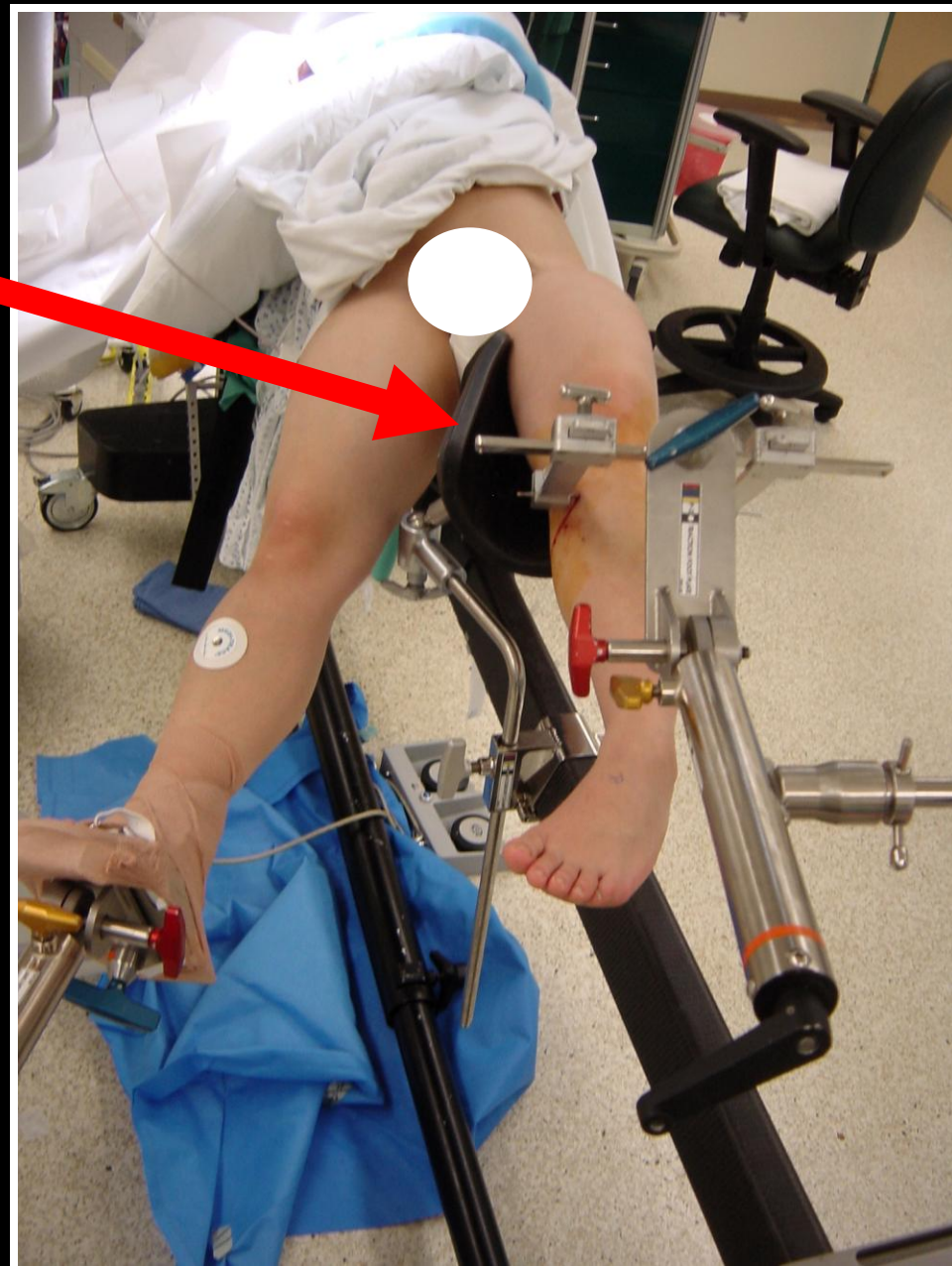
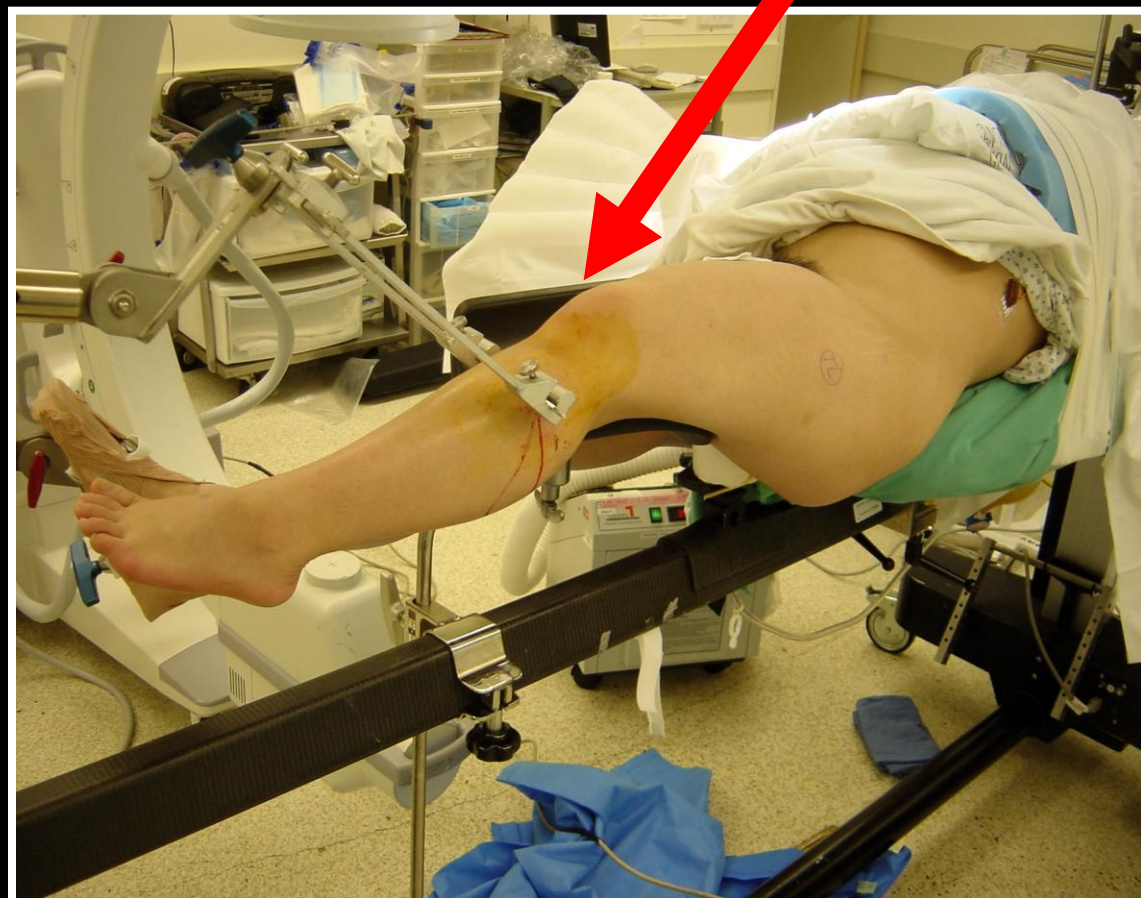


preop c-arm

Make sure you can get a perfect lateral of head and neck

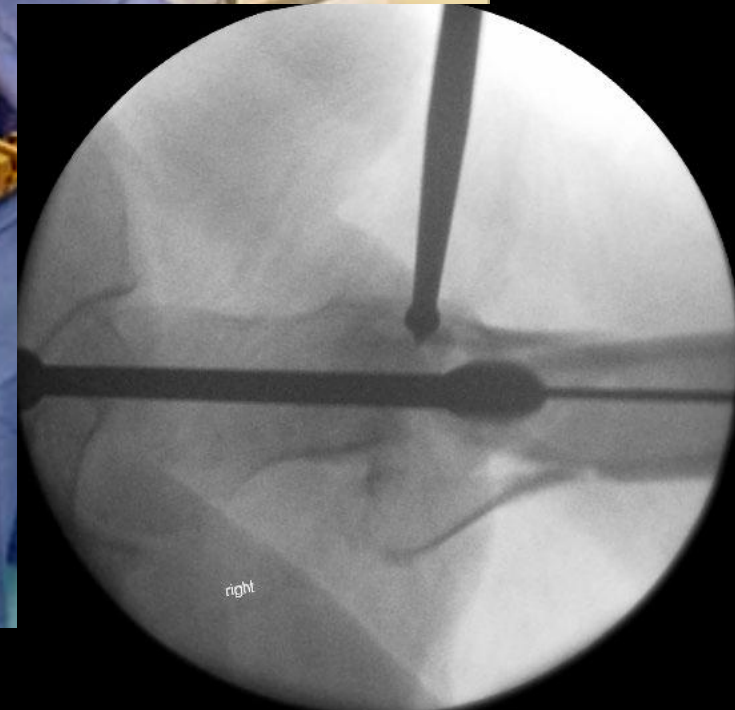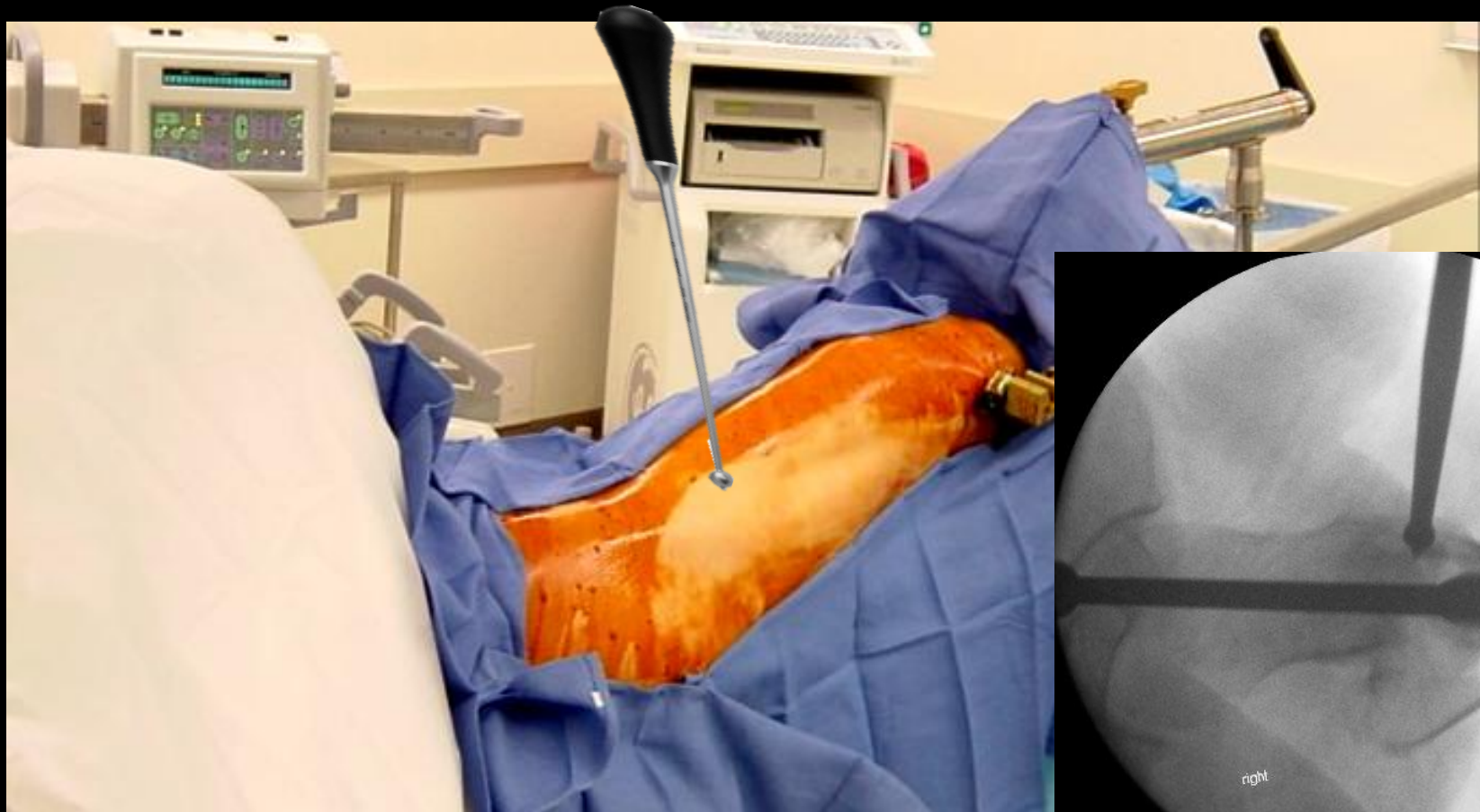


# OR Set up EM reduction

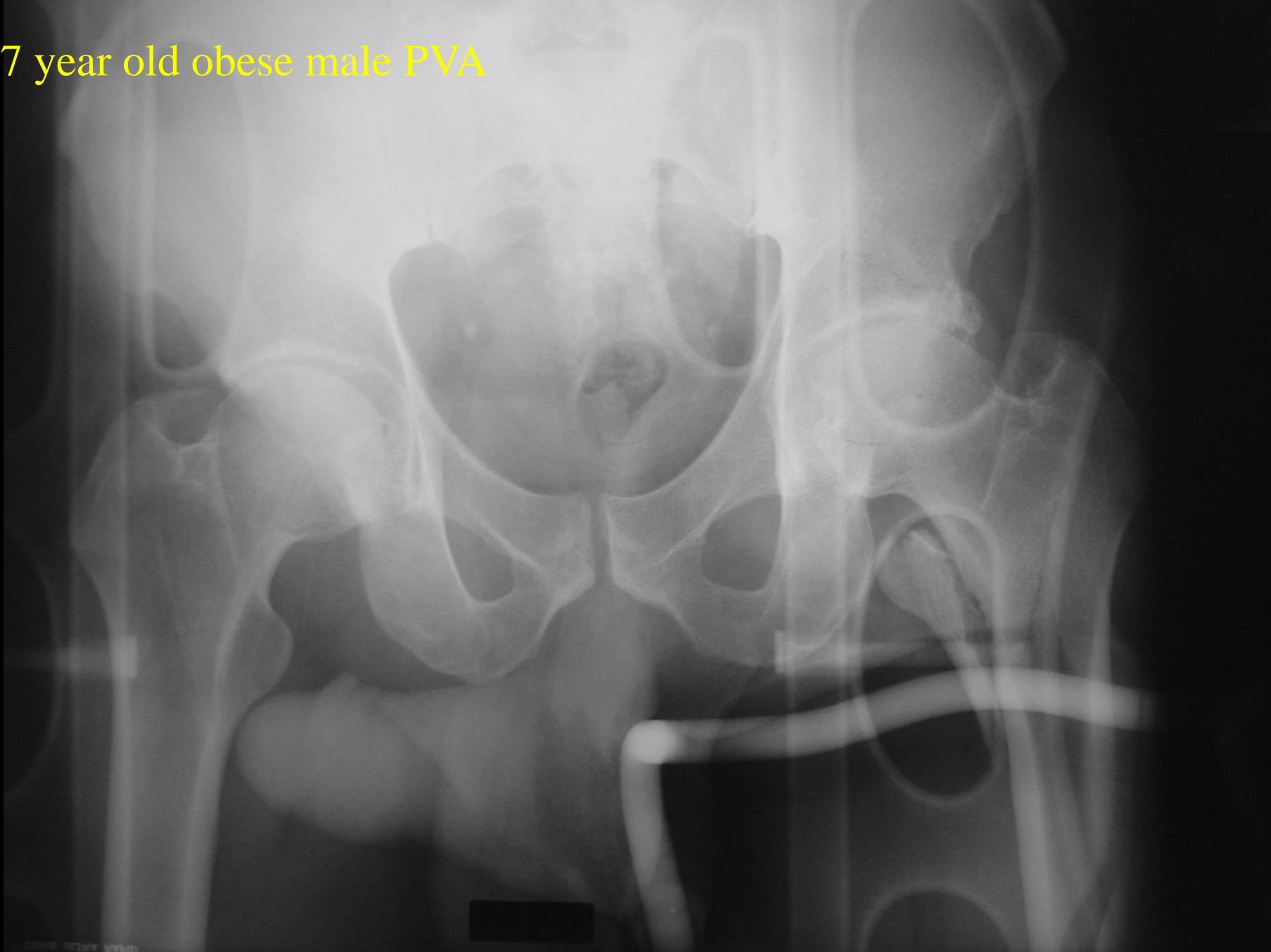




# Prep anteriorly in case you need to push down

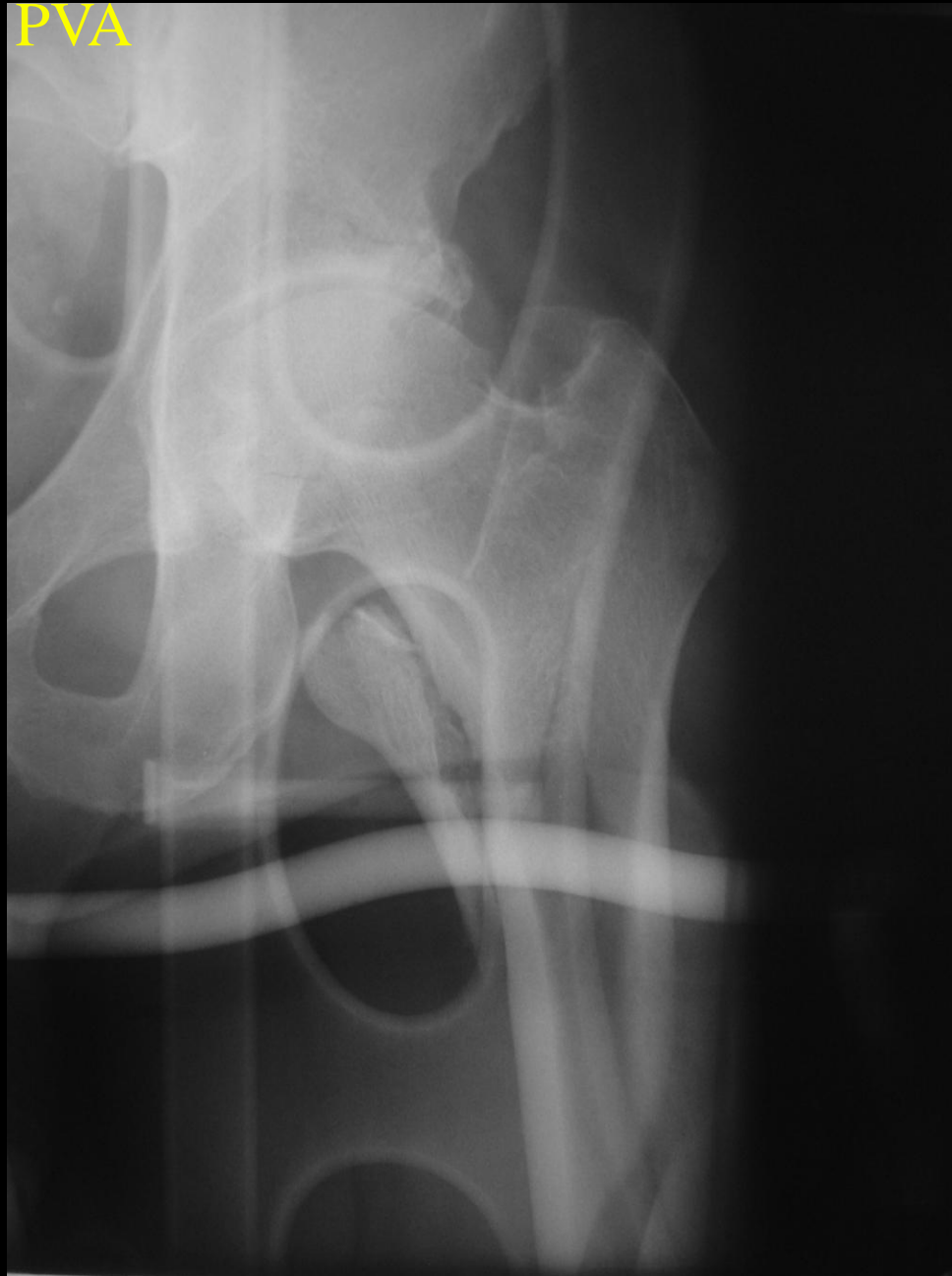


57 year old obese male PVA



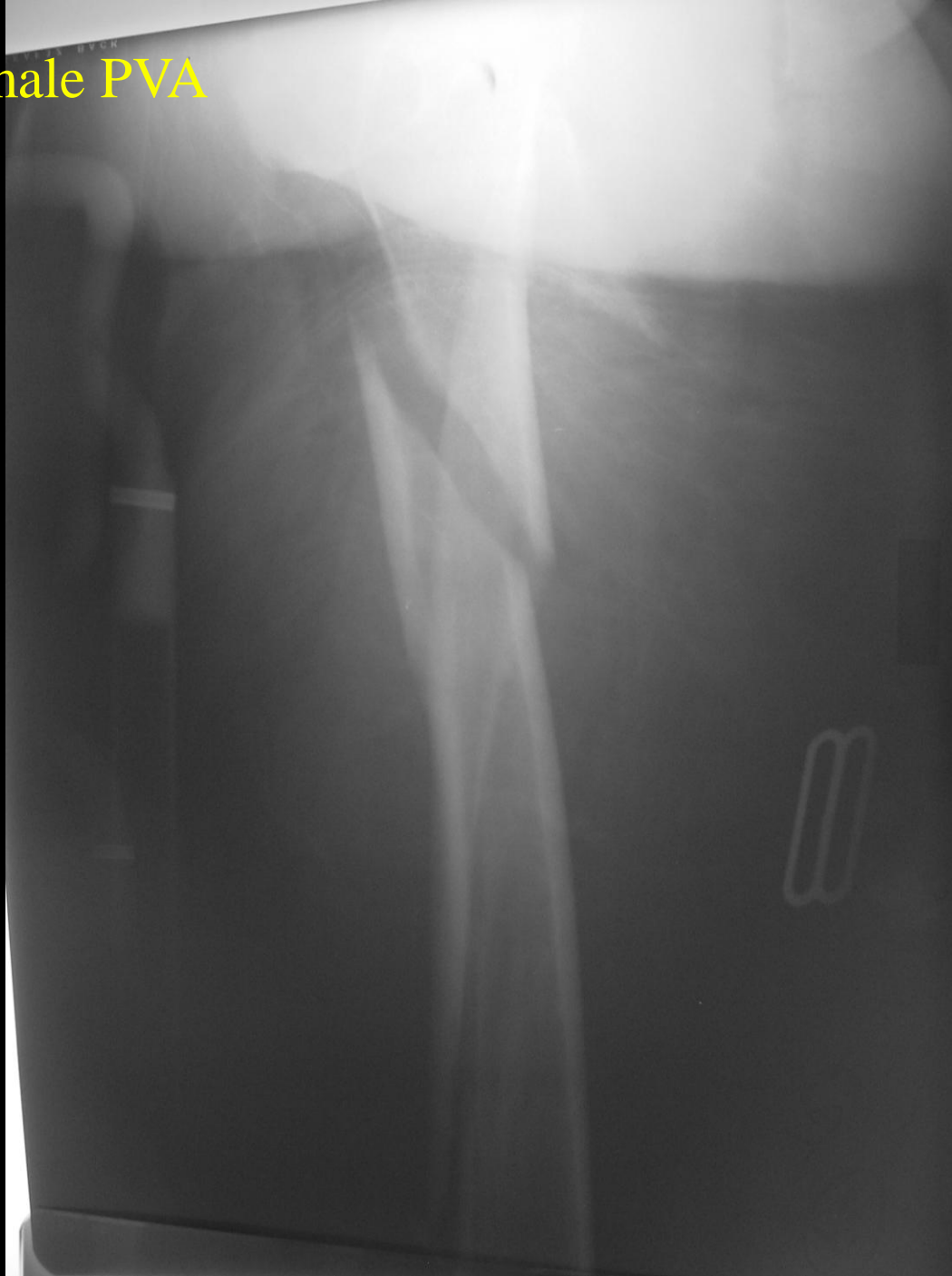**Orthopaedic Trauma Institute**  
UCSF + SAN FRANCISCO GENERAL HOSPITAL

57 year old obese male PVA

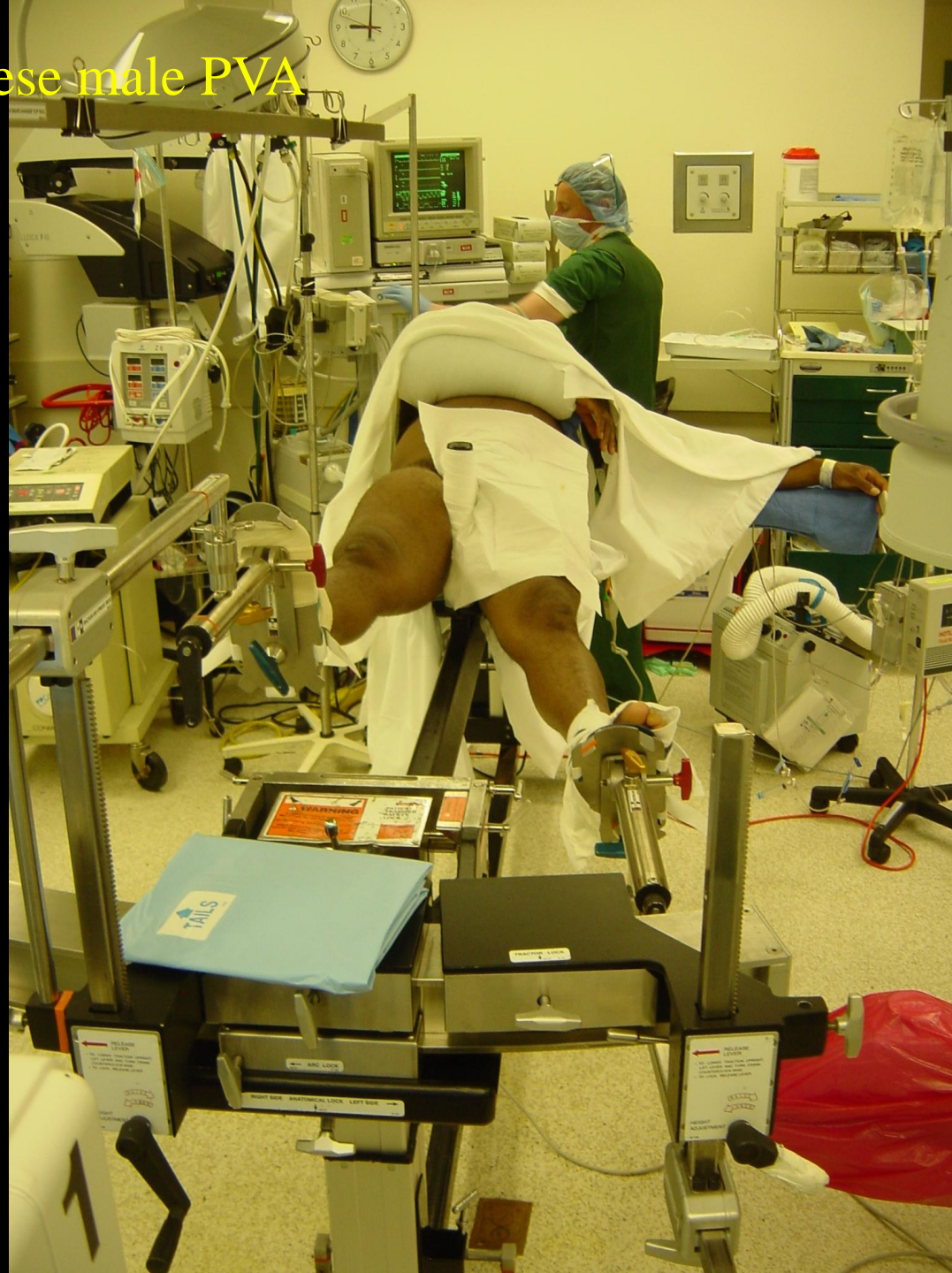



57 year old obese male PVA

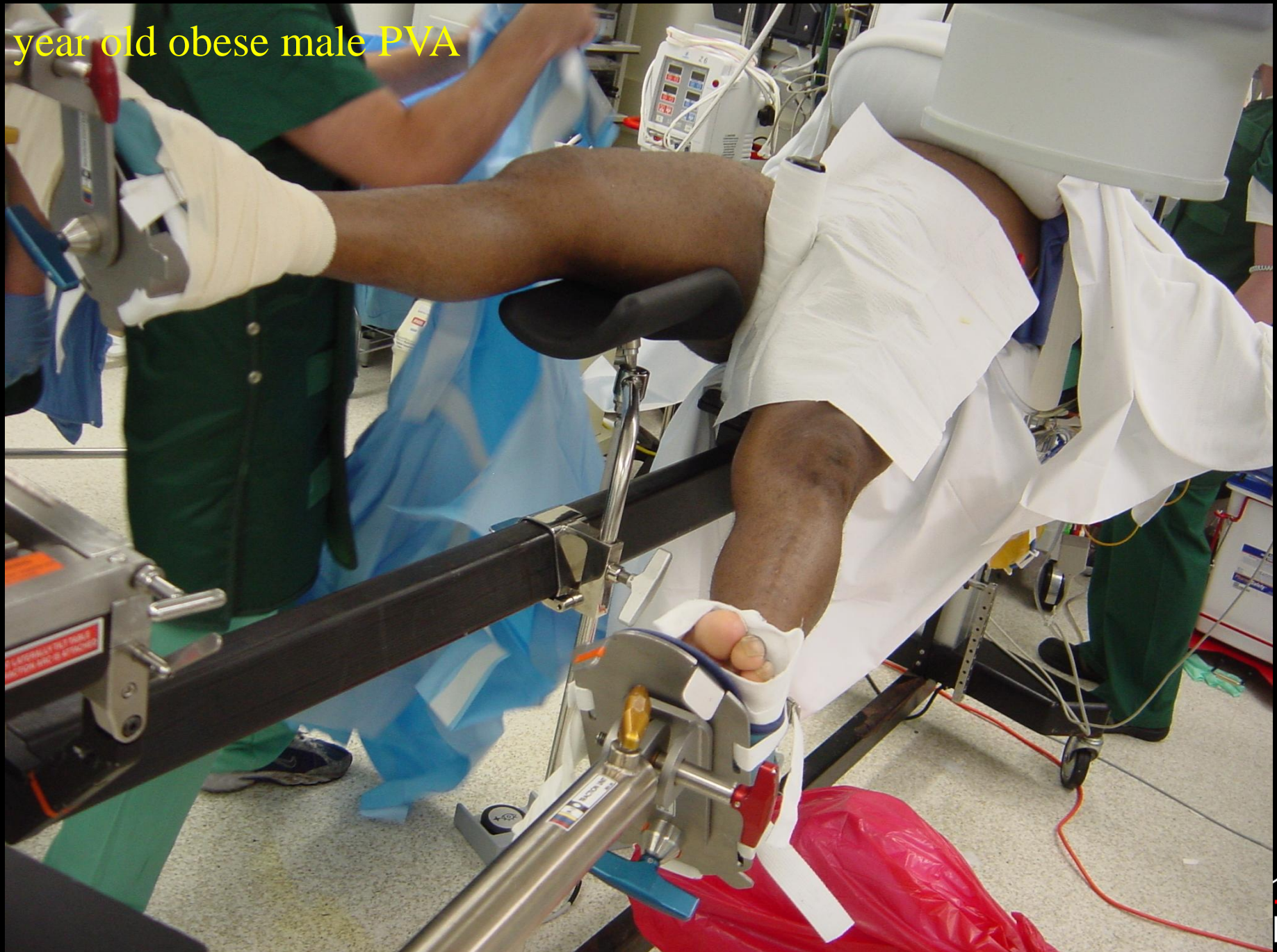

57 year old obese male PVA



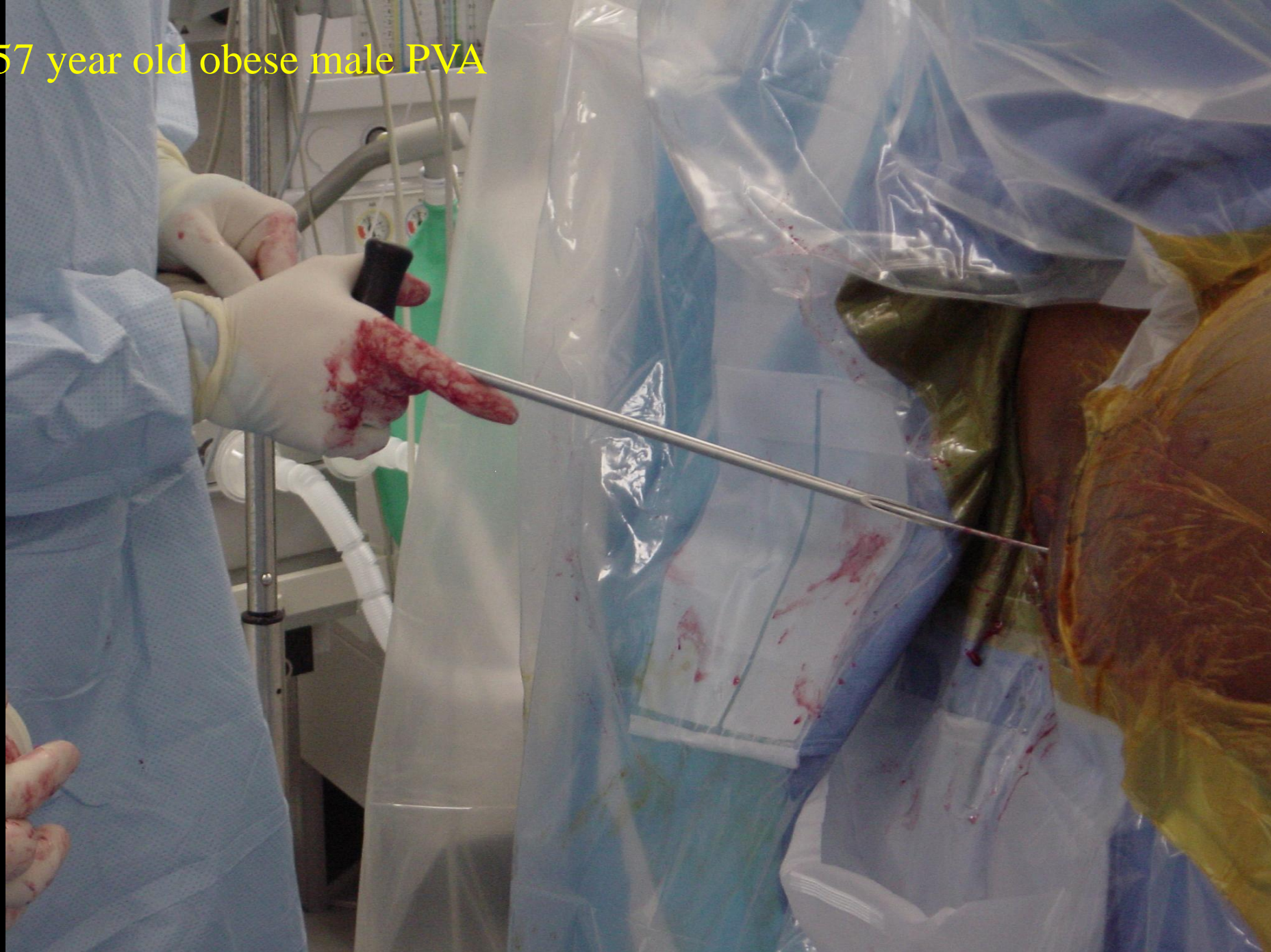


57 year old obese male PVA



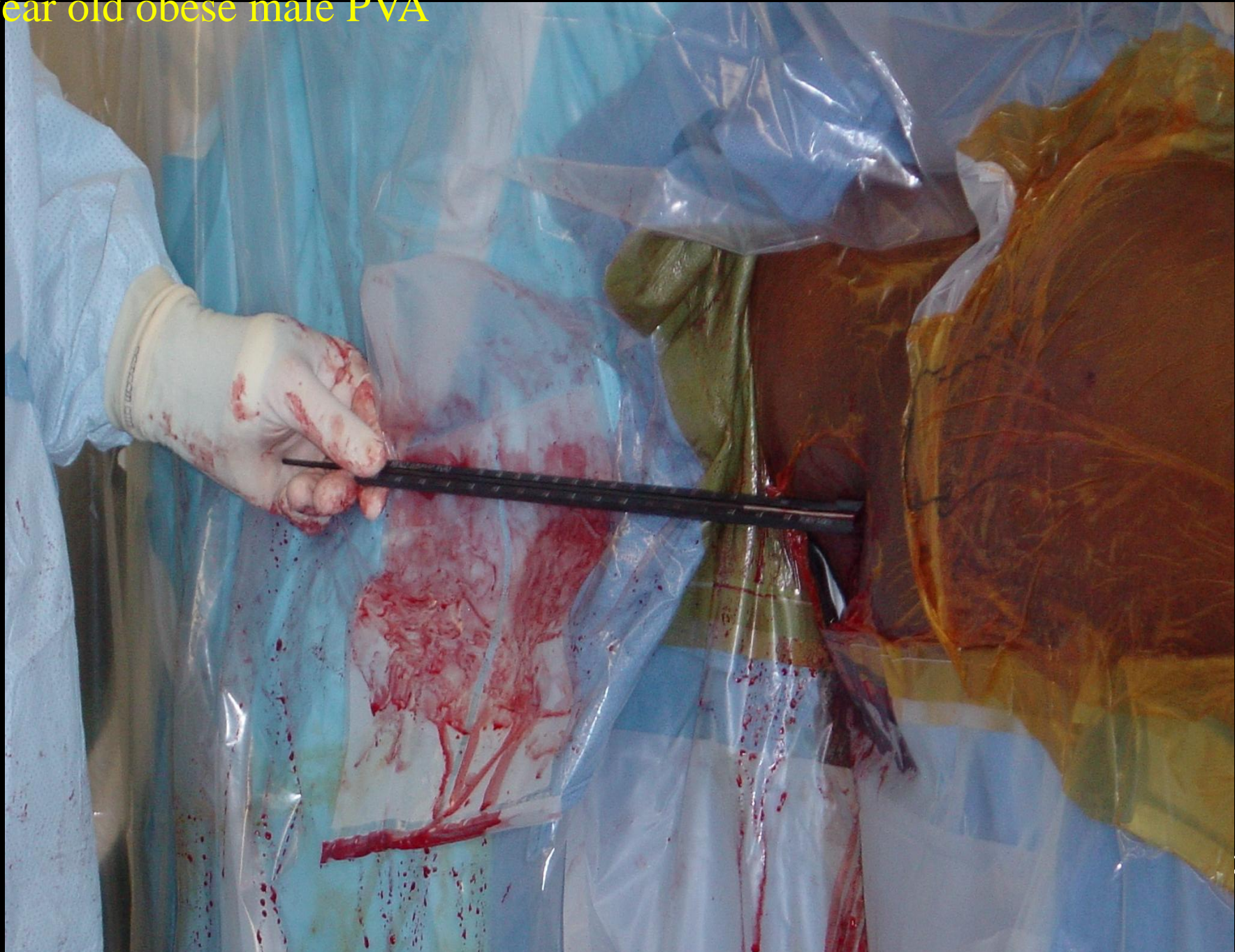

57 year old obese male PVA



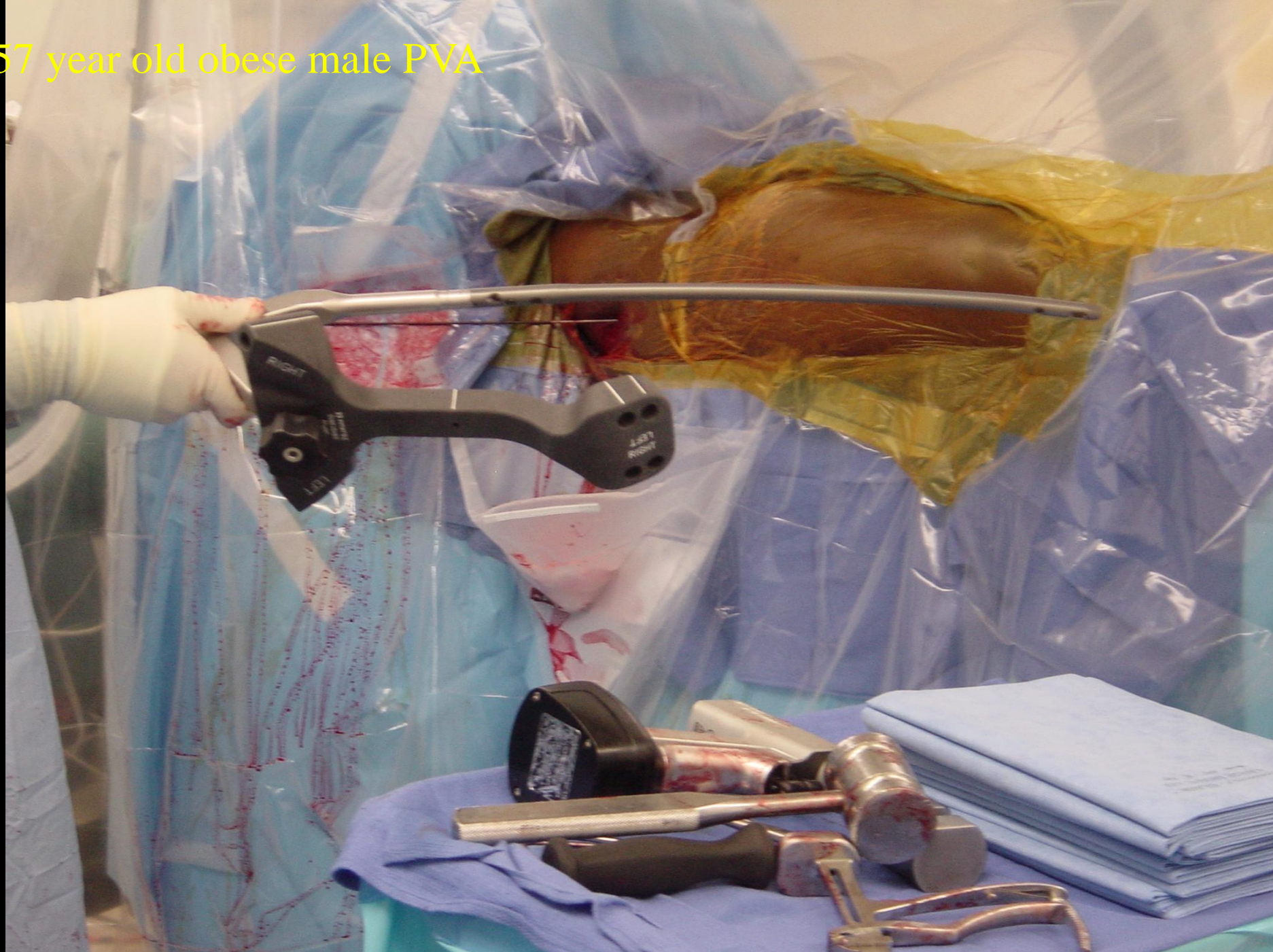


57 year old obese male PVA



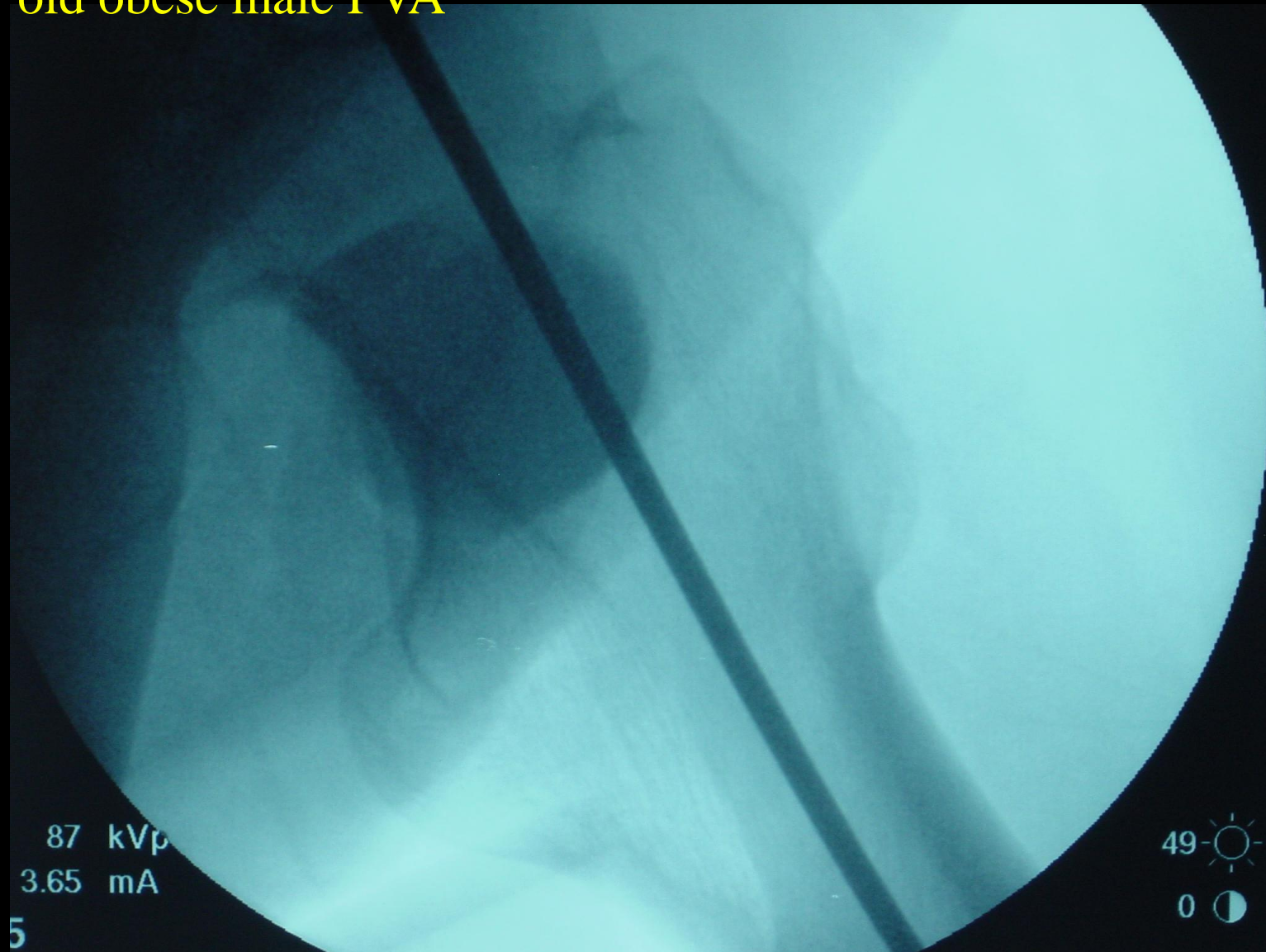


57 year old obese male PVA

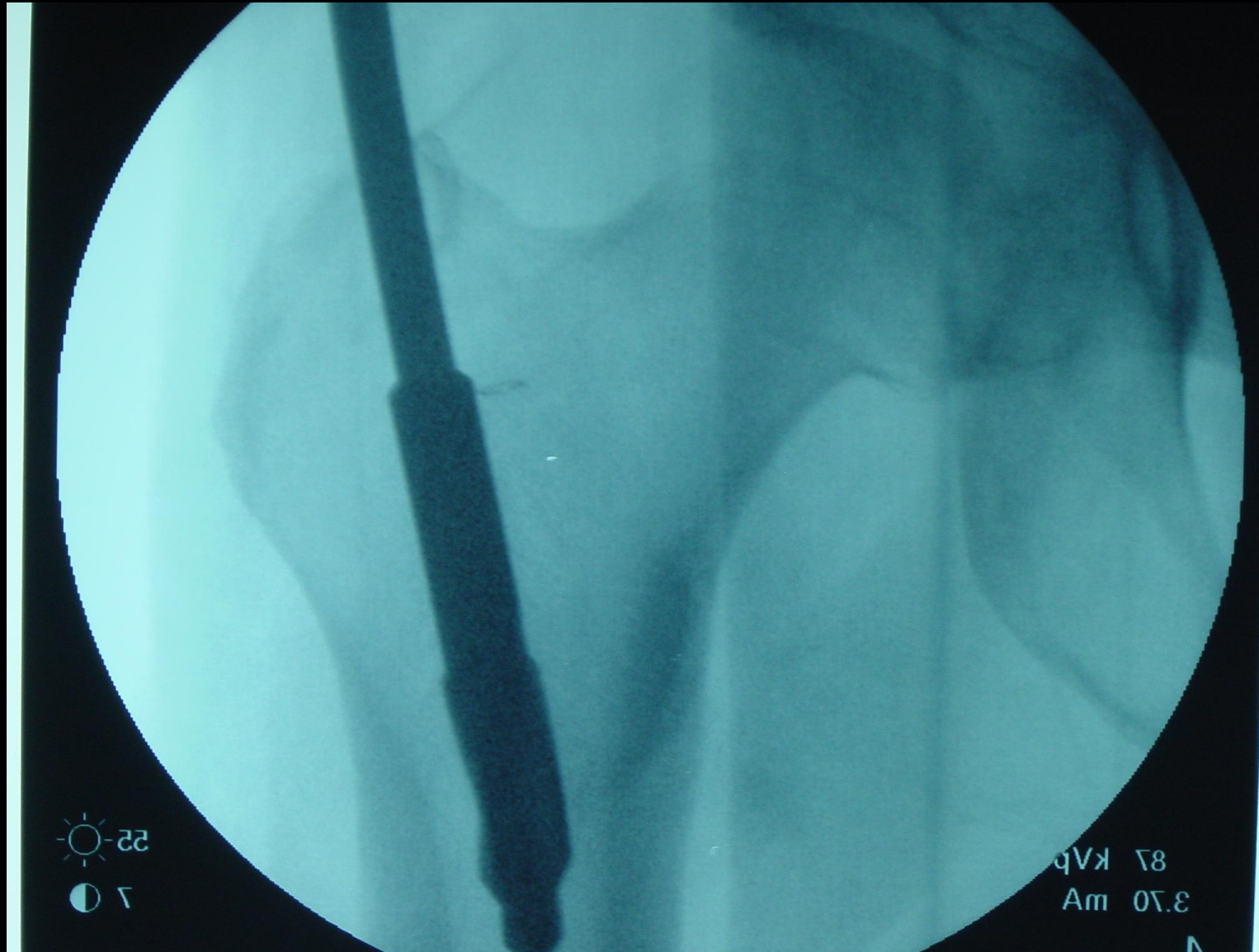




57 year old obese male PVA

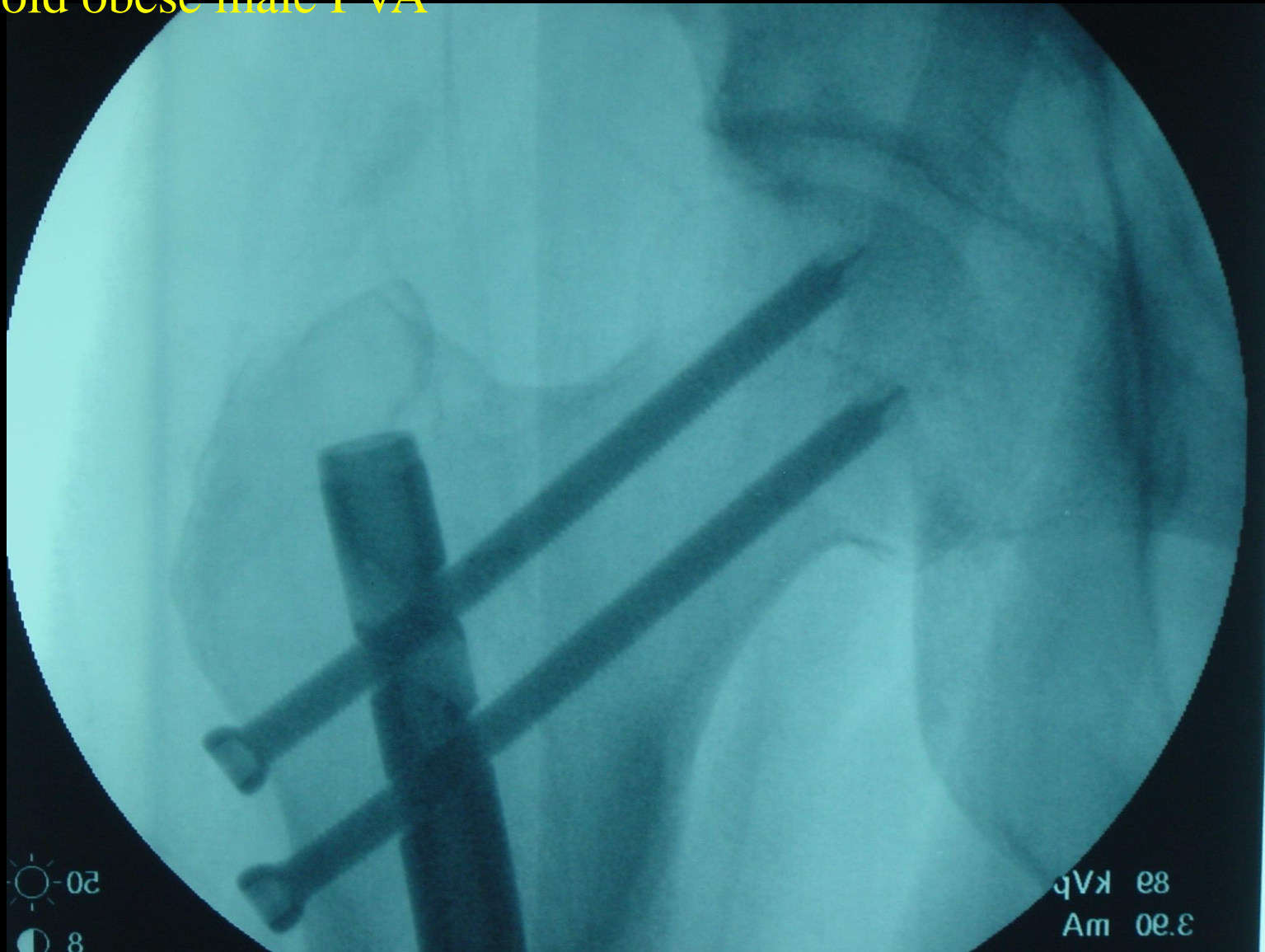


57 year old obese male PVA

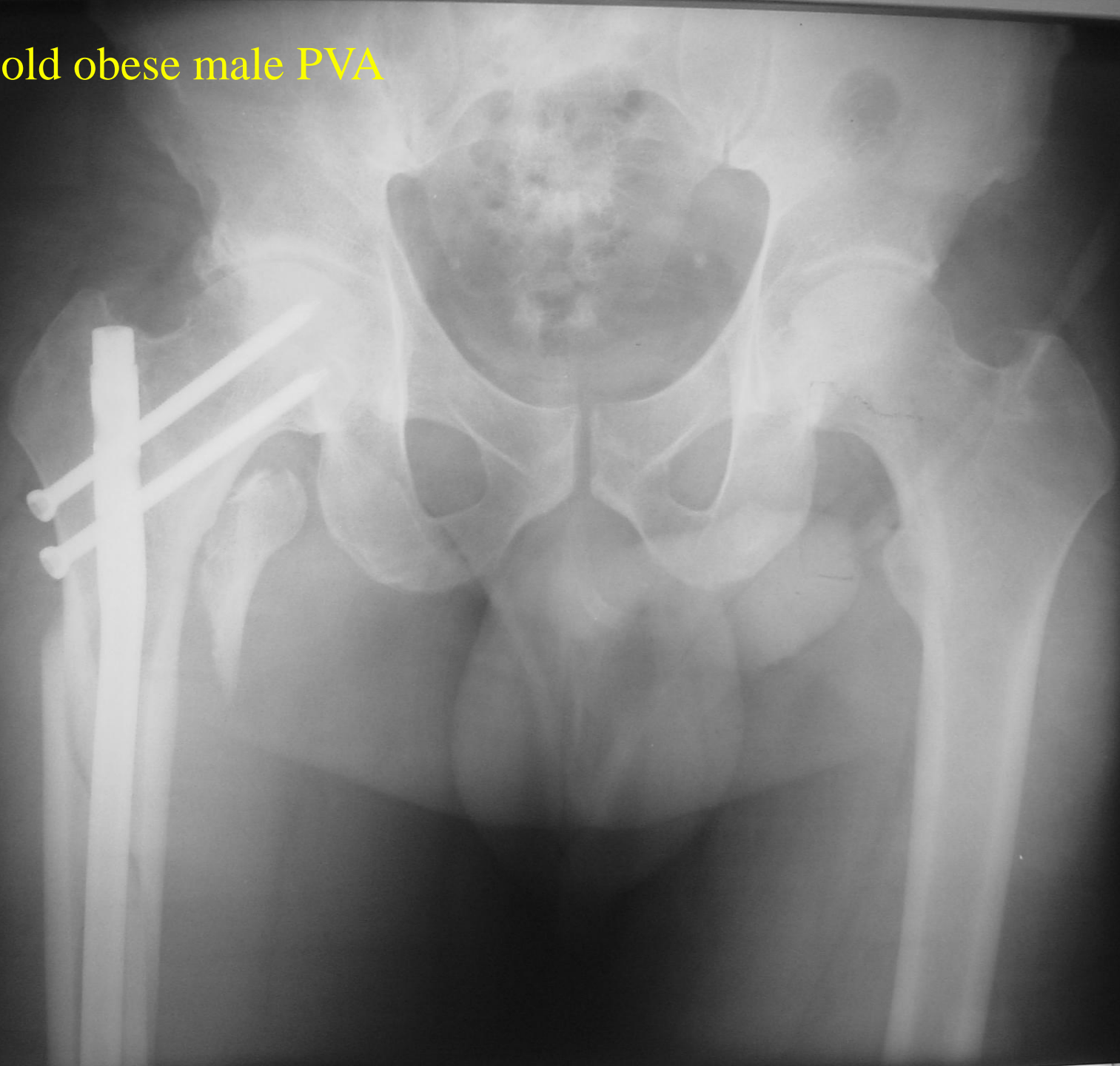




57 year old obese male PVA

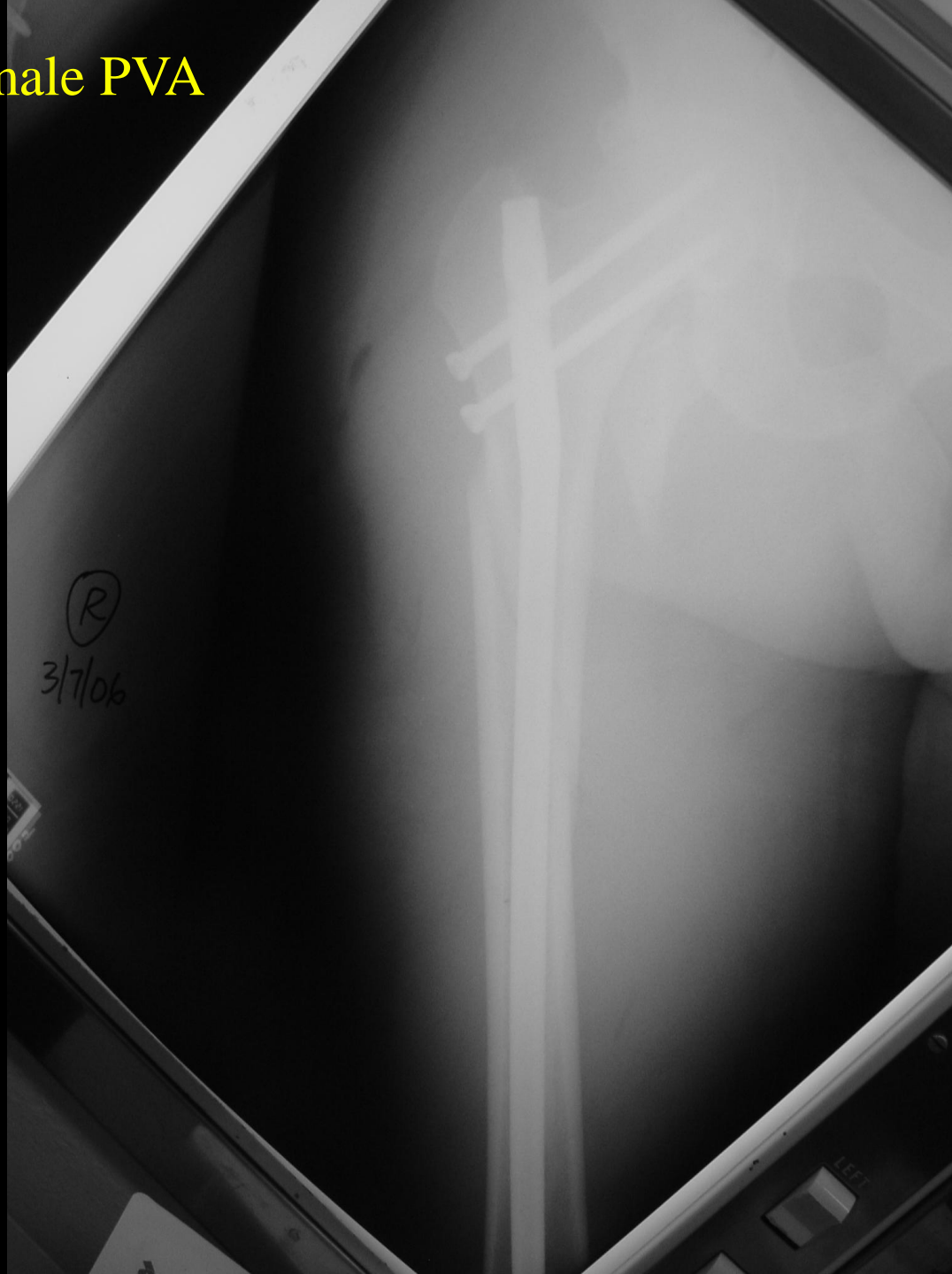


57 year old obese male PVA

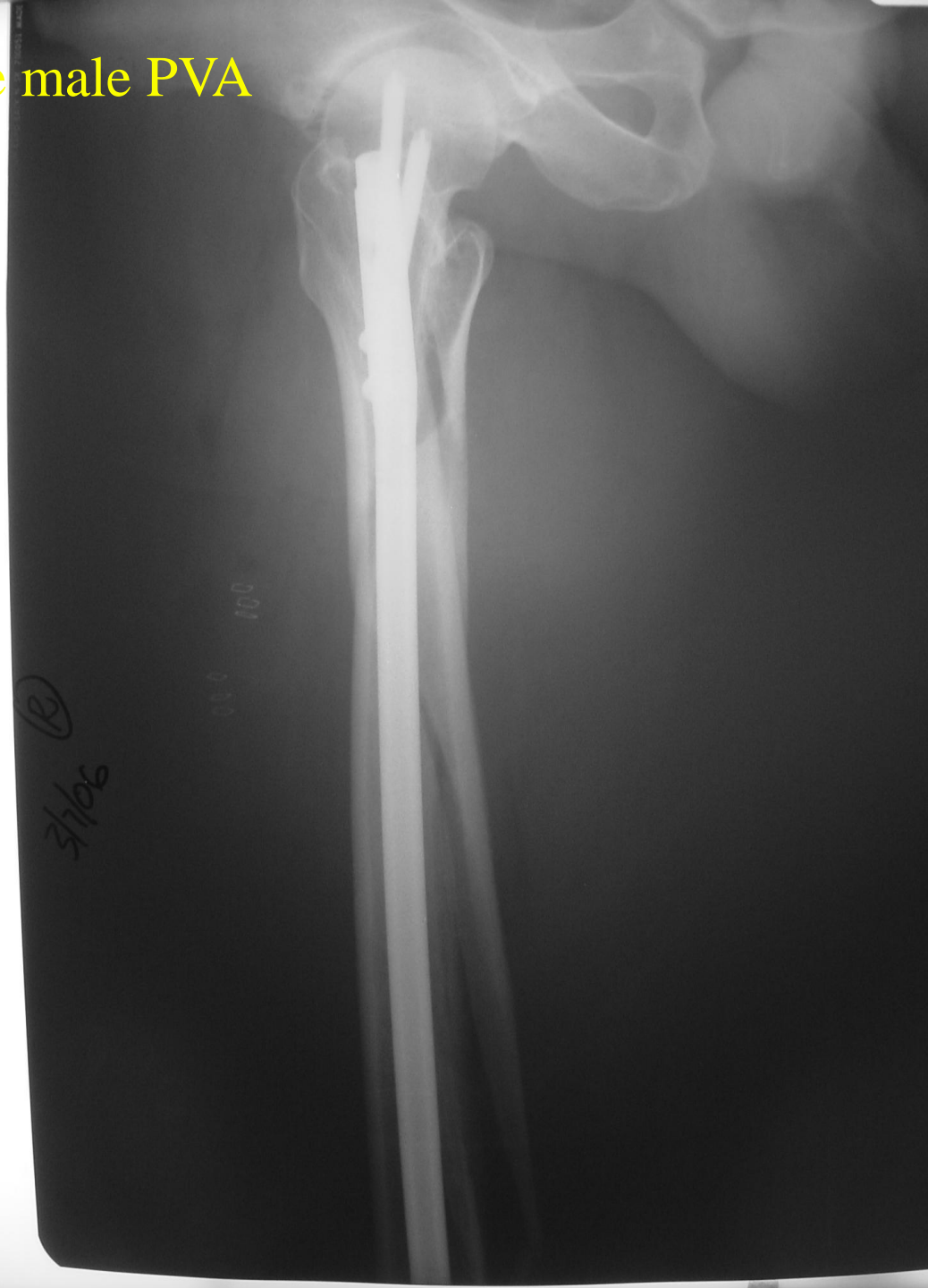



57 year old obese male PVA

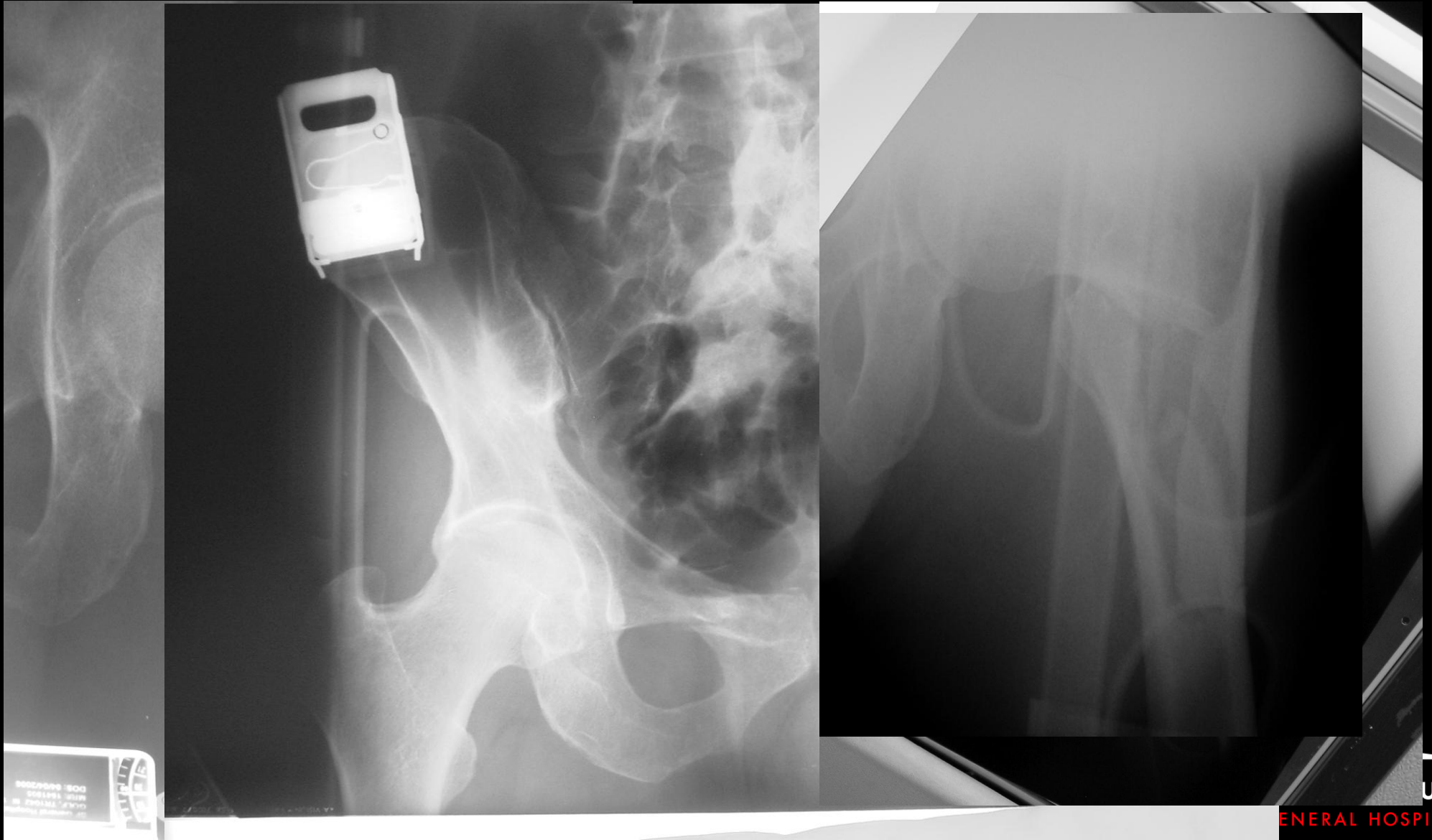

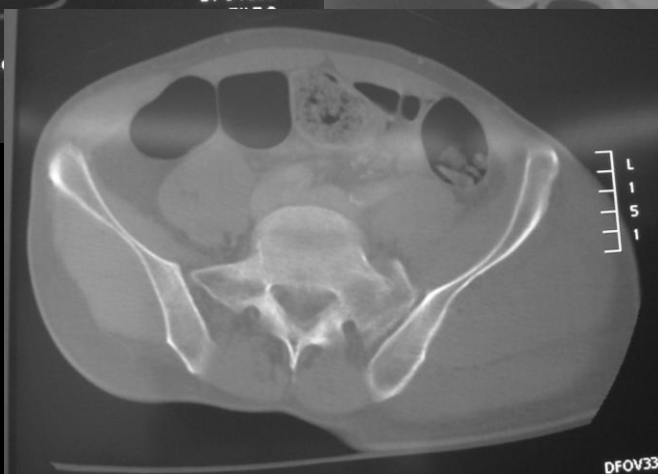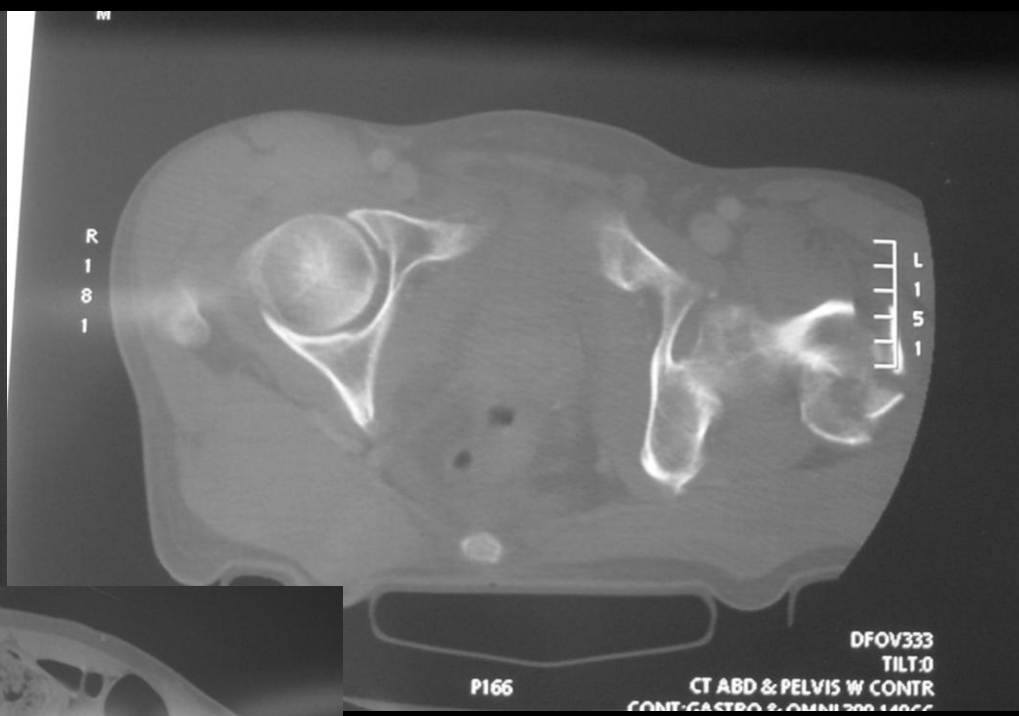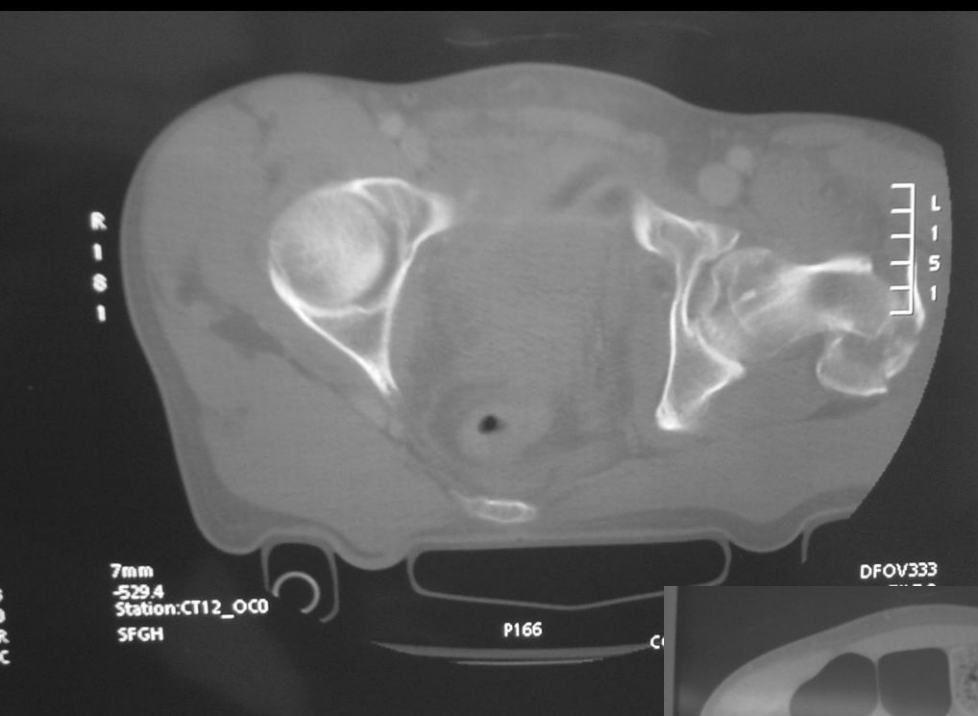
57 year old obese male PVA



# Short Segment Femur Fracture

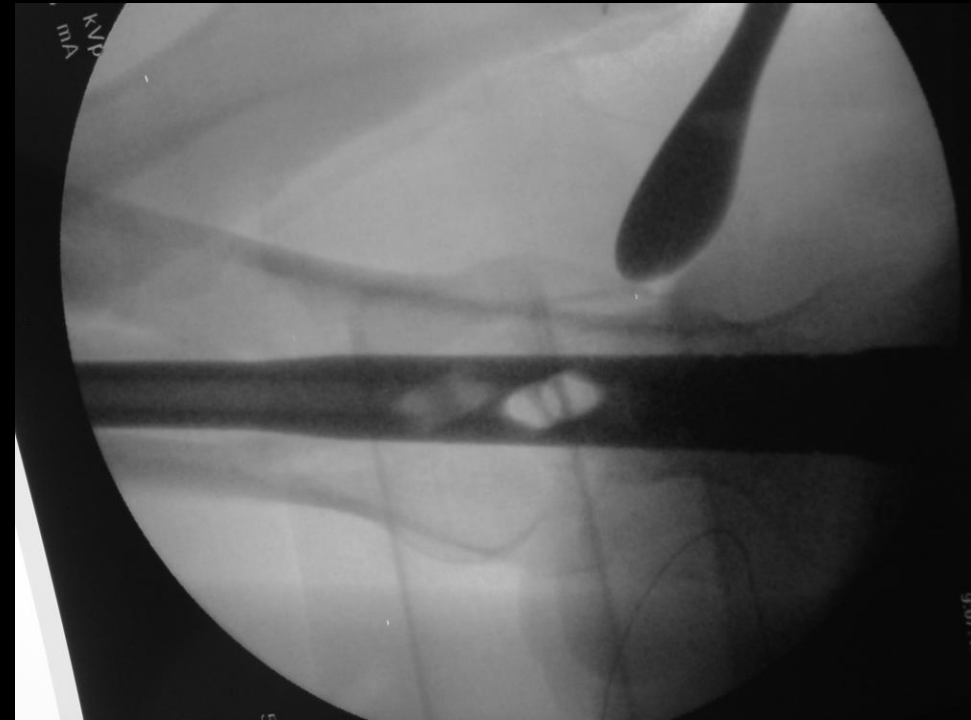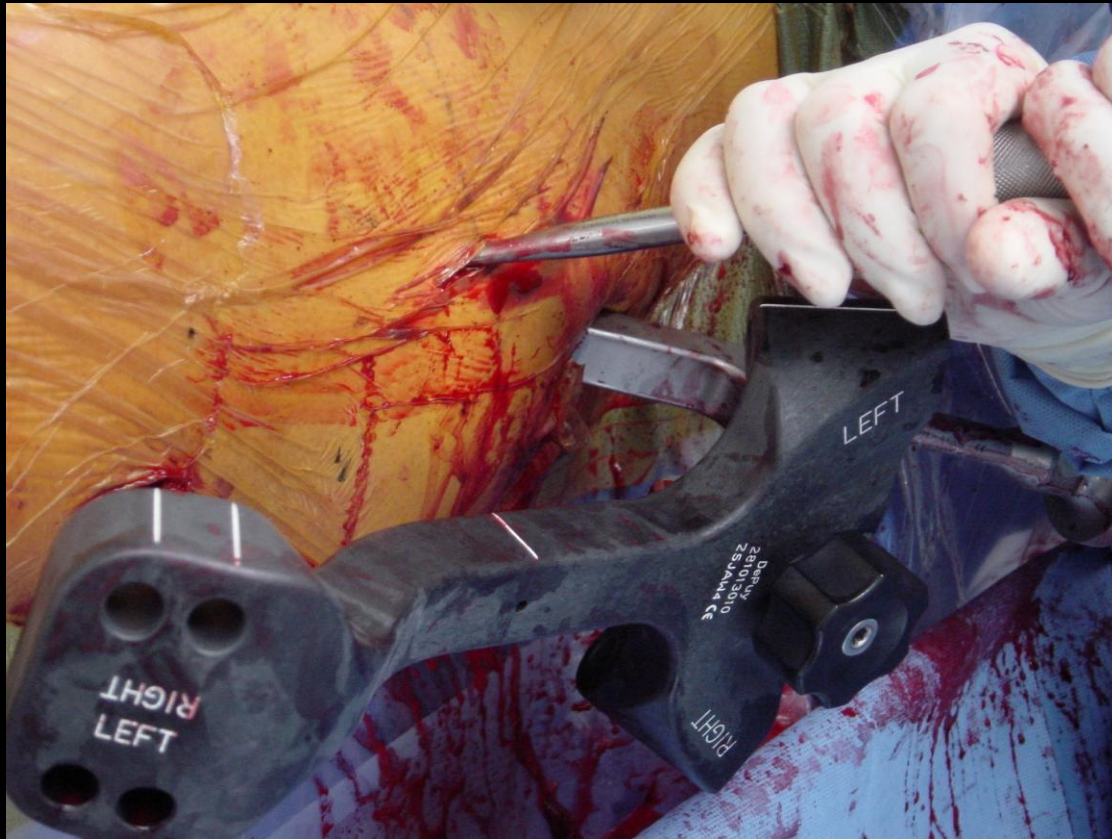## 54 yo male jumper 30ft





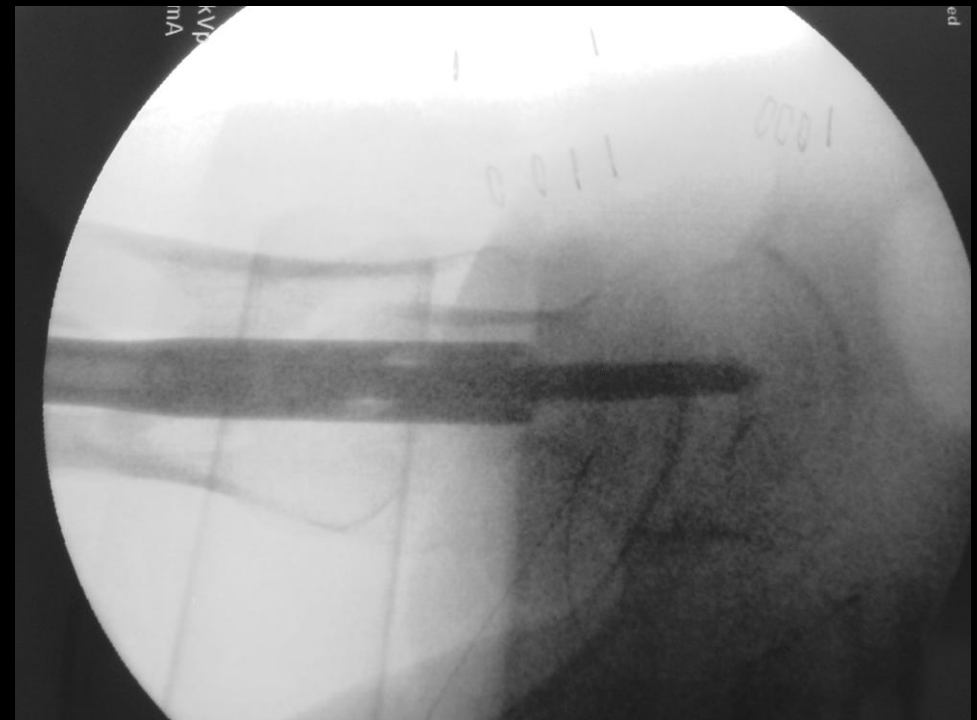
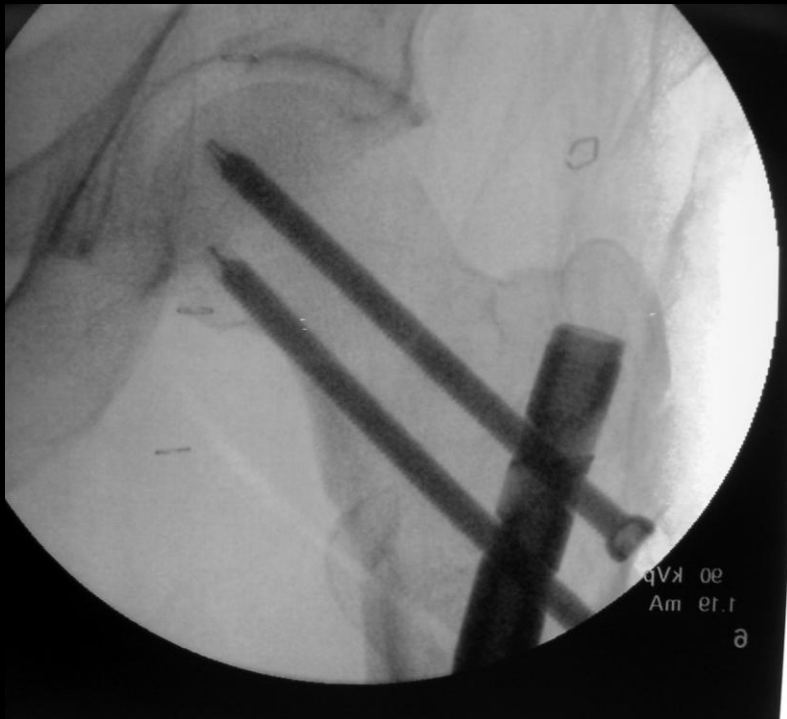

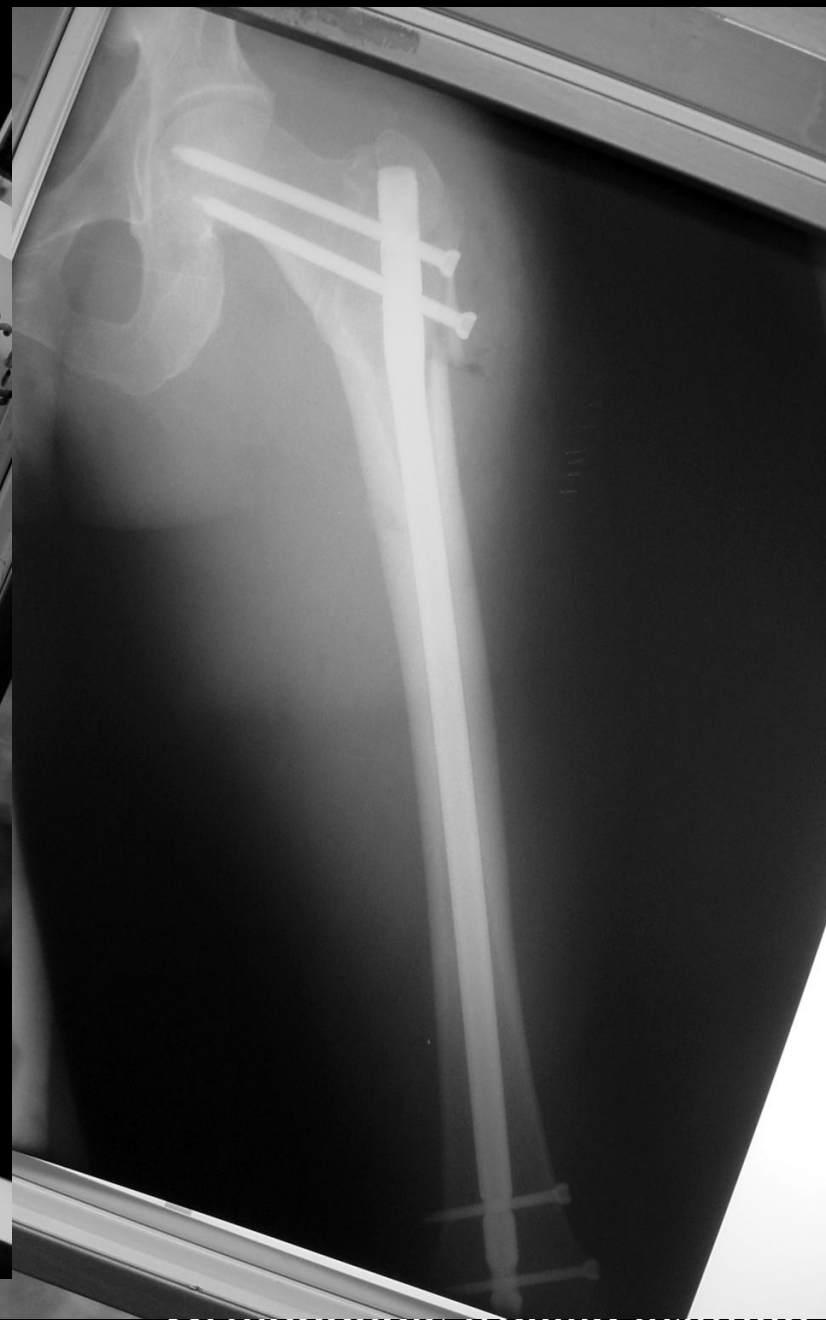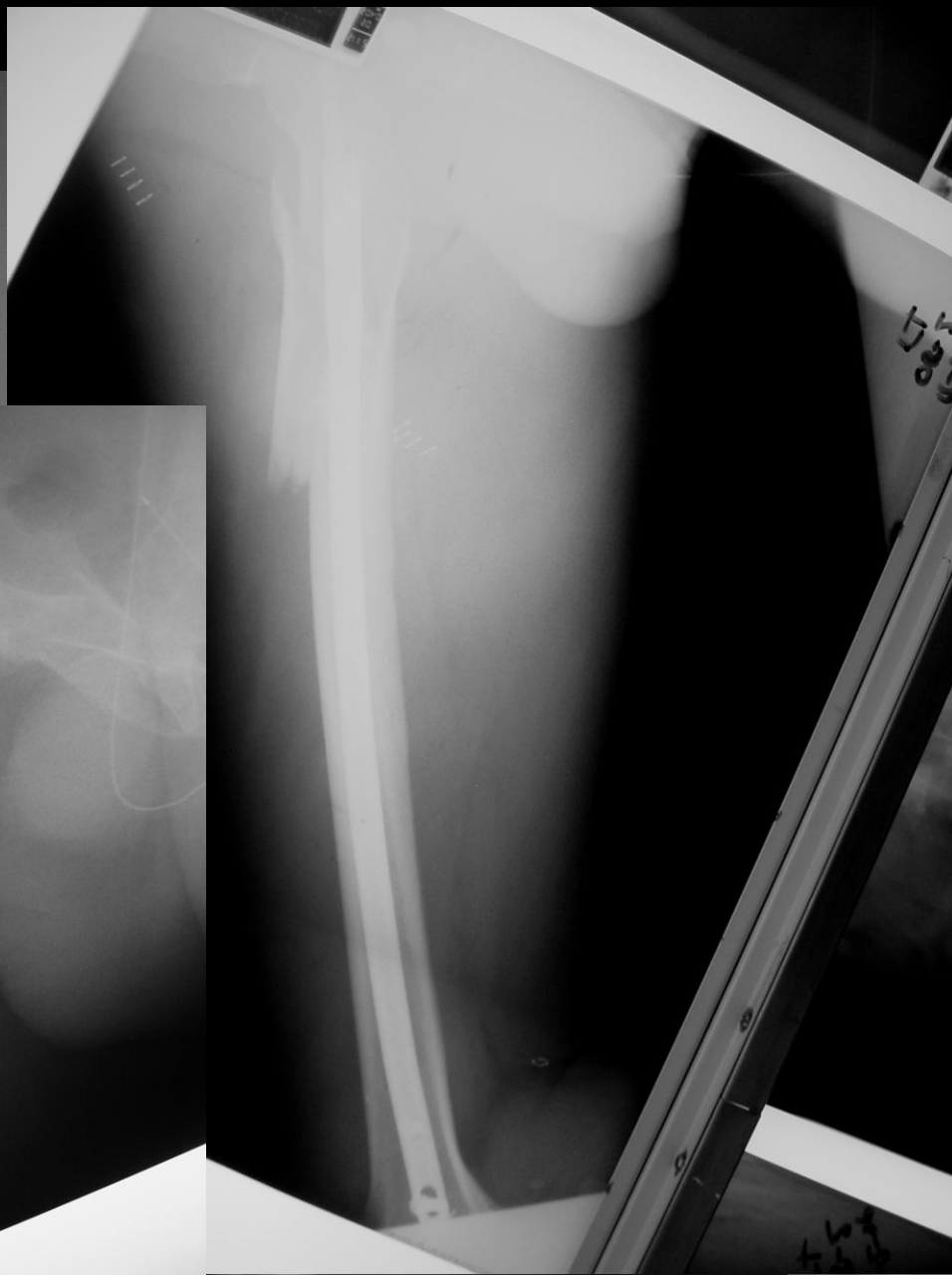
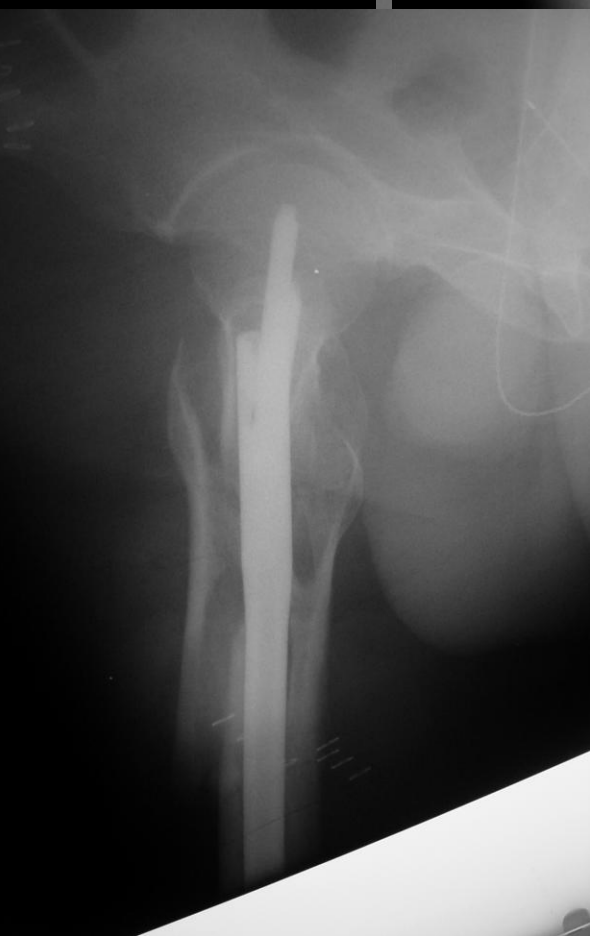# TEN 38cm x 11 mm

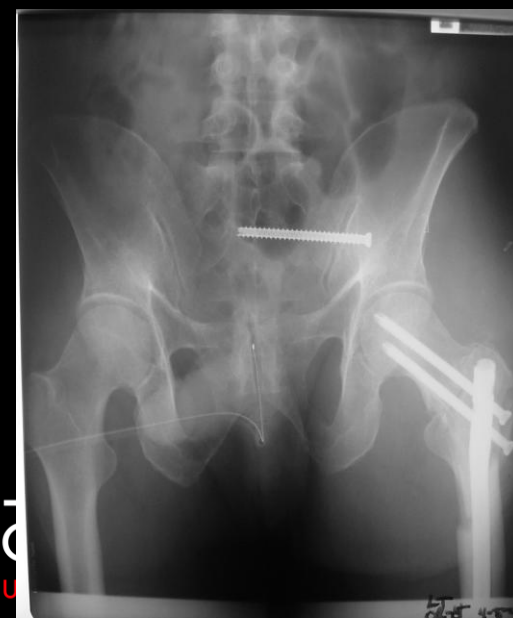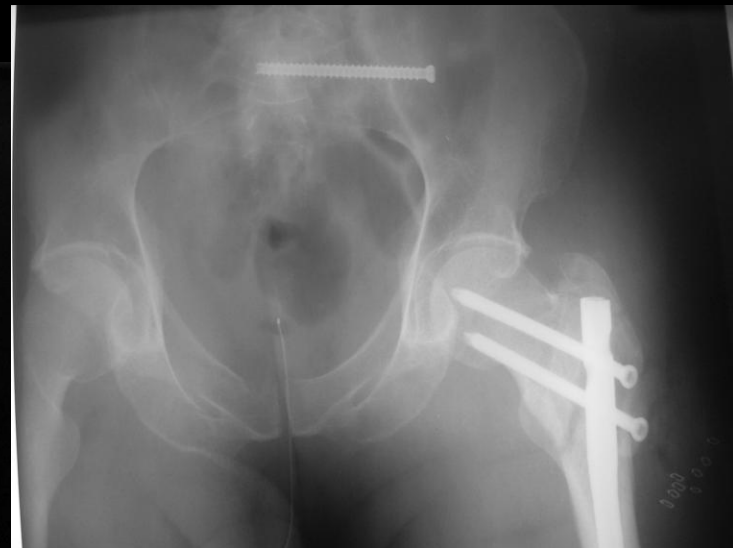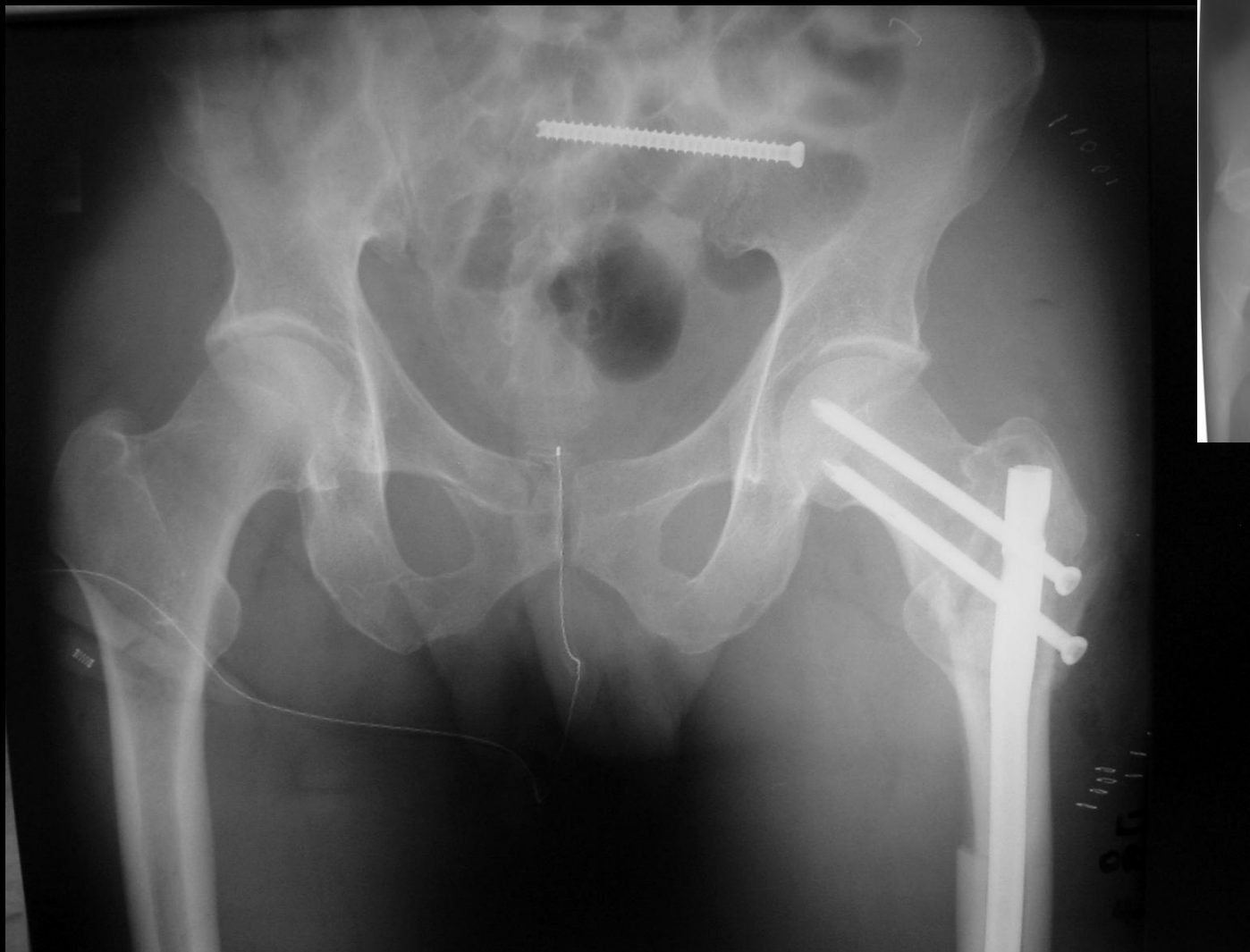




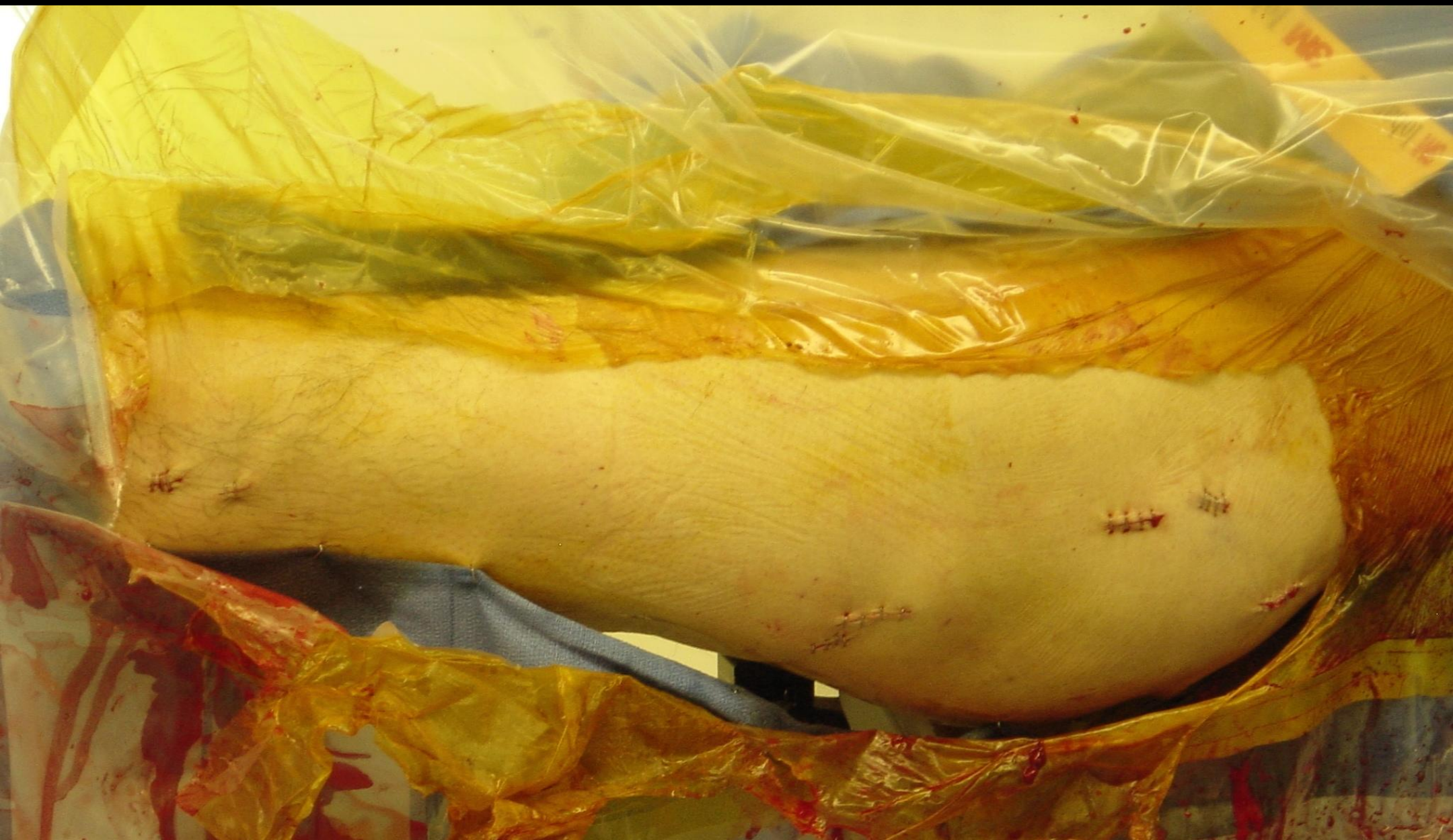# Two screws into head





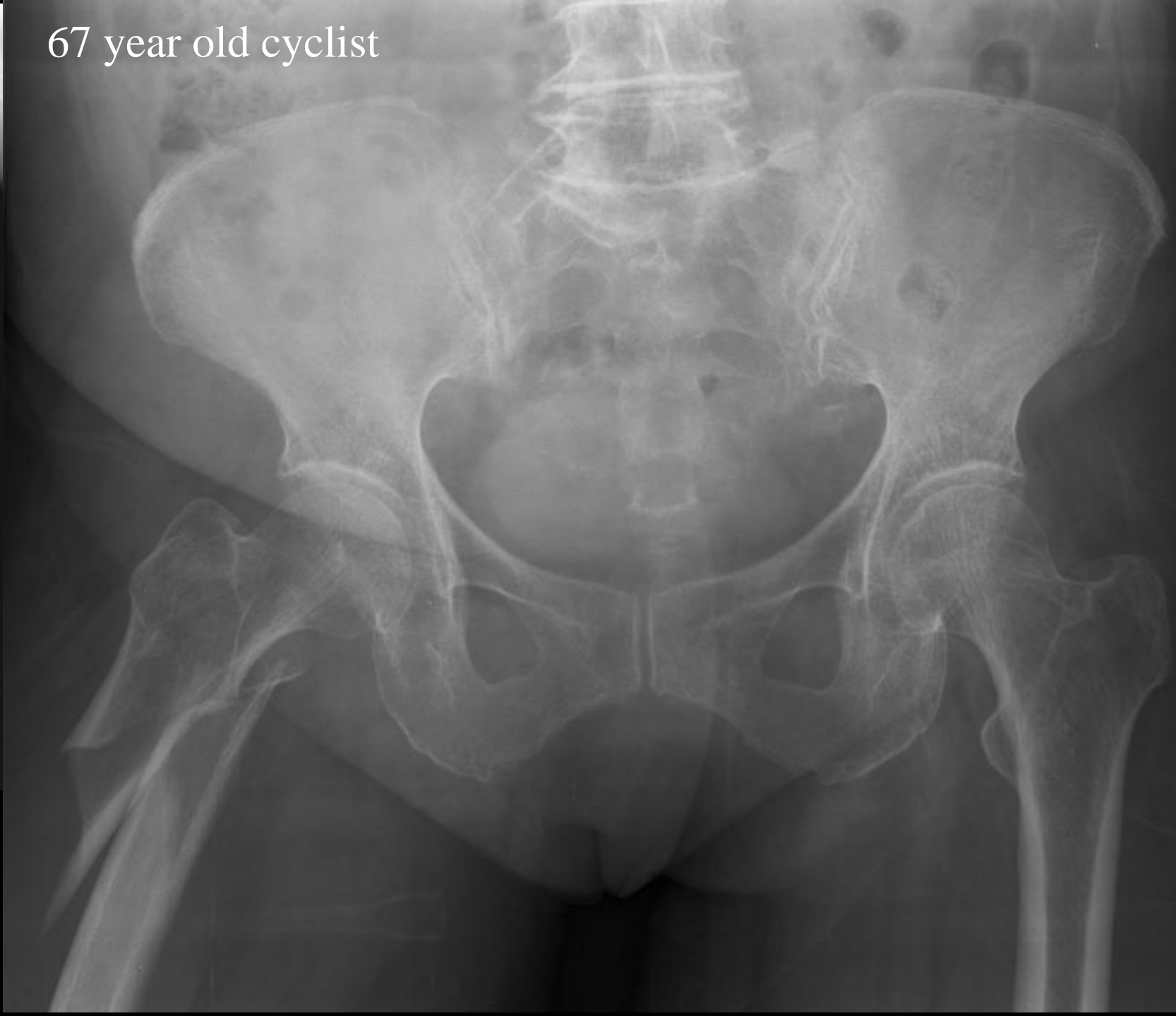

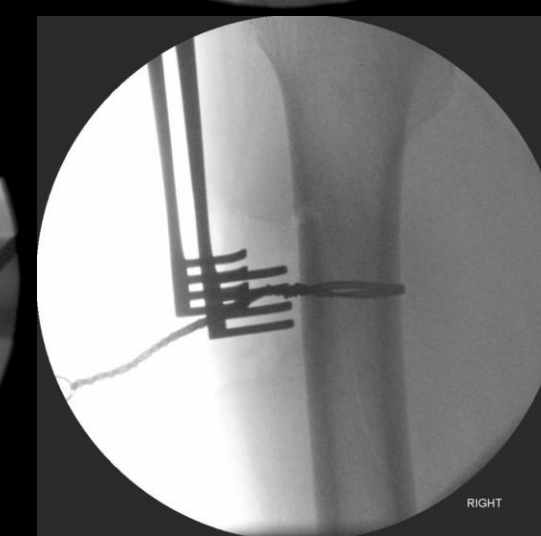

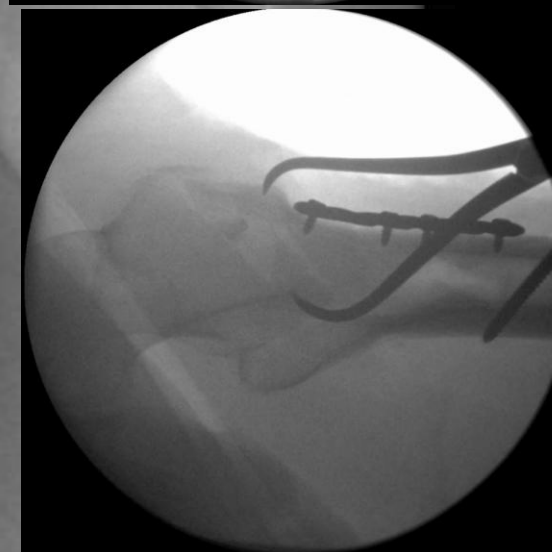
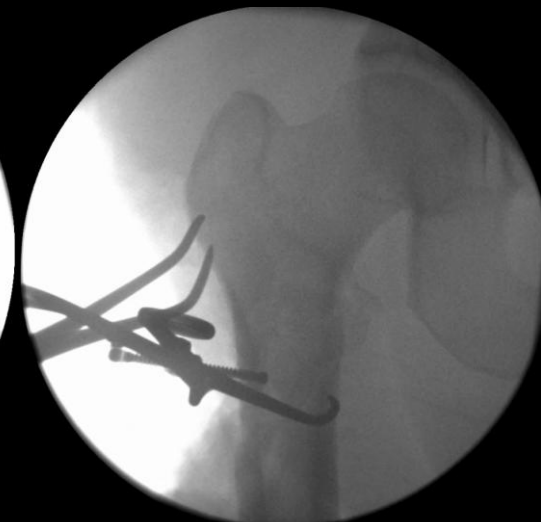
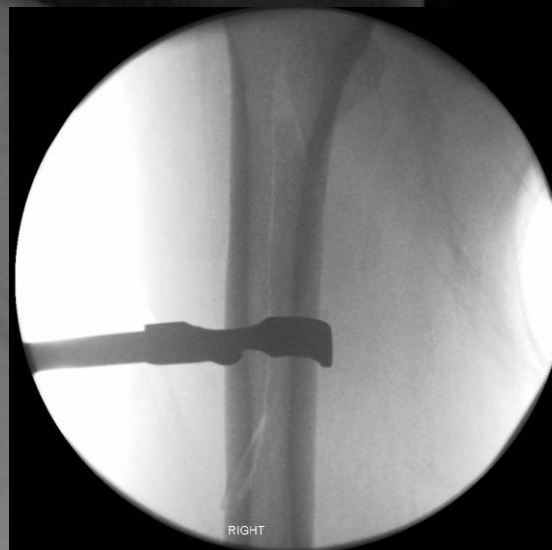




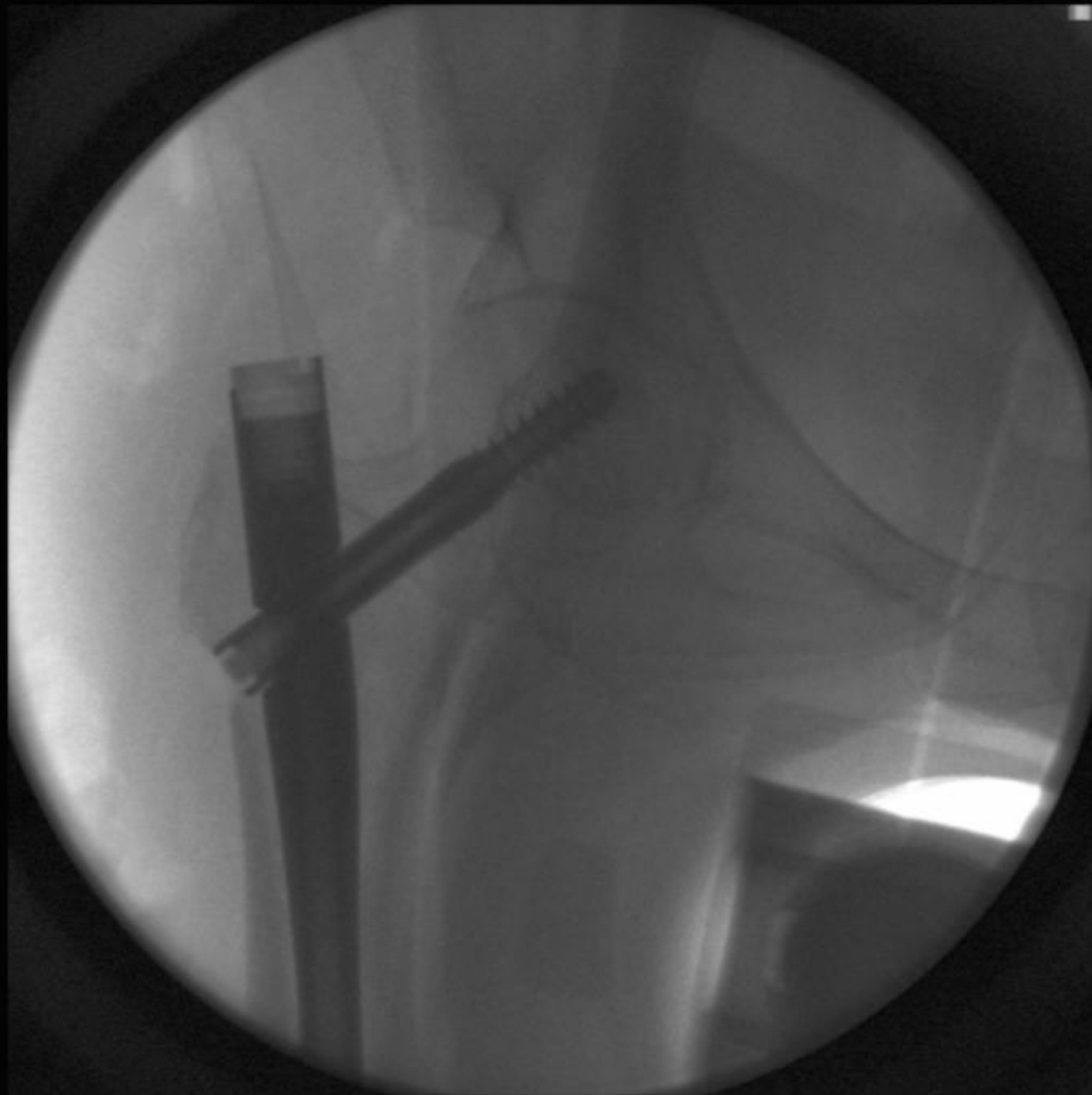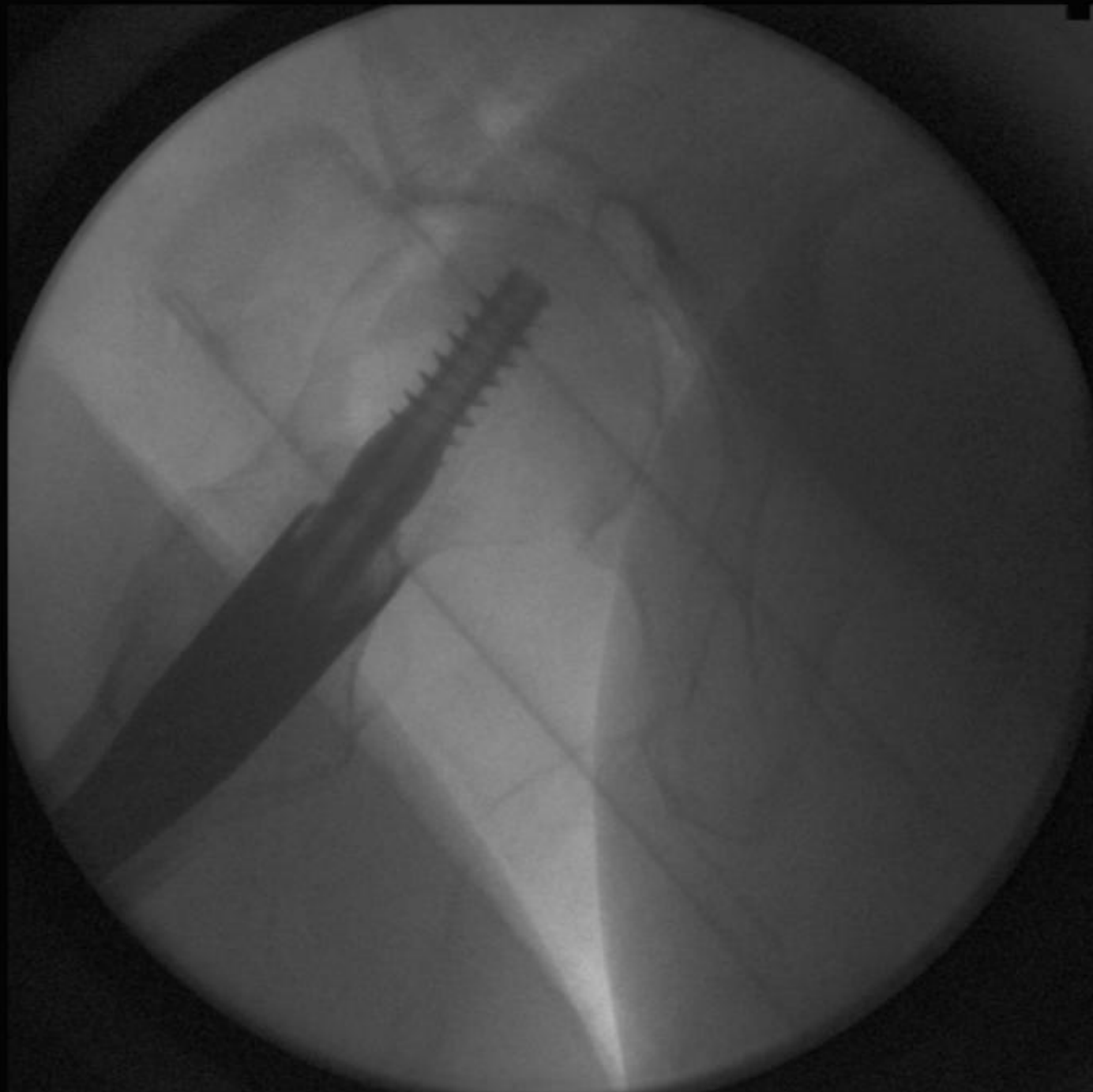
67 year old cyclist



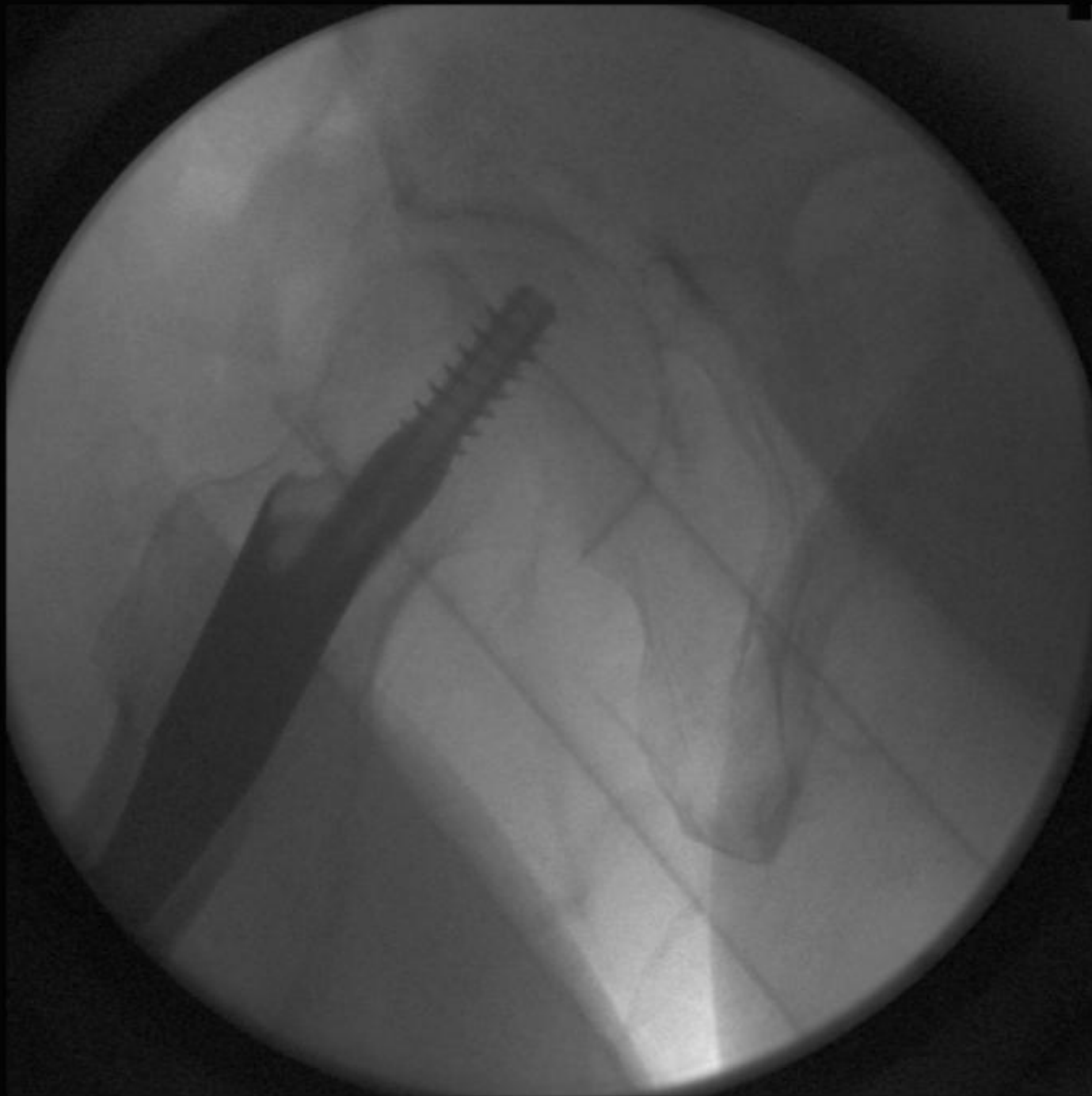


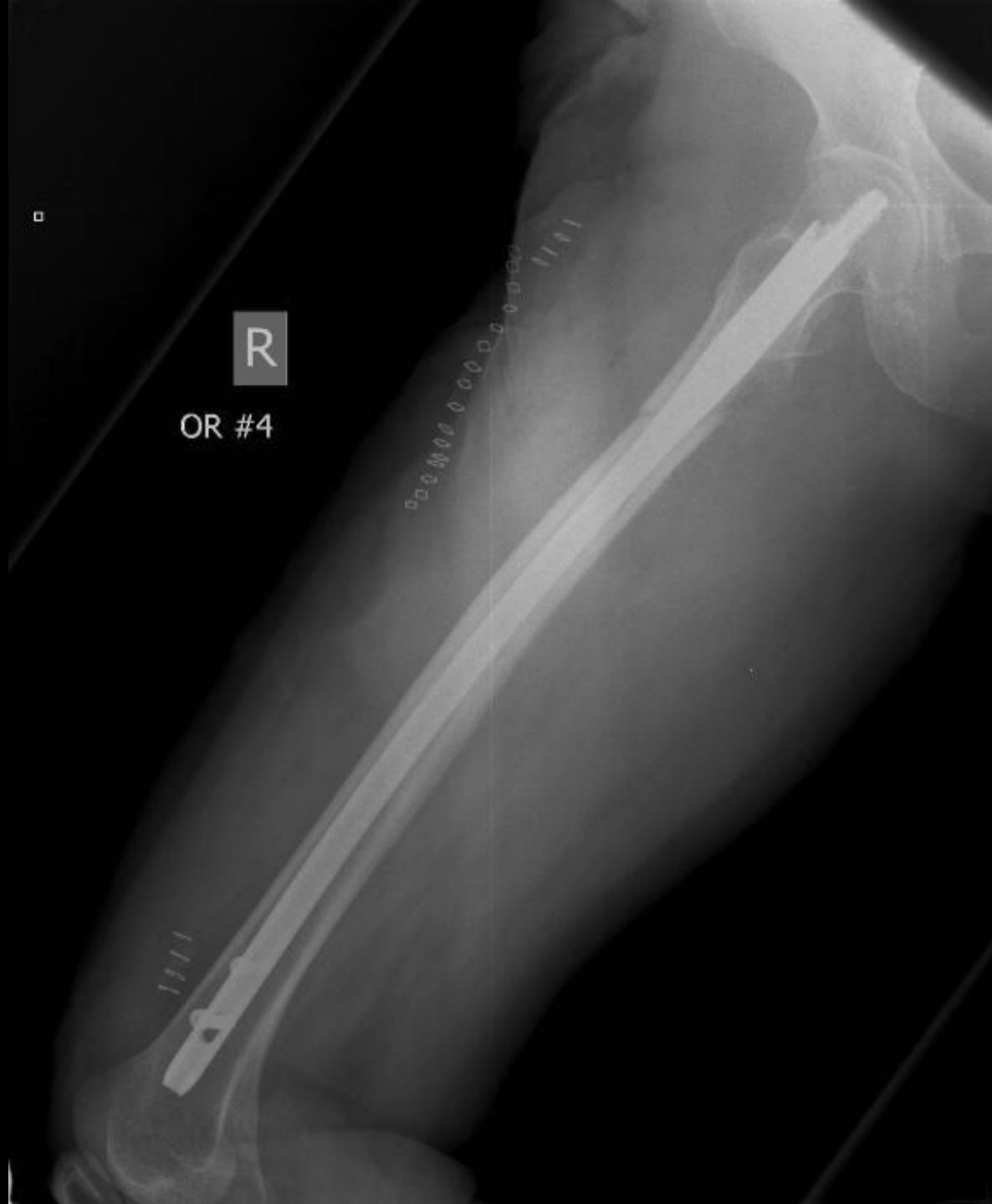OTA Resident Lecture

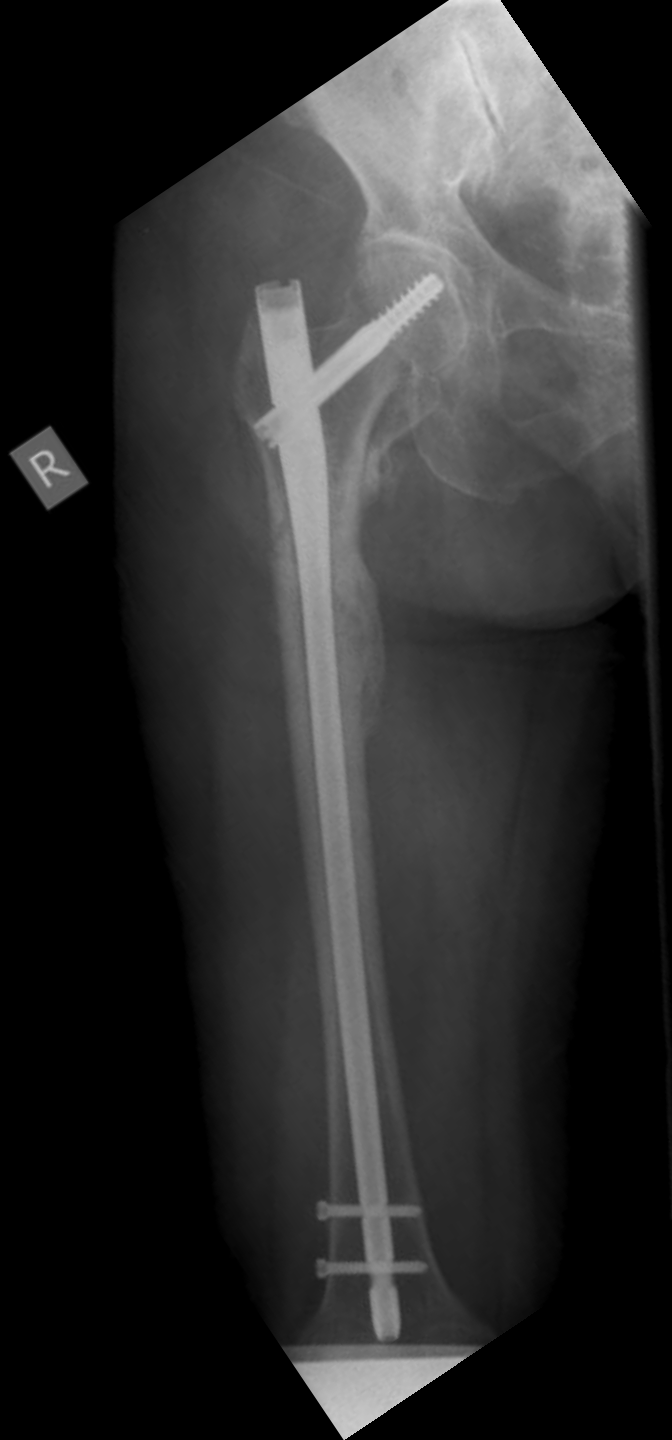







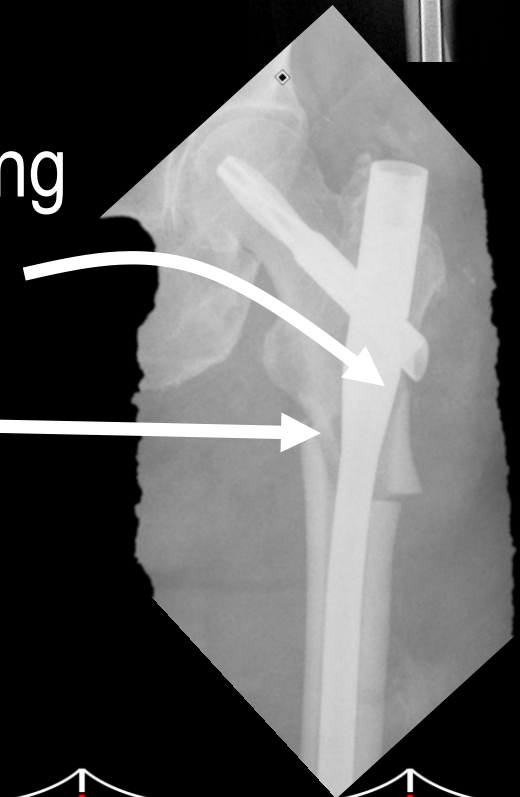






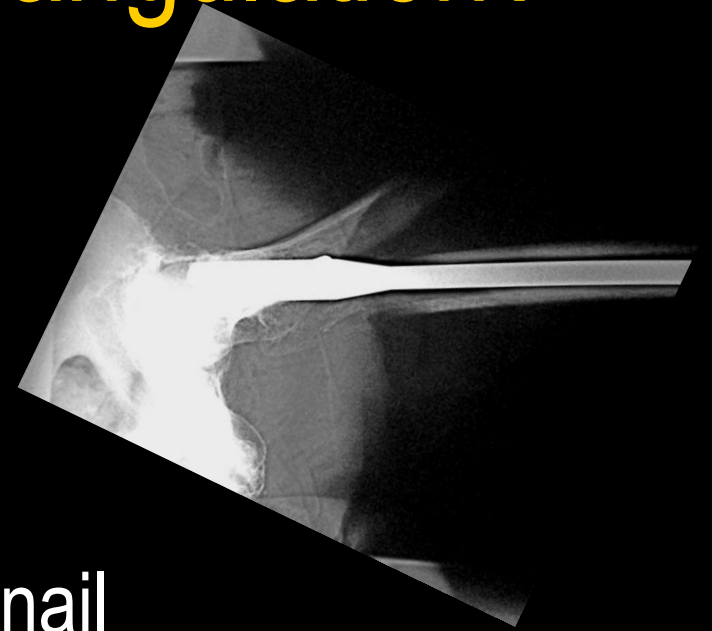
# Why Do You get Varus?

- Reduction
  - Fracture not reduced before reaming
  - Not holding reduction during reaming
  - Not holding reduction while inserting nail
  - Not holding reduction while proximal locking
- Lateral Proximal cortical nail abutment
- Medial Distal cortical nail abutment
- Ovalization of entry hole
- Not knowing proximal bend of nail
- Not enough or too much traction



# Why Do You get anterior angulation?

- Inadequate Imaging
- Reduction
  - Fracture not reduced before reaming
  - Not holding reduction during reaming
  - Not holding reduction while inserting nail
  - Not holding reduction while proximal locking
- Entry hole too anterior
- Too much traction



# Summary

- ❑ Avoid varus or Procurvatum
- ❑ Anatomy that has predisposition to varus and procurvatum – Muscle pull
- ❑ Mechanical axis is medial and causes high stress on implants and malreductions
- ❑ Intraop technical causes of malreduction
- ❑ Treatment options and gold standard
- ❑ Tips for successful reduction



# Thank You