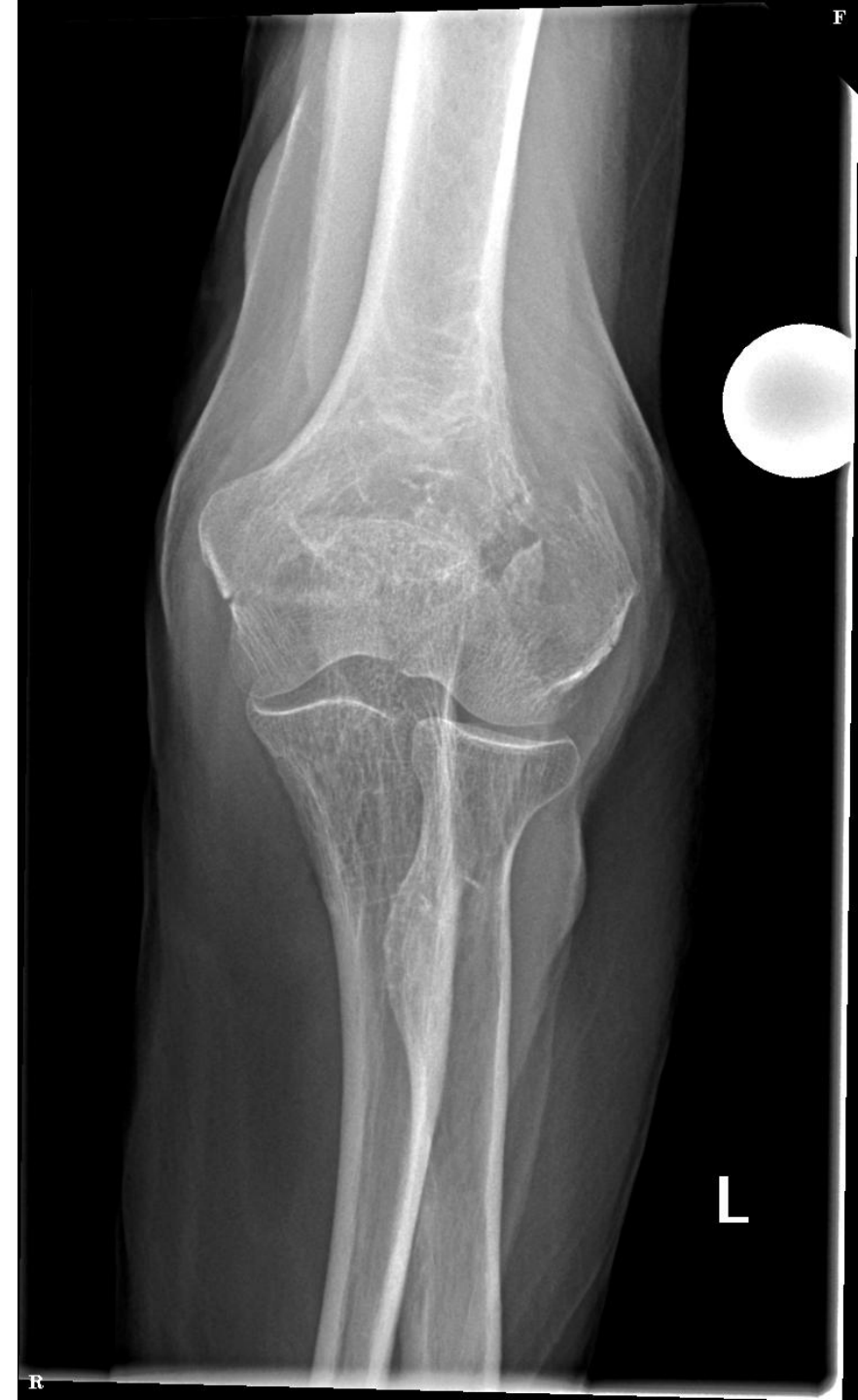
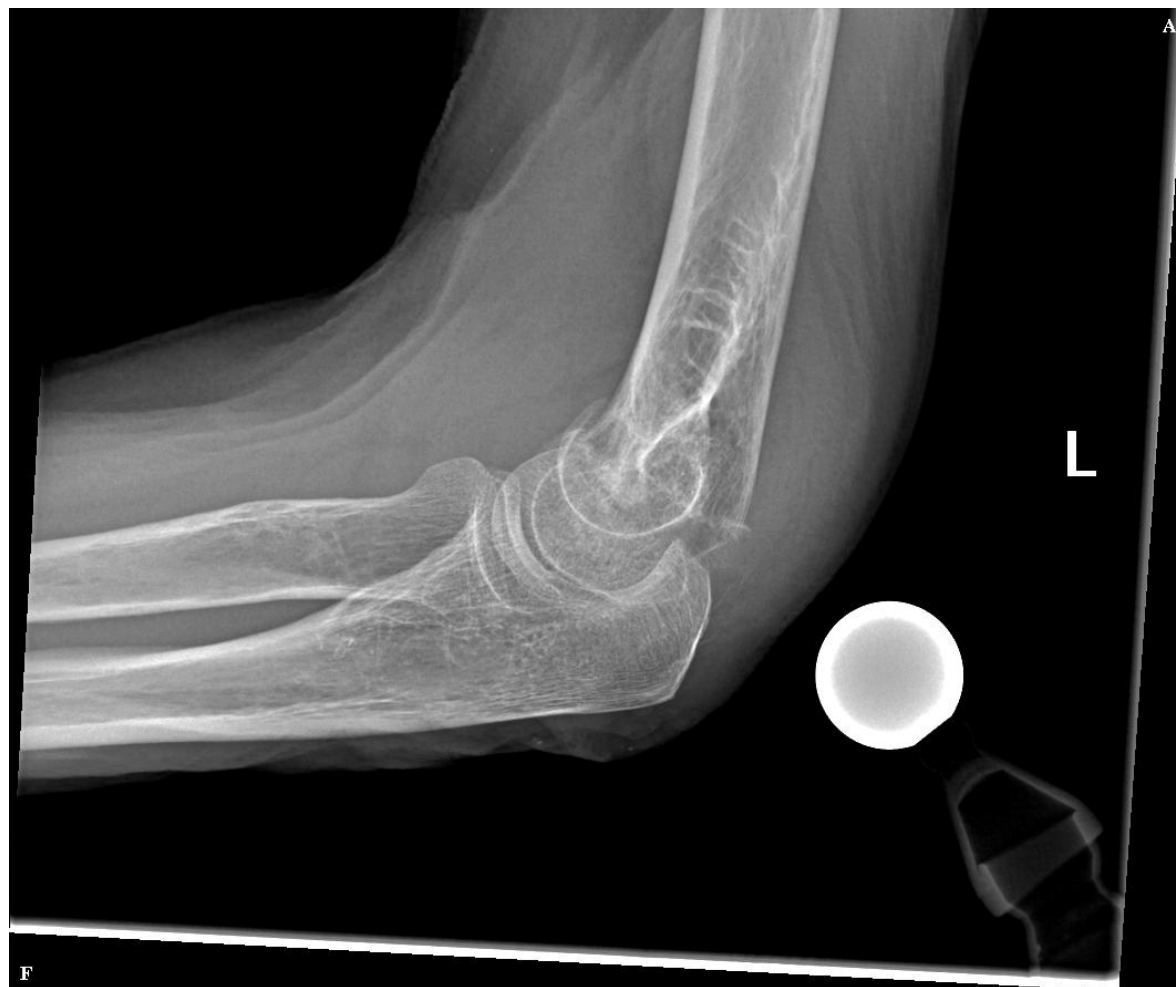
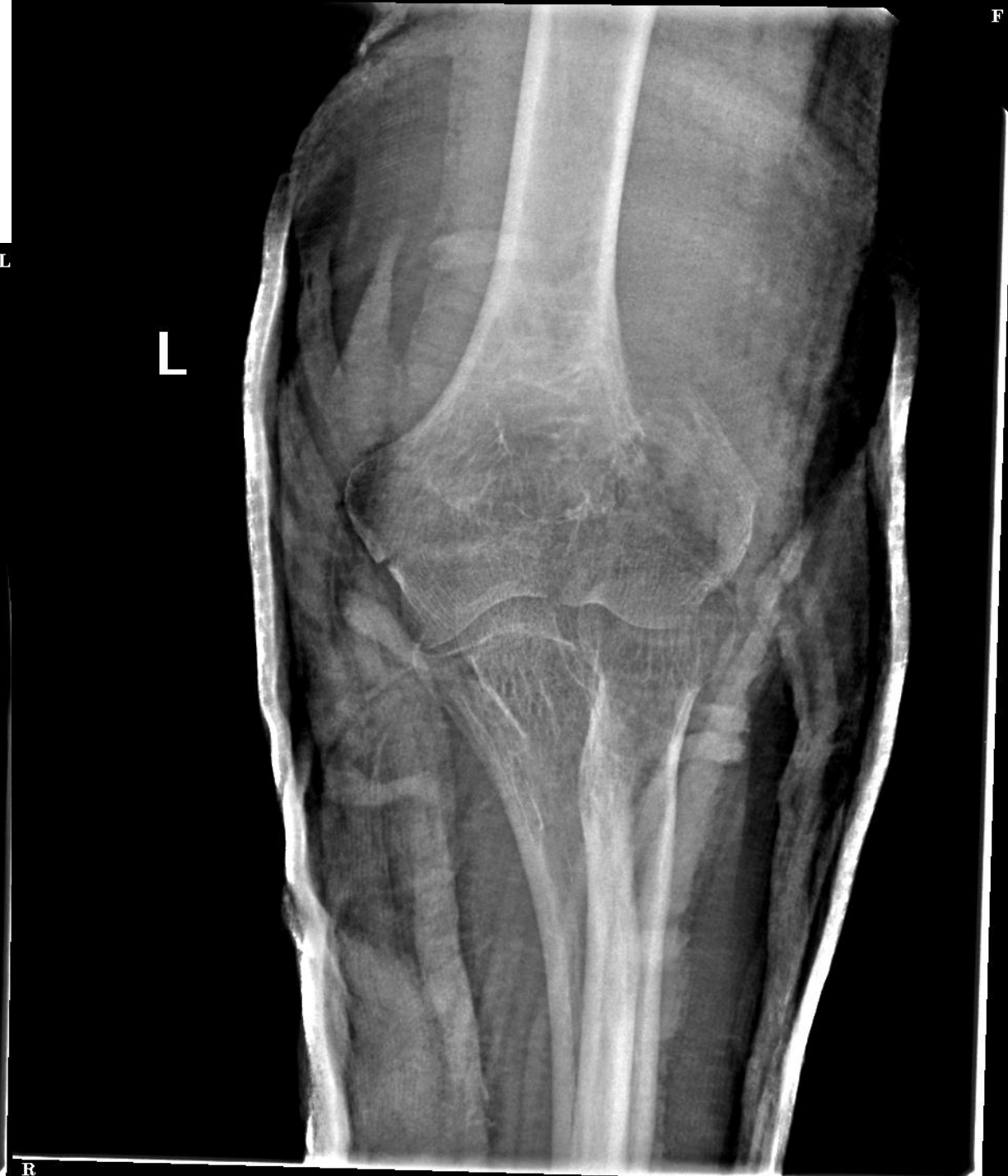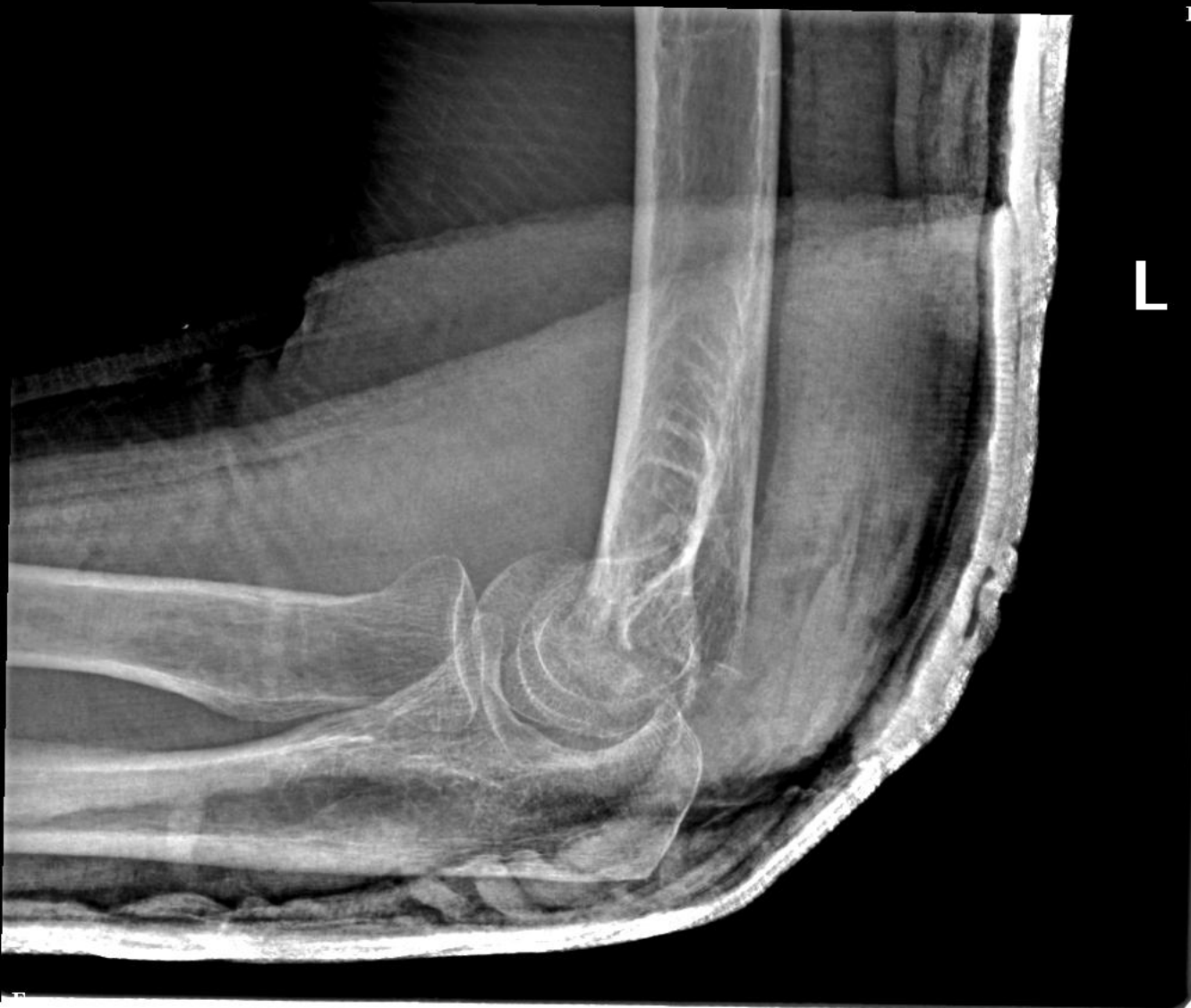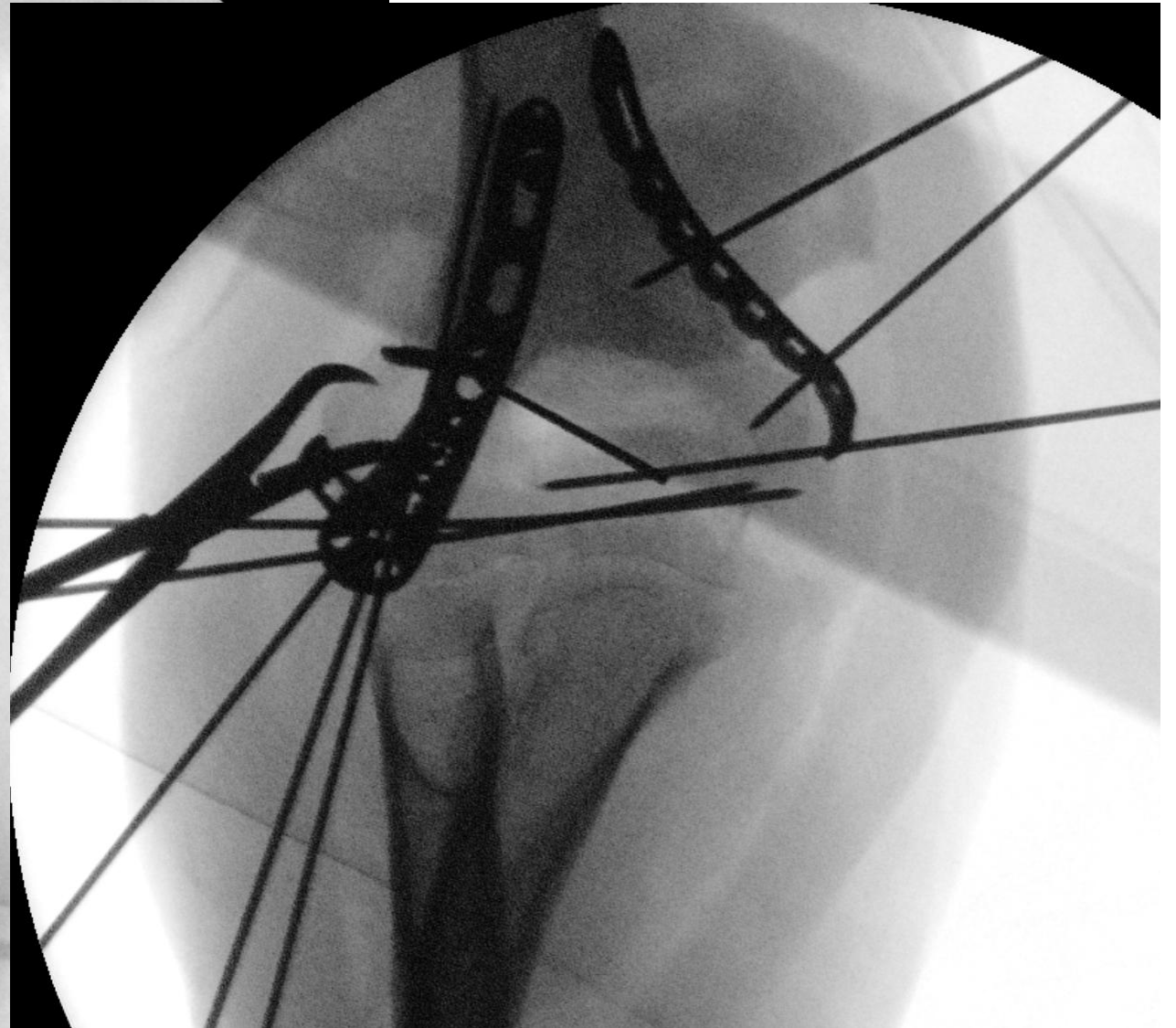
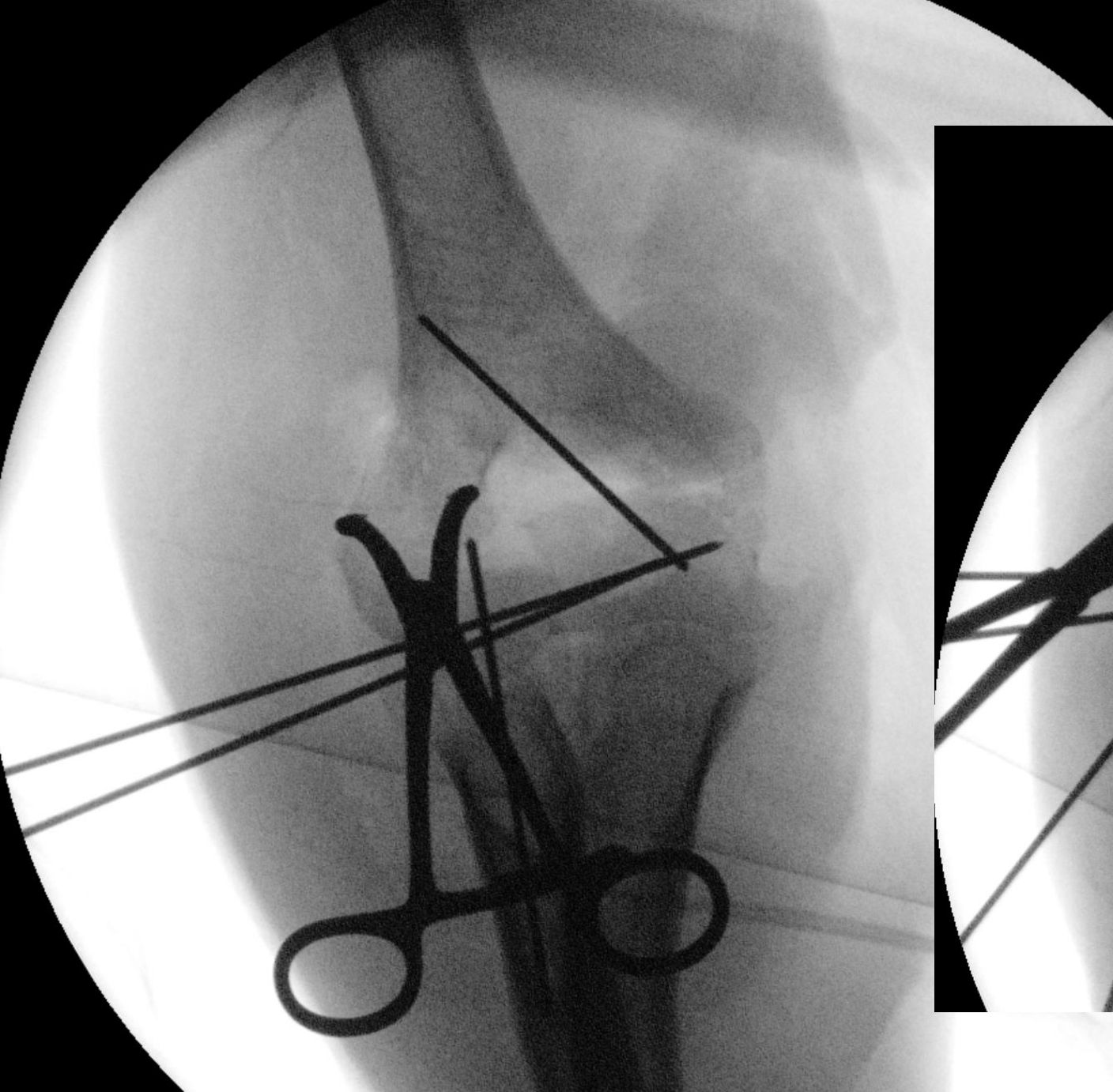
# Elbow Fxs – Distal Humerus

# 71 yo Male - Active

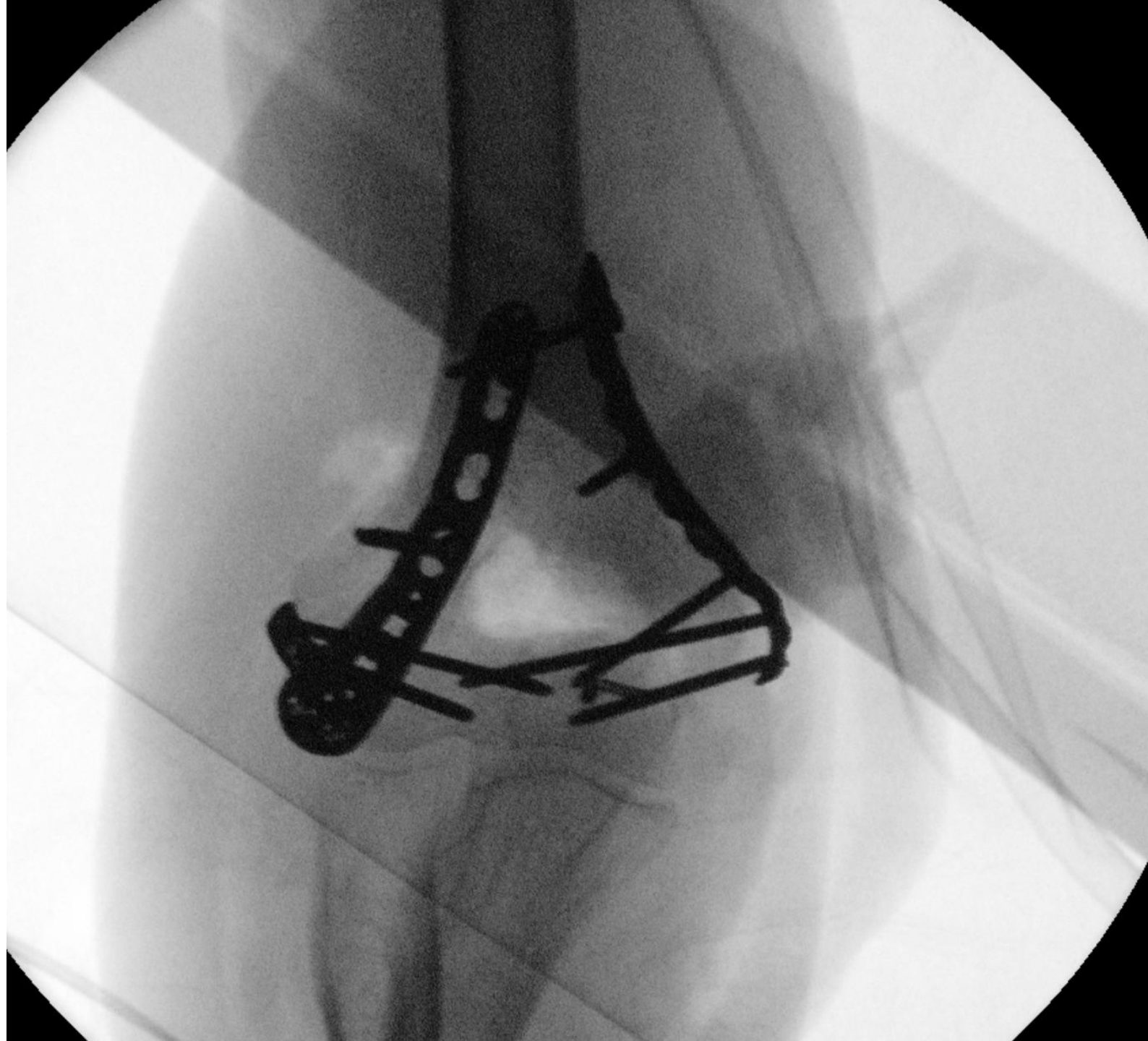


3 weeks later in your  
clinic



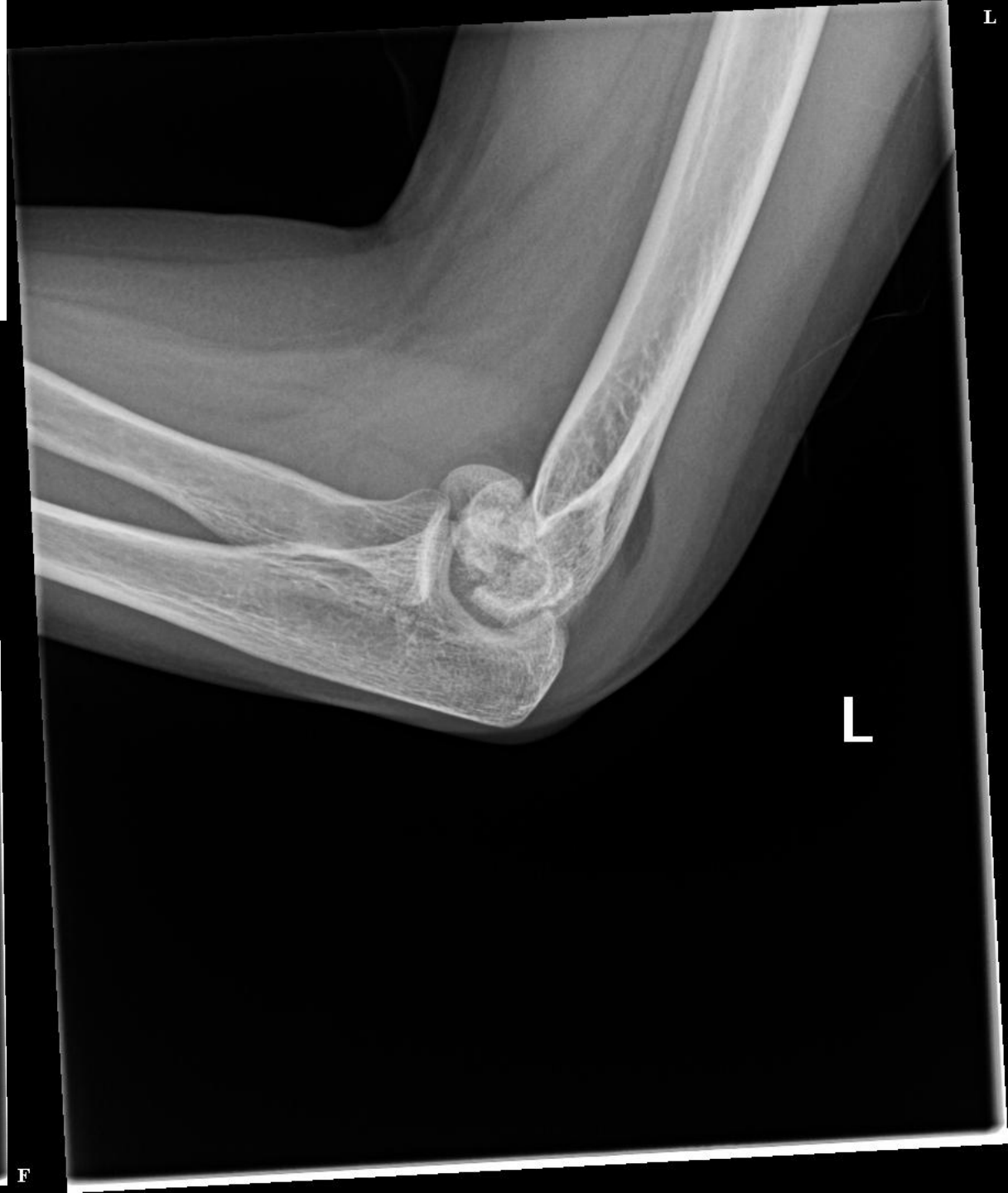
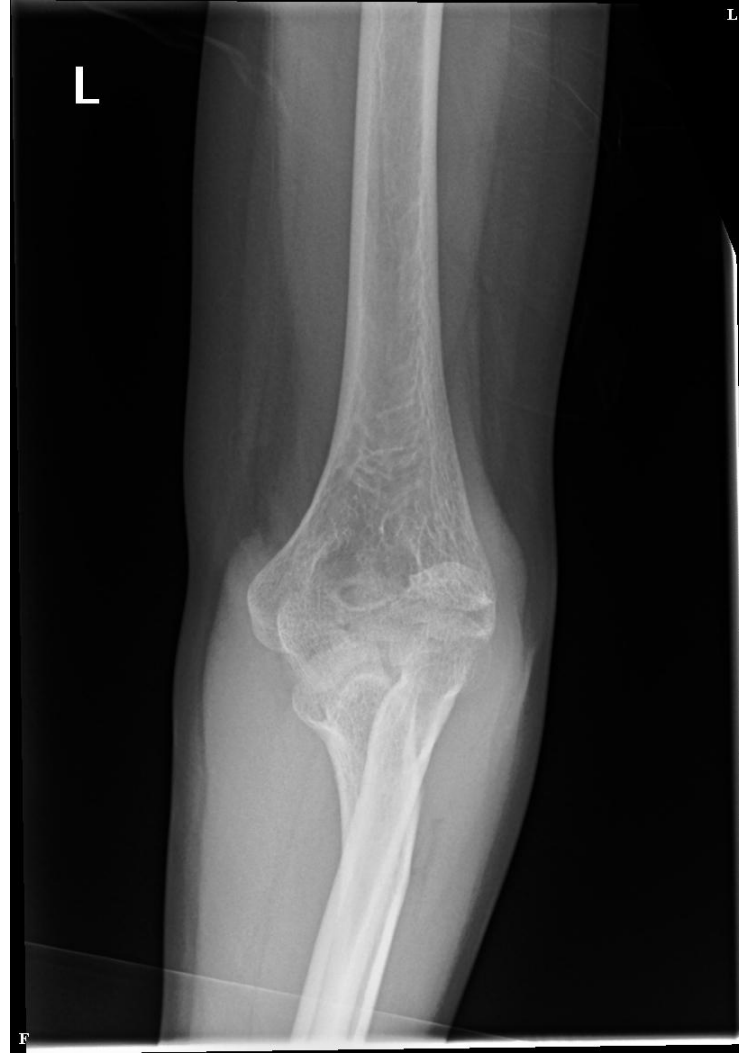
2 year follow up  
10-140  
Full Pro-sup  
playing squash





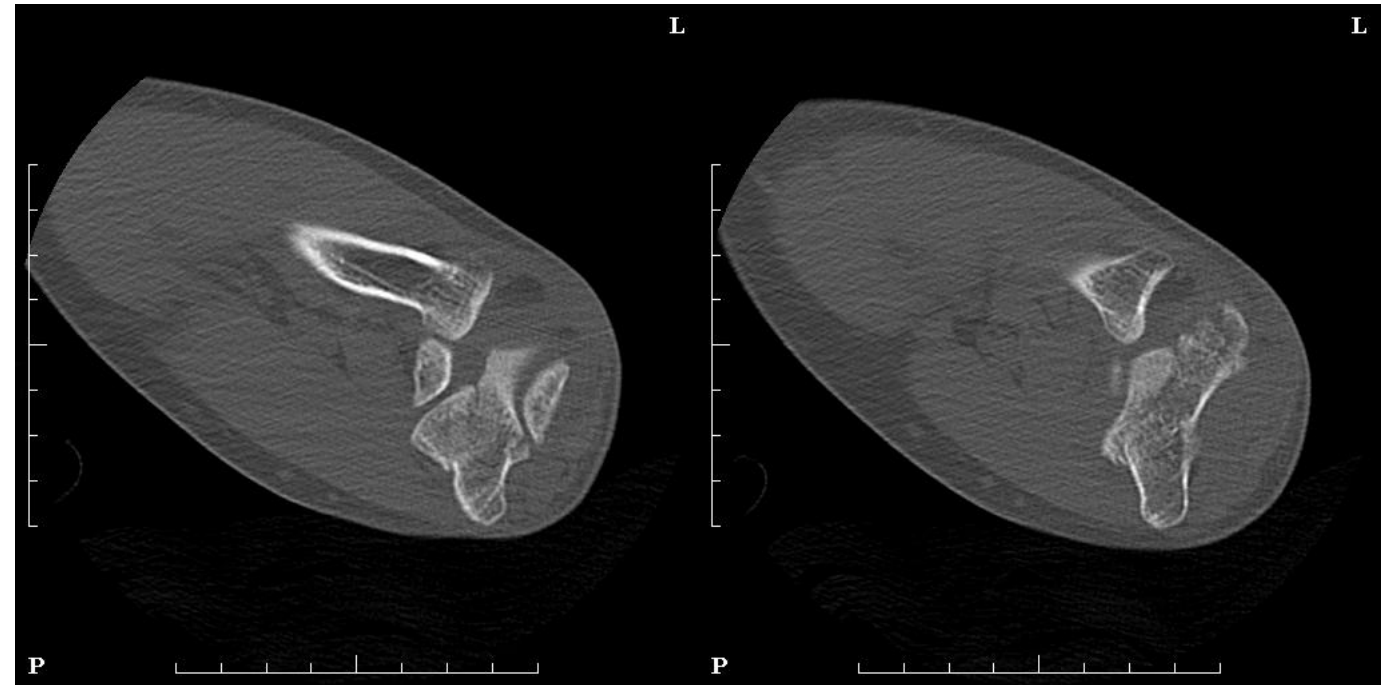
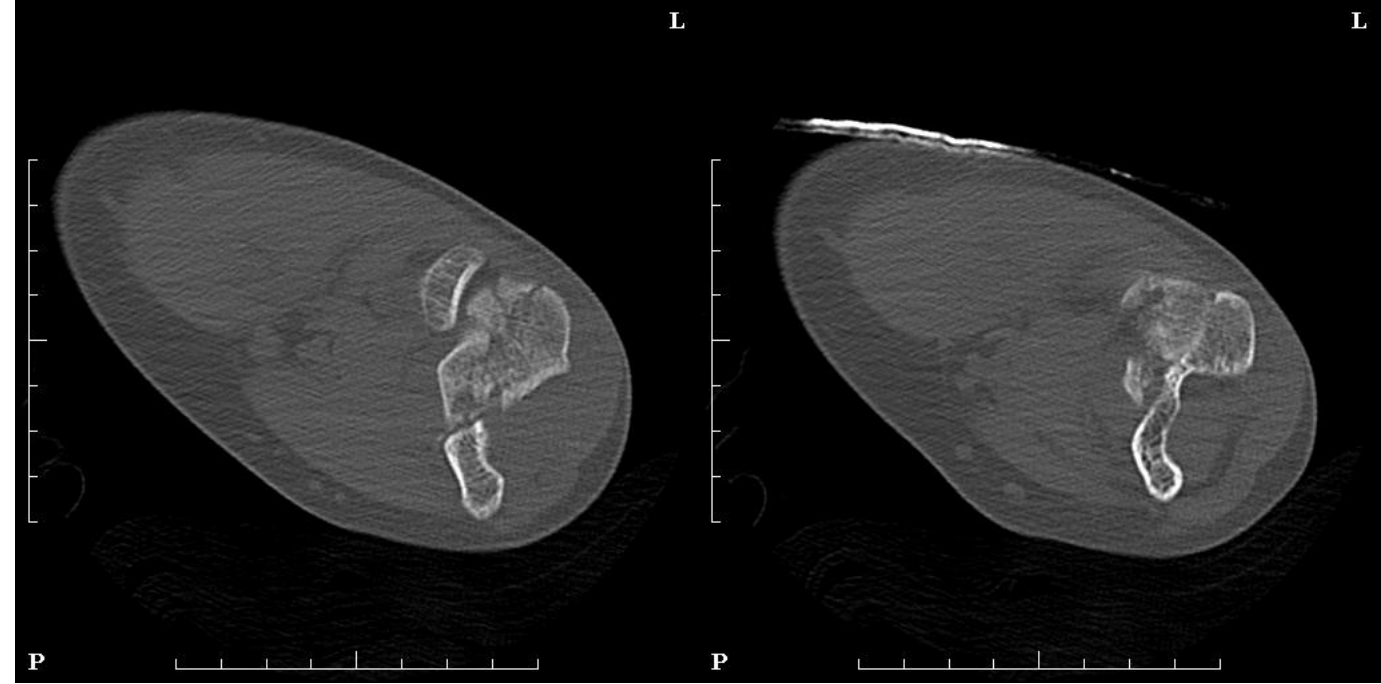
65 yo housewife  
fall from own height  
No bone health workup





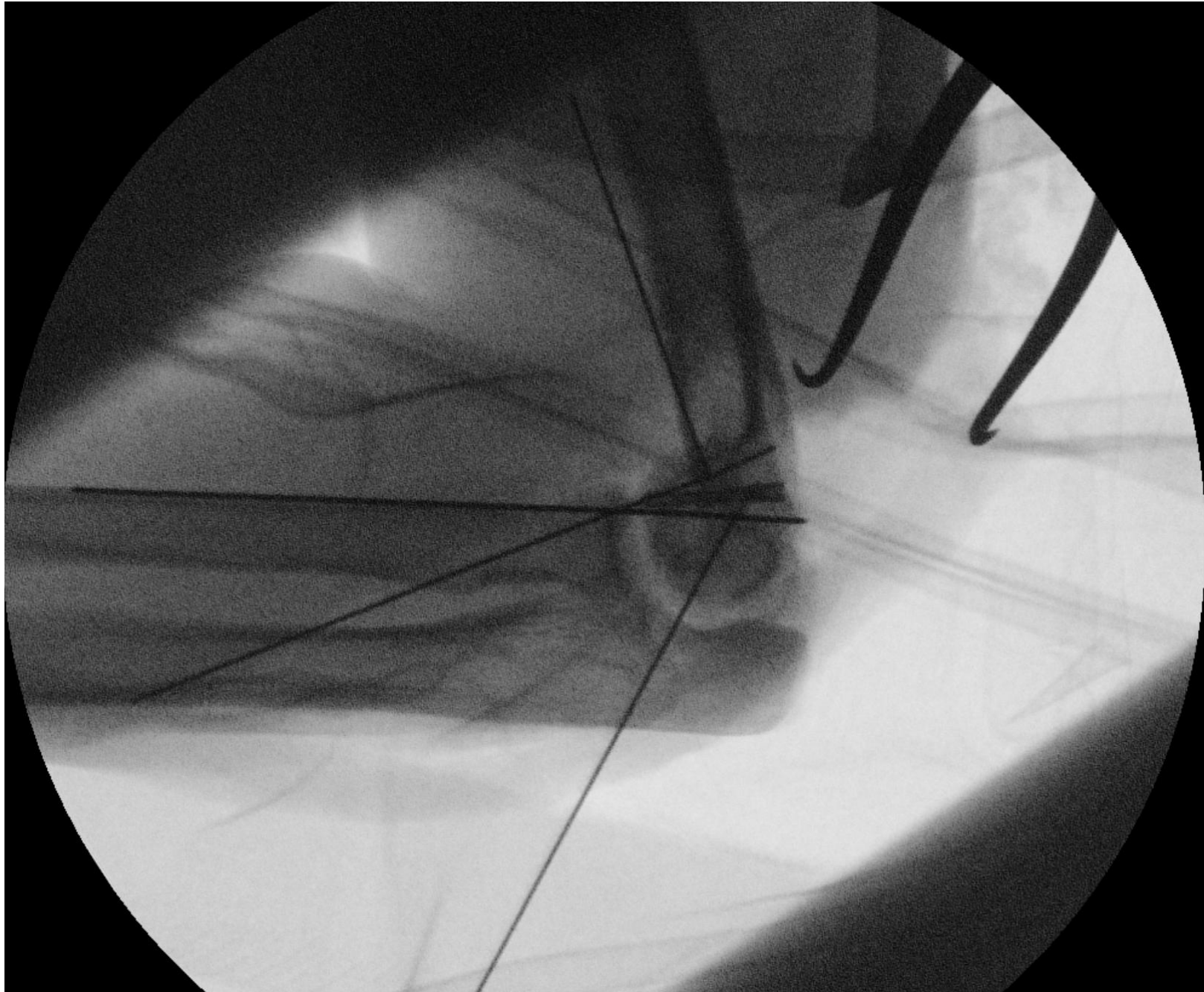
Scans show  
multiple fx lines

Humerus side





Surgery  
Options?  
Approach?



# Other options?

