

# NEUROMUSCULAR DISORDERS

Evaluation.....	217	Presentation .....	228
History .....	217	Spine.....	229
Physical Examination .....	219	Hip.....	230
Management Principles.....	222	Lower Limb .....	230
Cerebral Palsy .....	222	Muscular Dystrophy .....	231
Classification.....	222	Duchenne Muscular Dystrophy .....	231
Medical Considerations .....	223	Myotonic Dystrophy .....	232
Diagnosis .....	223	Facioscapulohumeral Muscular Dystrophy.....	232
Movement Management.....	223	Emery-Dreifuss Muscular Dystrophy.....	232
Spine.....	224	Other Neuromuscular Diseases.....	233
Hip.....	225	Charcot-Marie-Tooth disease .....	233
Lower Limb .....	227	Spinal Muscular Atrophy .....	234
Spina Bifida.....	228	Friedreich Ataxia.....	234
Pathophysiology .....	228	Poliomyelitis .....	234
Natural History .....	228		

Neuromuscular disorders account for the greatest burden of chronic disability in children. Because motor dysfunction is often an early manifestation, the orthopaedic surgeon may be the first to evaluate the child.

Injury to the central nervous system may include several outcomes [A]. The prevalence of neuromuscular disease is evolving [B]. Poliomyelitis has declined due to immunization, and spina bifida has declined due to dietary supplementation with folic acid during pregnancy. Cerebral palsy remains unchanged, in part because advances in obstetrical knowledge and practice are balanced by increased survival of premature infants.

Neuromuscular disorders may be distinguished based upon level of disease [C]. Such a simplified system serves as a basis upon which to organize the approach to complex patients.

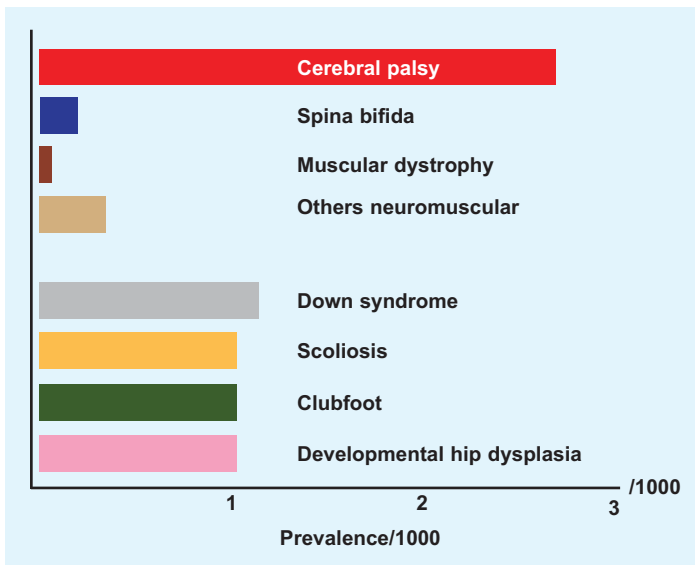
## EVALUATION

### History


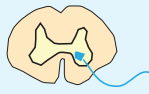


Inquire about pregnancy and birth. Were fetal movements reduced or delayed? Was there perinatal distress? What were the Apgar scores? Was the child premature? What about hospitalizations and procedures? Is the child sufficiently interactive that desires and pain are known? The family is essential to determination of how much a deformity impairs care and hurts the child. Inquire about milestones. Delay in motor development is least variable among patients and most reliable from parents [D]. Early hand dominance is not a sign of advanced development but suggests unilateral loss of function. Initiate a neurologic assessment for walking delayed beyond the 2nd year. In older children with severe delay, absence of independent sitting by 4 years or independent walking by 7 years is prognostic of never walking. Do not underestimate a parent's intuition, which may identify correctly a problem that escapes quantification. For most patients with neuromuscular disease, the diagnosis will be established before orthopaedic consultation.



**A Outcomes of central nervous injury** Most result in cerebral palsy or mental retardation.



B Prevalence of neuromuscular disorders Cerebral palsy is dominant.

	 Brain	 Spinal cord	 Peripheral nerves	 Muscle
<b>Congenital</b>	Cerebral palsy Spina bifida Mental retardation Aneurysm	Diastematomyelia	Insensitivity pain	Congenital myopathy Arthrogyrosis Absent muscles
<b>Degenerative-Inherited</b>		Friedreich ataxia Syringomyelia Spinal muscle atrophy	Hereditary Motor Sensory Neuropathy Herniated disc	Muscular dystrophy Myotonia
<b>Infectious, inflammatory</b>	Meningitis Encephalitis	Poliomyelitis Transverse myelitis Guillain-Barre syndrome		Myositis Collagen disorders Dermatomyositis
<b>Tumor</b>	For example, medulloblastoma	For example astrocytoma	Neurofibromatosis	
<b>Traumatic</b>	Shaken baby Near drowning	Paraplegia	Obstetric palsy	Torticollis
<b>Presentation</b>	Spastic paralysis Hyper-tonicity Hyper-reflexia Sensation: abnormal Primitive reflexes MRI: abnormal	Flaccid paralysis Hypotonicity Hyporeflexia Sensation: abnormal EMG: variable Nerve conduction: normal	Distal weakness Hypotonicity Hyporeflexia Sensation: abnormal Family history +/- Nerve conduction: abnormal	Proximal weakness Hypotonicity Sensation: normal Family history + EMG: abnormal Creatine kinase high

C Neuromuscular disease according to level of disease.

**Physical Examination**

The neural examination includes:

- **Cognition.** Cognitive function is essential to evaluation, management, and outcomes. For example, it may be difficult to determine pain in a cognitively impaired child with cerebral palsy.
- **Motor function.** Assess strength manually and against body weight. In addition to individual muscle groups, a functional assessment is based upon standing and walking ability: standing for demonstration, standing to assist transfer, walking at home, and walking in the community. For walkers, determine total distance as a general measure of function. Assistive devices are not limiting but liberating.
- **Sensory function.** Altered sensation may be direct, due to neural loss, for example, spina bifida, or indirect, due to cognitive loss.
- **Special signs,** for example, a child using the hands to “walk up” the anterior legs and thighs in order to rise from a seated position in the setting of muscle weakness. Divide tone into normal, reduced (hypotone), or increased (hypertone).

**Gait** Evaluate by observation (*cf.* Lower Limb chapter). Gait is divided into stance and swing phases, which overlap for 20% of the normal cycle. Stability during single-limb stance can be limited by cognition, balance, proprioception, coordination, standing posture, bony deformity, contractures, and weakness. Without stability in stance, it is impossible to develop an effective gait pattern. Each swing phase requires clearance of the off-loaded foot to preposition that foot in terminal swing. Ankle equinus, weakness in dorsiflexors, and cospasticity are examples that will prevent clearance and repositioning and lead to an ineffective gait, one with inadequate stride length, poor cadence, or otherwise biomechanically impaired and energy inefficient. Gait also may be assessed in a laboratory, including instrumented motion analysis, dynamic electromyography, pedobarography, and energy consumption test. Include walking and running, which as a stress test will amplify deficit, for example, asymmetry of the limbs in hemiplegia.

There are several morbid gaits [E].

**HIP ABDUCTOR WEAKNESS** This produces a Trendelenburg gait, which is characterized by shifting of the center of mass over the affected joint in stance to eliminate the moment arm. Because the patient has the tendency to fall away from the weak limb in stance, a compensatory mechanism is to raise the walking velocity, thereby reducing time for the effect of gravity, for example, advanced hip deformity.

**HIP EXTENSION WEAKNESS** Walking slows to reduce forward momentum. Lumbar lordosis increases to move center of mass posteriorward. Knee flexion decreases to limit hip flexion, for example, muscular dystrophy.

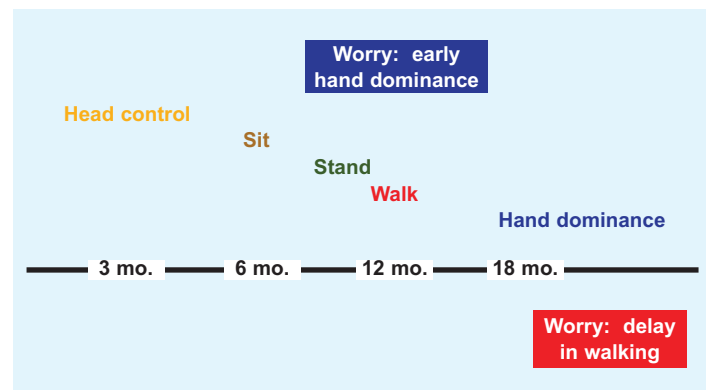
**SCISSORING** Adductor spasticity slows walking velocity and narrows the base of stability, for example, diplegic cerebral palsy.

**QUADRICEPS WEAKNESS** This reduces knee control and is the principal determinant of walking. Body weight flexes the knee, which is counteracted by hip extension, plantar flexion, and locking of the knee in extension. Additionally, the limb may be rotated lateralward to move the force vector medialward away from the sagittal plane, for example, spina bifida.

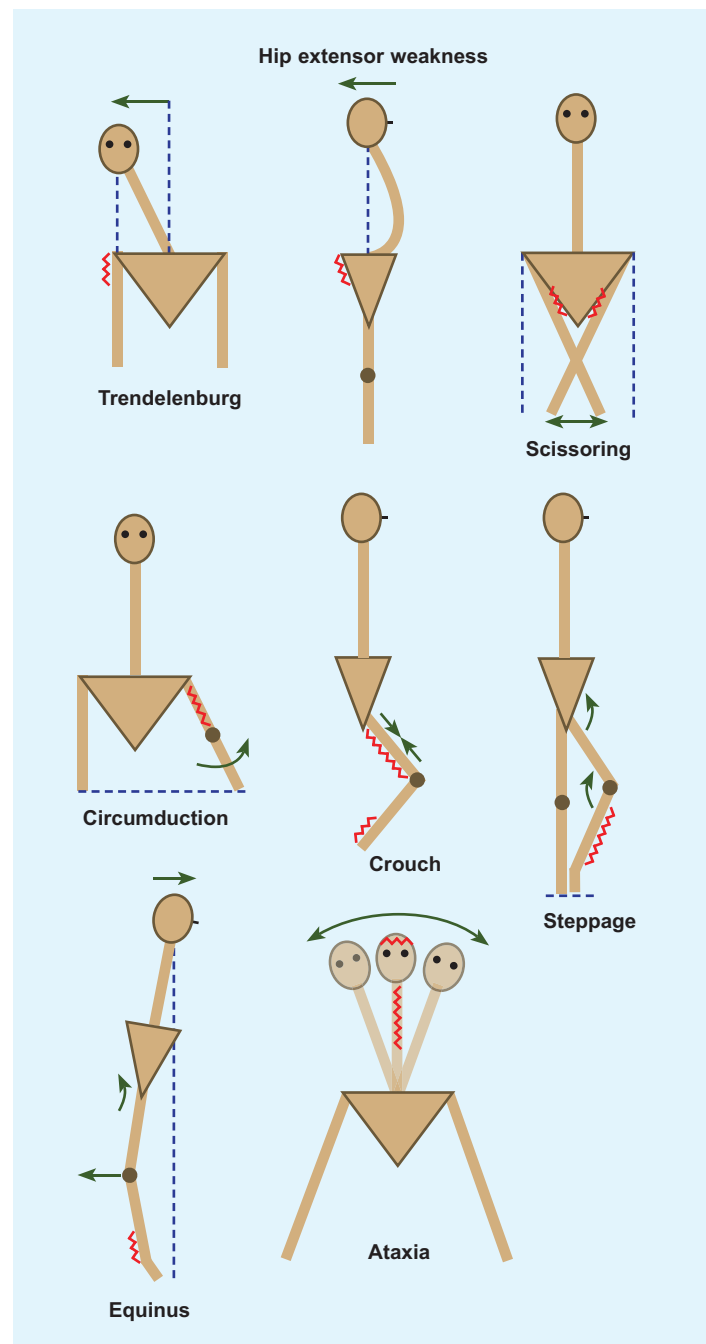
**CIRCUMDUCTION GAIT** Hamstring weakness, or quadriceps contracture or spasticity, reduces knee flexion, which is a major hindrance during swing. The limb is functionally lengthened, necessitating that it be swung outward for the foot to clear the ground.

**CROUCHED GAIT** This may be compensatory to reduced hip extension, due to knee flexion contracture, or a result of triceps suræ weakness. The gait cycle is shortened, there is forward trunk lean to reduce demand on quadriceps, and energy consumption increases, for example, overlengthening of tendo Achillis.

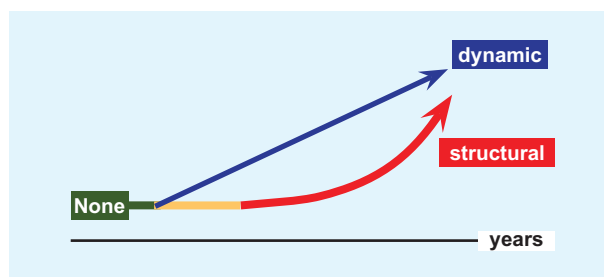
**STEPPAGE GAIT** Anterior crural muscle weakness is compensated for by increasing hip and knee flexion for swing phase toe clearance.



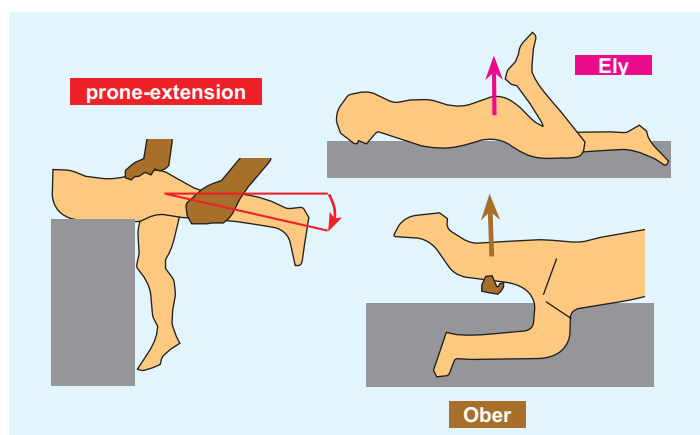
D Select milestones.



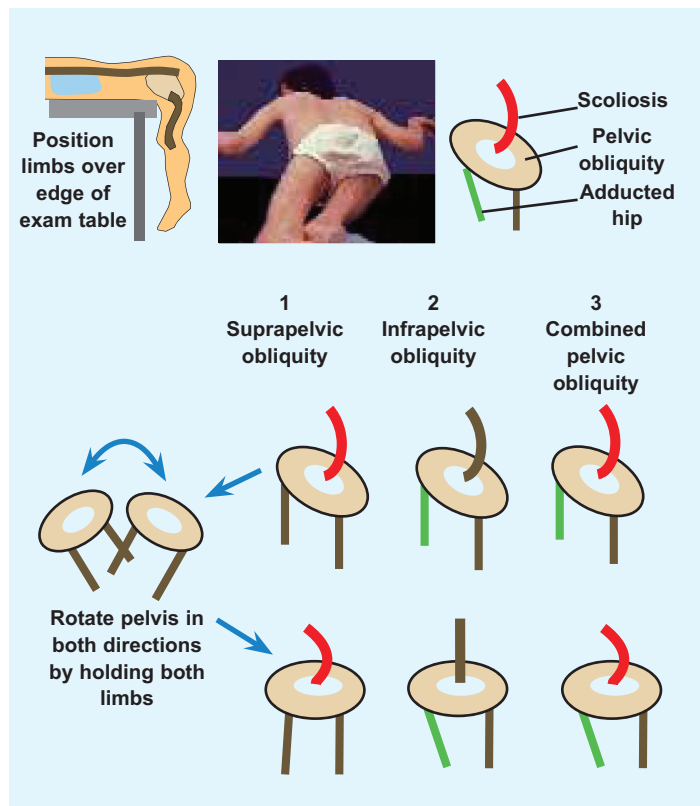
E Abnormal gait Site of disease in red and motion, compensatory and morbid, in green.



**F Effect of time on contracture formation** The orange part of the curve may be lengthened by early intervention such as stretching and bracing.



**G Some contracture tests** These are common tests to assess contractures in cerebral palsy.



**H Pelvic obliquity** Rotate and neutralize the pelvis to unmask a primary spine deformity (red) that persists despite neutral alignment of pelvis and hips or a primary hip deformity (green) that remains despite pelvic and spine position. Combined deformities are present when pelvis rotation has no influence.

**EQUINUS GAIT** Reduced ankle flexion leads to a toe-toe gait, concentrating force at the forefoot during stance. There is reduced flexion or extreme hyperextension of the knee. In the neuromuscular patient, with compromised proximal muscle strength and control, forward translation of the center of mass reduces the effective base of support, thereby reducing stride length, for example, muscular dystrophy.

**HINDFOOT VARUS** This concentrates force over the lateral border of the foot during stance, for example, Charcot-Marie-Tooth disease.

**ATAXIC GAIT** Greek ( $\alpha$ -: “not,”  $\tau\alpha\acute{\xi}\iota\varsigma$ : “precise arrangement”). This is a sign of central nervous disease, for example, in the cerebellum. It is characterized by a broad base, short stride, and titubation due to impaired balance.

The neuromuscular patient must balance benefits against energy consumption of walking. Speed declines first, to maintain energy cost *per* time. However, energy cost *per* distance increases: most patients will select a wheelchair for mobility once this exceeds thrice the normal.

**Deformity** Deformity may be dynamic or static.

**DYNAMIC** This reflects errant neural signaling. It may vary by position, for example, upright posture increases tone that accentuates dynamic deformity. Surgical correction is compensatory and less predictable.

**STRUCTURAL** Dynamic deformity may become fixed or structural with time [F], such as due to spasticity or positioning in wheelchair. Manual interventions before structural deformity sets in, such as stretching and bracing, may delay onset. Sites of contracture include the skin, muscle, and joint capsule or ligaments. Surgical correction is direct, but may be limited by concomitant contracture of neurovascular structures, which would be intolerant of stretch, for example, popliteal artery and tibial nerve behind a flexed knee. With more time, fixed contractures lead to joint deformity and instability, for example, flattening of the head of the femur subluxated against the rim of acetabulum in cerebral palsy.

Deformity may develop even in the setting of hypotonia, for example, scoliosis. Contracture matters when compensatory mechanisms are overwhelmed, thereby interfering with function. Titrate expectations and interventions according to function. For example, a child in a wheelchair has less demand than does an ambulatory child; by contrast, a plantigrade foot is a universal goal.

**HIP FLEXION** This tips the trunk forward, which is compensated for by lumbar hyperlordosis or knee flexion into a crouched gait. Assess this by the prone extension test [G] or by extending the affected hip in the supine position with the opposite hip maximally flexed to eliminate compensatory lumbar lordosis (Thomas). 30 degrees is a guide to release.

**HIP ABDUCTION** Hip abduction is important for perineal access and care. While limitation of abduction <45 degrees is a guide to release, let function be the ultimate guide.

**ILIOTIBIAL TRACT** The patient lies decubitus with affected limb up and with opposite hip and knee flexed. Flex, abduct, and extend the affected hip to bring tract over the trochanter major, where it will be tensioned to prevent the ipsilateral knee from adducting beyond midline under gravity (Ober).

**GRACILIS** In the prone position, abduct the hip with the knee flexed: tensioning the biarticular gracilis by extending the knee causes hip adduction (Phelps).

**RECTUS FEMORIS** This biarticular muscle flexes the hip and extends the knee. In the prone position, flexion of the knee tensions the muscle: contracture is revealed by the elevation of the buttock as the hip is obligatorily flexed (Duncan-Ely). Rectus femoris contracture also may limit knee extension and draw the patella proximalward (alta).

**KNEE FLEXION** Measure this by the popliteal angle. Hip flexion to 90 degrees tensions the hamstrings, thereby exposing contracture as the knee is extended.

**KNEE EXTENSION** Genu recurvatum is abnormal. It may be a direct result of a compensatory mechanism for weakness at the knee.

**EQUINUS** Invert the hindfoot to lock the subtalar joint. Flex and extend the ankle in knee flexion (gastrocnemius relaxed) and knee extension (gastrocnemius tensioned). 10 degrees of flexion allows heel-toe gait.

0 degree allows a plantigrade foot in the nonambulatory. >30 degrees risks crouch gait in the setting of weakness.

**ROTATIONAL PROFILE** This often is abnormal in neuromuscular patients. Medial femoral torsion is a characteristic of cerebral palsy. Lateral tibial torsion is a characteristic of spina bifida.

**PELVIC OBLIQUITY** This may be suprapelvic, originating in the spine, or pelvic, due to hip deformity [H].

**SPINE** Deformity is common in neuromuscular disease. Assess this in the unweighted prone position, upright, and with traction. Pay attention to the skin for signs of decompensation, such as sore, due to limited movement, and for surgical incisions, for example, spina bifida repair.

**Reflexes** Knowledge of reflexes, reactions, and signs is essential to understanding normal and delayed development [I].

**MORO** A startled baby, for example, simulated fall or clapping, abducts and extends all limbs and spine, which may be followed by opposite movement into an embrace [J]. The reflex is lost by 6 months. This aids differentiation of neonatal paralysis, for example, brachial plexopathy, from pseudoparalysis, for example, due to clavicle fracture.

**PLACING REACTION** In the vertical suspension position, the anterior leg is brought into contact with an edge: the normal infant flexes hip, knee, and ankle to surmount the edge and spontaneously extends the lower limb when the sole is planted. The reflex also may be elicited in the upper limb with the dorsal forearm as initial point of contact. This is normal up to 12 months.

**ASYMMETRIC TONIC NECK** Supine and neutral neck. Turn head in one direction then the other: the limbs toward which the head is turned extend while the opposite flex, assuming a “fencer position.” This is lost by 6 months.

**PARACHUTE** Suspend the baby prone by holding the waist. Simulated fall elicits extension of the upper limbs toward and to protect the head. This appears at 6 months and remains.

**EXTENSOR THRUST** In the vertical suspension position, pressing the soles down against a flat surface elicits hip and knee extension for support. This reflex is lost by 6 months. Persistence will interfere with normal reciprocal hip and knee flexion during swing phase.

**VERTICAL SUSPENSION** A baby suspended vertically by the axillae with examiner’s thumbs supporting the neck flexes the hips and knees until 6 months. Extension and scissoring are signs of spasticity.

**PALMAR GRASP** The digits contract to receive an object inserted into the palm, and tone in the entire limb increases as the object is withdrawn. This reflex is lost by 6 months.

**BABINSKI** Plantar stimulation results in extension of the hallux and fanning out of the lesser toes. This reflex is lost by 2 years.

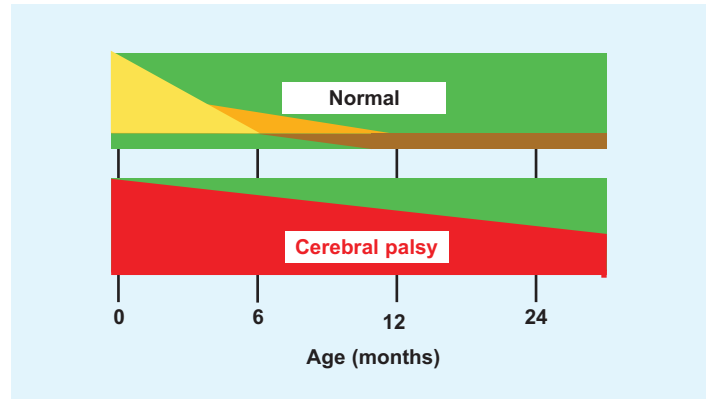
**TONIC LABYRINTHINE** In the supine position, tilting the head backward produces opisthotonos. This reflex is lost by 6 months.

**DEEP TENDON** Corticospinal reflex to acute muscle stretch. Hyperreflexia, including clonus >5 beats, indicates upper motor neuron disease.

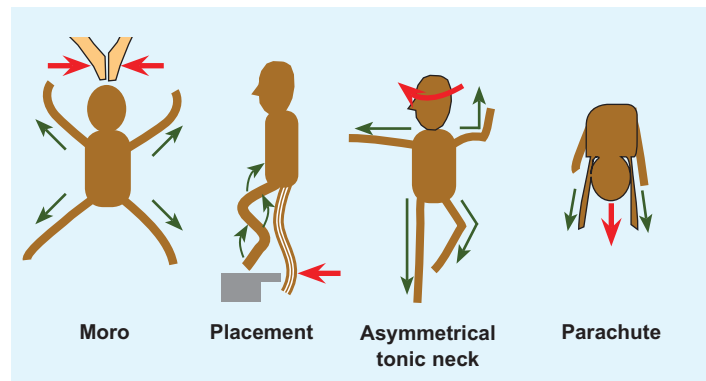
While primitive reflexes aid diagnosis of developmental delay, they also are prognostic: loss of these reflexes by 2 years is predictive of independent walking.

**Imaging**

**MRI** This is the modality of choice for evaluation of the brain. It shows congenital malformations, such as polymicrogyria, heterotopia, and schizencephaly. Other findings in developmental delay include intracranial haemorrhage or ischaemia, periventricular leukomalacia, cystic encephalomalacia and ventriculomegaly. It also allows determination of whether myelination is appropriate for age.



**I Natural history of reactions, patterns, and reflexes.** Most reflexes are lost by 6 months (yellow) and others by 12 months (orange). Persistent primitive reflexes and pathologic patterns represent a delay in development, such as in cerebral palsy (red). Appearance of the parachute reflex (brown) at 6 months and its persistence are normal.



**J Common reflexes.** Provocation in red and response in green.

Study	Value
Total lymphocyte count	> 1500/mm <sup>3</sup>
Albumen	> 3.5 g/dL
Transferrin	> 175 mg/dL

**K Laboratory analysis before operation.** These values are associated with reduced infection rate.

**Laboratory analysis** The diagnosis of neuromuscular disease is typically not dependent upon laboratory analysis.

**CYTOGENETICS** Chromosomal analysis for a genetic disorder.

**INFECTION** Because of the high prevalence in this patient population, tests such as urinalysis often are indicated. Infectious workup also screens the mother for *in utero* exposure.

**NUTRITION** Preoperative assessment may reduce infection rate after major operation, for example, spine fusion for cerebral palsy [K].

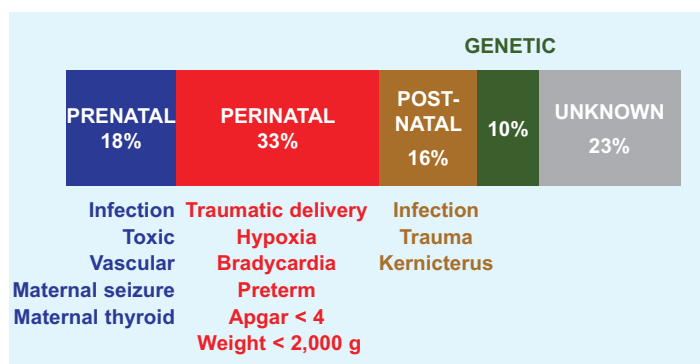
**PULMONARY FUNCTION** Preoperative testing estimates risk of prolonged ventilator dependence after spine fusion in muscular dystrophy.

**ELECTROENCEPHALOGRAPHY** Diagnosis and evaluation of seizure.

**ELECTROMYOGRAPHY AND NERVE CONDUCTION** Diagnosis of muscular dystrophy and neuropathy.



**A Cognitive dissonance** In Aesop's fable, the fox decides that the grapes he cannot reach are not ripe yet but sour, thereby reconciling his desire with his inability to fulfill it. In surgery, this may set into motion a cycle in which family perceives benefit despite equivocal outcomes, which confirms both their and the surgeon's choice of treatment, perpetuating the process.



**A Causes of cerebral palsy.**

Tone		Comment
Pyramidal	Spasticity	Velocity-dependent hypertonicity 80%
Extra-pyramidal	Athetosis	Greek αθετος: "unable to position" Slow, writhing, convoluted
	Choreiform	Greek χορεία: "dance" Sequential, rhythmic, ballistic
	Ataxia	Imbalance, incoordination, tremor
Mixed		Heterogeneity of disease

**B Tonal classification of cerebral palsy** Spasticity is caused by loss of inhibition of the reflex arc. Velocity dependence is manifested by tone that is dependent on the rate of stretch. Spastic patients have hyperreflexia, clonus, and myostatic contracture. Many patients will defy distinct classification. Response to surgical intervention is most predictable in spasticity.

Site	Features
Hemiplegia	Affects half the body in sagittal plane (Greek 'εμι: "half") Focal intracranial haemorrhage or infarct
Diplegia	Affects "both" lower limbs (Latin bis: "both") Periventricular leukomalacia due to vascular insufficiency 3/4 are premature
Tetraplegia	Affects "four" limbs (Greek τετραρες: "four") Variable cognitive dysfunction, including total involvement characterized by diffuse brain disease.
Monoplegia	Rare
Mixed	For example, asymmetric diplegia, double hemiplegia

**C Geographic classification of cerebral palsy.**

## MANAGEMENT PRINCIPLES

Balance the burden of disease with the morbidity of intervention. Orthopaedic care addresses the downstream effects of a primary disease that it cannot cure. Prioritize function over deformity: "normal" is unrealistic and unattainable. Prioritize communication, independence, and mobility over walking.

Appreciate the significance of sensation and perceptive disabilities. Terms such as "spasticity" and "plegia" do not acknowledge sensory impairment in cerebral palsy.

Account for all costs: pecuniary, social, and familial. Think of the family as a computer: running too many and incompatible programs may crash it.

Beware of cognitive dissonance. This describes the tension that results from attempting to reconcile two contradictory beliefs or realities, a tension that may be relieved by changing one of the two to be consistent with the other. To parents and caregivers with high expectations before operation, a poor or even fair outcome may be dissonant whereas a good outcome will be harmonious. This may explain how a positive subjective outcome is not contradicted by a negative objective outcome. An understanding of cognitive dissonance may bridge the divide between family expectations and surgeon restraint.

Recognize that natural history may be harnessed when favorable, such as in nonprogressive conditions or those with spontaneous improvement, yet it can be an obdurate force against influence, hence the failure to preserve walking despite the best intentions and surgical interventions.

Adhere to the proof razor: the burden of proof lies with one who makes a claim and not with one challenged by it. Exhaustive and exhausting remedies, foisted upon vulnerable families, may be rejected absent evidence. Do not be dogmatic: absence of proof is not proof of absence. Alternative remedies are acceptable when they do not harm the child or family; when they do not delay, interrupt, or otherwise interfere with proven treatments; and when there are no other effective options. Recognize the ethical limitations of caregivers consenting to high-risk procedures on behalf of a cognitively impaired patient. Be mindful of the ethical imperative *primum non nocere*: "first do no harm."

## CEREBRAL PALSYP

The name describes motor dysfunction caused by a disease of the brain. The suffix -plegia is derived from Greek πλῆγη: "a blow, stroke," used by Hippocrates to describe "paralysis" resulting from being struck by disease. While it is referred to as static encephalopathy, in recognition of a defined insult resulting in a stable brain disorder, the musculoskeletal consequences are progressive. It also is known as Little disease, after the English physician W. J. Little (1810–1894), who championed tenotomy (having undergone the procedure himself) and who attributed the disease to difficult pregnancy, premature birth, and neonatal asphyxia.

The appellation encompasses a group of disorders resulting from pre- and perinatal brain insult as well as postnatal causes such as near drowning and traumatic brain injury [A]. 1/4 walk independently, 1/2 have capacity with walking aids, and 1/4 do not walk.

### Classification

The disorder is classified according to tone [B] and geographically [C]. Pyramidal pathways (in particular corticospinal) directly continue to the motor neurons of the spinal cord. The extrapyramidal system, including the basal ganglia and cerebellum, indirectly modulates motor function. A lesion in this system results in "dyskinetic" movements, characterized by abnormalities in control, posture, and timing. The geographic classification correlates with timing and mechanism of brain injury [D]. For example, the basis for prematurity as a risk factor is incomplete development of the cerebrum. Vasculature, resulting in hypoperfusion to the periventricular white matter, the region most susceptible to injury

because it is a watershed zone between striate and thalamic arterial systems. These areas carry fibers responsible for lower limb motor function, manifesting as spastic diplegia. Geographic subtypes have several characteristics [E]. A final component of classification is the Gross Motor Function Classification System [F].

**Medical Considerations**

Multiple comorbidities beyond the musculoskeletal system impact decision making and outcomes.

**Cognition** Half of patients with cerebral palsy have cognitive impairment. This correlates with severity. It is exacerbated by dysarthria, which impedes expression of intellectual capacity.

**Skin** Hygiene is difficult, impeded by contracture, and dependent on caregivers. Skeletal distortion without the ability to accommodate due to movement restriction may lead to decompensation such as decubitus ulcer.

**Gastrointestinal** Poor oromotor control has several consequences:

- Failure to thrive due to feeding and swallowing difficulty. Patients may require gastrostomy or jejunostomy to augment nutrition. Low weight is the greater concern, by contrast with spina bifida, where overweight challenges function.
- Gastroesophageal reflux and associated aspiration pneumonia.
- Constipation.

**Teeth** Dental caries, enamel dysgenesis, and malocclusion.

**Respiratory** Aspiration pneumonia due to oromotor dysfunction and seizure. Motor dysfunction impairs cough. Reduced mobility reduces mechanical factors that aid lung inflation. Prolonged recumbency after operation adds risk.

**Seizure** 1/3 of patients have epilepsy, a direct result of brain insult. This correlates with extent of involvement, increasing with cognitive impairment and tetraplegia.

**Visual** Visual field defects due to cortical injury. Premature infants may develop retinopathy.

**Hearing** Loss is seen in patients with history of kernicterus.

**Diagnosis**

Presentation demonstrates a temporal evolution:

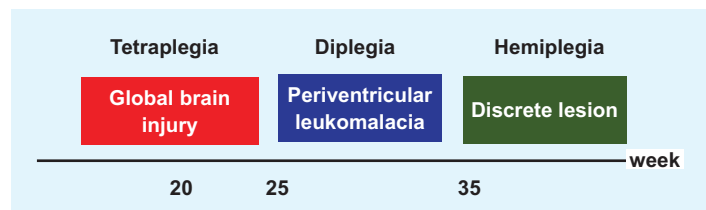
- At birth, if risk factors are recognized in mother, such as toxic or infectious exposure, or in child, such as asphyxia or prematurity.
- In the first few months for tone abnormality, hypotonia precedes hypertonia. Failure to thrive also may manifest in this period.
- In the first couple of years for abnormal developmental milestones, such as delayed walking and premature hand dominance. Milestones are delayed but not lost: regression suggests a hereditary neurodegenerative disease rather than cerebral palsy.

**Movement Management**

This may be focal, to address local or segmental spasticity, or it may be generalized.

**Botulinum toxin** This neurotoxin, produced by the Gram-positive anaerobic rod *Clostridium botulinum* (Latin botulus: "sausage," after poisoning from contamination), binds to motor nerve terminals where it cleaves SNARE proteins to inhibit release of acetylcholine. It first was used to treat strabismus. It is injected into the skeletal muscle to produce a dose-dependent reversible paresis to overcome spasticity and potentiate manual lengthening. Needle placement may be determined anatomically or aided by ultrasonogramme or electromyography.

Botulinum toxin may be administered therapeutically or diagnostically. It is most effective in the lower limb, in particular triceps surae in combination with casting for equinus. Other applications include the hip adductors for scissoring, to reduce subluxation of femoral head, and to facilitate perineal care, the rectus femoris to alleviate stiff knee gait, and the upper limb for flexion deformities of elbow and wrist. It may serve as



**D Timing of brain insult** Although correlations are imprecise, the earlier the event during gestation, the greater the injury.

Features	Hemiplegia	Diplegia	Tetraplegia
<b>Disability</b>	Mild	Moderate	Severe
<b>Feet</b>	Equinovarus, equinovalgus		
<b>Knees</b>	Mild	Moderate	Severe
<b>Hips</b>	OK	Subluxation	Dislocation
<b>Spine</b>	OK	OK	Scoliosis
<b>Upper Limbs</b>	Variable	Little	Major
<b>Seizure</b>	Common	Rare	Common
<b>Walking</b>	Yes	Variable	No



**E Characteristics of geographic subtypes** *Boy with a clubfoot* by Jusepe de Ribera (1591–1652) is a vivid depiction of hemiplegia. The boy stands in equinus, with the forearm pronated and the wrist and fingers flexed.

Level	Function
<b>I</b>	Walking: without limitation. Running and jumping. Decreased speed, balance, coordination
<b>II</b>	Walking: with limitation For example, railing for stairs. Difficulty on uneven surface or interactive environment
<b>III</b>	Walking: at home with hand-held mobility device Community: wheel-chair.
<b>IV</b>	Does not walk. Stands to transfer. Supported sitting. Wheel-chair for mobility.
<b>V</b>	Global impairment. Unable to independently walk, stand or sit: requires transportation

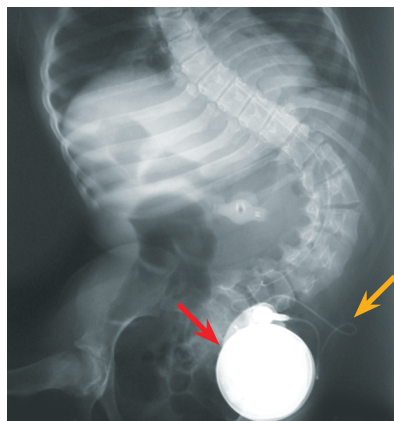
**F Gross Motor Function Classification System** Because it measures self-initiated movement and ability, this is a functional assessment, as opposed to systems that describe type of movement or part of body affected. It consists of 66 measures of sitting (truncal control) and walking ability, subdivided according to age.

an adjunct to preoperative assessment of tendon lengthening, providing a reversible preview of the operative effect. Because it blocks dynamic muscle activation, it is not effective for fixed contracture.

Maximum dose of botulinum toxin is 20 U/kg, distributed as 2 U/kg in small muscles and 6 U/kg in large muscles, and 600 U total. Maximal effect is seen in 1 to 2 weeks. Duration of effect is 3 to 6 months; redosing should be no more frequent, in order to avoid immunity.

**Phenol** This also is known as carbolic acid, after its discovery from coal tar. It was the agent used by the Scottish surgeon Sir Joseph Lister (1827–1912) to clean wounds and soak bandages in his development of antisepsis. It targets a major motor nerve directly (rather than diffusing over muscle endings), which is identified with a nerve stimulator under general anaesthesia. It is most effective for musculocutaneous nerve to improve extension of the elbow and obturator nerve to improve hip abduction.

**Baclofen** This activates GABAB receptor, opening potassium channels and closing sodium and calcium channels, thereby blocking neurotransmitter release and muscular contraction. It is indicated for generalized movement disorder. It may be administered *per orem* or via a pump placed in the anterior abdominal wall connected by a catheter with the subarachnoid space at a level in the spine determined by how much upper limb effect is desired [G]. The intrathecal route allows better control of dose and limits side effects. The pump is refilled every month and replaced once batteries are spent.

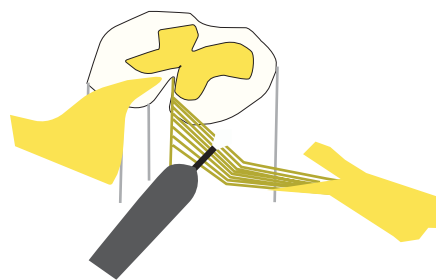


**G Intrathecal baclofen** Pump is implanted in the anterior abdominal wall (red), and catheter leads to subarachnoid space in lumbar spine (orange).

**Rhizotomy** This refers to “cutting” (Greek *τομή*) of dorsal nerve “roots” (Greek *ρίζα*). The rationale is section of afferents to counteract loss of descending central nervous system inhibition of spinal cord stretch reflex [H]. The procedure consists of:

- L1–S2 laminoplasty. This gives access to the cauda equina while potentially reducing the development of postoperative spinal deformity, including hyperlordosis, spondylolisthesis, and scoliosis.
- Dorsal nerves are divided into rootlets that are stimulated to threshold using intraoperative electromyography, including external anal sphincter. Rootlets selected for section are those demonstrating abnormal response ( $\geq 2$  muscles having a titanic or crescendo pattern), which typically represents 1/3 of the total.


Vigorous postoperative physical therapy is necessary to overcome associated weakness. Controversy surrounding this procedure is due in large measure to lack of strict criteria for patient selection. The ideal candidate is a 4- to 8-year diplegic who is cognitively spared and ambulatory. The child is intelligent and old enough to succeed with postoperative therapy, but young enough to have few if any permanent contractures. Furthermore, in patients who harness spasticity to stand or walk, underlying weakness may be exposed by rhizotomy. Even though the procedure improves range of motion and function in the lower limbs, orthopaedic procedures are required in more than half of cases. Postoperative spinal deformity typically is self-limited, rarely requiring active management.



**H Dorsal rhizotomy** Afferent fibers in dorsal roots are sectioned to decrease spasticity.

### Spine

Development of scoliosis correlates disease severity: 2/3 of tetraplegics are affected, hemiplegics rarely [I].



**I Deformity correlates with disease severity** Consider doing more for less: exercise restraint in the totally involved child, where risk may outweigh benefits in the setting of severe deformity and reduced demands.

These curves differ from idiopathic scoliosis:

- Onset is earlier, typically first decade.
- Increased likelihood and magnitude of progression.
- Bracing does not alter natural history.

Thoracic scoliosis may impact pulmonary function. Lumbar lordosis influences posture, including the need for assistive device to sit and engagement of the upper limbs for truncal support. It also may aggravate gastrointestinal dysfunction, such as constipation and swallowing. Deformity, including pelvic obliquity, with limited compensatory mechanisms risks overlying skin and soft tissues and may hurt.

**Evaluation** Disability may be difficult to determine in the cognitively impaired. Ask family and third parties about burden of care, such as ability to sit and feed. Assess flexibility of curve by comparing magnitude upright, supine, and with traction. Check the skin for any lesion that might increase infection risk. Refer to a nutritionist or abdominal surgeon for failure to thrive.

**IMAGING** Follow general principles (*cf.* Spine chapter), including traction views for flexibility since many patients may not be able to cooperate fully when asked to bend in the sagittal plain. Specialized modalities may be necessary in severe deformity.

**LABORATORY EVALUATION** This includes measures of infection and nutrition. There is no consensus on pulmonary function testing for cerebral palsy.

**Management** Outcomes are based more upon caregivers than upon the patient. They tend to be subjective, for example, sitting in a wheelchair is facilitated, more than objective. Objective measures, which might include such postoperative hospitalization, treatment of pneumonia, use of analgesics, rate or size of decubitus ulcer, have eluded demonstrated improvement.

Observe the relaxed, unweighted spine: this will buy time for the early-onset patient. Modify a wheelchair and consider an orthotic.



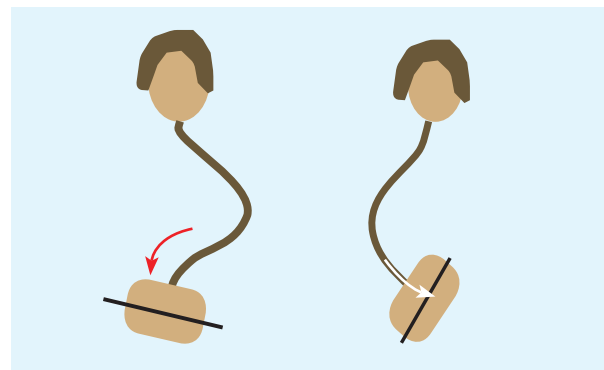
For postural support. Indications for surgical treatment follow general rules: >10 years of age with progressive curve >50 degrees. There are several special considerations:

- Infection rate approaches 10%. Contributing factors include the burden of chronic disease, malnourishment, multiple procedures and hospitalizations that result in polymicrobial colonization and may disturb the soft tissue envelope on the trunk, complex procedures with prolonged wound exposure, and impaired cognition and global involvement that interferes with aftercare. Addition of antibiotic powder directly to the wound after final irrigation may reduce the infection rate in such high-risk patients.
- Pelvis. Establish whether an oblique pelvis is part of the structural curve, acting like a spinal segment in continuity with the scoliosis, or is independent, based upon orientation and flexibility testing on physical examination and röntgenogramme [J]. To include the pelvis in a spine fusion may be debated [K]. If flexible, sparing it reduces operative time, blood loss, and risk of pseudarthrosis (highest at the lumbosacral junction) and preserves flexibility that may be of value for positioning. That such flexibility improves walking ability is unproven. Including it avoids a subsequent operation to extend the fusion in a curve type known for progression and a patient population that is fragile. Differentiate pelvic obliquity due to hip disease. There is no rule for whether spine deformity or hip deformity takes precedence for correction.
- Fusions tend to be long. Follow-up operations after the index may not be feasible. Spared curves are unpredictable. The benefits of preserving mobility are outweighed by the morbidity of a secondary operation.
- Blood loss. This is high in an ill patient who presents with anaemia of chronic disease and who has depleted reserves upon which to draw. This may be reduced by the use of antifibrinolytic agents such as tranexamic acid.
- Anterior procedure. Avoid this in a patient who has baseline pulmonary decline and a high-risk profile. Have realistic and reasonable goals: a stable spine with head balanced on pelvis does not need to be straight. Do not add to the morbidity of the procedure.
- Tissue quality. Patients may have a thin soft tissue envelope to cover prominent implants, increasing the risk of breakdown. Be mindful of the axiom: “the soft tissue is hard and the bone is soft.” Osteopenia reduces implant stability, while contractures can be unyielding. Exercise restraint during spinal reduction.
- Complications are many [L]. Synchronize incentives and expectations, and educate and keep the family actively involved from the outset.
- Resource utilization. Spine fusion for neuromuscular patients taxes facility, such as intensive care unit, and health care providers, including other consultant physicians and therapists.

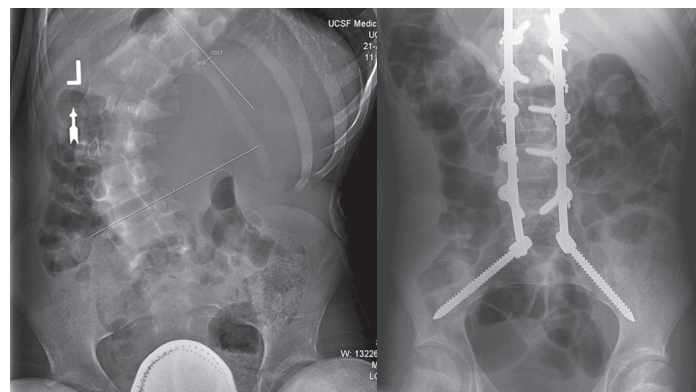
**Hip**

Like the spine, acquired deformity of the hip correlates with severity of disease, affecting more than half of tetraplegics. It is a manifestation of asymmetric neuromuscular control that does allow the hip to remain centered and is exacerbated by medial femoral torsion that twists the head of femur out the front of the acetabulum.

**Evaluation** Monitor the hip with serial röntgenogrammes, because subtle changes may not be perceptible manually and because the earlier dysplasia is detected the simpler the treatment. Limited hip abduction (<45 degrees) due to hypertonia of adductors is an at-risk sign. Ask the family if there is pain or other difficulty with perineal care. This may not be evaluable during a limited consultation.



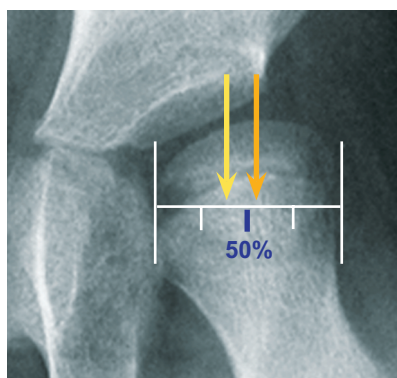
**J Pelvic obliquity in neuromuscular scoliosis** Both pelves are oblique. One (red) is not part of the structural C-shaped curve, as evidenced by opposite deflection, even though there is not enough spine remaining for the pelvis to return to horizontal. The other (white) is part of the curve, which continues into a pelvis that acts like a scoliotic spinal segment.



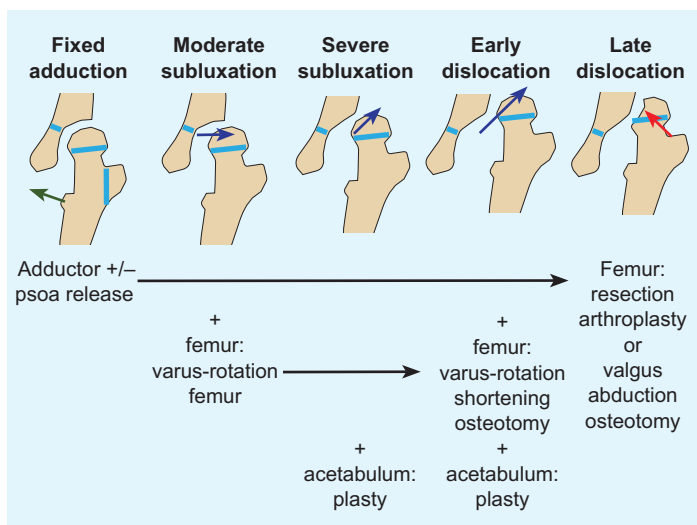
**K Spine fusion for cerebral palsy** The pelvis was included in a nonambulatory patient to reduce risk of secondary operation. Because the lumbosacral junction is at greatest risk of pseudarthrosis, the pelvis was rigidly fixed with S1 and S2 iliac screws. Simple AO screws in pedicles attached to a unit rod via wires looped through washers provide stability, allow gradual correction by creep, stay out of the canal to reduce haemorrhage and permit unrestricted laminar decortication and are cost-effective.

Complication	Factors
Pain and regression	Proportional to extent of operation Cause unknown Minimize duration by upright positioning, early and active therapy, reduced immobilization Partial loss may be permanent for example, marginal walker before operation does not walk after operation
Infection	Multifactorial, including chronic disease Malnutrition Complex disease requiring prolonged procedures Impaired movement and cognition
Decubitus ulcer	Impaired movement and cognition Unclear communication Sensory disturbance Use of casts and braces
Aspiration pneumonia	Oromotor dysfunction Reduced movement Prolonged recumbency

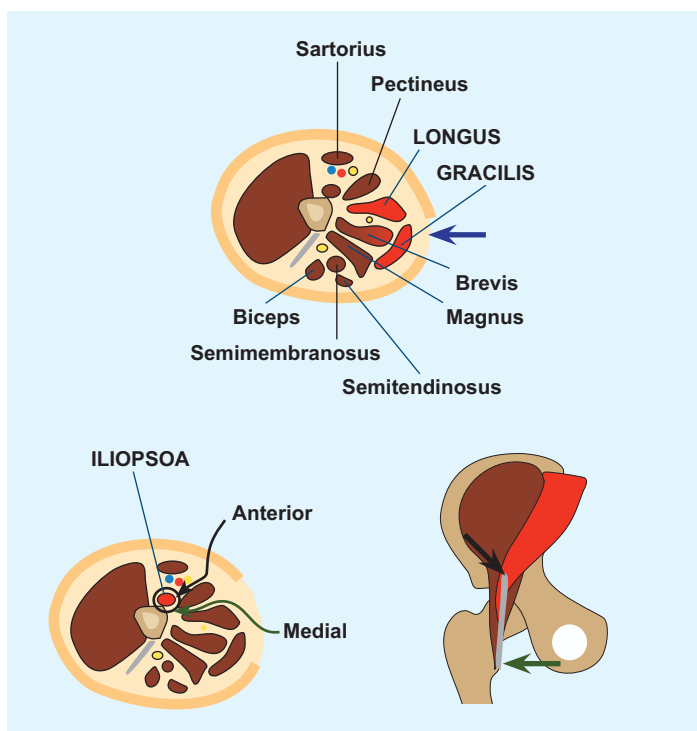
**L Select complications after spine surgery for cerebral palsy** These are common to all big surgery.



**M Hip migration index**  
Measurement error results from determination of where articular surface ends (yellow) versus edge of ilium on a two-dimensional image (orange). Note valgus orientation of the neck of femur, exaggerated by medial torsion.



**N Management of neuromuscular hip dysplasia** Hip deformity in cerebral palsy tends to be progressive, as is reconstruction. Begin with contracture release (green), follow by reconstruction osteotomy (blue), and end with ablation (red).



**O Management of neuromuscular hip dysplasia** Adductor release is performed through a medial incision (blue). Iliopsoa may be released through a medial (green) or anterior (black) incision.

**Management** Several factors influence management. The natural history is variable. There may be progression of subluxation to dislocation and of deformity from femur, for example, conoid epiphysis, to acetabulum, that is, obliquity, to degenerative joint disease. Risk of progression is related to the severity of involvement and walking ability. The gross motor function classification system is most predictive of progression. Progression often is silent, hence the importance of surveillance röntgenogrammes of at-risk hips. If pain arises, it is worst for subluxation: half of dislocated hips are asymptomatic. Intervention in the young child depends upon function, of which the ultimate level often is unknown, and later in childhood pain, of which again the level may be unclear. A proactive rather than reactive strategy is predicated on the recognition that outcomes of reconstruction of a good hip are better than salvage of a bad hip.

In contrast with developmental dysplasia, the hip in cerebral palsy is normal at birth and later becomes deformed by a combination of delayed walking and neuromuscular imbalance. There is a frameshift delay in the temporal schedule of operative treatment compared with developmental dysplasia of the hip (*cf.* Hip chapter). In addition, more deformity is tolerated at younger age, in part because function is delayed and functional demands are less predictable. Consider intervention for hip migration index (Reimers) >1/3 on röntgenogramme [M].

**0 TO 4 YEARS** Hip abduction brace. Augment abduction by adductor release as indicated.

**GREATER THAN 4 YEARS** Osteotomy without or with open reduction [N]. Because torsion is a significant feature of neuromuscular hip dysplasia, varus and derotation osteotomy of the femur is a central component of correction. Fix rigidly (e.g., blade plate) to avoid postoperative immobilization and associated morbidities, such as pressure phenomena and pulmonary compromise. Add innominate osteotomy based upon acetabular dysplasia. The neuromuscular acetabulum often is patulous due to constant microinstability; plasty (Pemberton) corrects this as it wraps the acetabulum around the head of the femur to contain it.

In the older child, take into consideration function, pain, and appearance on röntgenogrammes, which may show femoral head deformity as well as (sub)luxation and acetabular deformity. If the child stands to transfer and walks, perform a complex reconstruction to maximize hip function. Add open reduction, which may uncover significant degenerative change in the femoral articular surface where it has been rubbing against the edge of the acetabulum. In this setting, pain may persist due to osteoarthritis despite deformity correction. If the child does not walk, let pain guide treatment. If the deformity is painful, perform a proximal femoral resection arthroplasty (Castle-Schneider) or a proximal femoral valgus-abduction osteotomy (Schanz). Both procedures remove the head of the femur from acetabular contact, the source of pain. The former markedly improves hip motion and obviates the need for contracture release, but is plagued by proximal migration and reossification. The latter leaves the head of the femur in the buttock, which may break down over the prominence.

**CONTRACTURE RELEASE** This may be a part of hip reconstruction, or it may be an independent procedure [O]. For passive hip abduction <45 degrees, the adductors are approached *via* a direct medial approach (Ludloff). Cut gracilis and adductor longus. Neurectomy of obturator, of which the branches are defined as anterior and posterior relative to their position relative to the adductor brevis, is the ultimate release; however, it may be complicated by abduction contracture.

For hip flexion contracture >30 degrees, iliopsoa may be sectioned *via* same medial incision at its insertion into the trochanter minor, in the very young or the older patient who does not walk, or *via* the anterior approach (Smith-Petersen) for innominate osteotomy, where it is fractionally lengthened at the pelvic brim. For the latter approach, recognize that femoral nerve lies on the superficial surface of the iliopsoa, while its tendinous portion begins to form deep and medial in the muscle.

For popliteal angle  $>45$  degrees, hamstrings may be released *via* the medial approach by traveling deep to the adductor magnus to reach ischial tubercle. Differentiate tendons that originate from the bone and may be tensioned more by knee extension from the sciatic nerve, which may be apposed to the posterior surface of ischium. Consider a nerve stimulator. Alternatively, hamstrings may be lengthened at the knee by a direct approach: cut gracilis, cut or Z-lengthen semitendinosus, fractionally lengthen semimembranosus by cutting surrounding aponeurosis, and resist the biceps femoris for fear of weakening and extension contracture of the knee.

Tailor amount of release to achieve symmetry. Consider performing releases in the lower limbs simultaneously (including with other lower limb reconstruction), to limit number of independent surgical and anaesthetic exposures and to not weaken disproportionately one level, thereby amplifying the deformity at other levels.

### Lower Limb

**Leg** Lateral torsion of the ankle axis reduces push-off power by shortening the lever arm of the foot. This may be addressed by supramalleolar rotational osteotomy and fixed with percutaneous wires or with plate to obviate the need for a postoperative cast.

**Sagittal deformity** Patterns emerge from a sea of variations that elude comprehensive classification and universal rules of care [P].

**EQUINUS** The child may compensate by knee flexion or the knee may be driven into recurvatum by the ankle equinus. At early stage, botulinum toxin may allow fitting of an ankle foot orthotic. Later, operative lengthening of triceps surae may be necessary. While equinus in cerebral palsy is tenacious, gastrocnemius recession is preferable if Silfverskiöld sign is present. Based upon concern that this may be insufficient or not durable, lengthen tendo Achillis: err on less ankle flexion at operation in order to avoid weakening an already weak and contracted patient who thereby will be driven into a crouch gait. Add tibialis posterior fractional lengthening above the tibial malleolus for associated varus.

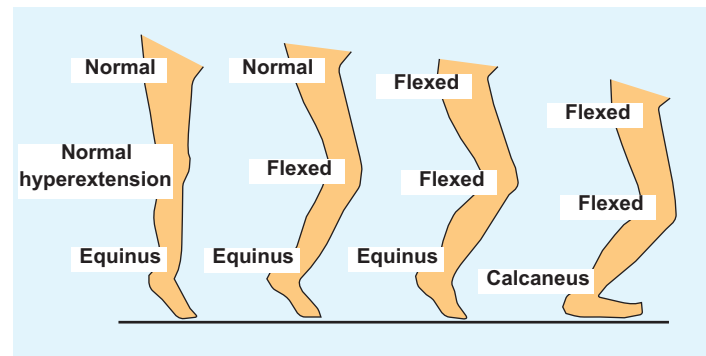
**STIFF KNEE** Spasticity of the rectus femoris, which is abnormally active during swing, leads to decreased knee flexion during swing, foot clearance problems, and reduced gait velocity and stride length. It may be defined as decreased knee excursion throughout the whole gait cycle of  $<30$  degrees. Distal transfer to sartorius fascia or medial hamstrings improves peak, timing of, and range of knee flexion in swing. Advocates of release of distal rectus femoris cite simplicity and failure of transfer (20%).

**"JUMP KNEE"** The term describes the appearance of bouncing up and down during walking. The knee and possibly the hip are flexed throughout stance, with equinus occurring in late stance. Diplegic patients with this presentation may be candidates for selective dorsal rhizotomy (v.s.) or multilevel single-event surgical release.

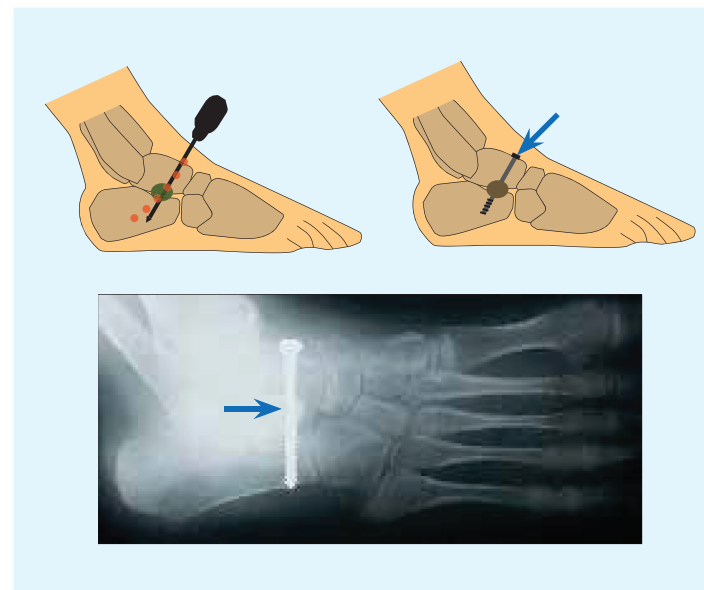
**CROUCH GAIT** This may result from weakness due to disease or that is iatrogenic, that is, tendo Achillis overlengthening. Release hip and knee, and support the ankle in an orthotic.

**Foot** Evaluation and management in the ambulatory child follow general principles (*cf.* Foot chapter).

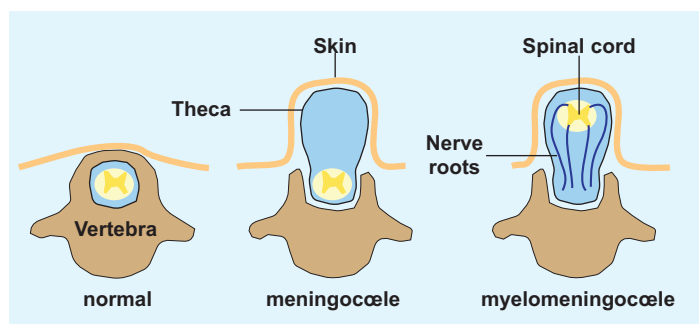
For the nonambulatory child, the goal is a plantigrade foot that can be stabilized in an ankle foot orthosis. Procedures for arthrodesis, stiffening, or limiting motion of the subtalar joint are attractive due to the limited demands of such a child and are indicated when rigid deformity precludes joint-preserving procedures such as lateral column lengthening [Q]. Procedures may be categorized as arthrodesis (e.g., Dennyson-Fulford), extra-articular fusion (e.g., Grice-Green), and extra-articular stabilizing or blocking procedures that limit eversion by an implant adjacent to the subtalar joint (e.g., Smith). The simplicity of these procedures has spilled them over into the flexible foot. Long-term outcomes remain pain and degenerative osteoarthritis, even if they may be less clearly or more slowly perceived in an involved child.



**P Sagittal deformity in the lower limb** Hemiplegia is characterized by greater distal involvement with relative proximal sparing and limb shortening that is advantageous to clear the floor in the setting of limited movement altering swing phase of gait.



**Q Subtalar arthrodesis for rigid flat foot in a nonambulatory** An Ollier incision is used to approach the sinus tarsi (red). Decorticate the talus and calcaneus or use a dowel cutter to excise a part of the subtalar joint; bone is grafted (green). The foot is placed in a neutral position and fixed with a screw (blue). This is combined with soft tissue releases, such as triceps surae lengthening.



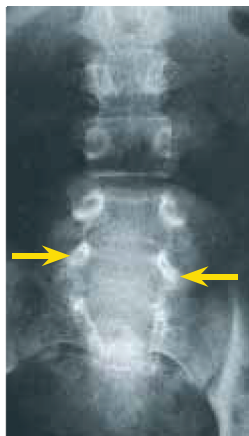
**A Pathology of meningocele and myelomeningocele** Meningocele (<10%) may have no neural deficit, whereas in myelomeningocele, by definition, the neural elements are stretched, exposed, and thereby injured.

Complication	Factors
Folate deficiency	1/2 cases 0.4 mg <i>per diem</i> preconception
Metabolic	Gestational diabetes
Toxic	Gestational exposure to drugs (e.g., neuroleptics)
Genetic	Chromosome anomaly (e.g., trisomy 13, 18)
Race	Whites = 3 X Blacks

**B Causes of spina bifida** Folic acid consumption and supplementation must be instituted when pregnancy is planned, because the lesion occurs before pregnancy is determined. Folic acid enrichment of cereal grain began in 1992 upon the recommendation of the U.S. Public Health Service, as a disease prevention measure.



**C Spina bifida** Spina bifida (red) may be repaired *in utero* or in the neonatal period. Patients will walk with anatomic lesion L4 or below (yellow), which is seen on röntgenogramme as pedicular dysplasia, absent spinous process contour and interpedicular widening.



## SPINA BIFIDA

Spina bifida (Latin *bifidus*: “cloven in two”) may be closed, designated occulta (Latin: “occult”), or aperta (Latin: “open”), also termed cystica (Greek *κυστις*: “bladder, sac of fluid”). Occulta affects >20% of the Caucasian population at the lumbosacral junction and is an incidental finding on röntgenogramme that has relevance to the surgeon operating on the spine in this region in order to avoid inadvertent entry into the vertebral canal. Cystica may be divided into two structural types [A]. The meninges (Greek *μηνιγξ*: “membrane”), dura mater and arachnoid, protrude to present a “sac” (Greek *θηκη*: “sheath” = Latin *theca*) filled with fluid without or with spinal cord (Greek *μυελος*: “marrow” of the vertebral column) and nerves. A variation is lipomyelomeningocele, in which a fibrofatty mass traverses the lumbodorsal fascia through a neural arch and theca to infiltrate and tether the spinal cord. While the clinical spectrum of disease is broad, the principal morbidities are cognitive, genitourinary, and musculoskeletal.

### Pathophysiology

Spina bifida results from failure of closure of the neural tube during 3rd and 4th weeks following conception. Because the neural tube folds and fuses from its middle toward each end, there are associated cranial defects. These include Chiari II malformation, which consists of caudal displacement through foramen magnum and squeezing of the brainstem that retards flow of cerebrospinal fluid to produce hydrocephalus. This and other brain anomalies account for varying degrees of mental impairment, which is worse the more cranial the lesion.

Many factors have been implicated in causation [B].

### Natural History

Untreated, mortality is 80%, within the first year, from infection and hydrocephalus. With surgical repair, the two factors most important to long-term functional outcomes are hydrocephalus and anatomic level. Cognitive function correlates with early and unobstructed shunting of hydrocephalus (>80% of cases). Walking ability peaks toward the end of the first decade and declines with the onset of the pubertal growth spurt, due to increasing body weight, worsening contractures and deformities, and complications of comorbidities and multiple medical and surgical treatments. Renal failure is the leading cause of death in adults.

### Presentation

Diagnosis may be made *in utero* based upon elevated a-fetoprotein and acetylcholinesterase due to an open neural tube detected by amniocentesis performed at the end of the first trimester of pregnancy. This may be confirmed by fetal ultrasonogramme, which shows ventriculomegaly and Chiari II malformation.

Myelomeningocele is evident at birth [C]. Lipomyelomeningocele may be more subtle, including soft tissue mass and stigmata of dysrhythmism such as hypertrichosis or sinus. Clinical presentation may be divided according to the locus of the disease.

- Central nervous system disease. Signs of encephalopathy due to hydrocephalus and anomalies include cognitive impairment and seizures. Brainstem and upper cervical compression due to Chiari II malformation may lead to upper limb weakness, spasticity, and incoordination. In addition, swallowing difficulty, gastroesophageal reflux, and aspiration pneumonia result in failure to thrive and are life threatening in the infant.
- Spinal cord disease. This includes myeloschisis, tethering, and syrinx as an extension of hydrocephalus. The zone of neural injury may be imprecise: functional level often does not correspond with anatomic level. Sensory level may not match motor level, and flexors are more proximally affected than extensors. Patients with upper thoracic lesions have poor trunk control. Those with lower thoracic and upper lumbar lesions do not walk. L4 or below walk, due principally to preserved quadriceps function.

Fetal repair for myelomeningocele reduces the need for shunting and improves motor, at the expense of preterm delivery and uterine dehiscence at delivery. Neural function may change longitudinally due to several factors, such as hydrocephalus and spinal cord tethering. By contrast with spasticity and dyskinesia in cerebral palsy, most patients with spina bifida present with flaccid paralysis.

- Musculoskeletal deformities, which reflect functional level. Upper thoracic level is characterized by scoliosis, thoracolumbar kyphosis, and lumbar hyperlordosis. Asymmetry of pericoxal muscle function in low thoracic/upper lumbar level leads to hip dislocation. Knee, ankle, and foot contractures and deformities are the principal features of more distal levels.
- Cutaneous breakdown. This is related to abnormal sensation; immobility that does not allow pressure relief; deformity concentrating pressure, such as over a gibbus or due to posture asymmetry; and lower limb distal vasculopathy. It is exacerbated by orthotics and casting and by maceration due to bowel and bladder dysfunction.
- Neurogenic bowel and bladder, accounting for routine urinalysis and preoperative coverage for urinary tract infection.

### Spine

Because of the pathogenesis, spinal deformity in spina bifida has two components. Like cerebral palsy, it may be acquired as a result of neuromuscular imbalance to produce scoliosis. It may be congenital, such as hemivertebral failure of formation, to produce kyphosis. With progressive deformity, the erector spinae dislocate anteriorward to the vertebral bodies to become flexors, thereby worsening the deformity.

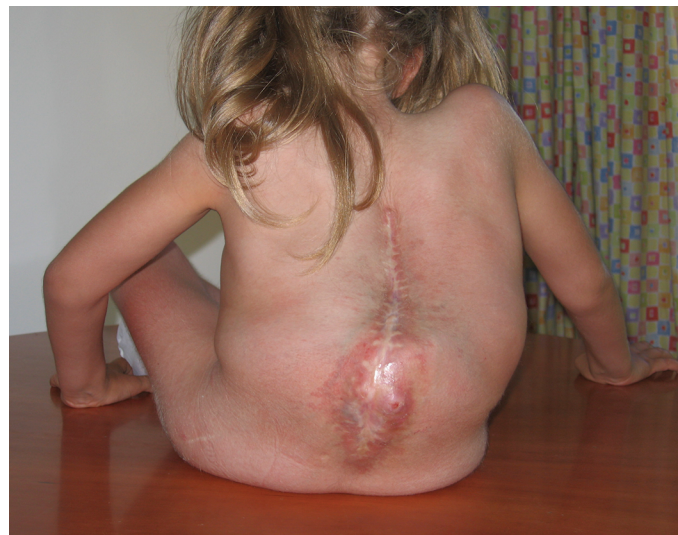An orthotic provides stability to a child with poor truncal control. Surgical indications include the following:

- For kyphosis, intractable soft tissue breakdown over gibbus. This is facilitated by corpectomy if there is no useful function in the lower limbs or bowel and bladder.
- For scoliosis, recruitment of the upper limbs to correct posture. Liberation of the upper limbs is critical for the child to interact with the environment.

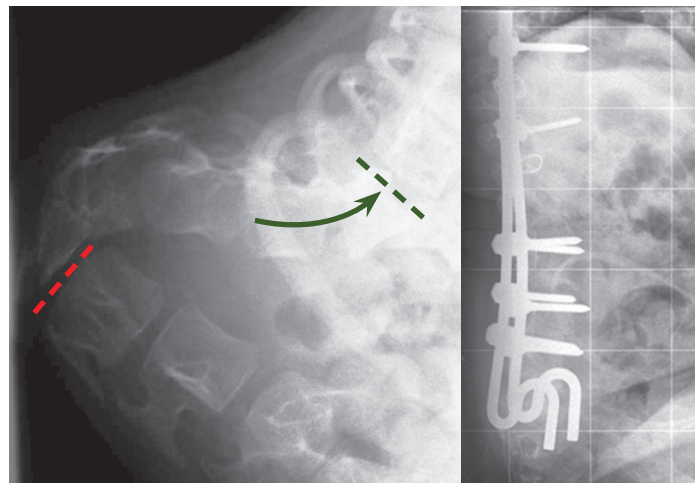
The benefits of surgical treatment of spine deformity have evaded demonstration. Accordingly, there is no clear role for prophylactic intervention to arrest progression or in anticipation of pulmonary or other visceral compromise.

There are several special considerations relevant to spine surgery in spina bifida.

- Infection. Multiple hospitalizations and operations, as well as neurogenic bowel and bladder requiring catheterizations and manipulations, result in polymicrobial colonization. The soft tissue envelope, stretched and bruised by deformity, and repeatedly incised, for example, starting with the spina bifida repair, is fragile and attenuated. Exposure of the theca risks dural tear, which may require synthetic reconstruction to prevent chronic leak. Sensory loss may remove protective mechanisms to decompress the wound.
- Pseudarthrosis. The posterior elements, and therefore the surface for fusion, are absent. This requires combination with anterior fusion, performed *via* separate approach, posterior interbody access, or vertebral column resection.
- Tethered spinal cord. 1/3 of patients will undergo detethering procedure. Evaluate level of conus medullaris (below L2) and filum terminale (thickened, fatty) by MRI, and solicit a neurologic surgeon for release before correction, lest the spinal cord be stretched by correction and there be a loss of neural function. Orthopaedic procedures are not reduced by detethering, and retethering is not uncommon.
- Latex allergy. This is not exclusive to spina bifida [F]. Anaphylaxis may be life threatening. Best practice is primary prophylaxis in a latex-minimized environment.



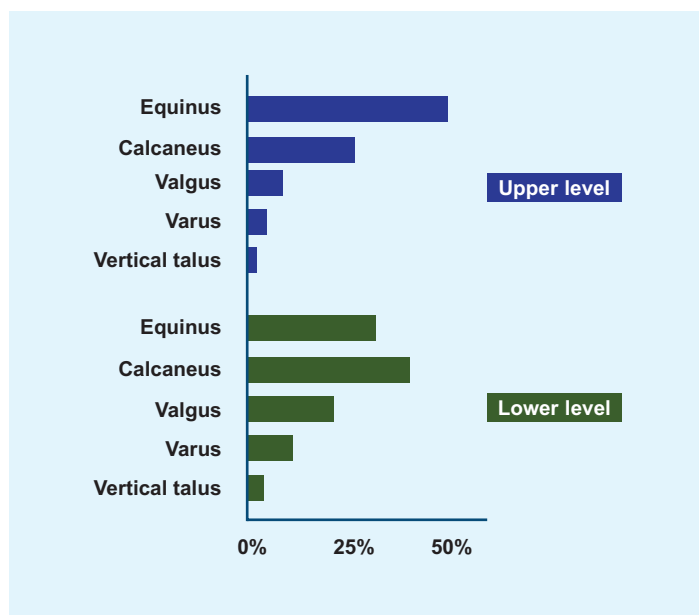
**D Cutaneous breakdown** Despite decompression of the gibbus by a gel support with cut out, the soft tissue is eroded by a progressive and rigid deformity.



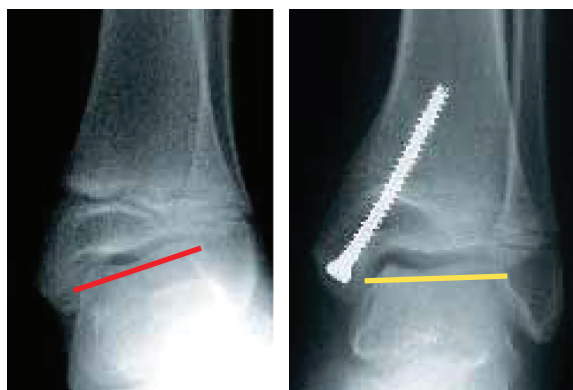
**E Kyphectomy for spina bifida** Perform a circumferential dissection from a posterior approach: the great vessels are safely anterior to the vertebral column. The resection includes the anomalous apical vertebra (red) and proximal lordotic segment (green), of which the total length is determined by what is necessary to reconnect a straightened spine. If a corpectomy is performed, then the junctional vertebrae may be removed one by one as necessary, instrumented, and returned to shape the reconstruction akin to the Sofield-Millar technique for osteogenesis imperfecta. In a young or thin child, S rods placed over the iliac alae provide pelvic fixation that is stable against sagittal displacement and not prominent. Monitor the hallux to make sure the great vessels are not stretched by correction. Excise the area of breakdown widely to close healthy wound edges, feasible by posterior soft tissues, including relocated paraspinous muscles, that will be relaxed by the kyphectomy.

Fraction	Disease
1/2	Spina bifida
1/4	Cerebral palsy
1/4	Other, e.g., ventriculoperitoneal shunt, muscular dystrophy, exstrophy of bladder,

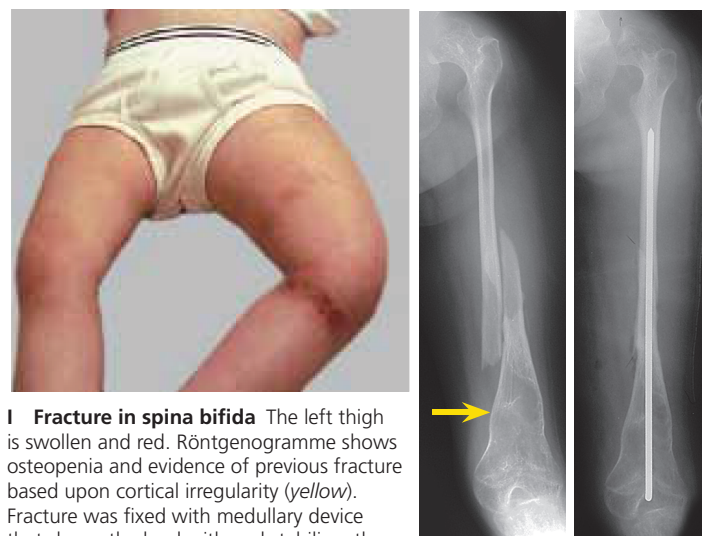**F Latex allergy in neuromuscular disease** This represents a type I IgE-mediated immune response to the highly elastic rubber polymer manufactured from the sap of the tropical tree *Hevea brasiliensis*. The allergy has as common factors multiple hospitalizations and procedures, including urinary catheterization and as early as ventriculoperitoneal shunt placement for hydrocephalus in the neonate.



**G Foot deformity in spina bifida** Most (>80%) upper level children present with significant foot deformity. The foot represents the greatest burden of deformity in lower level ambulatory child.



**H Correction of ankle valgus by temporary physal screw** Valgus inclination of talar trochlea (red) improves (yellow) with growth modulation of the distal tibia by a percutaneous screw, which is bent by the effect.



**I Fracture in spina bifida** The left thigh is swollen and red. Röntgenogramme shows osteopenia and evidence of previous fracture based upon cortical irregularity (yellow). Fracture was fixed with medullary device that shares the load with and stabilizes the femur against further injury.

## Hip

In an infant with demonstrated quadriceps function, and in a child who walks, hip dysplasia is evaluated and managed according to general principles (*cf.* Hip chapter). Hip dislocation may be seen in upper lumbar or higher levels, in whom it does not affect walking ability. This is managed according to general neuromuscular principles (*v.s.* cerebral palsy). Pain is mitigated by sensory loss, which may remove pain *per se* as an indication for surgical treatment. Asymmetric hip contracture and dislocation may lead to proximal femoral or pelvic prominence and sitting imbalance. These risk pressure concentration and soft tissue ischaemic necrosis, which may be exacerbated by sensory loss and reduced mobility. Despite such theoretical considerations, there is no consensus on operative indications: follow patients regularly, and intervene if a problem is imminent or arises rather than as prophylaxis in anticipation of one.

## Lower Limb

**Knee** The child who does not walk is more tolerant of a flexion contracture. Be prepared to combine tendon lengthening and release with posterior capsulotomy. Extension without or with shortening osteotomy of the distal femur may be necessary in the older child.

**Foot and ankle** Every deformity is possible in spina bifida [G]. Treat the foot and ankle of the walking child according to general principles (*cf.* Foot chapter). For the nonambulatory, the goal is a supple plantigrade foot.

- Deformity tends to be severe, stiff, and recurrent.
- Be careful when casting a foot in the setting of incomplete or absent sensation.
- Preserve motion: a flexible foot that bears weight on the sole will be most stable, easiest to maintain in brace, and least at risk for soft tissue breakdown.
- Tenodesis is useful and effective in the setting of absent voluntary control.
- Consider tendon exsection for release, to reduce recurrence of deformity.
- As with the knee, add capsulotomy of the ankle and subtalar joints as necessary.
- Supplement releases with osseous procedures, including decancellation and talectomy.

Distinguish hindfoot valgus from ankle valgus, which may be treated simply and effectively by distal medial tibial temporary physiodesis with percutaneous screw [H].

**Fracture** 30% of children will sustain a fracture, peaking at puberty, when the child is adapting to an increase in size and weight. Thoracic and nonambulatory patients are at highest risk: disuse osteopenia from motor loss and sensory neuropathy conspire to raise the risk with the level of disease. Correspondingly, most fractures involve the femur and tibia. In an ambulatory child, consider medullary fixation for repeated fracture or to prevent malunion, which may impair walking or increase risk for subsequent fracture [I]. Physal fractures heal more slowly and have a higher rate of growth disturbance. Balance prolonged immobilization against exacerbating osteopenia. Growth disturbance and deformity may require correction, or tip a patient with marginal ambulatory status toward the wheelchair.

Fractures in spina bifida may be confused with infection and occasionally neoplasm due to a vigorous inflammatory response characterized by swelling and redness, an exuberant callus on röntgenogramme, and the fact that many fractures occur after imperceptible trauma. Fever and inflammatory markers may be elevated, but in reduced proportion to the physical examination to be consistent with infection. Immobilization confirms fracture empirically as inflammatory signs subside.

## MUSCULAR DYSTROPHY

The term describes a group of hereditary, primary, progressive diseases of the muscle [A]. The pathogenesis is muscle cell death leading to weakness (fatty degeneration) followed by contracture (fibrosis).

### Duchenne Muscular Dystrophy

This is the most common type of muscular dystrophy and has the distinction of being the most lethal genetic disease of childhood. It is caused by a mutation in the gene encoding dystrophin on Xp21.1-2. Dystrophin is a sarcolemma protein that connects cytoskeleton with extracellular matrix. 1/3 are new mutations. The tissue distribution of dystrophin in cardiac and smooth muscle, as well as brain, in addition to skeletal muscle explains the pleiotropy of the gene defect.

**Evaluation** The French neurologist and electrophysiologist G-B-A Duchenne de Boulogne (1806–1875) recognized in his appellation “pseudohypertrophic muscular paralysis” that the most striking sign is weakness in the setting of apparently potent, overgrown calves. The first consultation may be for a general complaint that the child is unable to keep up physically with his peers. In addition to calf hypertrophy, discrepant with the early age, Gower sign may reveal proximal muscle weakness [B]. Characteristics of gait include an abductor lurch (Trendelenburg), hyperlordosis of the lumbar spine (to compensate for hip extensor weakness) [C], posterior thrust of the knee (to compensate for quadriceps weakness), and toe walking. Cardiac disease must be addressed and function optimized before operation. Gastrointestinal and urinary dysfunction reflect smooth muscle disease. Mean intelligence quotient is 20 below normal (105).

The natural history is predictable [D].

**LABORATORY ANALYSIS** Abnormal dystrophin allows leakage of intracellular components such as creatine phosphokinase, which is >100 times normal level (<200 IU/L). Polymerase chain reaction confirms the mutation. Pulmonary function testing is part of preoperative evaluation.

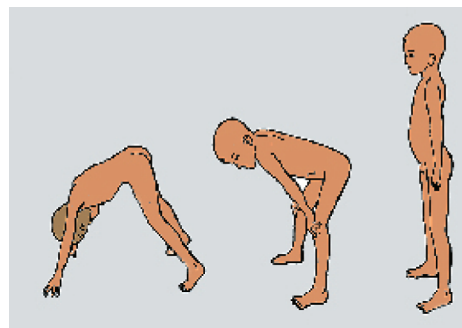
**IMAGING** Ultrasonogram reveals altered signal due to fibrofatty infiltration of muscle.

**Medical management** Steroids suppress immune-mediated cell destruction, temporarily improving muscle strength and delaying progression of scoliosis. Deflazacort is bone and carbohydrate sparing, limiting osteoporosis and weight gain. Creatine monohydrate, which improves muscle performance in healthy athletes, has been shown to increase muscle strength and functional performance. It remains early to determine efficacy of other avenues of investigation, such as gene therapy and disease-modifying drugs that act at a genetic level, for example, codon read-through and exon skipping. For example, eteplirsen and drisapersen are morpholinos (knockdown tools that block RNA and thereby modify gene expression) that results in skipping of exon 51 of the dystrophin gene. For a subset of patients with Duchenne muscular dystrophy due to a frame-shift mutation, such drugs may restore the reading frame to produce a functional protein.

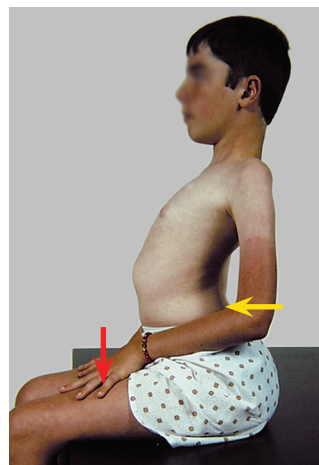
**Spine** Steroids and improvements in cardiopulmonary care have reduced surgical treatment of scoliosis. Bracing is contraindicated due to potential of thoracic constriction negatively impacting pulmonary function. Scoliosis is a marker of advanced disease, which also is marked by pulmonary decline. Recommendations for surgical treatment beginning at 20 degrees are indications that curve progression is inevitable and that the window for intervention is narrowed by pulmonary function. Preoperative cardiac evaluation and pulmonary function tests are essential. Operative ventilatory risk, including permanent postoperative dependence, rises sharply after forced vital capacity drops below 30%. Spine fusion rectifies and stabilizes the back, which is critical to a child with weak upper limbs. It slows the decline of pulmonary function, which is primarily affected by respiratory muscle weakness. Perform a long fusion that includes the pelvis, in order to reduce the risk of a second procedure and insult to the patient’s lungs. Operative risks include increased haemorrhage because of reduced constriction of the vascular muscle wall

X-linked
<ul style="list-style-type: none"> <li>• Duchenne</li> <li>• Becker</li> <li>• Emery-Dreifuss</li> </ul>
Autosomal dominant
<ul style="list-style-type: none"> <li>• Myotonic</li> <li>• Facioscapulohumeral</li> <li>• Emery-Dreifuss</li> <li>• Oculopharyngeal</li> <li>• Distal</li> </ul>
Autosomal recessive
<ul style="list-style-type: none"> <li>• Limb-girdle muscular dystrophy</li> <li>• Emery-Dreifuss</li> </ul>

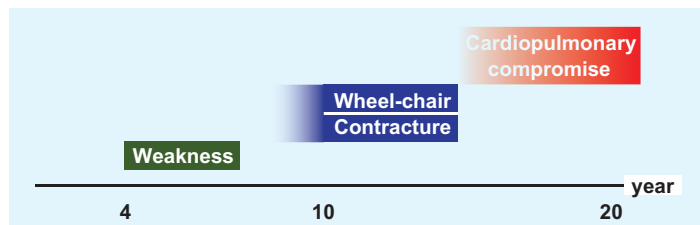
**A Muscular dystrophies** They may be classified according to inheritance pattern. There are many subtypes, for example, the limb-girdle phenotypic series includes 20 forms with unique mutations affecting >20 protein products. There are other forms of muscular dystrophy.




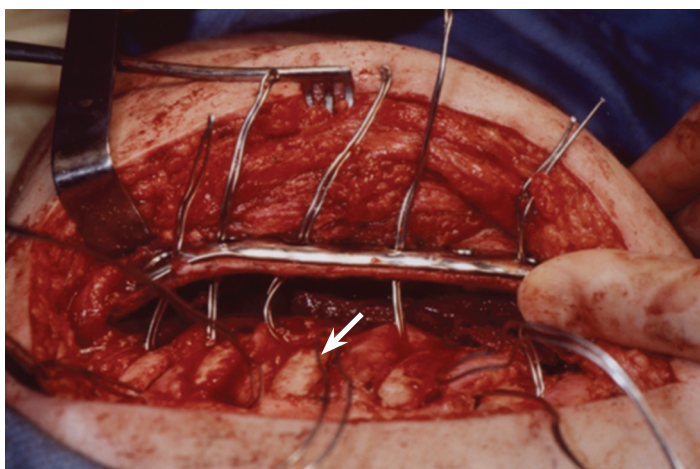
**B Gower sign** The child walks up the front of the legs and thighs when asked to stand from a seated position. Muscle weakness advances from proximal to distal in Duchenne muscular dystrophy.



**C Lumbar hyperlordosis** Hip flexion contracture and hip extensor weakness drive the lumbar spine into increasing lordosis to balance head over pelvis. Note the use of the hands for stability.



**D Natural history of Duchenne muscular dystrophy** Contracture, such as scoliosis and equinovarus, coincides with confinement to the wheelchair. Cardiopulmonary compromise accounts for death in the third to fourth decades. Walking after 13 years is Becker muscular dystrophy, which has a later onset and milder course, with survival into the fifth decade.



**E Scapulothoracic fusion for FSHMD** By a vertebral border of scapula approach, ribs are exposed for circumferential wiring (*white*), which is secured to a contoured LCDC plate to the dorsal scapular surface. Scapula and ribs are compressed with intervening bone iliac crest bone graft.

and malignant hyperthermia. The latter results from uncontrolled skeletal muscle oxidative metabolism, leading to a rise in end-tidal  $\text{CO}_2$  concentration as the first anaesthetic sign and cyanosis as the first sign in the operative field. Increased body temperature occurs late. Avoid volatile anaesthetics, and treat with nondepolarizing muscle relaxants.

**Foot and ankle** While the patients walk, deformity typically remains flexible. Support and maintain neutral position with orthotics, without or with casting. Gastrocnemius recession for toe walking is safe in a weakening condition. Equinovarus may be addressed effectively by the Rancho Los Amigos procedure:

- Split transfer of tibialis anterior to cuboid bone.
- Tibialis posterior fractional lengthening proximal to tibial malleolus.
- Open tendon of Achilles Z-lengthening.

In the nonambulatory child with profound weakness, in whom a plantigrade foot is the goal, tendo Achillis lengthening may be combined with transfer of tibialis posterior through the interosseous membrane to the dorsum, where tenodesis may suspend the foot in a neutral position.

### Myotonic Dystrophy

Myotonia refers to delayed muscle relaxation after contraction. This is the most common muscular dystrophy in adults, with onset in the second decade. Heterogeneity manifests by type 1 caused by a heterozygous mutation in the dystrophin myotonia protein kinase gene on 19q13.32 and type 2 caused by mutation in the zinc finger protein 9 gene on 3q21.3. It is distinguished by weakness that proceeds from distal to proximal, facies myopathica giving a haggard appearance, cataracts, insulin-resistant diabetes mellitus, encephalopathy, and male hypogonadism.

### Facioscapulohumeral Muscular Dystrophy

FSHMD is the third most common muscular dystrophy. It is associated with contraction of the D4Z4 macrosatellite repeat on 4q35. The disease is characterized by facial weakness, for example, inability to whistle, as well as weakness of the shoulder and proximal arm muscles, including serratus anterior, trapezius, and rhomboid major and minor, which results in the winging of the scapula and diminished shoulder abduction and flexion. Penetrance of this autosomal dominant disorder is 95% by 20 years age. An infantile form is characterized by hip flexion contracture and extensor weakness, lumbar hyperlordosis, foot drop, sensorineural hearing defects, and retinal vasculopathy.

The origin of deltoid, which is relatively spared, is reversed. Activation will anchor deltoid in the heavier upper limb to move a lighter scapula when not stabilized against the thorax. Patients complain of shoulder ache, inability to perform overhead activities such as combing the hair, and unsightly winging of the scapula. Surgical stabilization of the scapula against the posterior thorax [E] alleviates discomfort, advantages the deltoid to abduct and flex the shoulder, and improves shoulder appearance.

### Emery-Dreifuss Muscular Dystrophy

The phenotypic series includes X-linked subtypes (emerin gene on Xq28, FHL1 gene on Xq26.3), autosomal dominant forms (lamin A/C gene on 1q22, TMEM43 gene on 3p25.1, SYNE1 gene on 6q25.1-2, SYNE2 gene on 14q23.2), and an autosomal recessive form (1q22). The common feature is mutation of proteins associated with the nuclear membrane. The original appellation humeroperoneal dystrophy emphasizes triceps weakness leading to flexion contracture of the elbow and loss of hindfoot eversion and ankle flexion, leading to equinovarus. Other features are paraspinous muscle contracture limiting neck motion and cardiac disease, such as conduction defects that risk sudden death and are indications for insertion of a pacemaker. Onset peaks in the second decade. Creatine kinase is elevated 10 times normal, which contrasts with Duchenne muscular dystrophy.



## OTHER NEUROMUSCULAR DISEASES

### Charcot-Marie-Tooth disease

This is named after Jean-Martin Charcot (1825–1893) and his student Pierre Marie (1853–1940) of France and Howard Henry Tooth (1856–1926) of England, whose contribution was to recognize that this represents neuropathy and not myelopathy. While Charcot is regarded as the “Father of Neurology,” he acknowledged Duchenne as “My Master in Neurology.”

CMT is the most common hereditary neural disease. It represents a heterogeneous group of hereditary motor and sensory neuropathies, of which there are 7 phenotypic types, based upon the clinical presentation (e.g., age of onset), and >50 genetic subtypes, based upon identified mutation. CMT may be divided into demyelinating and axonal forms. Autosomal dominant and recessive as well as X-linked patterns of inheritance occur.

**Pathophysiology** Most types, including CMT types 1, 3, and 4, are demyelinating. Degradation of abnormal myelin results in dysfunction of motor and sensory axons, which thicken like an “onion bulb” due to attempts at repair and remyelination. Pain and temperature are preserved because they are carried by unmyelinated nerve fibers. In axonal forms of disease, such as CMT type 2, there is primary neuron death followed by wallerian degeneration. X-linked types include both forms of the disease.

**Evaluation** Family history varies according to type, whether this represents a new spontaneous mutation, and penetrance, which may be so low that affected relatives may not perceive the disease. Peripheral neuropathy manifests as weakness, muscle wasting, and loss of sensation, progressing from distal to proximal, involving the lower limbs before the upper limbs. Onset typically is in childhood. The earliest complaints are motor, such as clumsiness and frequent falls. As the disease advances, signs emerge such as steppage gait, deformity of the foot, and calf and interosseous muscle atrophy. Deep tendon reflexes, vibratory sensation, and proprioception are diminished, with normal pain and temperature sensation. In the foot, weakness begins in the interossei, producing clawing, followed by tibialis anterior weakness, producing cavus due to unopposed peroneus longus, and peroneus brevis weakness, allowing unopposed tibialis posterior to drive the hindfoot into the varus. 1/3 of children develop spine deformity. 5% to 10% develop hip dysplasia, which is acquired due to neuromuscular imbalance, silent in the first decade and progressive, and which is an indication for screening röntgenogramme of the pelvis. Enlarged peripheral nerves may be palpable.

Peripheral nerve thickening, for example, median, may be imaged with ultrasound. Nerve conduction is slowed in demyelinating forms of the disease. Sensory nerve action potentials and compound muscle action potentials are reduced in axonal forms, while nerve conduction is normal. Cytogenetic testing, such as for mutation in the gene encoding peripheral myelin protein-22 on 17p12 (CMT types 1A and 1E, Dejerine-Sottas disease, Roussy-Levy syndrome), confirms the diagnosis, although it is not available for all types.

**Management** Manage cavovarus and clawing of the foot according to general principle (*cf.* Foot chapter). Intervene surgically before the subtalar joint becomes stiff, in order to preserve motion. Spine and hip deformities also are managed according to general principles (*cf.* Spine, Hip chapters).

Type	Traditional Classification	
I	Werdnig-Hoffman, acute	onset < 6 mo.
II	Werdnig-Hoffman, chronic	onset 6–24 mo.
III	Wolfhart-Kugelberg-Welander	onset > 24 mo.
IV	no eponym	adult onset
International Spinal Muscular Atrophy Consortium		
I	Infantile	Onset <6 mo. Unable to sit, death in infancy
II	Intermediate	Onset 6–24 mo. Unable to walk, death by third decade
III	Juvenile	Onset >2 years Marginal walking, lost by second decade
IV	Adult	Mean onset fourth decade.

**A Classification of spinal muscular atrophy** Severity correlates inversely with age of onset.

### Spinal Muscular Atrophy

This represents a group of disorders characterized by anterior horn cell degeneration and progressive weakness and muscle atrophy [A]. It is the second most common autosomal recessive inherited disorders after cystic fibrosis. Sensation and cognition are unaffected. Spinal muscular atrophy is caused by mutation of the survival of motor neuron 1 gene on 5q13.2.

**Evaluation** A history of fetal hypokinesia may be elicited. Boys are affected more than girls, lower limbs more than upper limbs, and proximal more than distal weakness. Facial muscles are spared, except tongue fasciculation. There is absent tendon reflexes but no central neural signs. Type I presents as a floppy baby. Type II typically is diagnosed based upon hypotonia and delayed or missed motor milestones, in particular independent sitting and walking. Most common cause of death in spinal muscular atrophy is pulmonary infection.

Compound muscle action potentials are reduced, with neurogenic patterns on electromyography. Sensory nerve conduction is normal. Cytogenetic testing confirms diagnosis.

**Management** The spine and hip are most deformed and most treated. Follow general principles for the patient with muscle weakness and spine deformity (*cf.* Duchenne Muscular Dystrophy) and for the neuromuscular patient with acquired hip dysplasia based upon pain and walking ability (*cf.* Cerebral Palsy).

### Friedreich Ataxia

This is the most common hereditary ataxia. It is an autosomal recessive disorder caused by trinucleotide repeat mutation in the frataxin gene on 9q13.21. Disease severity is related to the number of repeats. It is characterized by degenerative changes in spinocerebellar tracts, dorsal columns, pyramidal tracts, cerebellum, and medulla.

**Evaluation** As the name implies, ataxia is the first and defining sign, with titubation and a tabetocerebellar gait, to which contribute both loss of position and vibratory sense in dorsal columns of spinal cord and degeneration of cerebellum. Additional features include dysarthria, dysphagia, absent tendon reflexes, preserved Babinski reflex, variable cognitive impairment, and rare chorea. Upper limbs and face are affected less and later than lower limbs and trunk. Typical course is onset toward the end of the first decade with loss of ambulation following in the second decade. Like spinal muscular atrophy, morbidity correlates inversely with onset. Contractures develop, resulting in kyphoscoliosis and cavovarus foot deformity in half of patients. Insulin receptor abnormality leads to diabetes mellitus in 10%. 25% have optic atrophy, and 10% have sensorineural hearing loss. Most patients succumb to hypertrophic cardiomyopathy in midadult life.

Nerve conduction is mildly slowed. Sensory nerve action potentials are reduced or absent. Somatosensory evoked potentials are abnormal. Echocardiography is an essential part of preoperative workup. Cytogenetic testing confirms the diagnosis.

**Management** This mirrors management of other neuromuscular disorders (*cf.* Cerebral Palsy).

### Poliomyelitis

This infection is caused by neurotropic enteroviruses of the *Picornaviridae* family. It is transmitted *via* an orofaecal route from contaminated water. In 1% of cases, from the gut, there is viraemia followed by lodgment and destruction of anterior horn cells and brain stem motor nuclei, causing paralysis over a 1- to 2-week period. Muscles with motor nuclei extending over several segments are particularly vulnerable. There may be partial or complete recovery. Neural imbalance leads to contractures, which are amplified by growth, which is stunted.

The disease peaked in the mid-20th century, since which it has declined by 99% due to immunization. Eradication is near.

**GENERAL**

- Babinsky JFF. Sur le spasme du peaucier du cou. *Rev. Neurol.* 9:693–696, 1901.
- Duncan WR. Release of the rectus femoris in spastic paralysis. *J. Bone Joint Surg. Am.* 37(1):634–636, 1955.
- Moro E. Das erste tremenon. *München Med. Wochenschr.* 65:1147–1151, 1918.
- Ober FR. The relation of fascia lata to conditions in the lower part of the back. *JAMA.* 109:554–558, 1937.

**CEREBRAL PALSY**

- Arens L, Peacock W, Peter J. Selective posterior rhizotomy: A long-term follow-up study. *Childs Nerv. Syst.* 5(3):148–152, 1989.
- Bell KJ, Ounpuu S, De Luca PA, Romness MJ. Natural progression of gait in children with cerebral palsy. *J. Pediatr. Orthop.* 22(5):677–682, 2002.
- Bleck EE. Locomotor prognosis in cerebral palsy. *Dev. Med. Child. Neurol.* 17(1):18–25, 1975.
- Castle ME, Schneider C. Proximal femoral resection-interposition arthroplasty. *J. Bone Joint Surg. Am.* 60(8):1051–1054, 1978.
- Dreher T, Wolf SI, Maier M, Hagmann S, Vegvari D, Gantz S, Heitzmann D, Wenz W, Braatz F. Long-term results after distal rectus femoris transfer as a part of multilevel surgery for the correction of stiff-knee gait in spastic diplegic cerebral palsy. *J. Bone Joint Surg. Am.* 94(19):1–10, 2012.
- Jevsevar DS, Karlin LI. The relationship between preoperative nutritional status and complications after an operation for scoliosis in patients who have cerebral palsy. *J. Bone Joint Surg. Am.* 75(6):880–884, 1993.
- Kay RM, Rethlefsen SA, Fern-Buneo A, Wren TA, Skaggs DL. Botulinum toxin as an adjunct to serial casting treatment in children with cerebral palsy. *J. Bone Joint Surg. Am.* 86(11):2377–2384, 2004.
- Little WJ. On the influence of abnormal parturition, difficult labours, premature birth, and asphyxia neonatorum, on the mental and physical condition of the child, especially in relation to deformities. *Trans. Obstet. Soc.* 3:293, 1862.
- Nordmark E, Josenby AL, Lagergren J, Andersson G, Strömblad LG, Westbom L. Long-term outcomes five years after selective dorsal rhizotomy. *BMC Pediatr.* 8:54, 2008.
- Noonan KJ, Halliday S, Browne R, O'Brien S, Kayes K, Feinberg J. Interobserver variability of gait analysis in patients with cerebral palsy. *J. Pediatr. Orthop.* 23(3):279–287, 2003.
- Palisano R, Rosenbaum P, Walter S, Russell D, Wood E, Galuppi B. Development and reliability of a system to classify gross motor function in children with cerebral palsy. *Dev. Med. Child Neurol.* 39(4):214–223, 1997.
- Phelps WM. Description and differentiation of types of cerebral palsy. *Nerv. Child.* 8(2):107–127, 1949.

- Reynell JK. Post-operative disturbances observed in children with cerebral palsy. *Dev. Med. Child Neurol.* 7(4):360–376, 1965.
- Rodda JM, Graham HK, Carson L, Galea MP, Wolfe R. Sagittal gait patterns in spastic diplegia. *J. Bone Joint Surg. Br.* 86(2):251–258, 2004.
- Schanz A. Zur Behandlung der veralteten angeborenen Hüftverrenkung. *Z. Orthop.* 42:442–444, 1921.
- Soo B, Howard JJ, Boyd RN, Reid SM, Lanigan A, Wolfe R, Reddihough D, Graham HK. Hip displacement in cerebral palsy. *J. Bone Joint Surg. Am.* 88(1):121–129, 2006.
- Sutherland DH, Larsen LJ, Mann R. Rectus femoris release in selected patients with cerebral palsy: a preliminary report. *Dev. Med. Child Neurol.* 17(1):26–34, 1975.
- Tachdjian MO, Minear WL. Hip dislocation in cerebral palsy. *J. Bone Joint Surg. Am.* 38(6):1358–1364, 1956.

**SPINA BIFIDA**

- Alman BA, Bhandari M, Wright JG. Function of dislocated hips in children with lower level spina bifida. *J. Bone Joint Surg. Br.* 78(2):294–298, 1996.
- Adzick NS, Thom EA, Spong CY, Brock JW III, Burrows PK, Johnson MP, Howell LJ, Farrell JA, Dabrowiak ME, Sutton LN, Gupta N, Tulipan NB, D'Alton ME, Farmer DL. A randomized trial of prenatal versus postnatal repair of myelomeningocele. *N. Engl. J. Med.* 364(11):993–1004, 2011.
- Centers for Disease Control and Prevention. Spina bifida and anencephaly before and after folic acid mandate—United States, 1995–1996 and 1999–2000. *MMWR Morb. Mortal. Weekly Rep.* 53(17):362–365, 2004.
- Drennan JC, Freehoffer AA. Fractures of the lower extremities in paraplegic children. *Clin. Orthop.* 77:211–217, 1971.
- Mercado E, Alman B, Wright JG. Does spinal fusion influence quality of life in neuromuscular scoliosis? *Spine* 32(19):S120–S125, 2007.
- Nutter AF. Contact urticaria to rubber. *Br. J. Dermatol.* 101(5):597–598, 1979.
- Sharrard JWW, Drennan JC. Osteotomy-excision of the spine for lumbar kyphosis in older children with myelomeningocele. *J. Bone Joint Surg. Br.* 54(1):50–60, 1972.

**MUSCULAR DYSTROPHY**

- Alman BA, Raza SN, Biggar WD. Steroid treatment and the development of scoliosis in males with duchenne muscular dystrophy. *J. Bone Joint Surg. Am.* 86(3):519–524, 2004.
- Conte G, Gioja L. Scrofolo del sistema muscolare. *Annali Clinici dell'Ospedale degli Incurabili di Napoli* 2:66–79, 1836.
- Diab M, Darras B, Shapiro FL. Scapulothoracic fusion for adolescent and infantile facioscapulohumeral muscular dystrophy. *J. Bone Joint Surg. Am.* 87(10):2267–2275, 2005.
- Duchenne GBA. Recherches sur la paralysie musculaire pseudo-hypertrophique ou paralysie myo-sclerosique. *Arch. Gen. Med.* 11:5–25, 1868.

- Drachman DB, Toyka KV, Myer E. Prednisone in Duchenne muscular dystrophy. *Lancet* 2(7894):1409–1412, 1974.
- Hoffman EP, Brown RH, Kunkel LM. Dystrophin: the protein product of the Duchenne muscular dystrophy locus. *Cell* 51(6):919–928, 1987.
- Kley RA, Tarnopolsky MA, Vorgerd M. Creatine for treating muscle disorders. *Cochrane Database Syst. Rev.* 2:CD004760, 2011.
- Landouzy L, Dejerine J. De la myopathie atrophique progressive (myopathie hereditaire debutant dans l'enfance, par la face, sans alteration du systeme nerveux). *Compt. Rend. Hebdomadaires Acad. Sci.* 98:53–55, 1884.
- Shapiro FL, Specht L. The diagnosis and orthopaedic treatment of inherited muscular diseases of childhood. *J. Bone Joint Surg. Am.* 75(3):439–454, 1993.
- Weimann RL, Gibson DA, Moseley CF. Surgical stabilization of the spine in Duchenne muscular dystrophy. *Spine* 8(7):776–80, 1983.

**OTHER NEUROMUSCULAR DISEASES**

- Brzustowicz LM, Lehner T, Castilla LH, Penchaszadeh GK, Wilhelmsen KC, Daniels R, Davies KE, Leppert M, Ziter F, Wood D. Genetic mapping of chronic childhood-onset spinal muscular atrophy to chromosome 5q11.2–13.3. *Nature* 344(6266):540–541, 1990.
- Chamberlain S, Shaw J, Rowland A, Wallis J, South S, Nakamura Y, von Gabain A, Farrall M, Williamson R. Mapping of mutation causing Friedreich's ataxia to human chromosome 9. *Nature* 334(6179):248–250, 1988.
- Charcot JM. *Clinical Lectures on Diseases of the Nervous System [Leçons sur les maladies du système nerveux]* 1889. Thomas Savill, translator ed., London: The New Sydenham Society; 2010.
- Friedreich N. Über degenerative atrophie der spinalen, hinterränge. *Arch. Anat. Physiol.* 26:391, 1863.
- Holmes JR, Hansen ST Jr. Foot and ankle manifestations of Charcot-Marie-Tooth disease. *Foot Ankle* 14(8):476–486, 1993.
- Kugelberg E, Welander L. Heredofamilial juvenile muscular atrophy simulating muscular dystrophy. *Arch. Neurol. Psychiat.* 75(5):500–509, 1956.
- Kumar SJ, Marks HG, Bowen JR, MacEwen GD. Hip dysplasia associated with Charcot-Marie-Tooth disease in the older child and adolescent. *J. Pediatr. Orthop.* 5(5):511–514, 1985.
- Milbrandt TA, Kunes JR, Karol LA. Friedreich's ataxia and scoliosis: the experience at two institutions. *J. Pediatr. Orthop.* 28(2):234–238, 2008.
- Ward CM, Dolan LA, Bennett DL, Morcuende JA, Cooper RR. Long-term results of reconstruction for treatment of a flexible cavovarus foot in Charcot-Marie-Tooth disease. *J. Bone Joint Surg. Am.* 90(12):2631–2642, 2008.
- Wetmore RS, Drennan JC. Long-term results of triple arthrodesis in Charcot-Marie-Tooth disease. *J. Bone Joint Surg. Am.* 71(3):417–422, 1989.

