

HIP

General.....	59	Legg-Calvé-Perthes Disease.....	77
Development.....	59	Pathoanatomy.....	77
Vascularity.....	60	Evaluation.....	77
Pathoanatomy.....	60	Natural History.....	78
Distinguishing Features.....	61	Management.....	79
Evaluation.....	62	Slipped Capital Femoral Epiphysis.....	81
History.....	62	Pathoanatomy.....	81
Physical Examination.....	62	Evaluation.....	81
Imaging.....	64	Natural History.....	82
Developmental Dysplasia of the Hip.....	66	Management.....	83
Incidence.....	66	Complications of SCFE Treatment.....	86
Cause.....	66	Coxa Vara.....	86
Pathoanatomy.....	66	Pathoanatomy.....	86
Evaluation.....	66	Evaluation.....	86
Natural History.....	69	Management.....	87
Management.....	70	Snapping Hip.....	87
Birth to 6 Months.....	70	Exstrophy of the Bladder.....	88
6 to 18 Months.....	70	Protrusio Acetabuli.....	88
18 months to 3 years.....	73	Femoroacetabular Impingement.....	89
Three to Six Years.....	74	Pathoanatomy.....	89
Six Years to Maturity.....	74	Evaluation.....	89
Maturity.....	76	Management.....	89

GENERAL

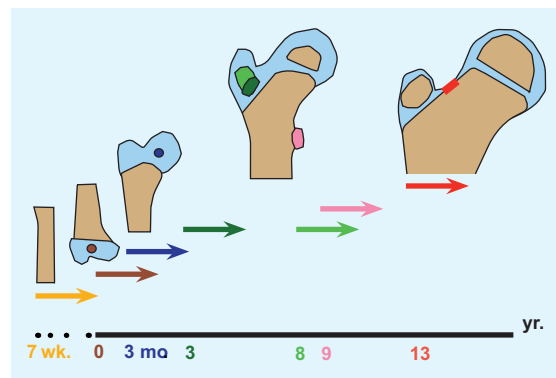
More than one-third of hip problems in adults have their origin during growth.

Development

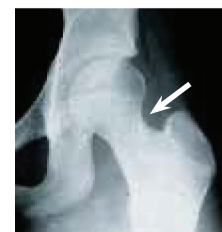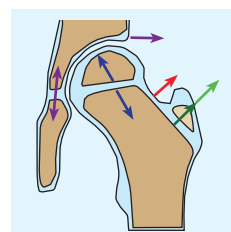
The distal femur is the only epiphysis consistently present at birth. The proximal epiphysis of the femur appears by the 2nd month in girls (2 to 6 months) and the 4th month in boys (4 to 8 months). The apophysis of trochanter major appears by the 3rd year, while that of trochanter minor appears by the 9th year. The proximal femur develops from a cartilage model in continuity from head to trochanter major until separation at the neck by the 13th year [A]. The acetabulum grows in depth and width from the triradiate cartilage and by apposition from the edge [B]. A secondary ossification center at the edge of the acetabulum appears in the early second decade, known as os acetabuli. The trochanter major enlarges by physal growth up to 8 years of age, after which growth is appositional.

Understanding growth of the hip elucidates disease and injury.

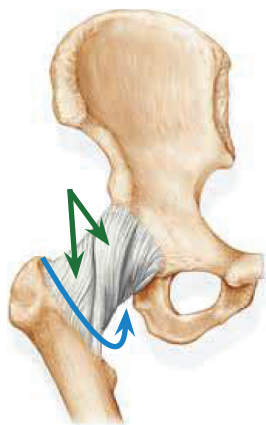- Röntgenogramme for hip dysplasia becomes more reliable after appearance of the proximal epiphysis of the femur.
- Disease of the proximal femur epiphysis, such as Legg-Calvé-Perthes disease, affects the height and shape of the head, as well as the length of the neck.
- Injury to the cartilage between the head and trochanter major, as in antegrade nailing or curettage of lesion, results in growth disturbance of the neck of the femur [B].
- Fracture or injury of triradiate cartilage may result in premature closure and acetabular dysplasia.



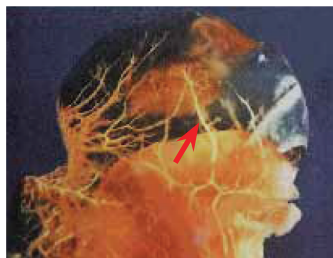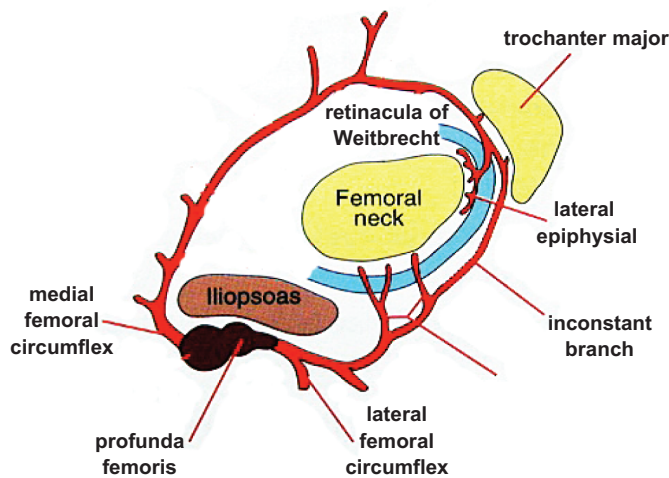
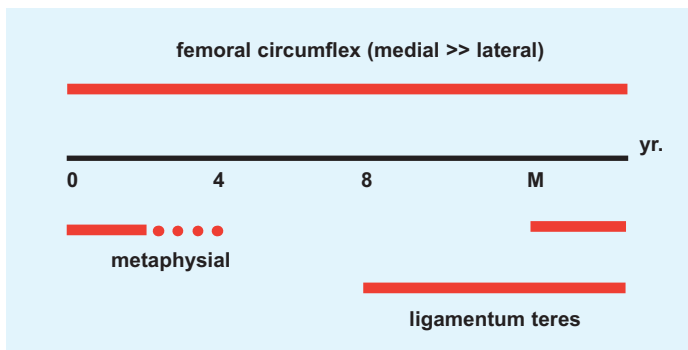
A Ossification of the femur Diaphysis (*orange*), distal epiphysis (*brown*), proximal epiphysis (*blue*), trochanter major (*green*), trochanter minor (*pink*), separation of proximal femur cartilage model (*red*).



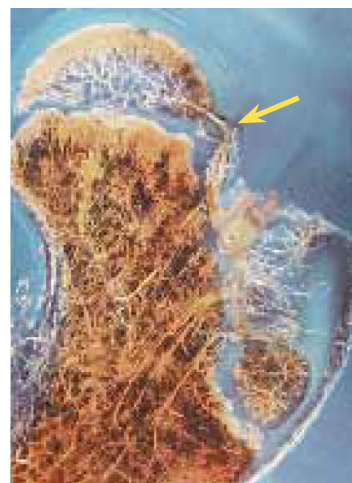B Growth of the hip Acetabulum and trochanter major growth is physal and appositional. Proximal femoral growth is physal, while the neck grows by apposition of bone. Interference with the latter results in growth disturbance, as the thin neck seen on röntgenogramme after curettage of cervical cyst (*white*).



C Orientation of the hip joint The fibers of the hip joint capsule are rotated medialward. The anterior capsule is stouter and includes the Y-shaped iliofemoral ligament of Bigelow (green). Relaxation of the capsular fibers is maximized by lateral rotation and flexion, which is the position of comfort in painful conditions.



D Vascularity of the head of the femur Blood supply varies according to age. M: maturity. Transphyseal vessels (red) and lateral retinacular artery (yellow). There is variability, as evidenced by inconstant branch.



- Antegrade nailing for femur fracture is safe through trochanter major after 8 years of age. A case of a 10-year-old boy was included in Küntscher's original report on the technique.
- Os acetabuli is separated from the remainder of the acetabulum by horizontal or mildly oblique physal cartilage; by contrast, a vertical orientation is seen with femoroacetabular impingement.

Evolutionarily, the forelimbs rotate laterally and the hindlimbs rotate medially. This results in medial twisting of the hip joint capsular fibers [C]. The universal response of a joint to injury or disease is effusion. The first and most consistently lost motion of a diseased hip is medial rotation: lateral rotation of the hip orients the capsular fibers parallel, thereby increasing volume of the hip joint to reduce pressure and stretch on pain fibers in the capsule.

Vascularity

In addition to growth disturbance, the immature proximal femur is susceptible to vascular injury. The head of the femur is perfused from three sources during childhood [D].

- In the neonatal period, metaphysial vessels may traverse the physis to supply the head of the femur; after 4 years of age, the physis becomes impervious.
- Between 4 and 8 years of age, the head of the femur is dependent upon a single source: the circumflex vessels “travel around” the neck of the femur and are divided into medial and lateral based upon their direction of origin from the profunda femoris artery. The medial circumflex provides >80% of the blood supply to the head of the femur and enters the hip joint posterior to travel in the retinacula of Weitbrecht as the lateral epiphysial vessels. The lateral circumflex travels anterior and supplies the trochanter major in addition to the head of the femur.
- After 7 years of age, the artery of ligamentum teres reaches the epiphysis from the obturator artery.

After physal closure, the metaphysial blood supply returns.

Pathoanatomy

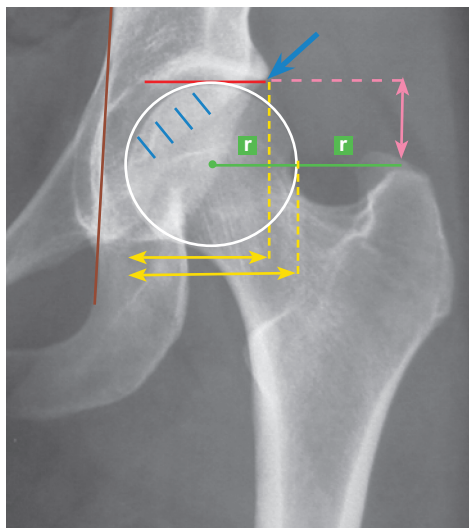
Select principles are essential to understanding hip deformity.

Cartilage Compression is good; shear is bad. Correct bone alignment to move oblique (shear) weight-bearing joint surface to horizontal (compression).

Acetabulum [E,F] The anterior wall overlaps the posterior wall approximately 50%. Margins of both walls meet at the lateral limit. In retroversion of the acetabulum, there is increasing overlap of the anterior wall until its margin overshadows that of the posterior wall to produce a crossover sign. The *sourcil* (named in French after its resemblance to an “eyebrow”) represents the principal weight-bearing surface: osteotomy of the pelvis aims to place this horizontal. Pressure = Force/Area. The acetabulum should cover enough of the head of the femur to avoid abnormal stress concentration, in particular at the edge. The “teardrop” represents medial wall of acetabulum: widening suggests insufficient medial force from a subluxated head of femur, and displacement beyond the ilioischial line (of Köhler) is defined as *coxa profunda*: “deep hip.”

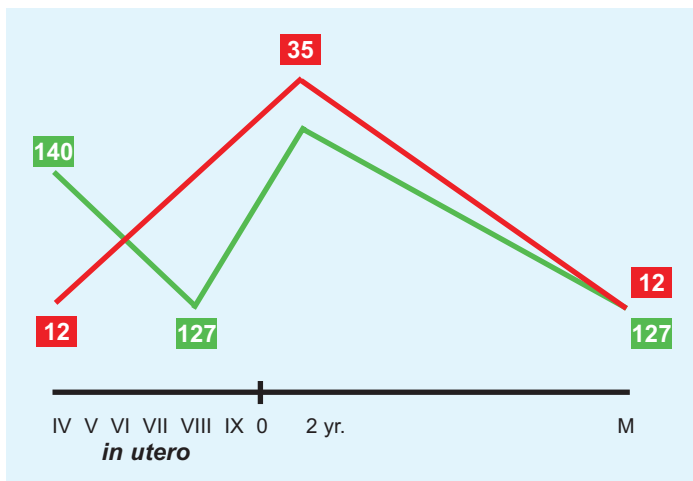
Proximal femur [E,F] The top of the trochanter major is at the level of the center of the head of the femur. If the top is above this level, there is varus deformity; if the top is below this level, there is valgus deformity. The articulo-trochanteric distance is measured from the top of the articular surface of the head of the femur to the top of trochanter major: it is increased in valgus, reduced in varus, and negative in severe varus. This assessment of varus and valgus is independent of rotation, which may distort measurement of neck–shaft angle. Tip of trochanter major is 2 radii lateral (offset) to the center of the head of the femur. “Protrusion” of the head of the femur beyond the ilioischial line is defined as *protrusio acetabuli*.

Femoral anteversion and neck–shaft angle vary *in utero*, are maximum at 2 years of age, and then decline until maturity [G]. The head is offset from the neck in coronal and sagittal planes [H]. The head–neck



E Anatomic relationships in two dimensions.

- Red: *sourcil*
- Blue: anterior wall
- Blue arrow: meeting of walls
- White: head circumference
- Green: radius
- Yellow: coverage 0.8
- Pink: articulo-trochanteric distance (mm)
- Brown: ilioischiac line



G Angulation of the proximal femur Mean values of neck–shaft angle (green) and neck anteversion (red) in degrees. Fœtal age in Roman numerals. M: maturity.

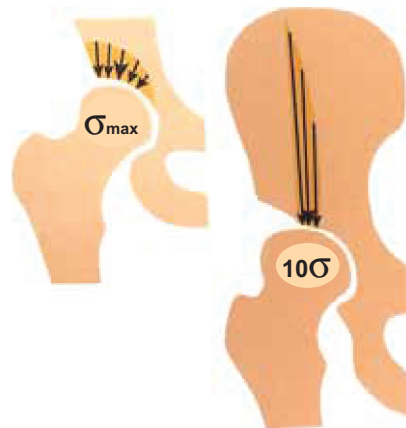
junction subtends an angle (designated α) with the longitudinal axis of the neck in both planes. Lateral offset is reduced and α angle is increased in femoroacetabular impingement and slipped capital femoral epiphysis. The latter also is characterized by reduction in coronal plane offset, simulating varus deformity in the anteroposterior projection.

The head of the femur is spherical, which allows motion in all dimensions. More important than sphericity is congruity: while the latter may concede limitation in motion, matching articular surfaces prevent stress concentration. Incongruity despite cosphericity occurs in subluxation, leading to edge loading.

Distinguishing Features

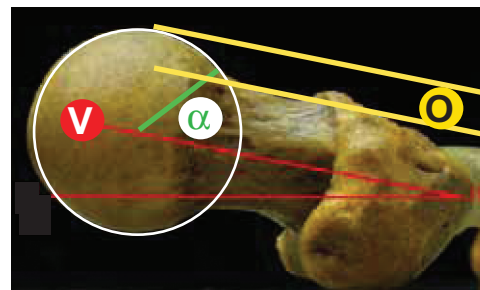
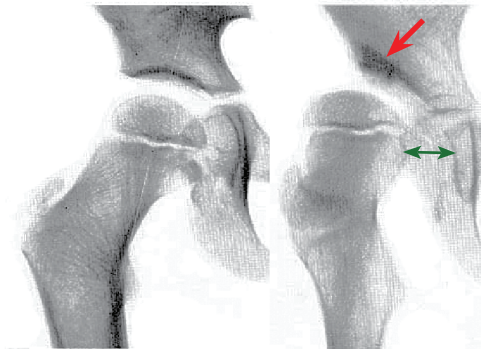
The hip is a bone-dependent joint, in contrast with the knee (ligament dependent) and the shoulder (muscle dependent). It is enarthrodial, consisting of a “ball in socket” that allows motion in all directions, like the shoulder and in contrast with the knee, which is ginglymoid (“hinge-like”), and the symphysis pubica or sacroiliac joints, which as syndesmoses absorb motion more than they allow it. The hip, like the shoulder, may be distinguished by its axial location, which under cover of multiple layers of thick muscle makes it obscure to direct observation and palpation. It also may be distinguished by the precariousness of its blood supply, raising the specter of osteonecrosis in several of its disorders and management. Outside of trauma, the hip in a

I Congruity versus sphericity Incongruity (red) leads to stress concentration, which may result from subluxation in hip dysplasia (brown) or rotational osteotomy (blue).



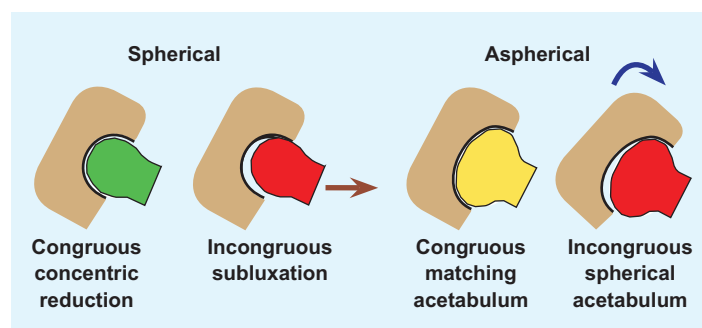
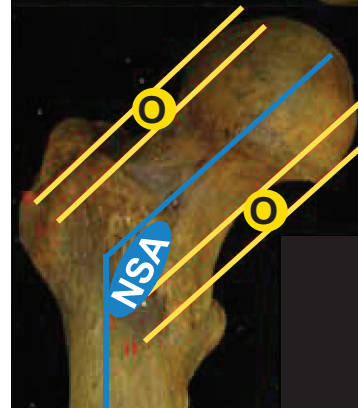
F Stress concentration

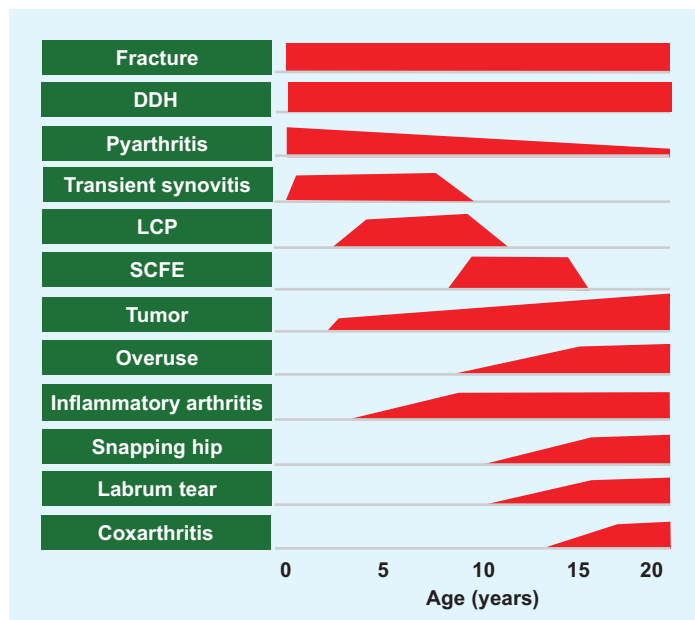
Reduction of coverage results in an order of magnitude increase in stress (σ) at *sourcil*. Subluxation, as measured by medial joint width (green), reduces coverage and congruity. The bone has reacted to stress concentration at *sourcil* (red).



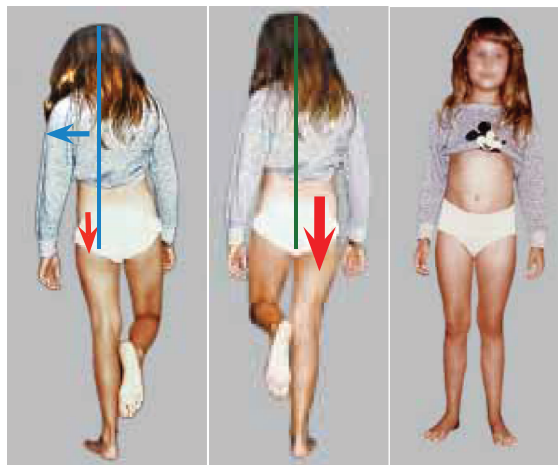H Architecture of the proximal femur.

- V: version of the neck (degrees)
- α : angle of head–neck junction
- O: offset of the head and neck (mm)
- NSA: neck–shaft angle

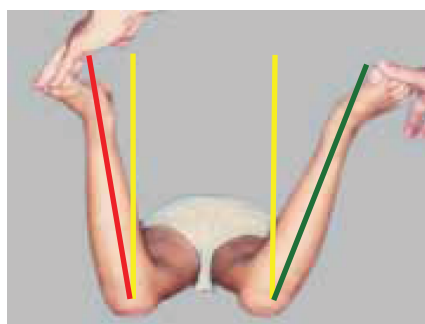




A Conditions affecting the hip by age DDH: developmental dysplasia of the hip. LCP: Legg-Calvé-Perthes. SCFE: slipped capital femoral epiphysis.



B Trendelenburg In developmental dysplasia of the hip, the abductor muscles are shortened and thereby weakened. In single limb stance, the patient reduces the lever arm of body mass by leaning toward the affected side (*blue*) to aid the contracting weakened hip abductors (*red*) to maintain the pelvis horizontal and avoid tilting and falling in the opposite direction. On the unaffected side, the head remains centered over the pelvis because the hip abductors are strong enough to maintain a horizontal pelvis with an unaltered lever arm. In two-limb stance, the affected limb is shortened. Gait may be observed as the child approaches the examination room. Trendelenburg elicited his sign during physical examination of a child with a dislocated hip (1895).



C Hip rotation prone Comparison may be made simultaneously of motion at both hips. Prone also exposes flexion contracture and allows isolation of movement of the knee from movement of the hip.

child demands more attention of the surgeon than any other joint. Like the glenoid cavity of the shoulder, the acetabulum is rimmed by a labrum. Like the cruciate ligaments of the knee, the hip joint is traversed by the ligamentum teres (also known as ligamentum capitis femoris), connecting the fovea centralis of the head of the femur with the fossa of the acetabulum.

EVALUATION

History

Is there a family history? Developmental dysplasia of the hip can be familial. Has there been an alteration of gait? The waddle of a dislocated hip may seem attractive in a young girl. Does the hip make noise or catch? Crepitus may be a sign of labrum tear.

Age Age is a universal discriminator of disease [A].

Onset In the acute presentation, it is imperative to rule out fracture, which occurs after an antecedent event, pyarthrititis, and slipped capital femoral epiphysis, which carries urgency due to the fragile vascularity of the hip. Other conditions, such as Legg-Calvé-Perthes disease, tend to have a more insidious onset and chronic course.

Physical Examination

Observation Does the child appear ill? Distress and fear are signs of infection or trauma. Are there constitutional or other system symptoms or signs? Hyperactivity and small for age have been associated with Legg-Calvé-Perthes disease. Overweight is typical of slipped capital femoral epiphysis. Rash is associated with inflammatory and autoimmune conditions that may affect the joints.

Pain Is there pain, and where? The law of Hilton (John Hilton, surgeon at Guy's Hospital London, 1860) states that "a nerve which innervates a muscle that acts on a joint will innervate that joint and the skin overlying the muscle's insertion." While groin pain may have an intrapelvic origin, such as inguinal hernia, the groin also is the locus of hip pain. In addition, femoral and obturator nerves supply muscles inserting about the anteromedial knee, where hip pain manifests in isolation in up to 15% of cases. Buttock pain may be from the back or from hip abductor muscle fatigue. The latter also may manifest as lateral pain, which in turn may be produced by contracture of the iliotibial tract.

Pain that awakens from sleep is concerning, in particular for osteoid osteoma. Tenderness may be seen in apophysitis or apophysial injury. Be careful of a "groin pull" in the peripubescent or associated with lateral rotation of the lower limb.

Gait Is there a limp, and if so what type? Reduced stance phase is seen in painful conditions such as trauma. Pain without an alteration in gait is less concerning. Abductor lurch (of Trendelenburg) results from weakness of pericoxal muscles [B]. Out-toeing gait is pathognomonic of slipped capital femoral epiphysis in a peripubescent child.

Palpation The hip joint is deep, and as such, points of tenderness are less revealing than more exposed joints such as the knee. Apophysis are accessible, including at iliac spines, tuberosity of ischium, and trochanter major in traumatic separation or irritation (overuse). Crepitus may be elicited from the hip joint, for example, labrum, or from pericoxal tissues, for example, a snapping psoa muscle in the groin or an iliotibial tract grating or "jumping" (*coxa saltans*) across trochanter major.

Motion

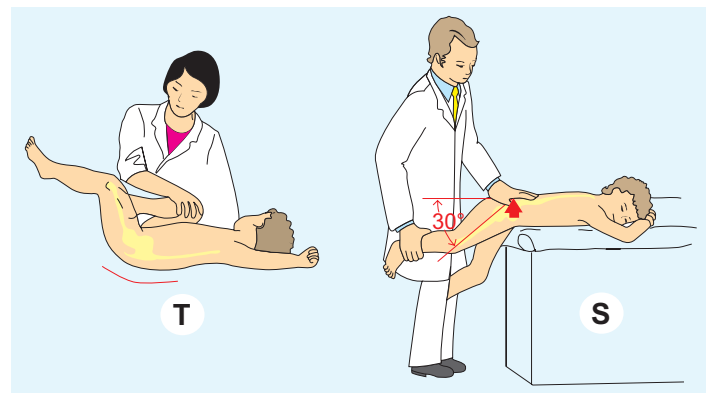
PSEUDOPARALYSIS Severity of disease or early age of onset may cause the child to quit the limb, out of pain and fear.

HIP ROTATION Medial rotation is the first and most characteristic motion lost in hip disease; this is followed by flexed posture or contracture. The prone position has three principal advantages [C]. It stresses a hip held in flexion. Comparison may be made as both hips may be moved simultaneously. The knee may be decoupled from the hip: the former may be moved without obligate motion of the latter, as occurs supine. Supine position allows assessment of rotation in the flexed position, which may be altered as the neck of the femur impacts acetabulum, as in slipped capital femoral epiphysis deformity.

FLEXION In addition to losing medial rotation, the painful or diseased hip is held in flexion. This is exposed automatically when evaluating motion in the prone position. In the supine position, a contracture may be detected by the Thomas or the prone extension test [D]. Pain with flexion beyond 90 degrees, exacerbated by adduction and medial rotation, suggests impingement. By contrast, the same pain with the same manoeuvre but with normal or increased motion is seen in hip dysplasia, due to damage of a deficient anterior wall of acetabulum.

EXTENSION Perform supine with pelvis at edge of table. The patient flexes contralateral hip while the examiner extends the hip and limb beyond table. Anterior deficiency of acetabulum, as in hip dysplasia, produces apprehension. Painful extension also may be seen in psoas abscess.

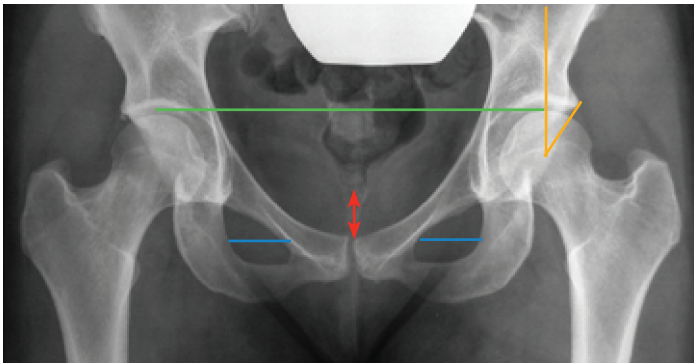
ABDUCTION-ADDUCTION Assess with fingers on anterior superior iliac spines as reference points, so that tilting of the pelvis does not mask contracture. Varus deformity of the hip, or growth disturbance of the head and neck of the femur, will lead to abutment of trochanter major against the ilium, thereby limiting abduction. Reduced adduction due to iliotibial tract contracture is assessed by Ober test: patient lateral; the examiner hand stabilizes the pelvis to keep it vertical; contralateral hip held by the patient in flexed position; and examined hip flexed, then abducted, and then extended while the examiner holds foot only. Contracture prevents the examined limb from adducting: the knee will remain suspended in abduction beyond midline.



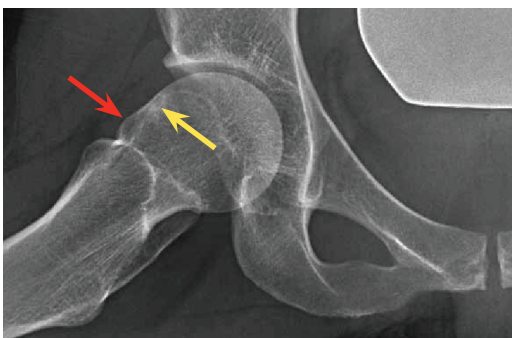
D Hip flexion contracture assessment In the Thomas test (T), maximal flexion of the contralateral hip eliminates lordosis of the lumbar spine, which can be a compensatory position for hip flexion contracture. In the prone extension test (S), gradually extend the hip until the hand on the pelvis begins to rise.

	Family history	Acute	Chronic	Antecedent event	Ill child	Pseudoparalysis	Loss of motion	Rigid	Limp	Crepitus	Serology	Other system	Urgent	Other features
Fracture		●		●		▨							●	scintigramme if röntgenogrammes negative
DDH	▨		●				▨	▨	▨					screening ultrasonogramme
Pyarthrits		●			●	▨		●	▨		●		●	ultrasonogramme
Transient synovitis		●		▨					●		●	●		remote infection
LCP			●				●		●					small for age; hyperactive
SCFE		▨	▨	▨			▨	▨	▨				▨	hypogonadal; overweight
Tumor		●			▨				▨			●		pain awakens from sleep
Overuse			●											pain delays sleep
Inflammatory arthritis	▨	●		▨		▨	▨	▨	▨		●	●		
Snapping hip			●							●				
Labrum tear		▨	▨							●				MRI arthrogramme

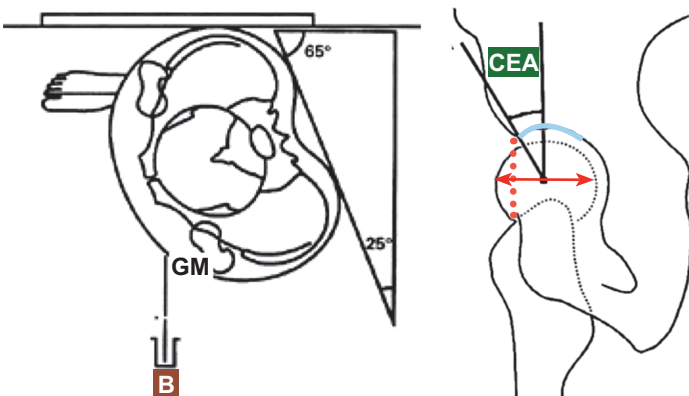
E Diagnosis of hip disease Characteristic (solid) and possible features (striped). DDH: developmental dysplasia of the hip. LCP: Legg-Calvé-Perthes. SCFE: slipped capital femoral epiphysis.



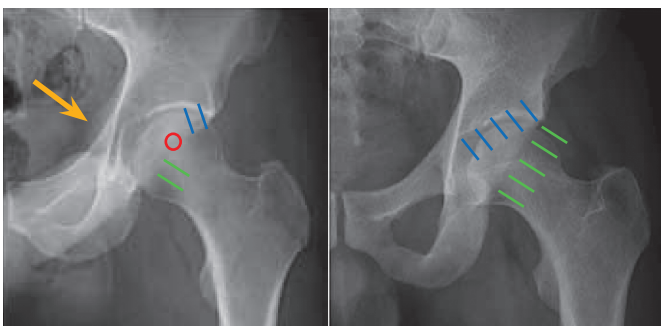
A Anteroposterior view of pelvis Rotation is determined by width of obturated foramina (blue). Inclination is determined by coccygosityphial distance (red). Limb lengths are similar (green). Note angle between head center–edge of acetabulum (orange).



B Lateral of proximal femur Note bump (red) on the neck with adjacent cyst (yellow), due to femoroacetabular impingement.



C False profile of acetabulum The *sourcil* is outlined by blue. B: X-ray beam (brown). CEA: center–edge angle, subtended by a line drawn from the center of the head to anterior articular margin of acetabulum with a vertical line. Coverage (d:D) is measured as a ratio determined by a vertical line from the anterior articular margin of acetabulum (d) to the diameter of the head (D).

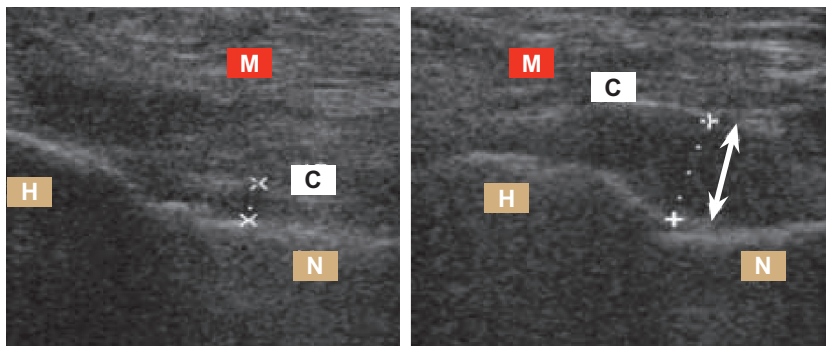


D Version of acetabulum The acetabulum on the left is retroverted: the anterior wall (blue) crosses (red) the posterior wall (green), and the ischial spine is visible (orange). On the right, where version is normal, anterior and posterior walls do not cross, meeting at the lateral margin of acetabulum, and the ischial spine is hidden behind the acetabulum.

Imaging

Röntgenogrammes These are the foundation of imaging for the hip.

- In the anteroposterior projection of the pelvis, symmetry of the transverse diameters of the obturated foramina ensures neutral [A]. In the standing position, tip of coccyx to symphysis pubica distance 1 to 3 cm ensures correct pelvic tilt. The top of the femoral heads may be used to determine limb lengths, assuming a standing position with knees straight. Medial rotation of the lower limbs neutralizes anteversion of the femora for true coronal relationship with acetabula. The angle between a vertical through the center of the head of the femur and a line drawn from the center to the edge of the articular margin of acetabulum is a measure of coverage. The normal range is 25 degrees to 45 degrees: less represents insufficient coverage, as in developmental dysplasia of the hip, while more represents overcoverage, as in pincer impingement or *protrusio acetabuli*.
- Lateral projection of the proximal femora may be obtained by supine abduction with external rotation (“frog-leg”), placing the feet together with the knees flexed to 90 degrees [B]. In the painful or unstable hip, an easier and safer view is taken supine with the contralateral hip flexed 90 degrees and the x-ray beam directed “cross-table” at 45 degrees to the symptomatic limb. Soft tissue may obscure details. In the operating room, a lateral projection of the proximal femur may be obtained by flexing the hip to 45 degrees while preserving neutral rotation, and rotating the image intensifier 45 degrees away (modified Dunn).
- Supine abduction with medial rotation of the femora (von Rosen) assesses center of rotation of the head of the femur compared with acetabulum and simulates redirection osteotomy of the acetabulum.
- The *faux profil* (“false profile”) provides a true lateral of the acetabulum, based upon its version [C]. The patient stands with affected hip against the film, pelvis rotated 65 degrees toward affected side, and affected foot parallel to film. The angle between a vertical through the center of the head of the femur and a line drawn from the center to the edge of the articular margin of acetabulum is a measure of anterior coverage. Less than 20 degrees is abnormal.
- Version of acetabulum [D]. Normal version presents a symmetric opening of the cup to the front of the hip, seen on anteroposterior projection as an anterior wall that covers half of the posterior wall, which it meets at the lateral margin of acetabulum. In retroversion of the acetabulum, the anterior wall advances on the posterior wall, progressively crossing it from lateral to medial. Retroversion rotates the ischial spine anteriorward and medialward into profile. Note that projection of the walls of the acetabulum is influenced by pelvic tilt, which must be correct to correctly assess version of acetabulum and crossover.



E Ultrasonography for hip effusion The joint capsule is elevated (*white*) off the femur by fluid. H: head of the femur. N: neck of the femur. C: capsule. M: muscle.

Ultrasonography This is the standard for screening and evaluation of hip dysplasia from neonatal period to 4 to 6 months. Ultrasonography is useful for evaluating the hip for effusion [E]. It is quantitative and qualitative, demonstrating volume of fluid and type (e.g., clear vs. turbid). It is harmless, is practical, and may be performed with the child awake, by contrast with MRI, which provides more detail at the expense of complexity and sedation. Other applications include assessment of severity of slipped capital femoral epiphysis, of head size and containment in Legg-Calvé-Perthes disease, and of neck continuity in coxa vara. This imaging technique is underutilized, despite the fact that it has the distinct advantage of being practicable by an orthopaedic surgeon in office.

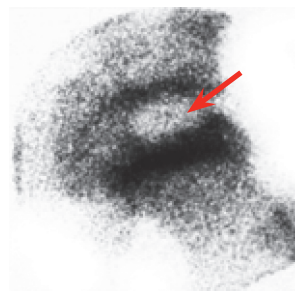
Scintigraphy This is a physiologic imaging modality, providing a measure of bone turnover and perfusion. After excluding pyarthritides by an ultrasonogram showing no effusion of the hip, a scintigram evaluates the lower limb for osteomyelitis as a cause of limp. Inflammatory conditions may be localized, such as osteoid osteoma of the proximal femur. Hypoperfusion may be detected, such as of a slipped capital femoral epiphysis with an acute or unstable or severe presentation, or of the proximal epiphysis of the femur during the initial ischaemic stage of Legg-Calvé-Perthes disease [F]. Hyperperfusion of the proximal physis of the femur may be an alert to a preslip state.

Arthrography Arthrogramme confirms articular penetration, as in arthrocentesis in infection or for diagnostic injection when a locus of pain is obscure. The technique aids operative evaluation of dislocation and reduction in developmental dysplasia of the hip. It provides further static definition of the deformed head of the femur in Legg-Calvé-Perthes disease [G] and permits dynamic assessment of hip motion. Arthrography enhances magnetic resonance imaging.

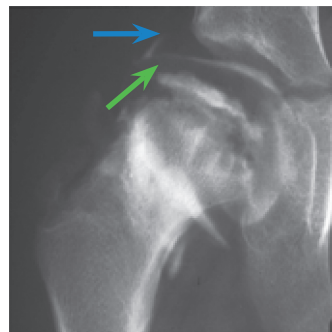Magnetic resonance imaging This modality provides greatest detail, in particular of intra-articular structures such as labrum in developmental dysplasia of the hip [H], epiphysis with altered perfusion, physis in slipped capital femoral epiphysis, a mobile body after trauma, or effusion as a first or only sign of disease. Rapid sequence protocol assesses location of the head of the femur after reduction of a dislocated hip, without X-radiation. Balance this with less availability, less agency for the surgeon, increased cost, and the fact that in the first decade sedation may be necessary to avoid motion artifact. Gadolinium may be injected for arthrography or *per venam* to measure proteoglycan content of cartilage.

Computerized tomography CT gives the most accurate depiction of osseous architecture, in particular as part of preparation for osteotomy of the pelvis or femur in the setting of complex deformity. It is less distorted than MRI by metal, as in postoperative evaluation of implant placement or healing of osteotomy [I]. Rapid sequence protocol assesses location of the head of the femur after reduction of a dislocated hip, but with radiation exposure in contrast with MRI.

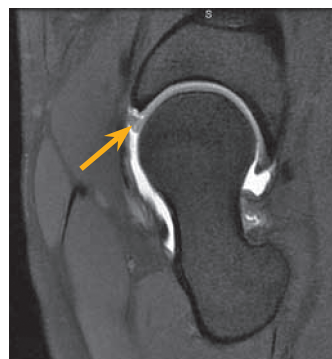
I CT to evaluate implant placement In this severe slipped capital femoral epiphysis, uncertainty about location of screw was resolved by CT, showing transarticular fixation (*red*).



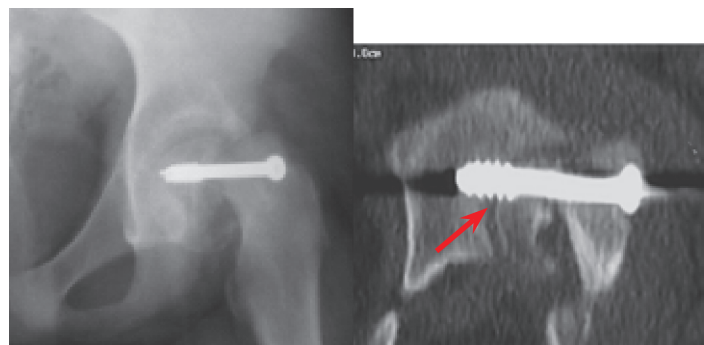
F Scintigraphy of the hip Focal lateral and anterior reduced uptake in the epiphysis (*red*) indicates ischaemic stage at presentation of Legg-Calvé-Perthes disease.

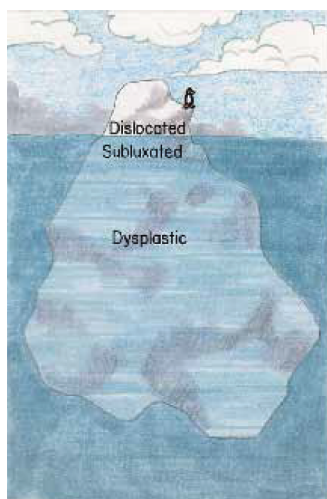


G Arthrography of the hip The articular surface is outlined showing flattening of the epiphysis (*green*) by the lateral acetabulum (*blue*) in Legg-Calvé-Perthes disease.

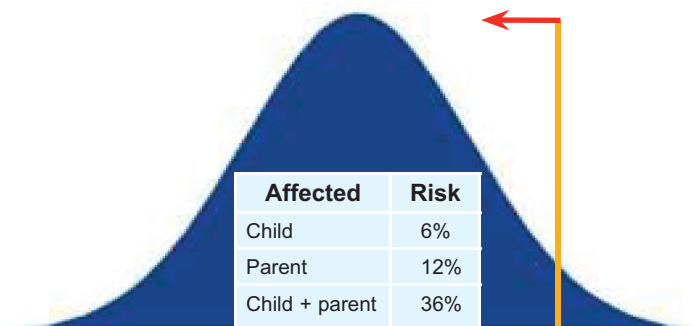


H MRI arthrography of the hip Gadolinium (*white*) fills the gap between acetabulum and anterior labrum, which is cystic and detached (*orange*) due to chronic stress concentration on a deficient anterior wall.

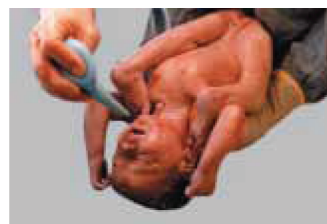



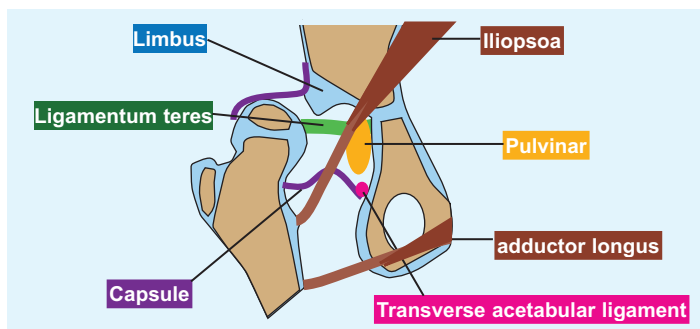
A Spectrum of hip dysplasia
Dislocated hips are usually diagnosed during infancy, but hip dysplasia may not become evident until adult life, when it presents as degenerative coxarthrosis.



B Inheritance of DDH Liability curve for affecteds. Polygenic inheritance follows a normal distribution: threshold (orange) above which a disease will be expressed (incidence) is lowered in first-degree relatives (red).



C Breech This extrinsic cause of DDH represents a problem of packaging.



D Obstacles to reduction These may be divided into extra-articular and articular.

Abduction	% normal
45 degrees	0%
60 degrees	<10
75 degrees	45%
90 degrees	45%

E Hip abduction Normal infants will rarely have <60 degrees of hip abduction.

DEVELOPMENTAL DYSPLASIA OF THE HIP

Dysplasia refers to “bad” (Greek *δυσ*) “formation” (Greek *πλασσω*) of the hip. The term developmental encompasses cases that are congenital, present “at birth,” and those developing after birth, in which the neonatal evaluation is normal.

Incidence

Hip laxity affects up to 1% of neonates, whereas clinically detectable DDH affects 0.1% of the Caucasian population. The true incidence remains unclear [A]. Physical examination and even screening ultrasonography will have a certain miss rate for several reasons, including operator error, single evaluation of a developing condition in a developing skeleton, and the use of indirect measures as proxies for final outcomes. As a result, DDH may underlie up to one-third of adult coxarthrosis.

Cause

The causes of DDH may be divided into intrinsic or extrinsic. The former represents polygenic inheritance (“problems of production”), in which a characteristic is controlled quantitatively by more than one gene (the quintessential example is height) [B]. The latter refers to “problems of packaging”, of which the most significant factor is breech, with oligohydramnios and primigravida uterus being relative factors [C]. Girls and the left hip are affected more. Incidence in Caucasians is 1%: it is five times more in Lapland and five times less in Africans.

Pathoanatomy

The acetabulum is shallow and maldirected. The proximal femur shows antetorsion and coxa valga. When either or both are sufficiently severe, the head of the femur will dislocate. Extra-articular obstacles to reduction include iliopsoa, which constricts capsule such that it will display an hour-glass configuration with arthrography, and adductor longus [D]. Articular obstacles include labrum, which may be inverted and hypertrophied as the limbus, ligamentum teres, a thickened and tortuous ribbon, pulvinar, which expands (nature abhors a vacuum), and medial inferior capsule.

Evaluation

Physical examination This first is performed as part of neonatal screening, during subsequent routine evaluations, and as part of an orthopaedic consultation. Take what the child will give: relax if there is resistance, and resume with no force when the child relaxes. Test for instability in the entire range of hip motion.

HIP CLICK This is normal. It refers to a fine short-duration feeling or sound that is a manifestation of laxity stressing the limits of motion. Differentiate from a “clunk,” which represents the deep perception of a shift as the head of the femur dislocates and relocates. The sensation of the hip being displaced over the acetabular margin.

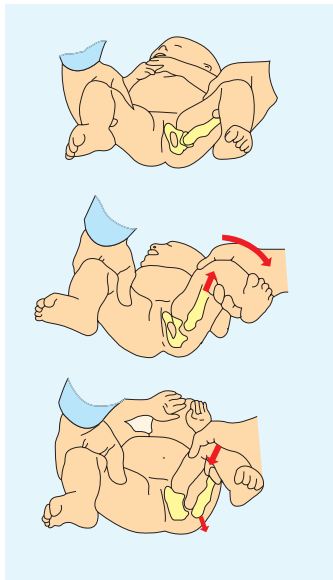
CUTANEOUS CREASES Asymmetry may be seen in long-standing dislocation in older children, where significant contracture has had time to develop. Asymmetric and extra creases affect approximately 50% of normal infants.

HIP ABDUCTION Abduction of the hip <60 degrees is concerning for DDH [E].

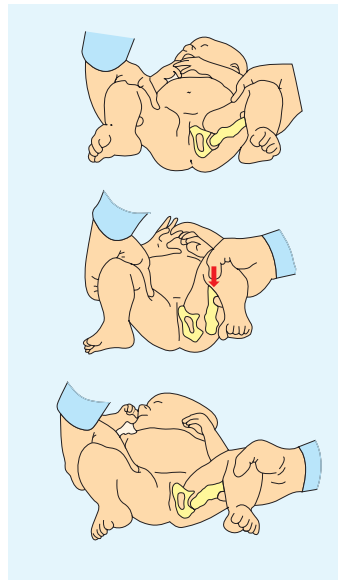
BARLOW SIGN Dislocation of a reduced hip [F]. With adduction of the hip, the head of the femur moves out over the rim of acetabulum. There is no need for posteriorward force: gravity will suffice.

ORTOLANI SIGN Reduction of a dislocated hip [G]. With abduction and anterior translation applied to the trochanter major, the head of the femur moves into the acetabulum. Prolonged dislocation may result in sufficient contracture to resist this manoeuvre, producing an “Ortolani negative” hip. The only sign may be limited abduction. The symmetry of bilateral presentation may obscure detection.

LOWER LIMB LENGTH DISCREPANCY The head of the femur, taking with it the rest of the limb, rests behind a dislocated hip, producing a lower limb length discrepancy [H].



F Barlow sign A reduced hip is dislocated by adduction, posteriorward under force of gravity.

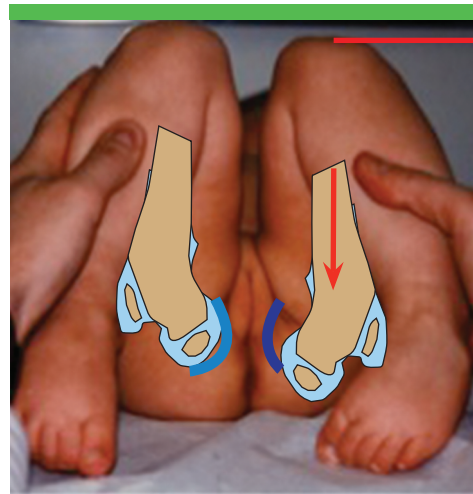

G Ortolani sign A dislocated hip is reduced by abduction with anterior translation applied to trochanter major, perceived as a "clunk."

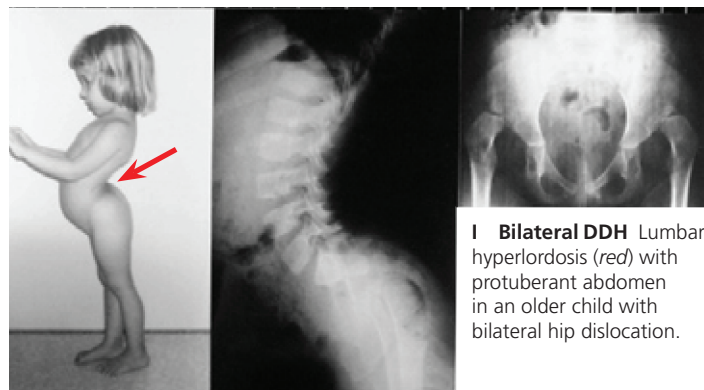
LUMBAR LORDOSIS Dislocation in which the hips are displaced significantly craniad, and posteriorward is accompanied by anterior pelvic tilt and flexion contracture of the hips. The child compensates by hyperlordosis of the lumbar spine to maintain sagittal balance [1].

GAIT The dysplastic acetabulum, without or with subluxation, is silent in the first decade. Hip dislocation produces a Trendelenburg gait due to craniad displacement of trochanter major with shortening and thereby weakening of hip abductor muscles.


PACKAGING SIGNS As part of the extrinsic causation of DDH, other parts of the musculoskeletal system may manifest deformation, including plagiocephaly, torticollis, and metatarsus adductus. The natural history of these is benign, with spontaneous resolution without active treatment. A corollary is DDH as a packaging sign in association with congenital dislocation of the knee.



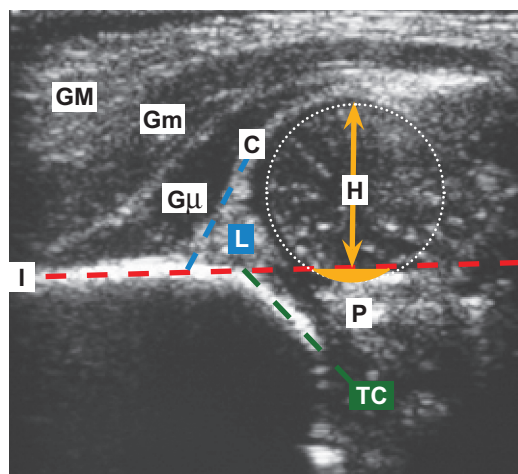
H Galeazzi or Allis sign Posterior displacement of the head and rest of the femur produces a limb length discrepancy that is exposed as differential knee heights.



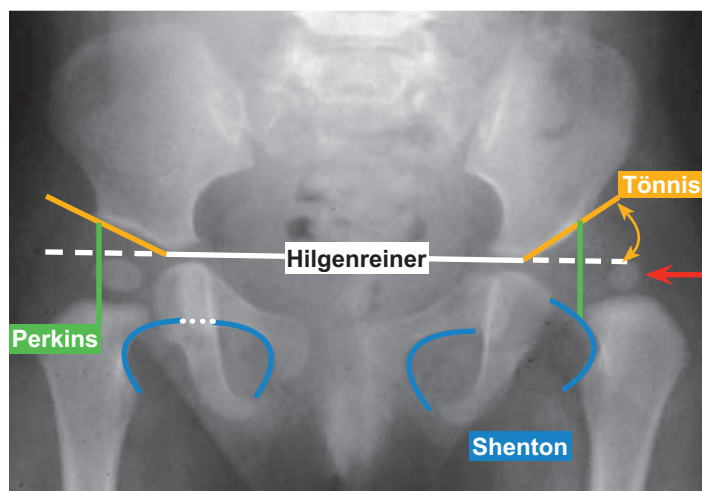
I Bilateral DDH Lumbar hyperlordosis (red) with protuberant abdomen in an older child with bilateral hip dislocation.



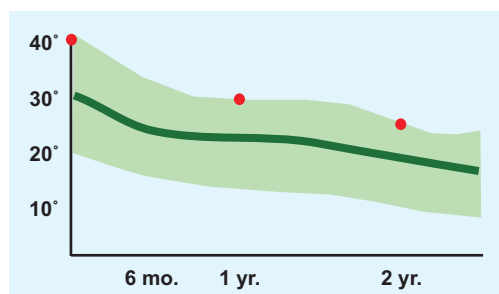A Imaging of DDH Green: ultrasonography. Grey: röntgenography. Red: MRI.



B Ultrasonography of the hip Developmental dysplasia of the hip with dislocation may be assessed by a portable ultrasonographic machine in the examining room. H: head of the femur, unossified. P: pulvinar and other fibrofatty tissue in fossa of acetabulum. TC: triradiate cartilage, hypoechoic. L: labrum. C: capsule. I: ilium, G: gluteus muscle, M: maximus, m: medius, m: minimus. Ilium line is the reference (red). Measure d:D ratio for coverage of the head of the femur (orange). Measure α (green) and β (blue) angles to assess depth of acetabulum and displacement of the head of the femur, respectively.



C Röntgenography of DDH Left proximal ossific nucleus (red) is dislocated into lower lateral quadrant.



D Acetabular index by age This is measured in degrees. Light green bounds two standard deviations from the mean (dark green).

Imaging This varies according to age [A]. It is performed as part of neonatal screening, during subsequent routine evaluations, and as part of an orthopaedic consultation. Take what the child will give: relax if there is resistance, and resume with no force when the child relaxes. Test for instability in the entire range of hip motion.

ULTRASONOGRAPHY Indications include the following:

- Screening tool. This is a practice in continental Europe.
- Infant at risk. This is the practice in the United States, in order to limit the false-positive rate. The definition of at risk varies: it may be restricted to breech girl, or it may include family history.
- Unclear physical examination, for example, if a fixed dislocation is suspected (Ortolani negative hip), where a clunk would be absent.
- To evaluate the success of brace treatment of the dysplastic hip.

Ultrasonography is not indicated when the physical examination detects a dysplastic hip, because imaging will not change management. There are two forms.

- Static [B]. This defines architecture. α (for “acetabulum”) angle measures depth of acetabulum. This is mirrored by the β (next letter in the alphabet) angle, which measures deflection of the labrum by the head of the femur. d:D ratio measures coverage of the head of the femur by acetabulum.
- Dynamic. This evaluates stability and is an aid to the physical examination.

Normal α angle is >60 degrees. Most hips in range 43 degrees to 60 degrees “heal up” (Graf) without treatment. Normal d:D ratio is >0.5 . Ratio <0.2 suggests failure of Pavlik harness. The static method describes architecture of the hip. The dynamic method may be considered the imaging extension of the physical examination: this, along with the fact that it is most operator dependent and is best assessed live (missed unless the surgeon is operator), makes it less useful.

RÖNTGENOGRAPHY This is the standard after 3 months of age, when the proximal femoral ossific nucleus is visible [C].

- Hilgenreiner line is the horizontal reference for the pelvis.
- Perkins line is a vertical mark of the lateral edge of acetabulum. In dislocation, the proximal femoral ossific nucleus lies lateral to this, with migration above Hilgenreiner line with increasing severity. If the nucleus has not ossified, medial corner of proximal metaphysis is medial to Perkins line in the normal hip.
- Shenton line is drawn along proximal metaphysis of the femur and margin of obturated foramen. Projected discontinuity between these two lines can highlight subluxation when dislocation is not apparent (e.g., when nucleus has not ossified).
- Acetabular index (of Tönnis) measures inclination of *sourcil*, a theme that arches over DDH regardless of age.

Normative data for acetabular index aid assessment of the dysplastic acetabulum without subluxation or dislocation [D]. The following are guidelines for abnormal (precision is evasive because measurement error is up to 10 degrees, due to observer, patient position, and projection):

- Index above 40 degrees in the first year of life.
- Index above 30 degrees in the second year of life.
- Index above 24 degrees by 24 months of age.

COMPUTERIZED AXIAL TOMOGRAPHY This is reserved for complex deformity, and when metal is present that would distort MRI. Be judicious in requesting this modality, due to radiation exposure early in life that is cumulative.

MAGNETIC RESONANCE IMAGING This has a bimodal application. It evaluates location of the head of the femur after closed or open reduction and immobilization of the infant hip, utilizing motion insensitive sequences that show sufficient detail despite sacrifice in resolution, avoiding need for anaesthesia. MRI has illuminated hip dysplasia in the teenager and young adult.

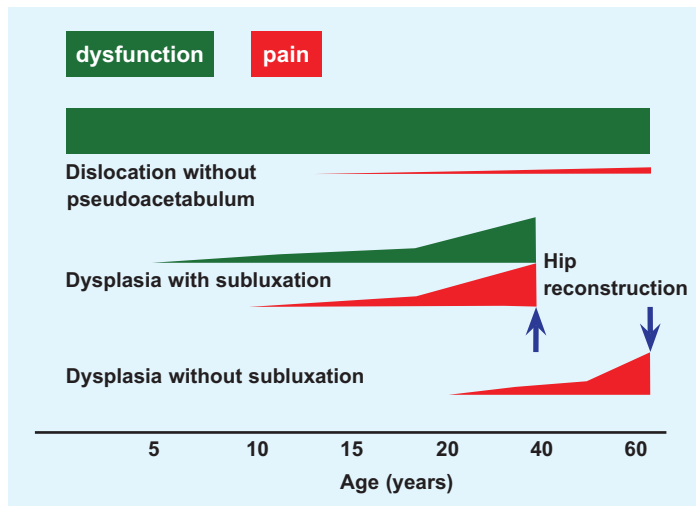
- Labrum. This is invisible to röntgenography or CT. Arthrography with gadolinium may highlight degenerative changes, such as tear or cyst.
- Impingement. This may be represented more accurately than by röntgenography, such as measurement of the α angle between the axis of the neck and a line drawn from center of the head to its junction with the neck in cam deformity of the proximal femur.
- Cartilage. Delayed gadolinium enhancement MRI of cartilage [E] is a measure of the biochemical composition of cartilage and as such of its health and mechanical properties. This contrasts with other structural or morphologic imaging modalities. An exogenous agent that may be nephrotoxic, the need for an exercise protocol to aid delivery to cartilage, and delay have stimulated development of other modalities. In sodium scanning, MRI may be used to measure relaxation times of the cation, which mirrors glycosaminoglycan concentration. Chemical exchange saturation transfer, T1r, T2 mapping, and diffusion-weighted MRI measure signal arising from protons as a biomarker, in particular hydroxyl and amide protons of glycosaminoglycans. Ultrasonography shows healthy cartilage as homogeneously hypoechogenic with a well-defined chondrosynovial boundary, characteristics that are lost in degenerative arthritis.

Natural History

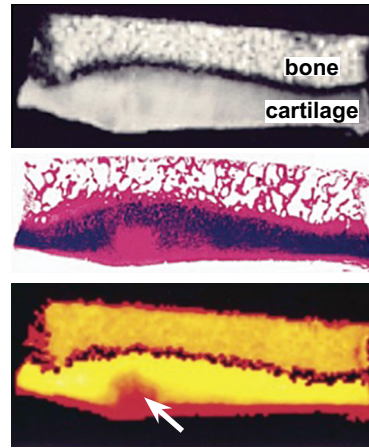
Untreated DDH may have the following outcomes [F, G].

- Acetabular dysplasia without subluxation. This presents in adulthood: cartilage degeneration results from stress concentration, according to the formula Pressure = Force/Area.
- Acetabular dysplasia with subluxation. This presents in childhood. Lack of concentric reduction significantly reduces surface area of contact, concentrating contact pressure. This is exacerbated by micro-motion that shears cartilage.
- Acetabular dysplasia with dislocation. This in turn may be divided into without or with pseudoacetabulum. The former leads to functional disability produced by shortening and weakening of hip abductors, including Trendelenburg gait, fatigue pain, and restricted hip motion. The latter is associated with disabling pain due to osseous erosion between the head of the femur and ilium.

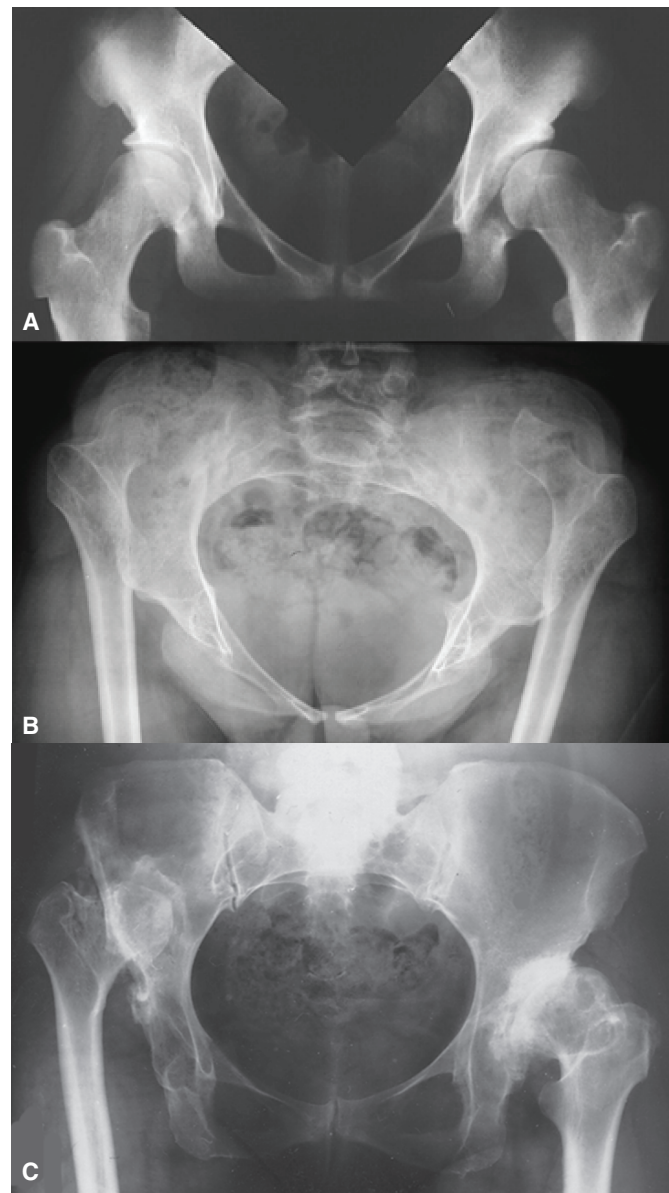
In one-third of patients treated for DDH (from bracing to operation), initial success will be followed by residual disease requiring secondary treatment. This is the rationale for long-term follow-up, through maturity. Treatment is mechanical and not more fundamental for a disease that has multiple causes, including genetic. Treatment aims to bring a dysplastic hip into the normative range and relies on it *sua sponte* to continue to grow appropriately once acetabulum and femur are correctly aligned. Such follow-up is akin to evaluation of height and weight at well checks by the paediatrician: a child in the 50th percentile may fall off the charts with growth.



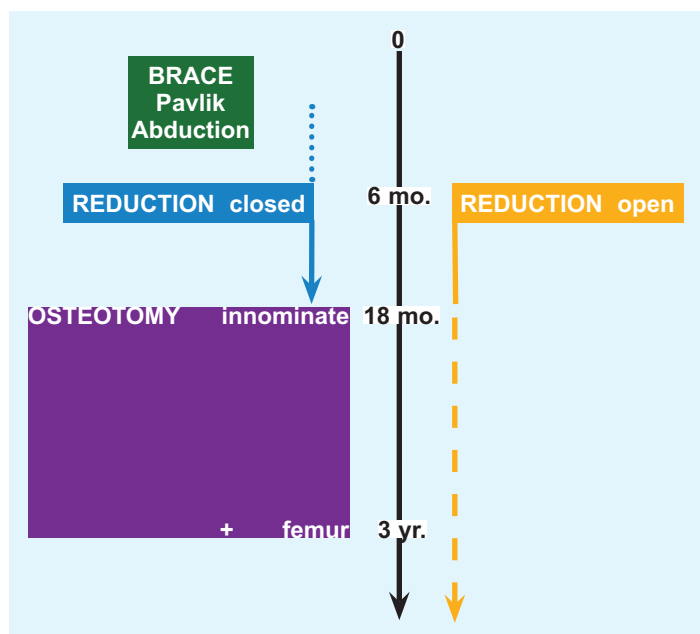
G Dysfunction and pain from DDH.



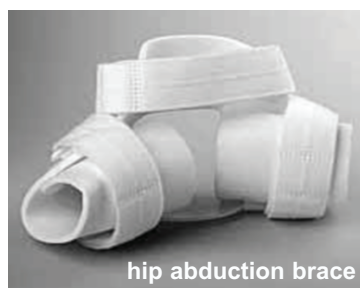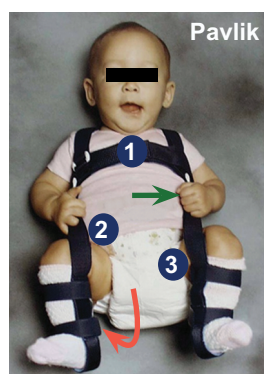E Delayed gadolinium enhancement MRI of cartilage (dGEMRIC) Gadolinium concentrates in degenerated cartilage (white arrow). The extracellular matrix is depleted of glycosaminoglycans, of which negatively charged carboxyl and sulfate groups otherwise would repel the anionic contrast agent.



F Natural history of untreated DDH. A. Asymptomatic young adult treated for bilateral DDH from infancy with residual dysplasia without subluxation. B. Middle-aged adult with waddling gait and no pain, with bilateral high dislocations. Note pelvic inlet view due to hip flexion contractures, with associated lumbar hyperlordosis. C. Poor outcome of DDH, with bilateral severe hip pain. Left hip subluxation with end-stage degeneration, and right hip dislocation with pseudoacetabulum.

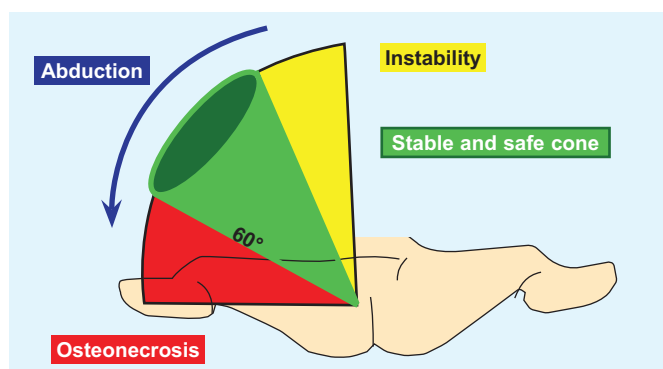


A Treatment of DDH according to age.

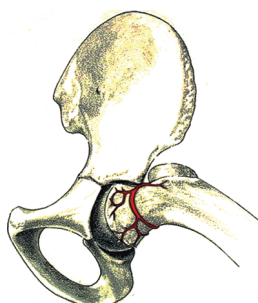


B Brace treatment of DDH 1: Allow comfortable passage of a finger under chest strap. 2: Adjust anterior strap (green) to flex hip to 90 degrees. 3: Keep posterior strap (red)

loose enough that hip abducts to 45 degrees while allowing the knees to come together easily.



C Position of hip in closed reduction "Cone" emphasizes the three dimensions of stability, which must be achieved safely without excessive abduction in order to avoid osteonecrosis, or insufficient abduction such that the hip redischlocates. Abduction >60 degrees brings the neck of the femur into contact with rim of acetabulum, where the medial circumflex artery can be occluded (arrow).



Management

Management is based upon age [A].

Birth to 6 Months

Pavlik harness This follows the principle of dynamic reduction: the child may move the limbs, which return to the favorable position for reduction and for stimulation of triradiate cartilage by the head of the femur when the child is still (including sleep). It is "simple, nondisturbing, and cheap" (Pavlik), hence its broad acceptance [B]. The straps, which are adjusted to maintain moderate force and to account for growth, are applied so that the hips are flexed to 90 degrees and abducted to 45 degrees while remaining readily adductable to neutral [B].

For the hip that rests located (Barlow or subluxatable), the harness is worn full time for 6 to 12 weeks. Treatment concludes once ultrasonographic or röntgenographic metrics have normalized, or if they have not done so by 12 weeks, at which point an alternative treatment is indicated.

For the Ortolani hip, the harness is applied and adjusted as necessary to convert to a Barlow hip over 3 weeks. Persistence of an Ortolani hip is a failure and an indication for alternative treatment. Restriction of the hip in a dislocated position may lead to deformation of the head of the femur and rim of acetabulum, worsening deformity. It also increases development of contracture of the hip. Both outcomes undermine subsequent treatment: the hip is more unstable, and contracture reduces likelihood of success with closed management.

There are other pitfalls of Pavlik harness. Do not overtighten the stirrups (e.g., to improve reduction of a very unstable hip): the posterior straps will abduct too much and risk the blood supply and osteonecrosis of the hip, while the anterior ones will hyperflex the hips and can cause a compressive femoral neurapraxia. While to the surgeon this is "simple" treatment, it may be confusing to parents: if you allow parents to remove the harness (e.g., to wash the child), spend time educating and follow-up with them to make sure they have reapplied the harness correctly.

The success rate of Pavlik harness is 80% to 90%. The Ortolani hip, bilateral disease, and increasing age reduce effectiveness. It is not indicated for teratic (e.g., arthrogryposis) or neuromuscular hip dysplasia.

Rigid immobilization This is indicated when Pavlik harness fails. For the persistent Ortolani hip, apply a hip abduction brace and follow Pavlik harness principles. For persistent abnormal imaging after 12 weeks of Pavlik harness treatment, apply a hip abduction brace full time until normalization of metrics. For a fixed dislocation (Ortolani negative hip), move to closed or open reduction.

6 to 18 Months

Closed reduction This is performed with general anaesthesia, in order to allow for arthrography and tenotomy of adductor longus. If there is contracture of the adductor longus origin, as determined by palpation with hip abduction, or if this necessitates excessive abduction to stabilize the hip, section the tendon to reduce the force of reduction. This may be performed through a stab incision after digital percutaneous isolation distal to the inguinal crease. Insert the blade over the lateral edge of the tendon and advance medialward away from the femoral vessels. A small incision and dissection avoids injury to the external pudendal artery (ramus of femoral artery), which accounts for at times considerable bleeding after percutaneous section. Excessive abduction risks compression of medial circumflex artery against the rim of acetabulum [C]. Excessive force of reduction adds direct compression of the head of the femur. If the hip reduces with a sufficiently stable and safe cone, apply a hip spica cast. If reduction is insecure, convert to an open reduction. If there is uncertainty, an arthrogramme may add clarity.

ARTHROGRAPHY Insert needle with trocar medial distal to inguinal crease raising the hand 30 degrees above the horizon directed at a point between anterior superior iliac spine and ipsilateral shoulder [A]. Alternatively, eliminate rotation of the hip and approach it laterally over trochanter major. Contact the neck of the femur (not the head and not the joint), relax force of insertion, and inject. Start with saline to confirm entry (so as not to obscure the joint by contrast reagent infiltrating the juxta-articular soft tissues), then just enough dilute contrast reagent to outline articular surfaces. Image intensifier assists. If there are significant obstacles to reduction, as evidenced by medial pooling of contrast due to lateral displacement of the head of the femur, open the hip. An inverted limbus may be a harbinger of persistent acetabular dysplasia despite successful reduction.

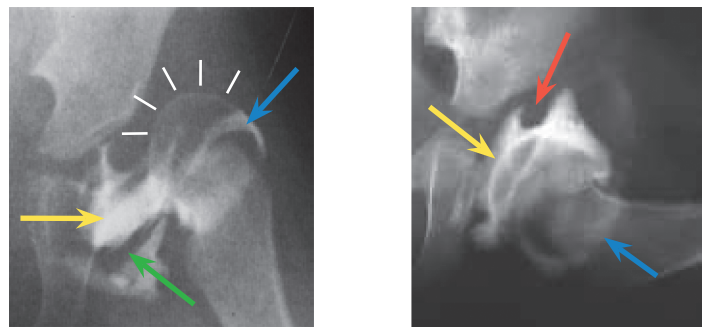
Open reduction The indication for this is articular obstacles to safe and stable closed reduction [B]. The hip may be approached anterior (Smith-Petersen) or medial [C]. The former is performed through an oblique incision in the “bikini line” (Salter). The latter, performed through a transverse incision centered on adductor longus origin one finger breadth distal to inguinal crease, may be divided according to relationship to the medial muscles of the hip (the adductor longus is sectioned). Ludloff described the “bloodless” approach between pectineus and adductor brevis. A more posterior medial approach travels between adductor brevis and adductor magnus. A more anterior medial approach follows the interval between pectineus and femoral vessels.

The anterior approach is familiar and utilitarian, including for osteotomy at an older age. Release of medial and posterior obstacles to reduction is blind to the medial femoral circumflex vessels, from which this approach is remote. A capsulorrhaphy is possible, which reduces redundancy of the dislocated hip capsule and adds a soft tissue restraint to redislocation. The medial is a more geographically direct approach to the obstacles to reduction. The medial femoral circumflex vessels are directly in its path, which lowers the risk of injury as these may be knowingly isolated and protected.

The anterior approach includes fractional lengthening of the iliopsoa at the brim of pelvis; the muscle is released from the trochanter minor in the medial approach. Do not make radial cuts, excise, or otherwise injure the limbus: just evert it out of the way. If you cannot see the entire acetabulum (horseshoe-shaped articular cartilage and fossa), take more time, and use a head lamp if necessary: all obstacles must be released completely, for a gentle and unequivocal reduction.

Immobilization in spica cast This follows closed or open reduction. The Latin term *spica* describes the manner in which strips of cast material are rolled in a crossing and layered pattern resembling an “ear of corn.” The child is placed in the “human position” (which Salter contrasted with the frog-leg), to contrast with the original technique of Lorenz, in which the hip was forcibly and maximally abducted to ensure and maintain a reduction in the older child [D]. After the child is aroused and has been mobilized in the cast, an MRI is obtained to ensure maintenance of reduction [E]. The cast is applied for 3 months, with a change under anesthesia at 6 weeks to accommodate growth and to permit physical examination of the hip as well as arthrography if necessary. After casting, a brace is worn until normalization of röntgenographic metrics or 18 months of age.

Traction There is no consensus. It is indicated for DDH with dislocation that is irreducible or requires considerable force to do so. Advocates point to gradual stretching of stiff pericoxal soft tissues such that closed reduction may be possible with less force and to a reduced rate of open reduction. The counterargument is based upon modern surgical techniques that significantly reduce risk and obviate the need for this closed method of treatment. Apply traction for 3 to 6 weeks, at home in 45 degrees of flexion and 30 degrees of abduction, with regular evaluation of the level of dislocation in order to estimate when the hip may dock without excessive force [E]. The debate surrounding traction for DDH resembles that surrounding halo traction for severe spine deformity.



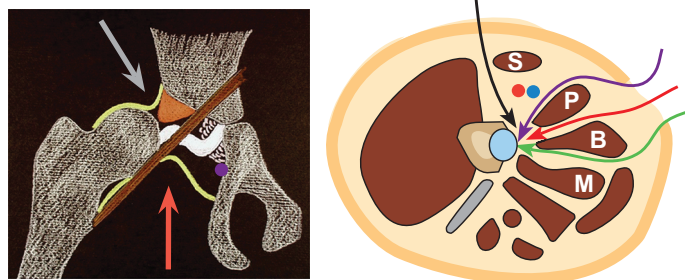
A Arthrography of the dislocated hip In the dislocated position (white), there is a medial contrast pool, which is eliminated with reduction (yellow). The ligamentum teres connects the head of the femur with fossa of acetabulum and displaces contrast (green). Contrast outlines zona orbicularis (blue) and limbus (red), which remains inverted despite reduction.

Extra-articular	Articular
Adductor longus	Capsule
Iliopsoa	Inverted limbus
	Ligamentum teres
	Pulvinar
	Transverse acetabular ligament

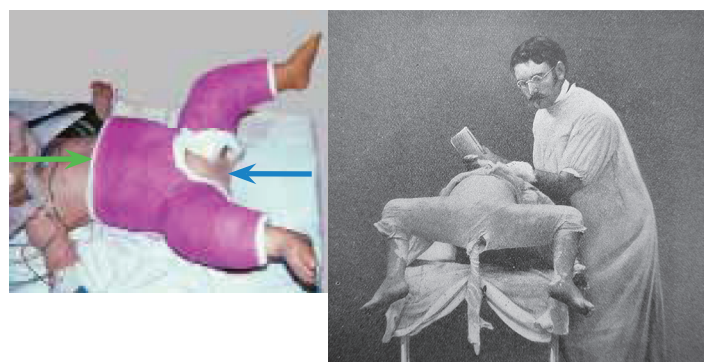
B Obstacles to reduction

These may be grouped in two. Section tendons to lengthen iliopsoa (at the brim of pelvis by anterior approach or off trochanter minor

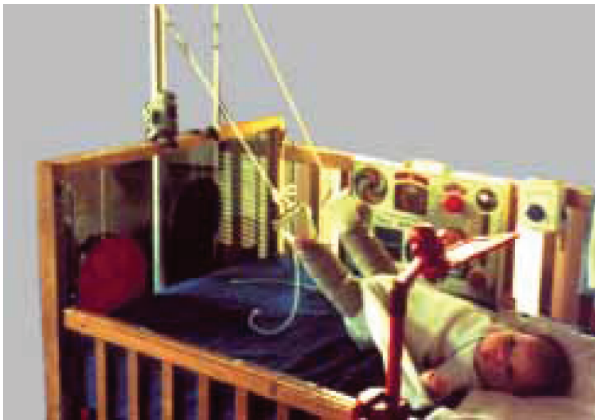
by medial approach) and adductor longus. Excise pulvinar and ligamentum teres, which is a guide to the fossa of acetabulum and transverse acetabular ligament. The latter is sectioned along with the medial inferior capsule to expand the space for reduction of the head of the femur. Reflect an inverted limbus out of the way.



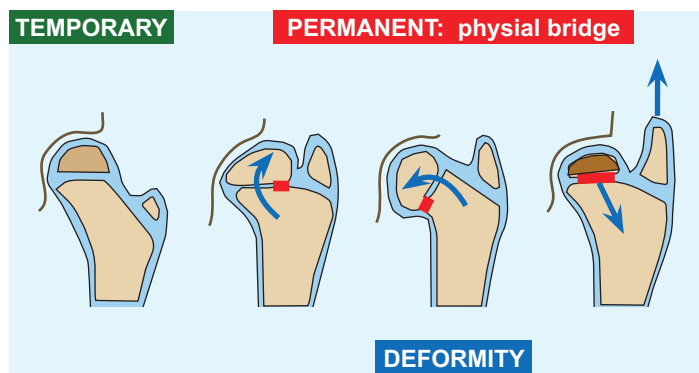
C Approach to the hip for open reduction The medial approach (red) is more direct than the anterior approach (gray). The anterior approach (black) is lateral to femoral vessels. There are three medial approaches (purple, red, green). P: pectineus. B: adductor brevis. M: adductor magnus. S: sartorius.



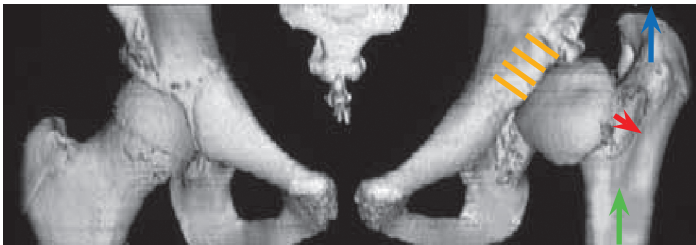
D Spica cast after closed or open reduction In the human position (right), hips are flexed to 90 degrees and abducted to 45 degrees, in contrast with the frog-leg position of Lorenz (left). The perineum is exposed (blue): reinforce the cast so that you do not restrict access with a dowel. Leave room for abdominal distension (green).



E Traction At home, reduces cost and stress for child and family.



F Osteonecrosis after closed or open reduction of the hip The principal discriminator is formation and location of a physal bridge.



G CT of hip Three-dimensional reconstruction aids analysis of complex deformity, in this case consequent to osteonecrosis after open reduction of the left hip in infancy. The neck is very short (*red*), the anterior acetabulum is deficient (*orange*), the trochanter major is relatively overgrown (*blue*), and the limb is shortened (*green*).

Complications

OSTEONECROSIS This is the most grave complications. Early signs include the following:

- Failure of the ossific nucleus to appear after reduction
- Widening of the neck of the femur
- Fragmentation of the ossific nucleus

Osteonecrosis may be classified by time, as well as presence and location of physal bridge [F]. The mildest form is characterized by no physal bridge, limited to temporary irregularity of ossification that resolves spontaneously with no sequela. A lateral physal bridge may not be apparent for several years, tilting the epiphysis into valgus. Less commonly, a medial physal bridge shortens the neck into varus. Total epiphysis and physis involvement is least common but most severe, resulting in significant coxa brevis, relative overgrowth of trochanter major, and shortening of the limb [G].

In closed reduction, osteonecrosis was seen historically in up to 30% of cases, related to excessive force and abduction for reduction. Current practice has reduced this to <5%. After open reduction, the rate of permanent growth disturbance has been reported as high as 40%: this correlates with increasing age at operation beyond 1 year. Residual proximal femoral deformity results in dysfunction, for example, abductor weakness, and risks premature coxarthrosis. Treatment includes the following:

- Intertrochanteric osteotomy to realign coxa vara
- Lengthening osteotomy for coxa brevis to restore offset
- Distal-lateral transfer of trochanter major to lengthen hip abductors
- Timed physiodesis of contralateral limb for length equalization
- Acetabular osteotomy if the head of the femur is uncovered

Other complications pale by comparison, including redislocation, bleeding from a percutaneous tenotomy site, hip stiffness after emerging from cast, and skin breakdown. Follow-up reduction with imaging to make sure that the hip remains located; a better molded cast with modification of the hip position (e.g., restoring flexion lost during original casting by a tiring assistant) as necessary usually suffice for redislocation. Bleeding from a percutaneous site will stop with reinforcement of dressing. Hip stiffness resolves in the normal child, as will skin breakdown. Counseling families of these possibilities will mitigate their negative effect.

18 months to 3 years

This marks a transition in surgical management from soft tissue reconstruction to osteotomy, based upon the concept that deformity will worsen and remodeling may be insufficient without realignment.

Open reduction This is indicated for the dislocated dysplastic hip and is performed through an anterior approach, because of concurrent innominate osteotomy. Cut the tendon of adductor longus separately. Expose the lateral surface of the ilium to reveal any pseudoacetabulum and identify the margin of the true acetabulum. Test the force of reduction. If this is excessive, plan to add a shortening osteotomy of the femur. If reduction is relaxed, as is typical in this age group, an innominate osteotomy will suffice. The rationale for innominate osteotomy follows the proverbial Sutton law (although the words were placed in Willie Sutton's mouth by a Mitch Ohnstad reporting on his trial): the acetabulum is where the deformity is.

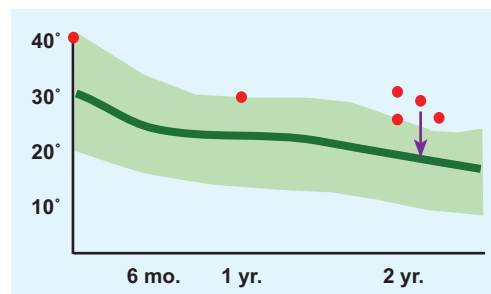
Osteotomy The indication is a dislocated hip or persistent acetabular dysplasia without dislocation, as determined by an abnormal acetabular index [A]. There are two principal types in this age group [B].

Single innominate osteotomy (Salter) This is the original of the modern era. It redirects an acetabulum that fits the head of the femur (not too large, not too flat) but does not cover it sufficiently. Divide the apophysis of the ilium sharply and repair precisely to minimize later deformation. Because this is a distalizing osteotomy, perform a fractional lengthening of the iliopsoa at the brim of the pelvis to avoid increased pressure on the head of the femur. Expose medial and lateral tables of the ilium, as well as greater sciatic notch, through which a Gigli saw (made by the Florentine surgeon to cut the pelvis in dystocia) may be passed subperiosteally to avoid injury to sciatic nerve and superior gluteal artery. Cut the ilium by drawing the Gigli saw lateralward, emerging proximal to the anterior inferior iliac spine. Harvest the anterior ilium proximally as an autogenous tricortical structural graft, or use an allograft. Open the osteotomy so that it hinges along the arcuate and pectineal lines and symphysis pubica, akin to a door. Correction may be augmented by translating the distal fragment lateralward, which is possible due to laxity in this age group. Insert the graft, and fix it and the osteotomy with antegrade steel wires that are left long for later removal.

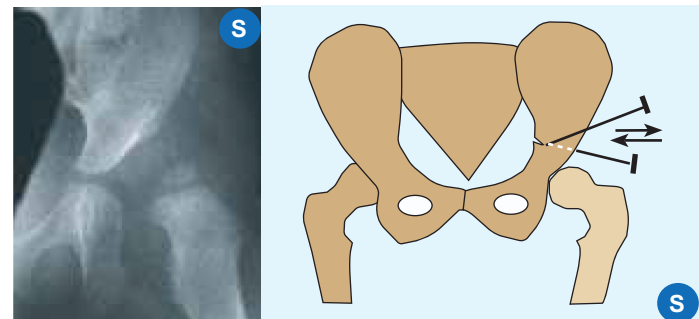
The length of the hinge restricts the extent and direction of correction. Lateral coverage is accompanied by oblique anterior coverage, which may lead to acetabular retroversion and femoral impingement. The instability produced by complete osteotomy of ilium requires fixation and a second operation for removal. In addition, the cut hemipelvis requires an opposite hemipelvis that is stable against which to hinge, thereby necessitating staged bilateral procedures.

ACETABULOPLASTY (PEMBERTON) This reshapes an acetabulum that is too large, indicating translation in addition to rotation of the head of the femur, and too shallow. It reduces the radius of curvature of the acetabulum as it deepens it. The approach is the same as for a single innominate osteotomy. Perform a curved osteotomy of medial and lateral tables of ilium beginning above the anterior inferior iliac spine and ending close but not into the triradiate cartilage, where the osteotomy hinges. Open the osteotomy and place a tricortical graft of appropriate height to correct the acetabular deformity. Compression of the graft by the incomplete osteotomy produces a stable interference fit.

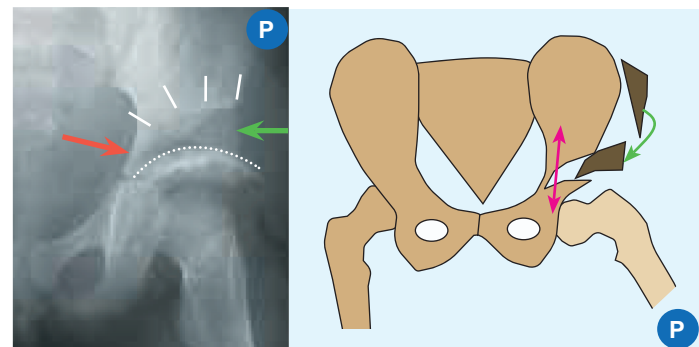
The posterior column of the pelvis is not disrupted: this inherent stability obviates the need for implants and permits simultaneous bilateral procedures. The angle of osteotomy, as well as the extent of medial corticotomy, may be varied to decouple anterior from lateral coverage, allowing modulation of the former without restricting the latter. It is contraindicated when the head of the femur is large, such as hypertrophy from previous operation or Legg-Calvé-Perthes disease: in this setting, the osteotomy may drive the head out of the acetabulum, increasing subluxation and reducing coverage.

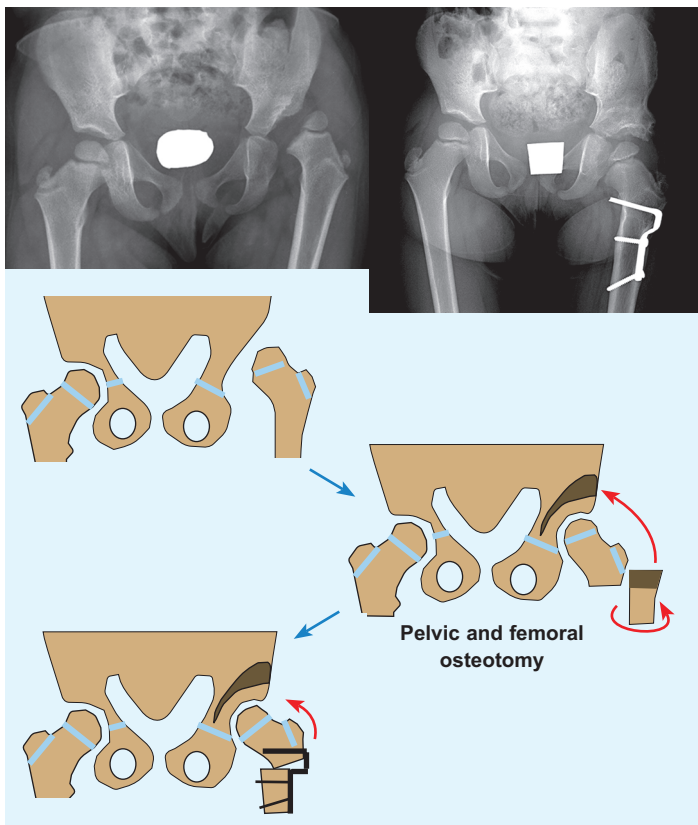


A Innominate osteotomy The procedure is indicated for persistent acetabular dysplasia, as measured by acetabular index (degrees), which is reduced into the normal range (purple).

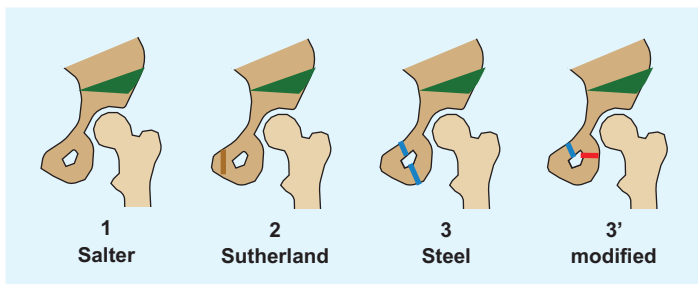


B Innominate osteotomy The Salter osteotomy (S) is linear and complete. The osteotomy may be opened and translated (orange) laterally. Because it is complete, the pelvis is destabilized, mandating internal fixation. The Pemberton osteotomy (P) is curved (dots) and incomplete. It hinges at the triradiate cartilage: because only the upper half of the acetabulum is displaced, a shallow acetabulum is reshaped to a smaller radius of curvature. Because the posterior column of the pelvis is preserved (red), no fixation is necessary. Both osteotomies are filled with a tricortical osseous graft (green).

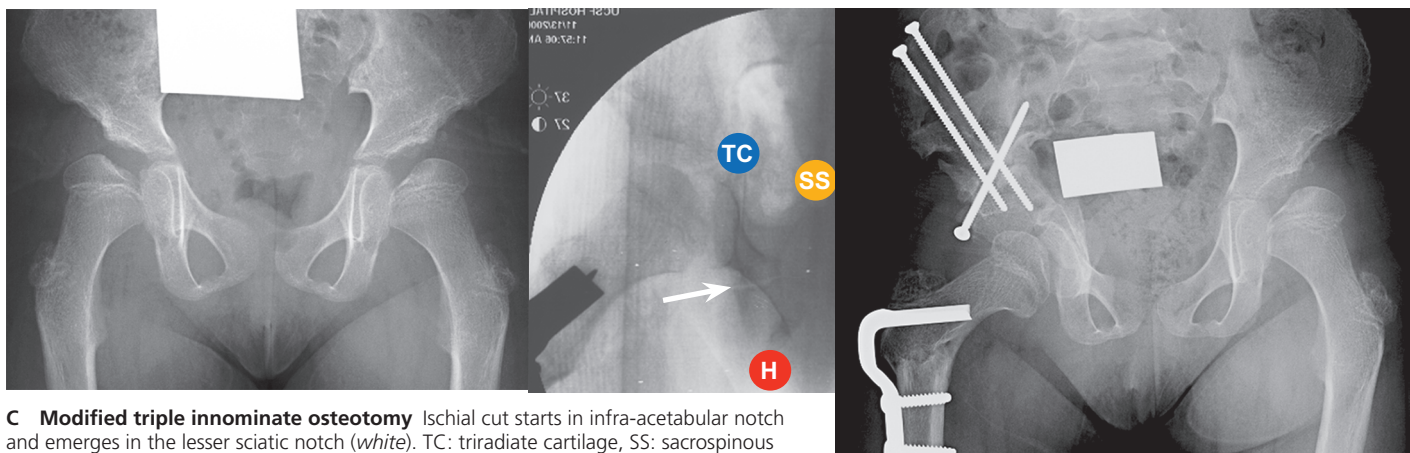




A Femoral osteotomy, open reduction, and innominate osteotomy The overlap of fragments necessary to reduce the head of the femur is cut and grafted to the pelvic osteotomy. The femur is derotated and tipped into varus to complete correction and fixed with an offset blade plate.



B Evolution of the innominate osteotomy Salter was first. Parasymphysis osteotomy (Sutherland) does not sufficiently improve mobility to justify dissection in an unfamiliar area. The triple (Steel) has been modified (red) to escape the hamstrings and thereby improve fragment mobility.



C Modified triple innominate osteotomy Ischial cut starts in infra-acetabular notch and emerges in the lesser sciatic notch (white). TC: triradiate cartilage, SS: sacrospinous ligament, H: hamstrings origin.

POSTOPERATIVE CARE Support the osteotomy with a spica cast or hip abduction brace for 6 to 12 weeks. Cast is standard, but brace is better tolerated by child and patient. Obtain röntgenogrammes 1 week after operation to ensure no displacement of osteotomy or graft. Six weeks are sufficient for osseous stability, but 12 weeks may be necessary for soft tissue remodeling in a very unstable hip.

Three to Six Years

There is no consensus on femoral osteotomy before this age, either to reduce the force of reduction and lessen the extent of soft tissue release, thereby reducing risk of osteonecrosis, or to better direct the proximal femur in order to stimulate remodeling of the acetabulum and thereby avoid innominate osteotomy. Three years of age is a guideline to long-standing DDH, beyond which dislocation may be associated with such severe pericoxal contracture that it cannot be released or overcome to permit safe and stable reduction. Shortening is necessary to sufficiently relax the soft tissue envelope [A]. Varus and derotation become more important with increasing age.

Cut the proximal femur. Perform an open reduction. Locate the head of the femur. Apply moderate tension to the distal femoral fragment and resect the overlap. Fix the femur with simple or blade plate. Perform an innominate osteotomy: use the resected femur as graft.

Six Years to Maturity

Treatment of a patient presenting with DDH with dislocation at this age is controversial. For unilateral disease, treat surgically for presentation in the first decade. For bilateral disease, do not operate. The rationale for the former is that asymmetry *per se* adds morbidity. Deformity (bone), contracture (soft tissue), and arthritis (cartilage) that accompany this late a presentation call for the prudent approach of acceptance and accommodation to the disease rather than treatment with outcomes that will be worse than the disease, including redislocation, pain, and stiffness.

Reconstructive osteotomy Treatment of persistent dysplasia without dislocation and without significant arthritis includes osteotomy of innominate bone and femur. Osteotomy of the femur may be indicated for correction of deformity resulting from growth disturbance after prior treatment. It also adds another locus for correction of severe deformity. Innominate osteotomy is more extensive because an older child will be stiffer and have a potentially more dysplastic acetabulum requiring further displacement to sufficiently cover the head of the femur. Add cuts to mobilize the acetabulum: hence the evolution of the single iliac osteotomy to the double then the triple [B].

TRIPLE INNOMINATE OSTEOTOMY The three cuts are of ilium, of os pubis, and of ischium. This has been modified to bring the cuts closer, based upon the principle that correction is most effective at the site of deformity, namely, the acetabulum, and in order to escape tethering by pericoxal soft tissue [C]. An open triradiate cartilage precludes peri-acetabular osteotomy. Cutting the ischium through the infra-acetabular

Notch proximal to the tuberosity liberates the fragment from the hamstrings. The sacrospinous ligament remains a constraint to acetabular positioning. The iliac cut is the same as for the single osteotomy, as is the approach. Medial dissection is extraperichondrial to avoid injury to the triradiate cartilage. The os pubis is cut by a Gigli saw passed through obturated foramen round the superior ramus, subperiosteally to avoid the obturator neurovascular bundle. The ischium is cut by an angled osteotome passed distal and posterior between the neck of the femur lateral and tendon of iliopsoa medial to the infra-acetabular notch and driven horizontally into the lesser sciatic notch. The image intensifier aids location, direction, and extent of osteotomy. Complete disengagement of acetabular from the pelvis underlies the potency of this osteotomy. Conversely, pelvic disruption necessitates internal fixation, and wide displacement risks delayed or nonunion, in particular in the older child.

Salvage osteotomy This is indicated for persistent dysplasia without dislocation but with significant arthritis. It may serve as a bridge between reconstruction and ablation. In salvage osteotomy, a raw osseous surface is created to cover the head of femur, with joint capsule interposed. The hyaline cartilage surface is expanded to include a fibrous layer (to expect cartilage metaplasia is optimistic). Both types of salvage osteotomy start at the junction of lateral ilium and labrum, which is pried down to mark the level for the added osseous surface at, and not above (where it will result in a step off), the articular surface [D].

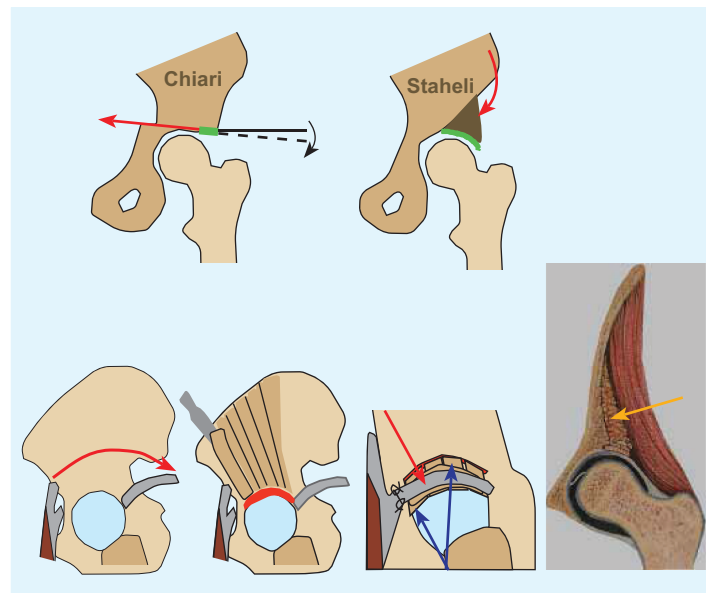
CHIARI OSTEOTOMY A complete iliac cut is angled inferior lateral to superomedial in the coronal plane to complete the *sourceil* and retain the head of the femur. It is curved in the sagittal plane to follow the contour of the acetabulum. The femur is abducted as the distal fragment is displaced medialward to deepen the hip joint by means of the distal surface of the proximal fragment. Fix the osteotomy with screws.

STAHELI OSTEOTOMY This also is known as slotted acetabular augmentation and is a type of shelf procedure. Identify reflected head of rectus femoris, cut at the conjoined tendon, dissect off capsule, and preserve lateral attachment. Pry the labrum down and create a 1-cm deep slot parallel to its margin as wide as possible to maximize the weight-bearing surface. Harvest corticocancellous strips from the lateral table of the ilium. Cut strips to allow them to be contoured and of a length that will produce the desired center-edge angle based upon ante-operative röntgenographic planning, accounting for the depth of the slot. Place strips and secure them by sewing reflected head over them back to the conjoined tendon of rectus. Fill the space above the shelf with remaining osseous graft, which will be retained by the hip abductor muscles.

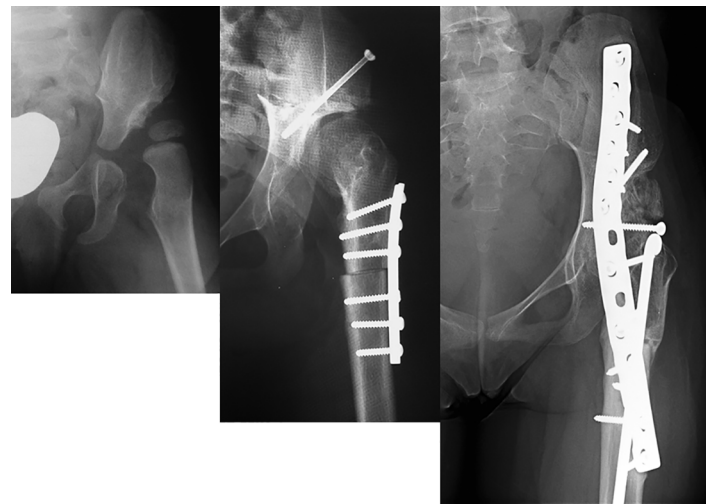The Staheli procedure is least traumatic and has the advantage of augmenting the acetabulum; as a result, it may be considered for conditions in which the head of the femur is enlarged, including Legg-Calvé-Perthes disease. Because it is performed through an anterior approach, posterior coverage is limited and total coverage is incomplete, despite the appearance in an anteroposterior röntgenogramme.

Hip ablation Ablative procedures, hip arthrodesis and hip replacement, should be delayed as long as possible. They are a surrender to unacceptable dysfunction (principally pain) and terminal joint disease.

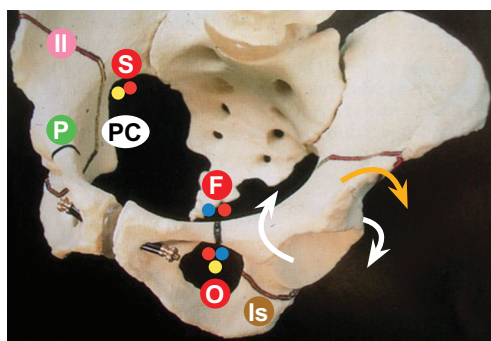
HIP ARTHRODESIS This is underutilized, increasingly unfamiliar to surgeons and unacceptable to patients, despite good outcomes, including ability to work and to bear children, a low rate of conversion to arthroplasty, and a willingness to have the same treatment again [E]. It relieves pain. It is durable: survivorship of hip arthrodesis is >20 years. It does not impose activity restriction. It may be converted reliably to a replacement, the principal determinant of success being function of abductor muscles. On the other hand, it eliminates motion. This alters function, both for daily living, such as donning socks, and for recreation. It alters gait, including visibly, characterized by short stance and prolonged swing, anterior pelvic tilt, and lumbar hyperlordosis. It transfers stress to low back and ipsilateral knee, which may become painful. The descent of arthroplasty, which provides pain relief without sacrificing motion, into younger age groups must be balanced by reduced longevity and multiple revisions [E].



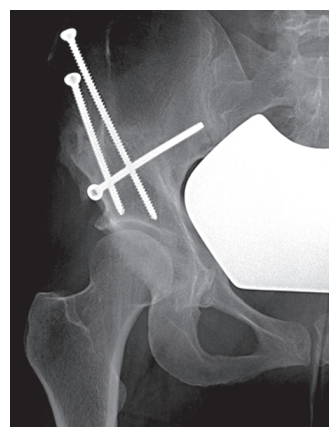
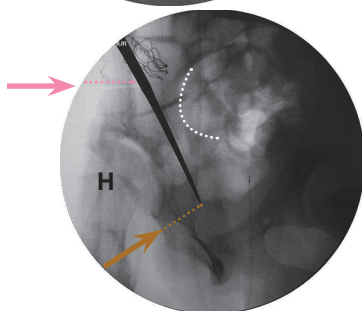
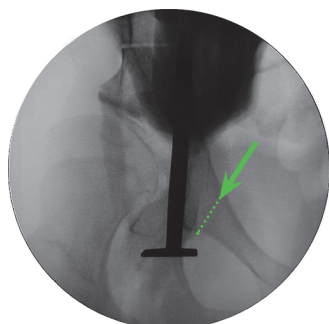
D Salvage innominate osteotomy Chiari cut the ilium obliquely to match the sourceil and displaced the acetabulum medialward. Staheli used the reflected head of rectus (*red*) to secure corticocancellous strips slotted at the edge of acetabulum (*blue*) and completed by additional harvested bone (*orange*).



E Hip arthrodesis The patient underwent six operations for DDH with dislocation from infancy to late teens, including a Chiari procedure to deepen a pseudoacetabulum, but pain persisted and was intolerable. The arthrodesis was performed through an anterior approach, where a plate may be applied as a tension band and the abductors are preserved for future reconstruction, and with the patient supine to ensure proper positioning of the limb: 20-degree to 30-degree flexion, 5-degree adduction, and 10-degree lateral rotation, and <2-cm limb length discrepancy. A femoral exsection (used as autogenous graft) was performed to return the head to the native acetabulum without stretching the sciatic nerve in anticipation of future reconstruction.



A Periacetabular osteotomy There are four principal cuts. P: pubic, Is: ischial, PC: posterior column, Il: iliac. The major neurovascular bundles to the lower limb pass by the surgical field. S: sciatic, superior gluteal artery, F: femoral, O: obturator.

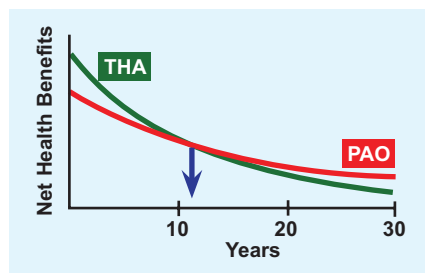


B Technique of periacetabular osteotomies Ischial cut is reverse and incomplete, by an angled osteotome (brown). Pubic cut is complete by a Gigli saw (green). Iliac cut is complete (pink) to a point midway between greater sciatic notch (white) and

acetabulum, whence posterior column cut (black) may be connected with ischial cut. H: head of femur.

Complication	Rate
Neural-major	1%
Vascular	<1%
Intra-articular osteotomy	1%
Loss of fixation	1%
Over-/undercoverage	≤10%
Nonunion	2%
Heterotopic ossification	≤10%
Neural - LFC	50%

C Complications of periacetabular osteotomy The operation is safe, as complications have declined with experience.



D Net health benefits after periacetabular osteotomy In mild coxarthrosis (CA), these become superior to total hip arthroplasty (THA) after approximately 10 years. Benefits are delayed with moderate coxarthrosis (blue) and may not be realized in severe coxarthrosis.

Maturity

The triradiate cartilage is closed; as a result, the posterior column may be preserved in redirectional innominate osteotomy.

Periacetabular osteotomy This is performed through an anterior approach with a 10-cm oblique incision [A]. Develop the superficial interval through sheath of tensor fasciæ latæ to avoid lateral femoral cutaneous nerve (akin to approaching the anterior aspect of distal radius through the sheath of flexor carpi radialis to avoid radial artery). Reflect iliopsoa off rectus femoris, which is preserved to avoid weakness, to expose anterior inferior iliac spine. Reflect iliocapsularis from underneath the rectus femoris, as well as the glutei minimus et medius, to expose the hip joint capsule. Follow iliopsoa tendon to trochanter minor. Dissect along medial table of the ilium into greater sciatic notch, staying subperiosteal to avoid sciatic nerve and superior gluteal artery, and leaving the lateral table and abductors undisturbed. Develop the interval between iliopsoa tendon and medial neck of femur posteriorward past obturator externus to the infra-acetabular notch. Reflect iliopsoa, which protects the femoral vessels, medialward beyond iliopectineal eminence, where the root of the os pubis may be exposed circumferentially subperiosteally in order to avoid the obturator neurovascular bundle.

Perform an anterior, medial, and lateral arthrotomy around the rectus femoris without detaching it, which has been associated with long term weakness. Inspect the labrum and repair or débride as indicated: the rate of labrum tear is low in the first two decades, increasing 10% per decade thereafter. Disease of the head and neck of the femur also may be addressed, such as cheilectomy.

Pass a Gigli saw through the obturated foramen and cut the os pubis from inside outward (antegrade cut may increase risk of obturator neurovascular injury). Insert an angled osteotome between iliopsoa tendon and medial neck of the femur to the infra-acetabular notch and cut the ischium posteriorward incompletely [B]. Cut the ilium beginning distal to the anterior superior iliac spine and ending lateral to the arcuate line at a point that bisects the posterior column. Cut the medial table of the posterior column midway between greater sciatic notch and acetabulum, ending at the incomplete ischial cut. Cut the lateral wall of the posterior column with an angled osteotome starting at the medial cut table. The posterior column remains in continuity, accounting for the inherent stability of the osteotomy.

Position the fragment, ensuring lateral and anterior coverage to place the *sourcil* horizontal without retroverting the acetabulum and producing impingement. The intraosseous nature of the osteotomy is key to its stability: fix with three to four screws. It also means that the osteotomy is free of soft tissue restraints that deny freedom to innominate osteotomies for the immature pelvis, where fragment positioning couples anterior and lateral coverage, thereby retroverting the acetabulum.

Complications of this osteotomy decline with experience [C]. Sciatic nerve injury is most grave; obturator and femoral nerve injuries are rarer. Femoral vascular injury may relate to exposure and manipulation of the vessels *via* an ilioinguinal approach. Intra-articular osteotomy may be avoided by image intensification. That impingement has such a high rate emphasizes the precision required for correct fragment positioning. Isolated pubic nonunion typically is asymptomatic, whereas ischial nonunion may require osteosynthesis. Heterotopic ossification is multifactorial, including genetic tendency, an inherent characteristic of the hip, and surgical trauma. Lateral femoral cutaneous is a compression neurapraxia from retraction and resolves completely in many, and enough in others not to matter to most patients long term.

Outcomes are related to amount of preexisting coxarthrosis [D]. It is a hip preserving, not disease reversing, procedure. This differs from the expectation of remodeling after osteotomy in the immature pelvis. Patients with mild or moderate coxarthrosis demonstrate improvement in general, hip-specific and sports functional outcome instruments. Severe coxarthrosis is not benefited by periacetabular osteotomy, even as a temporizing procedure in a young patient, and is an indication for hip ablation.

LEGG-CALVÉ-PERTHES DISEASE

Despite the fact that shelves groan under the weight of its literature (Rang), Legg-Calvé-Perthes disease (LCP) remains obscure and a source of controversy. It is named after an American, who focused on the painless limp (1910), a Frenchman, who called it *coxa plana* after the residual deformity (1910), and a German, whose assistant took the first röntgenogramme (1898, published 1910). It also is known as Waldenström disease, after the Swedish surgeon who attributed it to tuberculosis (1909). It first was documented in Köhler's atlas, published 10 years after Röntgen discovered x-rays in 1895.

Pathoanatomy

The condition is consistent with avascular necrosis of the head of the femur, radiographically and pathologically [A]. Age of presentation supports this. Other factors implicated in causation include genetic predisposition, vascular anomaly (focal condition of the hip), and endocrine abnormality (a generalized disorder). Animal models of LCP demonstrate a repair response after revascularization that is characterized by osteoclastic bone resorption followed by a fibrovascularization without coupled bone formation, which may make the head of the femur fragile and put it at risk for deformity.

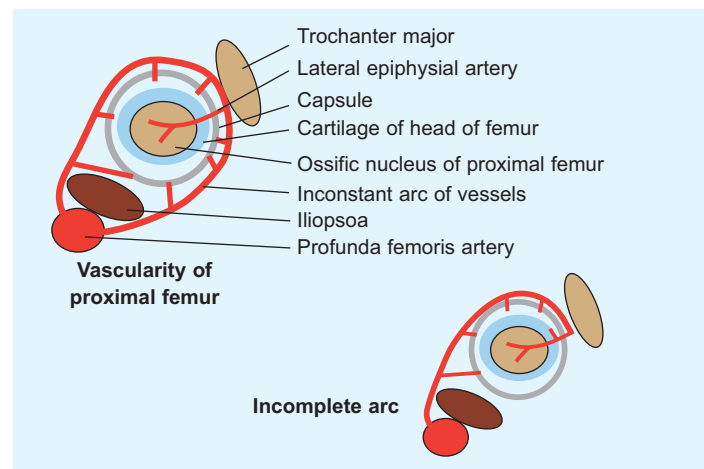
Ischæmia is transient, lasting weeks, and stimulates an inflammatory response, including pain, synovitis, and effusion. The dead bone eventually loses its structural integrity, whereupon it collapses, leaving behind a subchondral space known as a crescent sign in the midst of a radiodense epiphysis. Physical injury may lead to bridge formation, which exacerbates growth disturbance. Resumption of blood flow permits resorption of dead bone of the epiphysis, which swells and appears fragmented on röntgenogramme. During this phase, the head of the femur is soft and susceptible to deformation, becoming flattened and widened, and in the most severe cases indented by the edge of acetabulum. After resorption of the dead bone, creeping substitution by new bone reconstitutes the head of the femur, which remodels with varying residual deformity that is dependent upon age of the child and extent of head involvement.

Both familial and isolated cases of LCP have been reported. A missense mutation in the gene encoding α -1 chain of type II collagen on chromosome 12q13 has been identified in affected members of a Japanese family segregating LCP.

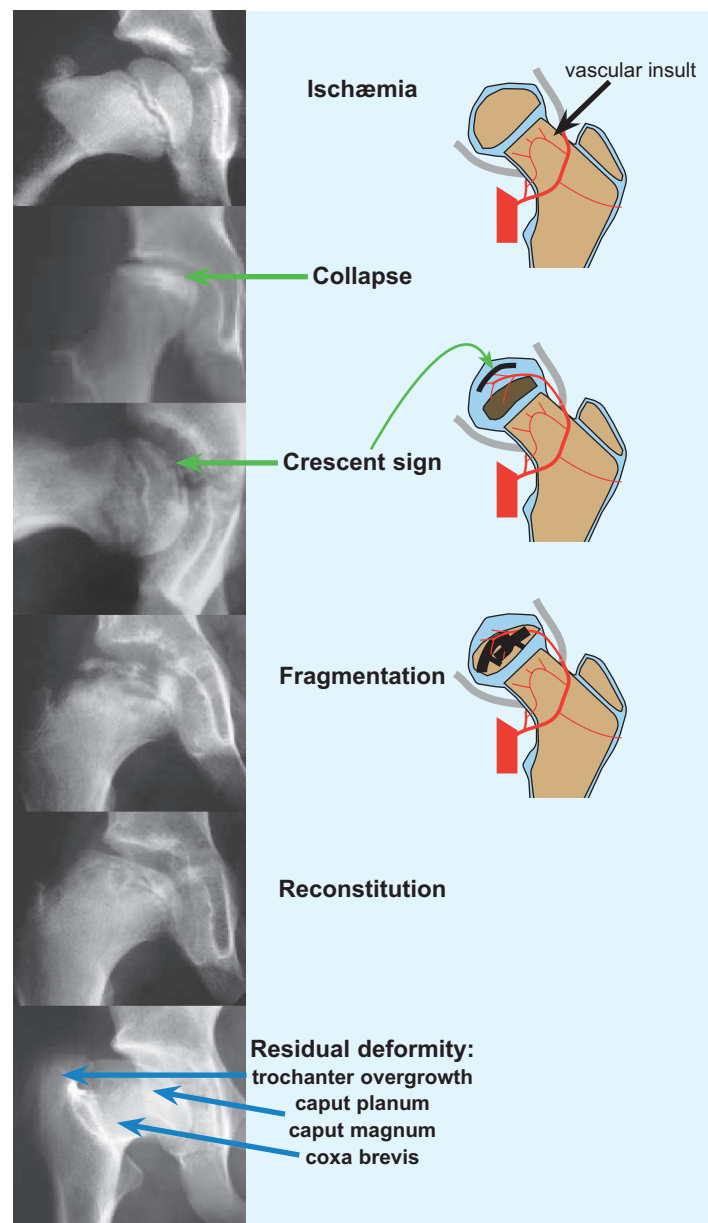
Evaluation

The classic presentation is a small, hyperactive Caucasian boy who is constitutionally and socially disadvantaged (Wynn-Davies). Girls are affected one-fifth the time, but more severely. Peak age is 4 to 8 years, when the head of the femur is dependent on the medial femoral circumflex artery as sole blood supply. Ten percent are bilateral but asynchronous. Synchronous bilateral disease is the rarer dysplasia epiphysialis capitis femoris (Meyer), which has an earlier onset, is less deforming, and is characterized by a more rapid and complete resolution. Consider a generalized survey, including skeletal, in synchronous disease, to rule out a skeletal dysplasia such as spondyloepiphysial or multiple epiphysial dysplasia. Other conditions that feature irregularity of the proximal epiphysis of femur, such as metabolic and endocrine disorders, may be distinguished by nonskeletal symptoms and signs.

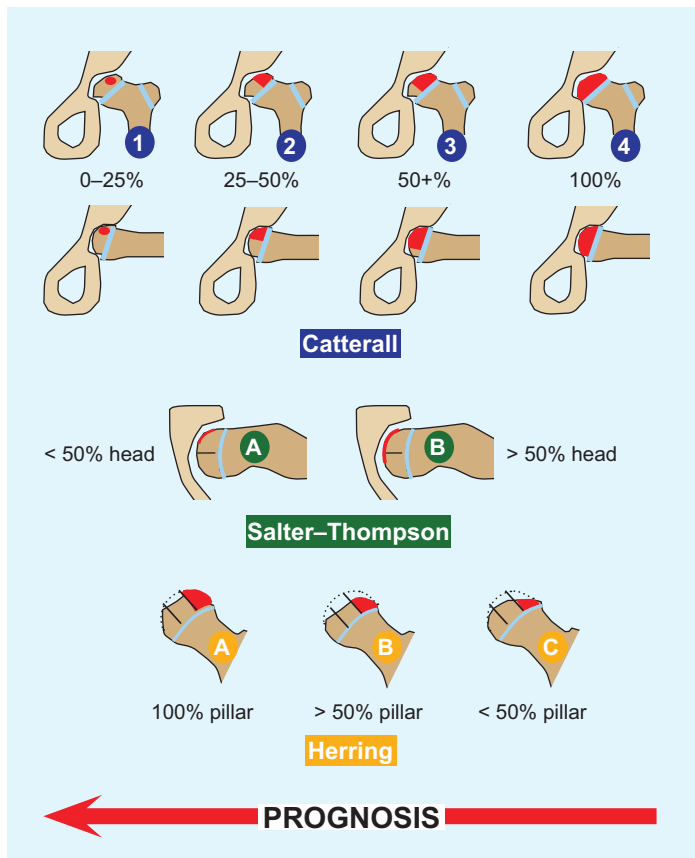
Physical examination There is a history of limp which is not "painless" so much as it is disproportionate to presentation: pain at onset may be severe, after which it evolves to mild and episodic. In long-standing disease with residual deformity, limp may be due to abductor weakness, manifesting as a Trendelenburg gait. The child is small for age. The hip is stiff. Medial rotation is lost first, most and universally, with coexistent adduction and flexion contractures.



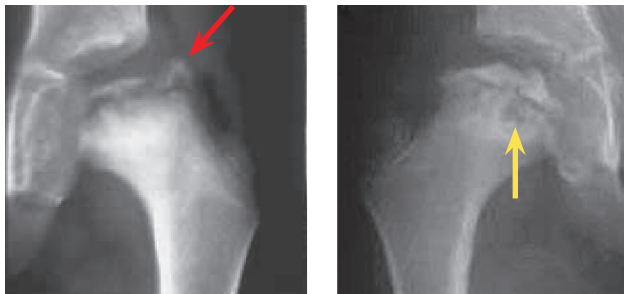
A Circulation to the proximal epiphysis of femur Anomaly of the redundant arcade of the proximal femur may make the head of the femur vulnerable to vascular insufficiency.



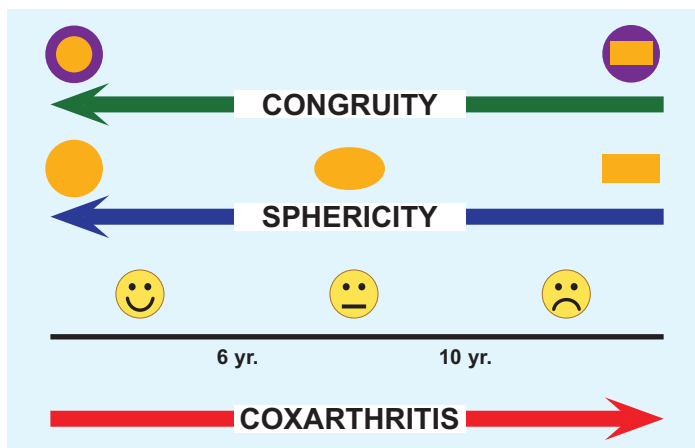
B Clinical stages of disease These form a predictable sequence.



C Three classification systems of LCP.



D Risk signs in LCP Lateral extrusion of epiphysis (red) and metaphyseal cyst (yellow) are negative prognostic signs.



A Natural history of LCP Most important to outcome are age and residual deformity. Orange: head of the femur, which may be spherical, ovoid, or flat. Purple: acetabulum.

Imaging Röntgenogrammes are fundamental and usually all that are needed for evaluation and management.

CLINICAL STAGE [B] While ischæmia is said to be radiographically silent, the inflammation that accompanies this stage may thicken the neck of the femur, which is the earliest radiographic sign. Ischæmia is followed by collapse, in which the epiphysis appears radiodense. Collapse may leave behind a crescent sign, which represents a subchondral fracture. Reperfusion ushers in bone resorption during the fragmentation stage, which lasts for months. During this stage, the epiphysis is soft and fragile: it is most susceptible to deformation and most responsive to treatment. After resorption, reconstitution of the epiphysis can commence, taking 1 to 2 years. Thereafter, the proximal femur remodels to a residual deformity during the remainder of growth.

RADIOGRAPHIC GRADE [C] There are three methods. They are descriptive, prognostic, and guide treatment. The original was devised by Catterall, whose divisions mirror perfusion of the head of the femur. Most vulnerable is the anterolateral region, furthest from the medial femoral circumflex artery, while last affected is the posteromedial region, closest to the artery. This method may be divided into anterior involvement in the first two grades and posterior involvement in the second two grades. It is prognostic in that outcome correlates negatively with extent of disease: poorest is seen with total head involvement. Salter and Thompson focused on the crescent sign, which delimits the extent of osteonecrosis. They simplify: in A, the crescent sign affects <50% of the head, while in B, it affects >50%. The specificity of this classification is its limitation: the crescent sign is present for a short time and is not always visible and not always in its entire extent. However, it is the earliest predictive sign. It is prognostic in the same way as the Catterall system. Herring emphasized the lateral pillar, which is a measure of the durability of the head against the edge loading of acetabulum during the time when it is softest and most vulnerable to fragmentation and which is a guide to treatment. The fovea bounds the central pillar by two lines drawn perpendicular to the physis.

RISK SIGNS [D] These negatively impact prognosis.

- Gage described a transradiant “V” formed by ossification of an extruded lateral epiphysis. This is a sign of indentation of the head of the femur, which carries risk of hinge abduction.
- Catterall described lucency of the lateral epiphysis, representing collapse of the lateral pillar.
- Rarefaction and cystic change in the subjacent metaphysis, which is affected by a widening zone of ischæmic injury.

Ultrasonogramme detects joint effusion as a manifestation of the inflammatory response to ischæmia. Scintigramme confirms ischæmia as reduced uptake in the epiphysis. MRI shows serpiginous or cavity loss of signal in the epiphysis due to osteonecrosis. These modalities may aid earlier diagnosis but do not influence management.

Arthrography is an operative aid. It provides an image of the true contour and deformation of the unossified cartilage model, which may be assessed dynamically to determine center of rotation of the head of the femur relative to acetabulum.

Natural History

There is no treatment effect in children younger than 6 years, in whom outcomes are better [A]. By contrast, outcomes are grave for onset of disease in the second decade. Between these two age groups, outcome is dependent upon treatment. The younger head is more resilient to injury and has more potential to recover and longer to remodel. The most important prognostic factor is residual deformity and fit between the head of the femur and acetabulum. The former is divided into spherical, reduced sphericity, and flat. The latter is divided into congruent or incongruent. Physial bridge adds growth disturbance to exacerbate deformity.

Management

Treatment is founded upon the principle of containment [A]. Containing the head of the femur within the confines of the acetabulum keeps the edge of the latter, where stress concentrates, away from the fragile bone and cartilage of the former, which otherwise may subluxate and become deformed. Redirect the femur so that the normally hard acetabulum may mold the soft head.

Nonoperative treatment Abduction and medial rotation of the thigh centers the head of the femur in the acetabulum. This may be achieved with cast or brace, without or with traction, without or with weight bearing. Such treatment must be maintained for fragmentation and for a variable amount of reconstitution, when the head is most susceptible to deformation. The temporal requirement makes this unrealistic when operative treatment may achieve this.

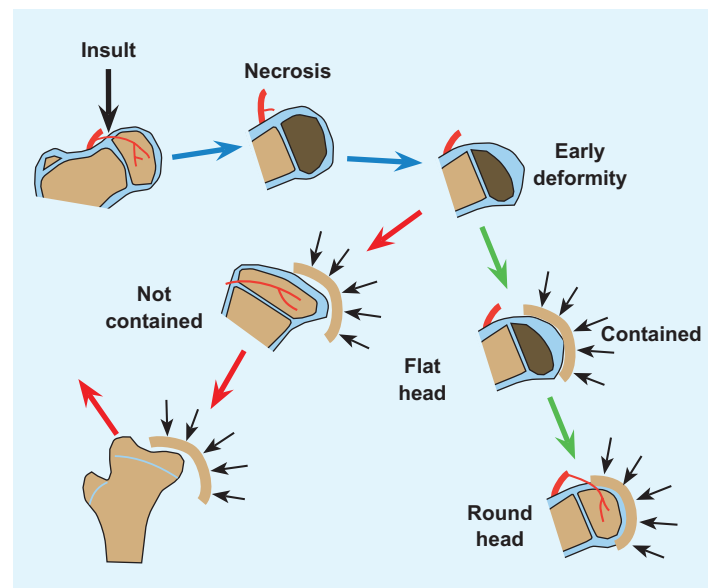
There is no consensus on activity restriction. Balance the logic of limiting force on a fragile head of the femur against the benefits of recreation, exercise, and maintaining as normal a childhood as possible.

Operative treatment The integrity of the lateral pillar informs operative treatment. If the lateral pillar demonstrates no collapse (A), then the epiphysis is sufficiently durable that it needs no help. If little of the lateral pillar remains (C) under the onslaught of the edge of acetabulum, then the head has been damaged beyond the benefits of containment. Treatment is beneficial in the second half of the first decade: before this, outcomes are not influenced by active treatment, while after this, outcomes are poor despite operative intervention. The decision to intervene is made during fragmentation. An essential challenge is timing: earlier is better, to minimize collapse and before swelling makes the head of the femur too big for the acetabulum to contain. This is may be the principal benefit of the crescent sign (if apparent): a type B is the first sign that intervention is indicated. Such a narrow window of time, and the narrowing range of age to treat, are seeds for nihilism among some surgeons.

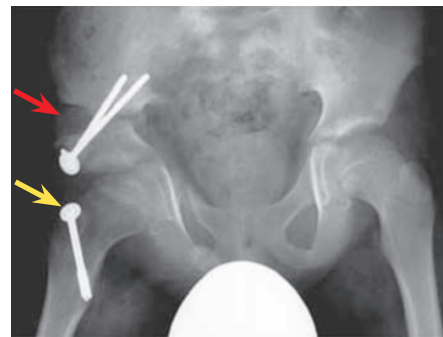The head of the femur may be redirected into the acetabulum by varus and derotation osteotomy of the femur (simulating the effect underlying the concept of cast or brace). Alternatively, the acetabulum may be redirected to take the edge away from the head of the femur [B]. Osteotomy of the femur has the theoretically advantages of reducing intra-articular pressure and intraosseous pressure. It accepts exacerbating the eventual deformity of the proximal femur as a price to protect the head and requires a secondary realignment procedure. Osteotomy of acetabulum treats the side of the hip joint that is not diseased, introducing a compensating deformity, which has implications long term if the acetabulum is retroverted or the *sourcil* is sloped downward, thereby creating femoroacetabular impingement. Add physiodesis of the trochanter major to slow its growth. An adduction contracture may be addressed by a concomitant adductor tenotomy.

Toward or at maturity, residual deformity may require operation, directed at reduced coverage due to an enlarged head, and relative overgrowth of the trochanter major due to growth disturbance of the proximal physis of the femur [C]. Stress concentration at the articular surface of the head presents as groin pain. Fatigue of shortened hip abductor muscles presents as peritrochanteric or buttock pain. Redirect the acetabulum by a periacetabular osteotomy, after ensuring that the head does not hinge with abduction. Offset may be increased by:

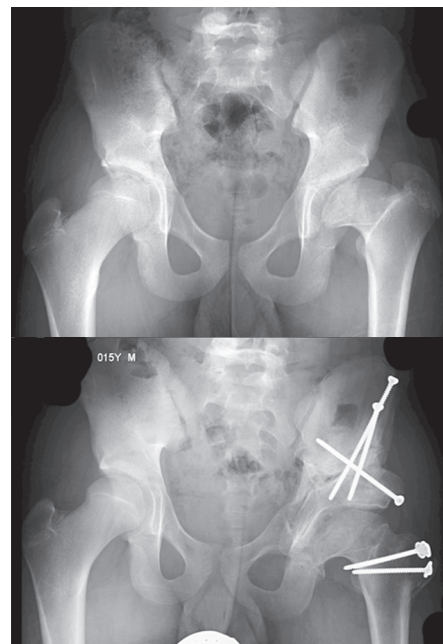
Distal and lateral transfer of the trochanter major. This is simplest and safest. Use a direct lateral approach. Release soft tissue such that only the hip abductors remain attached to the trochanter. Cut the trochanter in line with the superior margin of the neck toward the trochanteric fossa. Finish with an osteotome in order not to injure the medial femoral circumflex artery. Bluntly reflect remaining adherent soft tissue restraints. Resect the lateral corner of the distal fragment to aid displacement of the trochanter. Distalize and lateralize the trochanter until its top is at the level of the



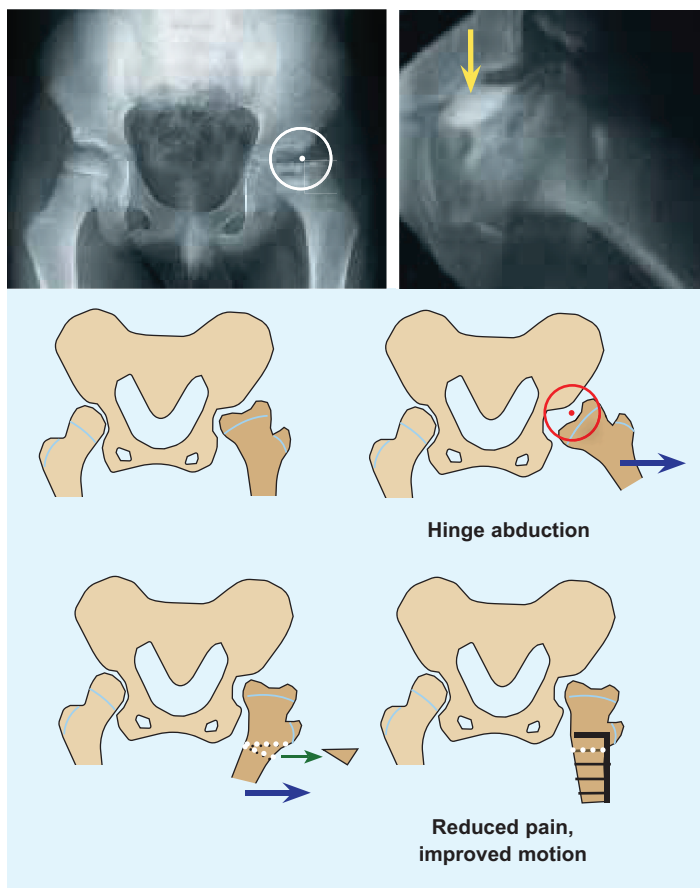
A Concept of containment in LCP Containing the head of the femur in acetabulum reduces deformity.



B Containment osteotomy for active LCP Triple innominate osteotomy (red) brings edge of acetabulum beyond articular surface of the head of the femur. Trochanter major physiodesis was performed with a screw (yellow).



C Osteotomies for residual deformity in LCP Periacetabular osteotomy is combined with trochanter major transfer to cover the head of the femur and restore correct anatomic alignment of the proximal femur.



D Hinge abduction in LCP Center of rotation at point of contact between indentation of the head of the femur and edge of acetabulum (*white, red*) opens the medial joint, where arthrography shows contrast pool (*yellow*). Valgus osteotomy of the proximal femur is diagrammed.

center of the head of the femur. Fix with screws and washers, and support in a brace.

- Valgus osteotomy of the proximal femur. Use a direct lateral approach. Perform a transverse intertrochanteric osteotomy. Based upon ante-operative templating or intraoperative adduction of the lower limb, displace the distal fragment until the top of trochanter major is at the level of the center of the head of the femur. Fix with a plate.
- Lengthening osteotomy of the neck of the femur. Use a direct lateral approach. Cut the trochanter major. Cut the intertrochanteric region in line with the axis of the neck. Distalize the distal fragment and fix with a plate. Fix the trochanter in a position that places its top at the level of the center of the head of the femur. Graft the gap thereby left in the neck with part of the trochanter.

In addition to addressing the hip joint, assess and treat significant lower limb length discrepancy. If there is sufficient growth remaining, a timed physiodesis of the longer lower limb is simplest; otherwise, consider a femoral shortening osteotomy with internal fixation of the longer femur. The discrepancy is not great enough to warrant lengthening of the affected femur.

In milder deformity, innominate osteotomy may be avoided by performing an osteochondroplasty of the head of the femur by means of a surgical hip dislocation. The trochanter major may be transferred in association with this approach.

A requisite for redirection osteotomy is reduction of the head of the femur in acetabulum. This may be determined by röntgenogrammes of the hip in abduction without or with arthrography. If the head hinges, then either do not treat surgically or perform a valgus osteotomy of the proximal femur to bring up a rounder part of the head into contact and take indentation away from the edge of the acetabulum, thereby reducing pain and improving motion [D]. Add extension to the osteotomy as necessary to compensate for flexion contracture.

Medical treatment Bisphosphonates have a PO₃-C-PO₃ backbone, with a long side-chain that determines mode of action and a short side-chain that determines pharmacokinetics. As synthetic analogs of pyrophosphate, they bind with high affinity to hydroxyapatite. Non-nitrogenous bisphosphonates are absorbed by osteoclasts, which are induced to undergo apoptosis. Nitrogenous bisphosphonates kill osteoclasts by inhibiting protein prenylation.

In LCP, bisphosphonates delay osteoclastic resorption of necrotic bone during the fragmentation stage, which may permit more time for revascularization and new bone formation to occur before structural failure. While bisphosphonates are administered systemically, osteonecrosis may limit access of these agents due to absent perfusion. In an animal model, direct injection into the head of femur enhances efficacy.

Bisphosphonates are anticatabolic, which may limit fragmentation, but not anabolic, such as bone morphogenetic protein-2, which would aid reconstitution. Agents that block the inflammatory response elicited by ischaemia represent a third avenue for development of the medical treatment of this disorder.

Drug delivery may be systemic, which requires revascularization to reach the region of osteonecrosis and therefore presents a narrow therapeutic window. Alternatively, they may be injected directly into the affected bone, which allows earlier access before fragmentation of the femoral head begins.

SLIPPED CAPITAL FEMORAL EPIPHYSIS

This is the most common hip disorder of adolescence.

Pathoanatomy

In slipped capital femoral (upper) epiphysis (SCFE, SUFE), the proximal metaphysis of the femur displaces posteriorward and to a lesser degree lateralward relative to the capital epiphysis at the level and in the plane of the intervening physis. This produces a major apex anterior and a minor lateral rotation deformity that leaves the epiphysis in a relatively posterior position [A]. The sagittal plane deformity is accompanied by apparent varus in the coronal plane: corrective osteotomies should address primarily the former, which is the major plane of malalignment, rather than the latter. While the name of the disorder is misleading mechanically, it places emphasis on the source of morbidity. SCFE may be distinguished from transphyseal fracture [B], with the exception of the acute unstable subtype, where distinctions blur. Anatomic factors that conspire in pathogenesis include obesity with increased weight and widened gait as well as retroversion of the neck of the femur, which tilt the proximal physis of the femur vertical and amplify shear force. Physisal anticipation of puberty includes thinning of the perichondrium, which weakens the physis. Endocrinopathy, including hypogonadism, hypothyroidism, and renal osteodystrophy, or metabolic disorder, including radiation or chemical therapy, may weaken the physis.

Evaluation

The typical presentation is a 13-year-old boy who is obese and hypogonadal. Skeletal age is delayed 1 to 2 years. Boys are affected twice as often as are girls, whose mean presentation is 11 years. One-quarter of cases are bilateral: half are synchronous, while nonsynchronous cases present within 18 months. Always evaluate the other hip, and educate patients so that they come to medical attention if symptoms or signs develop. Pacific islanders are affected twice as often as Blacks, who are affected twice as often as Whites, who are affected twice as often as Asians. Atypical presentation is defined as a child outside of the 10 to 16 years' age range who is <50th percentile in weight. Evaluate the atypical patient for a generalized disorder of which SCFE is one feature, such as endocrinopathy.

History Ten percent are acute, which is defined as symptoms up to 3 weeks. Symptoms >3 weeks is chronic. Less than 25% (of the 10%) are true acute presentations; the other >95% are defined as acute or chronic presentations. The 2% to 3% of the total number of presentations that are purely acute carry the greatest morbidity [C]. These may be regarded as transphyseal fractures and treated as such.

Physical examination

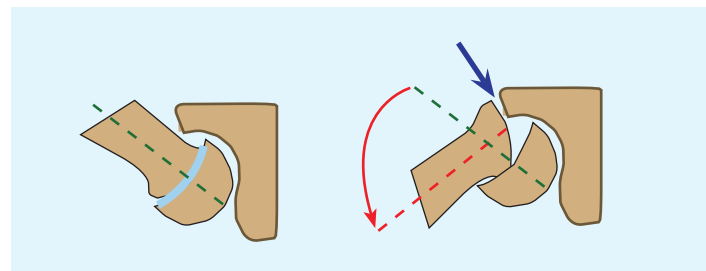
WEIGHT BEARING Up to 10% have an unstable presentation, defined as inability to bear weight on the affected limb: such patients are at risk for osteonecrosis. Stable SCFE is characterized by ability to bear weight, producing an out-toeing gait due to loss of medial rotation. Severe deformity may weaken hip abductor muscles resulting in a Trendelenburg gait.

PAIN Pain in chronic stable SCFE may be misdiagnosed as a groin pull. Fifteen percent of patients present with knee pain.

MOTION Patients with unstable SCFE are intolerant of hip motion, including on physical examination and during imaging, and are at risk for osteonecrosis. Medial rotation is lost: this is most apparent in the supine position. With increasing deformity, the anterior apex abuts the edge of acetabulum such that obligate lateral rotation accompanies increasing hip flexion.

Imaging

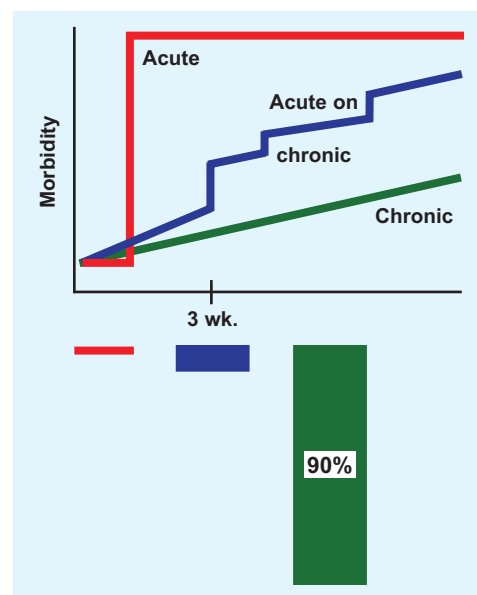
RÖNTGENOGRAMMES AP pelvis and lateral of the affected proximal femur are the foundation. The AP pelvis allows survey of both hips. A cross-table lateral is indicated if the hip cannot be placed in the frog lateral position due to pain or if there is concern about displacement of an unstable SCFE with manipulation of the hip.



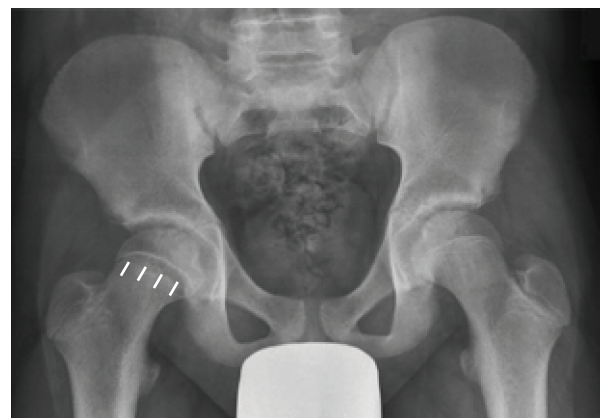A Deformity in SCFE The essential deformity is an extension type in the sagittal plane. The apex anterior deformity limits flexion as the prominent metaphysis abuts the edge of acetabulum (*blue*). Red arrow shows the loss between normal (*green*) and abnormal (*red*) flexion.

	SCFE	Transphyseal fracture
History	Antecedent symptoms in > 90%	Negative
Profile	Obese Hypogonadal	Nonspecific
Energy	Low	High

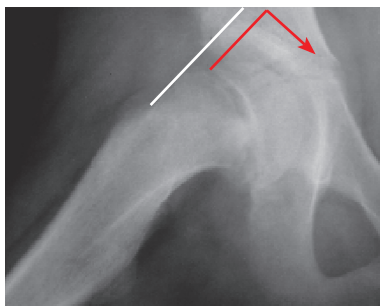
B SCFE versus fracture Most SCFE may be distinguished from fracture.



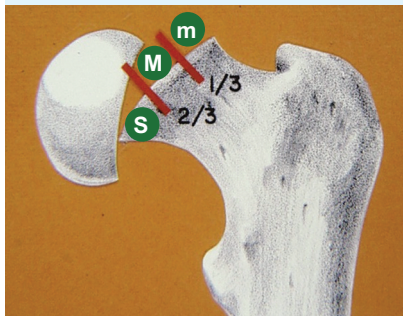
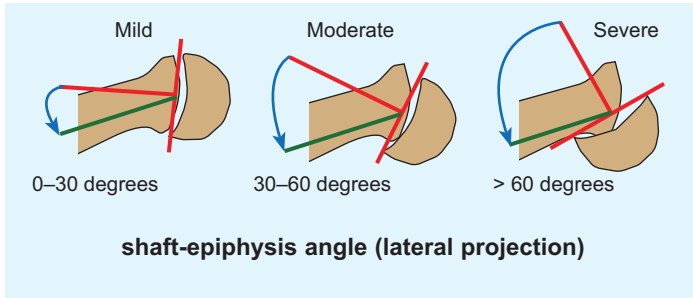
C Temporal classification of SCFE The majority are chronic (*green*). Most acutes have a chronic history (*blue*). Acuity carries greatest morbidity.



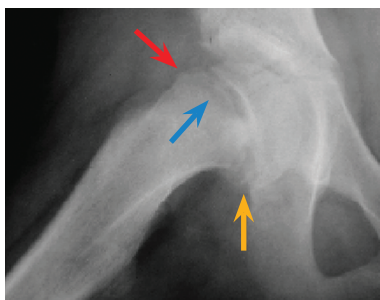
D Preslip Widening of physis and rarefaction of subjacent metaphysis (*white*) are signs.



E Epiphysis–neck relationship
The epiphysis (red) slips away from, and is not crossed by, a line (white) drawn along the anterior and lateral margin of the neck.



F Severity of deformity in SCFE Severity may be expressed as the slip angle, measured between shaft and epiphysis, or as translation of the epiphysis on the neck. m: mild. M: moderate. S: severe.



G Remodeling in SCFE
The neck is heaped up (red), there is resorption of the metaphysis (blue), and projection of a rounding epiphysis beyond the neck (orange) has been likened to a “crow’s beak.”

- Evaluate the physis. A “preslip” [D] represents early presentation before deformity. Signs include widening of the physis, which may appear bounded by sclerotic margins, and rarefaction of the subjacent metaphysis.
- Evaluate the relationship of epiphysis and the neck of the femur [E]. The epiphysis appears slipped medial (anteroposterior projection) and posterior (lateral projection) to a line (Klein) drawn along the lateral and anterior margin of the neck.
- Determine severity of deformity [F]. This is measured as the shaft–epiphysis angle on the lateral view. The shaft is used due to version of the neck, which will vary its axis according to rotation of the hip. The direction of epiphysis is taken as a perpendicular to a line that marks its base. An alternate method is based upon translation of the epiphysis on the neck of the femur. This is less reliable because the epiphysis may obscure the neck, and remodeling may distort the neck.
- Observe signs of osseous reaction to chronic disease [G]. These may be useful when displacement is subtle.

SCINTIGRAMME This may show increased uptake in a typical clinical presentation without clear röntgenographic signs. It also enables assessment of epiphysial perfusion in acute, severe, unstable SCFE, where risk of osteonecrosis is highest.

ULTRASONOGRAMME This may show effusion early in the course of disease, including when röntgenogrammes are inconclusive. It also permits measurement of “step off” of epiphysis relative to the neck of the femur.

MAGNETIC RESONANCE IMAGING This has become the second line of imaging after röntgenogramme, because it provides most information. It may detect an inflamed physis and a reactive joint effusion in the preslip state. It evaluates perfusion of the epiphysis and aids in ruling out other causes of hip pain where there is diagnostic dilemma.

Natural History

Outcomes after SCFE may be divided into early and late.

Early Avascular necrosis results from tear or compression of the epiphysial blood supply. It is associated with acute, severe, unstable SCFE. Acuity does not allow vascular remodeling. Severe slip may stretch vessels to failure or lead to kinking and compression under a slipped epiphysis. Ischæmic bone is so painful that the child will not bear weight upon or move the affected hip: this is defined as an unstable presentation. Avascular necrosis has been associated with closed reduction, which historically was imprecise and too forceful. Gentle, controlled, open reduction may reduce osteonecrosis by unkinking and restoring proper orientation and patency of blood vessels supplying the epiphysis, in the same way as open reduction for neck of femur fracture.

Chondrolysis is rarer and more obscure than avascular necrosis. It is defined as a joint width ≤ 3 mm, or $< 50\%$ of the unaffected side. Pathogenesis after SCFE is unknown. It is more common in girls and African Americans. It tracks with avascular necrosis, being more common in acute, severe presentation and after closed reduction. The only known cause is mechanical, due to permanent articular implant penetration. The hip becomes stiff. Anti-inflammatory medications may relieve pain but do not alter natural history. The benefits of protected weight bearing, traction, continuous passive motion, and capsulectomy are uncertain. Recovery is variable and typically incomplete.

Late Osteoarthritis is related to deformity. Mild SCFE may go undetected until presentation for arthroplasty as an adult, when a “tilt” or “pistol grip” deformity of the proximal femur may be seen on röntgenogramme. The grip represents the rounded and varus head and the neck of the femur, the cylinder, hammer, and trigger represent the trochanteric region, and the barrel represents the shaft. Mild deformity is accepted. Severe deformity is morbid from the outset of disease, beginning with restricted hip motion, proceeding to labrum and anterior acetabular cartilage injury, and ending in global joint degeneration. Deformity correction, by reduction or osteotomy, is indicated to alter this natural history. There is no consensus on moderate deformity.

Management

Objectives of treatment are stabilization of proximal physis of the femur without or with restoration of anatomy.

Stabilization of physis This is indicated for mild slips. It is urgent, in order to mitigate risk of further slip or transformation of a stable presentation to an unstable one, with its attendant risk of osteonecrosis. Protect weight bearing on the affected limb with crutches or a wheelchair, if the patient is at risk for fall with the former.

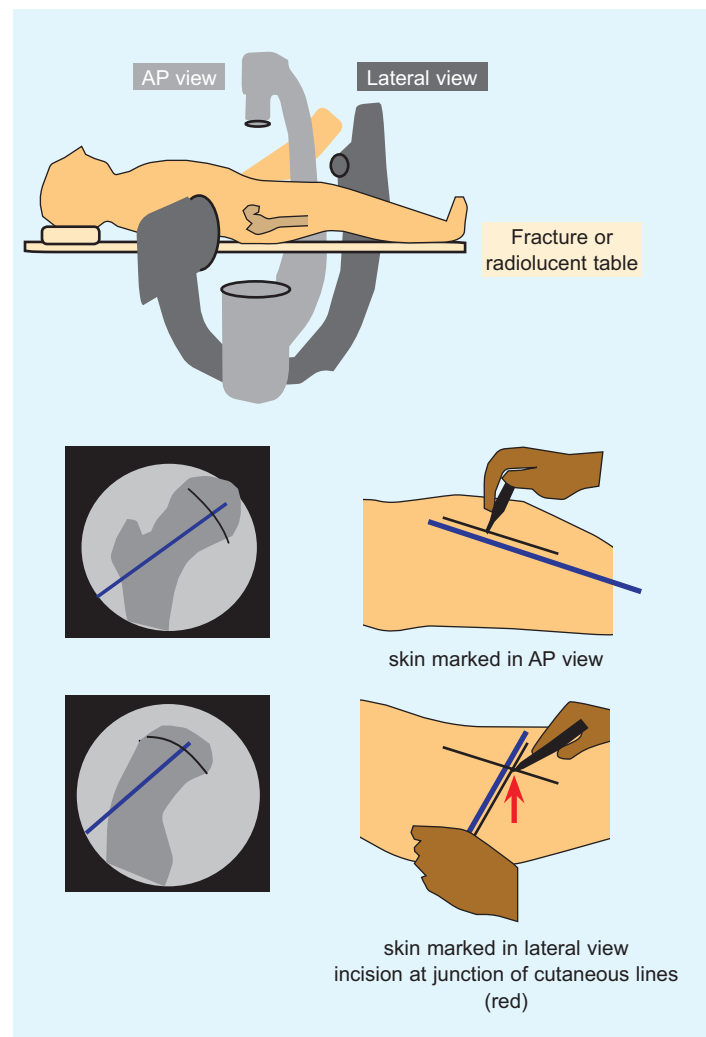
Immobilization in a hip spica cast was advocated to avoid operative complications and to simultaneously treat both hips; however, it has been associated with further slip and chondrolysis.

Open physodesis with a bone peg under direct vision avoids articular or cervical penetration, effects more rapid physal closure and therefore stability, allows osteoplasty in severe deformity, and requires no implant; however, it is invasive (long incision, bloody, increased operative time) and requires postoperative immobilization in hip spica cast until union.

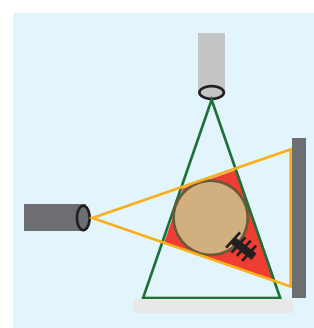
The standard of care is *in situ* screw fixation [A]. This is cannulated and performed under image intensification, making it rapid through a small incision.

- A fracture table allows simultaneous use of two image intensifiers for anteroposterior and lateral imaging without manipulation of the hip. On a regular radiolucent table, lateral view is obtained by rotating the image intensifier and flexing the hip.
- Draw lines perpendicular to physis and centered in epiphysis on both projections: the incision is 1 cm at the intersection of the lines on the anterolateral thigh skin.
- Insert a terminally threaded guide wire perpendicular to the physis into the center of the epiphysis using the cutaneous lines as directional aids.
- Ream the cortex without or with the subphysal hard bone, leaving the epiphysis in order not to dislodge the guide wire and not to risk articular penetration.
- Insert an appropriate length cannulated screw. Don't bury the screw lest it need be removed later. A titanium screw will allow MRI imaging, in the event of osteonecrosis. Use full threads: compression across the physis is not indicated, and risks insufficient threads in the epiphysis, where five threads are the minimum for stability. In addition, a partially threaded screw may not be able to back cut through a long column of bone during removal, if this be necessary. Using more than one implant increases the risk of articular or extraosseous penetration.
- Balance placing as many threads as possible in the epiphysis for stability with not penetrating the joint. The latter may be assessed by watching the screw tip approach then withdraw from the articular margin of the head of the femur during hip rotation under continuous image intensification. The rationale for continuous imaging of approach withdraw is the blind spots in static orthogonal imaging [B]. Alternatively, inject contrast into the screw: if the contrast fills and flows back out of the screw without an arthrogramme, the screw tip is safe [C]. This is a functional test, subject to less interpretation and less dependent upon limb position, and as such is more reliable.

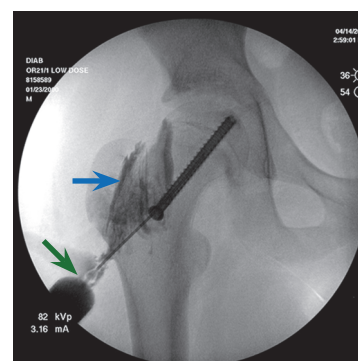
After operation, the patient may walk *ad libitum*. There is no fracture to unite, so crutches or a walker with protected weight bearing are for comfort, and a 6-week time period is arbitrary. The physis fuses after a mean of 18 months, during which time axial loading activity, including jumping and running, should be avoided. Focus the patient, who typically is overweight, on swimming and closed chain kinetic activity. After physal fusion, liberate the patient to activity *ad libitum*.



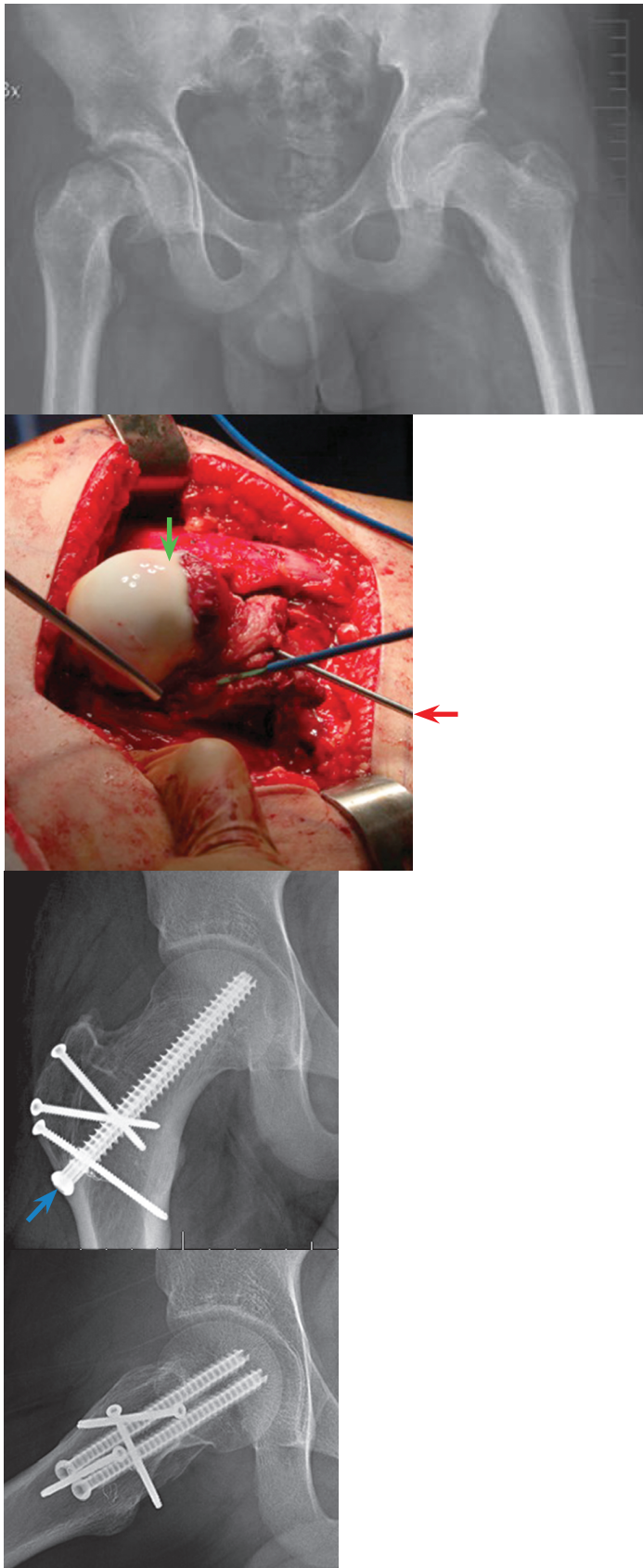
A In situ screw fixation of SCFE Image intensifier aids insertion of a cannulated screw perpendicular to physis into center of epiphysis (without reference to the neck).



B Blind spot during imaging of SCFE Placement of the tip (black) of a screw beyond the subchondral margin of the head of the femur may escape detection due to the blind spots (red) of static imaging, despite orthogonal views.



C Implantography Injection (green) of contrast reagent fills lumen and flows back out (blue) of fixation screw. Absence of a hip arthrogramme means the cannulated tip of the screw has not penetrated the joint.



D Open reduction and internal fixation of SCFE Acute or chronic, severe, unstable SCFE (1) underwent open reduction and internal fixation (2) with cannulated full thread titanium screws and small fragment fixation of trochanter major. Temporary threaded fixation wire of epiphysis before dislocation (*red*). Epiphysis shows chronic changes (*green*). Cannulated screws placed immediately distal to trochanter major (*blue*).

Reduction and stabilization of physis This is indicated for acute severe slips. A closed partial reduction may occur spontaneously with placement of patient on an operative table. Do not perform a forcible closed reduction: this is associated with osteonecrosis.

OPEN REDUCTION VIA ANTERIOR APPROACH Perform an anterior approach after Smith-Petersen in supine position. Open the joint to decompress a haematoma, and apply digital force at the apex of deformity. Use moderate force to move the epiphysis from an acute to a chronic position; pushing beyond the acute position risks injury to the retinacular vessels, which have shortened to accommodate the chronic position. Fix the epiphysis.

OPEN REDUCTION VIA HIP DISLOCATION This allows controlled maximal reduction under complete view. It is safe, actively avoiding the early complication of osteonecrosis, and allows restoration of anatomy to avoid late complications of coxarthrosis.

- Position the patient lateral for a posterior approach through gluteus maximus.
- Cut the trochanter major lateral to piriformis, in order to avoid medial femoral circumflex artery.
- Elevate trochanter major with glutei medius et minimus off hip joint capsule, leaving piriformis and subjacent blood supply undisturbed.
- Cut capsule along the axis of the neck, extending a posterior limb parallel to acetabulum (away from retinacula of Weitbrecht) and an anterior limb parallel to base of the neck.
- Expose neck subperiosteally. Cut the posterior margin of trochanter major to take retinacula of Weitbrecht with medial circumflex vessels away from area of dissection to protect them.
- Stabilize the epiphysis in place with a temporary threaded wire, in order that it not displace during hip dislocation.
- Cut ligamentum teres to allow dislocation of the hip anteriorward by adducting the lower limb across the body. The retinacula of Weitbrecht may be demonstrated in continuity with epiphysis after dislocation.
- Mobilize the epiphysis through the physis. Trim callus from the anterior epiphysis–neck junction. Shorten the neck as necessary to reduce the epiphysis without tension.
- Fix the epiphysis antegrade by passing a guide wire through the fovea centralis to emerge from the lateral cortex of the femur subjacent to trochanter major. Withdraw guide wire to articular margin of the femur, and select a 5-mm shorter cannulated screw. Place a second guide wire retrograde parallel to the first guide wire. Place a cannulated screw retrograde over each wire. An ACL guide may improve accuracy of guide wire placement.
- Oozing of blood through epiphysal bone during physal débridement and guide wire hole demonstrate preservation of blood flow.
- Reduce the hip, repair periosteum and close the capsule.
- Fix trochanter major at its original site around the epiphysal screws, adding washers or cutting a semitubular plate to enhance stability.

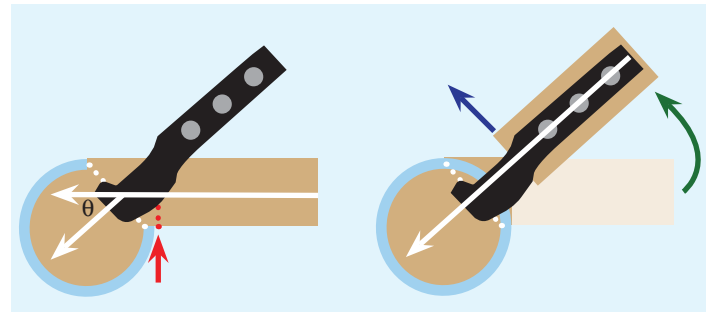
After operation, protect weight bearing with crutches or walker until union of trochanter major. Because this treatment is indicated for acute severe SCFE, avascular necrosis is a significant risk (*vide infra*).

Osteotomy This is indicated for chronic severe SCFE. In the chronic state, the epiphyseal vasculature has shortened to accommodate for deformity of the proximal femur. As a result, an acute correction risks injury to this blood supply unless accompanied by sufficient shortening, which may be difficult to judge. This differs from the acute presentation, where reduction is indicated. A safer approach is osteotomy in the intertrochanteric region of the femur, remote from the epiphyseal blood supply. Olisthy occurs along the plane of the proximal physis of the femur, principally in the sagittal plane to produce an extension (apex anterior) deformity, accompanied by a lesser degree of lateral rotation. Osteotomy that places emphasis on the apparent varus in the coronal plane, focusing on valgus realignment (Southwick), will not correct the deformity sufficiently. Osteotomy that primarily addresses the extension deformity, adding medial rotation of the distal fragment as necessary (Imhäuser), is more anatomic [E, F].

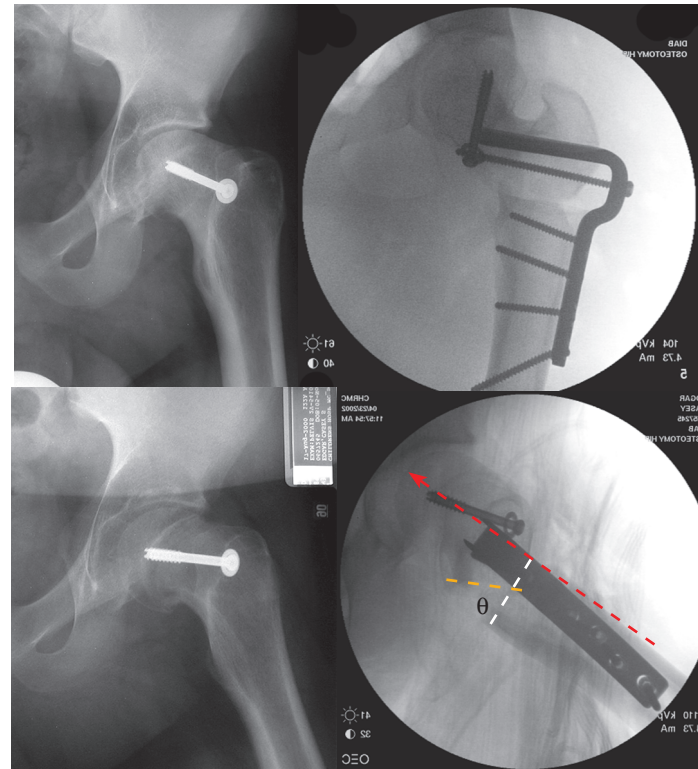
- Perform an anterolateral approach to the hip is utilized through a straight lateral incision.
- If the SCFE has been stabilized previously in an acute setting, the angle of the fixation screw, placed perpendicular to the physis, serves as a guide to correction as it is equal to the angle of posterior inclination of the epiphysis: this represents the degree of flexion of the distal fragment that is necessary to restore a normal relationship between epiphysis and diaphysis of the femur.
- A slotted chisel for a 90-degree blade plate is placed at the base of the trochanter major and is rotated until the anticipated anteriorward inclination of the side plate matches the direction of the fixation screw, or the desired degree of flexion based upon preoperative CT. Because no valgus is required, the chisel is placed perpendicular to the long axis of the shaft of the femur in the coronal plane. Once the chisel is started, remove any fixation screw, lest it get in the way.
- A transverse osteotomy is performed immediately proximal to trochanter minor.
- Insert the blade into the proximal fragment. Flex the distal fragment to the plate. Release adherent posterior soft tissues, including periosteum. Flexion of the distal fragment will be accompanied by obligate anterior translation, of which the amount is proportional to the degree of correction. In this way, the axis of the diaphysis will move toward the axis of the head of the femur, thereby compensating for osteotomy away from the site of deformity.
- Rotate the distal fragment medialward to match the uninjured femur, and fix the distal fragment to the plate.
- Cut the anterior hip joint capsule to reduce contracture, which will allow the head of the femur to return to its normal position within the acetabulum as the thigh is extended back to the operative table.

Cheilectomy This is indicated for femoroacetabular impingement due to SCFE deformity in a patient in whom a more extensive reconstruction is not acceptable to the patient or surgeon [G]. This may be performed through an anterior approach, or a hip dislocation approach. Because the “lip” or head-neck prominence to be removed is anterior and lateral, the former approach is sufficient with less morbidity. The image intensifier may serve as an aid. The hip is flexed as a functional test to guide amount of resection. While this procedure may provide relief from impingement, it does not restore the correct relationship of articular surfaces of the head of the femur and acetabulum.

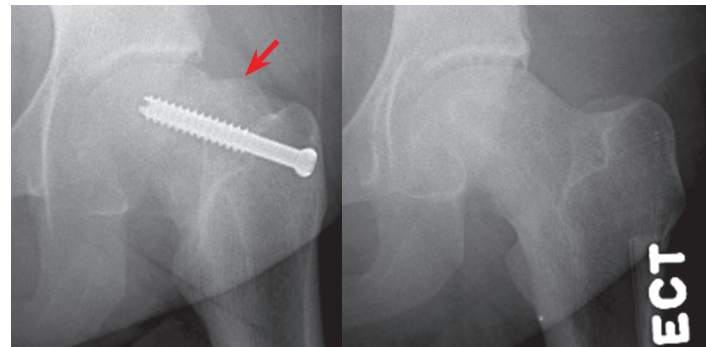
G Cheilectomy for SCFE A large prominence at superior corner of the neck of the femur (red), exposed by slip of epiphysis away posterior and medial, was débrided by an anterior approach. The screw head was prominent, contributing to the cam femoroacetabular impingement.



E Technique of flexion intertrochanteric osteotomy (Imhäuser) for SCFE A transverse intertrochanteric osteotomy is performed (red). The blade is inserted so that its plate is in line with the epiphysis (white). The distal fragment is flexed (green) and translated anteriorward (blue) to the plate.



F Flexion intertrochanteric osteotomy (Imhäuser) of SCFE In the anteroposterior projection, the apparent varus is corrected, increasing the articulo-trochanteric distance, offset, and neck-shaft angle, as well as bringing the trochanteric fossa into profile. The correction is highlighted by change in screw direction clockwise (valgus) without valgus displacement at osteotomy. The lateral projection shows that epiphysis is aligned with shaft of the femur (red). Correction is measured as θ . The corner of the proximal fragment (orange) sits inside the medulla of the distal fragment (white), which translates anteriorward with increasing flexion to compensate for a Z-shaped correction remote from locus of deformity.

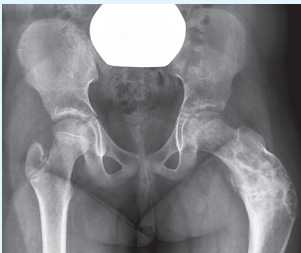


Prophylactic stabilization of contralateral physis Bilateral SCFE occurs in about one-quarter of patients. This has been used by some (Europe) as an indication for this approach. Indications for stabilization of the contralateral physis in the United States are:

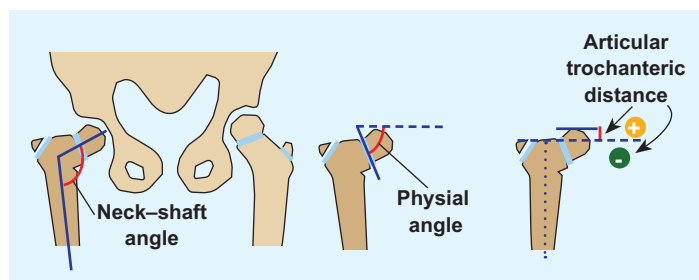
- Pain in the contralateral hip
- High risk medically, including outside of the 10- to 16-year age range and comorbidity such as endocrinopathy
- High risk socially, such as unreliable patient or family, and difficult access to medical care

Complications of SCFE Treatment

Avascular necrosis In SCFE, avascular necrosis is not transient and tends to affect the entire epiphysis. Hip pain and stiffness set in within a year of injury or treatment. MRI may detect changes before collapse on röntgenogrammes. Remove implants to improve MRI evaluation of extent of head involvement and to avoid protrusion and injury to acetabulum in case avascular necrosis is partial, and the hip may be salvaged by redirection osteotomy of the femur to move dead bone away from weight bearing. If osteonecrosis is extensive, consider hip arthrodesis in a young patient with isolated joint disease who will be unrestrained by other joint disease in systemic illness (e.g., juvenile inflammatory arthritis).

Primary	
Termed “congenital” or “Development.”	
Acquired—local	
Congenital deficiency of the femur.	
Trauma	- malunion.
Avascular necrosis	- management of developmental dysplasia of the hip.
	- Legg-Calvé-Perthes disease
Slipped capital femoral epiphysis.	
Tumor	- Bone cyst
	- Fibrous dysplasia (Shepherd’s crook deformity)
	
Iatrogenic	- postvarus osteotomy
Acquired—general	
Skeletal dysplasia e.g., spondyloepiphysial dysplasia.	

A Classification of coxa vara There are three categories.



B Measurements of the proximal femur Neck–shaft angle is most familiar, including from templating for adult reconstruction, but least precise. The articlotrochanteric distance is a functional measure.

Femoroacetabular impingement As deformity becomes more severe, apex anterior deformity at the head and neck junction produces cam impingement. This is an indication for reduction or osteotomy. Impingement may be exacerbated by implant prominence: as deformity becomes more severe, implant entry site migrates anteriorward and proximal on the neck of the femur, where a prominent head of screw *per se* may collide with acetabulum during hip flexion. This is an indication for implant removal once physis has closed if a severe SCFE is treated with *in situ* screw fixation. Implant removal is unnecessary for mild deformity.

COXA VARA

The proximal femur (despite the Latin *coxa*: “hip”) may have a varus shape primarily in isolation, known as congenital or developmental coxa vara, as part of a localized or regional disease process, for example, Legg-Calvé-Perthes disease, or secondary to a generalized disorder, for example, in skeletal dysplasia [A].

Pathoanatomy

Varus of the proximal femur may be defined as [B]:

- Negative articlotrochanteric distance. This measurement becomes negative when the top of trochanter major (normally level with the center of the head of the femur) is proximal to the articular surface of the head of the femur.
- Physial angle >30 degrees. This angle is subtended by a line drawn through proximal physis of the femur and the horizontal. Normal range is 0 to 30 degrees, mean 15 degrees. Physial angle 30 to 60 degrees, while abnormal, may spontaneously improve or progress unpredictably; as a result, this is followed closely lest there be progression.
- Neck–shaft angle < 120 degrees, for relative varus, or < 90 degrees, for absolute varus. Normal development of neck–shaft angle is 150 degrees at birth to 125 degrees by maturity. Measurement is sensitive to femur rotation. The axis of the neck may be difficult to determine when incompletely grown early in life or when distorted by disease.

Primary coxa vara represents a focal growth disturbance of endochondral ossification in the medial inferior physis of the proximal femur. The defect is characterized by delayed chondral calcification and fibrous replacement. Coxa vara disadvantages the hip abductor muscles. Relative proximal location results in abutment of trochanter major against acetabulum and lateral ilium, limiting hip abduction. Reduction of the neck–shaft angle, associated with shortening of the neck of the femur (*coxa brevis*), shortens the affected lower limb and leads to length discrepancy.

Evaluation

History and physical examination History aids identification of acquired coxa vara. The condition typically manifests after walking. Abductor weakness results in a Trendelenburg gait. Hip abduction is limited. Trochanter major is prominent. The affected limb is short, with associated genu valgum. The older patient complains of lateral hip pain, in the region of trochanter major and in the buttock due to abductor muscle fatigue. A broad physical examination may show signs of a generalized disorder.

Imaging Röntgenogrammes are fundamental. They define the deformity and elucidate whether the presentation is primary or acquired. In primary coxa vara, an anomalous radiolucent line diverging from the inferior medial proximal physis of the femur forms an inverted Y and outlines a triangular island of bone having its base at the inferior contour of the neck [C]. Scintigraphy measures metabolic activity of primary osseous disease. MRI provides detail of the proximal physis of the femur and of a morbid process affecting bone. CT defines structure of the proximal femur, including in three-dimensions in preparation for operative treatment.

Management

Symptoms and signs may be managed medically, for example, nonnarcotic analgesics for hip pain. Osteotomy is indicated for:

- Unacceptable symptoms or signs, including hip pain from abductor fatigue or Trendelenburg gait
- Severe deformity, including negative articulothrochanteric distance, physical angle >60 degrees, neck–shaft angle < 90 degrees
- Progressive deformity

Intertrochanteric osteotomy Perform a transverse osteotomy, and fix with a blade or plate placed into the epiphysis if necessary [C]. More complex osteotomies (e.g., Pauwels) or less secure fixation (e.g., smooth wires or cable) may jeopardize stability of construct, in particular in a young child. In primary coxa vara, reduce the physical angle to < 30 degrees. Counsel parents that, like tibia vara (Blount), this is a growth disturbance, and as such, there may be recurrence of deformity despite correction. Whether the result of this osteotomy is improved, including reduction of recurrence, by concurrent physodesis of the trochanter major, is debatable. This latter procedure is reserved for a child toward the end of the first decade.

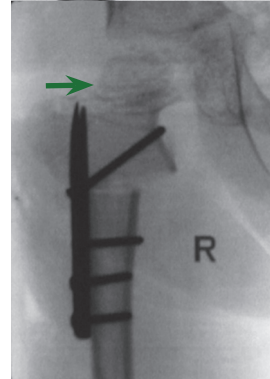
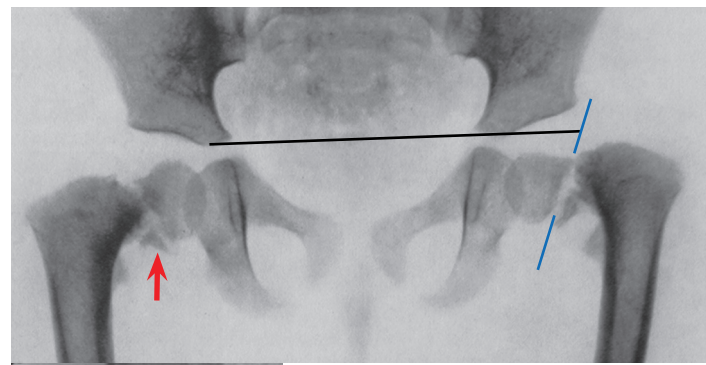
Trochanteric transfer This is indicated in the second decade, after acetabulum has remodeled in response to the deformed femur, and for secondary coxa vara, as a less morbid alternative to intertrochanteric osteotomy. The trochanter major is transferred distal and lateral, to bring its top to the level of the center of the head of the femur.

SNAPPING HIP

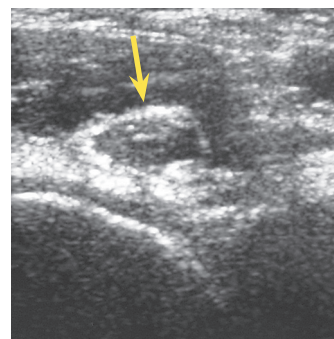
This term encompasses extra-articular causes, in contrast with intra-articular causes such as disease of labrum [D]. It also is known as *coxa saltans*, from Latin *saltare*: “to jump.” A snap may be heard or felt from the hip when a tight tendon or band shifts abruptly over an osseous prominence, such as when arising from a chair or changing direction of walking. Snapping may be accompanied by pain and a sense of hip instability. The iliopsoas may subluxate over the iliopectineal eminence during hip flexion–extension and medial–lateral rotation. The rectus femoris conjoined tendon may catch at the head of the femur during flexion. The iliotibial tract may subluxate over the trochanter major during walking.

Evaluation Presentation typically is in the second decade, when growth becomes rapid and sports become more demanding. Simulate the motion that produces snapping by physical examination, in order to localize the structure responsible. The Ober test reveals contracture of iliotibial tract. Crepitus may be palpated at the groin during extension and lateral rotation of the hip from a flexed, adducted, and medially rotated position, as the iliopsoas subluxates. Dynamic ultrasonography may show iliopsoas subluxation at the brim of the pelvis [A].

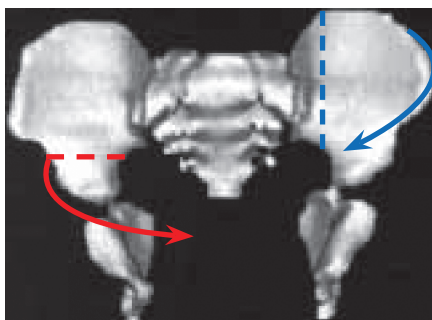
Management The foundation of management is stretching. This may be guided by a physiotherapist, who also may train the dancer who most commonly presents with a snapping iliopsoas, or the runner with an iliotibial tract contracture. For cases refractory to stretching, in addition to nonsteroidal anti-inflammatory agents and activity modification and progression, operative treatment is indicated. The iliopsoas may be lengthened open at the brim of the pelvis, or arthroscopically transcapsular or at trochanter minor. The latter may be associated with weakness of hip flexion. The iliotibial tract may be partially sectioned, ellipsed over the trochanter major or lengthened, open or arthroscopically.



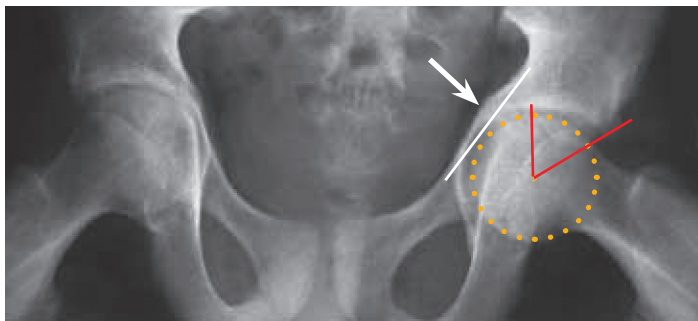
C Primary coxa vara An inverted radiolucent Y outlines a triangular island of bone in the medial inferior neck of the femur (red). The physical angle is > 60 degrees (blue). Intertrochanteric osteotomy using a modified LCDC plate cut to produce terminal prongs and inserted as a blade places proximal physis of femur horizontal (green).



D Snapping hip Ultrasonogram shows subluxation of the iliopsoas tendon (yellow) at the brim of the pelvis. Röntgenogrammes are normal.



A Osteotomy for exstrophy of the bladder Site of osteotomy may be posterior, parallel to the sacroiliac joint (*blue*), or anterior, proximal to the acetabulum (*red*).



B Deepening of acetabulum In coxa profunda, the floor of the acetabulum thrusts medialward beyond ilioischial line (*white*). When the head of the femur (*orange*) crosses the ilioischial line, this is distinguished as protrusio acetabuli. Note that as the acetabulum deepens, center-edge angle (*red*) increases (in this case, 60 degrees), producing pincer impingement.

EXSTROPHY OF THE BLADDER

This also is known *ectopia vesicae*. Anterior rupture of the cloacal membrane during the embryonic period with failure of midline closure of the pelvis results in eversion of the urinary bladder, genital anomalies, and diastasis of the innominate bones.

Evaluation This may be diagnosed by foetal ultrasonogramme. The diagnosis is clear on physical examination of the neonate.

Management Surgical reconstruction and midline closure of the bladder, genitalia, and abdominal wall are aided by innominate osteotomy with medial rotation of anterior ring of the osseous pelvis [A]. Site of osteotomy may be posterior, parallel to the sacroiliac joint, or anterior, proximal to the acetabulum. Both osteotomies pass through the greater sciatic notch. Posterior osteotomy is performed in the prone position, requiring turning of the patient supine for bladder repair. Postoperative care includes suspension with lower limbs adducted together until stable callus, after which a cast or brace is applied until healing. Anterior osteotomy is performed in the supine position. It is fixed with wires, which are supplemented with cast or brace that features sufficient space for postoperative care of bladder repair. External fixation in older patients obviates the need for immobilization, which facilitates postoperative care.

Despite innominate osteotomy, pubic diastasis persists, as do retroversion of the acetabulum and out-toeing gait. Persistent acetabular deformity may be addressed at maturity with reverse peri-acetabular osteotomy, which may reduce potential for femoro-acetabular impingement, improve hip motion and reduce out-toeing gait.

PROTRUSIO ACETABULI

Evaluation Presentation is hip pain without or with stiffness in a patient at risk, including Marfan syndrome, seronegative spondyloarthropathy, and conditions that weaken bone. The condition is defined radiographically [B]. Displacement of the floor of acetabulum medial to the ilioischial line (of Köhler) is defined as *coxa profunda*: “deep hip.” “Thrusting forward” of the head of the femur medialward beyond the ilioischial line is defined as *protrusio acetabuli*. Center-edge angle is > 45 degrees. MRI shows pincer morphology of acetabulum.

Idiopathic or primary protrusio acetabuli typically affecting middle-aged women, of whom 1/2 will have a bilateral presentation, first was described by the German surgeon A.W. Otto, whence the eponym Otto pelvis. It also is known by the Greek term arthrokatachysis: “joint sinking”.

Management Treat an underlying arthropathy. Relieve symptoms with rest, activity modification, and nonsteroidal anti-inflammatory medications. Operate rarely. While physodesis of the triradiate during childhood may slow deepening of the acetabulum, there are no reliable long-term studies of the procedure. Débridement of the anterior wall of acetabulum, or reverse periacetabular osteotomy, may relieve anterior femoroacetabular impingement.

FEMOROACETABULAR IMPINGEMENT

This relatively new concept fills a void heretofore unrecognized or deemed “overuse” hip pain. It depends on imaging, projection, and patient position. The natural history suggests premature coxarthrosis.

Pathoanatomy

There are two types [A].

- In cam impingement, relative posterior displacement of the head of the femur brings the neck into premature contact with the acetabulum, thereby leading to osteophyte formation with or without cystic change. This is characteristic of deformity after slipped capital femoral epiphysis and of implant prominence after its surgical treatment [B]. It may be measured by the angle between axis of the neck and junction of the neck and head. Cam impingement has been shown to increase risk of coxarthrosis by more than twofold
- In pincer impingement, an acetabulum that is deep and excessively covers the head of the femur “pinches” the neck and thereby restricts motion. This is seen radiographically as an increased center–edge angle and as a retroverted acetabulum with a crossover sign [C].

Evaluation

Abnormal contact between the neck of the femur and edge of acetabulum produces a spectrum of disease.

- There is groin pain with terminal flexion, which is reduced. This differs from the pain of DDH, which is associated with normal or increased motion due to deficiency of the anterior acetabulum.
- Disease of labrum includes hypermobility, cyst, and tear. This may manifest as crepitus during activity and during physical examination.
- Articular cartilage of acetabulum degenerates.
- Neck of the femur reacts as a result of stress concentration.

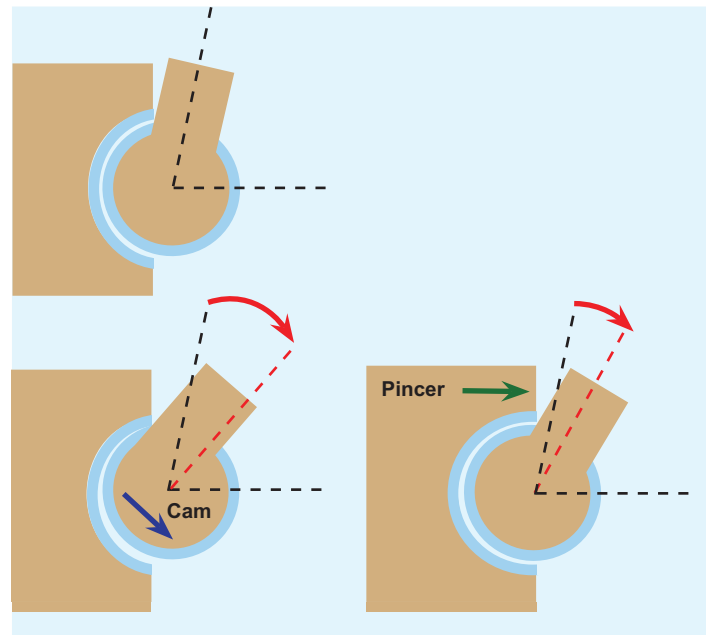
Neck morphology is apparent on röntgenogrammes. Articular disease may be seen on MRI and arthroscopy. Diagnostic uncertainty may be addressed by adding anæsthetic to arthrography during MRI.

Management

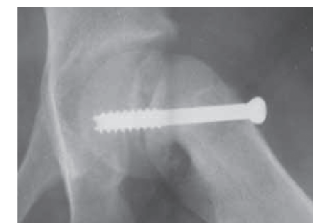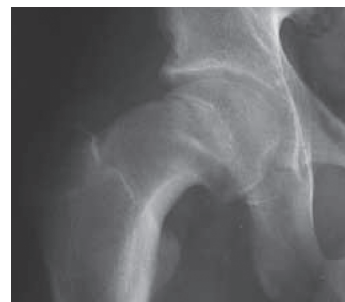Arthroscopy Absent significant underlying deformity, this is the most benign method. A diseased labrum may be débrided or repaired. A neck osteophyte or a prominent edge of acetabulum may be débrided, although the adequacy of these may be difficult to determine, for example, excessive bone removal from the neck of the femur risks fracture.

Open surgical treatment For osseous work, this offers greater control and allows dynamic testing to calibrate extent. Through a small incision anterior approach and exposure, labrum, neck osteophyte, and edge of acetabulum may be addressed. Through a hip dislocation technique, all may be addressed in addition to evaluation and management of acetabular cartilage. The severity of disease must justify the morbidity of the latter treatment method.

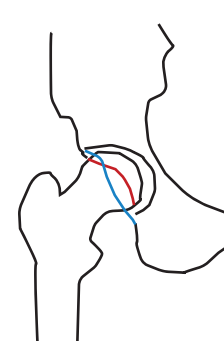
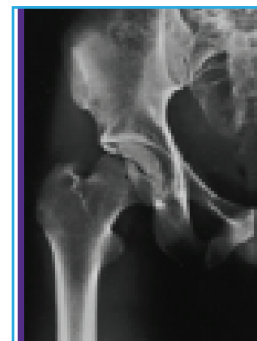Primarily treat significant underlying osseous deformity. Correct the deformity of the proximal femur after severe slipped capital femoral epiphysis, as well as the labral tear it has produced. Reorient an acetabulum that is retroverted but not too large, rather than trimming the anterior rim, lest a deficiency state be created [D].



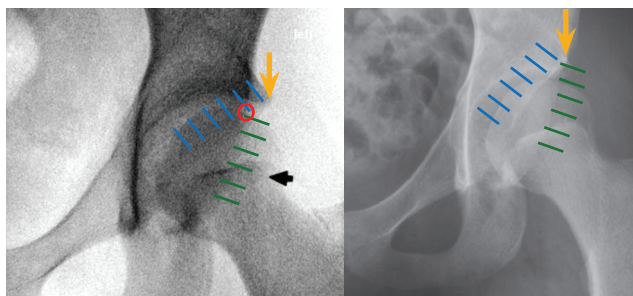
A Types of impingement Cam type may be seen with posterior displacement of the head on the neck of the femur (*blue*). Pincer type occurs when acetabulum is deep and excessively covers the head of the femur (*green*). Femur contacts acetabulum at earlier flexion (*red*).



B Cam impingement In slipped capital femoral epiphysis, this may be due to posterior displacement of the head on the neck, or to implant prominence on anterior neck with increasing olisthy.



C Acetabular retroversion Anterior wall (*red*) crosses posterior wall (*blue*) to impinge on the neck of the femur.



D Open treatment of impingement The anterior wall (*blue*) of acetabulum, which crosses (*red*) posterior wall, was trimmed by an anterior approach, exposing acetabular deficiency (*orange*).

GENERAL

- Chung SMK. The arterial supply of the developing proximal end of the femur. *J. Bone Joint Surg. Am.* 58(7):961–970, 1976.
- Hilton J. *On the Influence of Mechanical and Physiological Rest in the Treatment of Accidents and Surgical Diseases, and the Diagnostic Value of Pain.* London: Bell and Daldy, 1863.
- Pauwels F. *Biomechanics of the Normal and Diseased Hip.* New York: Springer-Verlag, 1976.
- Trueta J. The normal vascular anatomy of the human femoral head during growth. *J. Bone Joint Surg. Br* 39(2):358–394, 1957.

DDH

- Barlow TG. Early diagnosis and treatment of congenital dislocation of the hip. *J. Bone Joint Surg. Br.* 44(2):292–301, 1962.
- Chiari K. Medial displacement osteotomy of the pelvis. *Clin. Orthop.* 98:55–71, 1974.
- Dunn PM. Clicking hips should be ignored. *Lancet* 1:846, 1984.
- Ferguson AB Jr. Primary open reduction of congenital dislocation using a median adductor approach. *J. Bone Joint Surg. Am.* 55(4):671–689, 1973.
- Galeazzi R. *Il Pio Istituto Rachitici di Milano.* Milan, Italy: Bergamo, 1874–1913.
- Ganz R, Klaue K, Vinh TS, Mast JW. New periacetabular osteotomy for treatment of hip dysplasias. Technique and preliminary results. *Clin. Orthop.* 232:26–36, 1988.
- Graf R. Classification of hip joint dysplasia by means of sonography. *Arch. Orthop. Trauma Surg.* 102(4):248–255, 1984.
- Harcke HT, Kumar SJ. The rôle of ultrasound in the diagnosis and management of congenital dislocation and dysplasia of the hip. *J. Bone Joint Surg. Am.* 73(4):622–628, 1991.
- Harris WH. Etiology of osteoarthritis of the hip. *Clin. Orthop.* 213:20–33, 1986.
- Hilgenreiner H. Zur frühdiagnose und frühbehandlung der angeborenen hüftgelenkuerrenkung. *Med. Klin.* 21:1385, 1925.
- Le Damany P. *La Luxation Congénitale de la Hanche; Études d'Anatomie Comparée, d'Anthropogénie Normale et Pathologique, Déductions Thérapeutiques.* Paris: F. Alcan, 1912.
- Lequesne M, de Séze S. Le faux profil du bassin. Nouvelle incidence radiographique pour l'étude de la hanche. Son utilité dans les dysplasies et les différentes coxopathies. *Rev. Rhum. Mal. Osteoartic.* 28:643, 1961.
- Lorenz A. The operative treatment of congenital dislocation of the hip. *Trans. Am. Orthop. Assoc.* 7:99, 1895.
- Ludloff K. Open reduction of the congenital hip dislocation by anterior incision. *Am. J. Orthop. Surg.* 10(3):438–454, 1913.
- Ortolani M. Un segno poco noto e sua importanza per la diagnosi precoce di prelussazione congenita dell'anca. *Pediatria.* 45:129–137, 1937.
- Pavlik A. Stirrups as an aid in the treatment of congenital dysplasias of the hip in children. *J. Pediatr. Orthop.* 9(2):157–159, 1989. Translated by V. Bialik & N.D. Reis.
- Pemberton PA. Pericapsular osteotomy of the ilium for treatment of congenital subluxation and dislocation of the hip. *J. Bone Joint Surg. Am.* 47(1):65–86, 1965.
- Perkins G. Signs by which to diagnose congenital dislocation of the hip. 1928. *Clin. Orthop.* 274:3–5, 1992.
- Rosen S von. Early diagnosis and treatment of congenital dislocation of the hip joint. *Acta Orthop. Scand.* 26(2):136–155, 1956.
- Salter RB. Innominate osteotomy in the treatment of congenital dislocation of the hip. *J. Bone Joint Surg. Br.* 43(3):518–539, 1961.
- Sharp IK. Acetabular dysplasia. The acetabular angle. *J. Bone Joint Surg. Br.* 43(2):268–272, 1961.
- Shenton EWH. *Disease in Bones and its Detection by X-Rays.* London: Macmillan, 1911.
- Smith-Petersen MN. A new supra-articular subperiosteal approach to the hip joint. *Am. J. Orthop. Surg.* 15:592–595, 1917.
- Staheli LT. Slotted acetabular augmentation. *J. Pediatr. Orthop.* 1(3):321–327, 1981.

- Steel HH. Triple osteotomy of the innominate bone. *J. Bone Joint Surg. Am.* 55(2):343–350, 1973.
- Sutherland D, Greenfield, R. Double innominate osteotomy. *J. Bone Joint Surg. Am.* 59(8):1082–1091, 1977.
- Tönnis D. Normal values of the hip joint for the evaluation of X-rays in children and adults. *Clin. Orthop.* 119:39–47, 1976.
- Tönnis D, Behrens K, Tscharanri F. A modified technique of the triple pelvic osteotomy: early results. *J. Pediatr. Orthop.* 1(3):241–249, 1981.
- Trendelenburg F. *Dtsch. Med. Wschr.* 21:21, 1895.
- Wagner, H. Osteotomies for congenital hip dislocation. In: *Proceeding of the Fourth Open Scientific Meeting of the Hip Society.* St. Louis, MO; 1976.
- Wiberg G. Studies on dysplastic acetabula and congenital subluxation of the hip joint. *Acta Chirurg. Scand.* 83(Suppl. 58):1, 1939.

LCP

- Calvé J. Sur une forme particulière de pseudo-coxalgie-Greffée sur des déformations caractéristiques de l'extrémité supérieure du fémur. *Rev. Chir.* 42:54–84, 1910.
- Catterall A. The natural history of Perthes' disease. *J. Bone Joint Surg. Br.* 53(1):37–53, 1971.
- Gage HC. A possible early sign of Perthes' disease. *Brit. J. Radiol.* 6:295–297, 1933.
- Herring JA, Neustadt JB, Williams JJ, Early JS, Browne RH. The lateral pillar classification of Legg Calvé Perthes disease. *J. Pediatr. Orthop.* 12(2):143–150, 1992.
- Köhler A. *Die Normale und Pathologische Anatomie des Hüftgelenkes und Oberschenkels in Röntgenographischer Darstellung.* Hamburg, Germany; 1905.
- Legg AT. An obscure affection of the hip-joint. *Boston Med. Surg. J.* 162:202–204, 1910.
- Little DG, Kim HKW. Potential for bisphosphonate treatment in Legg-Calvé-Perthes disease. *J. Pediatr. Orthop.* 31(2 Suppl):S182–S188, 2011.
- Meyer J. Dysplasia epiphysealis capitis femoris. A clinical-radiological syndrome and its relationship to Legg-Calvé-Perthes disease. *Acta Orthop. Scand.* 34:183–197, 1964.
- Miyamoto Y, Matsuda T, Kitoh H, Haga N, Ohashi H, Nishimura G, Ikegawa S. A recurrent mutation in type II collagen gene causes Legg-Calvé-Perthes disease in a Japanese family. *Hum. Genet.* 121(5):625–629, 2007.
- Mose K. *Legg-Calvé-Perthes disease. A comparison among three methods of conservative treatment.* Thesis at Universitetsforlaget, Arthus, Denmark, 1964.
- Perthes GC. Über arthritiden juvenilis. *Deutsch. Ztschr. Chir.* 107:111–159, 1910.
- Petrie JG, Bitenc I. The abduction weight bearing treatment in Legg-Perthes disease. *J. Bone Joint Surg. Br.* 53(1):54–62, 1971.
- Rowe SM, Kim HS, Yoon TR. Osteochondritis dissecans in Perthes' disease. Report of 7 cases. *Acta Orthop. Scand.* 60(5):545–547, 1989.
- Salter RB, Thompson GH. Legg-Calvé-Perthes disease. The prognostic significance of the subchondral fracture and a two group classification of the femoral head involvement. *J. Bone Joint Surg. Am* 66(4):479–489, 1984.
- Stulberg SD, Cooperman DR, Wallensten R. The natural history of Legg-Calvé-Perthes disease. *J. Bone Joint Surg. Am.* 63(7):1095–1108, 1981.
- Waldenström H. Der obere tuberkulöse collumherd. *Ztschr. Orthop. Chir.* 24:487–498, 1909.
- Waldenström H. The first stages of coxa plana. *Acta Orthop. Scand.* 5:1–34, 1934.

SCFE

- Boyer DW, Mickelson MR, Ponseti IV. Slipped capital femoral epiphysis. Long-term follow-up of 121 patients. *J. Bone Joint Surg. Am.* 63(1):85–95, 1981.
- Carney BT, Weinstein SL, Noble J. Long-term follow-up of slipped capital femoral epiphysis. *J. Bone Joint Surg. Am.* 73(5):667–674, 1991.
- Diab M, Hresko MT, Millis MB. Intertrochanteric versus subcapital osteotomy in slipped capital femoral epiphysis. *Clin. Orthop.* 427:204–212, 2004.

- Dunn DM. Treatment of adolescent slipping of the upper femoral epiphysis. *J. Bone Joint Surg. Br.* 46:621–629, 1964.
- Fahey JJ, O'Brien ET. Acute slipped capital femoral epiphysis. *J. Bone Joint Surg. Am.* 47(6):1105–1122, 1965.
- Fröhlich A. Ein fall von tumor der hypophysis cerebri ohne akromegalie. *Wein. Klin. Rdsch.* 15:883–906, 1901.
- Ganz R, Gill TJ, Müller ME, Gautier E, Ganz K, Krügel N, Berlemann U. Surgical dislocation of the adult hip. A technique with full access to the femoral head and acetabulum without the risk of avascular necrosis. *J. Bone Joint Surg. Br.* 83(8):1119–1124, 2001.
- Hall JE. The results of treatment of slipped femoral epiphysis. *J. Bone Joint Surg. Br.* 39(4):659–673, 1957.
- Harris WR. The endocrine basis for slipping of the femoral epiphysis. *J. Bone Joint Surg. Br.* 32(1):5–11, 1950.
- Heyman CH, Herndon CH, Strong JM. Slipped femoral epiphysis with severe displacement. A conservative operative treatment. *J. Bone Joint Surg. Am.* 39(2):293–303, 1957.
- Imhäuser G. Spätergebnisse der sog. Imhäuser-osteotomie bei der epiphysenlösung. Zugleich ein beitrag zum problem der hüftarthrose. *Z. Orthop.* 115:716–725, 1977.
- Ingram AJ, Clarke MS, Clarke CS, Marshall RW. Chondrolysis complicating slipped capital femoral epiphysis. *Clin. Orthop.* 165:99–109, 1982.
- Ippolito E, Mickelson MR, Ponseti IV. A histochemical study of slipped capital femoral epiphysis. *J. Bone Joint Surg. Am.* 63(7):1109–1113, 1981.
- Jerre T. A study of slipped capital femoral epiphysis with special reference to late functional and roentgenological results and the value of closed reduction. *Acta Orthop. Scand.* (Suppl 6):3–15, 1950.
- Key JA. Epiphyseal coxa vara or displacement of the capital epiphysis of the femur in adolescence. *J. Bone Joint Surg.* 8:53–117, 1926.
- Klein A, Joplin RJ Reidy JA. Treatment in cases of slipped capital femoral epiphysis at Massachusetts General Hospital. *Arch. Surg.* 46(5):681, 1943.
- Lacroix P, Verbrugge J. Slipping of the upper femoral epiphysis. A pathological study. *J. Bone Joint Surg. Am.* 33(2):371–381, 1951.
- Lehman WB, Grant A, Rose D, Pugh J, Norman A. A method of evaluating possible pin penetration in slipped capital femoral epiphysis using a cannulated internal fixation device. *Clin. Orthop.* 186:65–70, 1984.
- Loder RT, Richards BS, Shapiro PS, Reznick LR, Aronson DD. Acute slipped capital femoral epiphysis. The importance of physal stability. *J. Bone Joint Surg. Am.* 75(8):1134–1140, 1993.
- Moseley C. The "approach-withdraw phenomenon" in the pinning of slipped capital femoral epiphysis. *Orthop. Trans.* 9:497, 1985.
- Murray RO. The etiology of primary osteoarthritis of the hip. *Brit. J. Radiol.* 38(455):810–824, 1965.
- Resnick D. The "tilt deformity" of the femoral head in osteoarthritis of the hip, a poor indicator of previous epiphysiolysis. *Clin. Radiol.* 27(3):355–363, 1976.
- Waldenström H. On necrosis of the joint cartilage by epiphysiolysis capitis femoris. *Acta Chir. Scand.* 67:936–941, 1930.
- Weiner DS, Weiner S, Melby A, Hoyt WA Jr. A 30-year experience with bone graft epiphysiodesis in the treatment of slipped capital femoral epiphysis. *J. Pediatr. Orthop.* 4(2):145–152, 1984.
- Wilson PD, Jacobs R, Schector L. Slipped upper femoral epiphysis. An end result study. *J. Bone Joint Surg. Am.* 47:1128–1145, 1965.

OTHER

- Khan M, Adamich J, Simunovic N, Philippon MJ, Bhandari M, Ayeni O. Surgical management of internal snapping hip syndrome: a systematic review evaluating open and arthroscopic approaches. *J. Arthroscop.* 29(5):942–948, 2013.
- Klaue K, Durm CW, Ganz R. The acetabular rim syndrome. A clinical presentation of dysplasia of the hip. *J. Bone Joint Surg. Br.* 73(3):423–429, 1991.
- Wild AT, Sponseller PD, Stec AA, Gearhart JP. The rôle of osteotomy in surgical repair of bladder exstrophy. *Sem. Pediatr. Surg.* 20(2):71–78, 2011.