

Commonly Missed or Mismanaged Injuries of the Hand

Michael J. Terry, MD

Associate Clinical Professor, UCSF Department of Surgery

April 4, 2024

How ERs classify hand injuries

- Lacerations
- Soft-tissue Injuries and Amputations
- Infections
- Fractures/Dislocations
- HPII
- Burns

How Hand Surgeons classify ER hand injuries

- Emergency
- Urgent
- Urgent Follow-up
- Maybe followup... or PMD

How Hand Surgeons classify ER hand injuries

- Emergency
 - What gets me out of bed at night
- Urgent
 - What could alter my day tomorrow
- Urgent Follow-up
 - What to overbook urgently
- Maybe followup... or PMD
 - What I guess I need to see...

How hand surgeons classify ER hand injuries

- Emergency
 - Necrotizing Fasciitis, Compartment Syndrome, Replant/Revascularization, Dysvascular hand/finger, HP11
- Urgent
 - Open fractures (some), Septic Joints, Spaghetti wrist (perfused)
- Urgent Follow-up
 - Scaphoid fractures, Operative fractures, Tendon and nerve injuries, certain wounds/lacerations
- Maybe followup... or PMD
 - Felon/paronychia/abscess s/p drainage, Fingertip injuries, triquetral avulsion fractures



Things I commonly see missed

1. “Wrist sprains”
2. “Finger sprains”
3. “Non-displaced fractures”
4. “Simple/superficial lacerations”

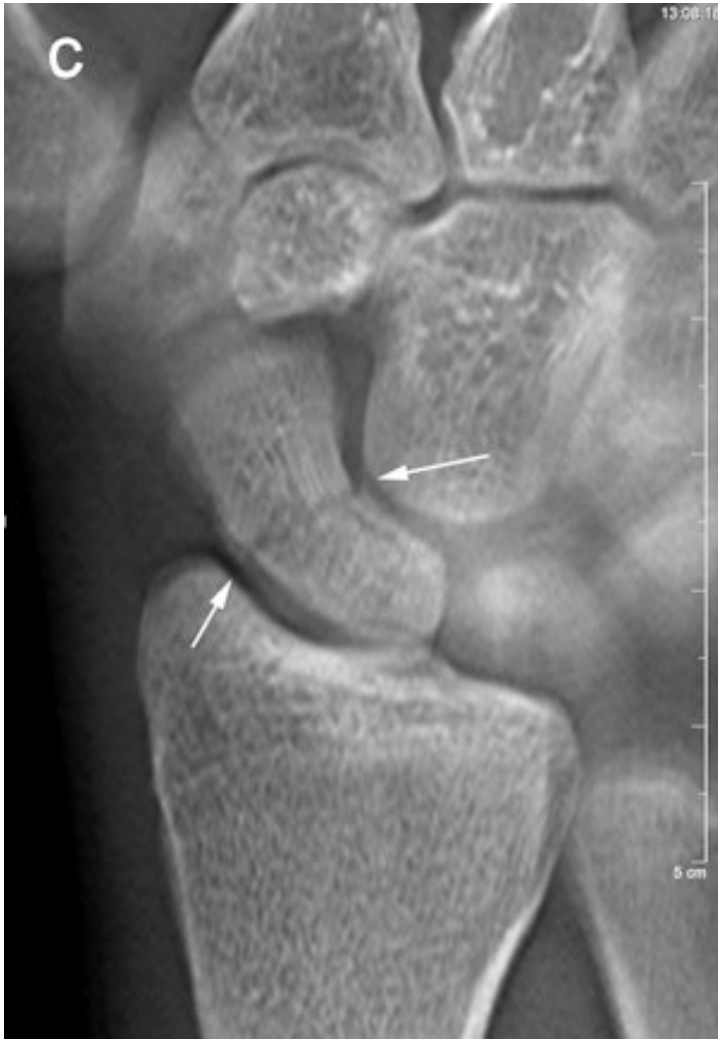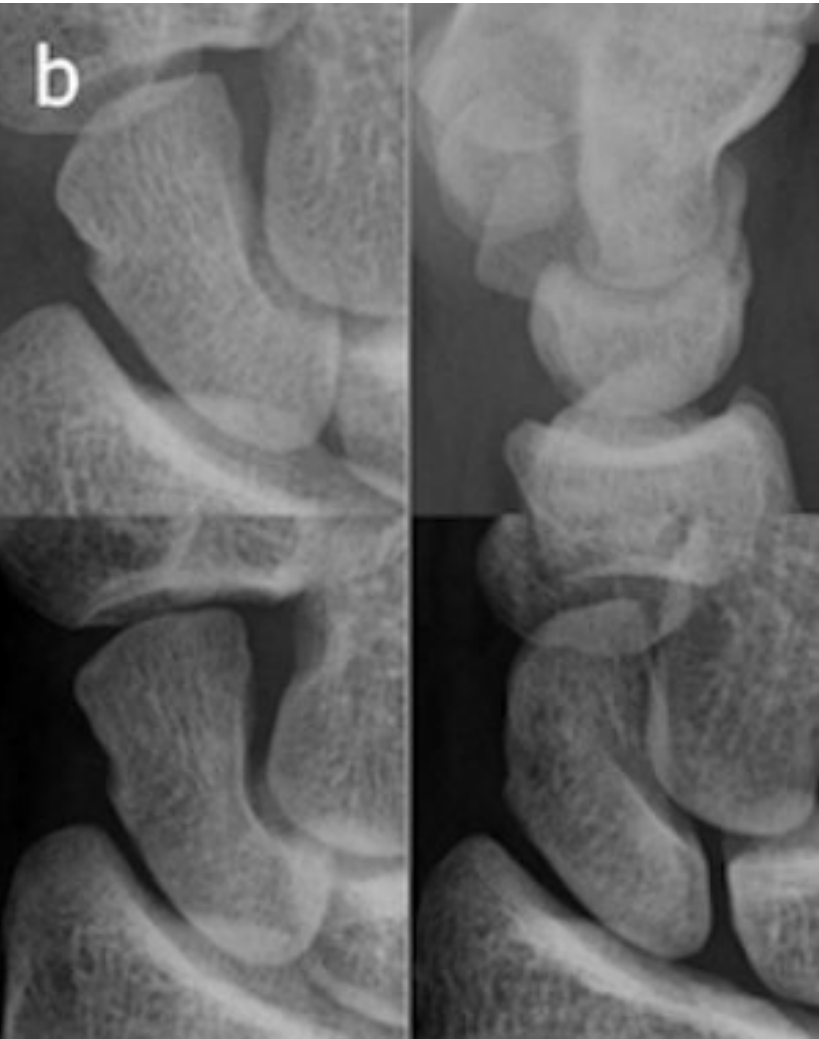
Common Missed Injuries

- “Wrist sprains”
 - Scaphoid fractures
 - Scapholunate injuries
 - Perilunate injuries
 - DRUJ injuries/dislocations
- “Finger sprains”
 - Jersey
 - Mallet
 - Boutonniere
 - Sagittal band rupture
 - UCL/RCL
- “Non-displaced fractures”
 - CMC fracture-dislocations
 - Pediatric finger fractures
- “Simple/superficial lacerations”
 - Missed nerve/tendon injuries
 - Open fractures

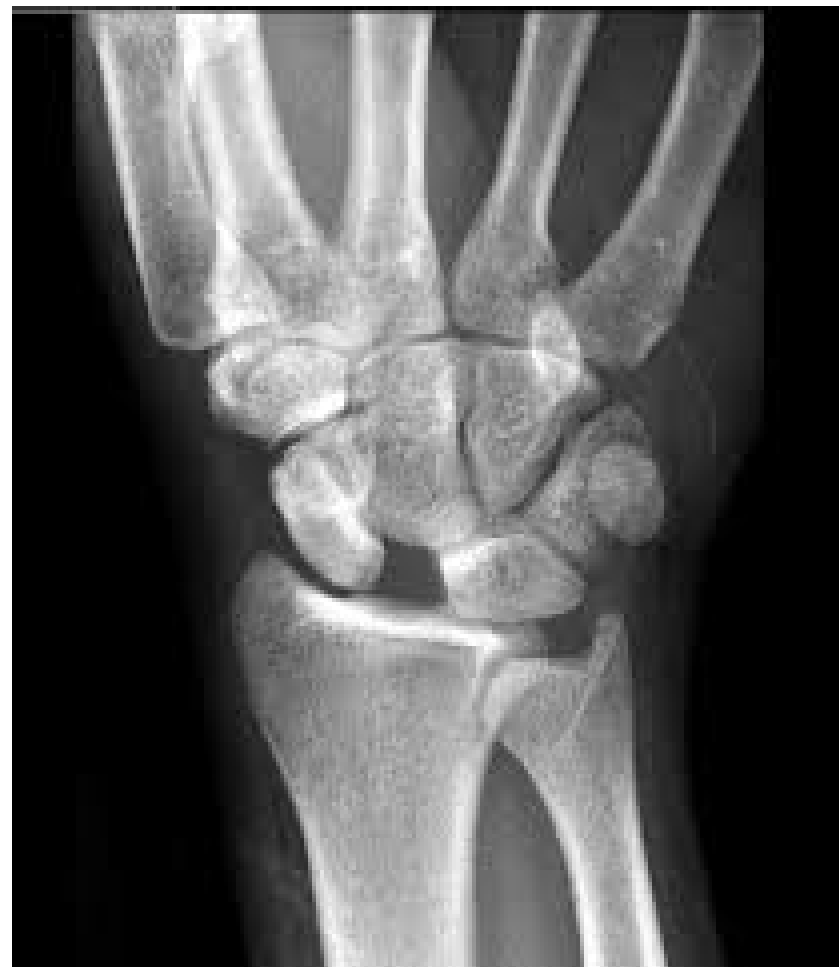“Wrist Sprains”

- Scaphoid fractures
- Scapholunate injuries
- Perilunate injuries

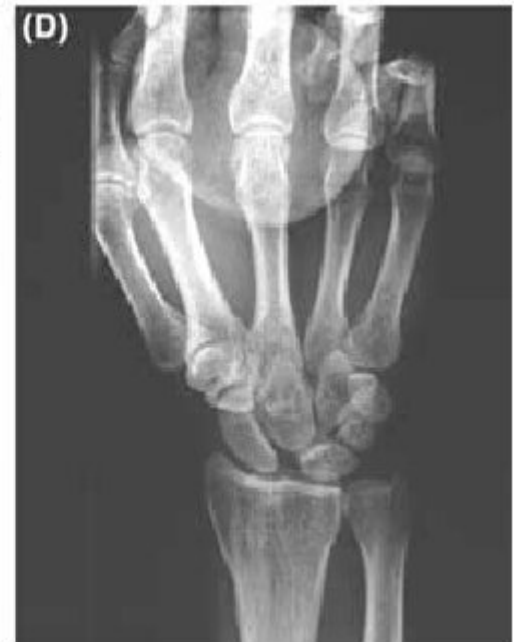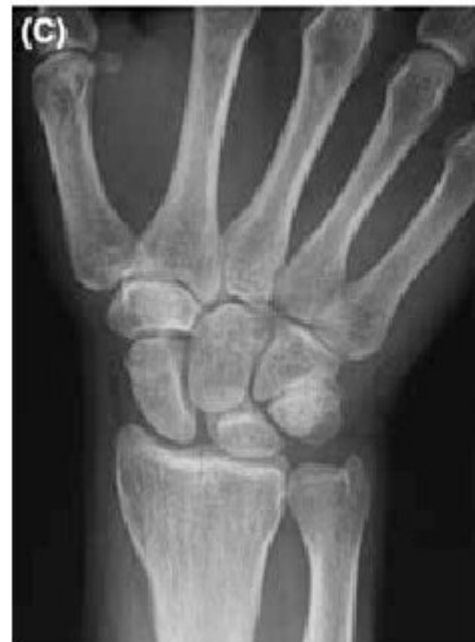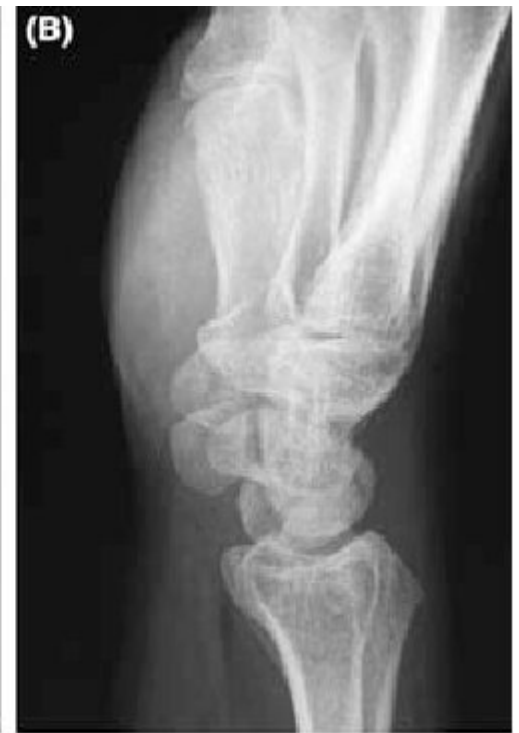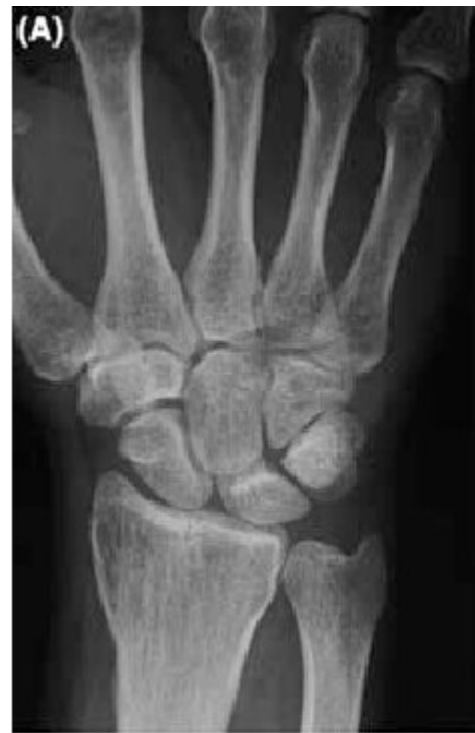Scaphoid Fractures



Scapholunate Injuries

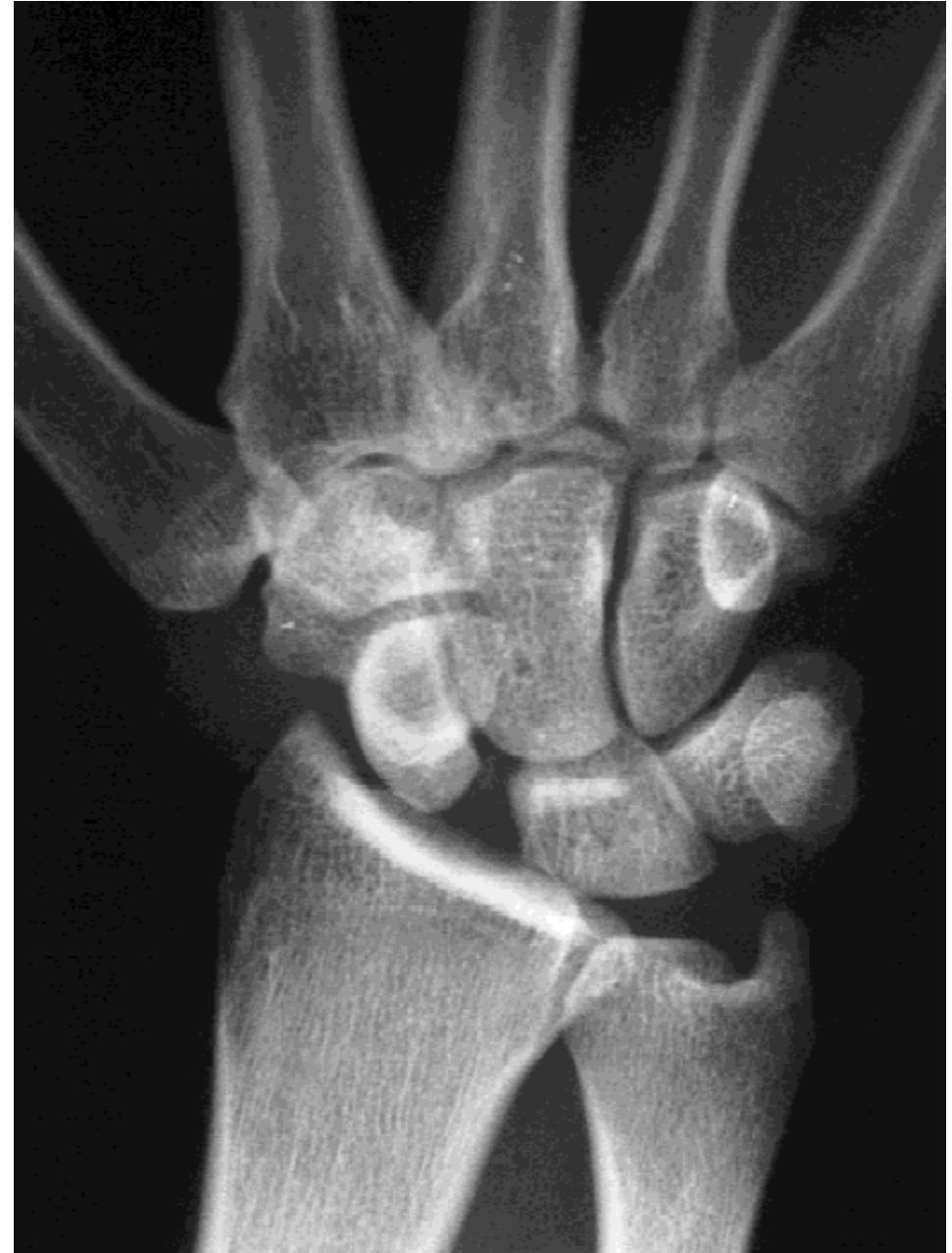

Clenched fist view

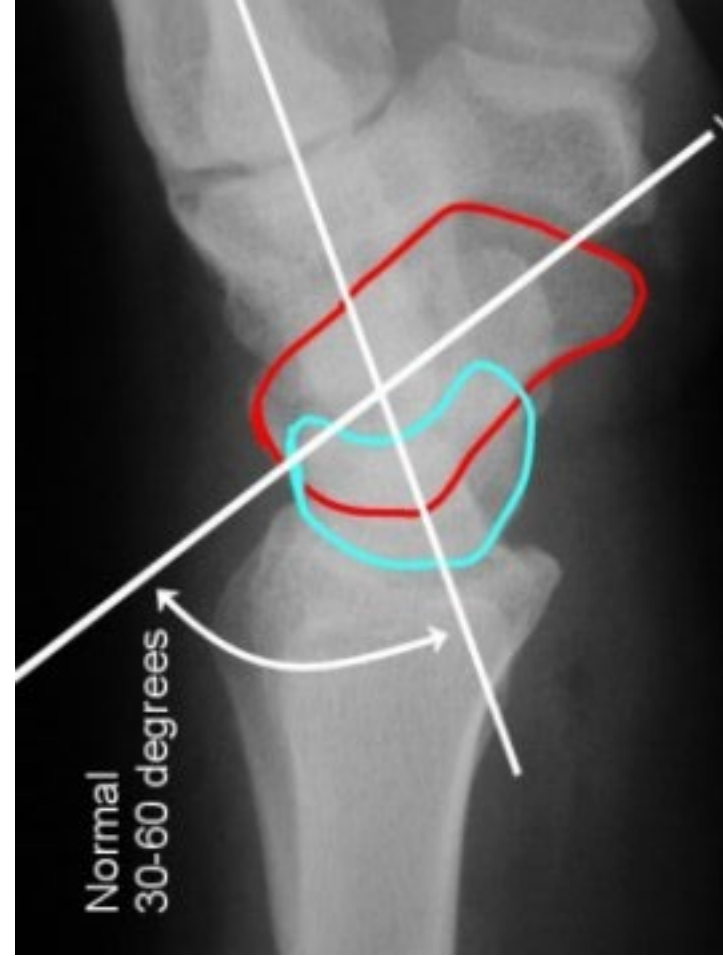
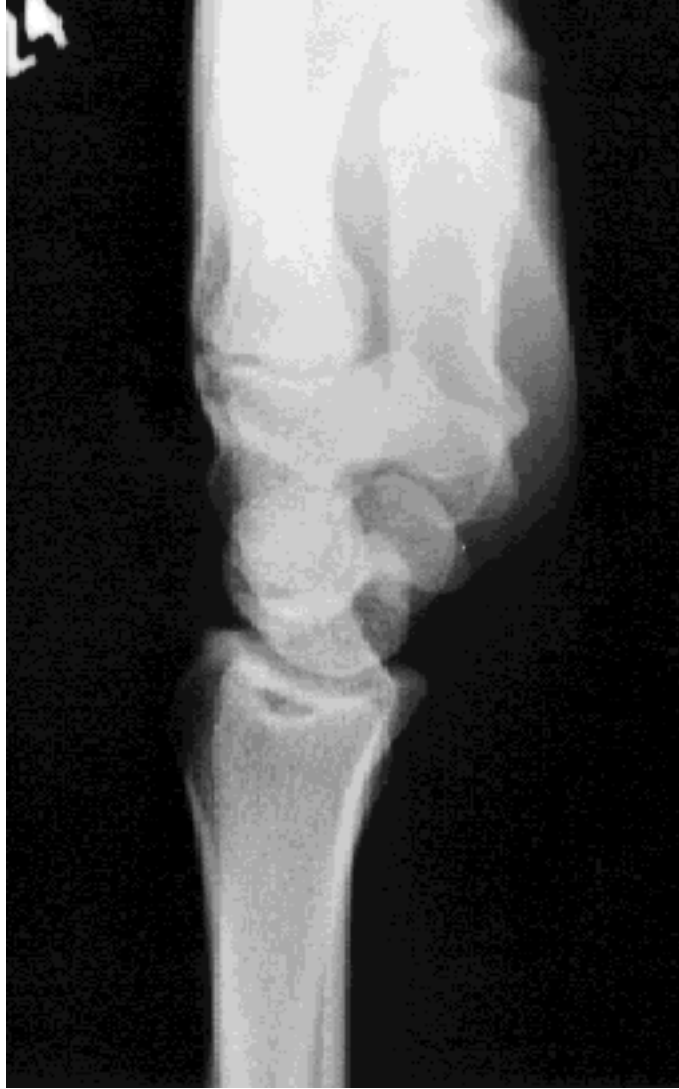

What do you see on imaging of SL tear?

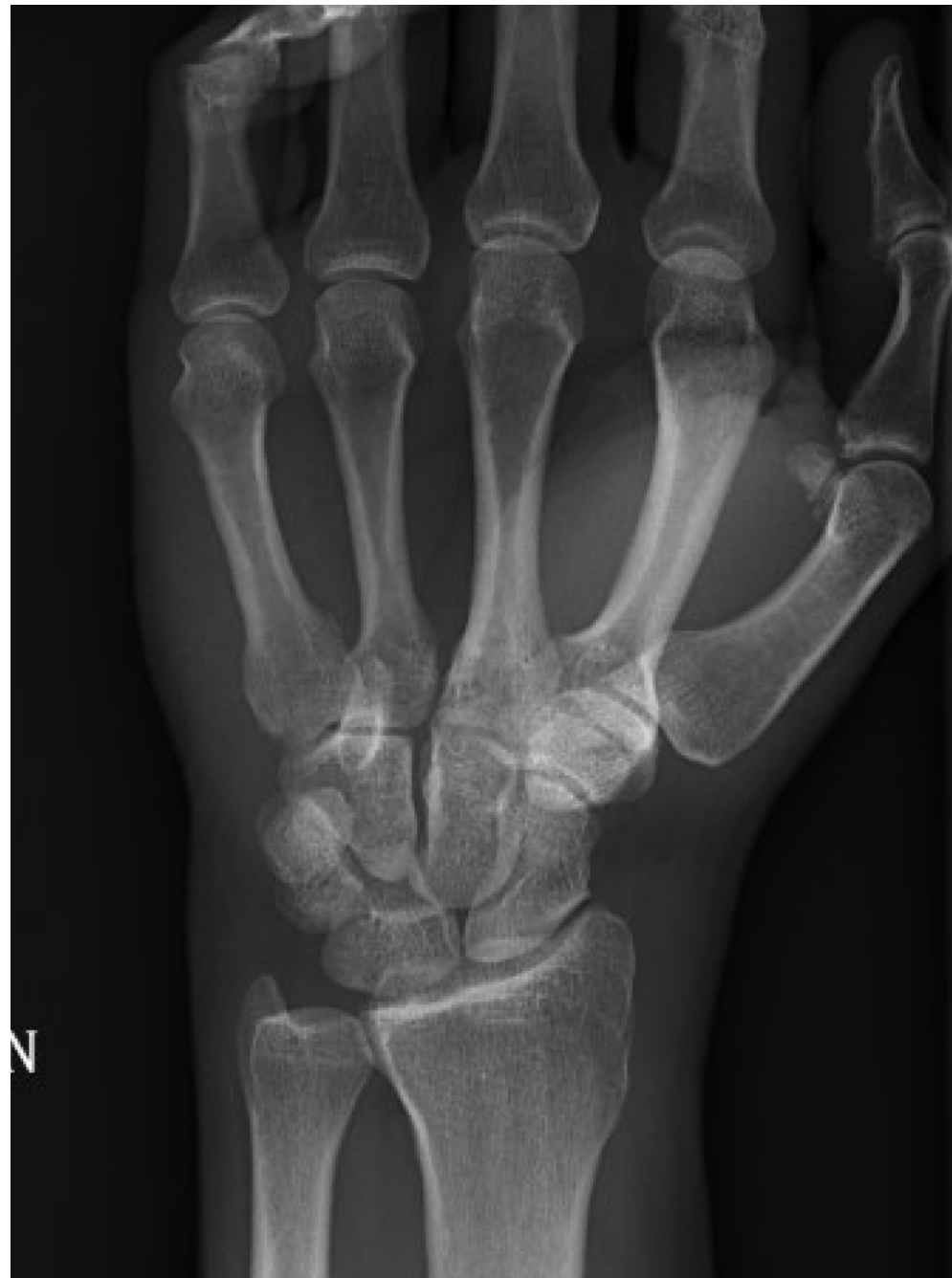- Increased SL interval
 - Terry Thomas
- Cortical ring sign
 - Ring appears (<7mm from the proximal pole)
- Lunate extension, scaphoid flexion



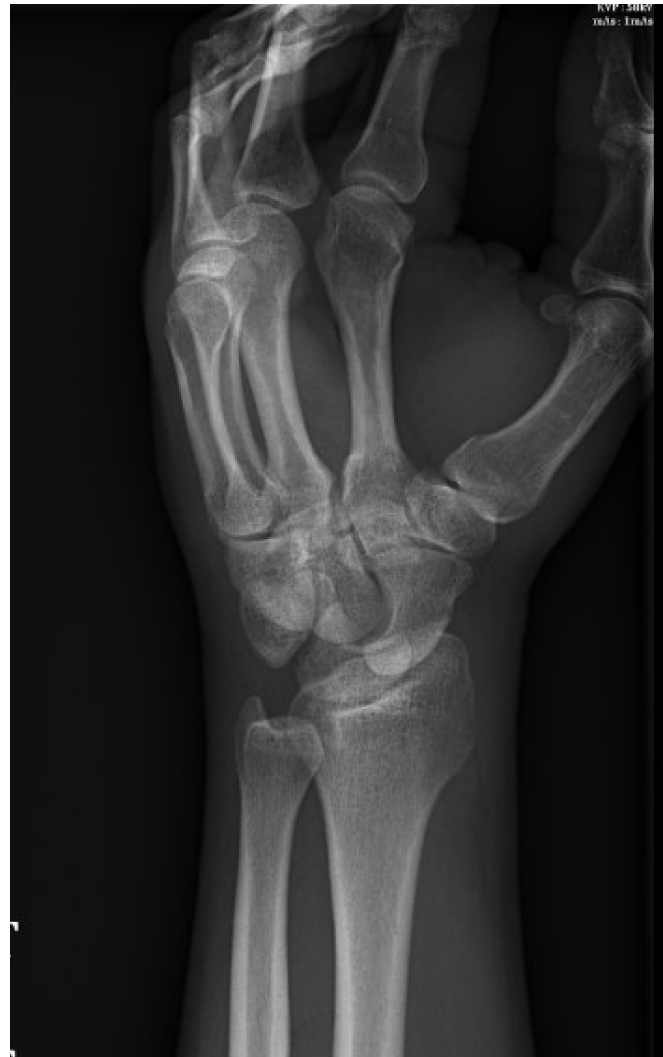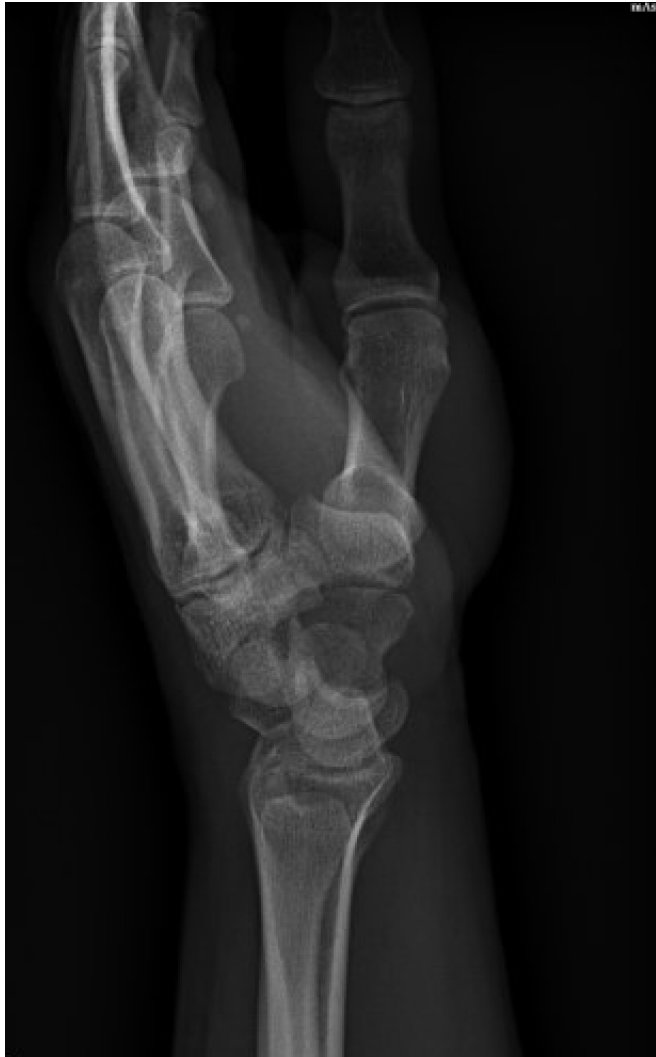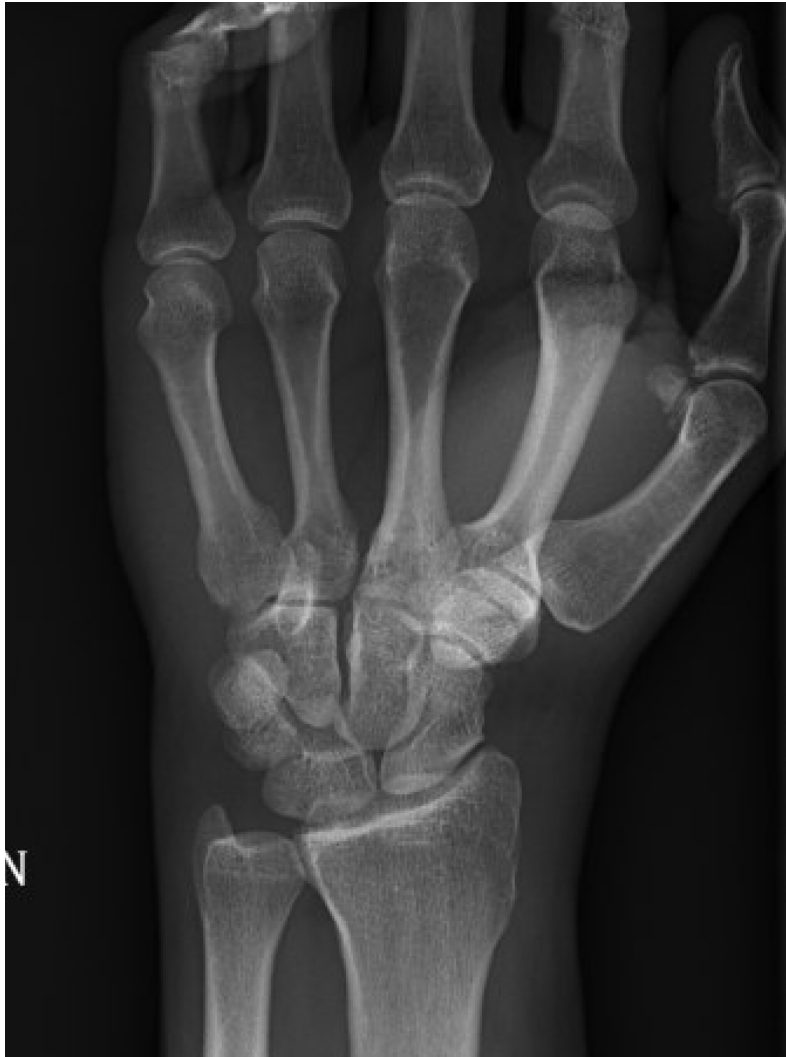Imaging

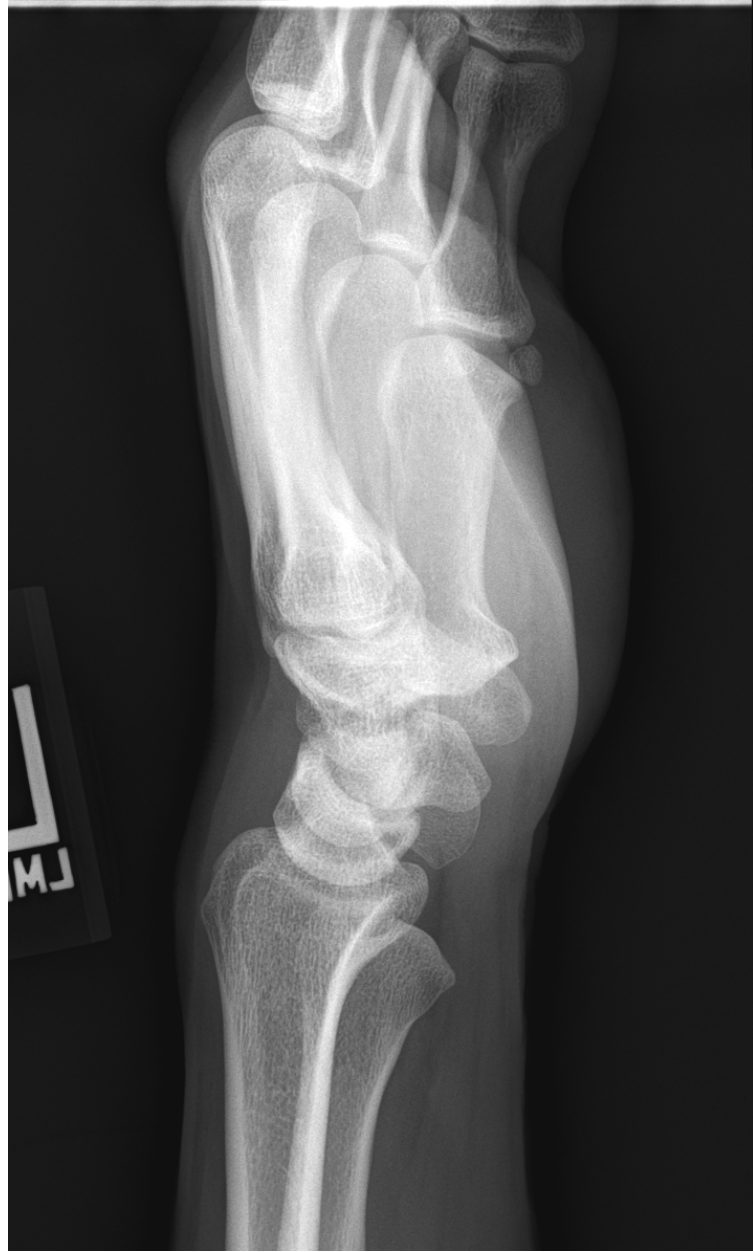
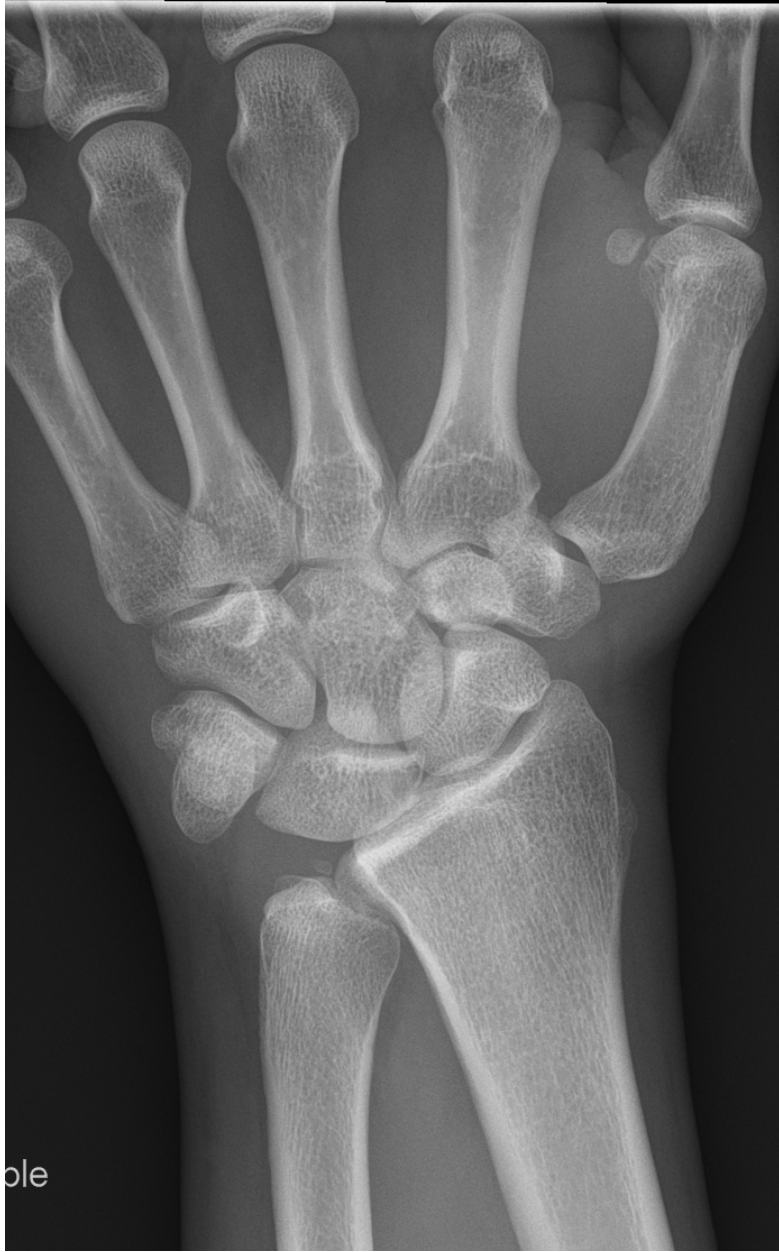
Perilunate Injuries



Perilunate injuries





“Non-displaced” fractures

- Don't settle for mediocre imaging

Findings

Finding:

EXAMINATION: Radiograph of the right fifth finger , 3 views

Indication: Injury

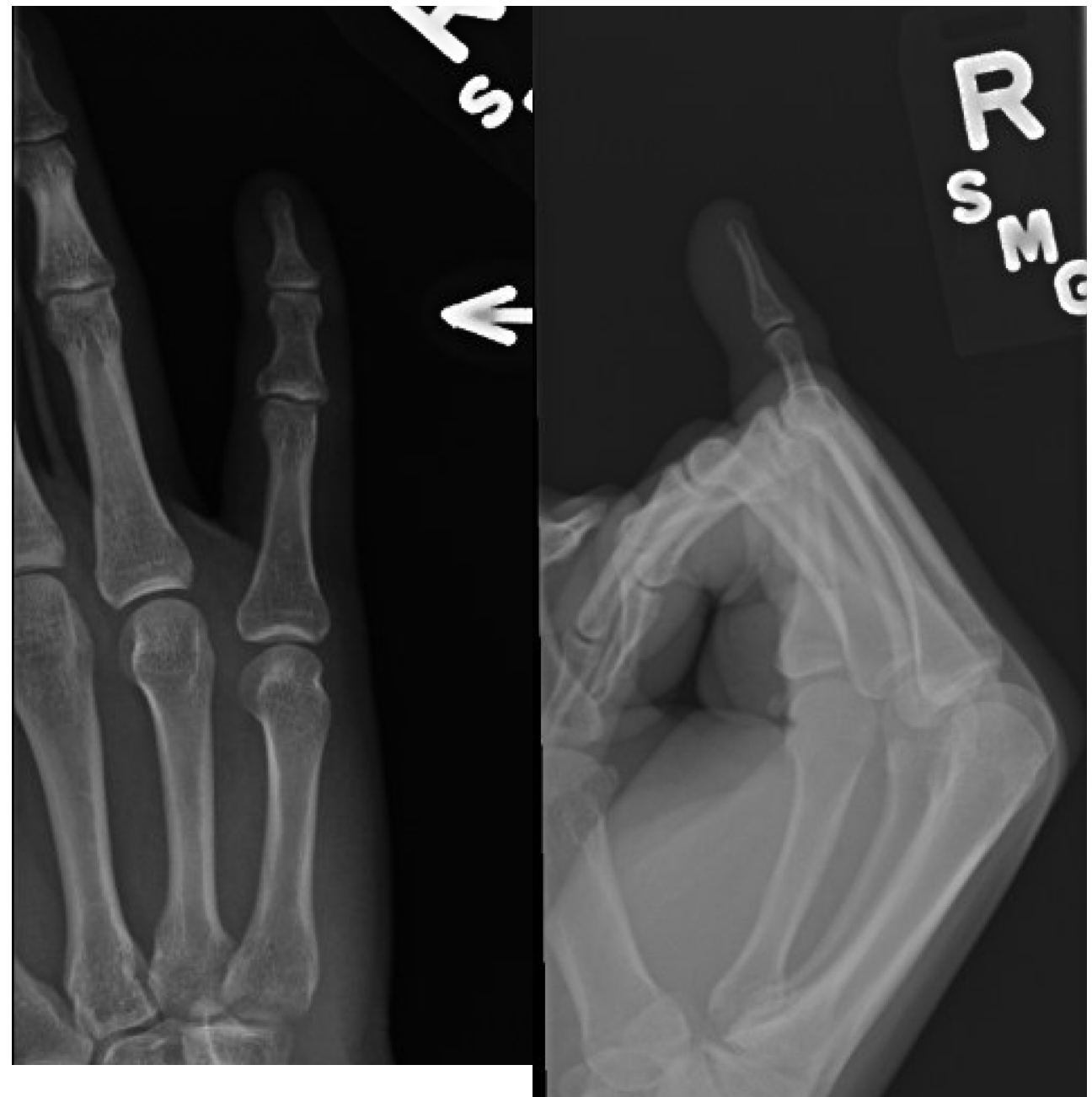Comparison: None

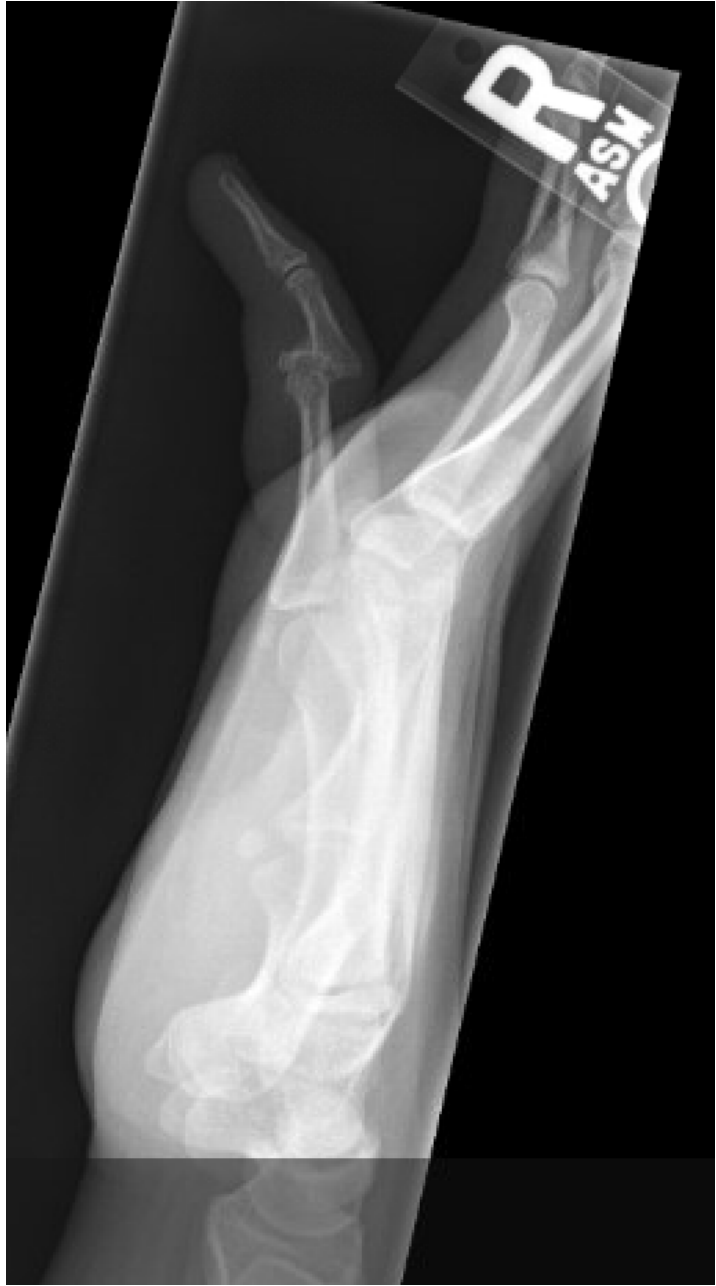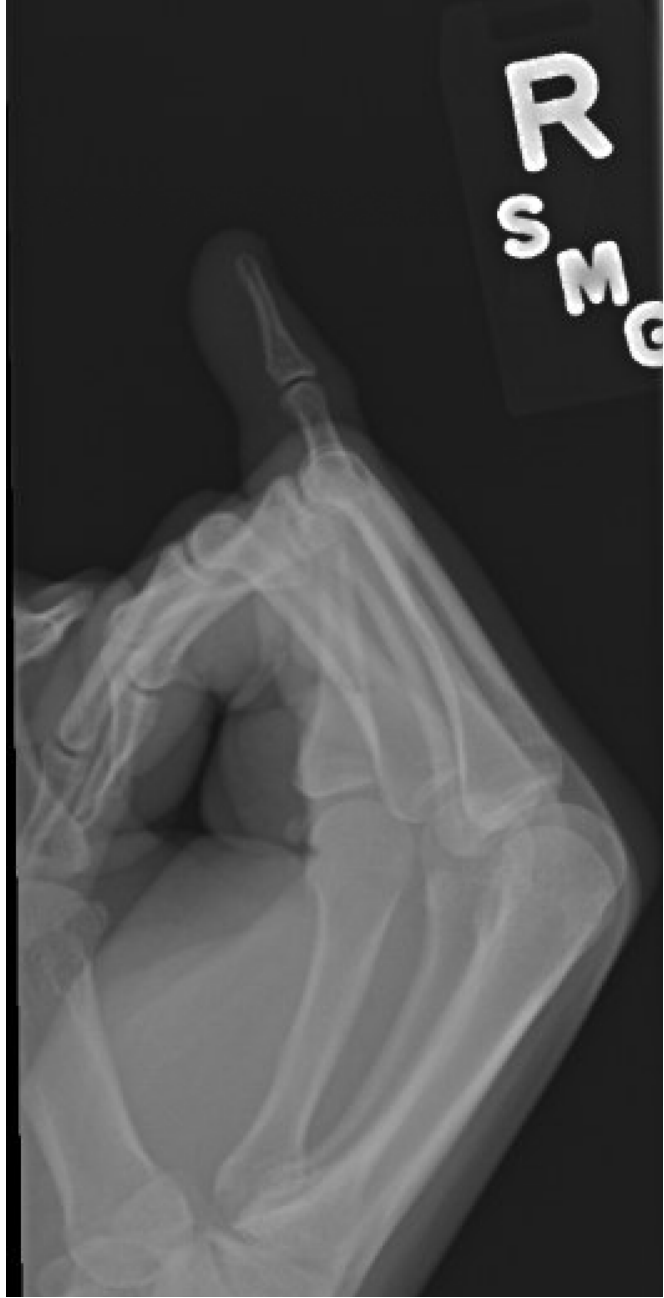Findings:

Bones: There is no acute fracture or malalignment.

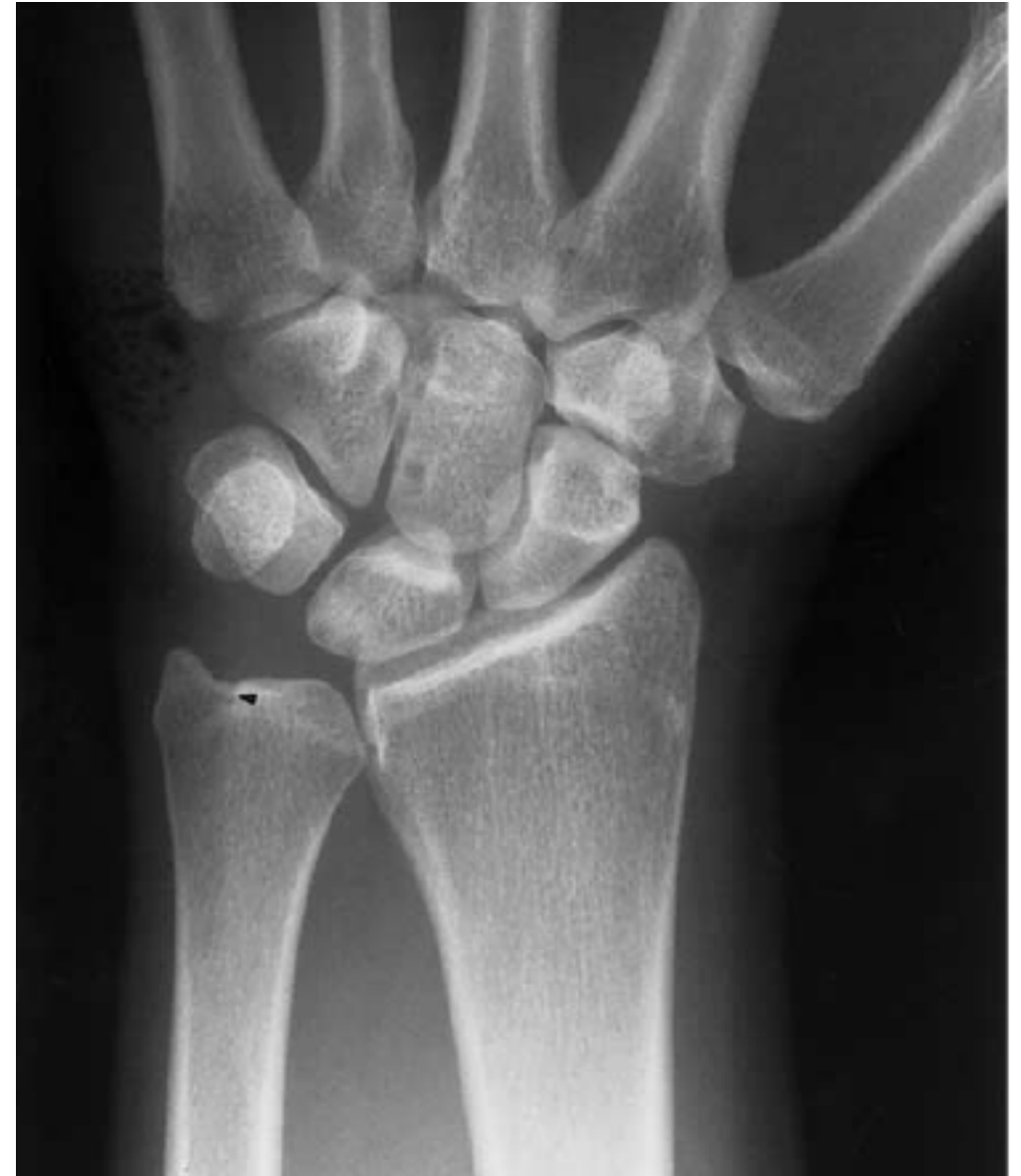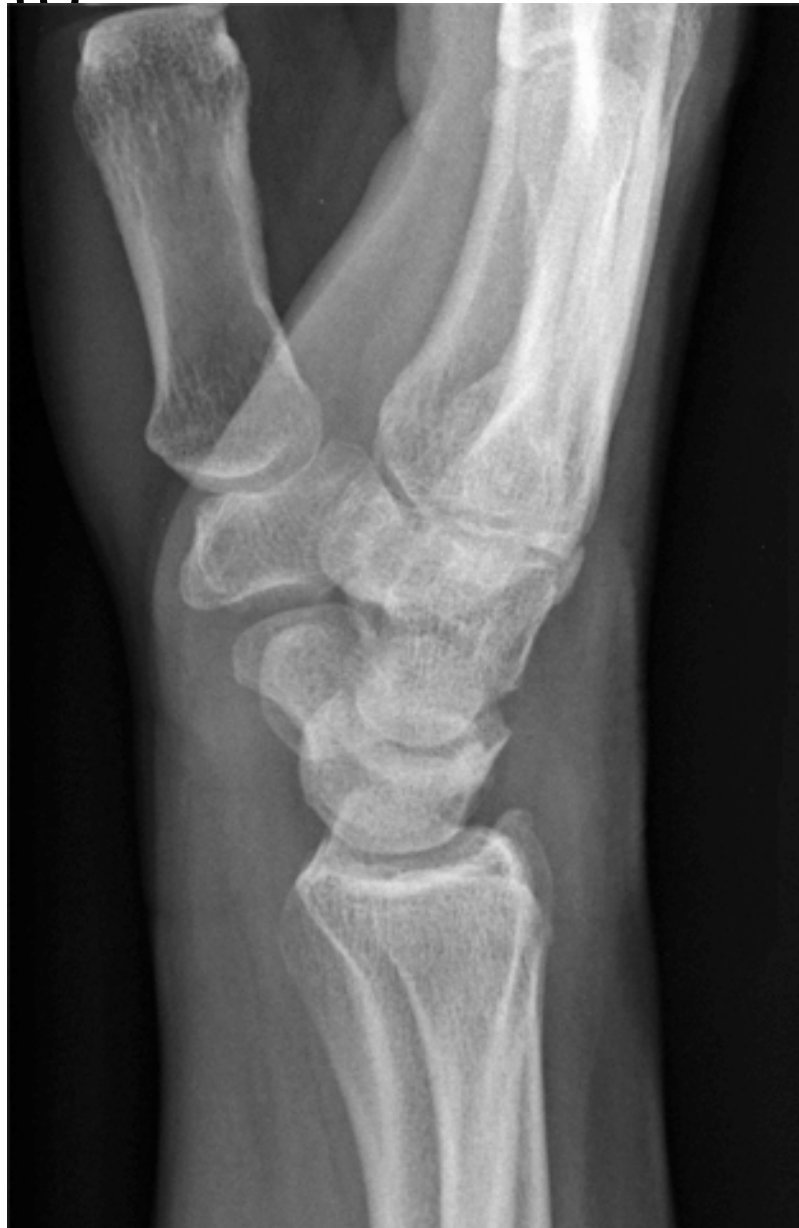Joints: There is no evidence of dislocation. The joint spaces are well-maintained.

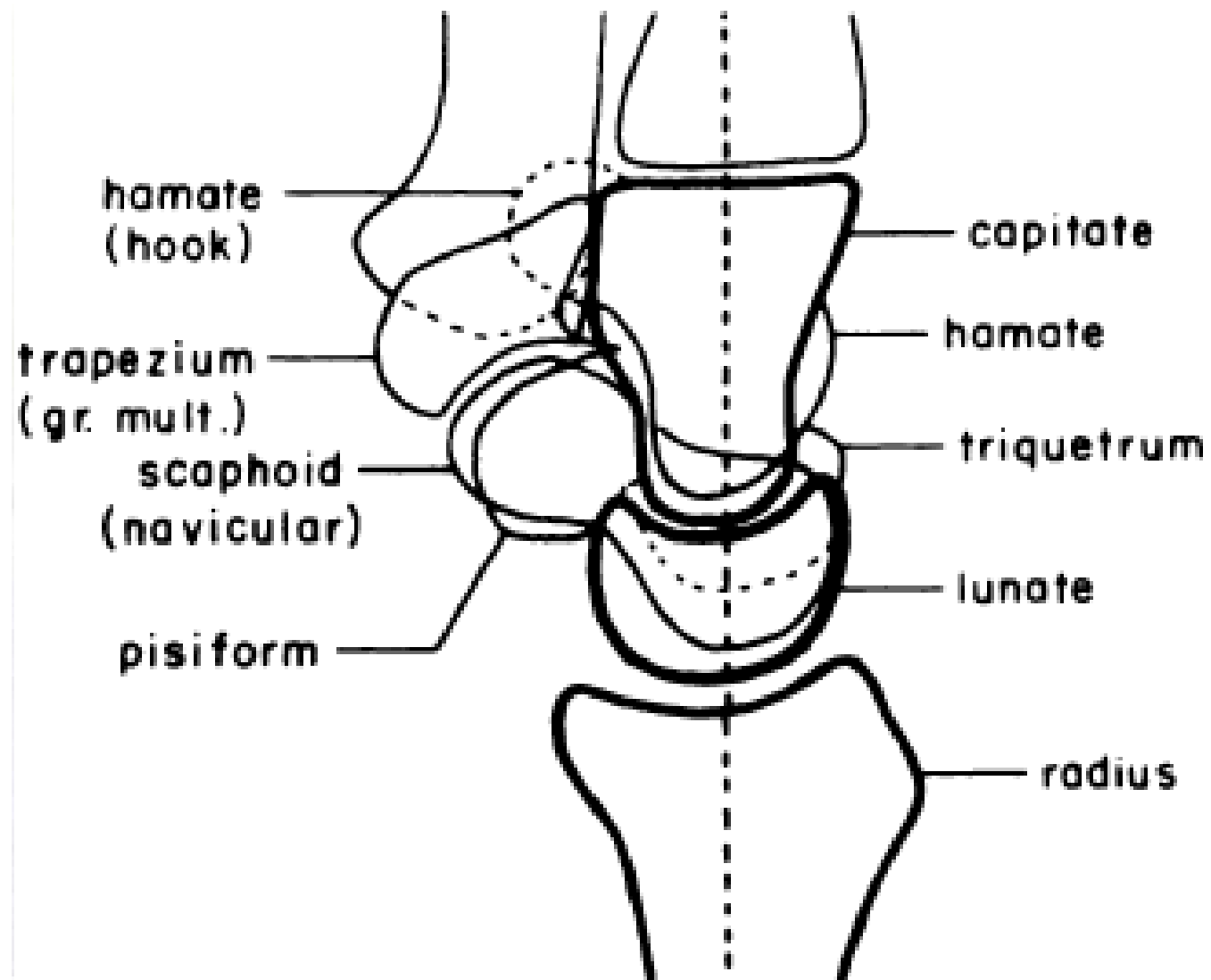
Soft tissues: Mild soft tissue swelling of the fifth ray.



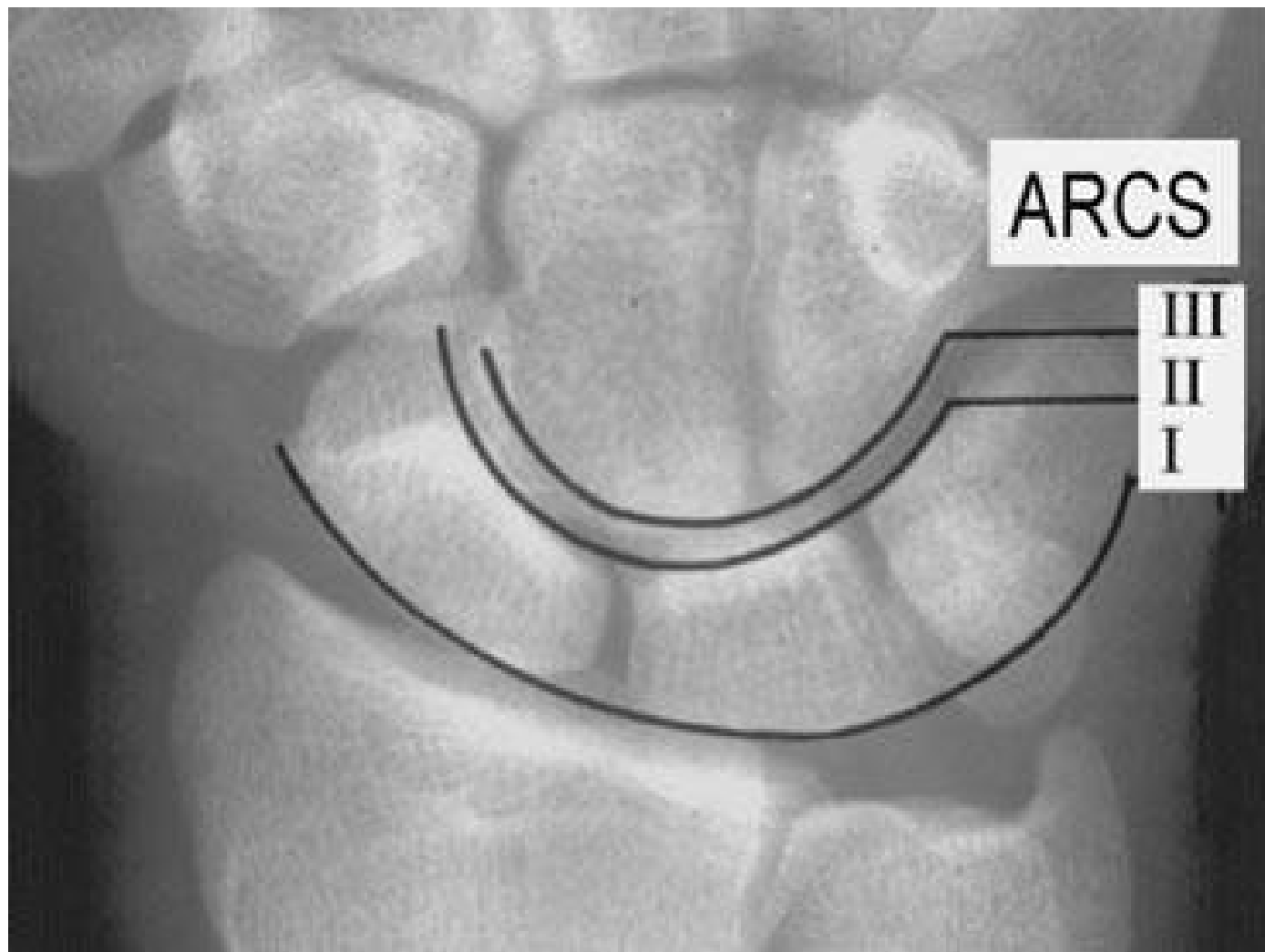


Imaging



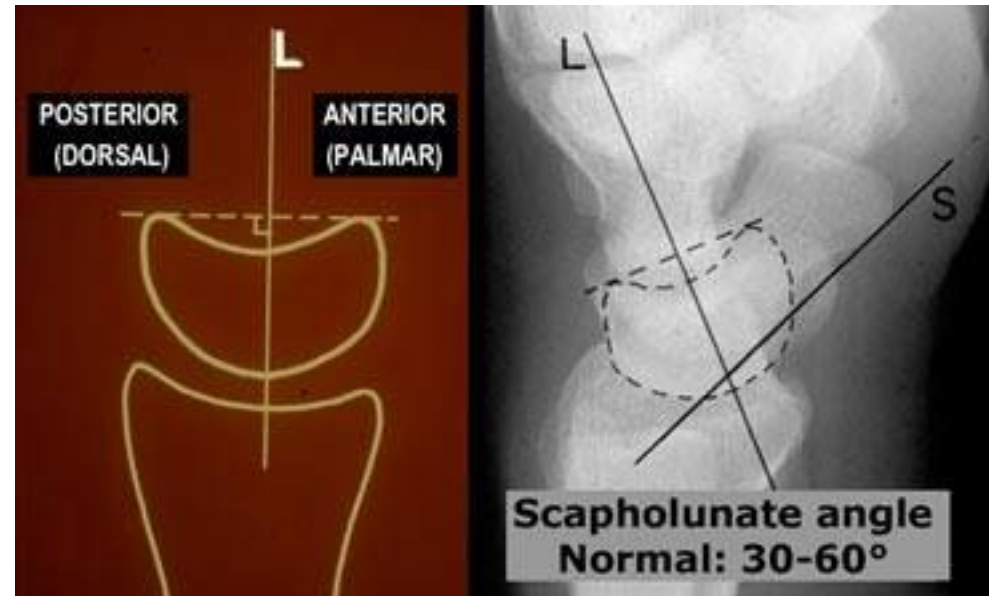
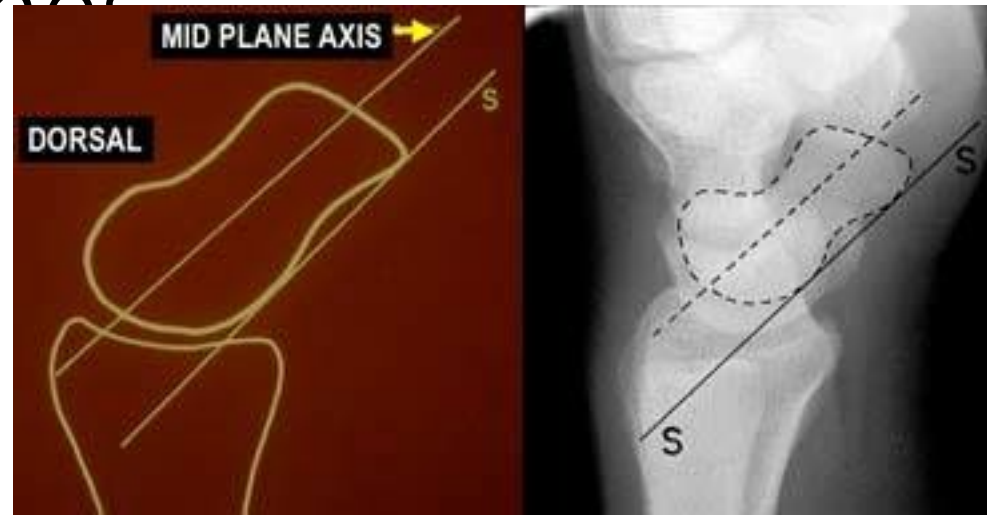


Carpal Arcs

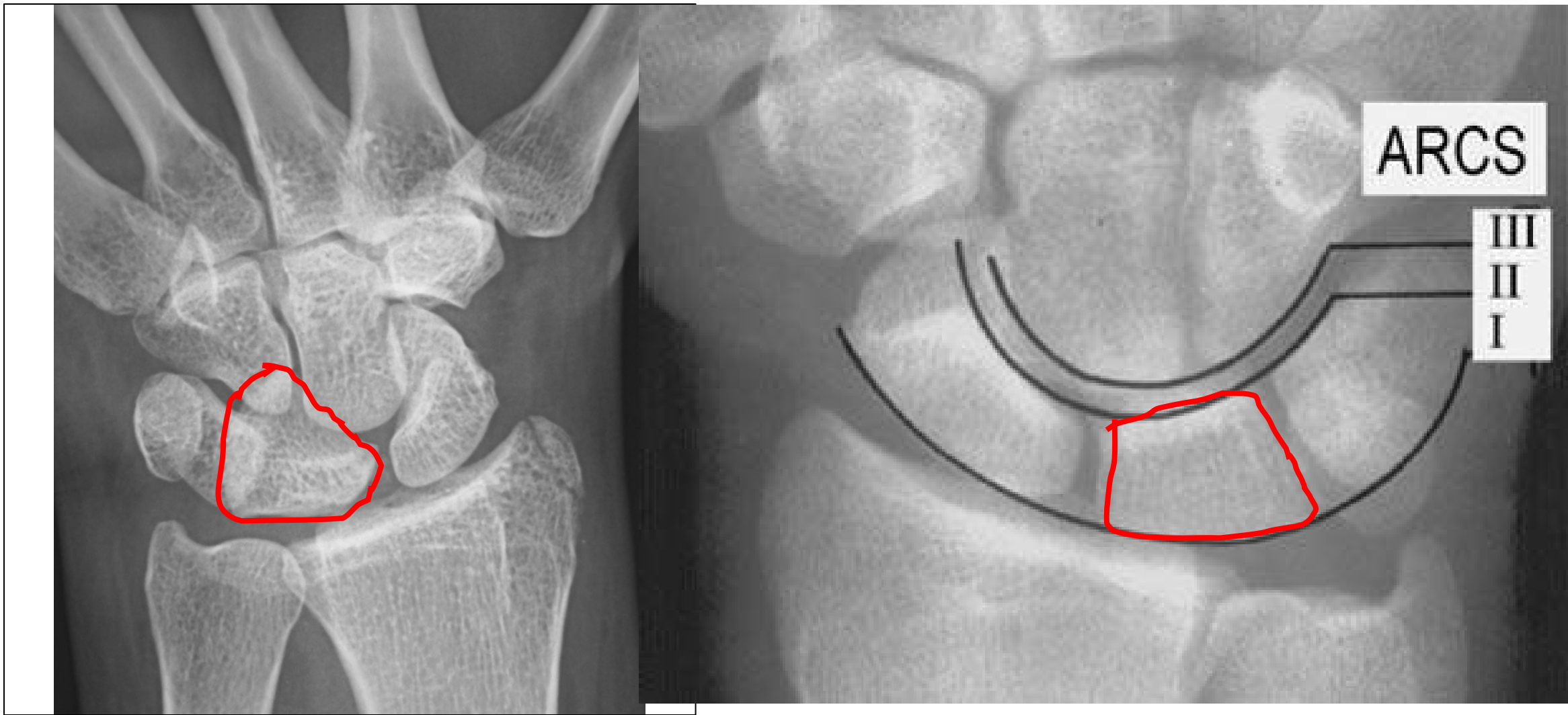


Axis of the carpal bones

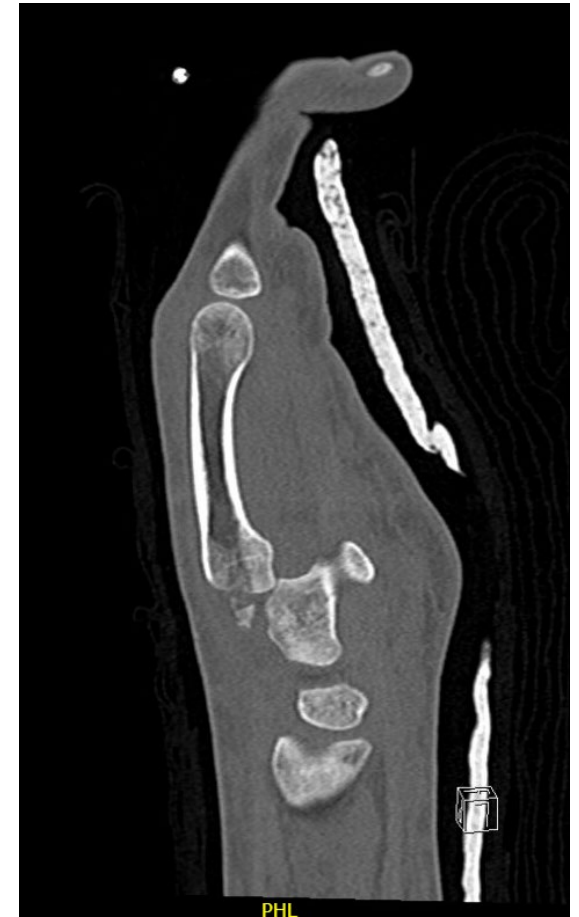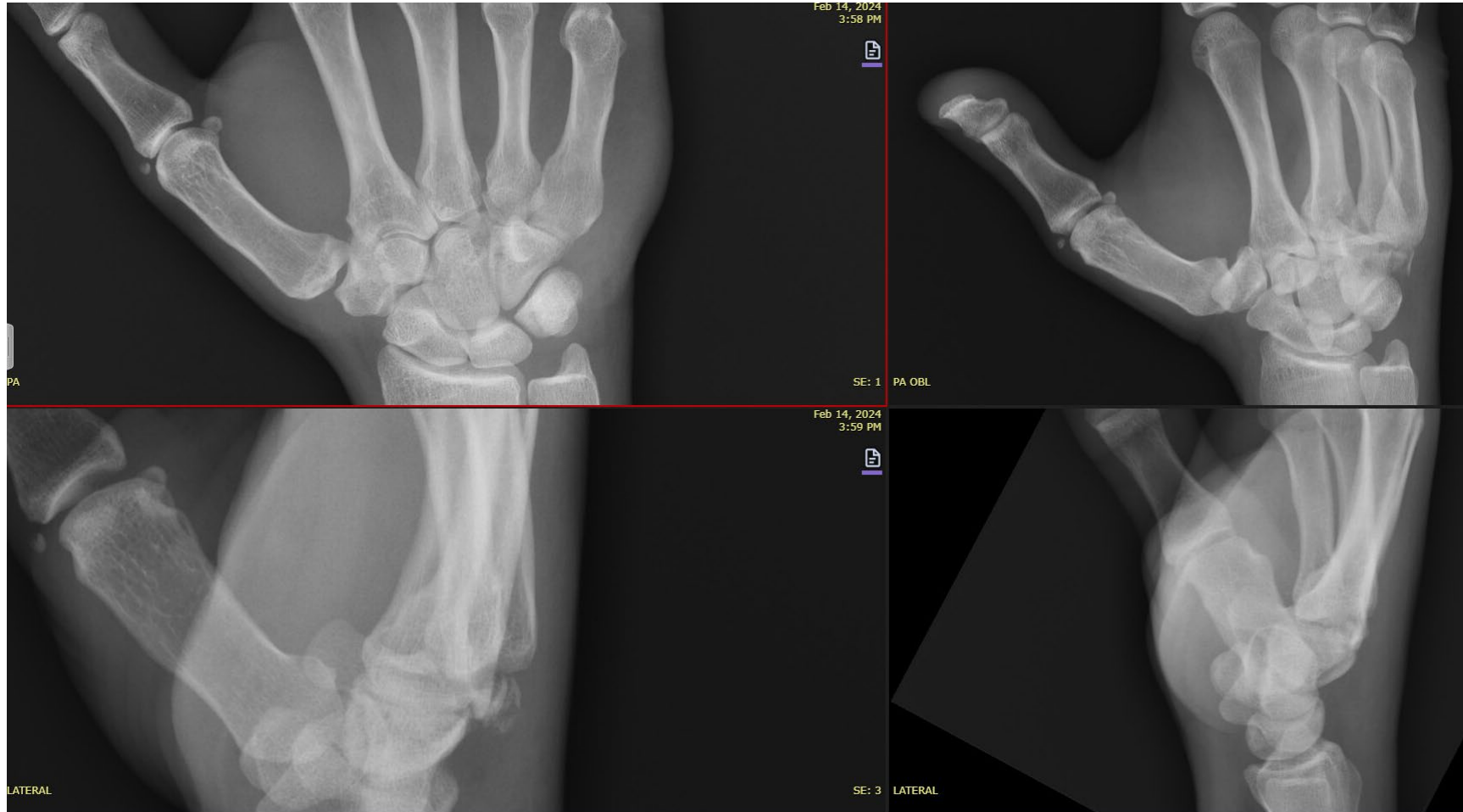- Scaphoid
- Lunate
- Scapholunate

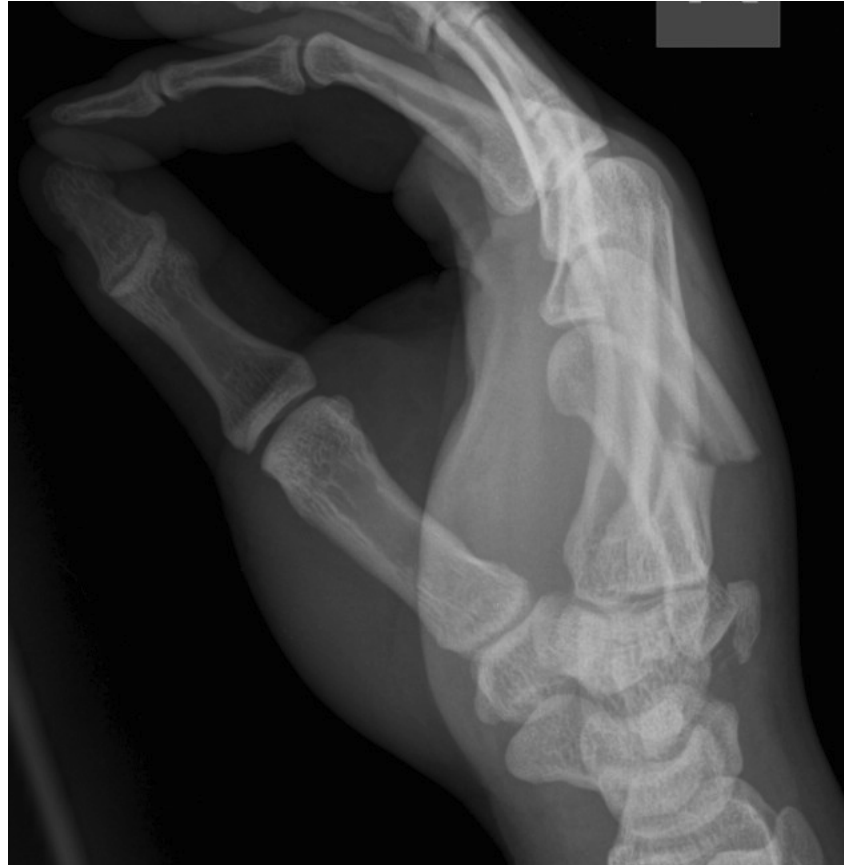
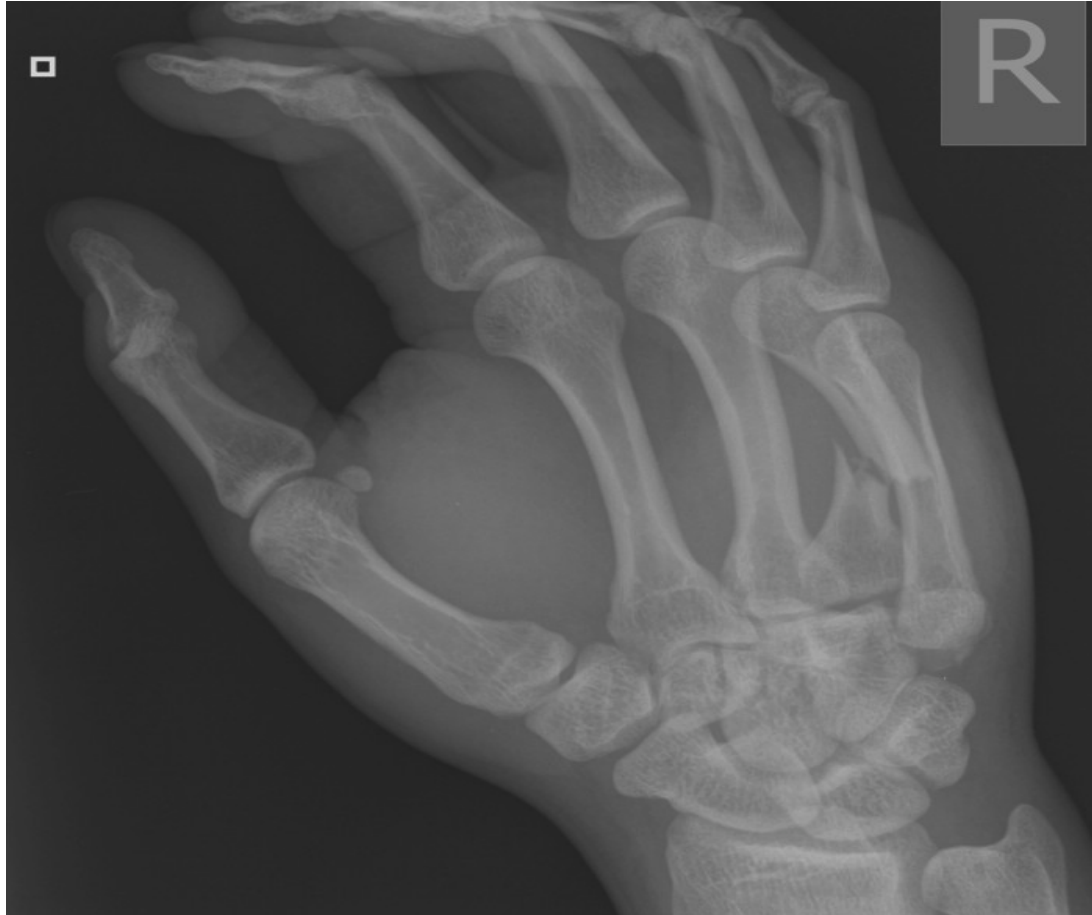
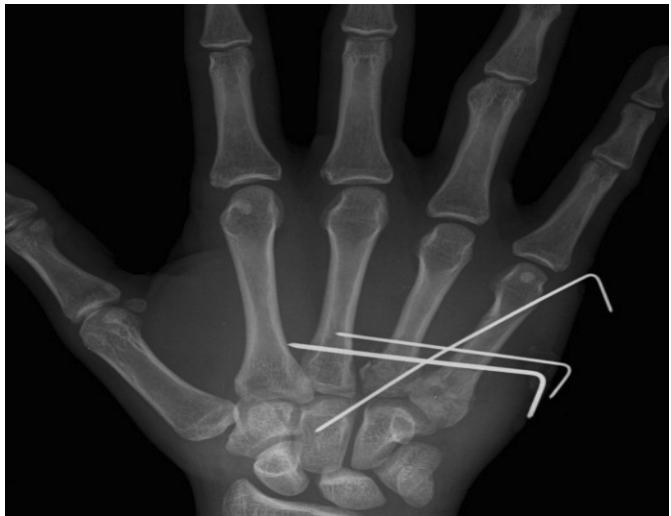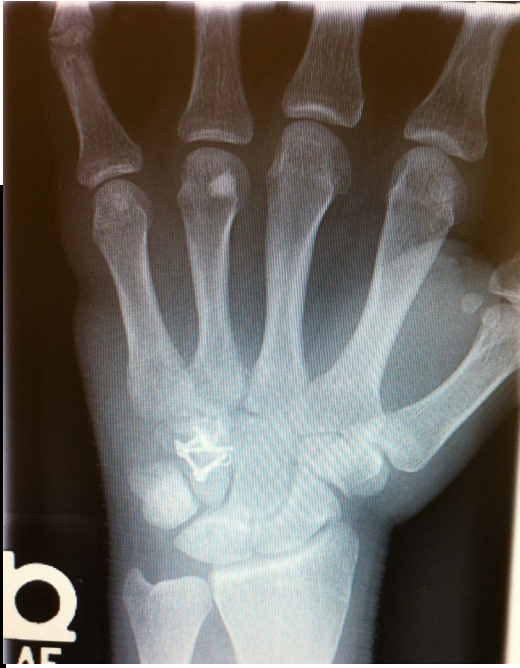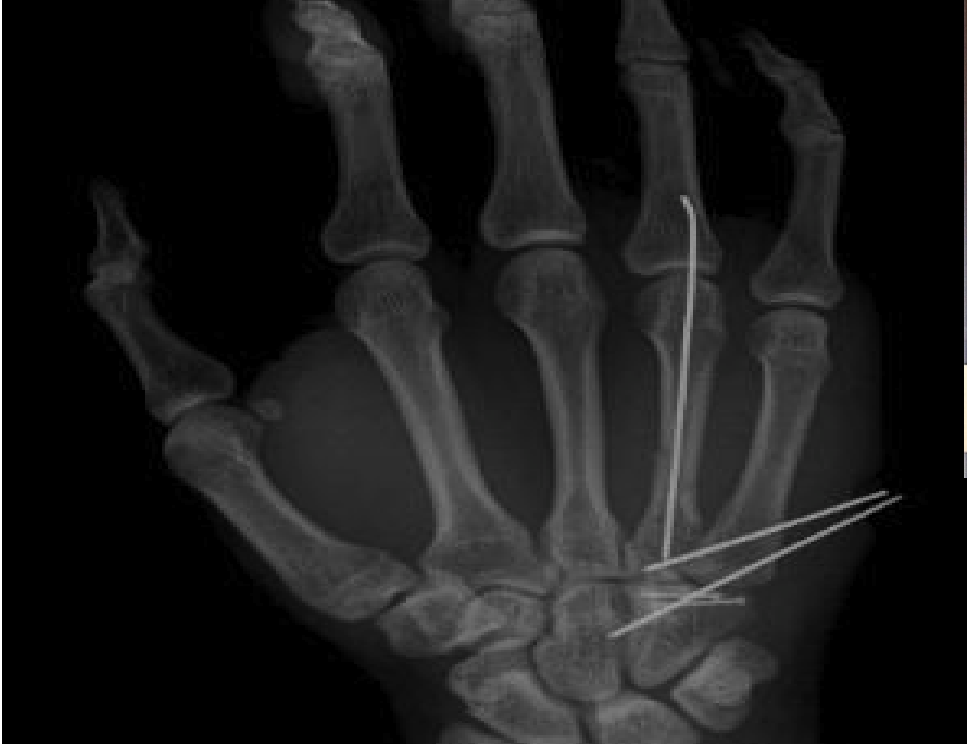Shape of the Lunate



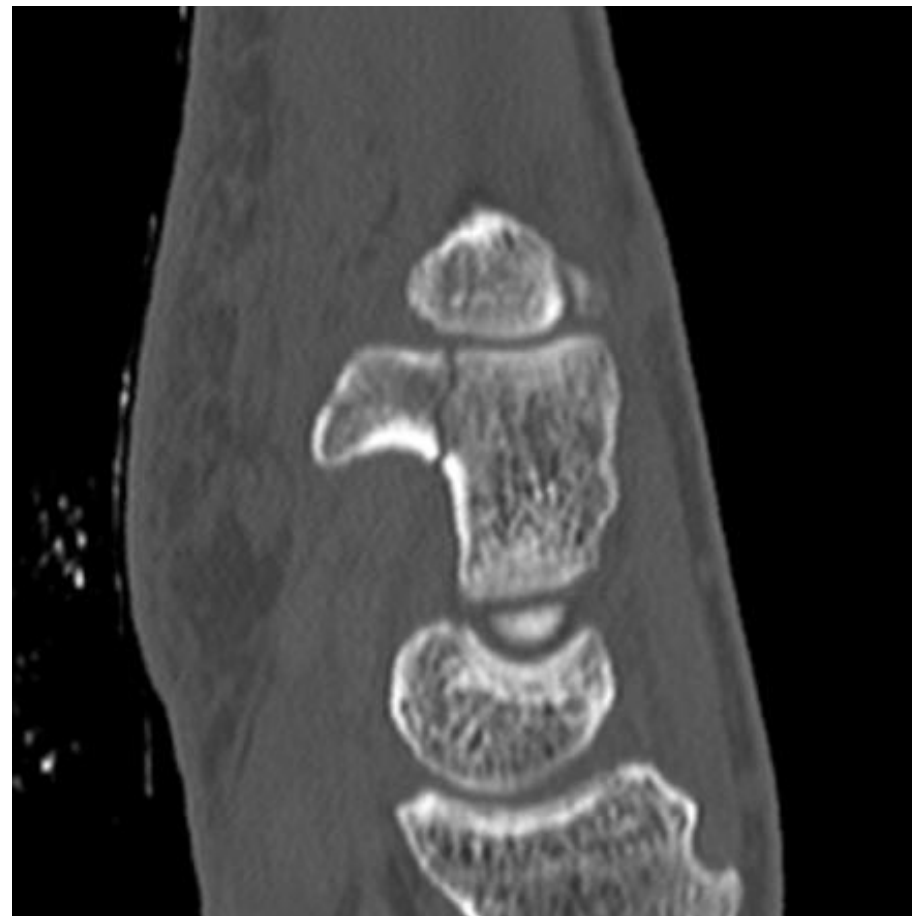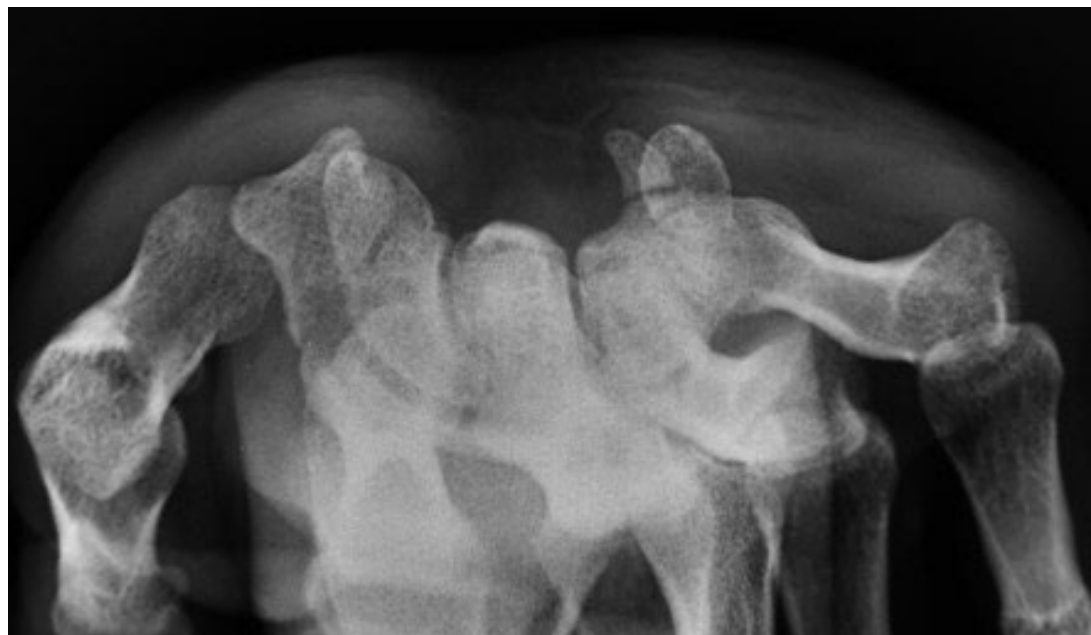CMC Fracture-dislocations



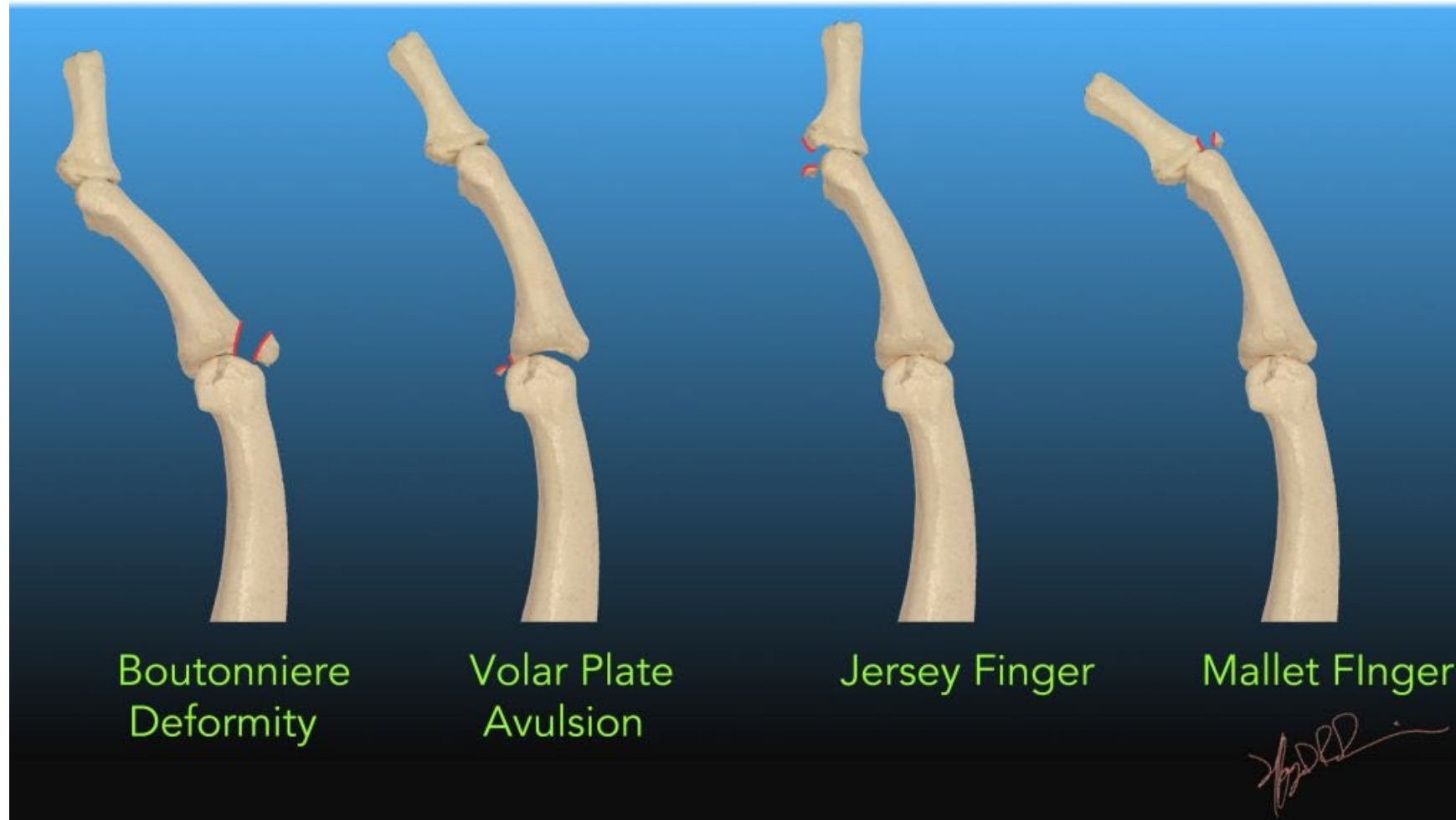




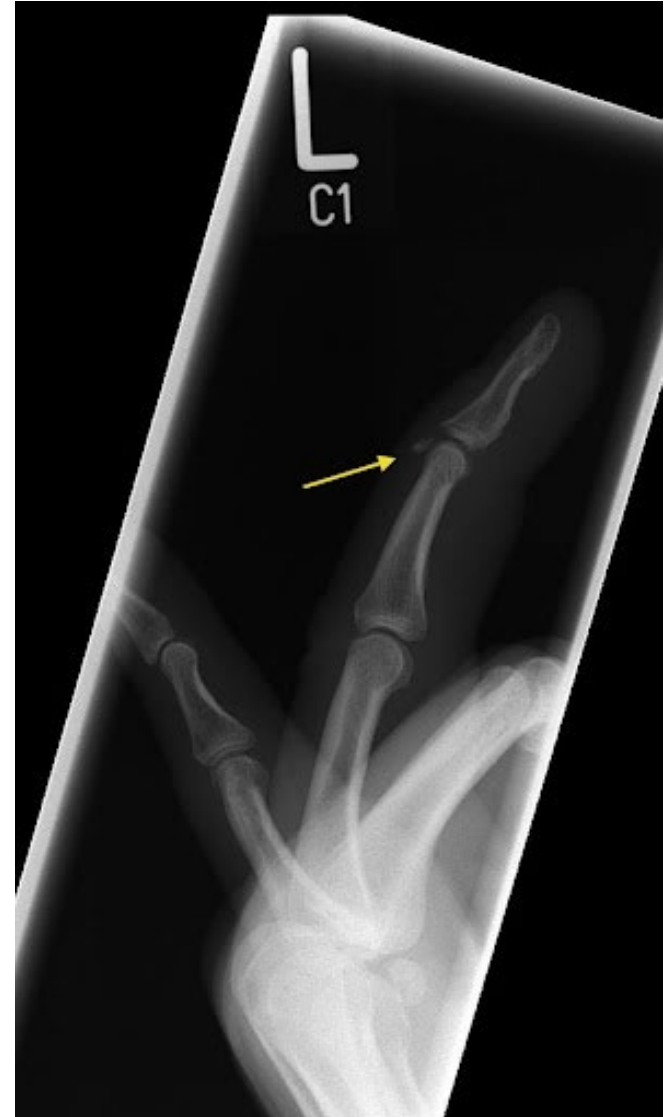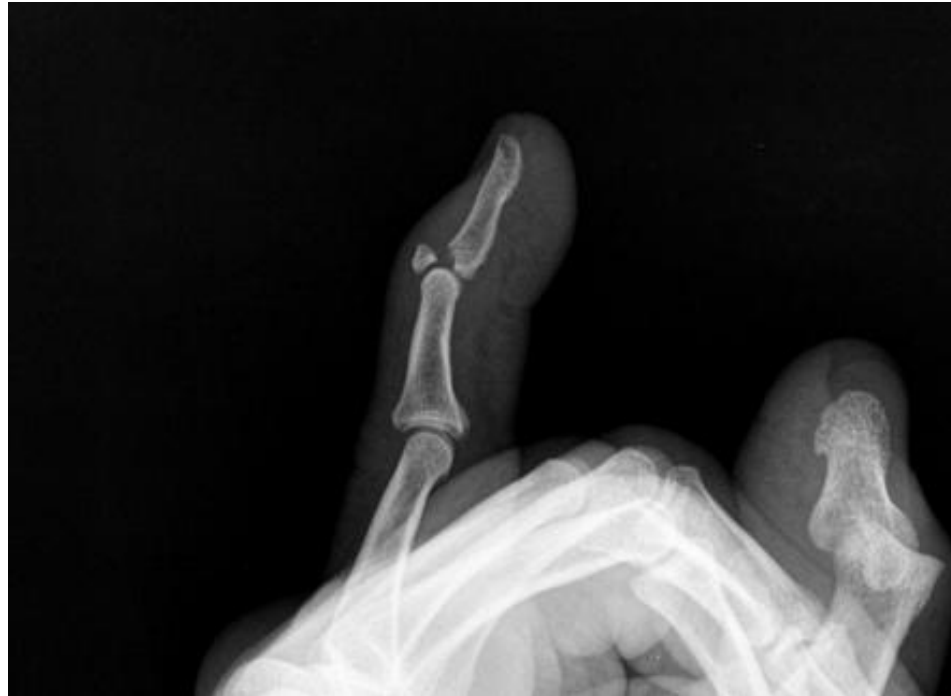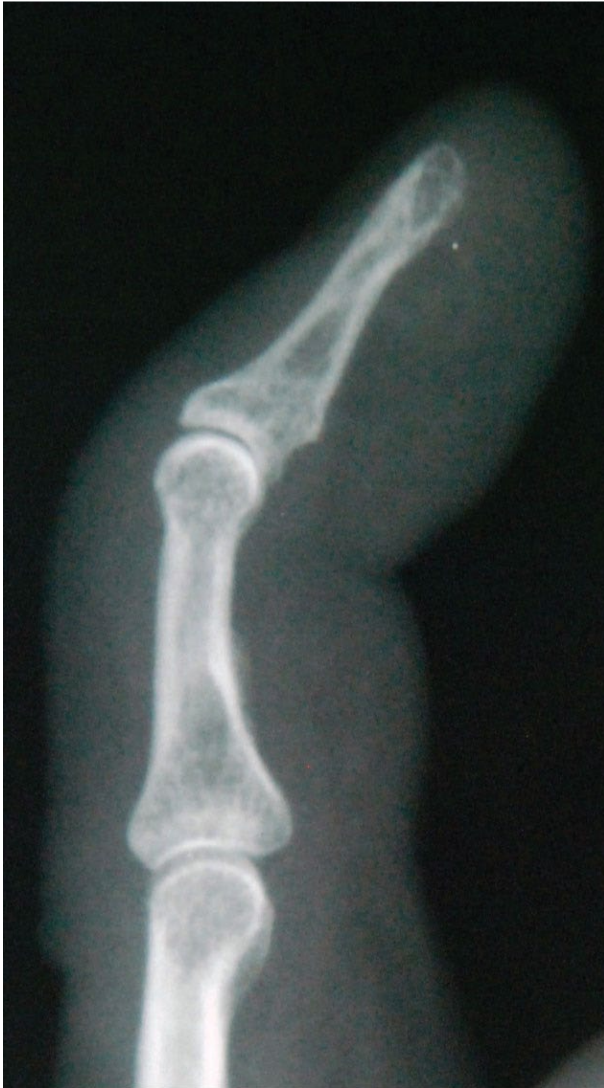Hook of Hamate Fractures



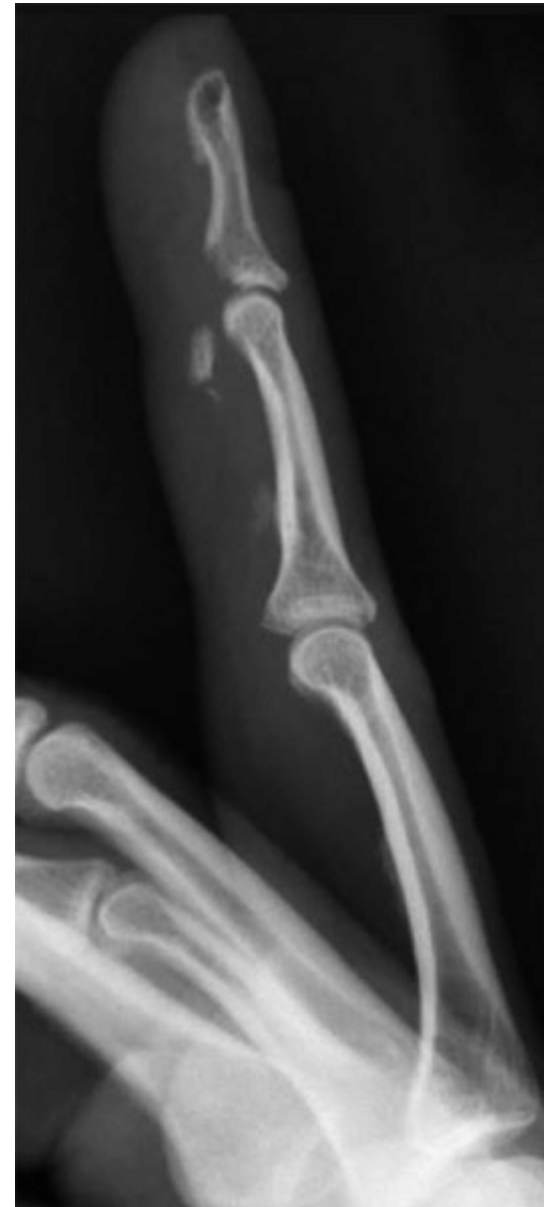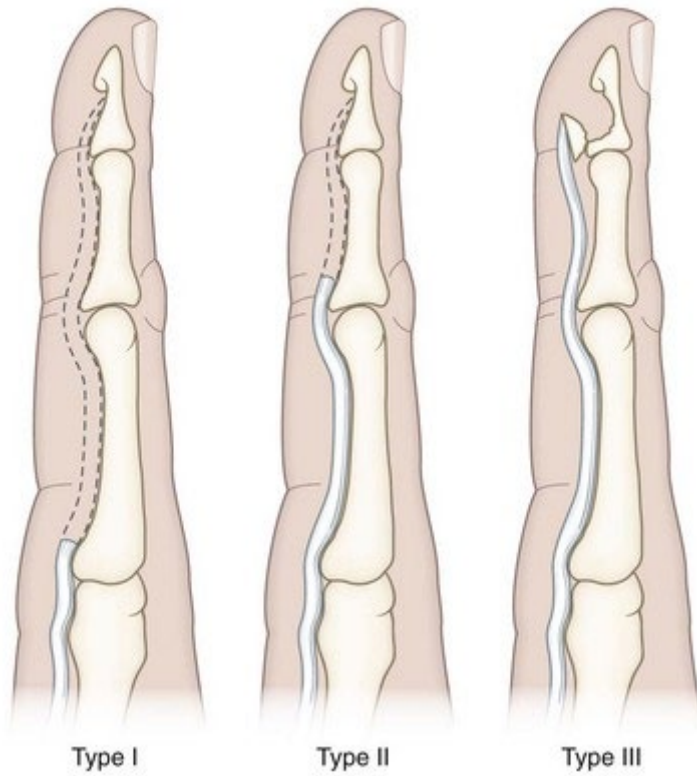
“Finger Sprains”



Mallet Finger

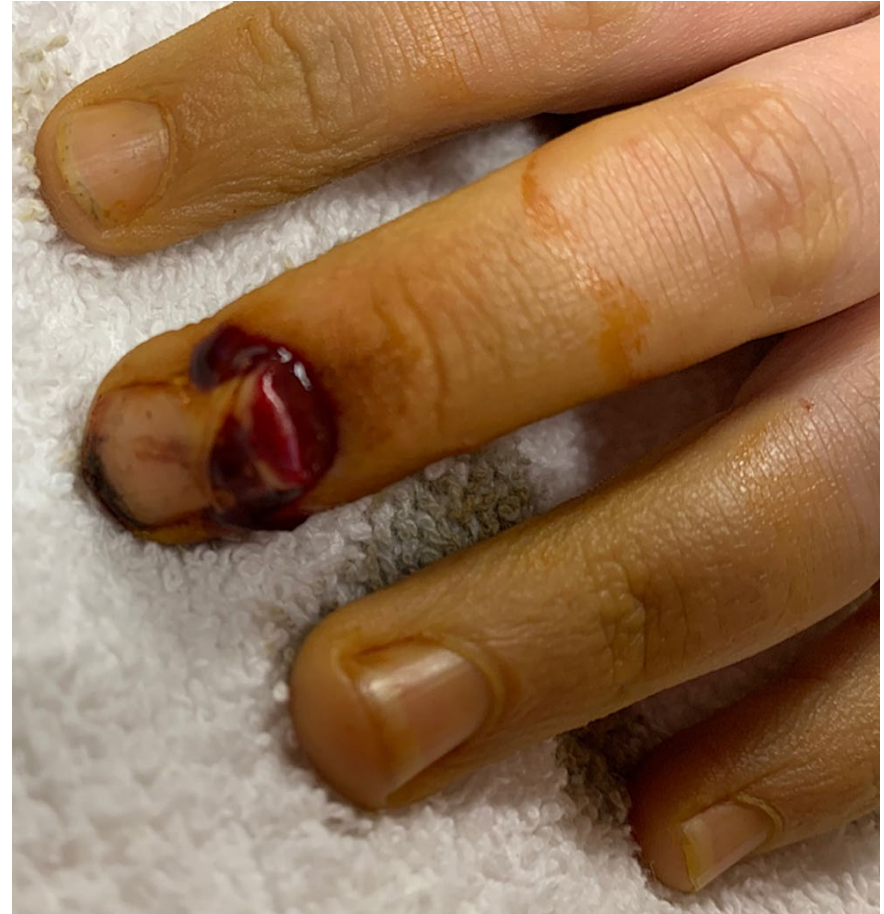
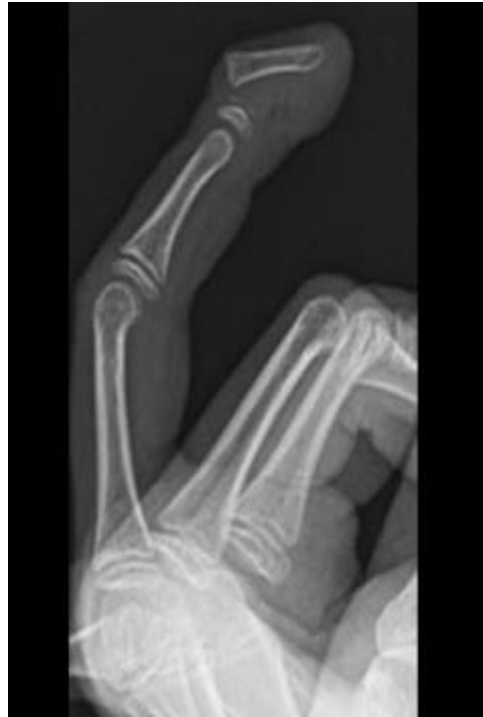
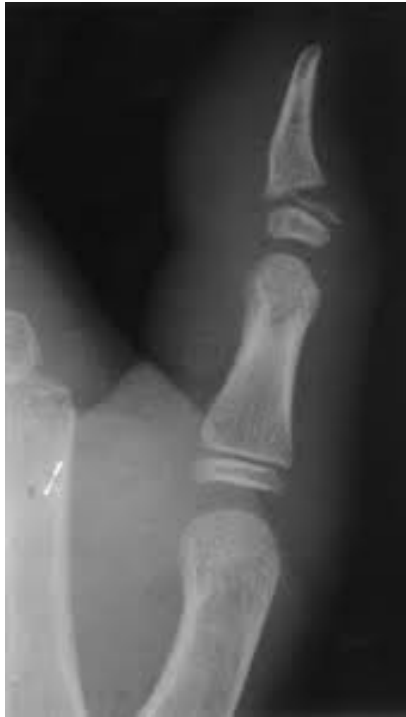
Jersey Finger

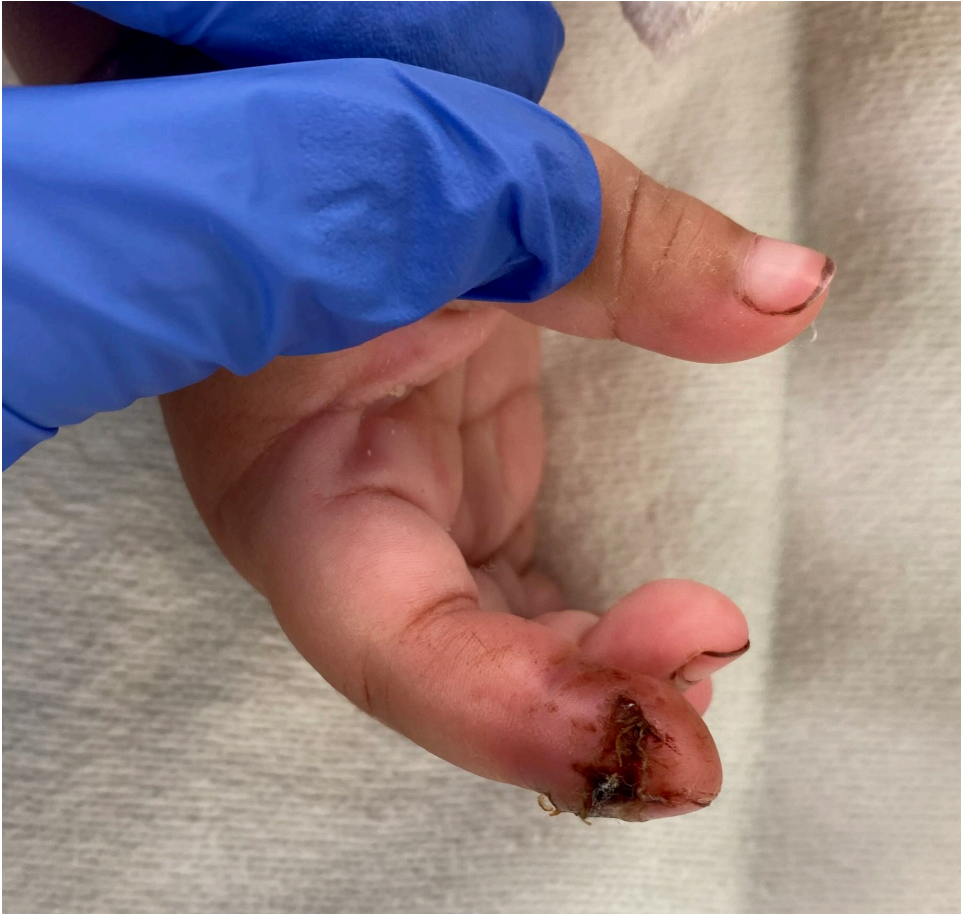
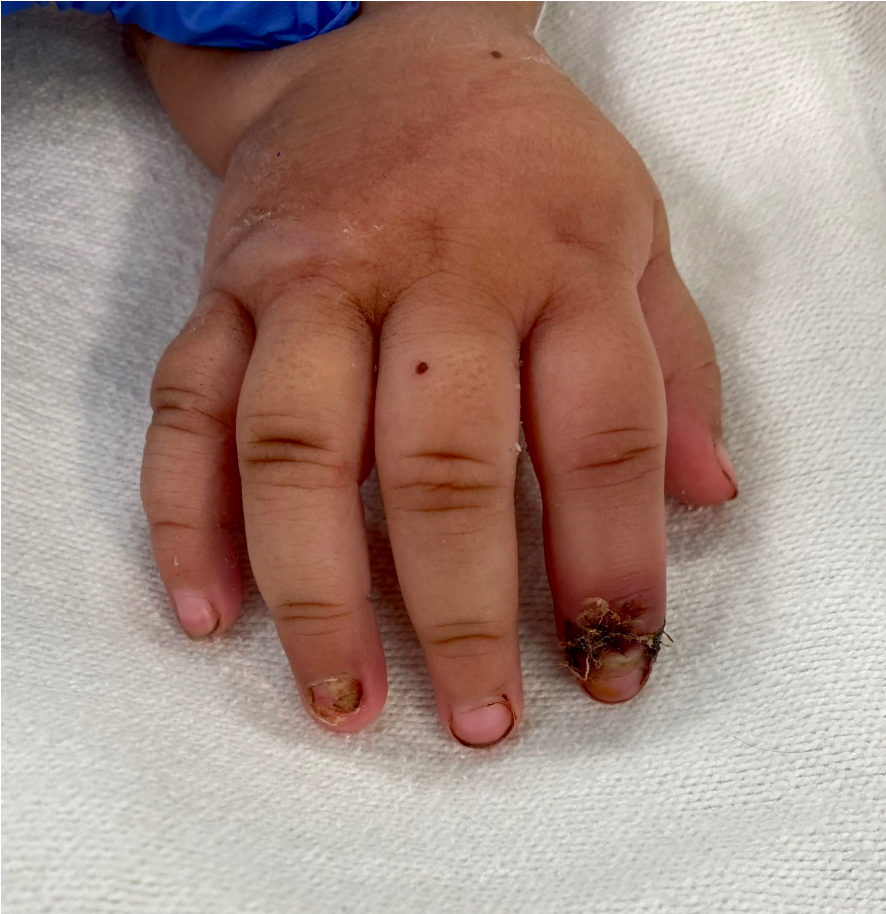
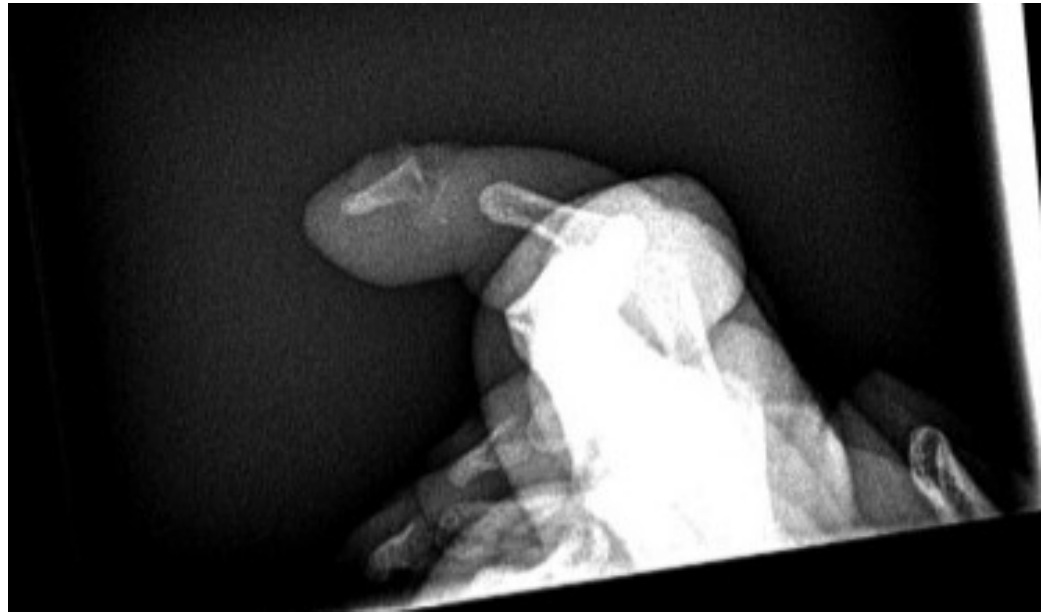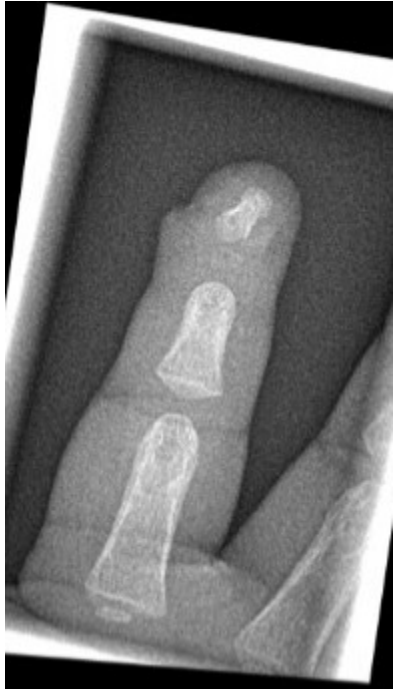Pediatric Fractures

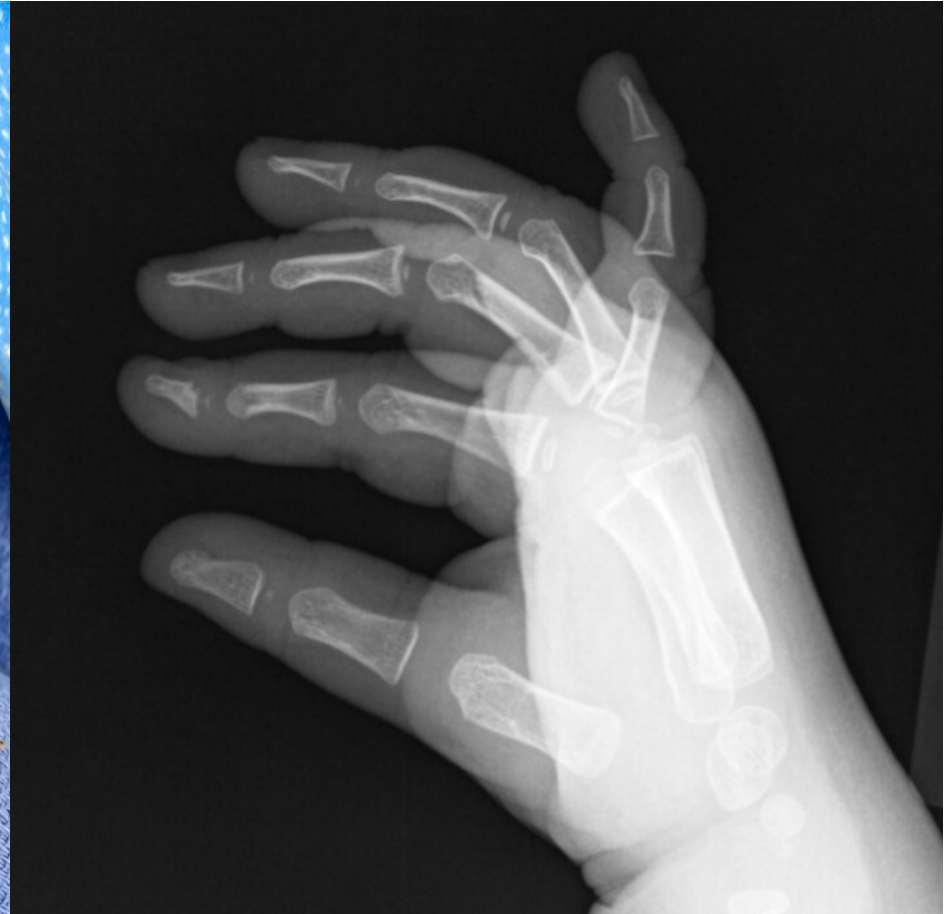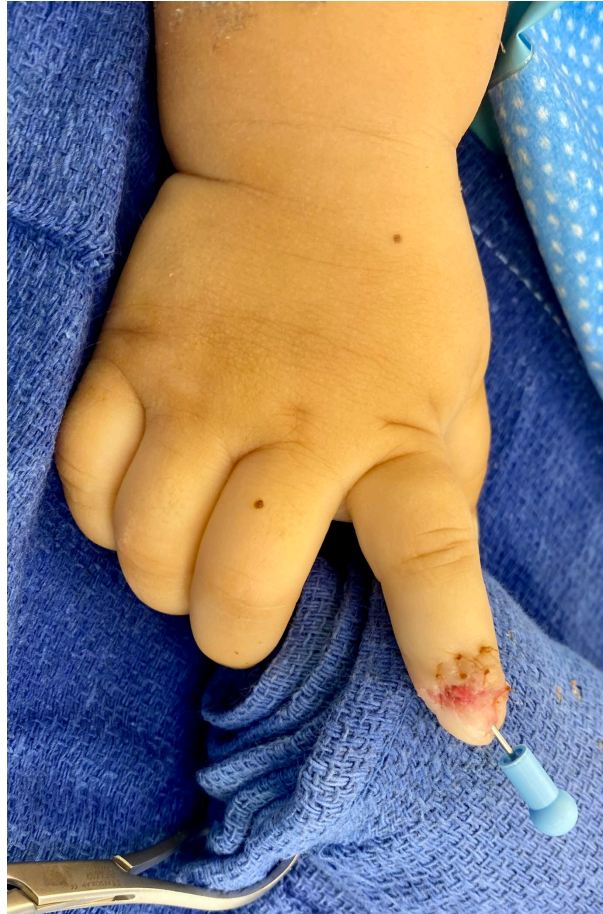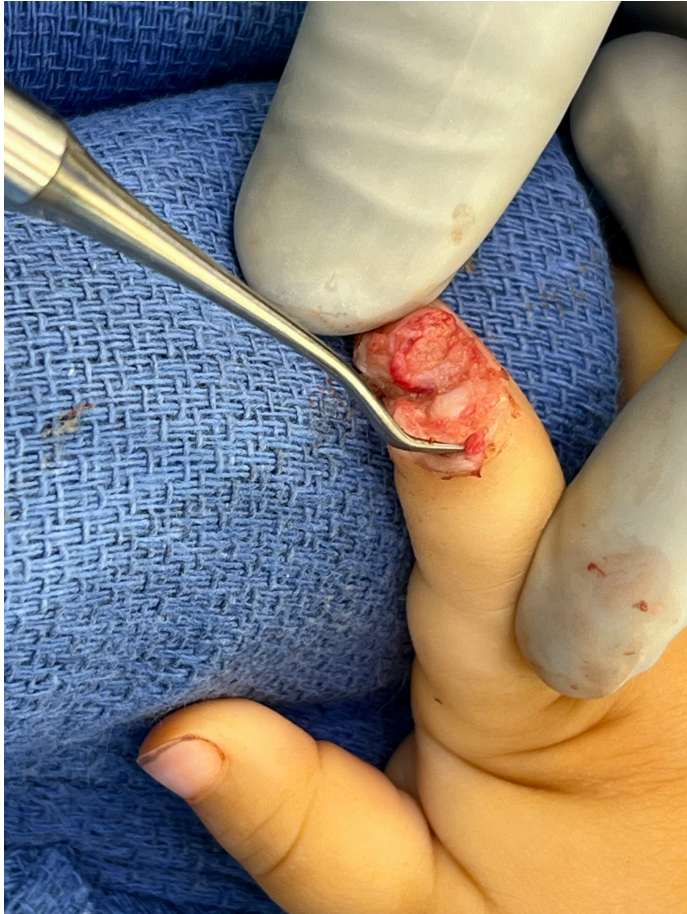- Seymour Fracture



Seymour Fracture







Thank You

- Michael.Terry@ucsf.edu