

# (Complex) Distal Humerus Fractures

**Edward J Harvey MD MSc**

Professor | **McGill University**

Head of Surgery and Interventional Sciences Program | **MUHC-RI**



McGill

# Disclosures

- × Co-Editor in Chief | Canadian Journal of Surgery, OTA Patient Portal
- × Editorial Board | OTA International, J Ortho Trauma
- × Partnerships | Google

## Corporate Ownership

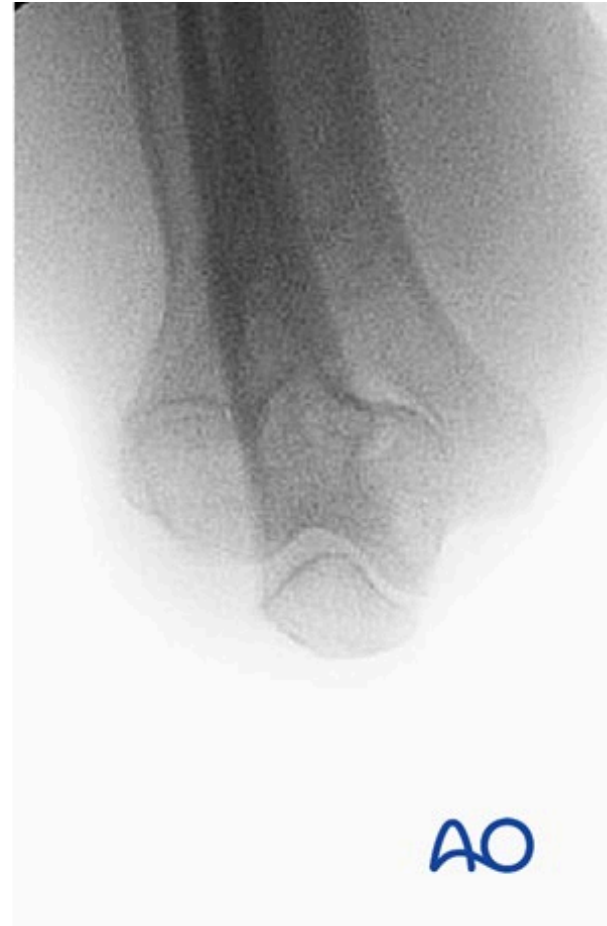

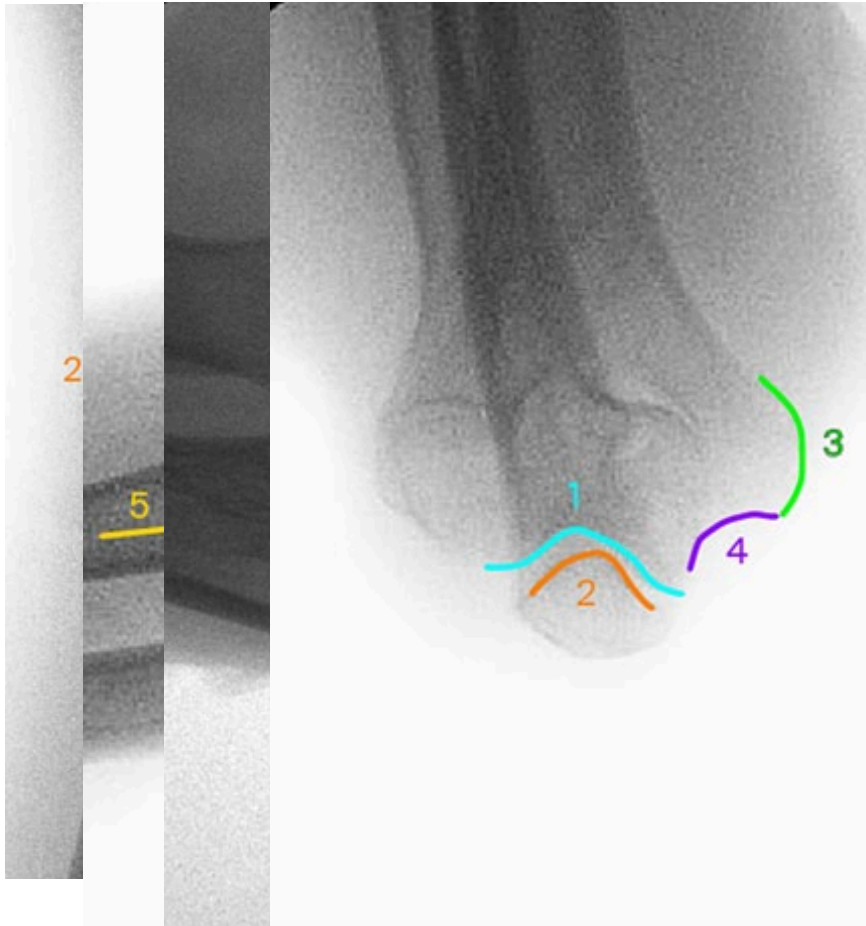
- × NXTSens Inc. | Co-Founder CSO
  - × MY01 Inc. | Co-Founder CSO
  - × Cananose Inc. | Co-Founder CMO
  - × ChemSense Tech Inc. | Co-Founder CRO
  - × Stathera Inc. | Co-Founder
- 
- × Board/Committee Member | Orthopedic Trauma Association
- 
- × Current Funding | US DOD, CIHR, DND, NSERC, NRFR

Two things make these challenging

× **Biology**

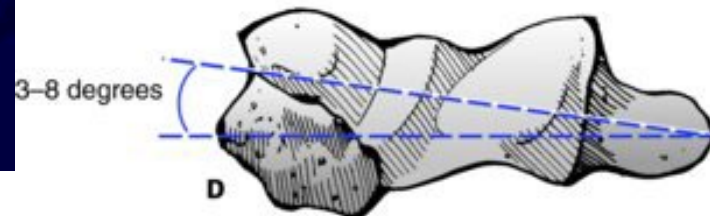
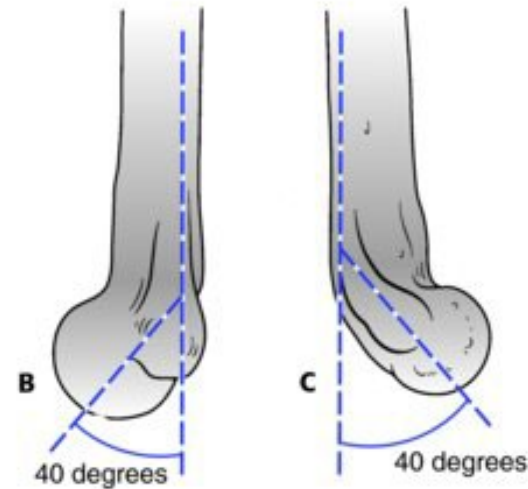
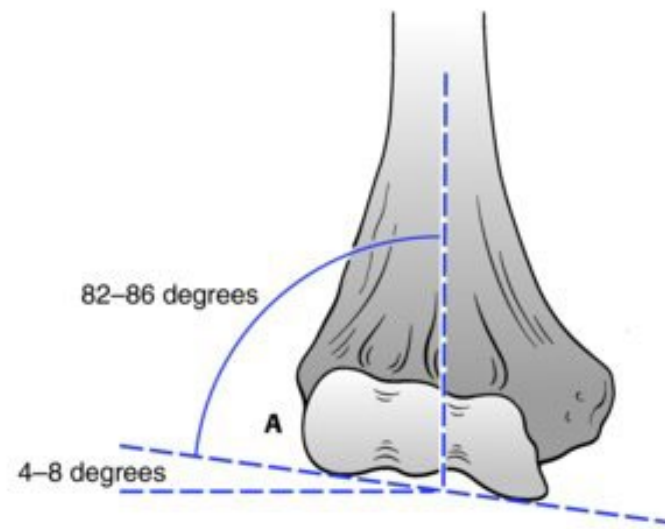
× **Anatomy**

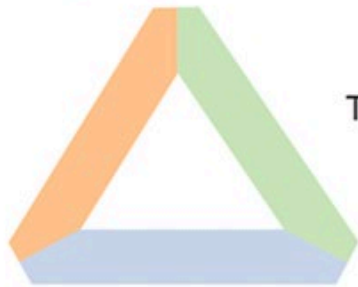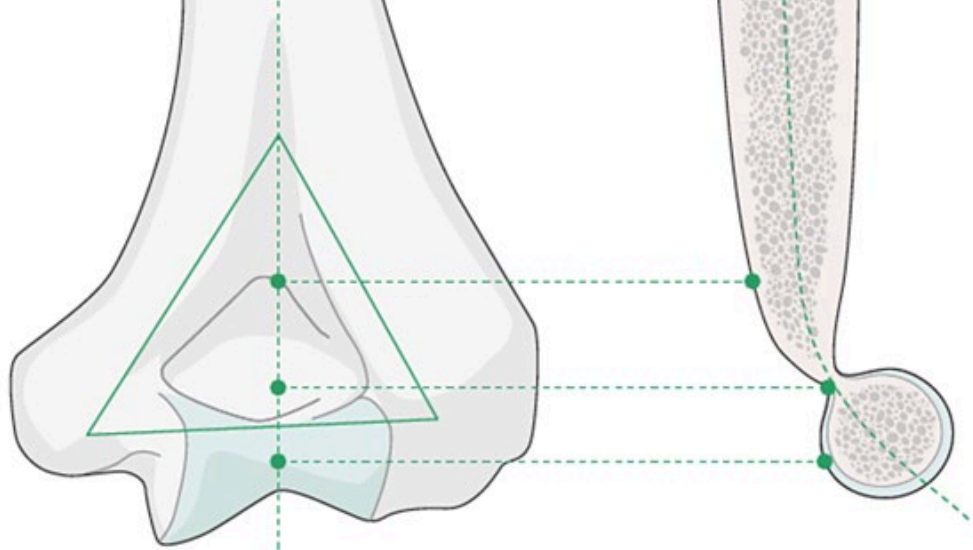
# All about anatomy – and getting to see it



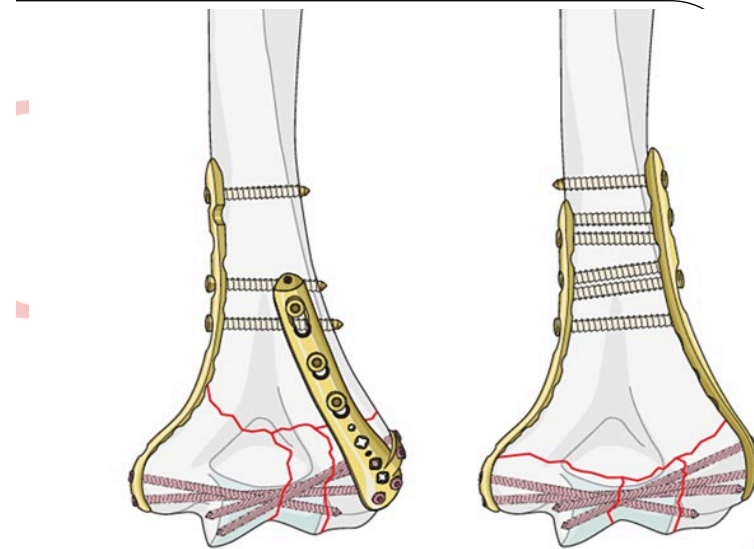
# Anatomy

- Hinged joint with single axis of rotation (trochlear axis)
  - At bottom of virtual distal humeral triangle
- Trochlea is center point of A with a lateral and medial column
- Trochlear axis compared to longitudinal axis is 4-8 degrees in valgus



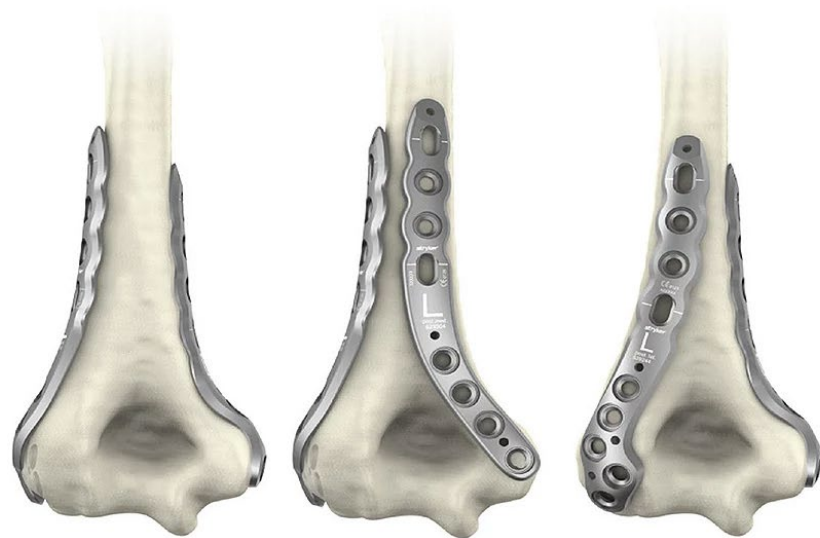


Triangle-of-stability concept



**surgical fixation of a distal humerus fracture**

**means anatomic articular reduction and rigid fixation**



180°

90°

90°



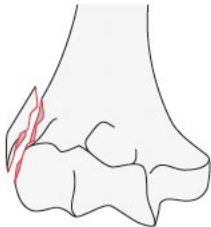
Distal Humerus Fx

Extra-articular

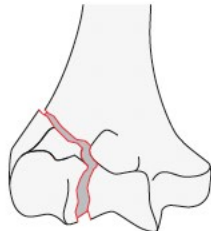
Simple

Complex

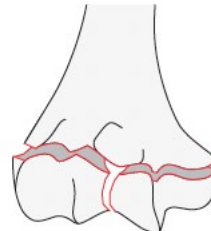
Humerus, distal end segment,  
extraarticular fracture  
13A





Humerus, distal end segment,  
partial articular fracture  
13B



Humerus, distal end segment,  
complete articular fracture  
13C



M



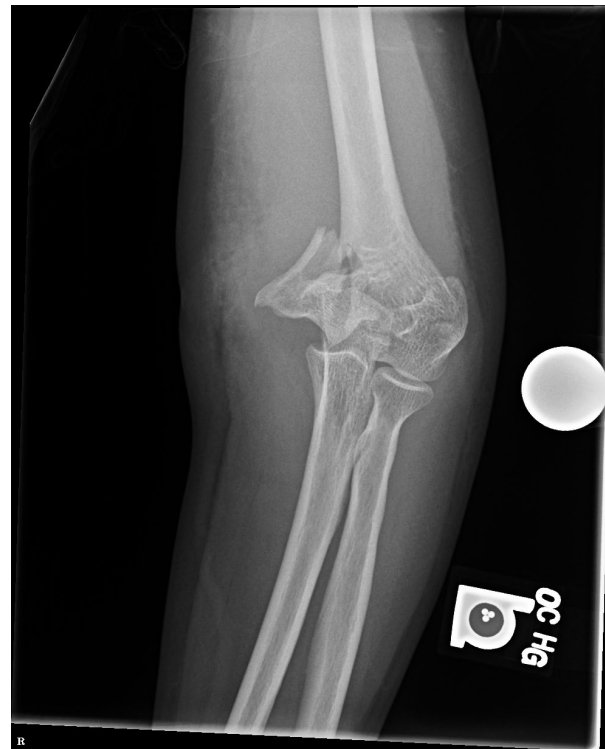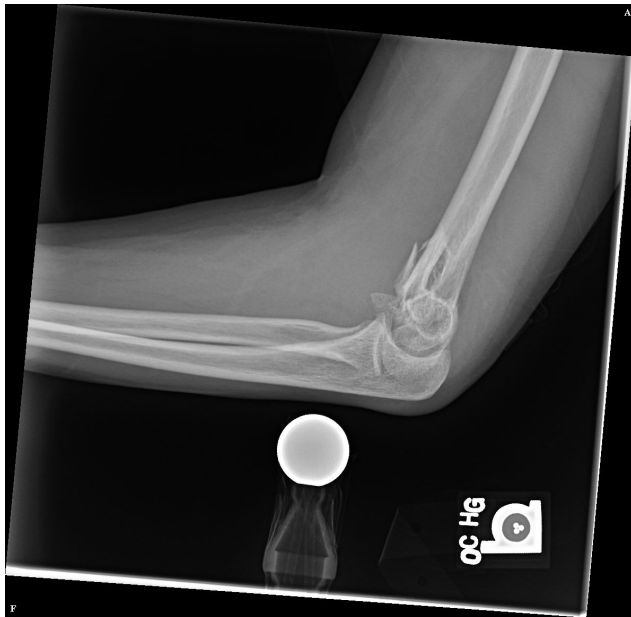
Distal Humerus Fx

These type of fractures

Extra-articular

Simple

Complex





Distal Humerus Fx

Talk about these type of fractures



Complex


All pieces easily reducible

Some bone missing

Some cartilage missing

What cartilage

Is that an elbow?





# McGill

All pieces easily reducible

Some bone missing

Some cartilage missing

What cartilage

Is that an elbow?


## Options

**Approaches**

**What to do with the pieces**

**Where to find new pieces**

**What pieces of metal to use**





# McGill

## Goals are the same

All pieces easily reducible


Some bone missing

Some cartilage missing

What cartilage

Is that an elbow?

- Implants determined by fracture pattern
- USE just as much as needed to **permit early ROM with minimal soft tissue stripping**
- “Bag of bones” technique
  - Rarely indicated if at all
  - Distal impacted fractures in elderly with early ROM



# Approaches



# McGill

All pieces easily reducible

Some bone missing

Some cartilage missing

What cartilage

Is that an elbow?

- Been 25 years since I performed a chevron osteotomy
- 50% hardware removal rate or unhappiness factor of 10
- Makes it hard to do revision TEA
- So, I NEVER do it
  - I know – never say never



# Approaches



# McGill

All pieces easily reducible

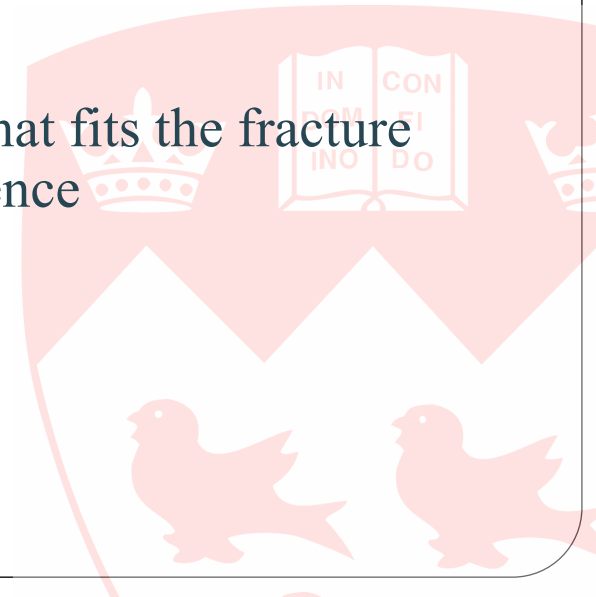Some bone missing


Some cartilage missing

What cartilage

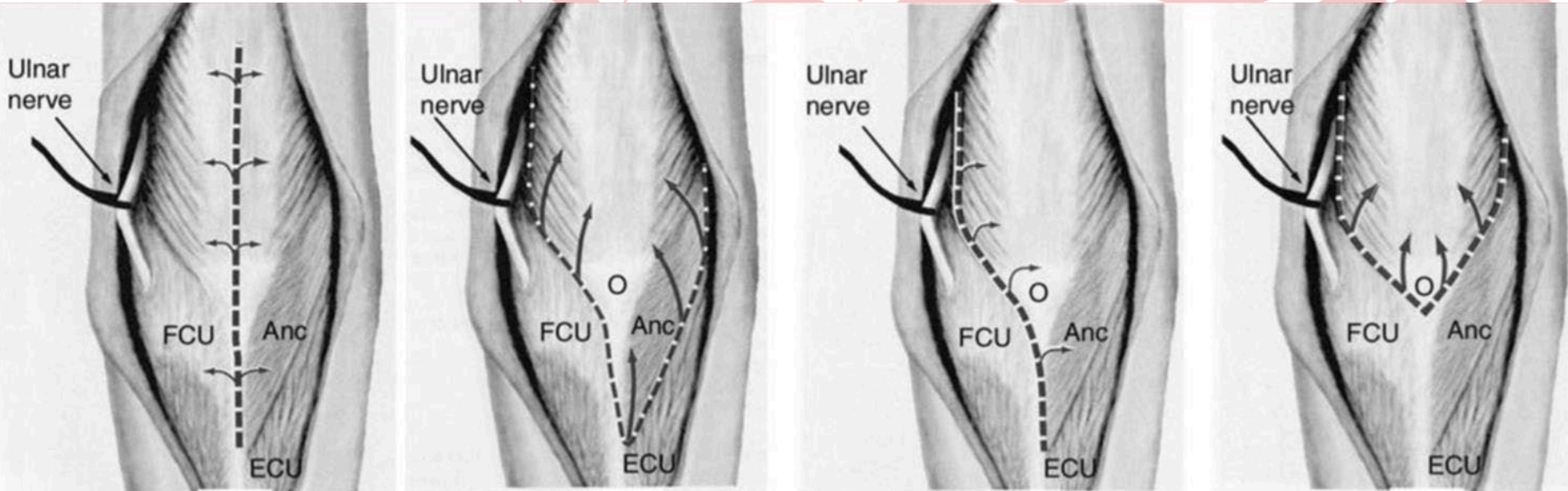
Is that an elbow?

- Reduction seems to influence outcome in articular fractures
- Exposure affects ability to achieve reduction
- Many different exposures give good to complete **visualization** of articular surface
- Choose the exposure that fits the fracture pattern or your experience

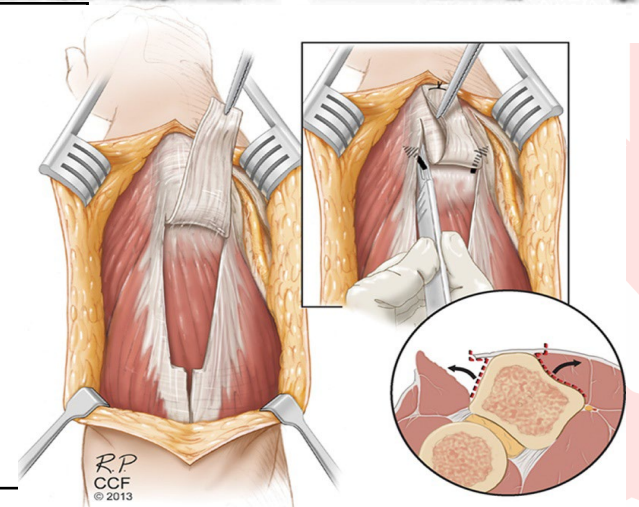




## Approaches



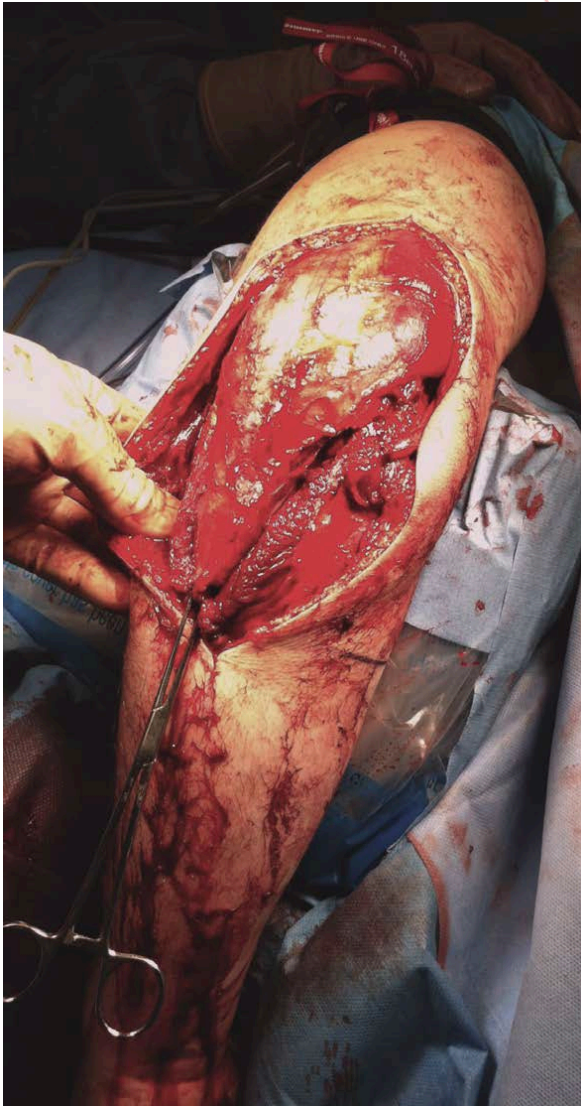
- Triceps Split**
- TRAP Flap**
- Morrey Medial Approach**
- Olecranon osteotomy**
- Para-tricepital**
- Tongues**





# Approaches

# McGill



## TRAP Flap

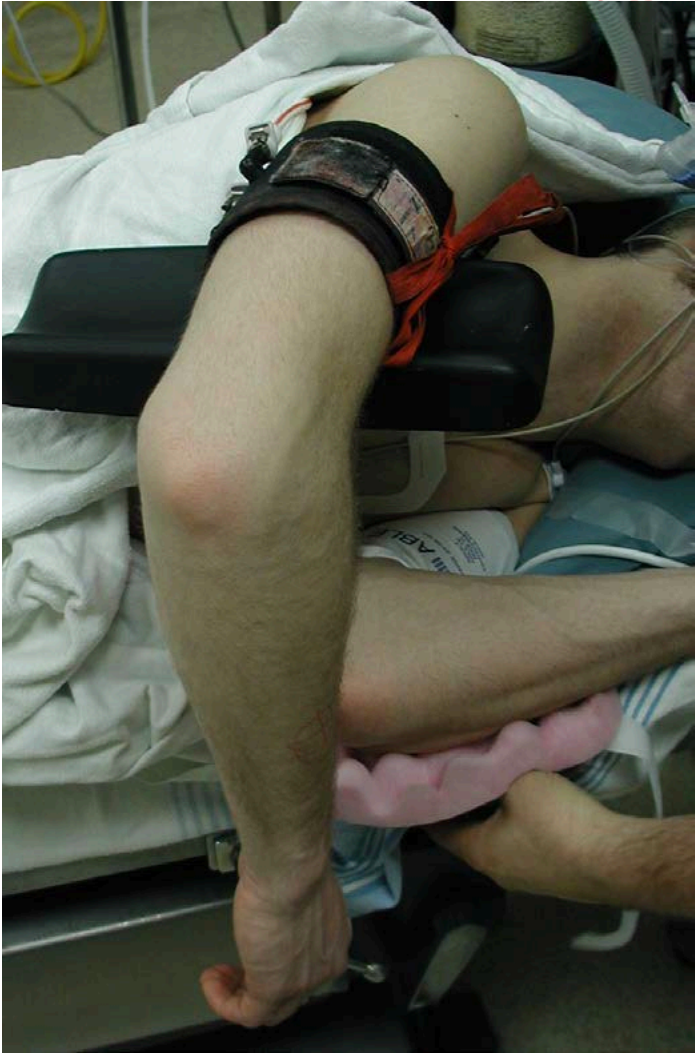- Posterior approach
- Flap lifted off ulna to about 15 cm distal to joint
- Preserve triceps to anconeus soft tissue
- Repaired through 3 ulna holes with FibreWire

# Approaches



# McGill

## Positioning



Lateral decubitus position  
Prone positioning possible  
Supine position OK? as well

- Arm hanging over a post
- I prefer a sterile bump in case convert to TEA
- Sterile tourniquet better- non-sterile in long arms maybe
- Midline posterior skin incision

# Approach



All pieces easily reducible

Some bone missing


Some cartilage missing

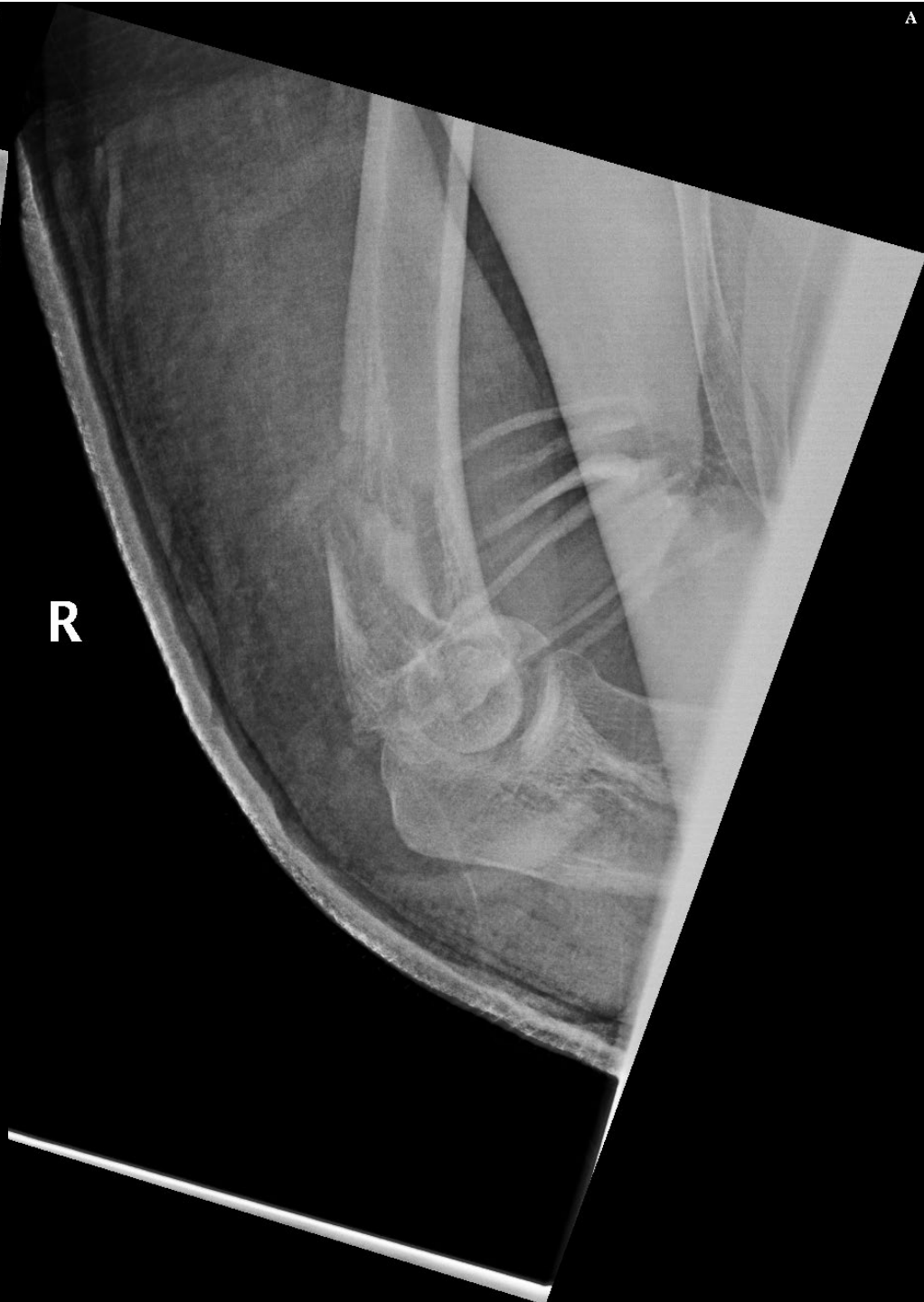
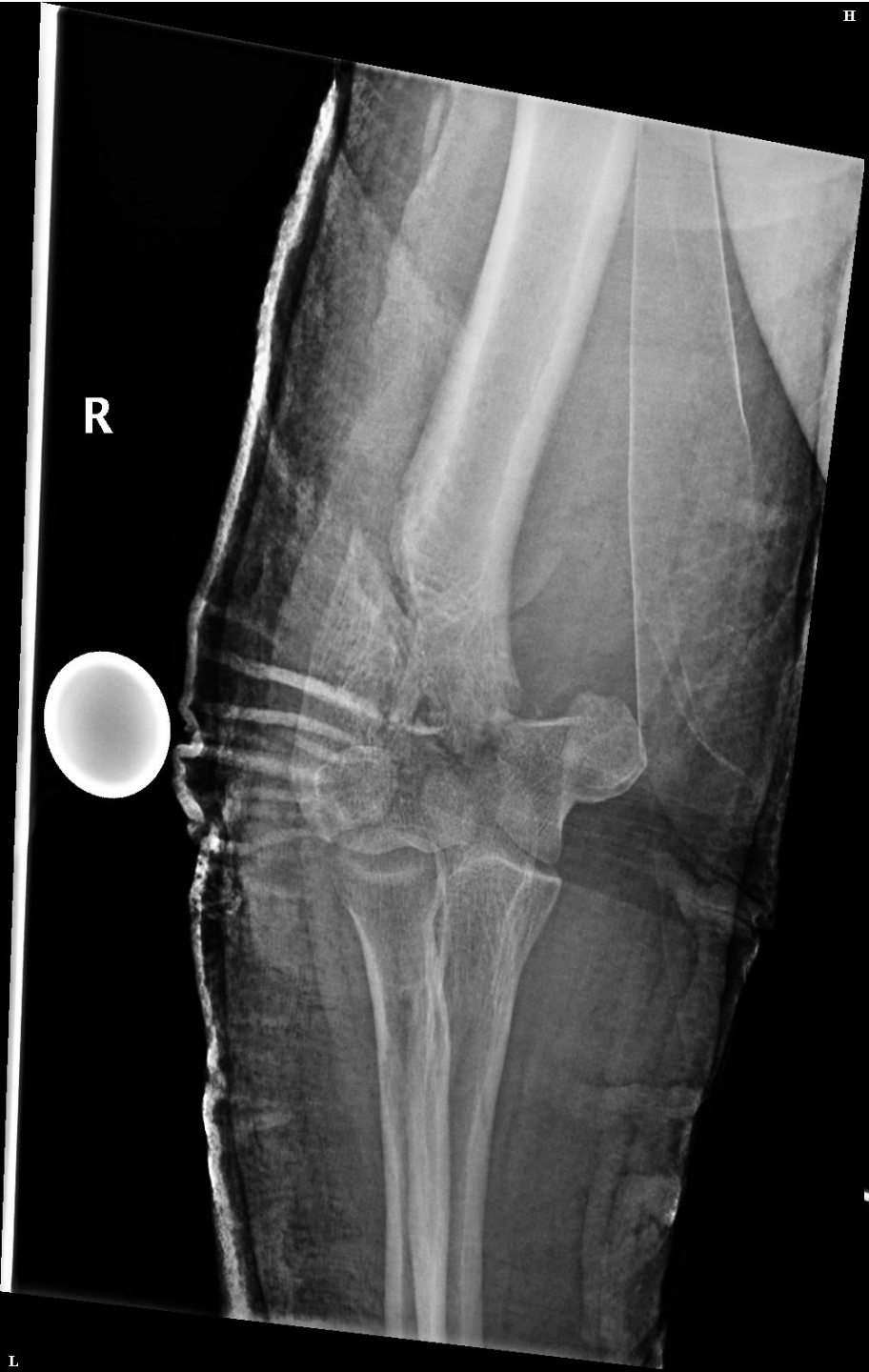What cartilage

Is that an elbow?

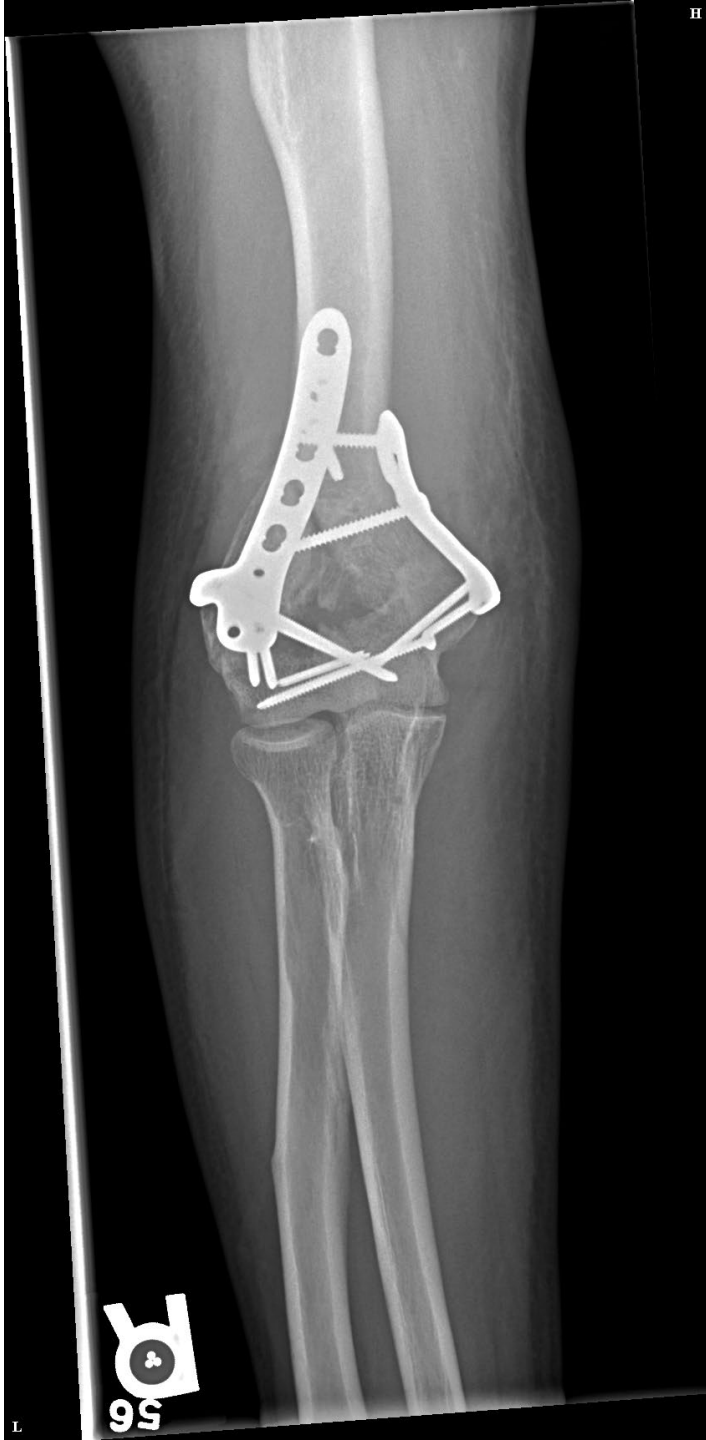# McGill

## Split Paratricepsital

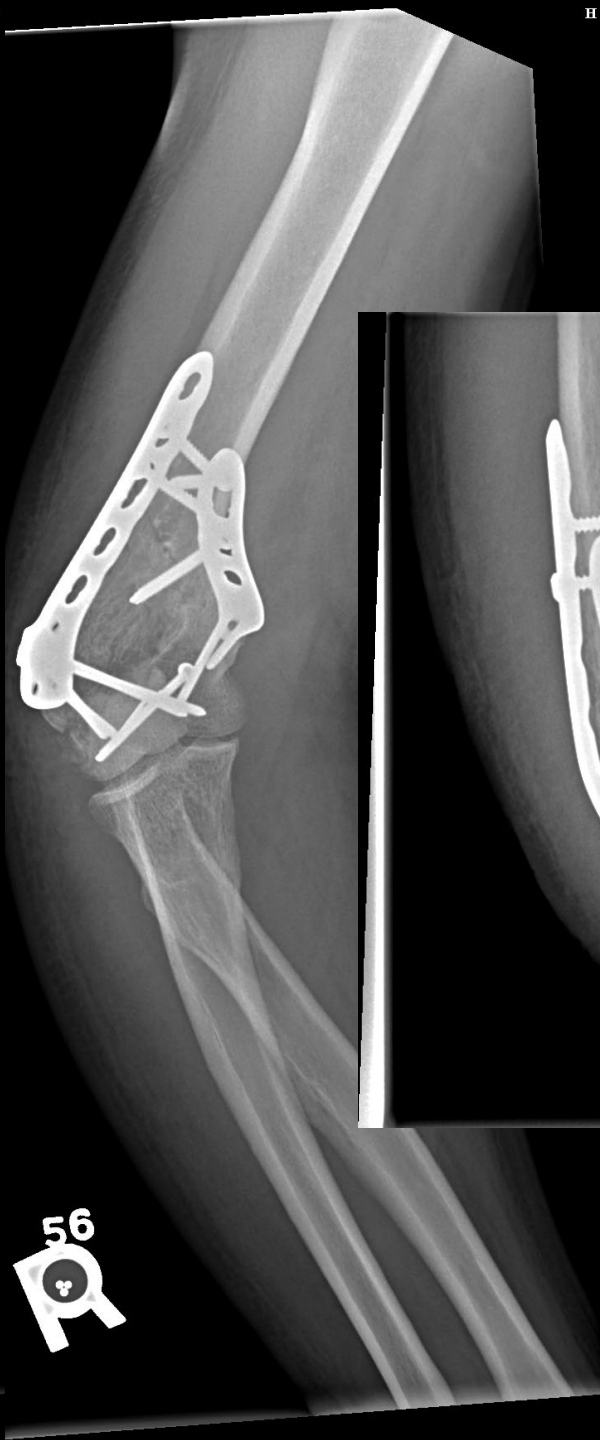



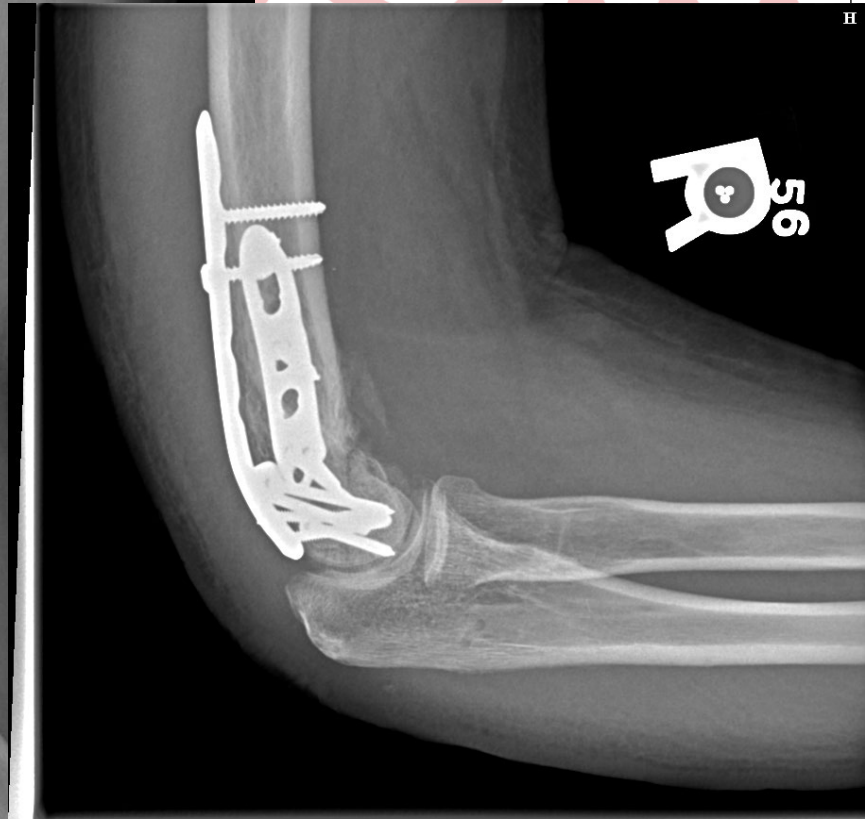




56  
R




56  
R



56  
R

Gill



# Approach



All pieces easily reducible

Some bone missing

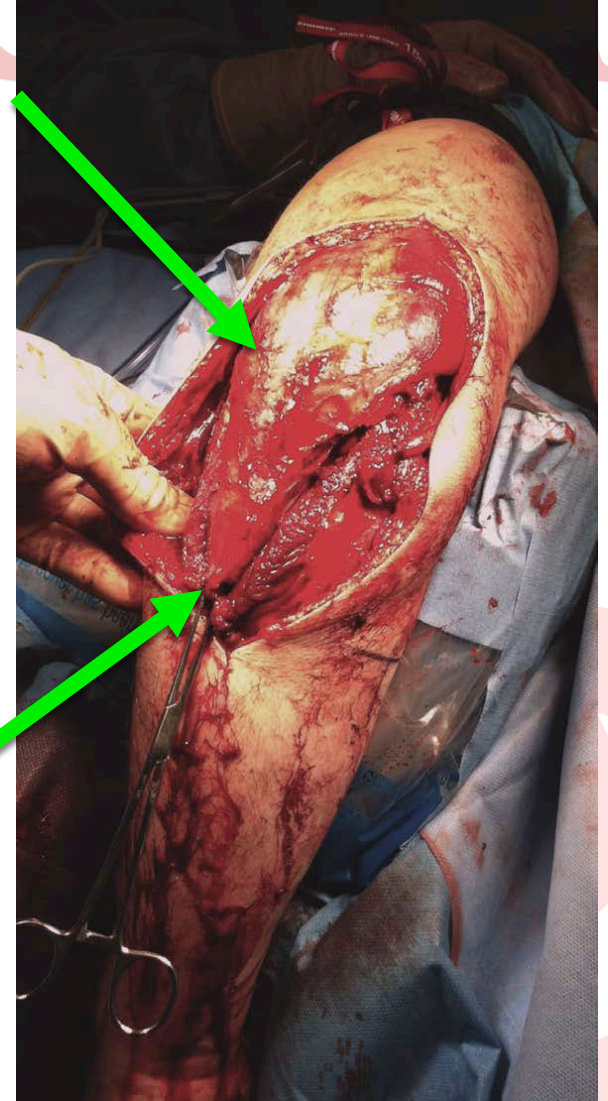
Some cartilage missing

What cartilage

Is that an elbow?

# McGill

## TRAP







## Approach I Use?

All pieces easily reducible

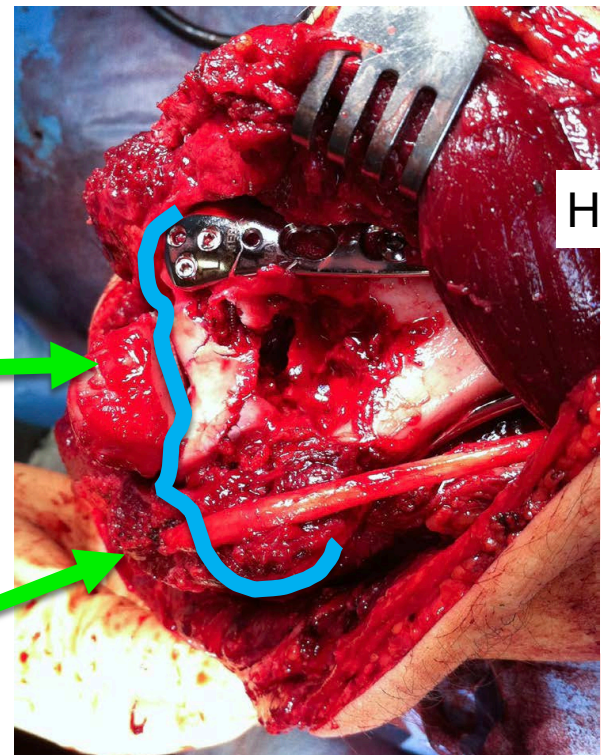
Some bone missing

Some cartilage missing

What cartilage

Is that an elbow?

Osteotomy 25% Olecrenon after exposure  
Can take down LCL – 100% of joint and operate in front



Ulna

Ulnar  
Nerve

Head

# Principles

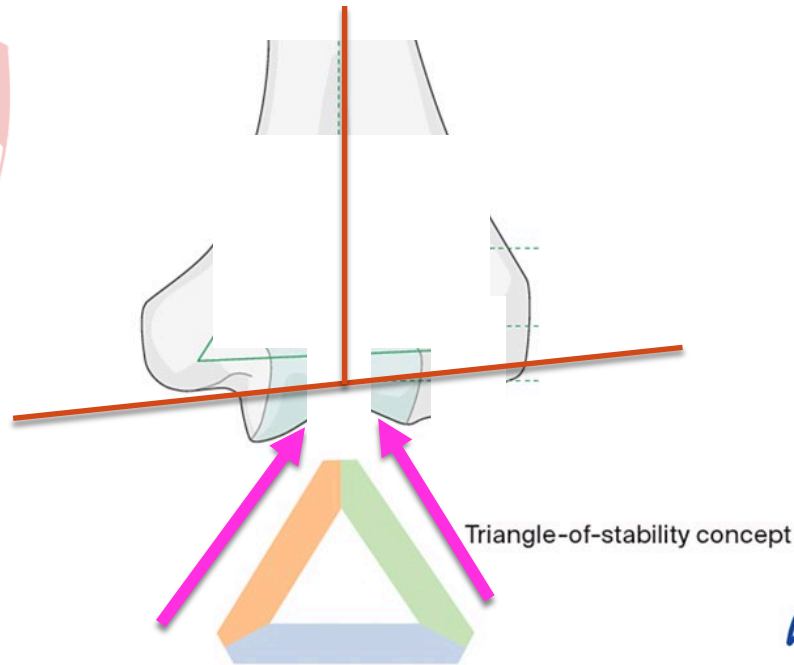
All pieces easily reducible

Some bone missing


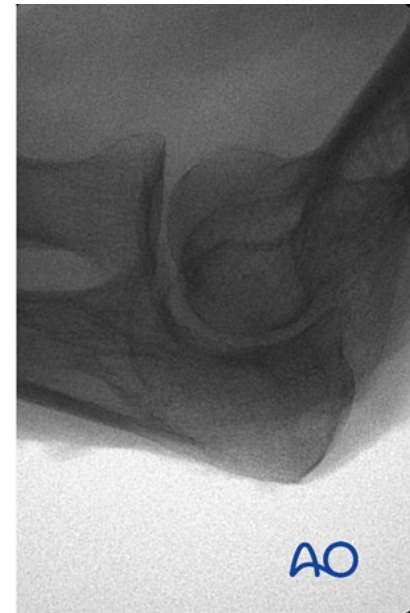
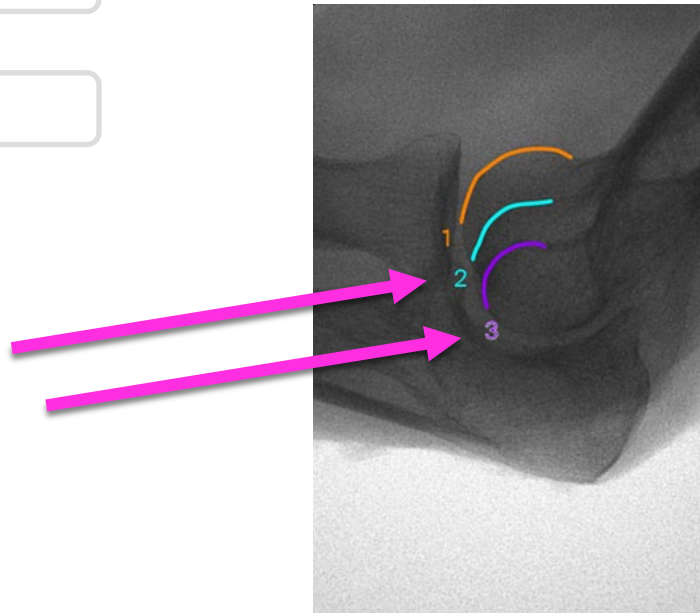
Some cartilage missing

What cartilage

Is that an elbow?



1



# Examples



# McGill

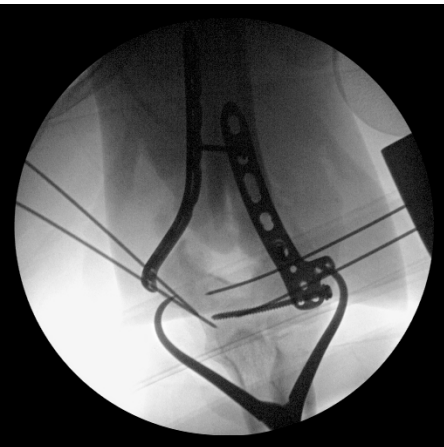All pieces easily reducible

Some bone missing

Some cartilage missing

What cartilage

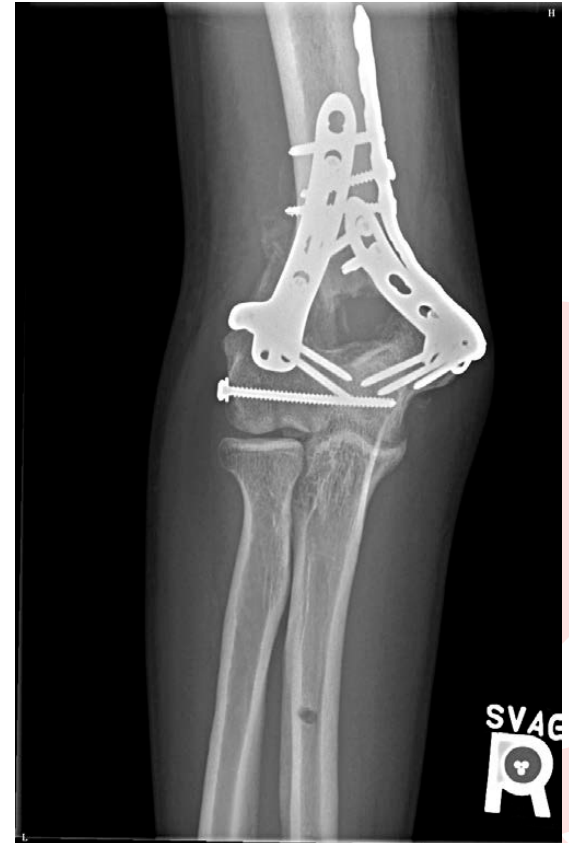Is that an elbow?



Open Fracture

Would do this differently now

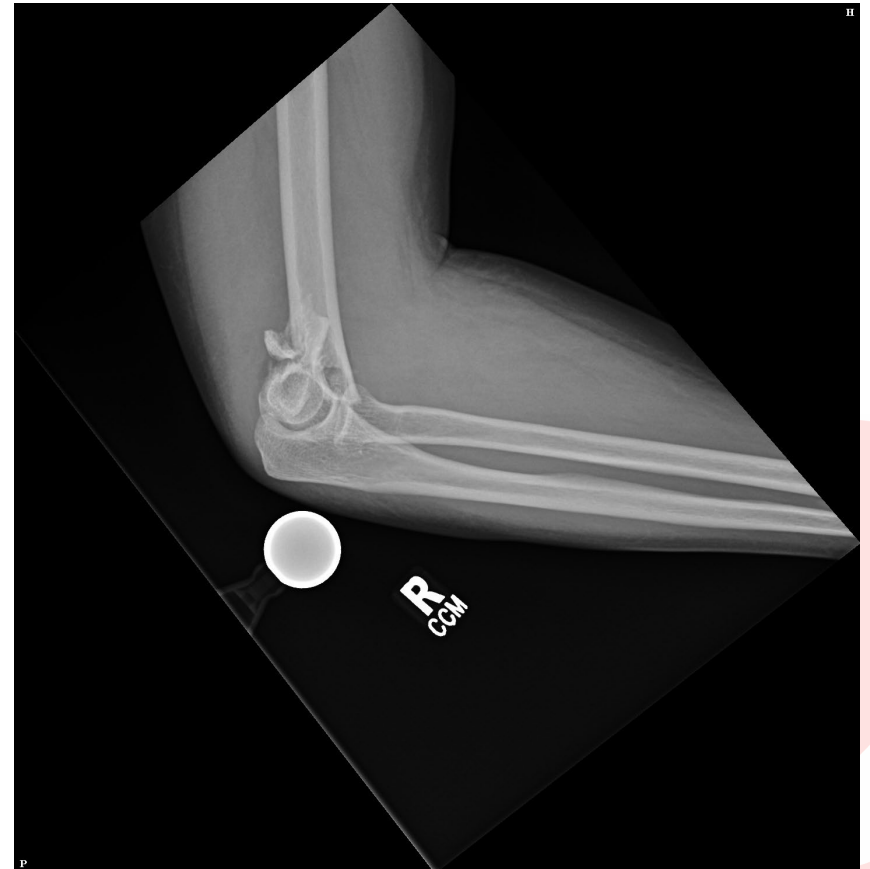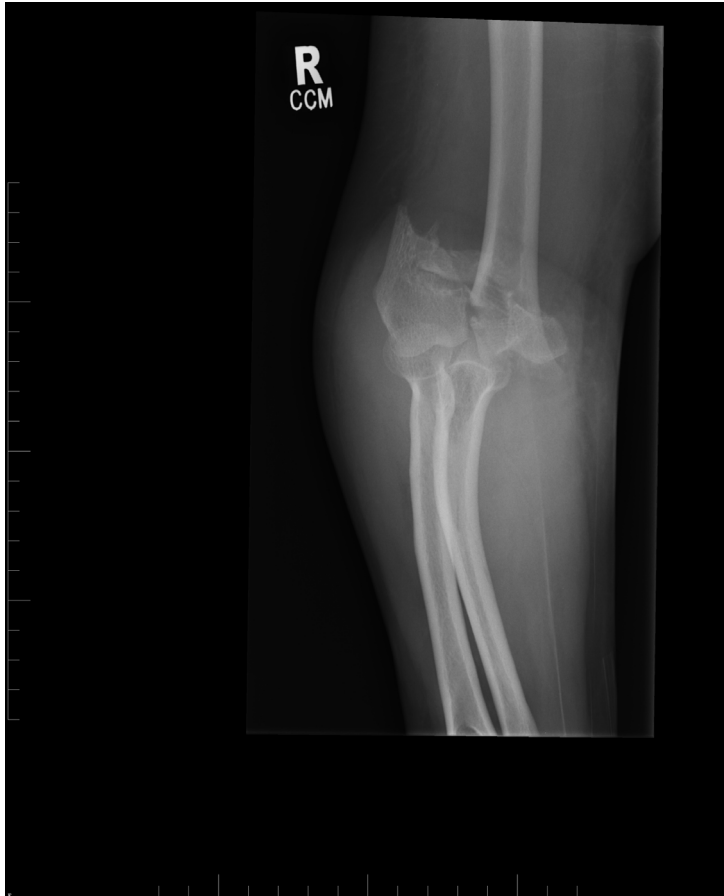Fibula / allograft

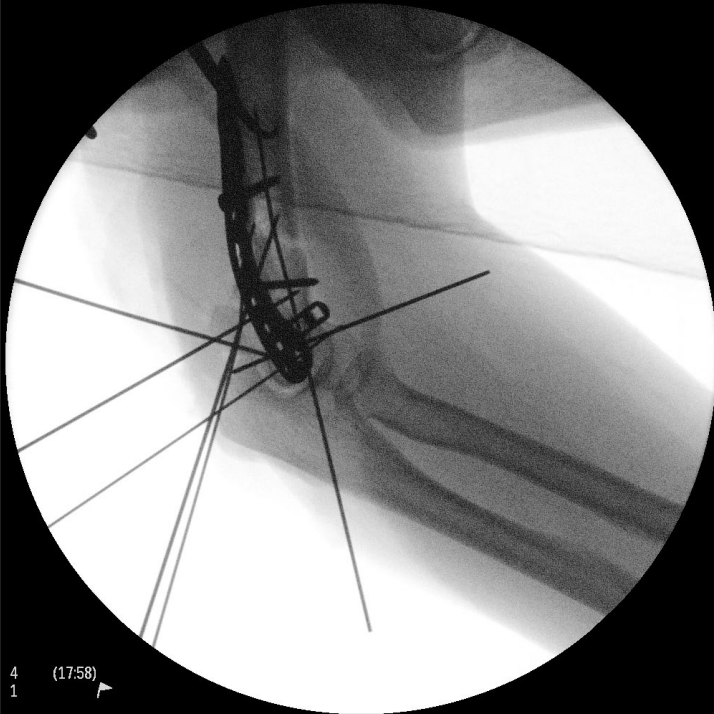

Young patient



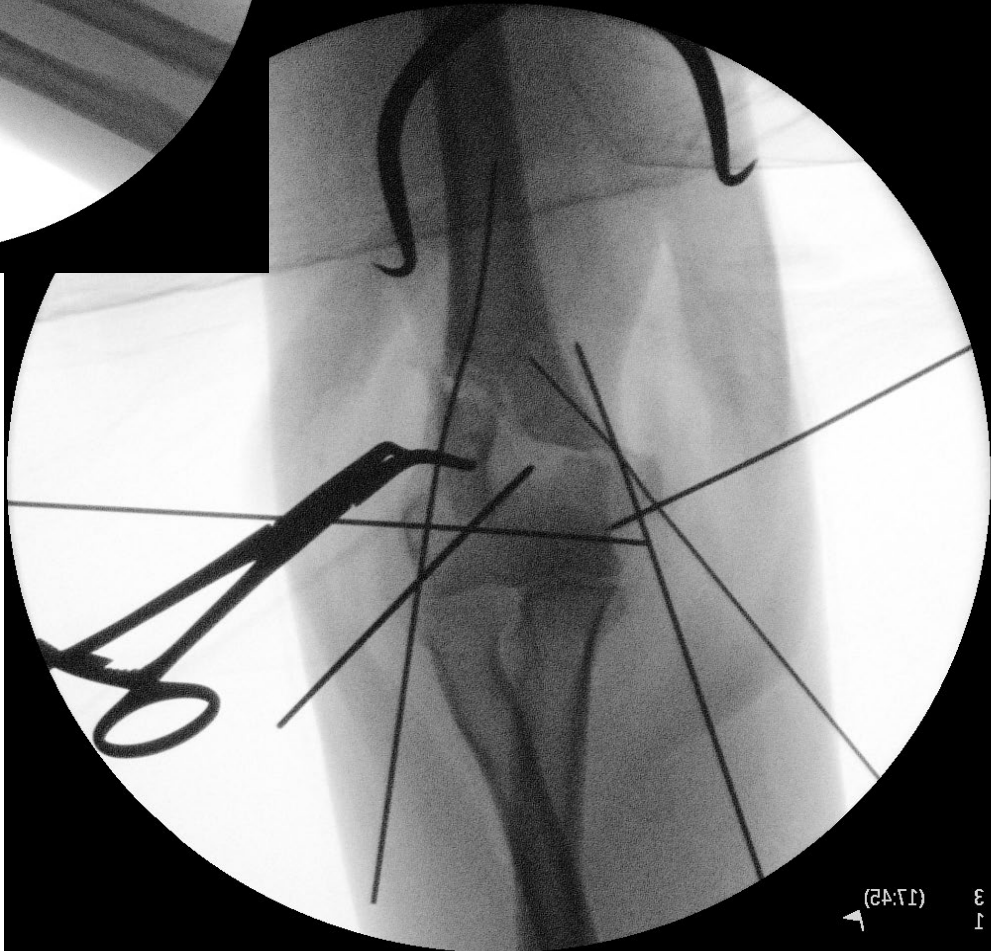
McGill





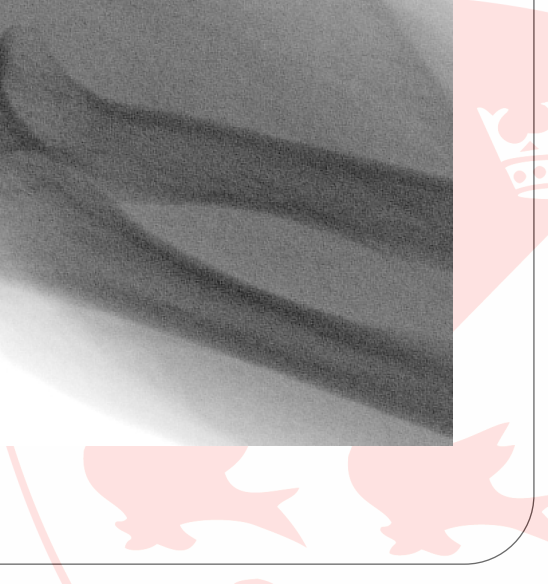
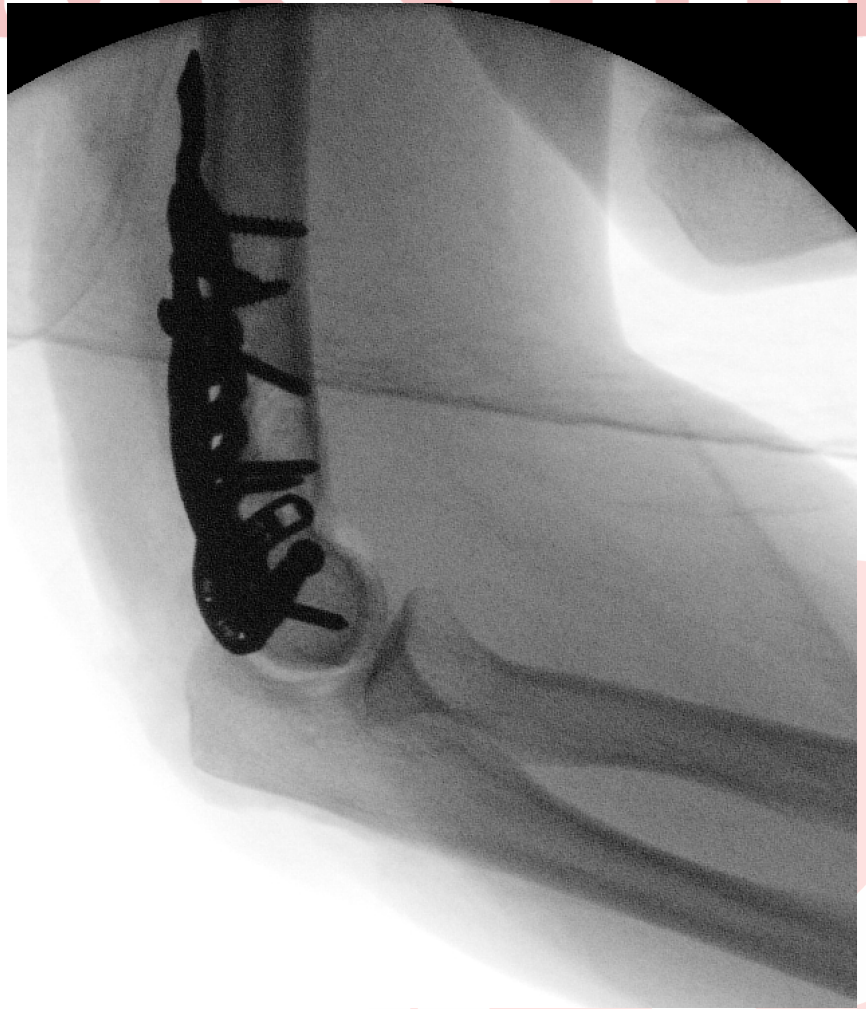
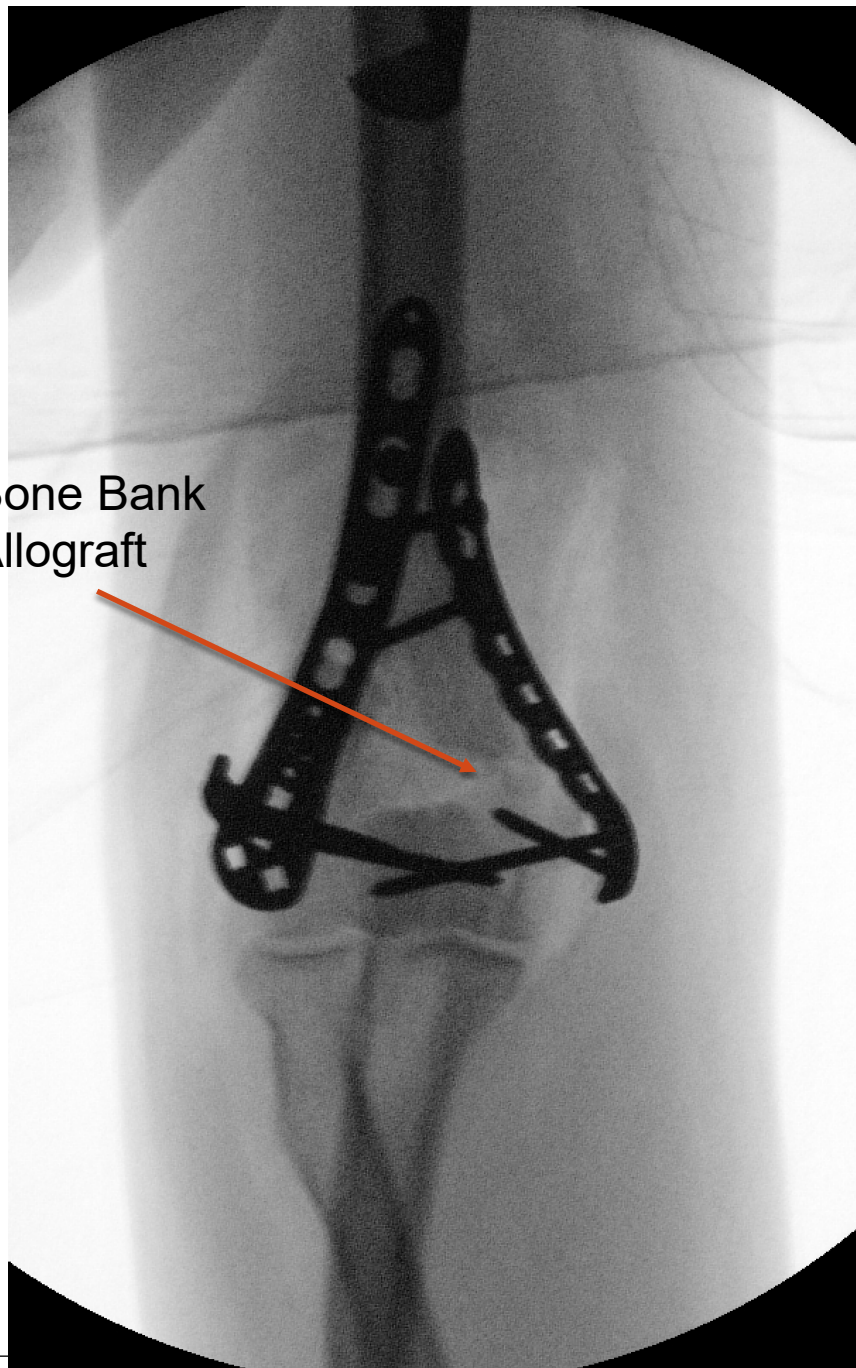
4 (17:58)  
1

# McGill



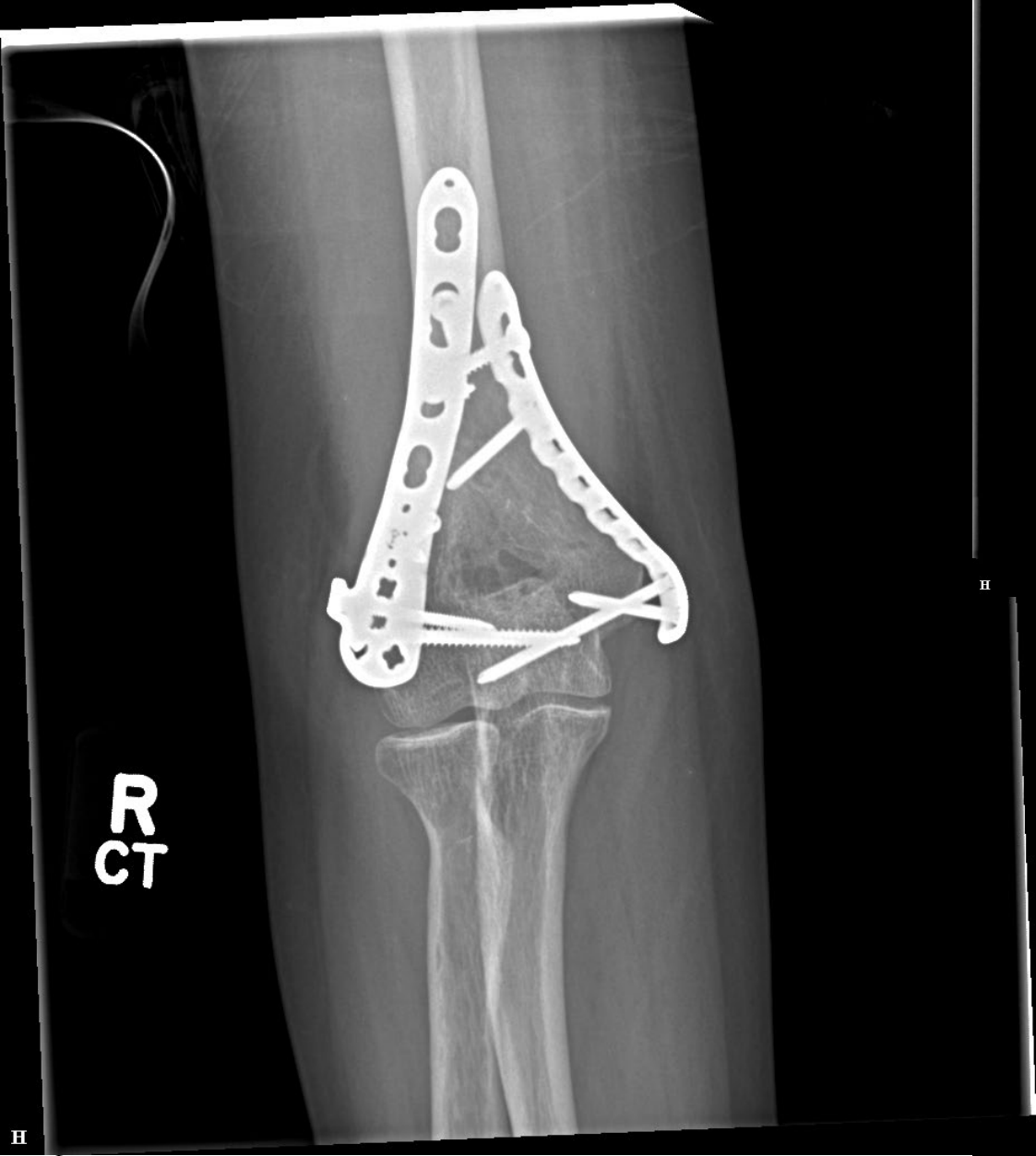3 (17:42)  
1



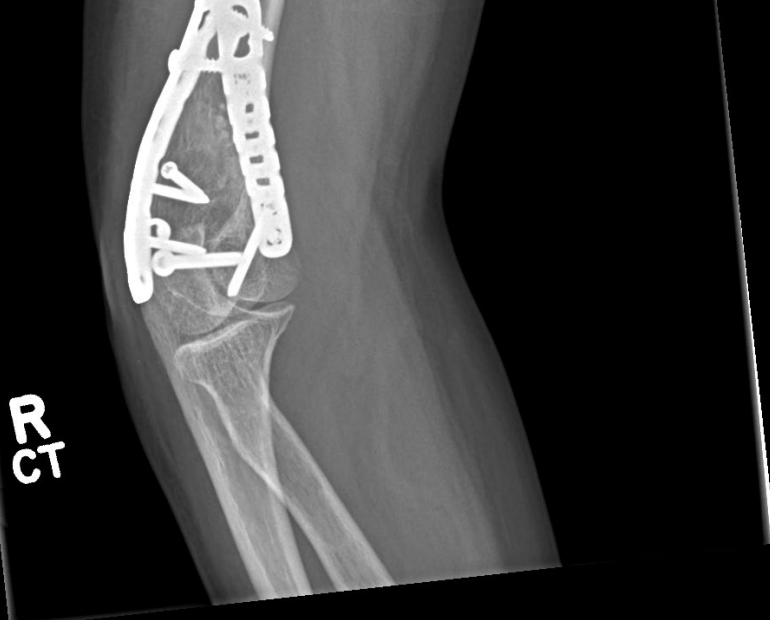
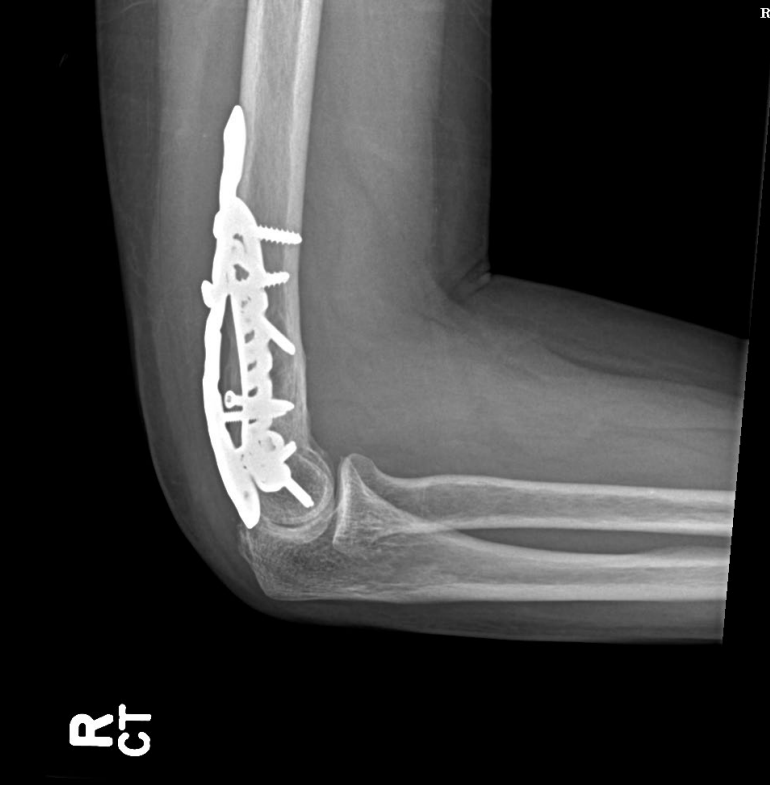


# 8 Year follow up



H



H

# Examples



# McGill

All pieces easily reducible

Some bone missing

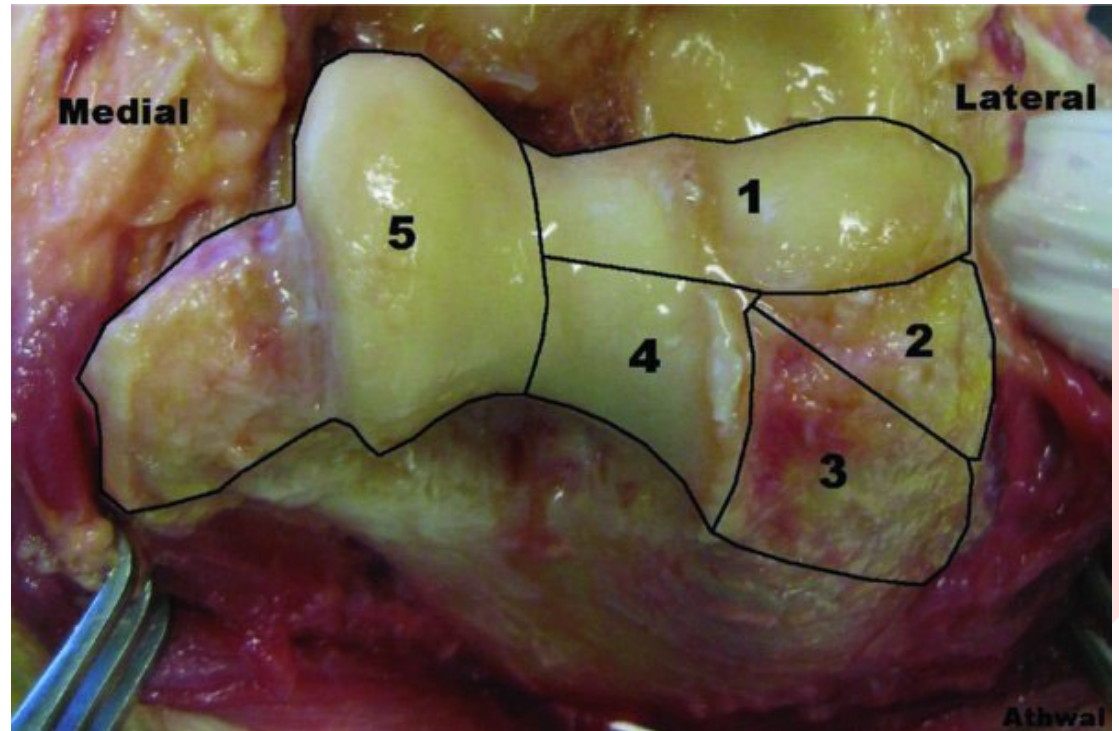
Some cartilage missing

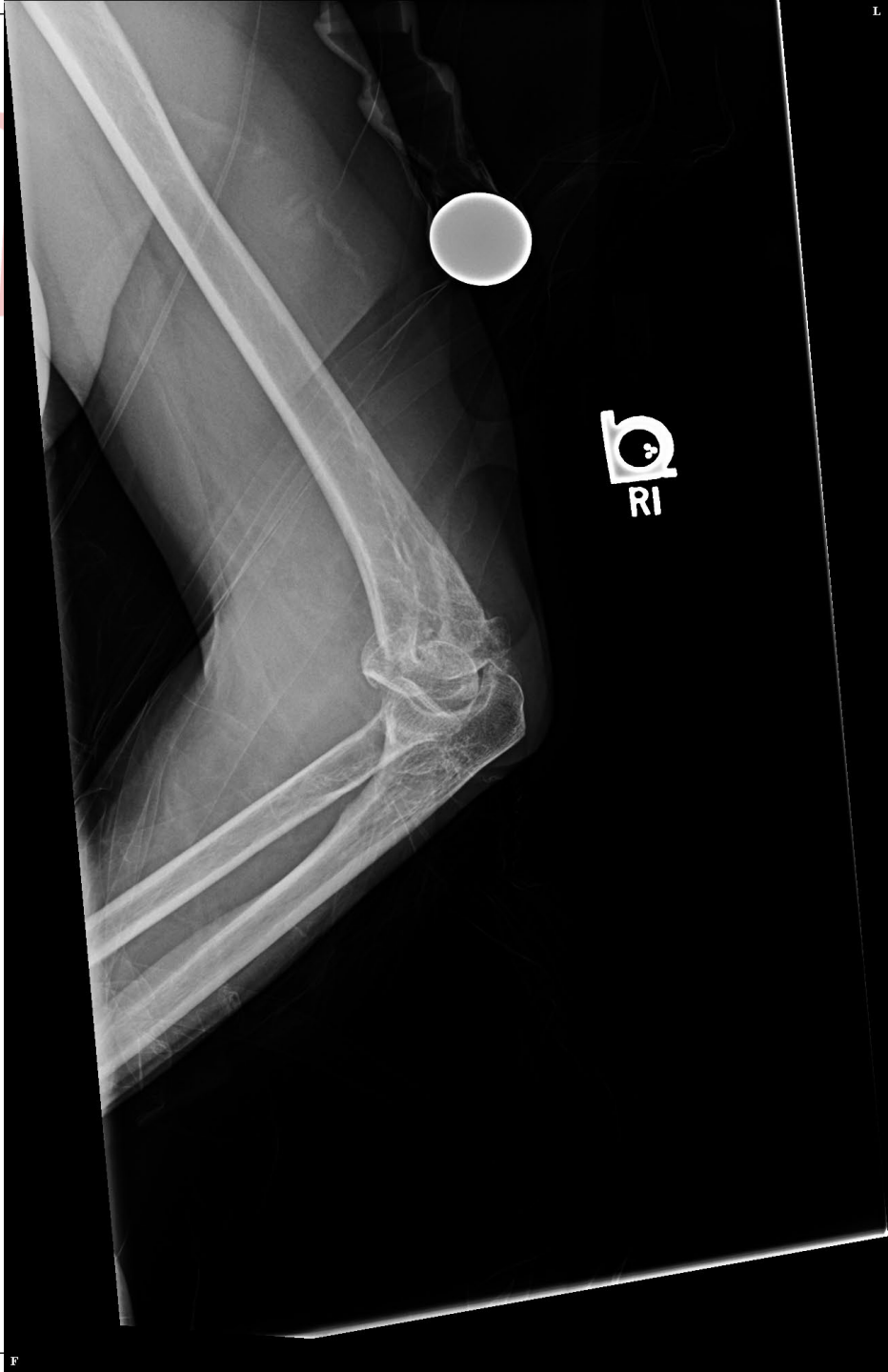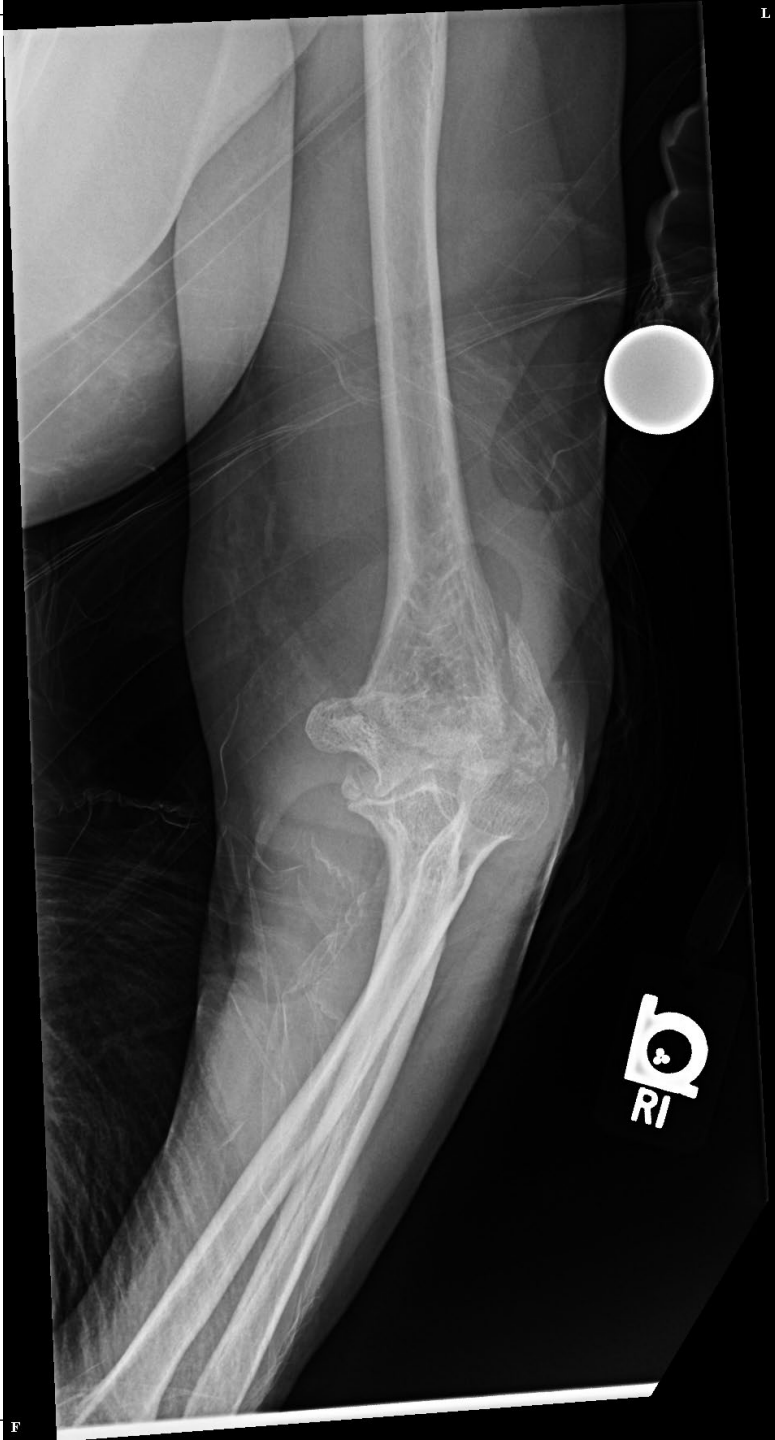What cartilage

Is that an elbow?

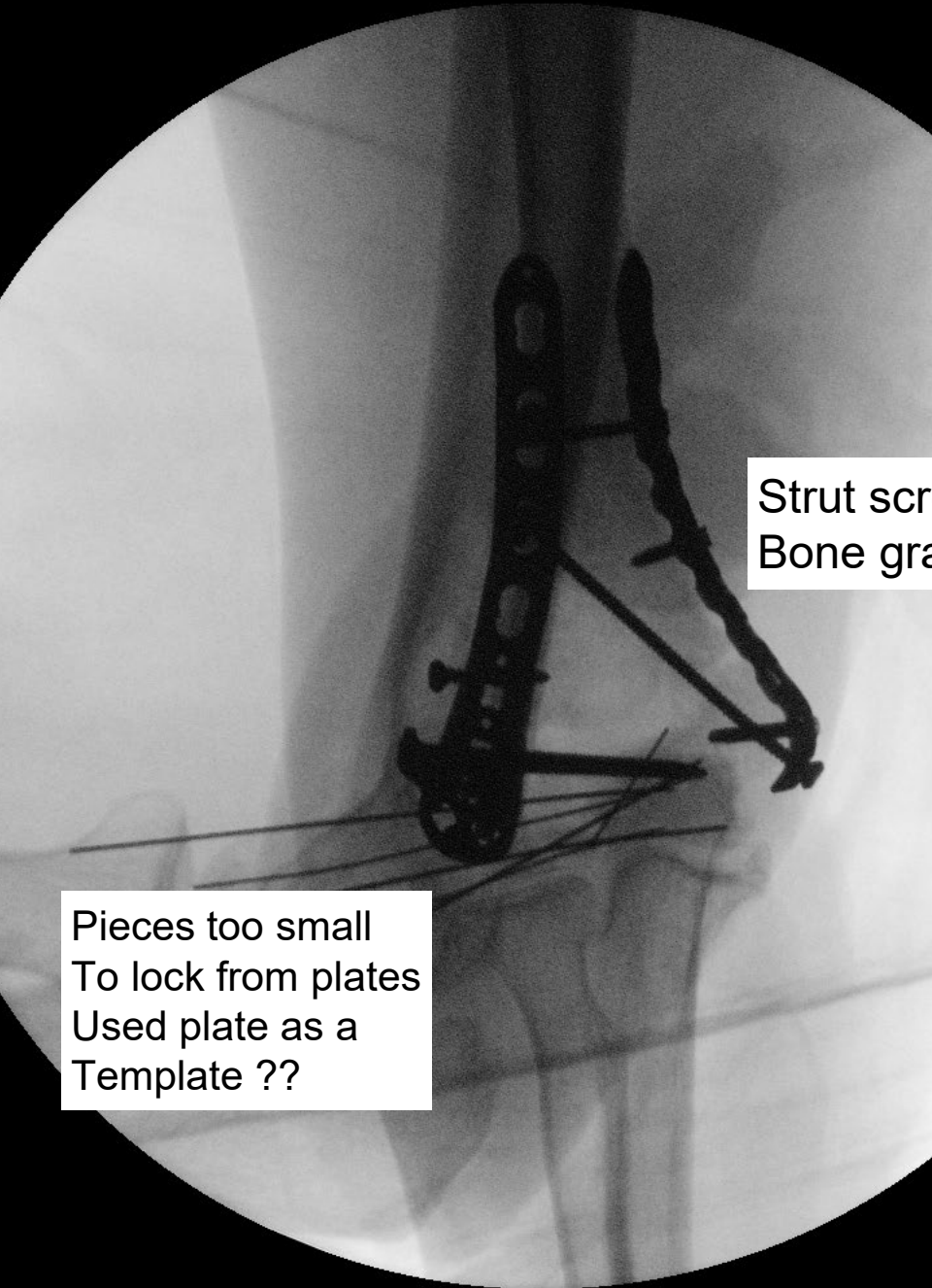
Realize where it is missing from

Ring Classification



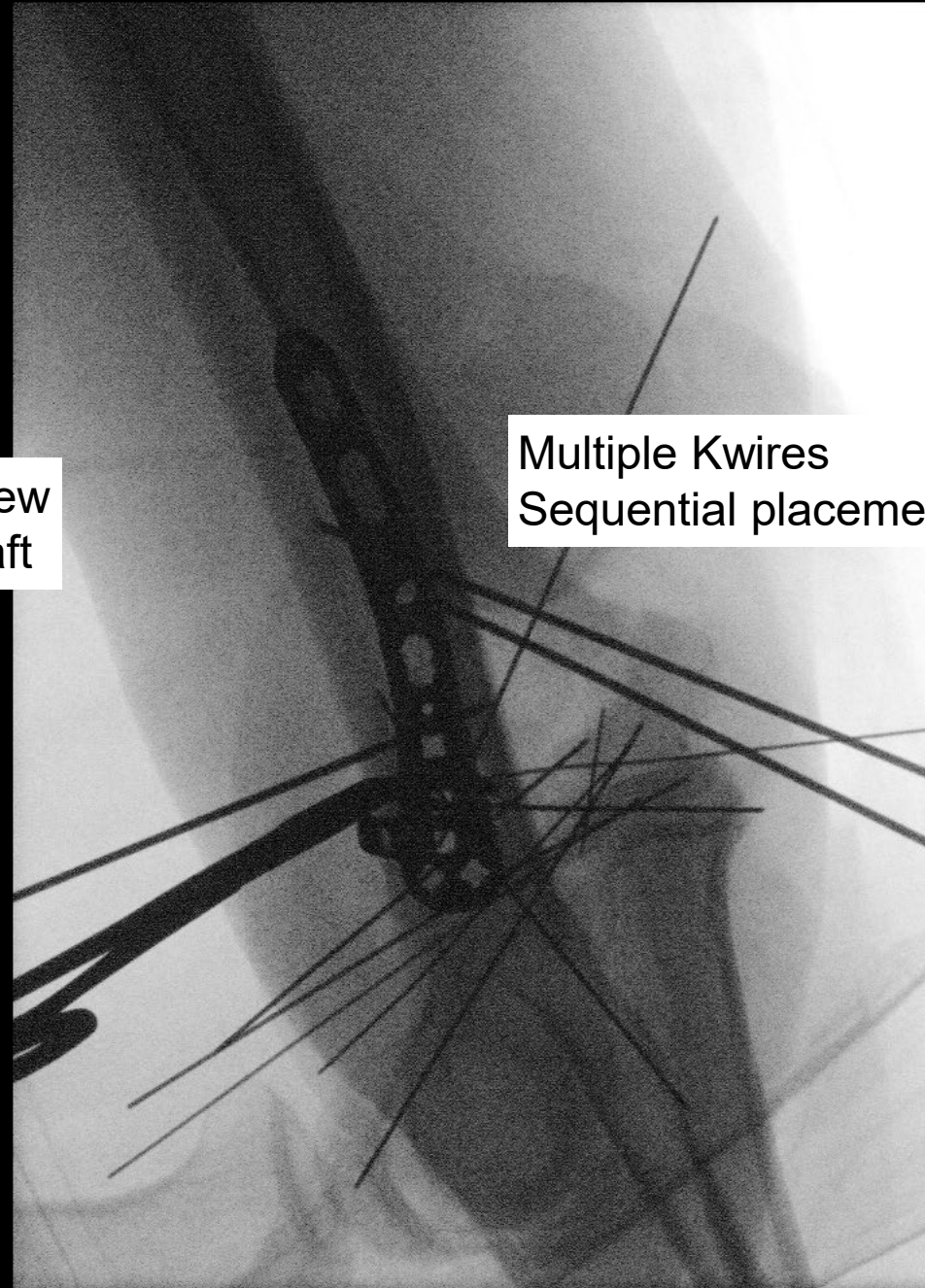






Strut screw  
Bone graft

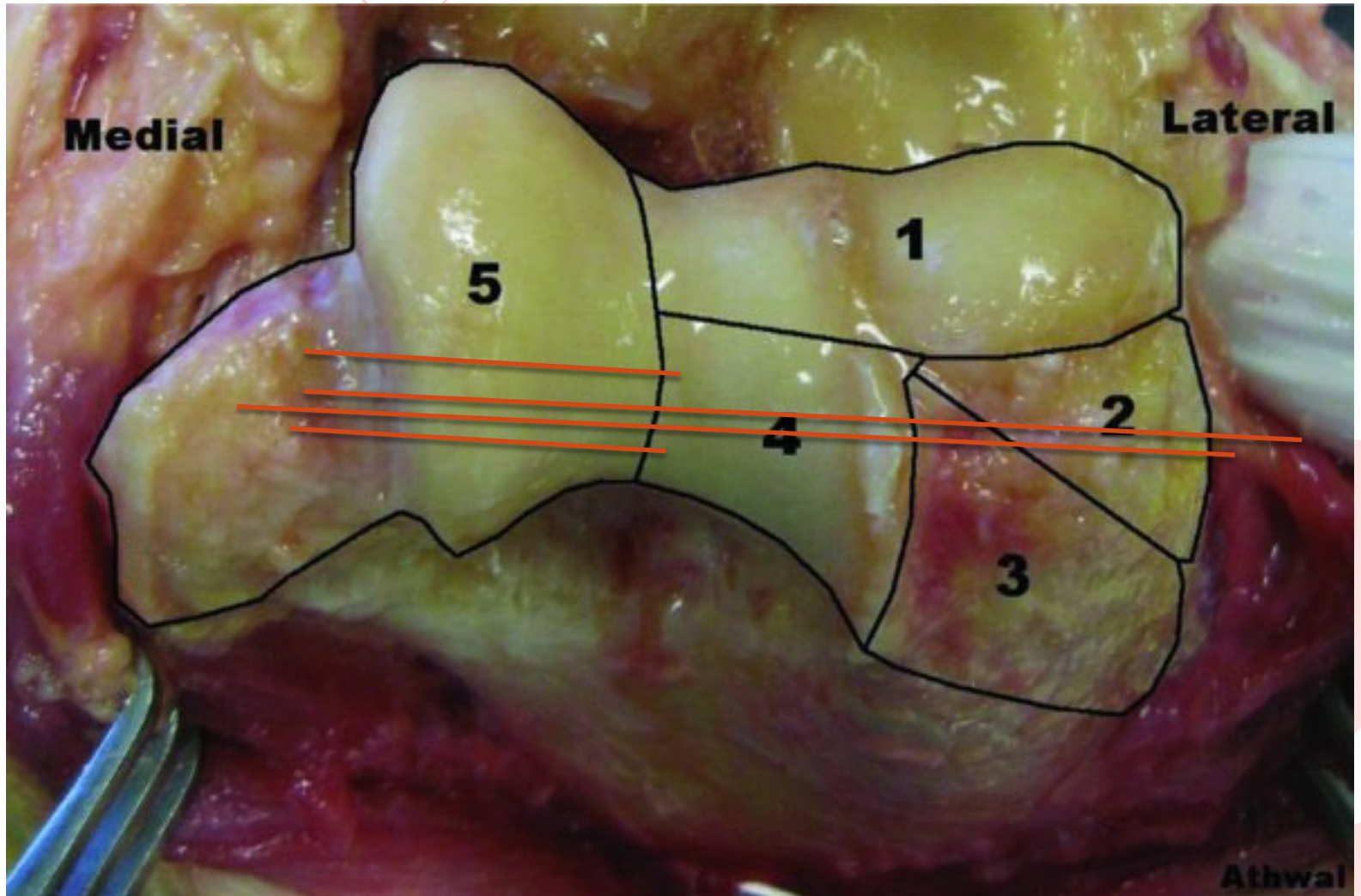
Pieces too small  
To lock from plates  
Used plate as a  
Template ??



Multiple K-wires  
Sequential placeme



## Small Kwire Usage

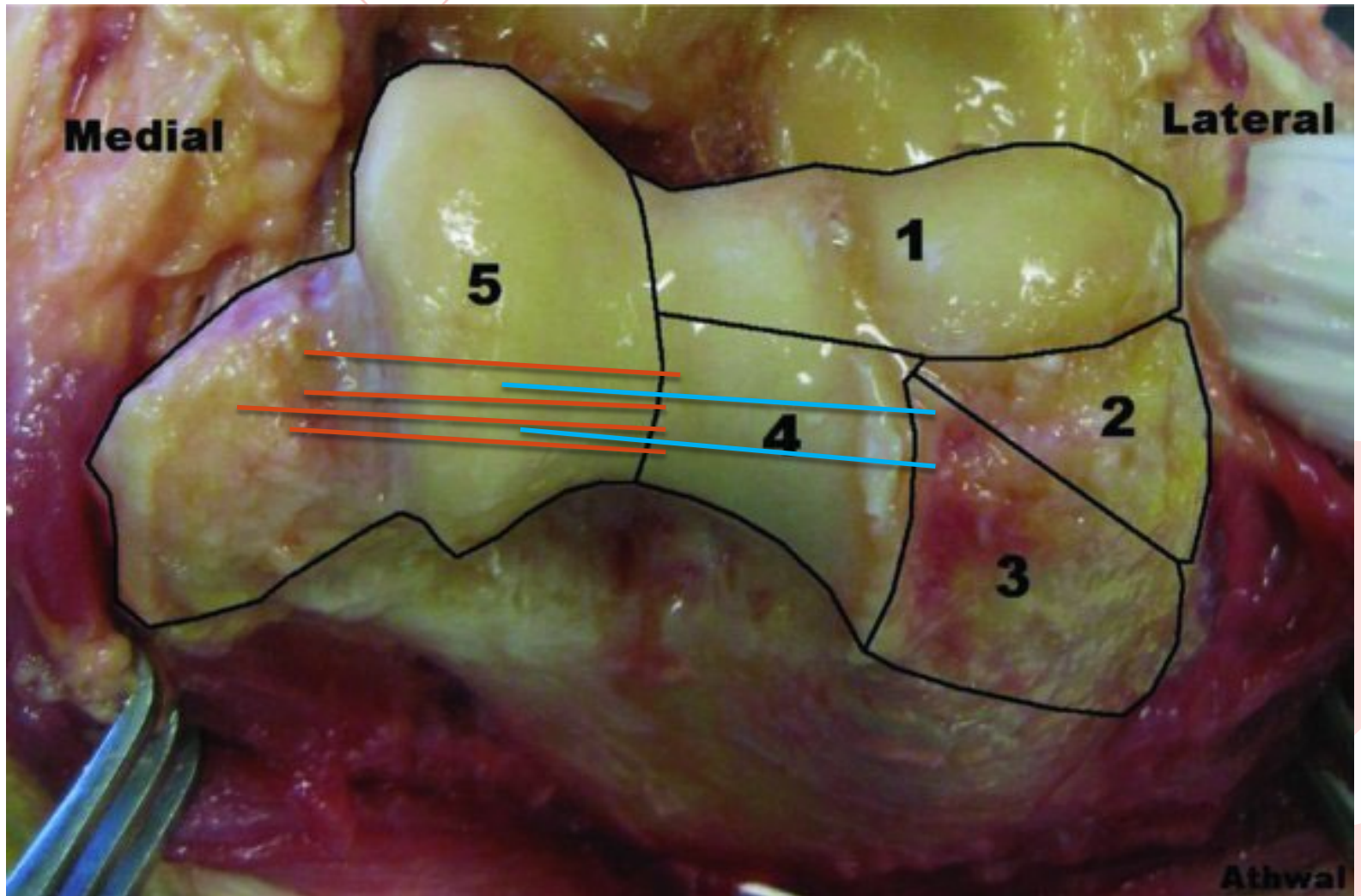




# Small Kwire Usage

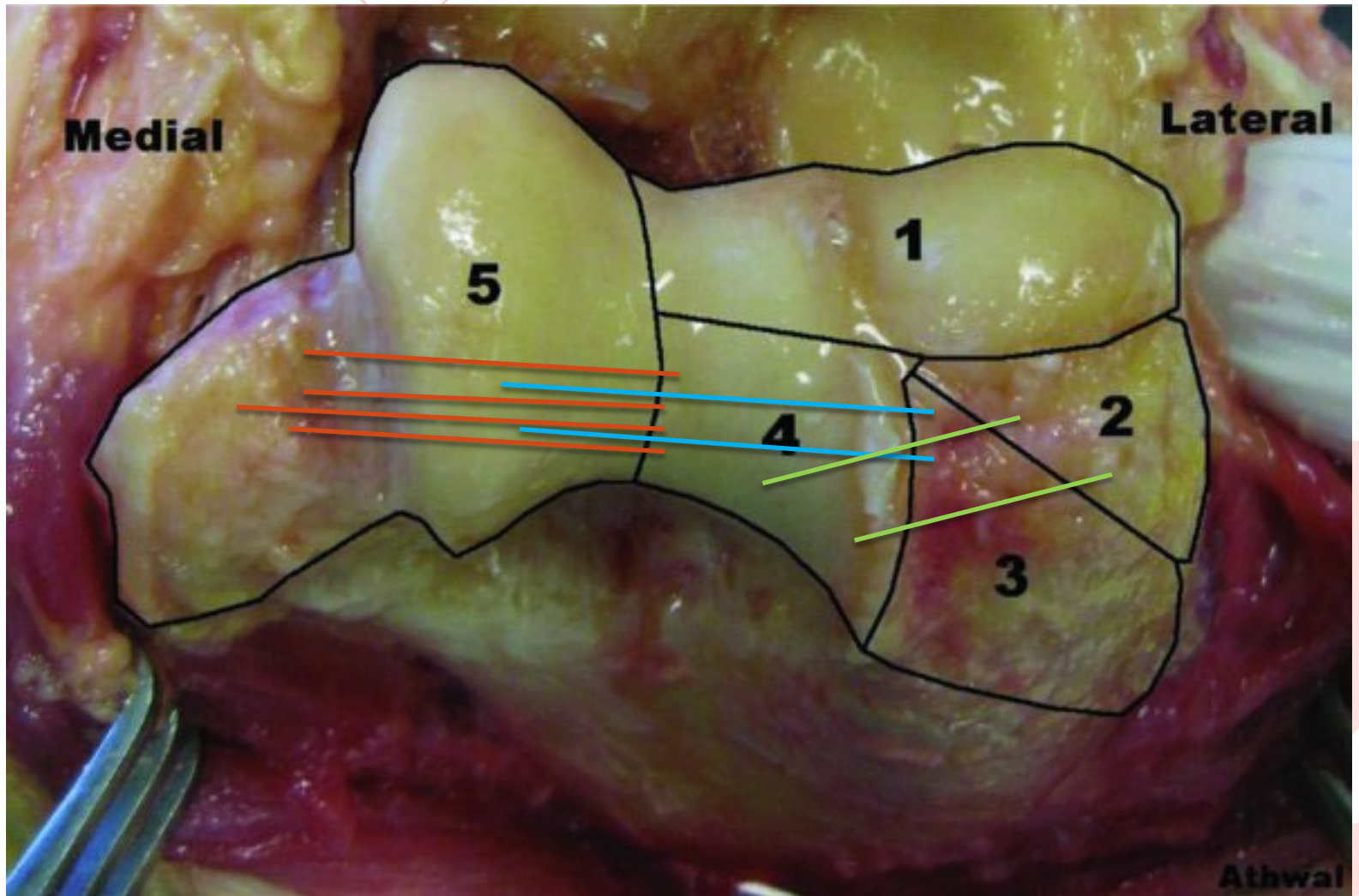


# McGill





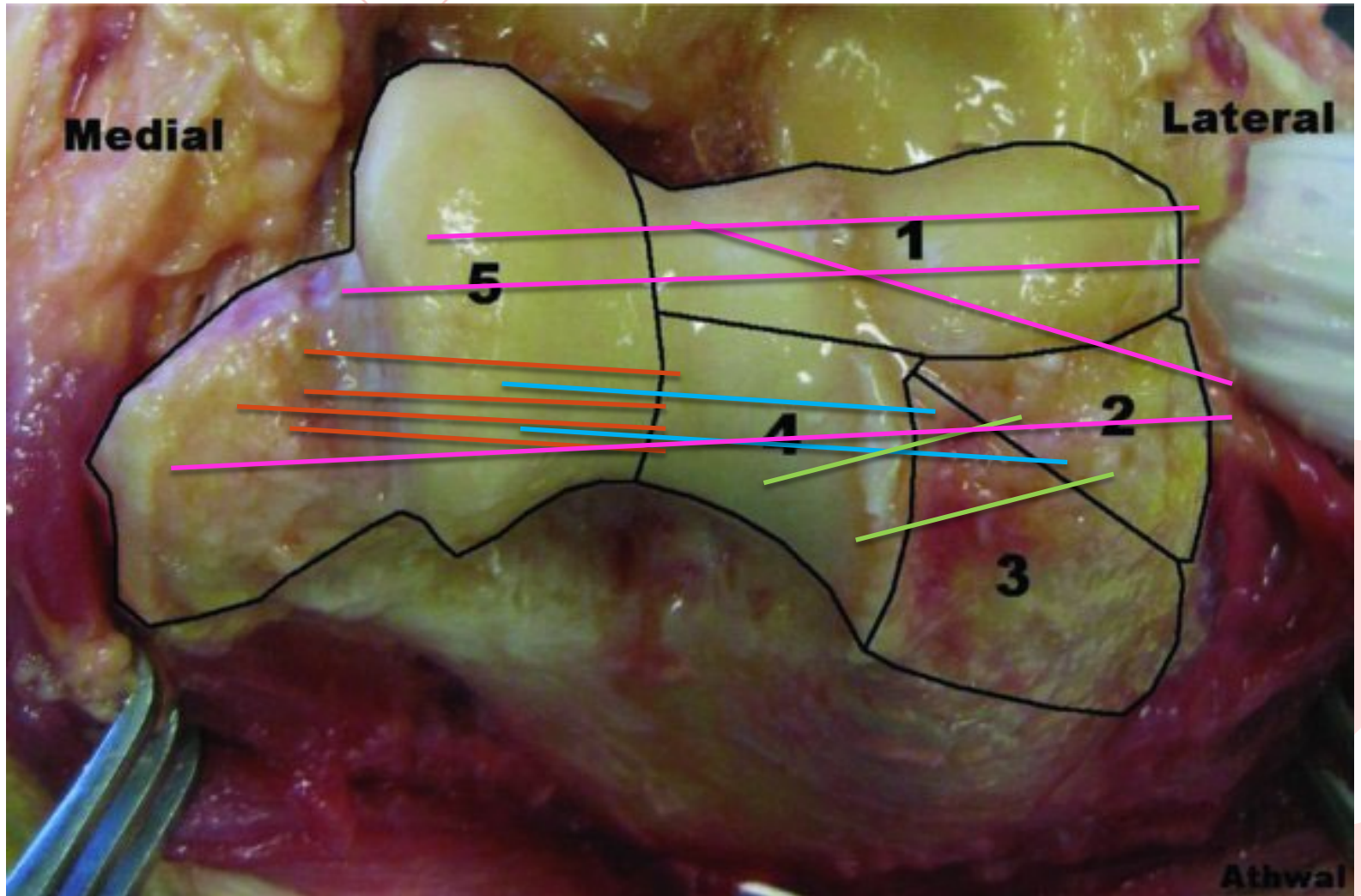
## Small Kwire Usage








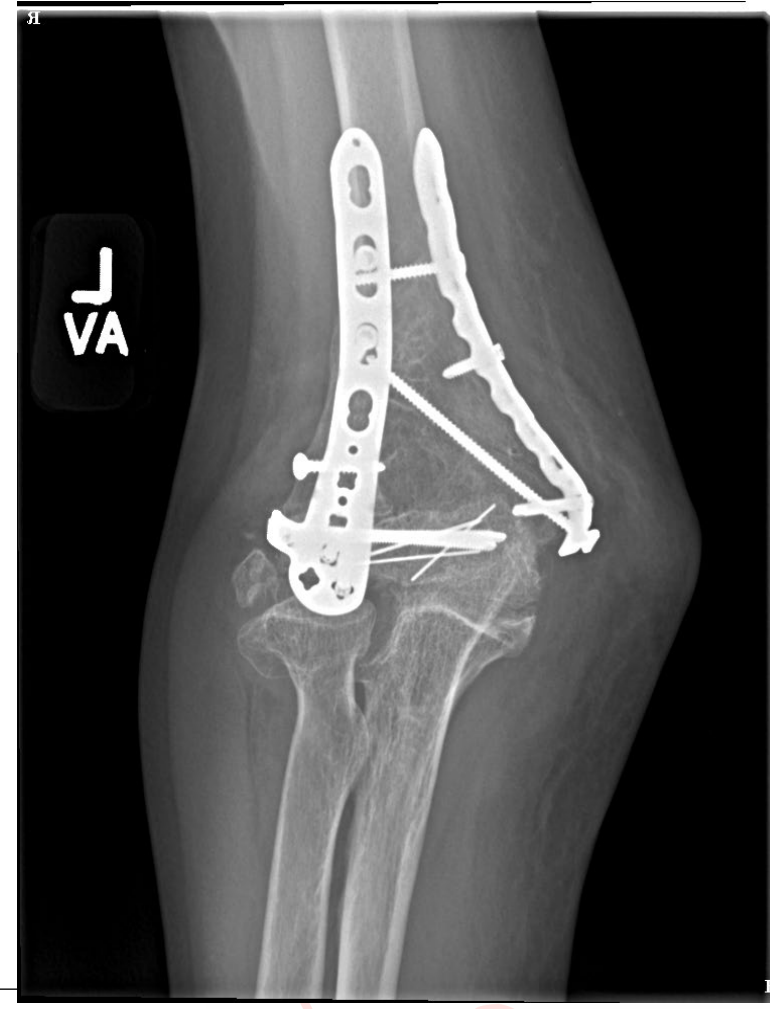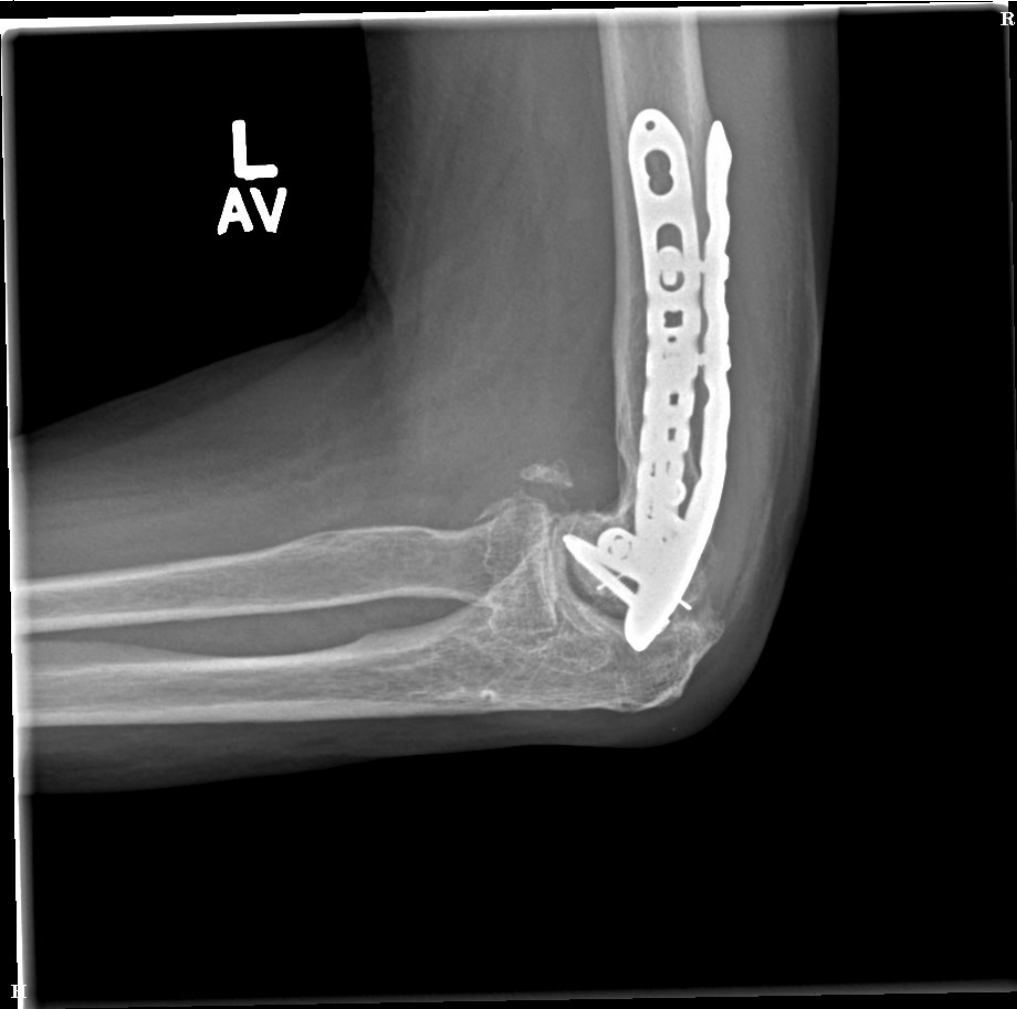
## Small Kwire Usage




6 year Follow up –  
now out 14 years



McGill




# DERMOPLASTY



# McGill

- Option for revision in young patient where TEA not an option
- Done a few – surprisingly, happy patients
- Use abdominal dermis – allows primary closure





# Examples



# McGill

All pieces easily reducible

Some bone missing

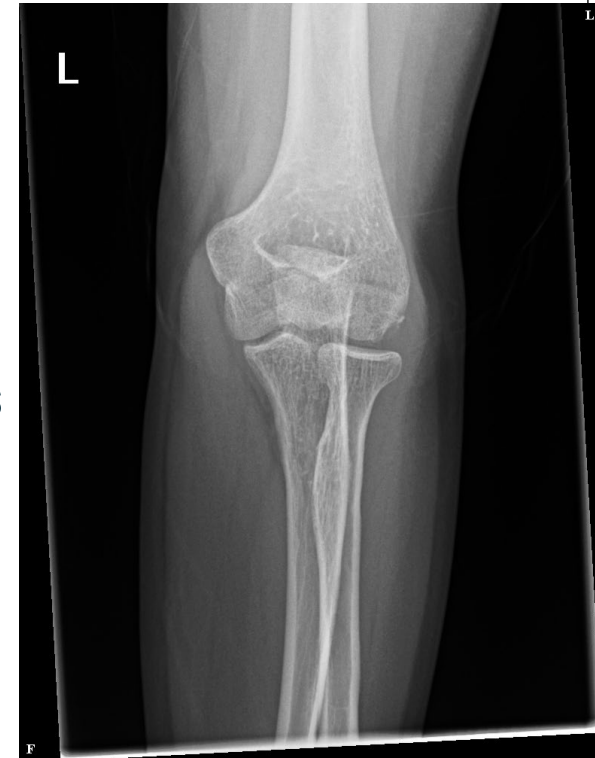
Some cartilage missing

What cartilage

Is that an elbow?

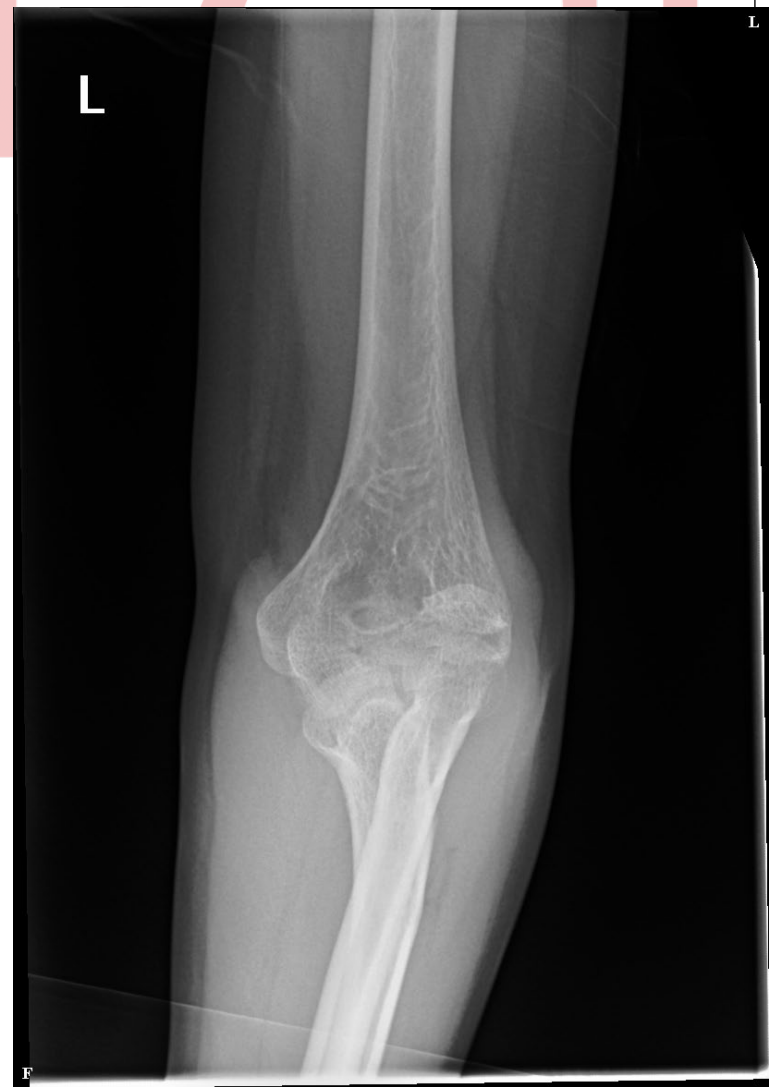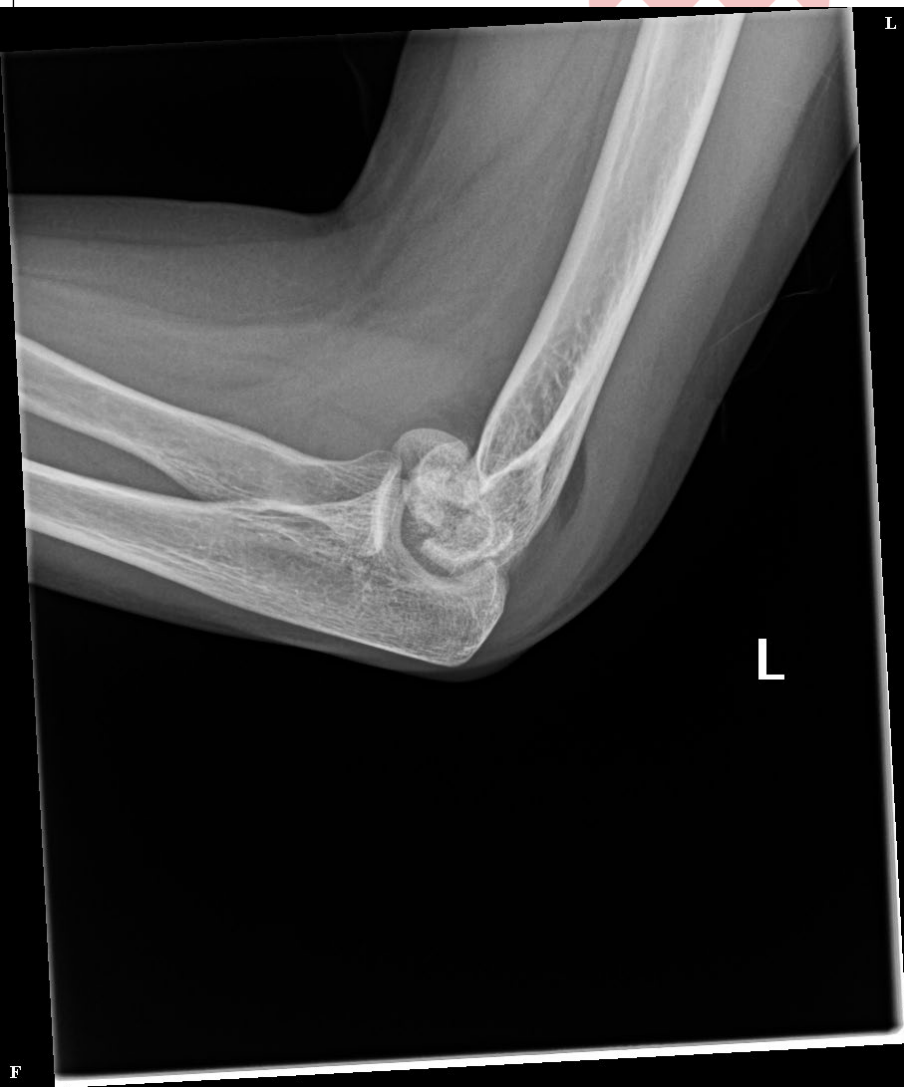38 y.o. Female

- Fell on stairs
- Otherwise well
- No soft tissue issues
- NV intact



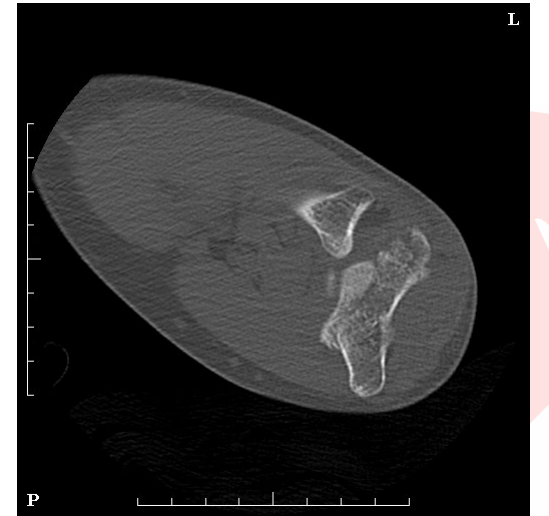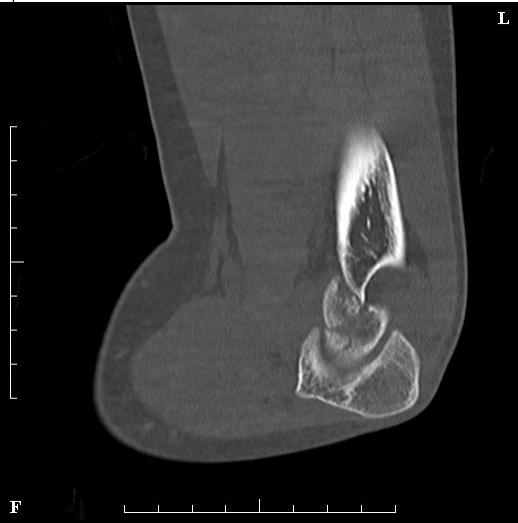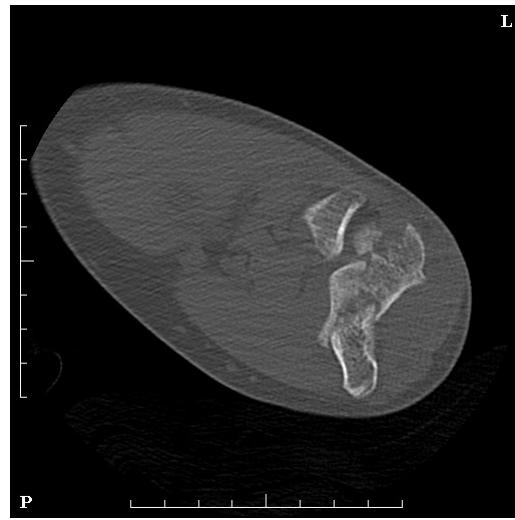


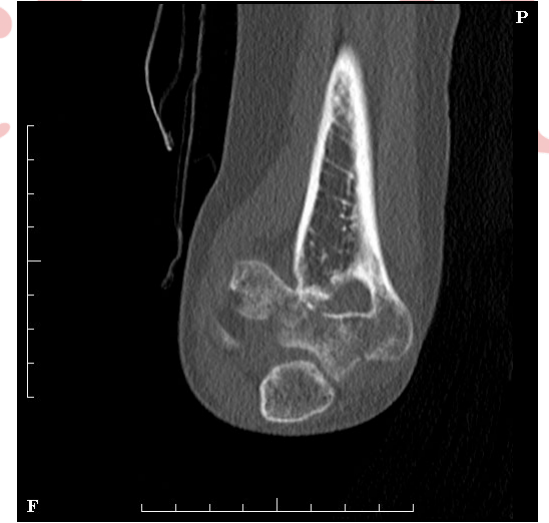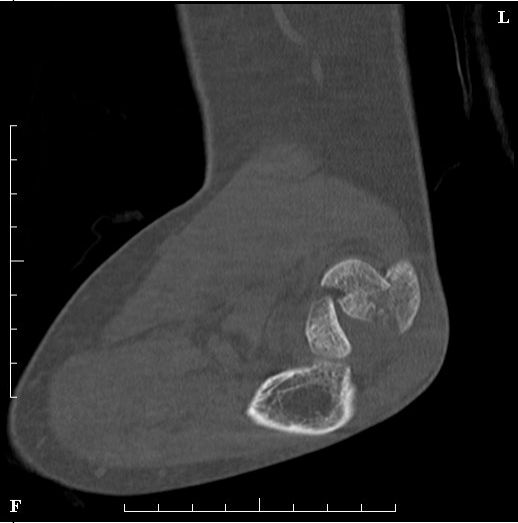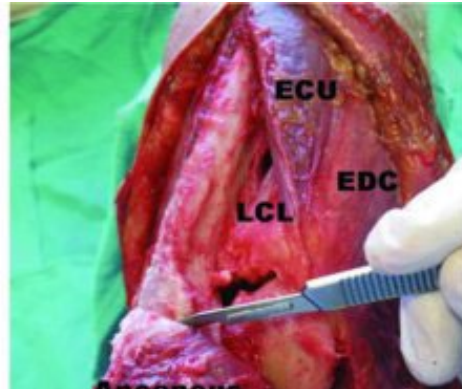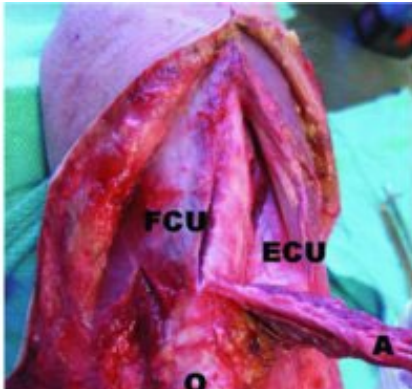
M C 11




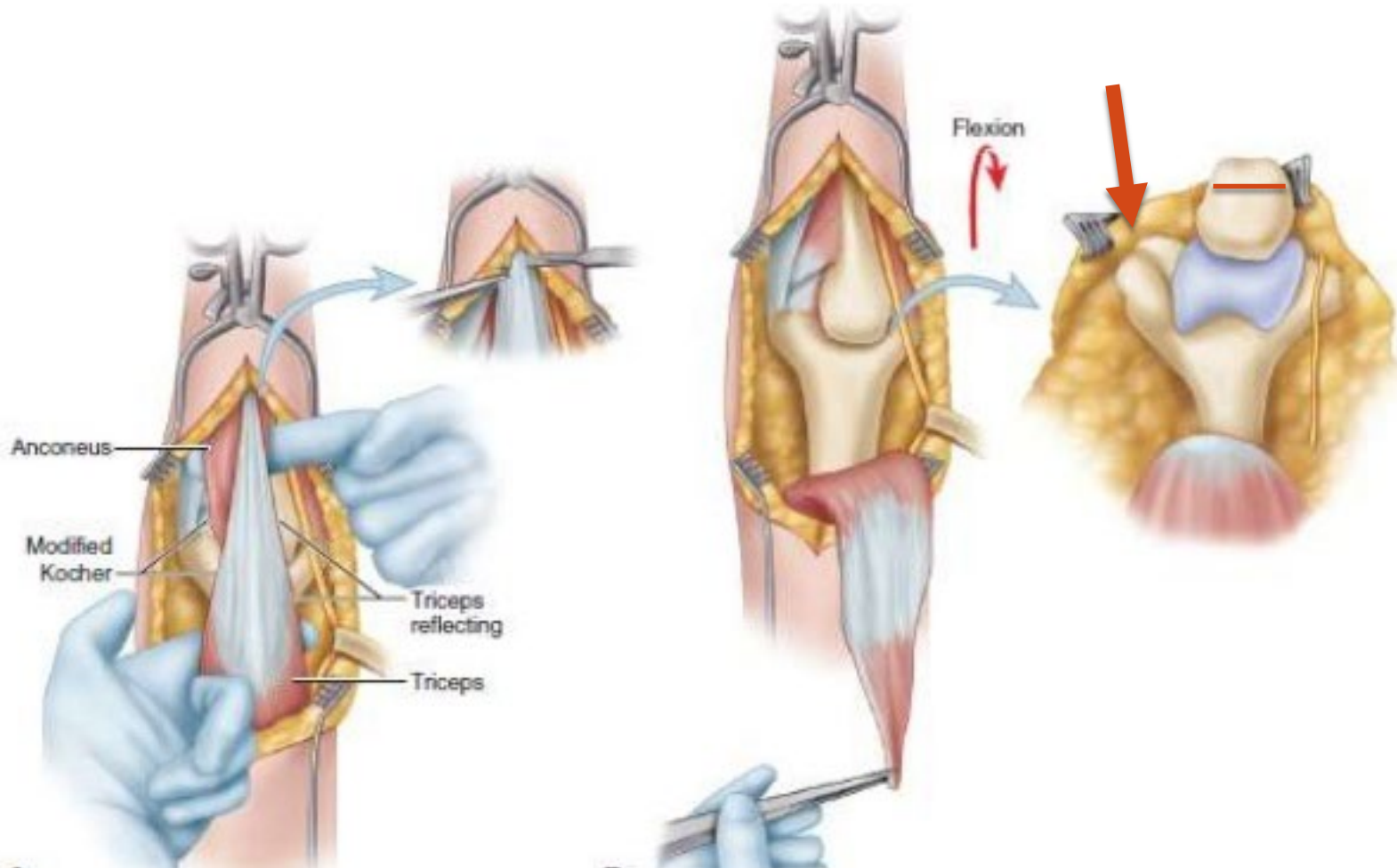

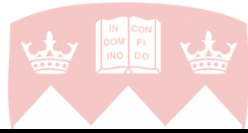
McGill



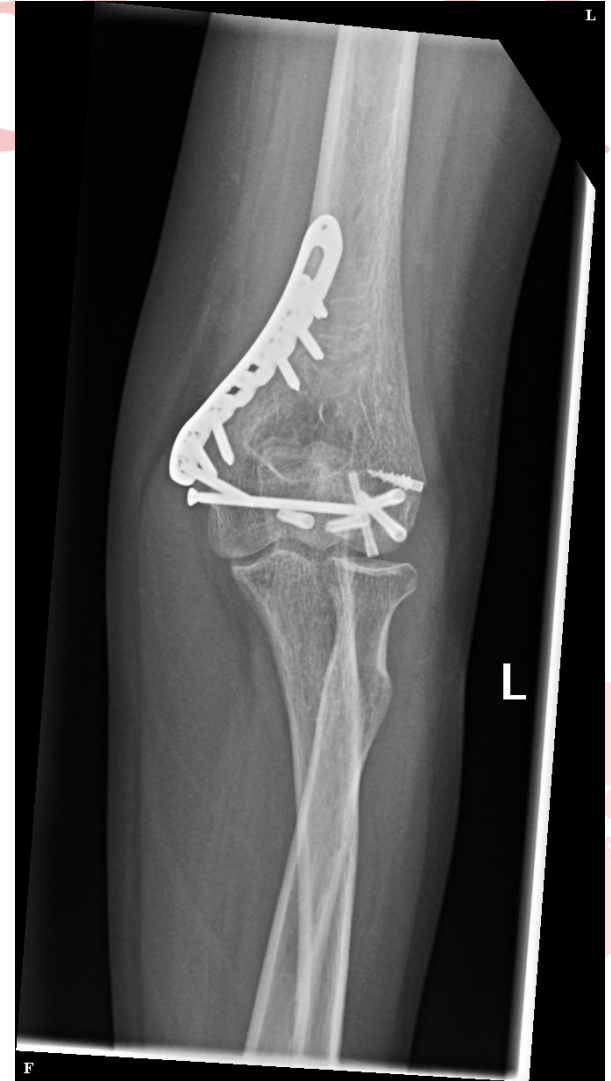
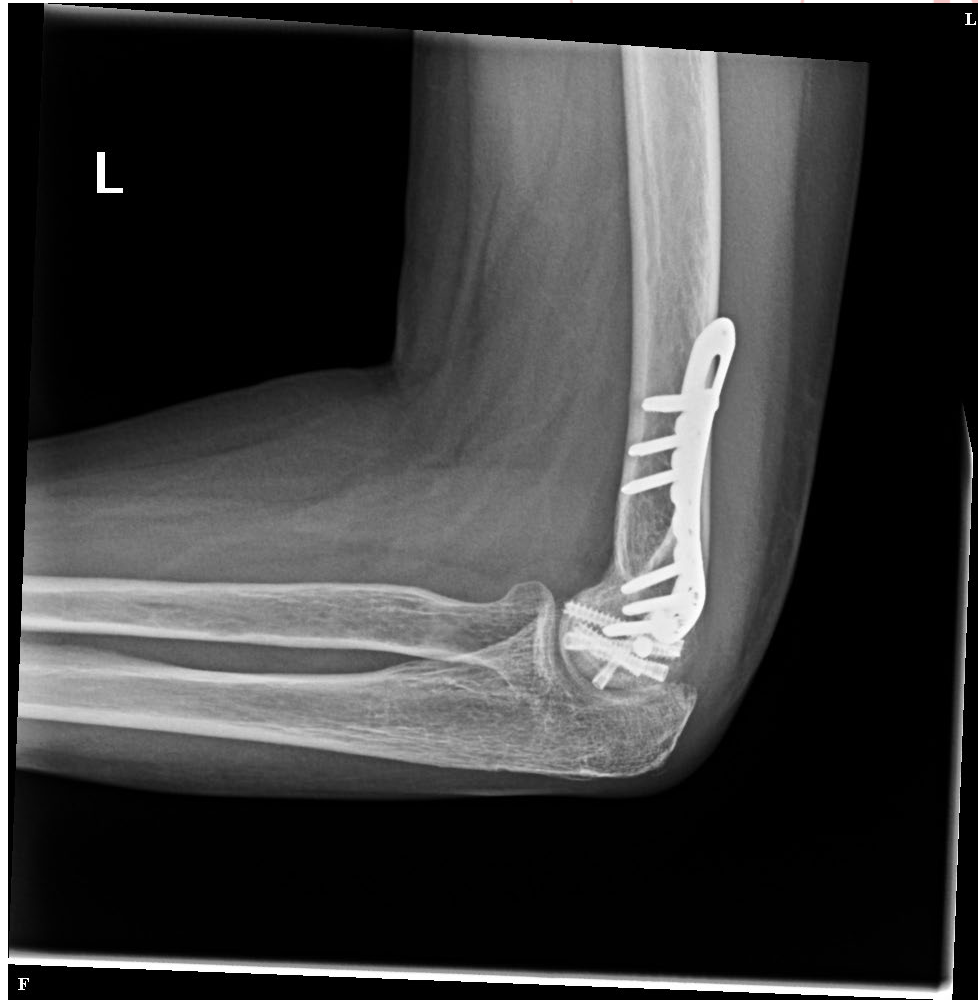
LCL is the secret





Medicine





# Approaches



All pieces easily reducible

Some bone missing

Some cartilage missing

What cartilage

Is that an elbow?

# McGill

## Medial Morrey

### TEA

### Allograft

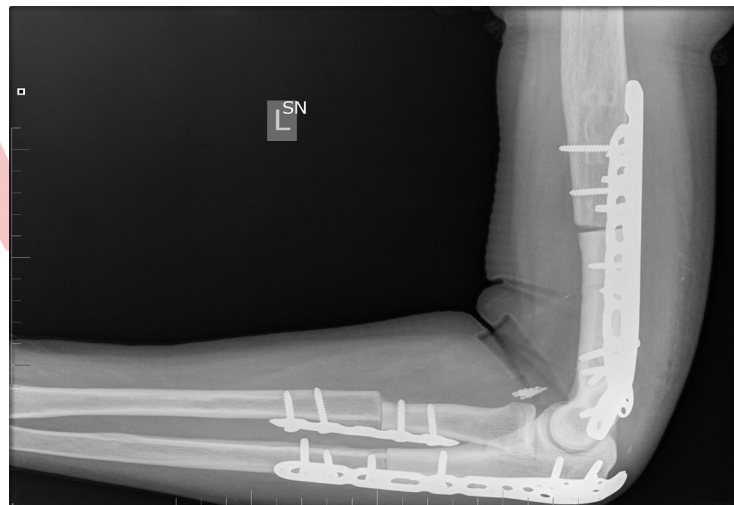
## Triceps Splitting

### Allograft

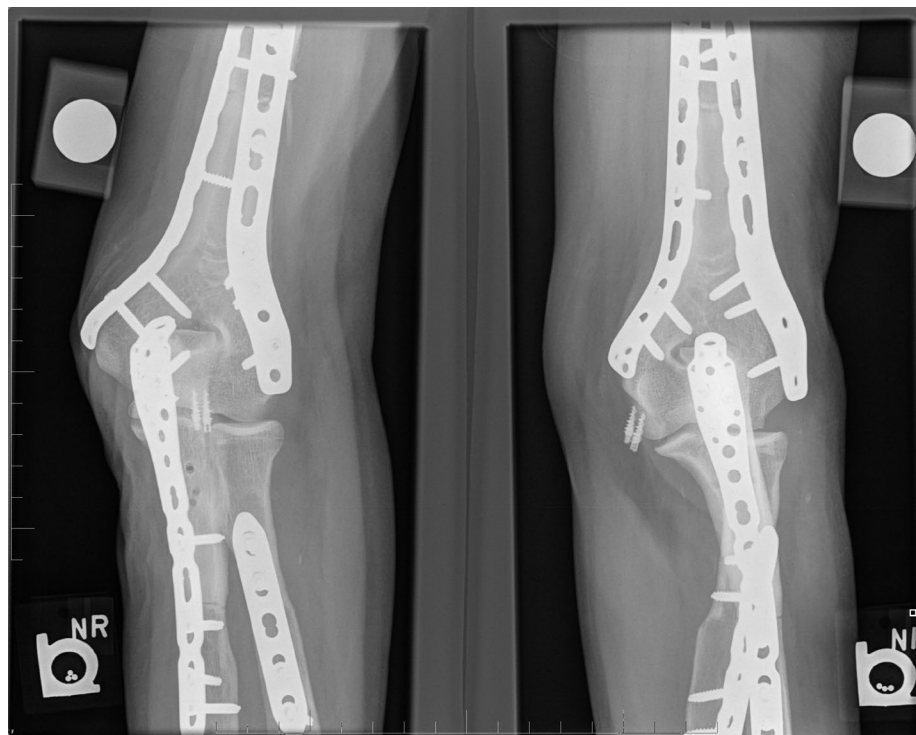
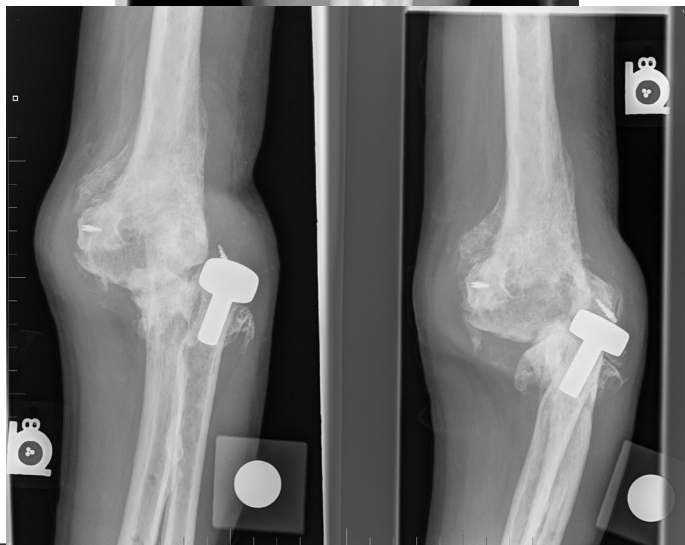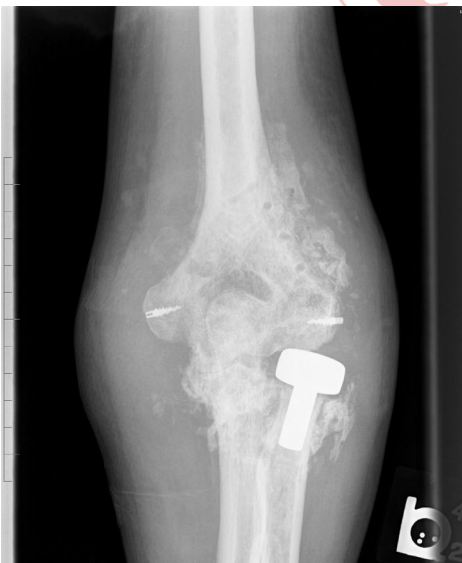# Allograft



N



1



# Examples

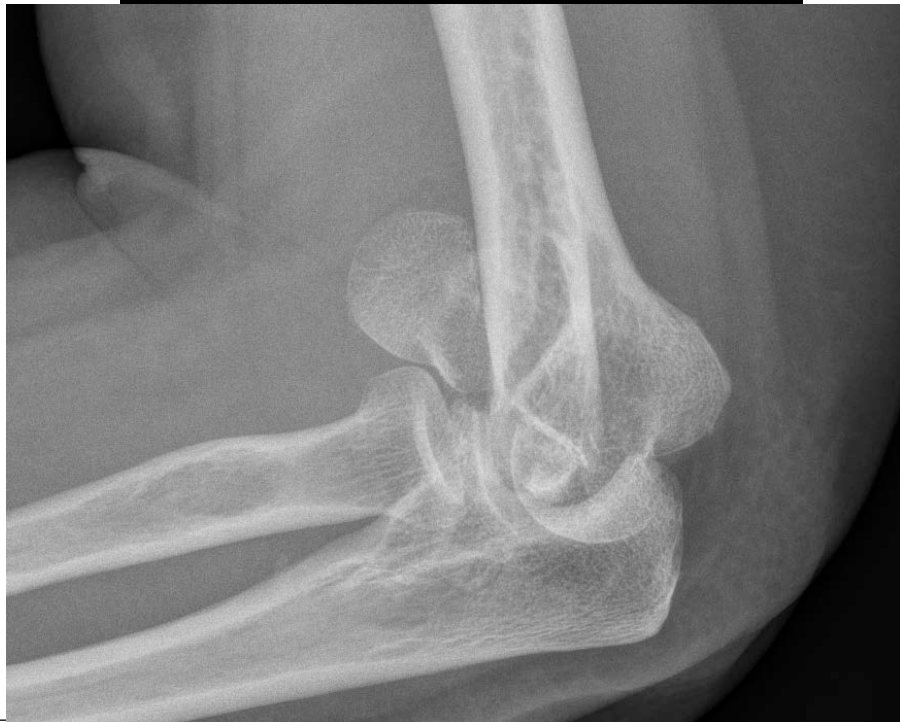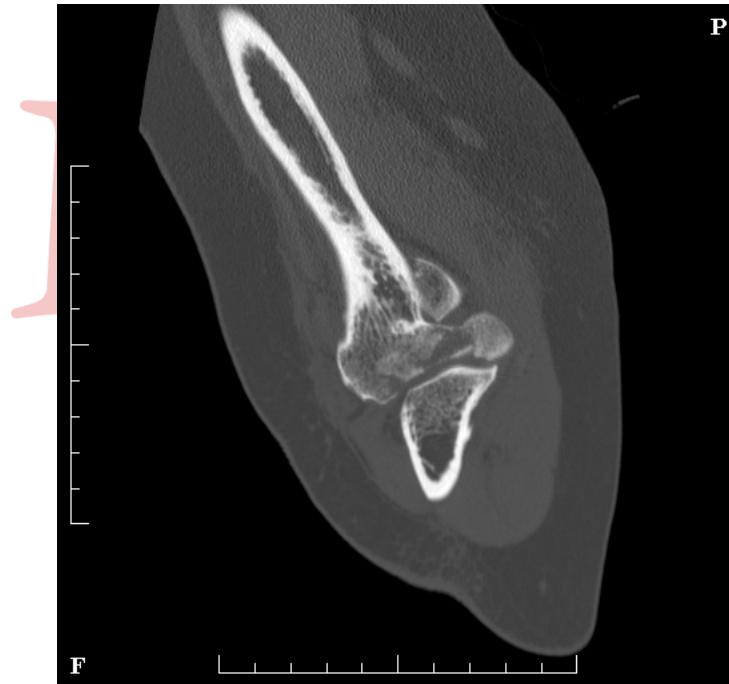
All pieces easily reducible

Some bone missing

Some cartilage missing

What cartilage

Is that an elbow?



# Examples



# M

All pieces easily reducible

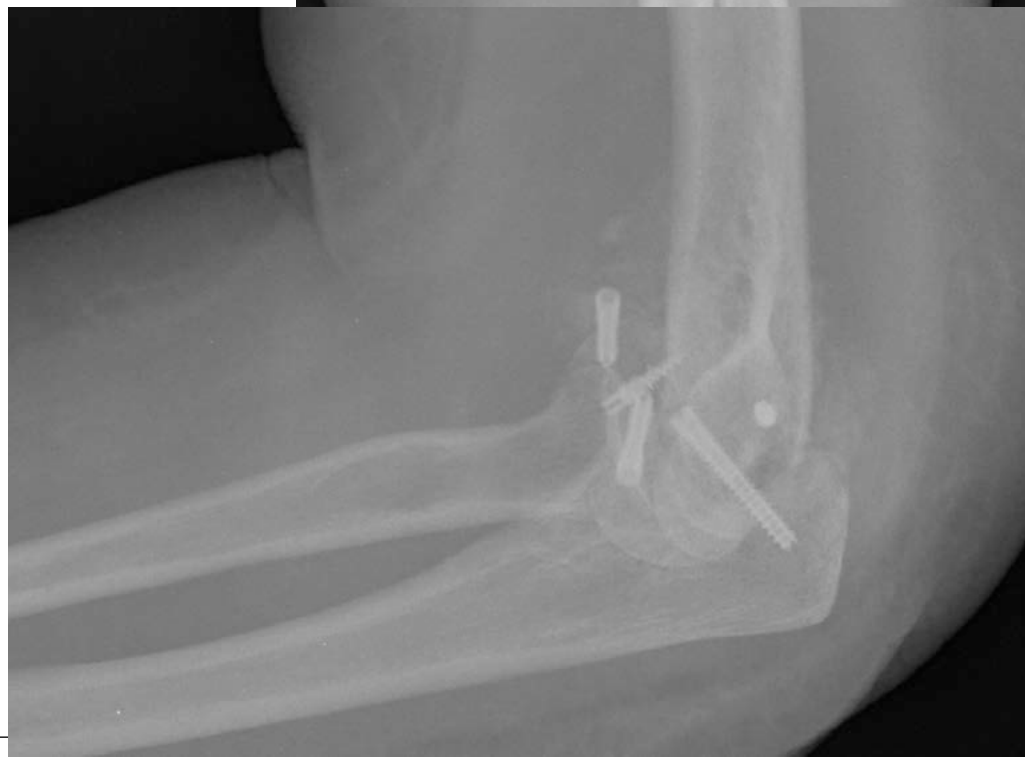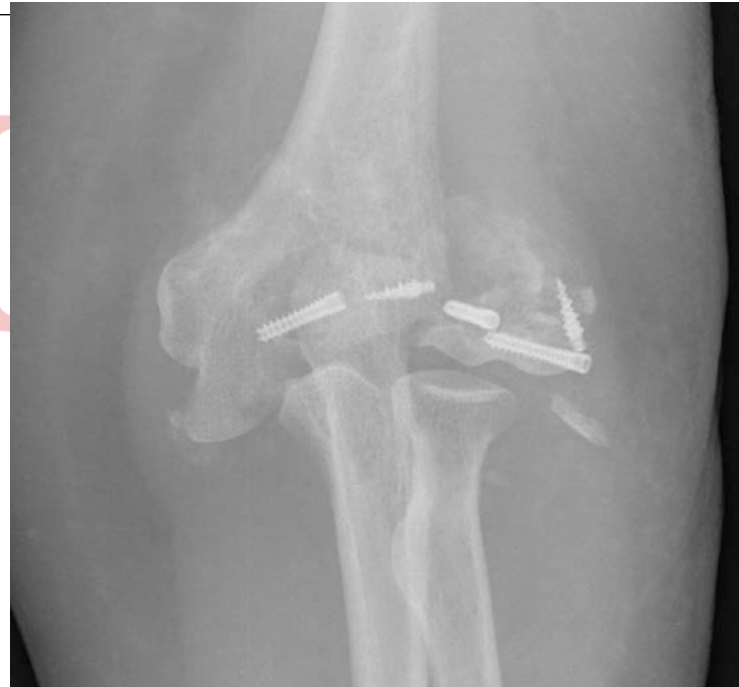Some bone missing

Some cartilage missing

What cartilage

Is that an elbow?

Somebody tried  
3 weeks old



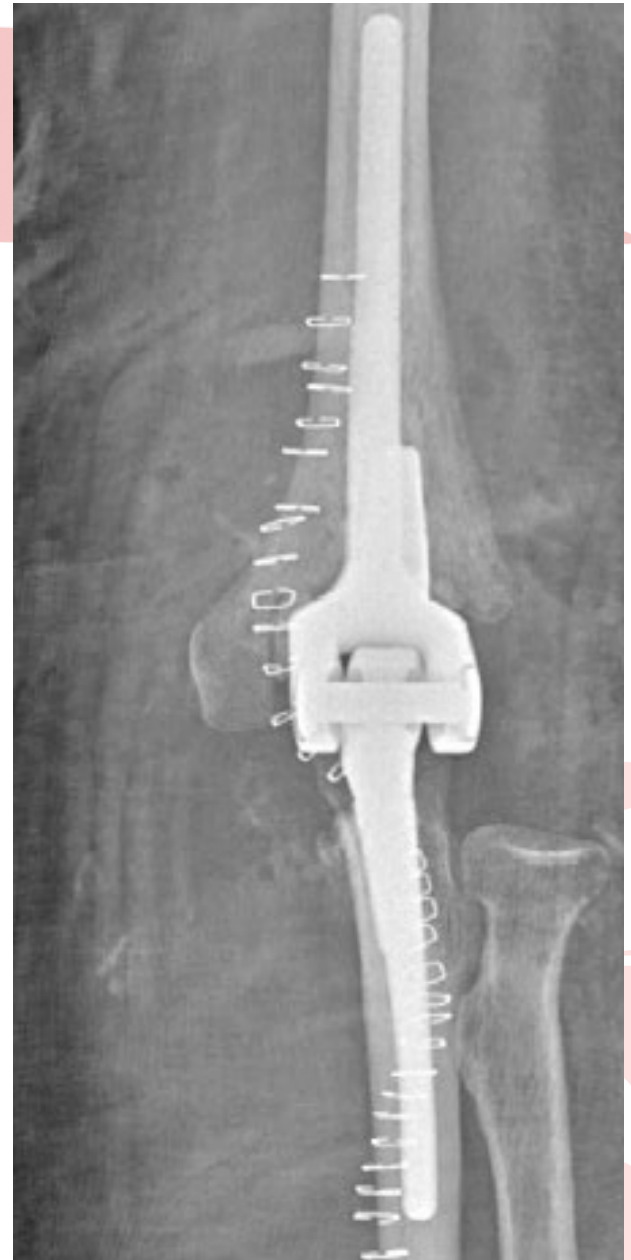




M

1

- Is there any good elbow?
- One that lasts
- One that can used under 60?



# Thanks

