

Sacroiliac Fixation:

Safely navigating the dysmorphic sacrum

Paul Toogood, MD

UCSF Department of Orthopaedic Surgery

Orthopaedic Trauma Institute

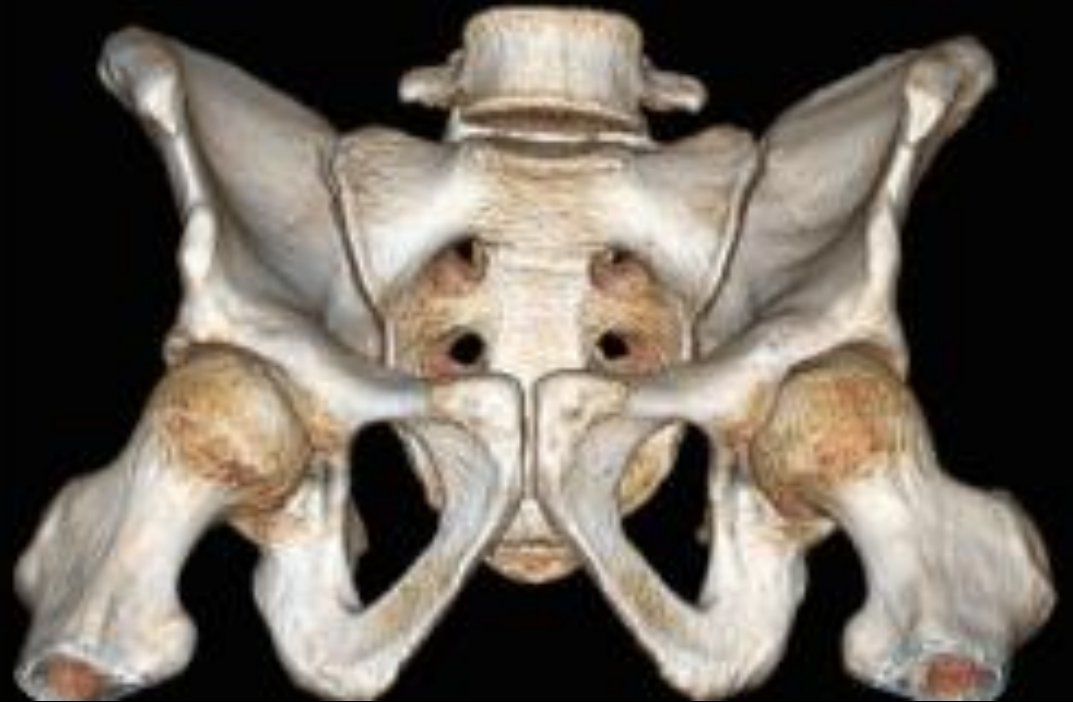San Francisco General Hospital

The Fundamentals

- | Reduced sacrum or SI joint
- | Anatomy: Normal vs Dysmorphic Sacrum
- | Fluoroscopic image interpretation
- | Pre-op Planning
 - Corridor size
 - Screw length
 - Inlet/Outlet angles

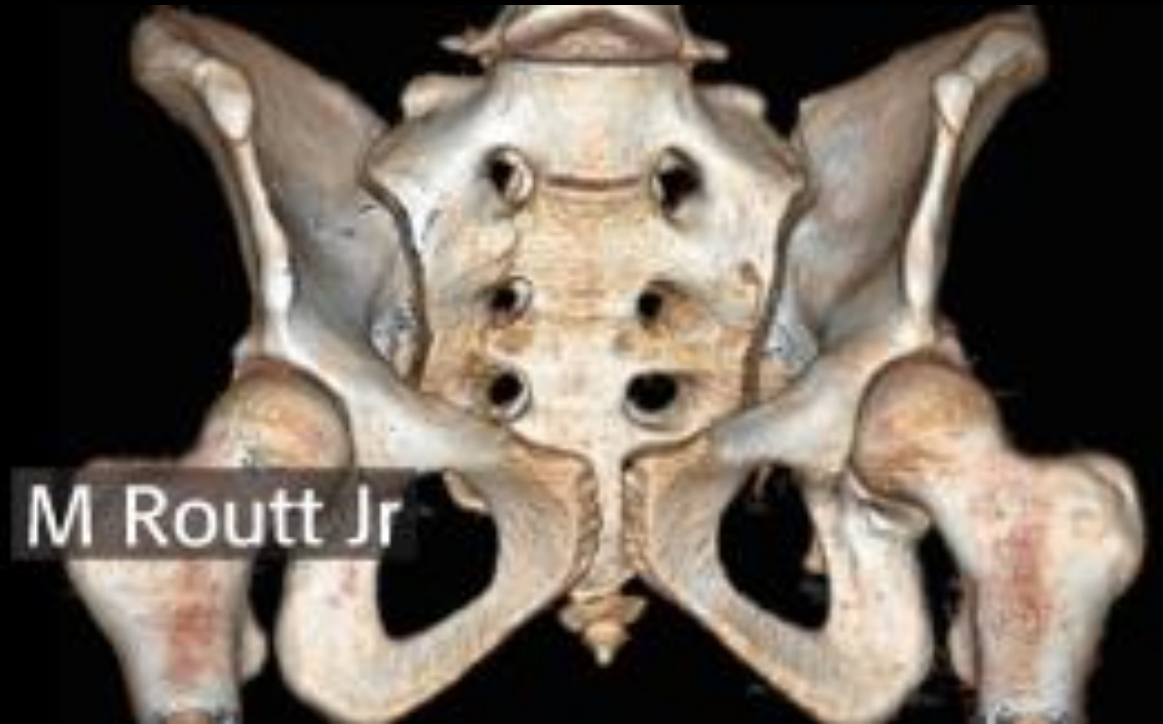Normal Sacrum

- | Sacrum is recessed into pelvis
- | No residual disc
- | S1 foramina are round
- | S1 between posterior ilium/SI joints

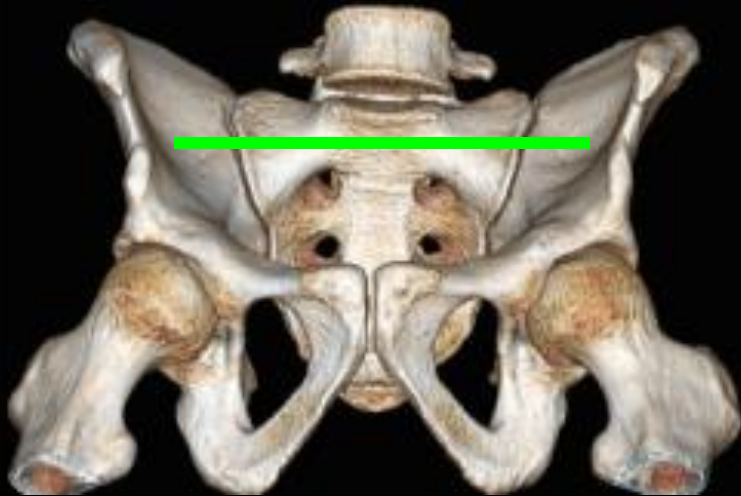


Dysmorphic Sacrum

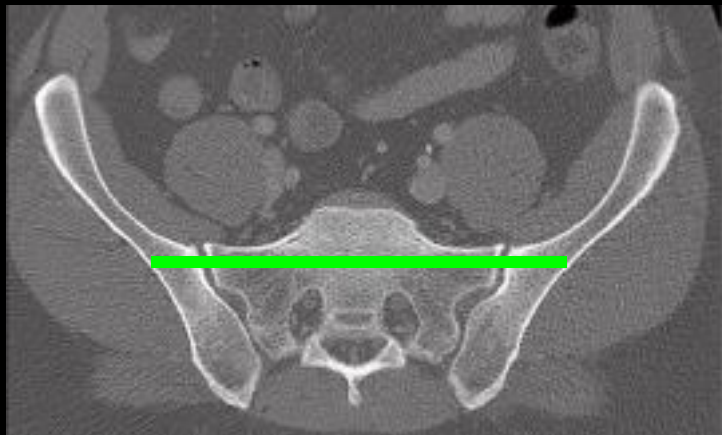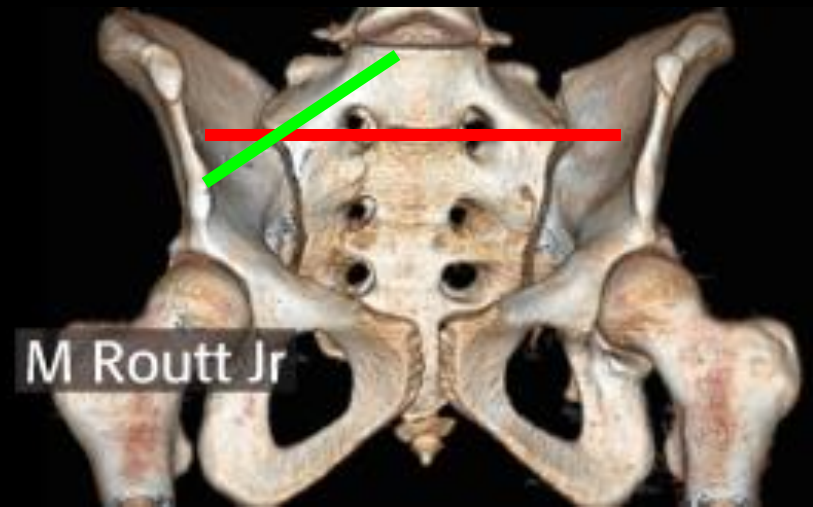
- Top of sacrum co-linear with tops of ilium
- Residual disc between S1/S2
- S1 foramina are oval
- Mamillary processes
- S1 NOT between posterior ilium/SI joints
 - Sacral Ala sloped
 - S1 positioned forward and cephalad



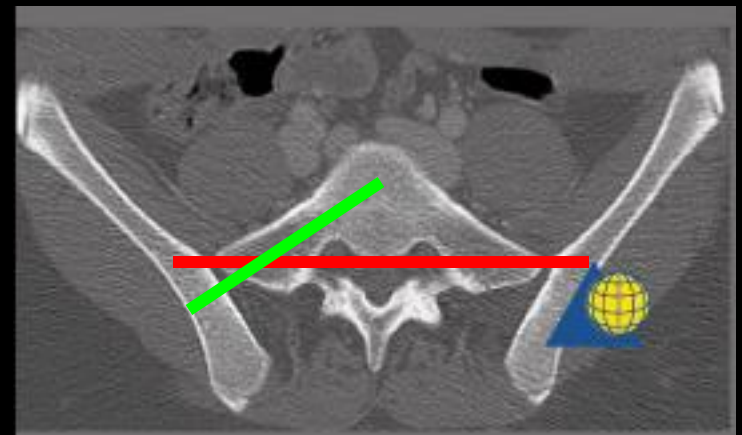
NORMAL



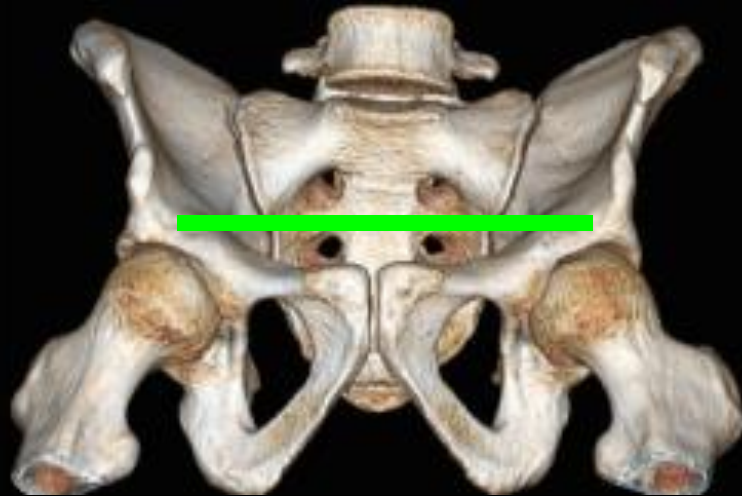DYSMORPHIC



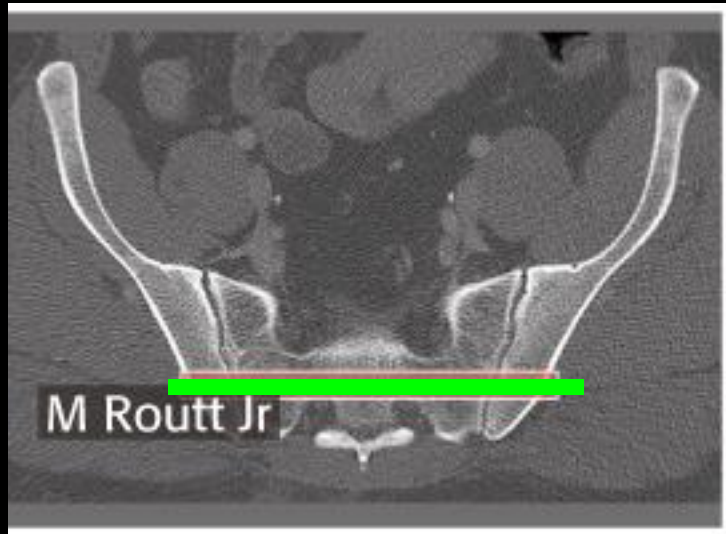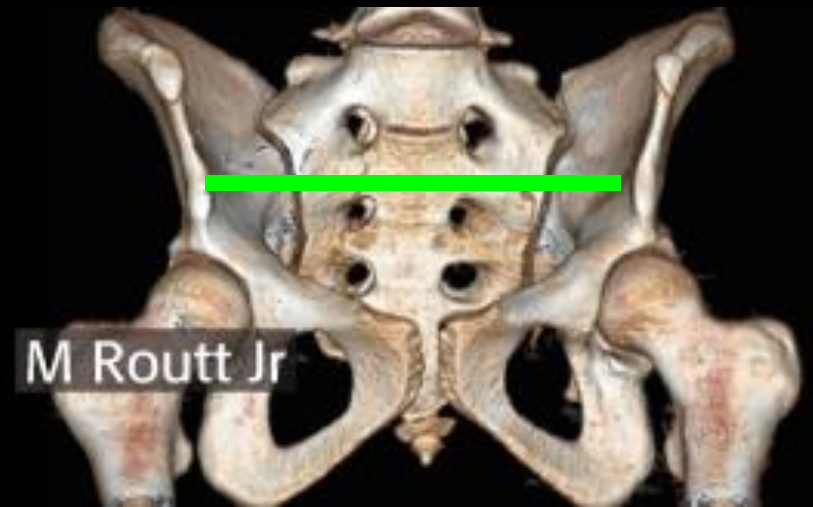
S1



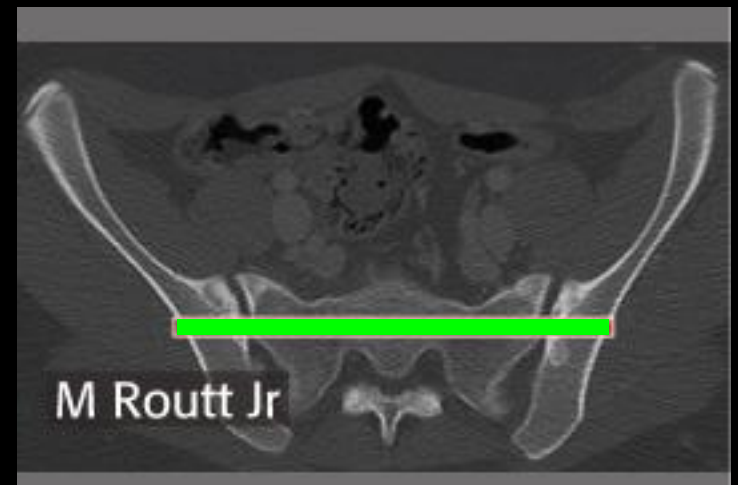NORMAL

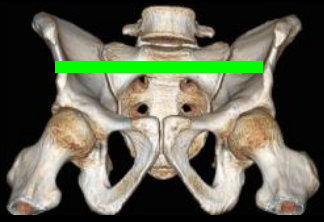

DYSMORPHIC

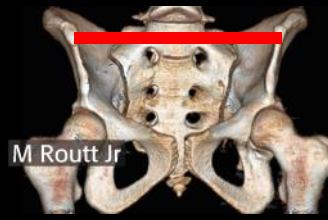


S2

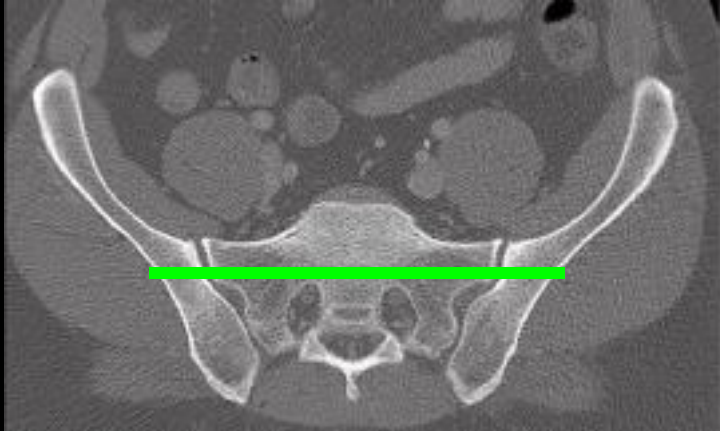




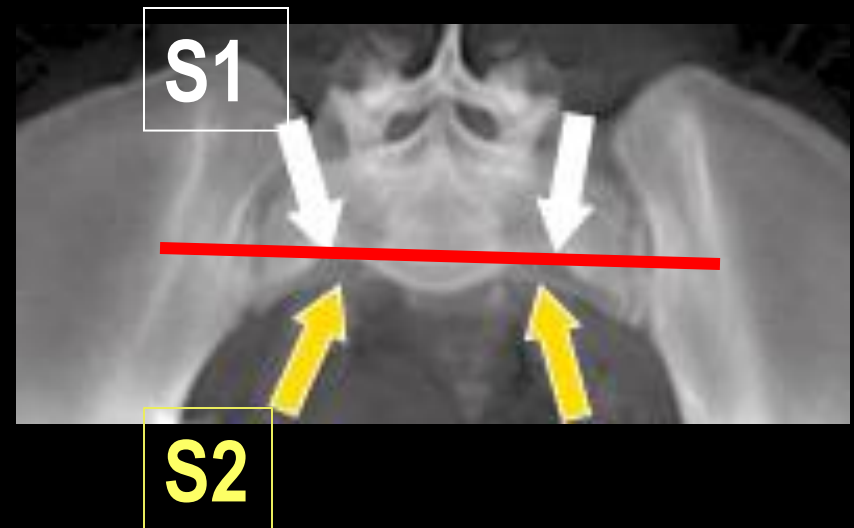
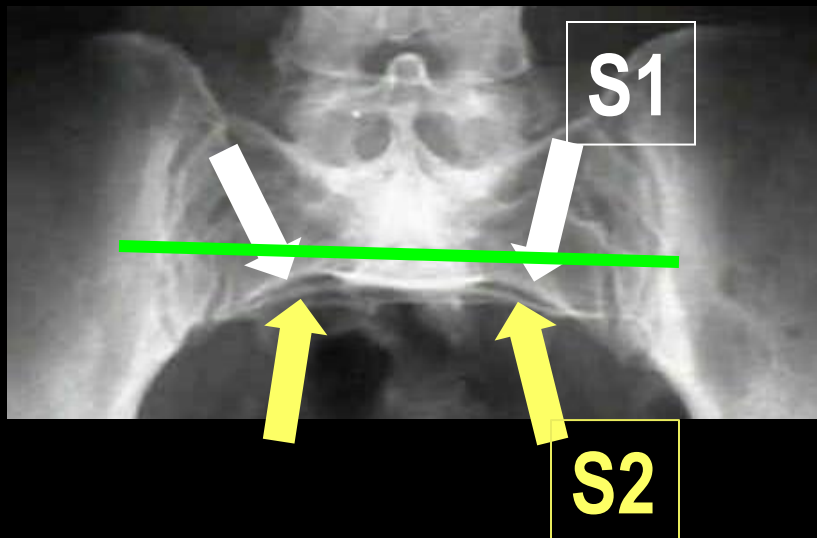
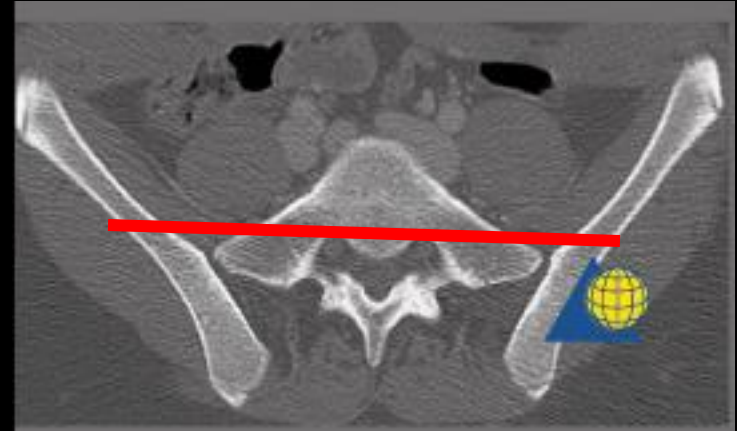
NORMAL

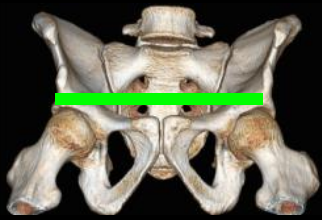

DYSMORPHIC

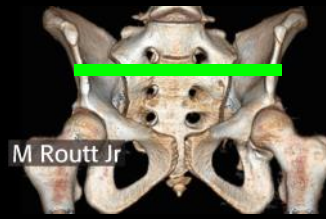


S1

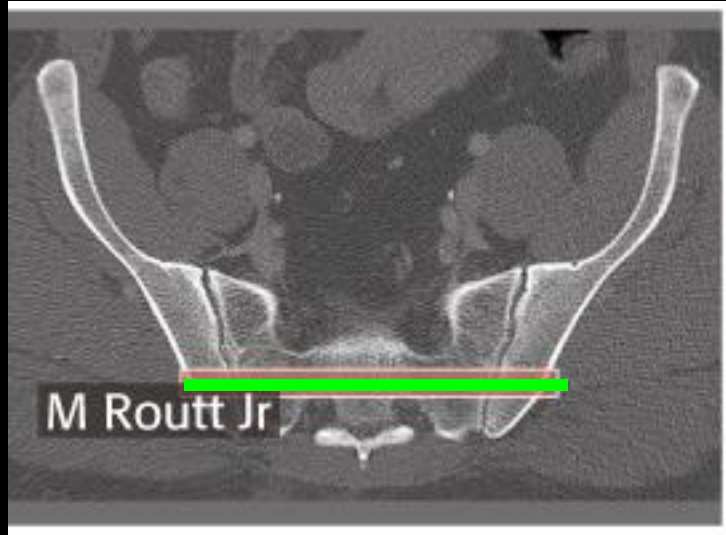




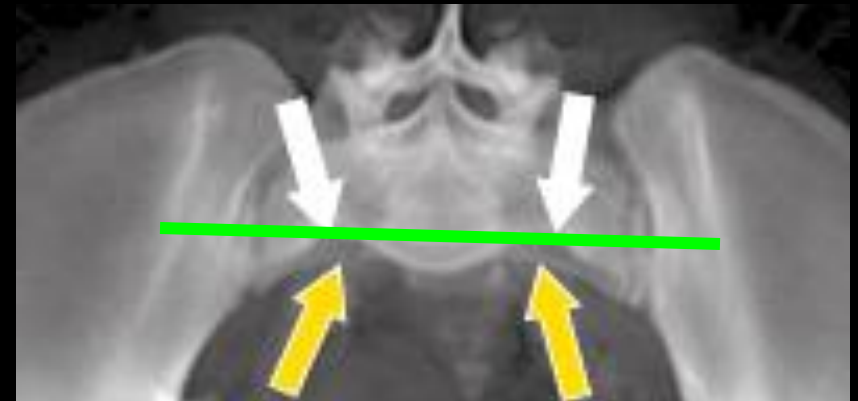
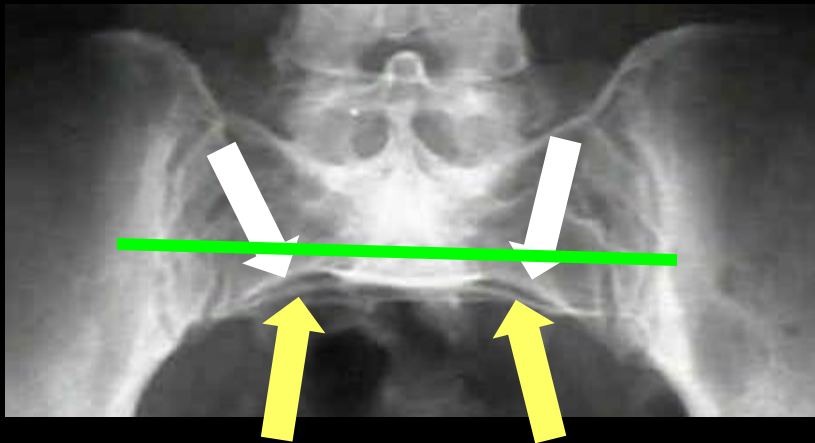
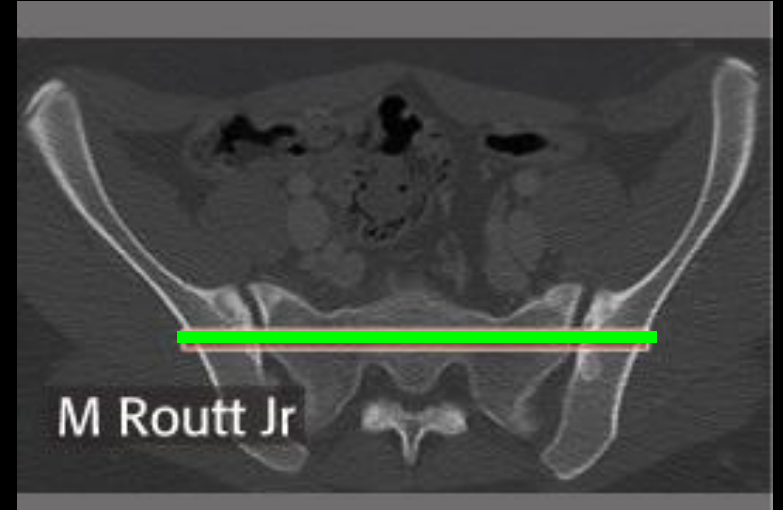NORMAL

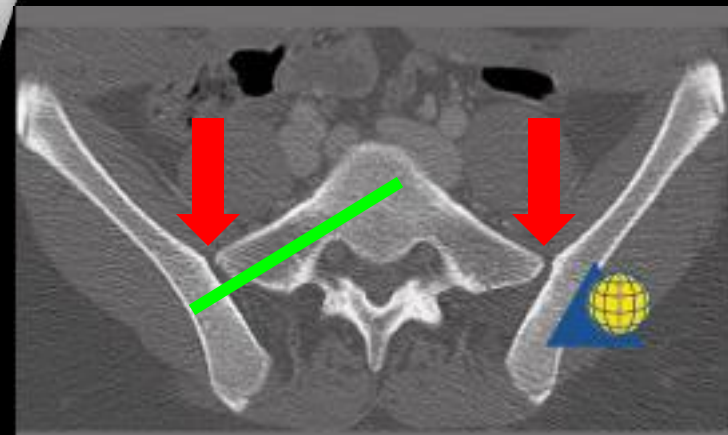
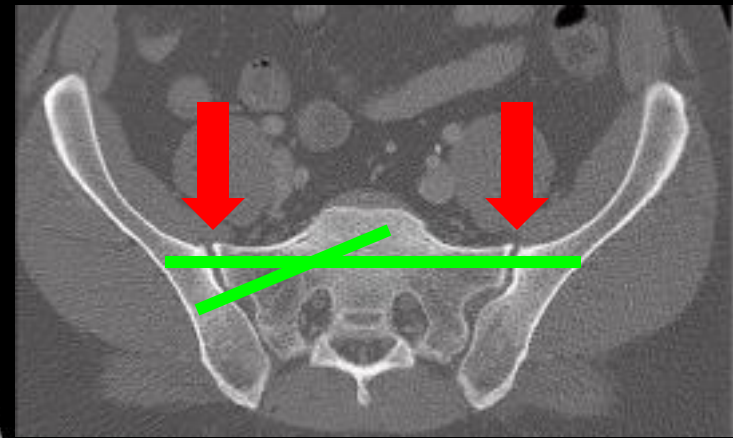
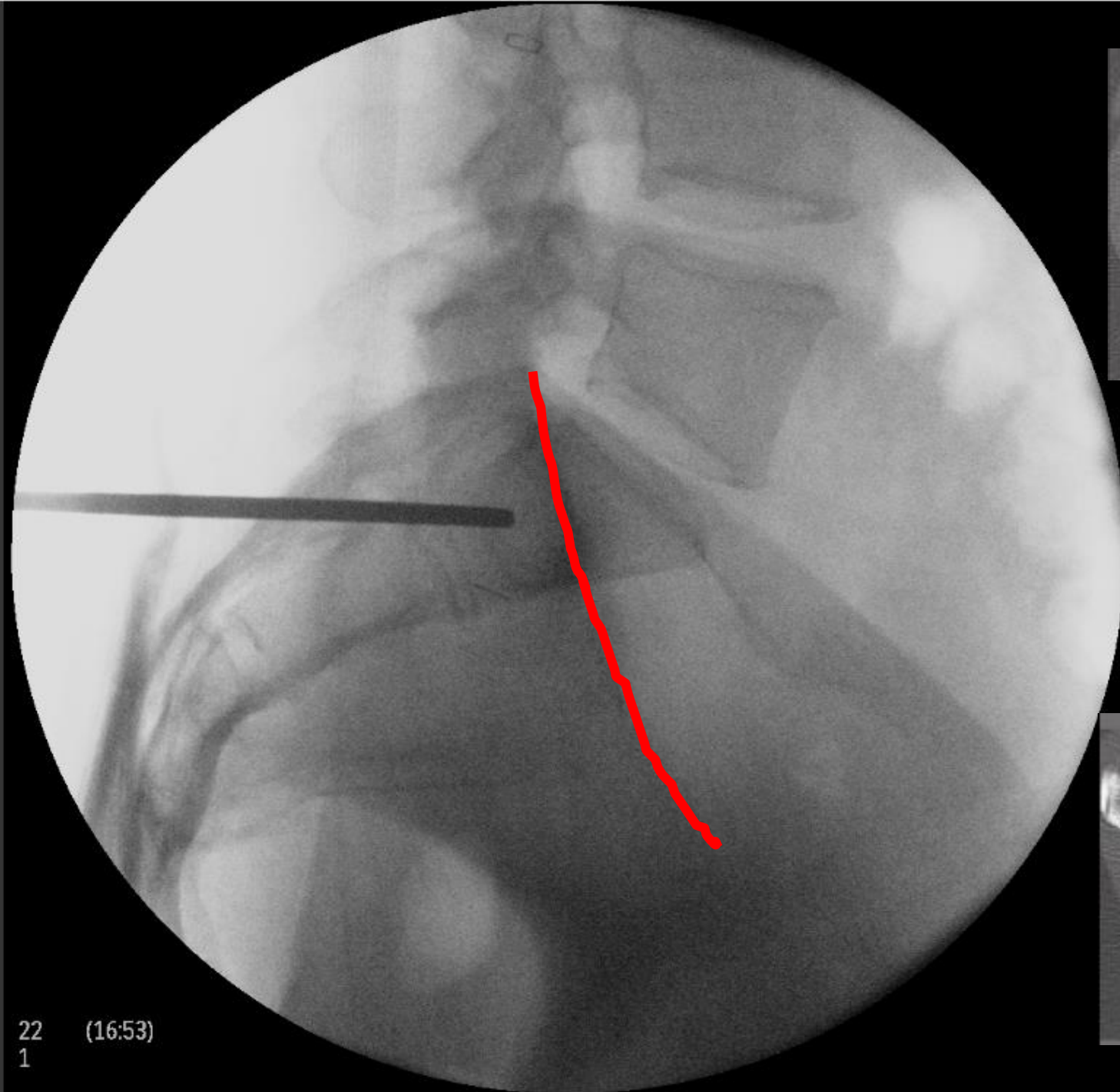


DYSMORPHIC

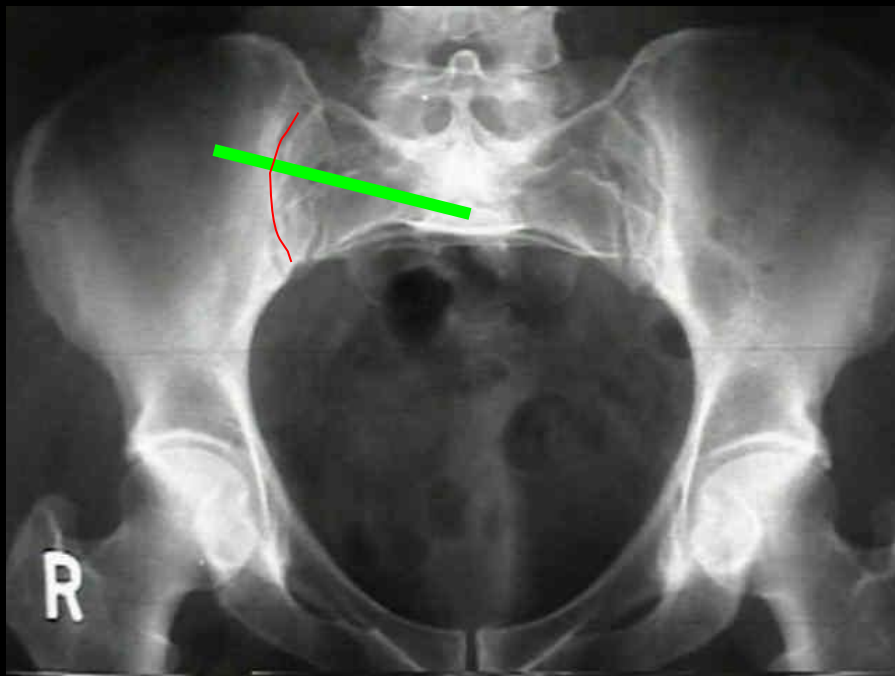


S2

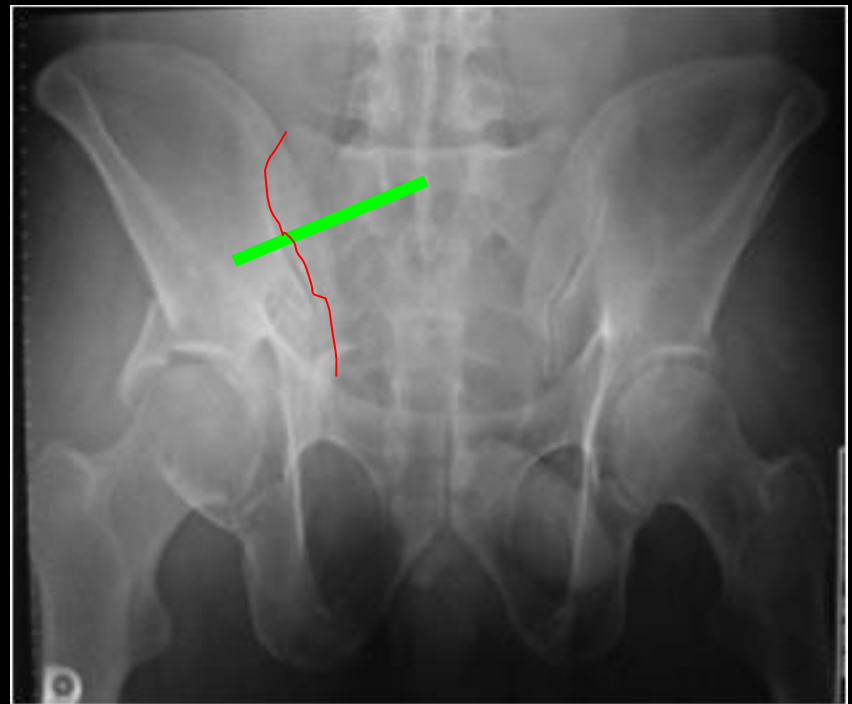




Screw Trajectory: SI joint Injury

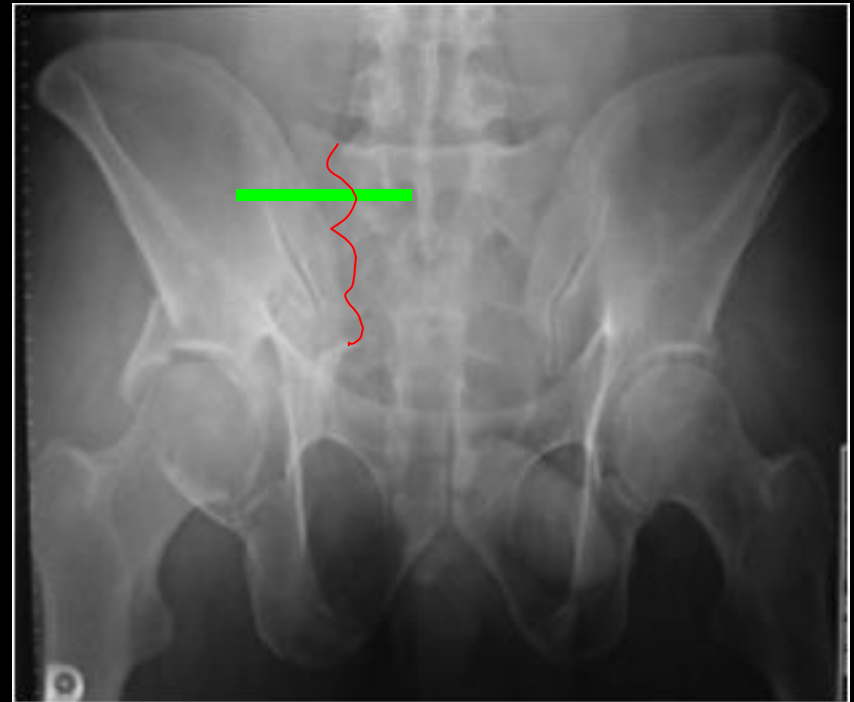
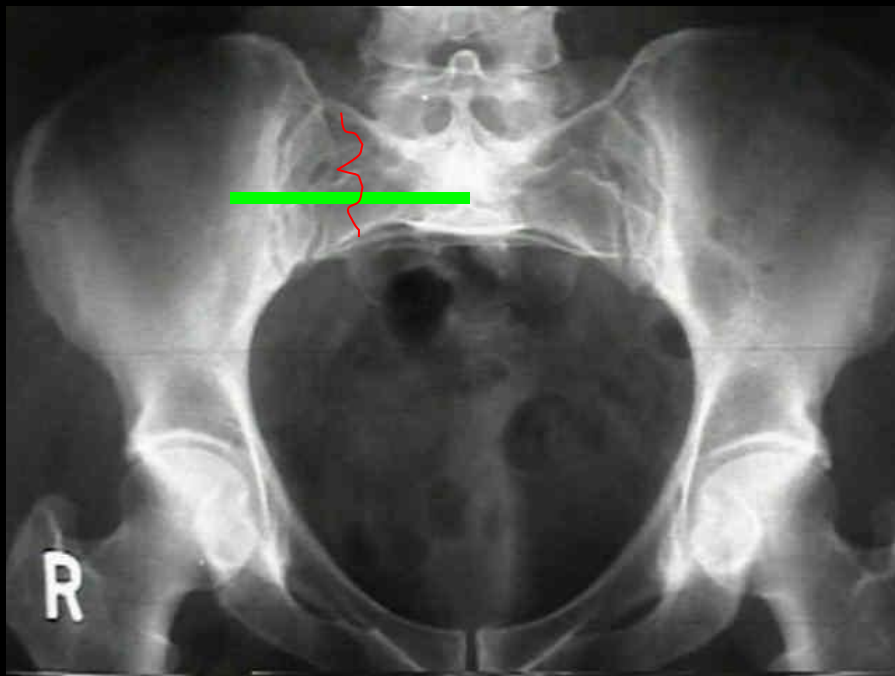


Inlet

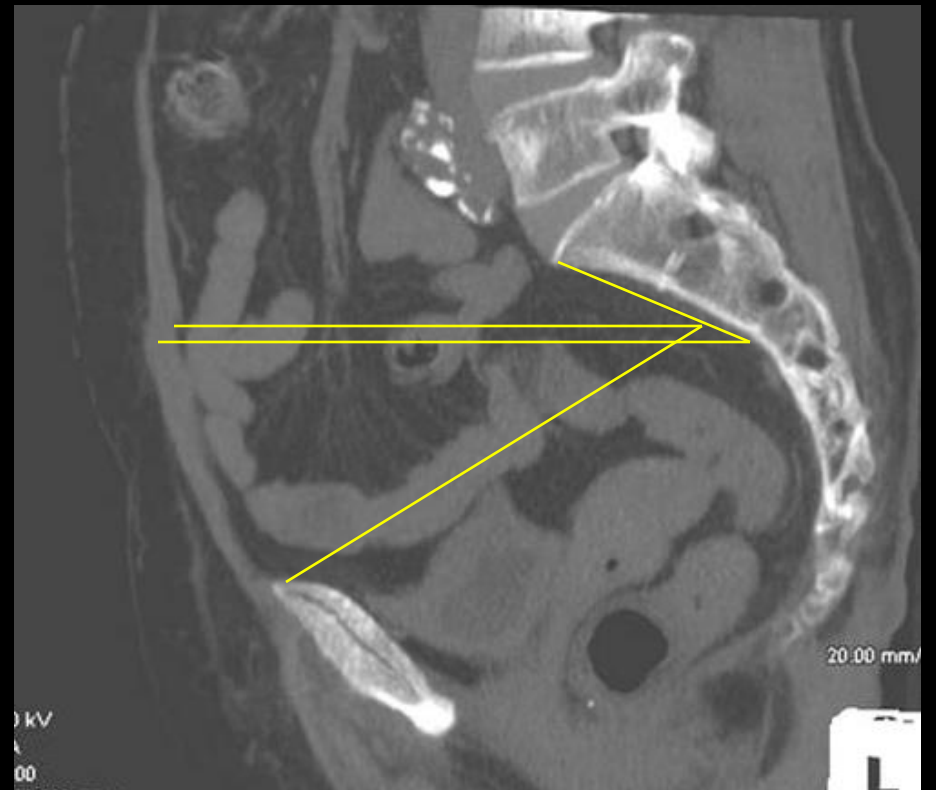
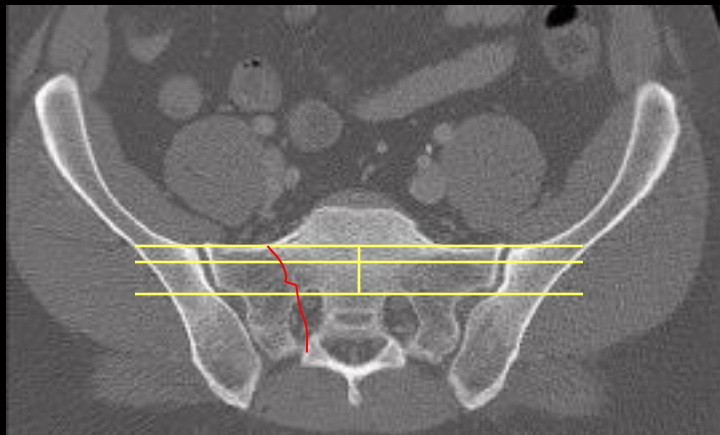
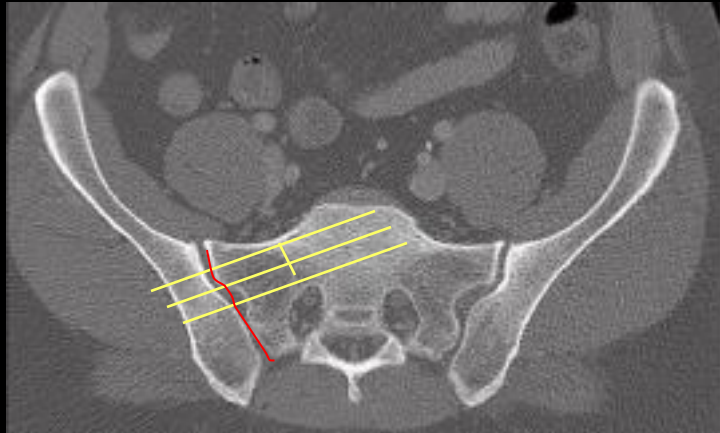


Outlet

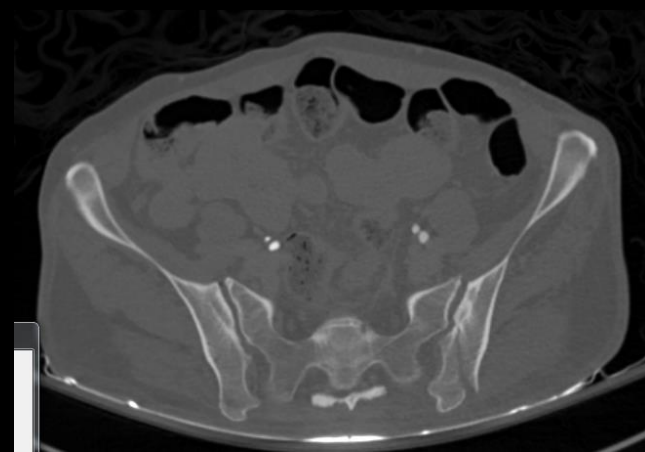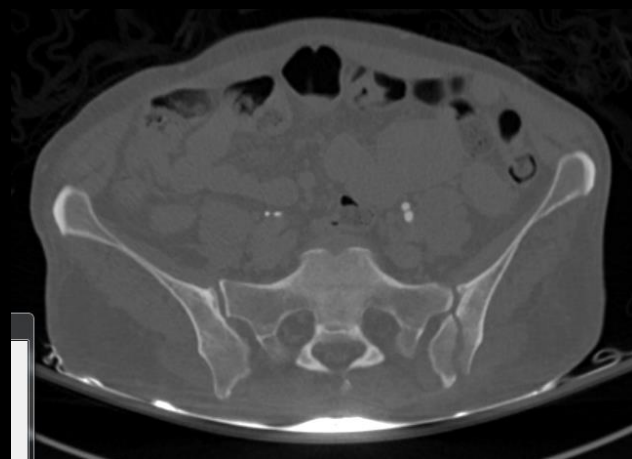
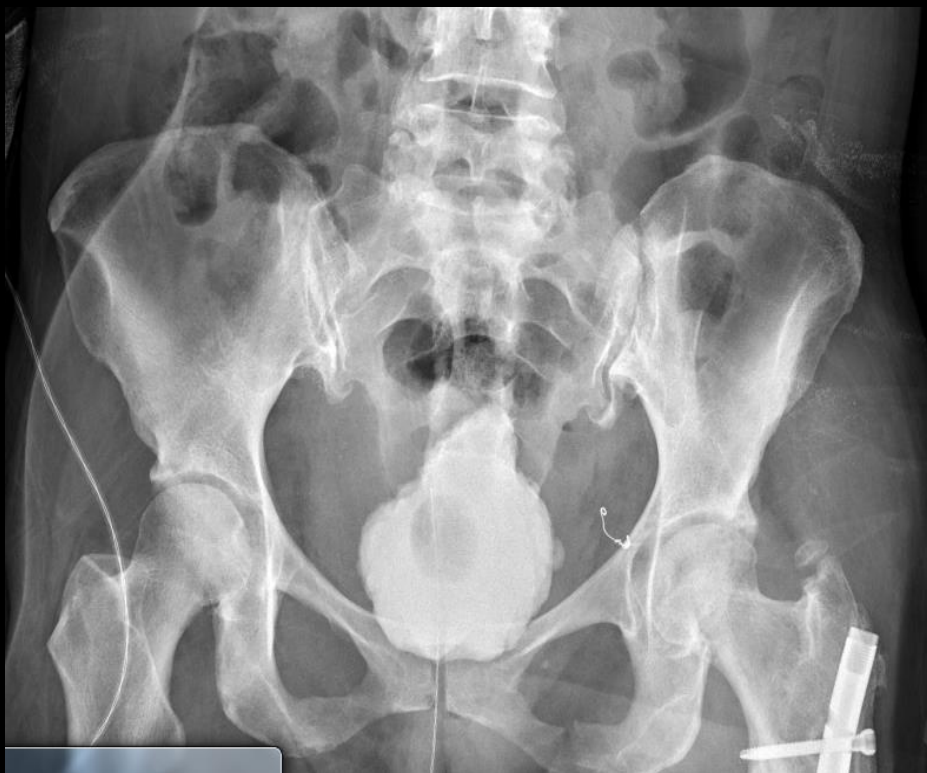Screw Trajectory: Sacral Fracture



Pre-Op Planning



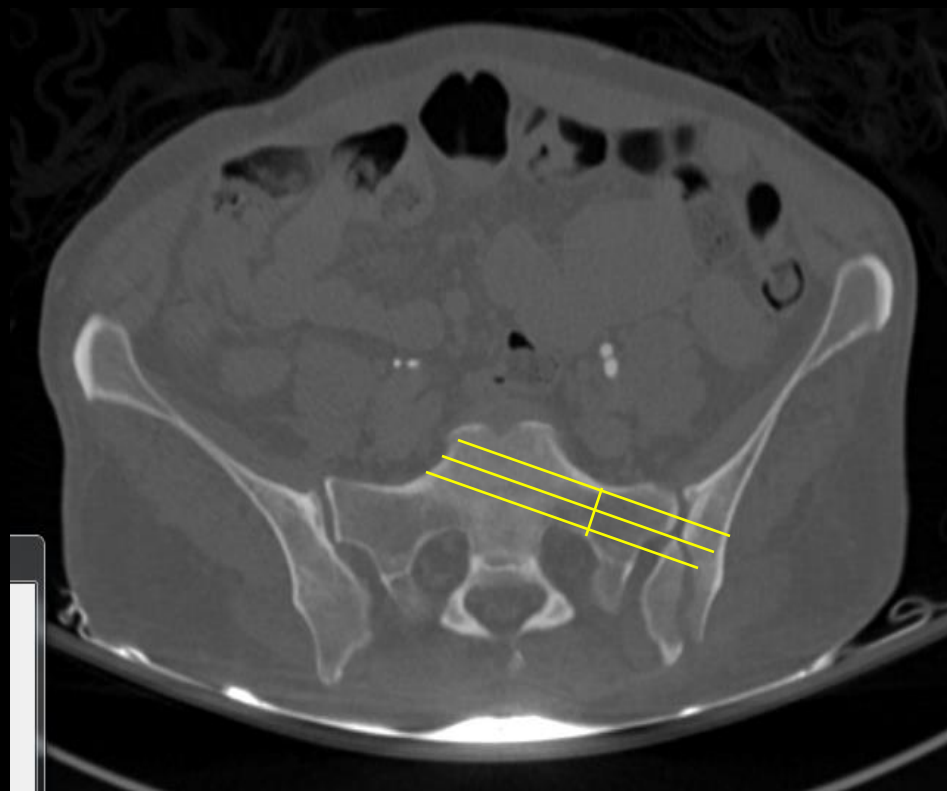
Case



Case

19mm

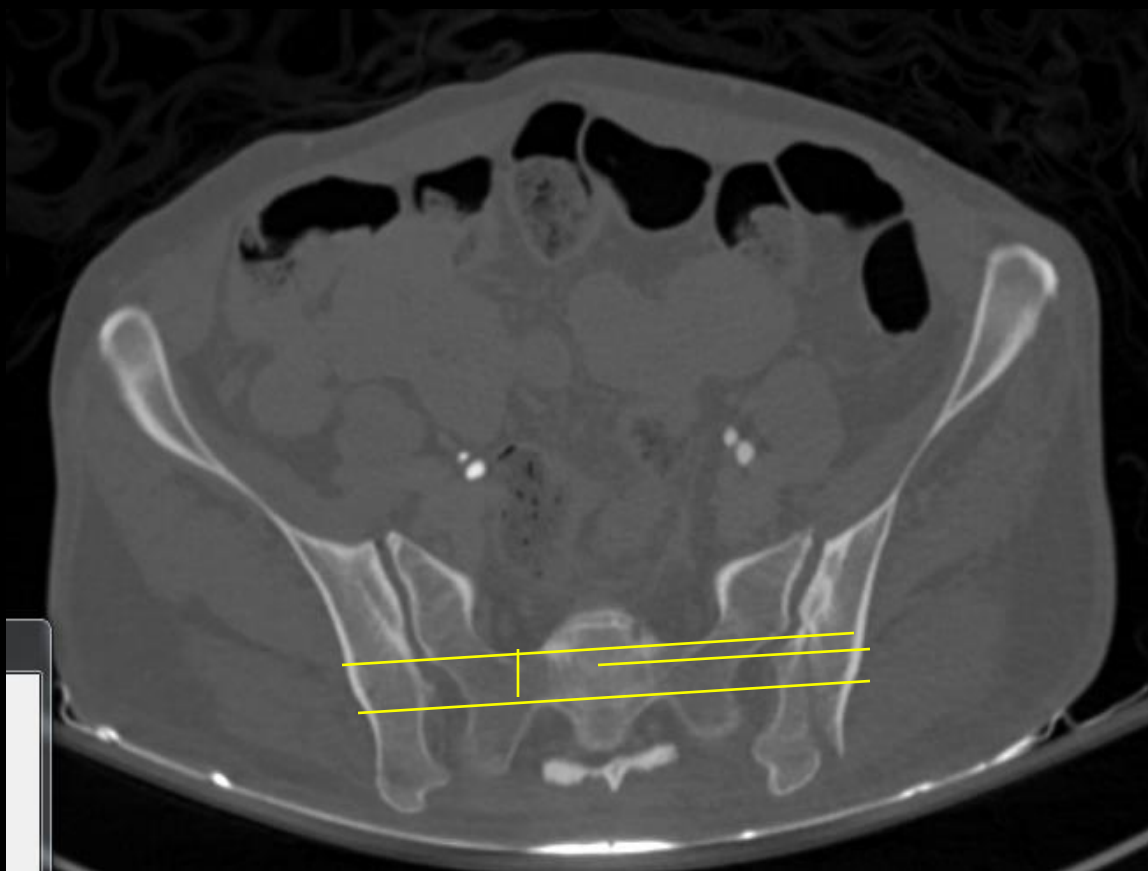85mm



Case

13mm

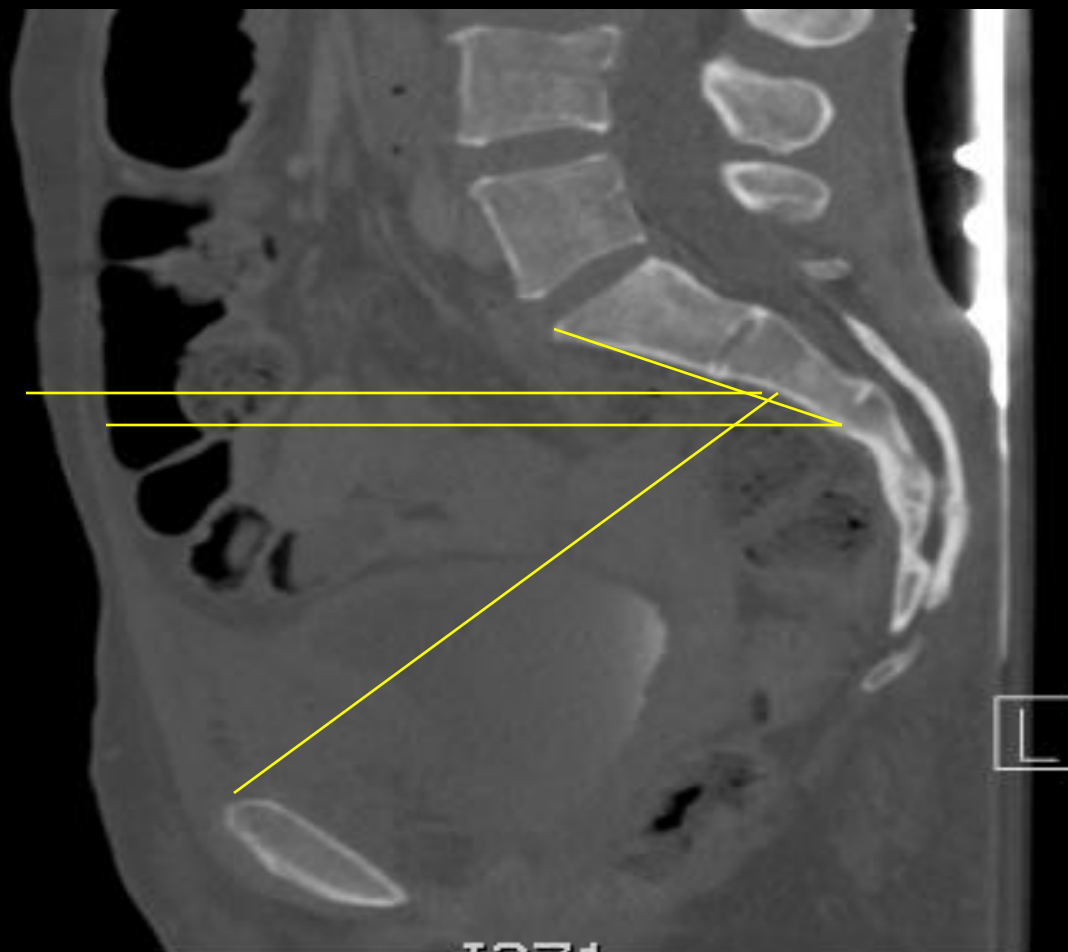
95mm



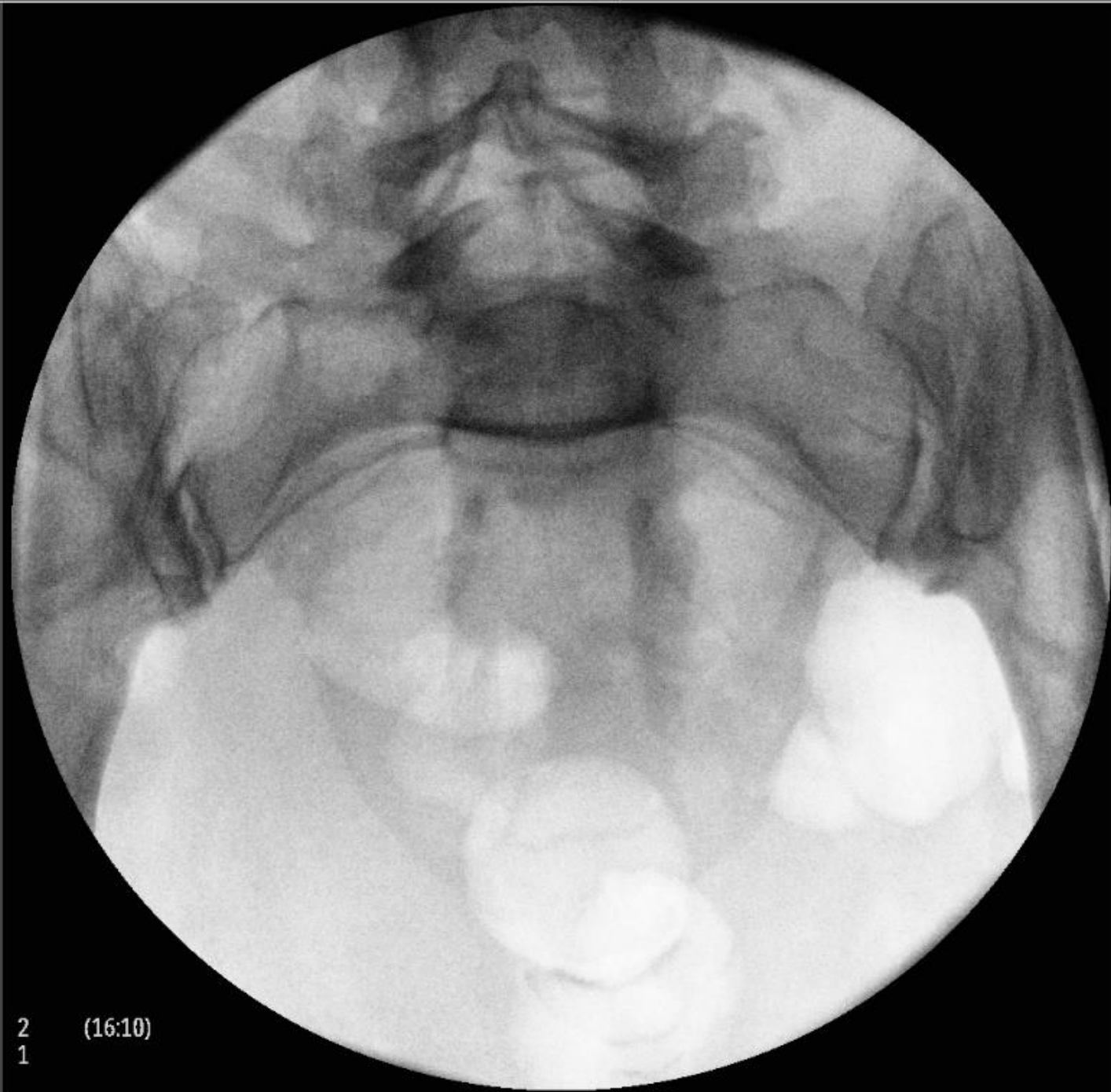
Case

INLET: 10

OUTLET: 40

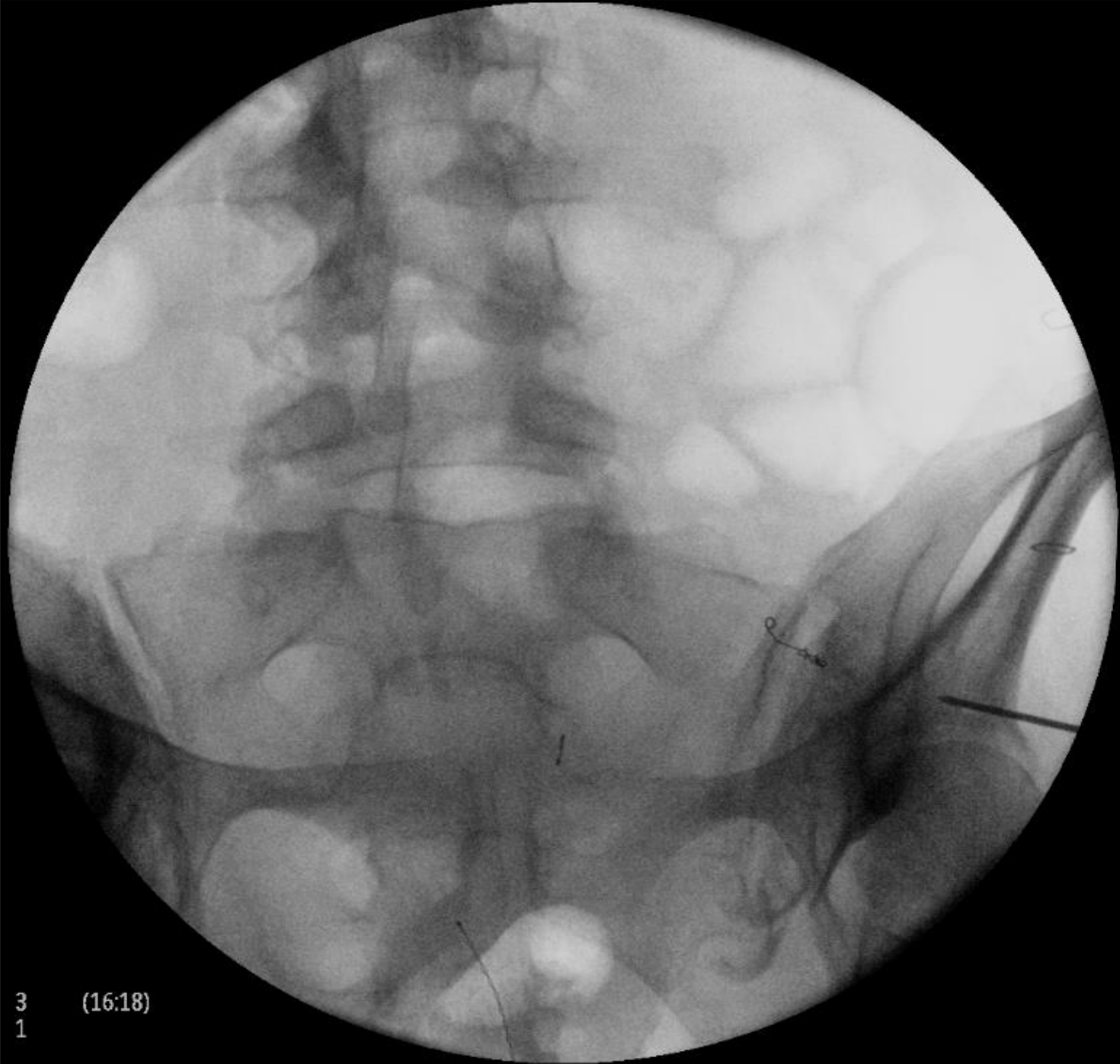


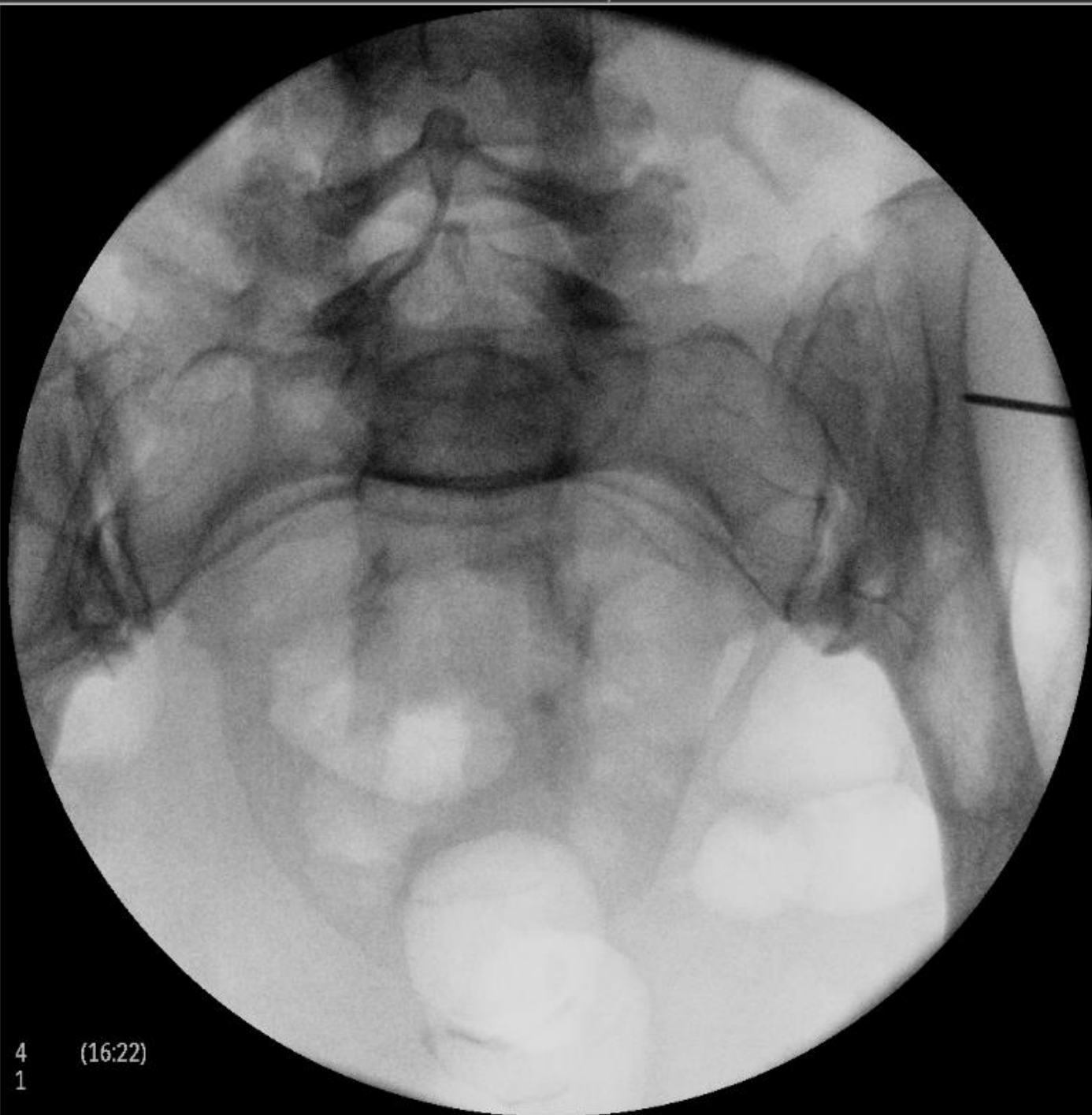
I371

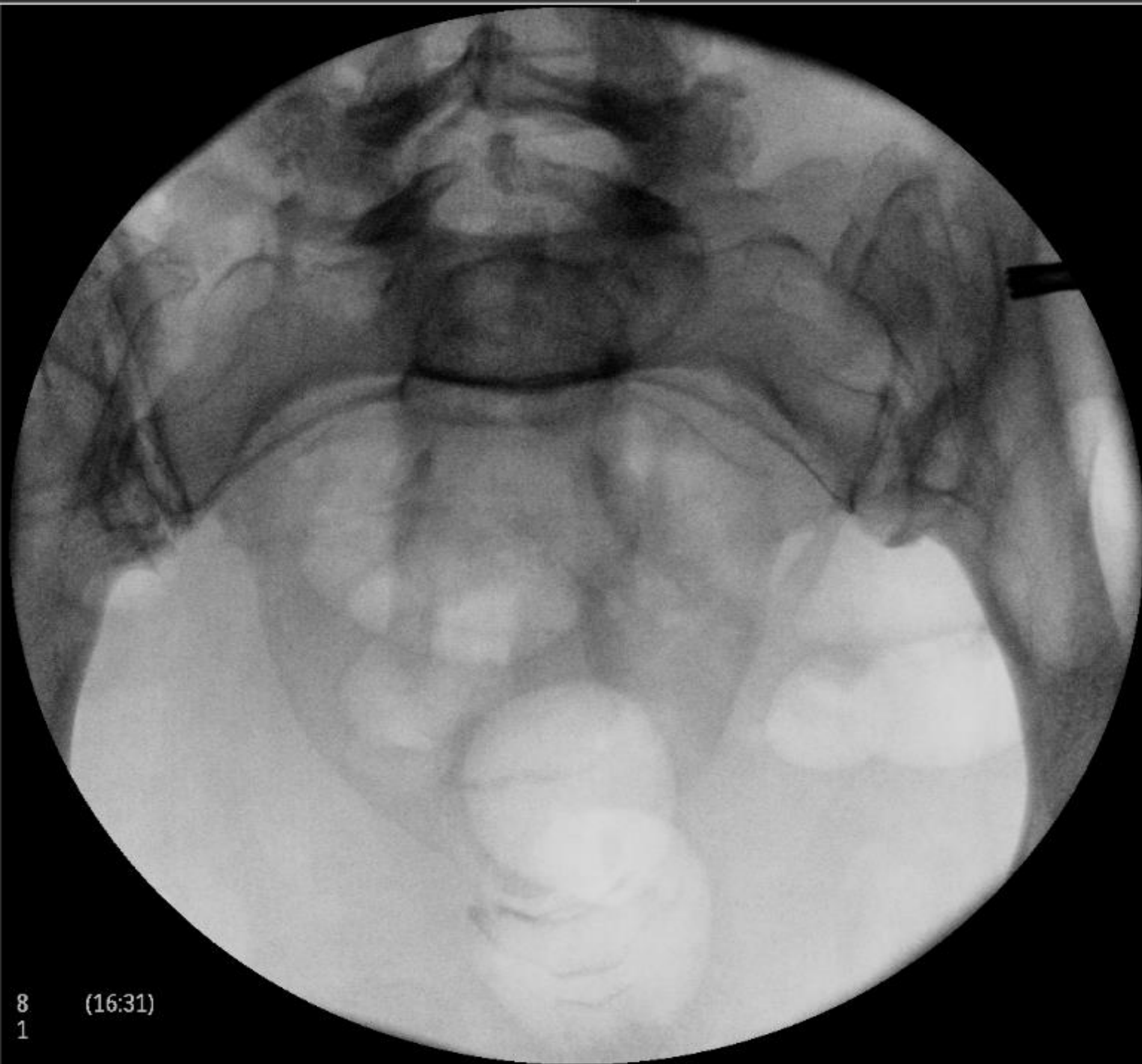


2
1

(16:10)

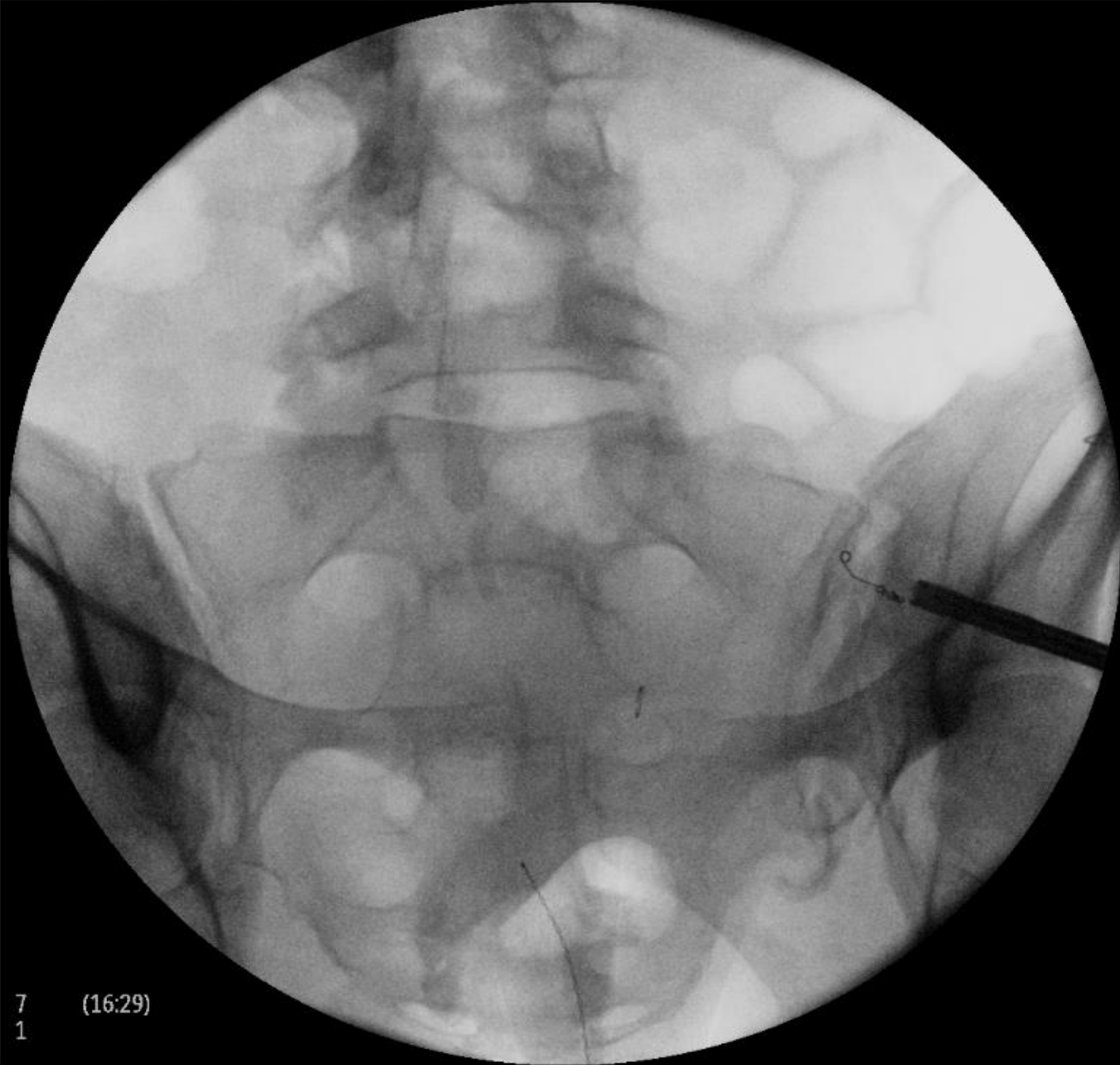





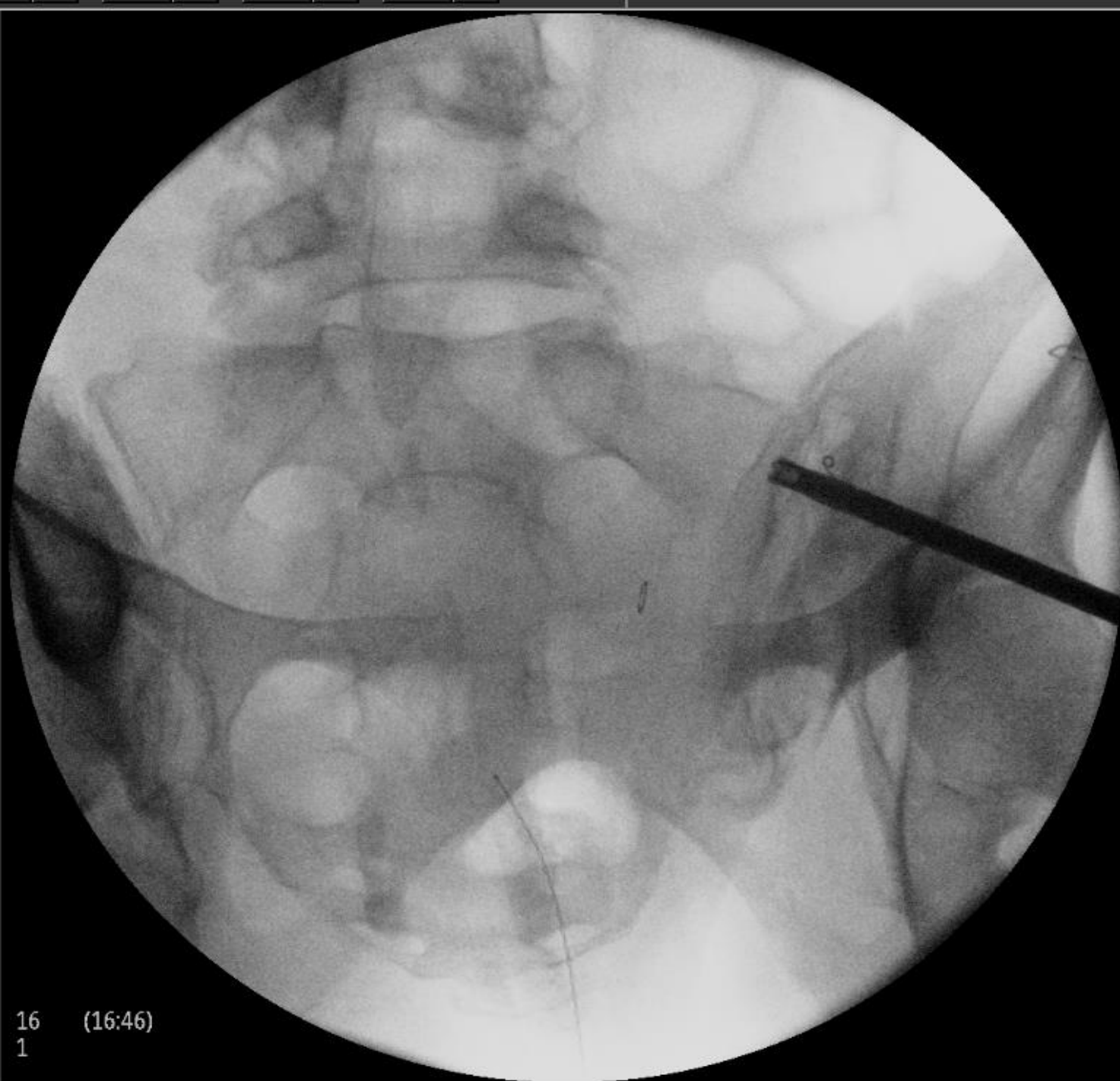8
1

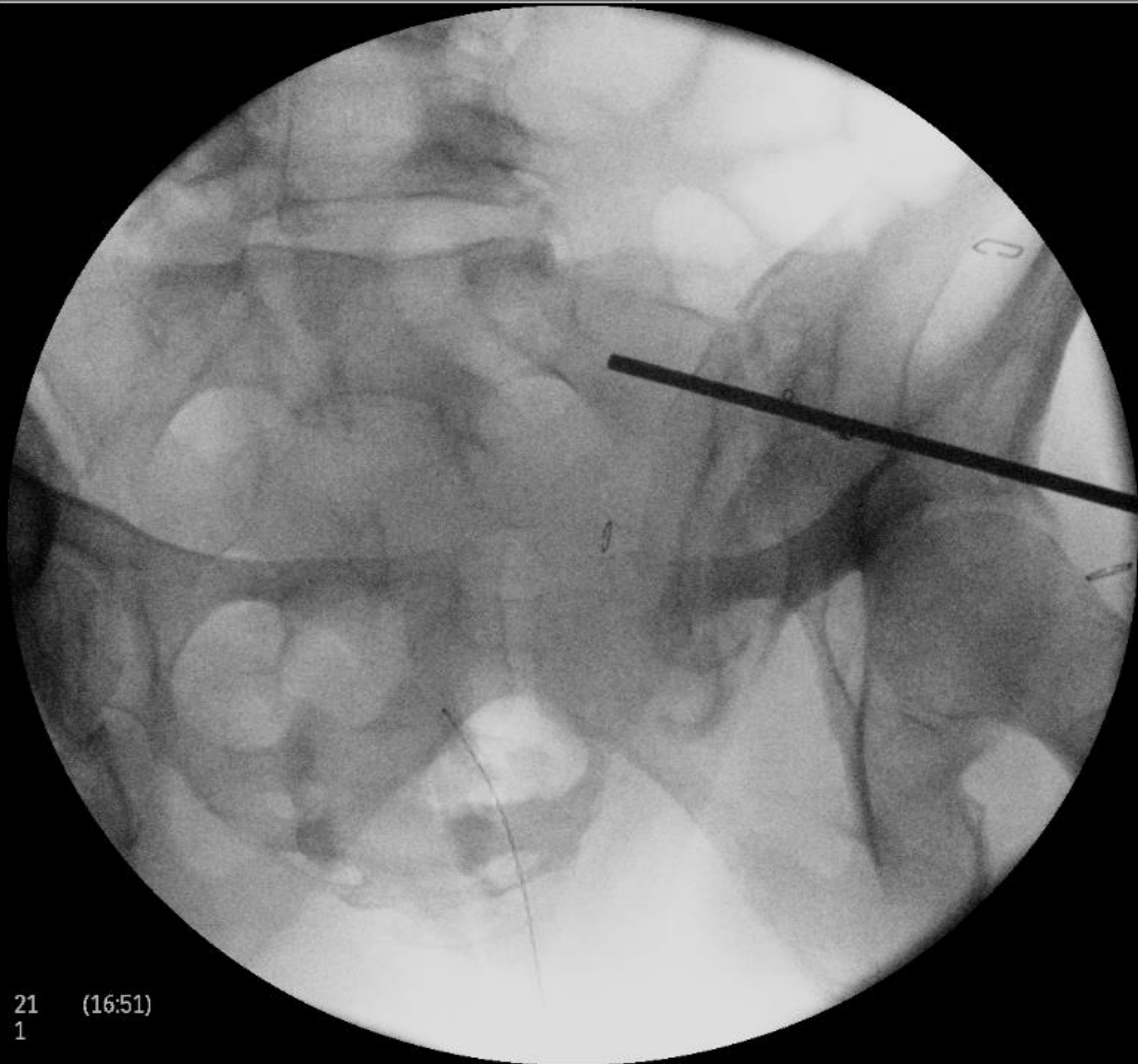
(16:31)

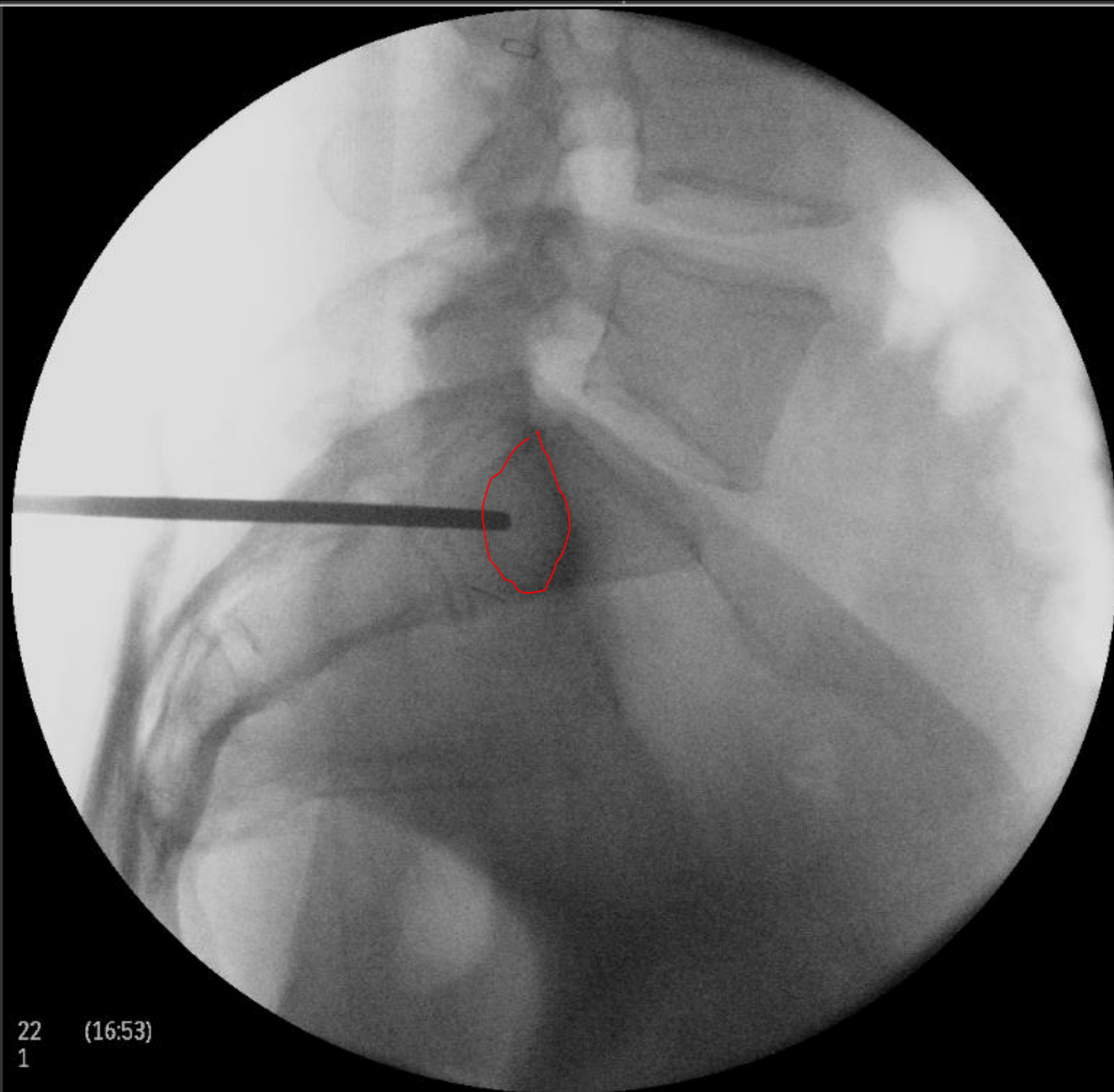


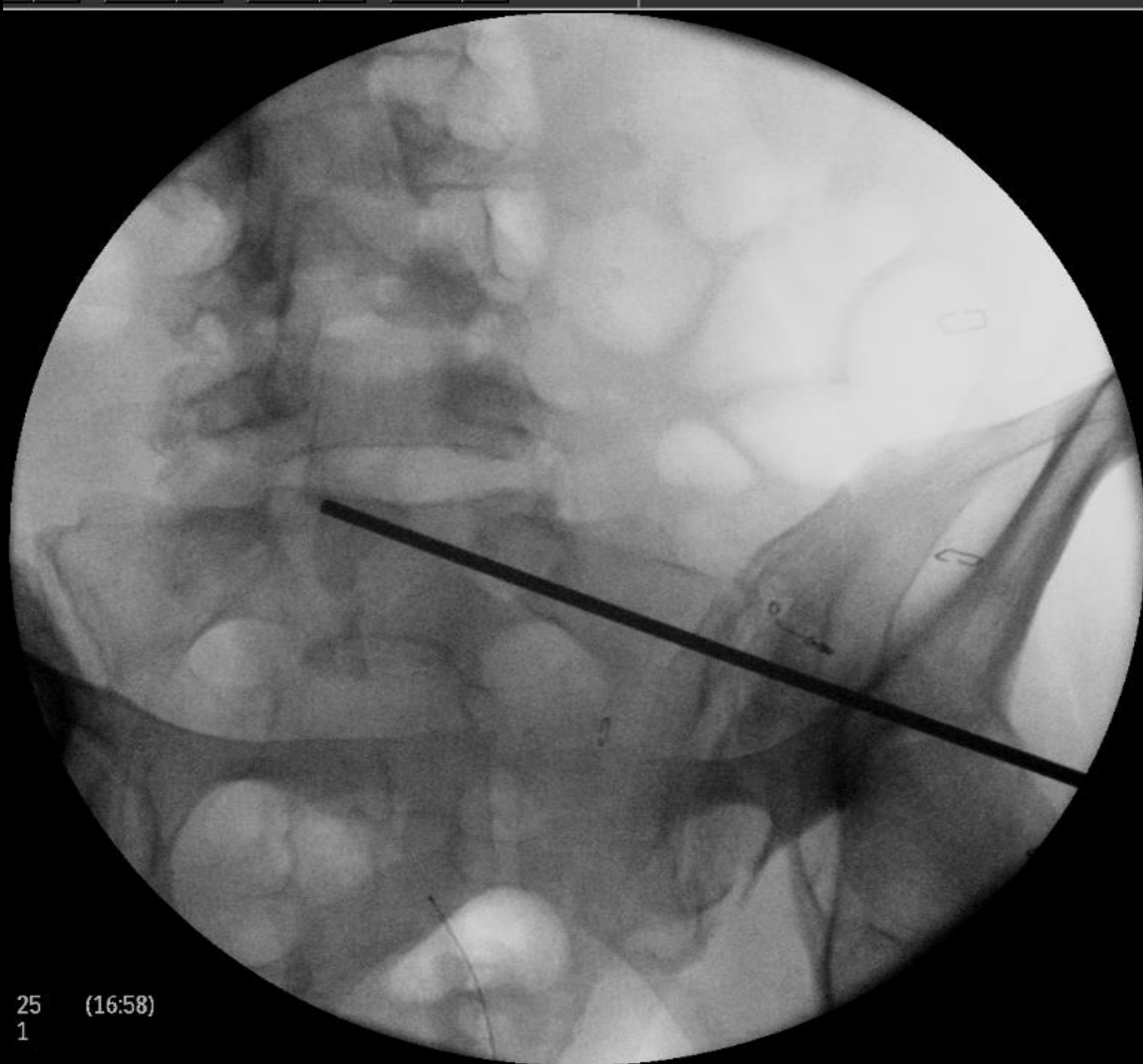
7
1

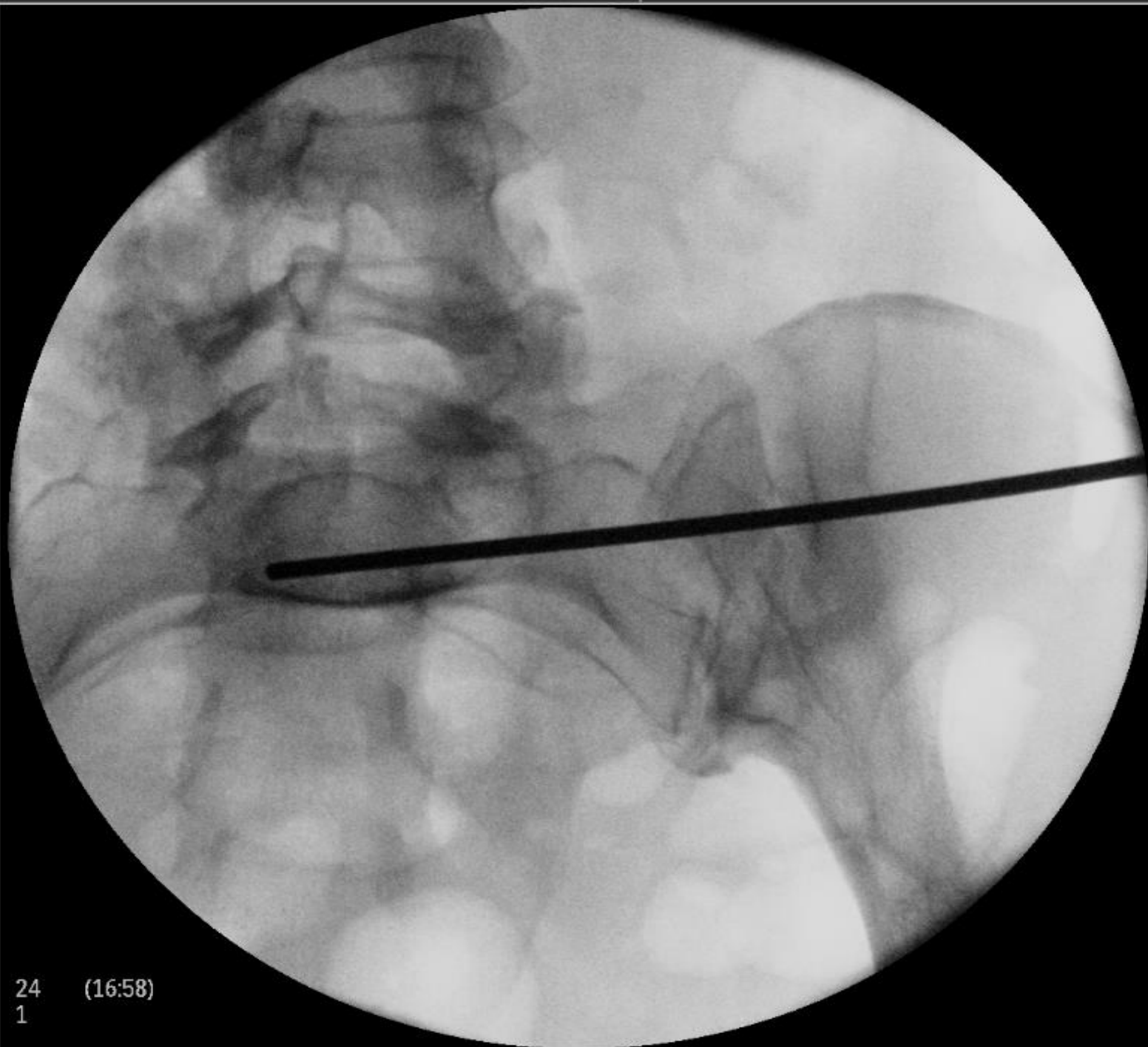
(16:29)



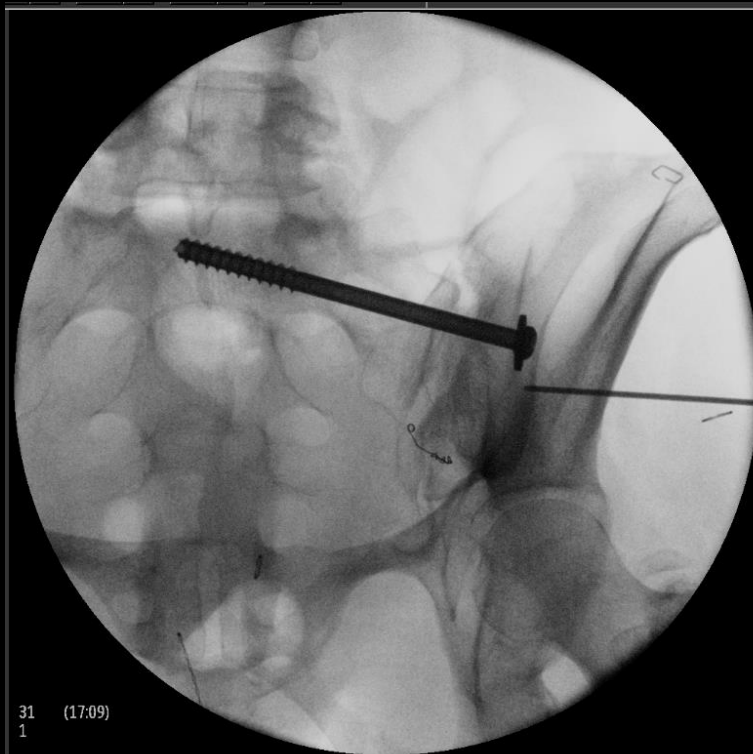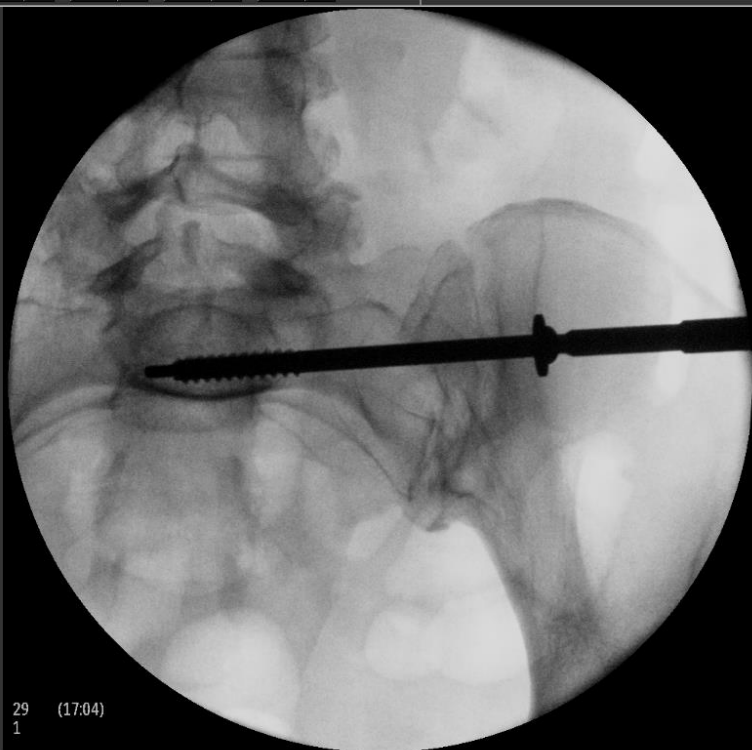


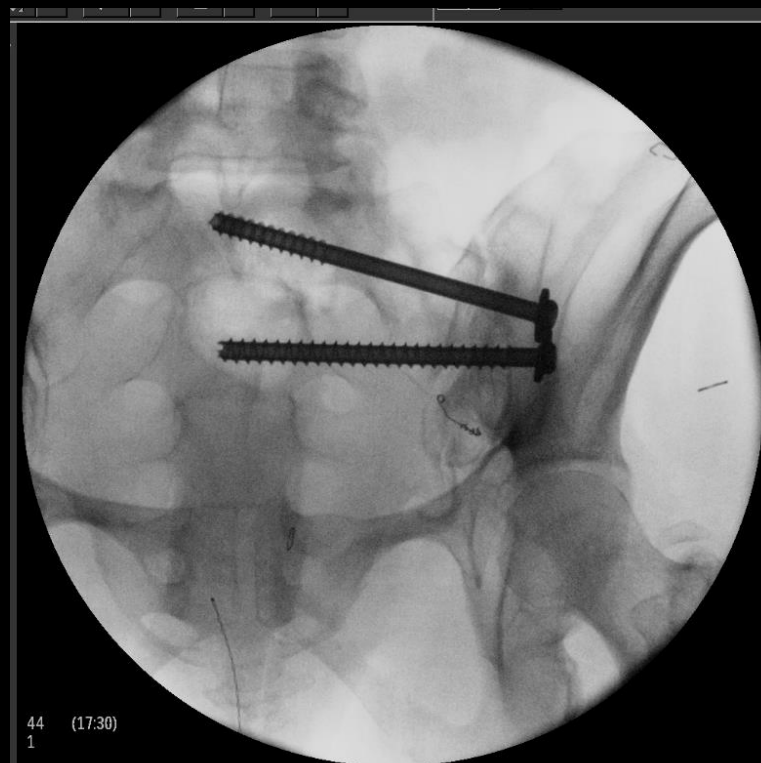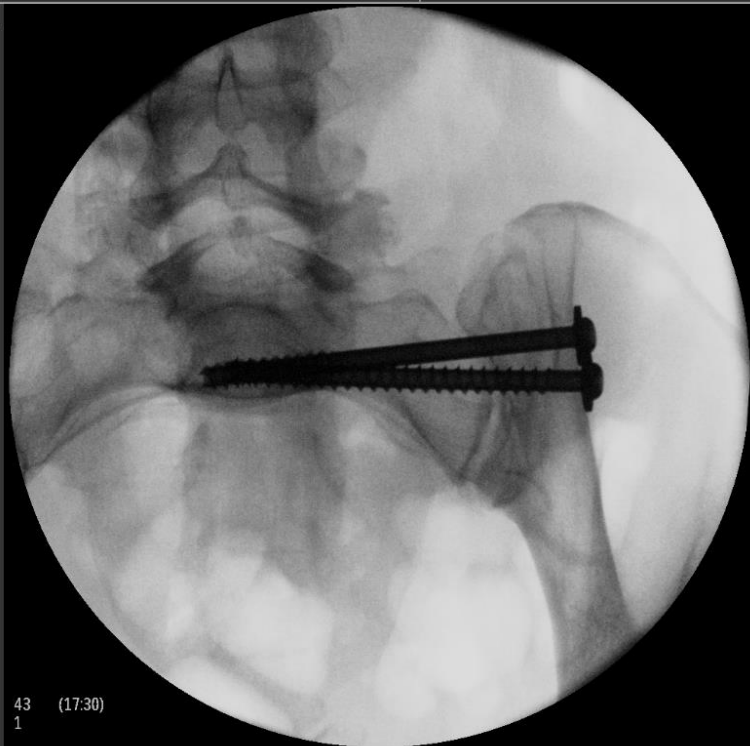




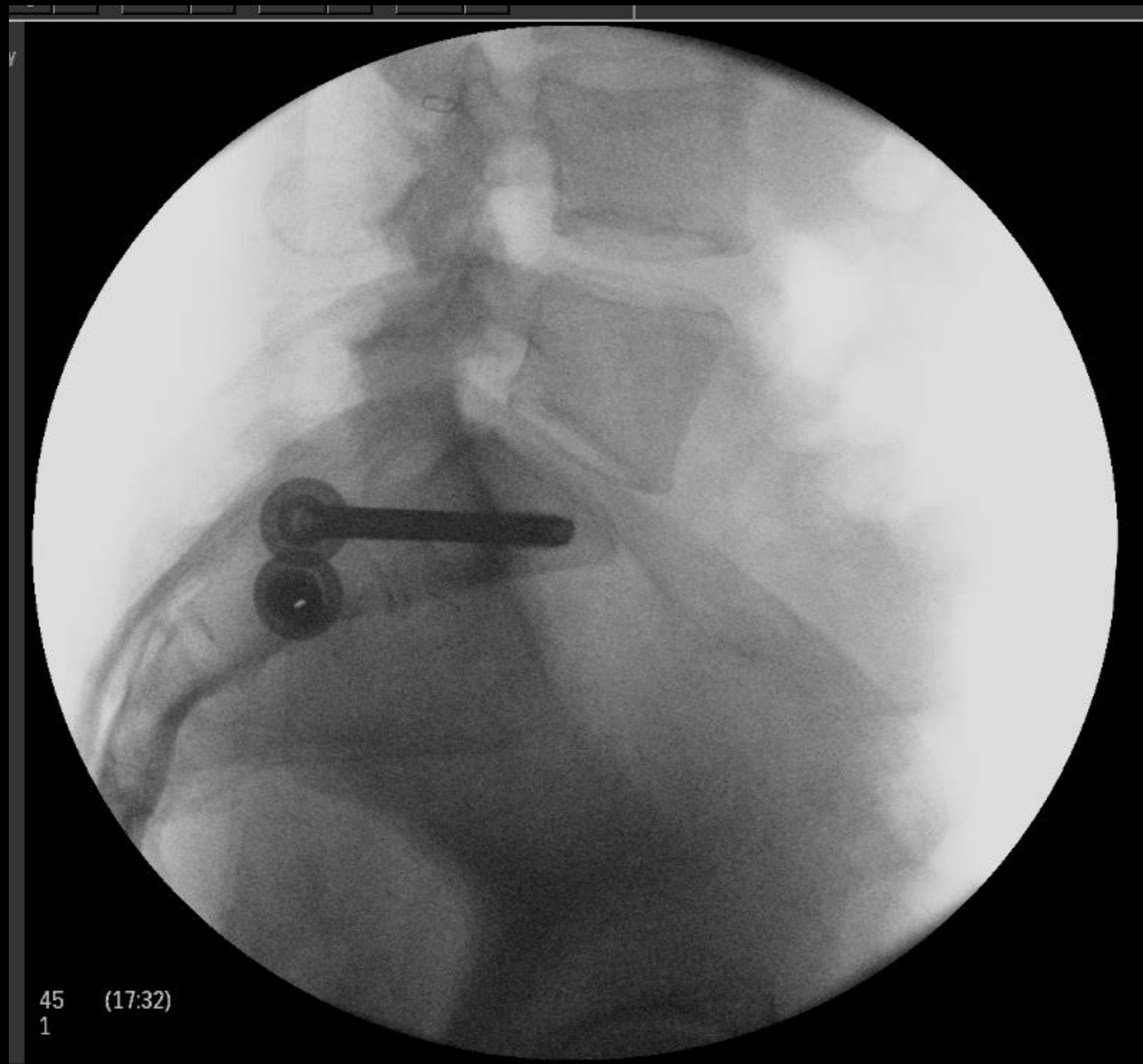

24 (16:58)
1







45 (17:32)
1



Thank You