Motorized Implants: Can They Work ?

Donald A Wiss MD Cedars-Sinai Medical Center Los Angeles, California

Post-Traumatic Deformity Correction & Leg Lengthening Using A Magnetic Intramedullary Limb Lengthening System (Precice)

Donald Wiss MD Cedars-Sinai Medical Center Los Angeles, California

Important Disclosure

Precise Lengthening Nail Is A Ti6-A14 Titanium Alloy Implant

Which Is FDA Approved

However,

The Newer Biodur 108 Stainless Steel Transport Nail Was

Removed From The USA Market In 2021 Because Of

Biocompatibility Issues With Pain, Breakage & Corrosion

(Similar To Metal-On-Metal THA)

Post-Traumatic Deformity & Limb Shortening
The Problem

- Relatively Uncommon Condition
- Challenging To Manage
- Treatment Often Prolonged
- Complications Are Common
- Recent Technological Breakthroughs

Post-Traumatic Deformity & Limb Shortening History

- Intrigued Surgeons For 100+ Years
- Ext Fixation Mainstay Of Treatment
  - Monolateral Frames (Wagner)
  - Ilizarov Fine Wire Technique
  - Taylor Spatial Frame
- Early IM Nail Techniques Unreliable



Post-Traumatic Deformity & Limb Shortening
Problems With External Fixation In Femur

- Pin Tract Infection
- Pain
- Soft Tissue Tethering
- Joint Stiffness
- N-V Issues
- Prolonged Treatment

Post-Traumatic Deformity & Limb Shortening
Precice Lengthening Nail

- Fully Implantable Magnetic Lengthening Nail
- Combined Deformity Correction & Lengthening
- Avoids External Fixation Issues
- Greater Patient Comfort & Acceptance
- A Lot Less Pain !
- Faster Healing ?

Post-Traumatic Deformity & Limb Shortening Precice Lengthening Nail

- Reliable Remote Control Mechanism
- Accurate & Controlled Distraction
- Optimal Rate & Rhythm Of Distraction
- Good Regenerate Formation
- Early Reports Encouraging

Post-Traumatic Deformity & Limb Shortening Indications In The Femur

- Must Establish A Patent IM Canal
- Shortening 2.5 – 8.0 Centimeters
- Rotational Mal-Alignment
- Angular Mal-Alignment <10 Degrees
- Often Done As A 2nd Stage Procedure

Post-Traumatic Deformity & Limb Shortening Contra-Indications In The Femur

- Inability To Establish A Patent IM Canal
- Infected Fractures
- Lengthening Greater Than 8 cm
- Angular Mal-Alignment >10 Degrees
- Not For Bone Transport In Isolation

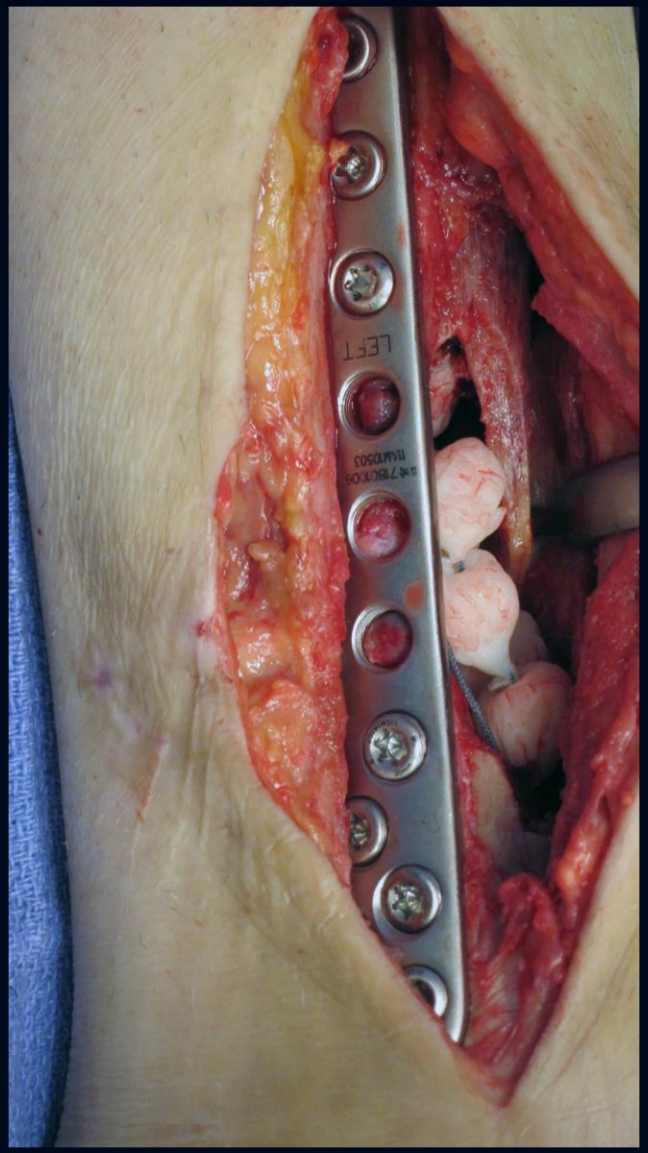

Post-Traumatic Deformity & Limb Shortening Technical Considerations

- Nail Is Very Stiff & Unforgiving
- Perfect Entry Portal Is Essential
- Prefer Antegrade Nailing
- Lateral Decubitus on Fracture Table
- Closed IM Osteotomy When Possible

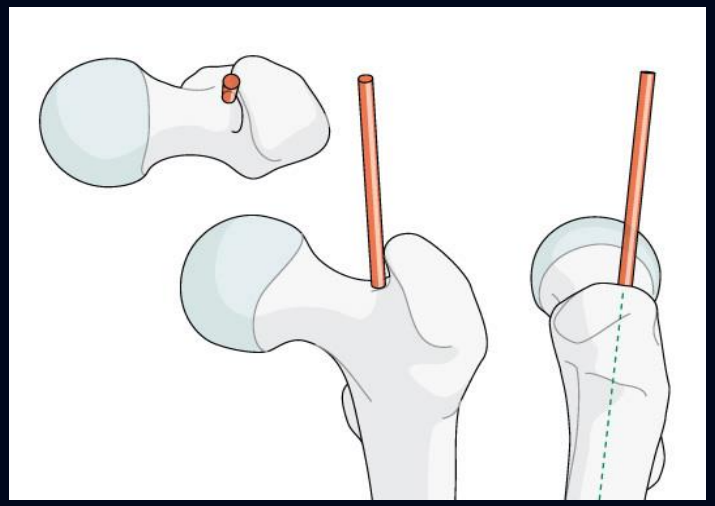

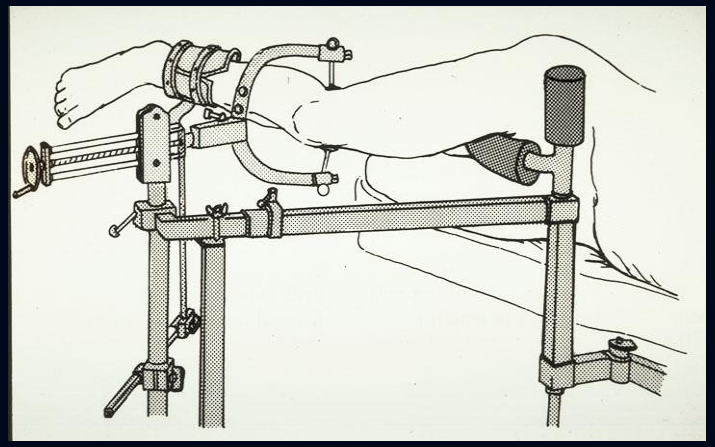

Post-Traumatic Deformity & Limb Shortening
Demographics

- Male 5 — Female 2
- Age 51 Yrs — 28-76 Yrs
- Closed 6 — Open 1
- Proximal Third — 4 Of 7
- Shortening 2-6 cm — Avg 3.6 cm
- Rotational > 25° — 5 / 7

Post-Traumatic Deformity & Limb Shortening Results

- Closed IM Osteotomy 5 Open Osteotomy 2
- Lengthening 0.75 mm per Day
- Cortical Bridging 4–6.5 Mos (Avg 5.4 Mos)
- 6 / 7 Pts Healed After Index Procedure
- 1 Revision For Rotation Mal-Alignment

57 Yr Old Female Fell Sustaining A Reverse Oblique Fracture Treated At An Outside Hospital; Nailed Short

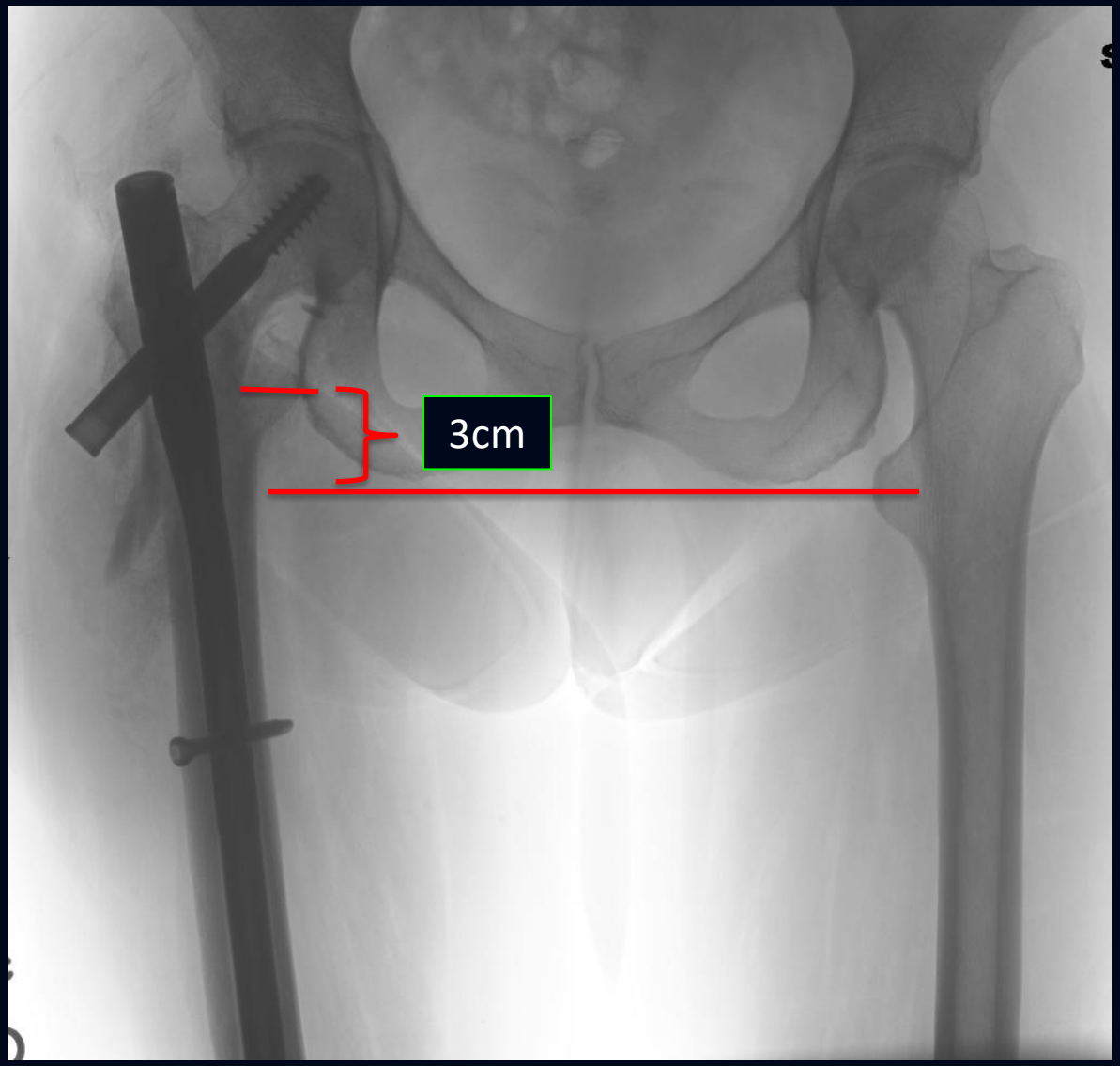

Referred At 7 Months With A Painful Non-Union

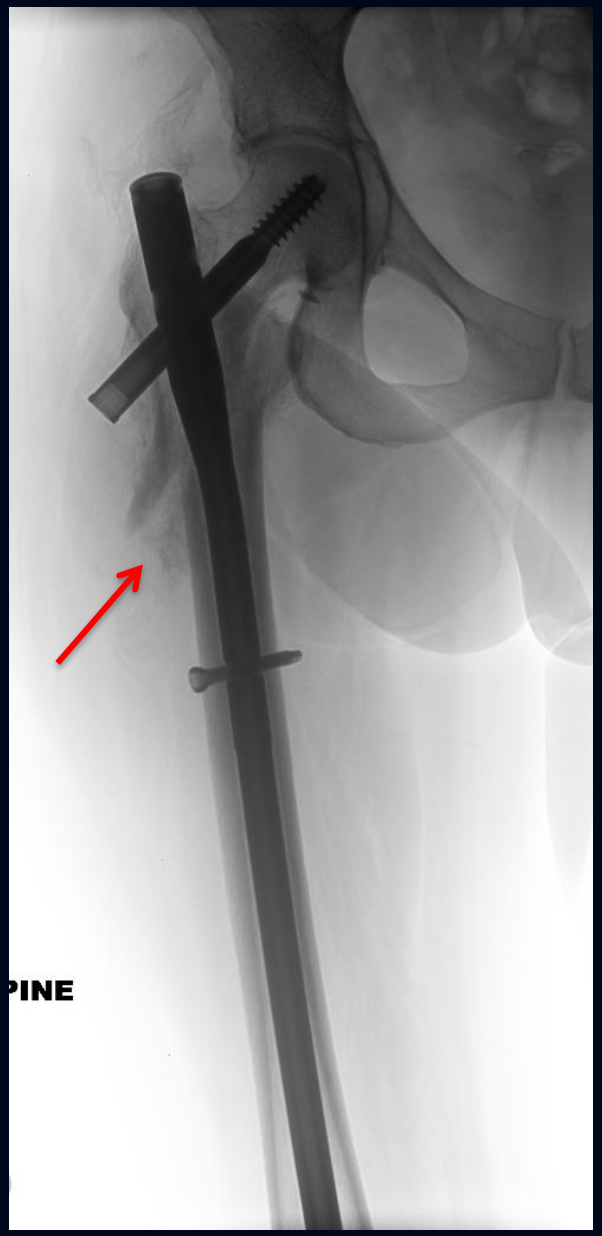

Exchange Reamed With A Reconstruction Nail

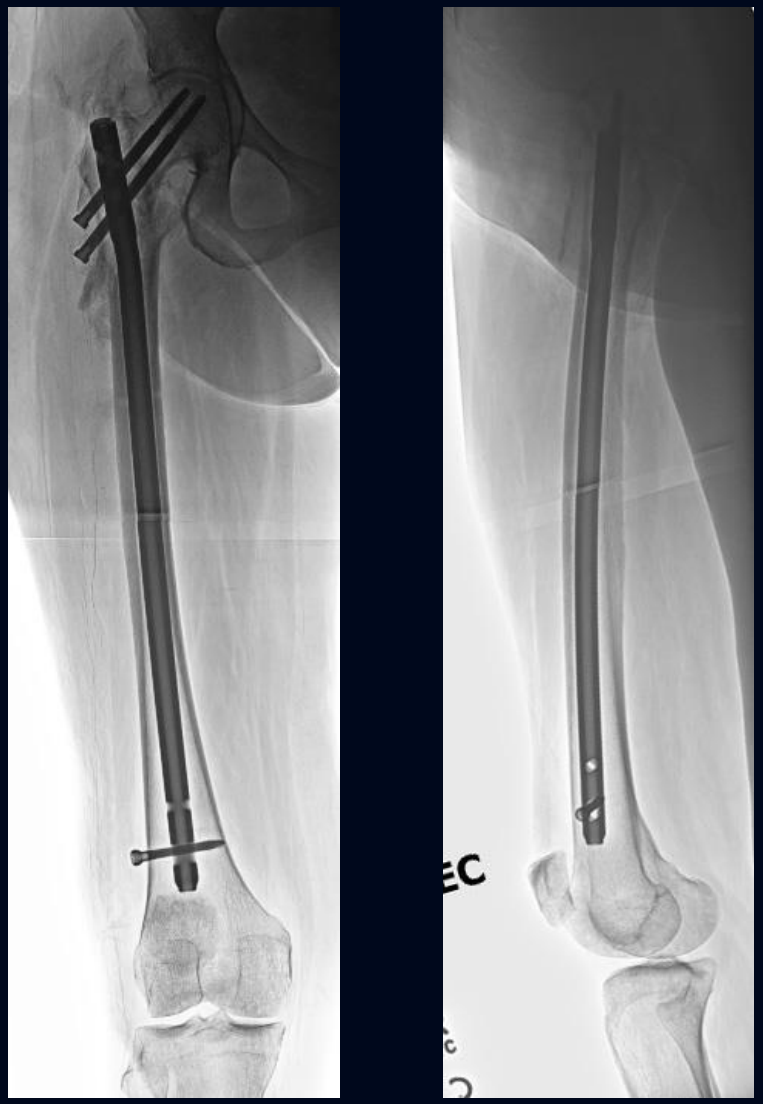

Healed At 5 Months With 4 cm Leg Length Discrepancy

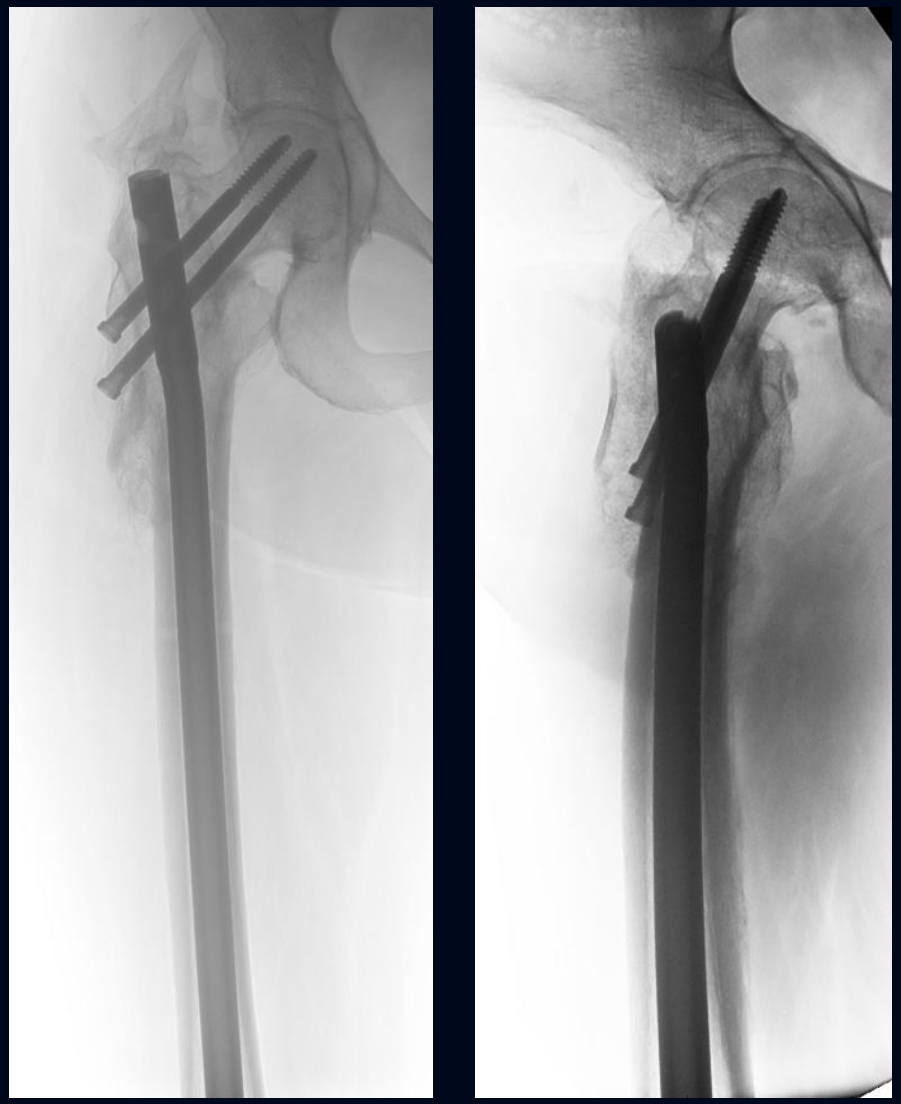

Shoe Lift Incompatible With Job & Lifestyle

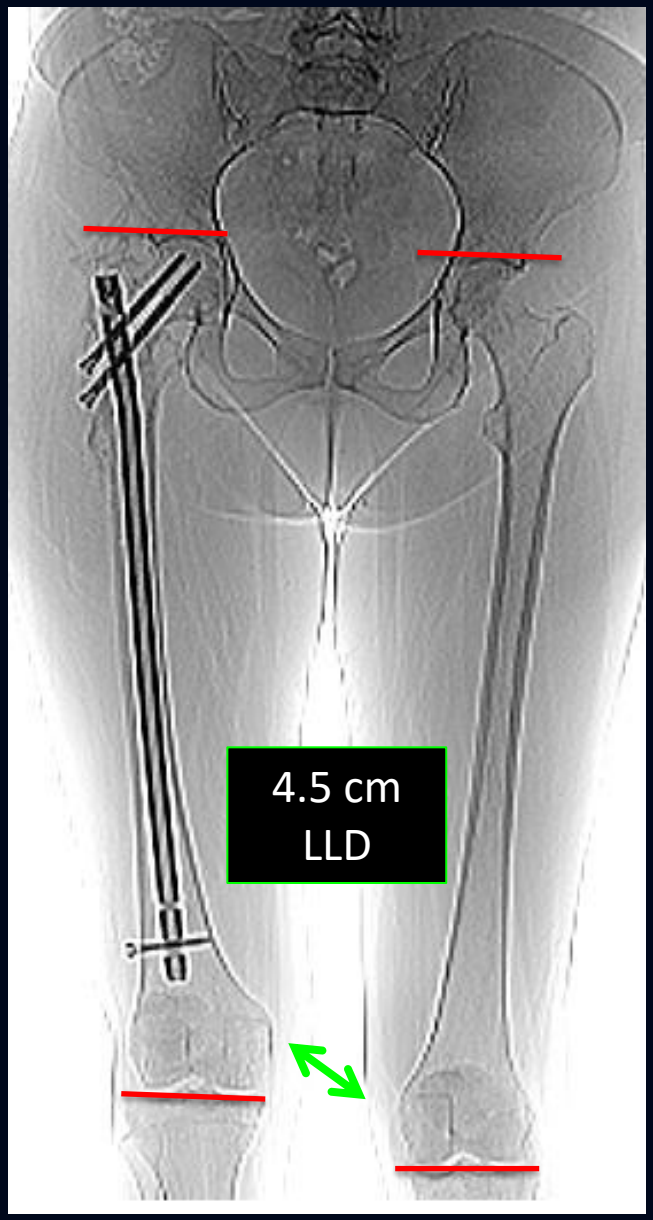

Removal Existing Nail; Closed IM Osteotomy & Insertion Of A Femoral Lengthening Nail

Precice IM Limb Lengthening Nail By Nuvasive

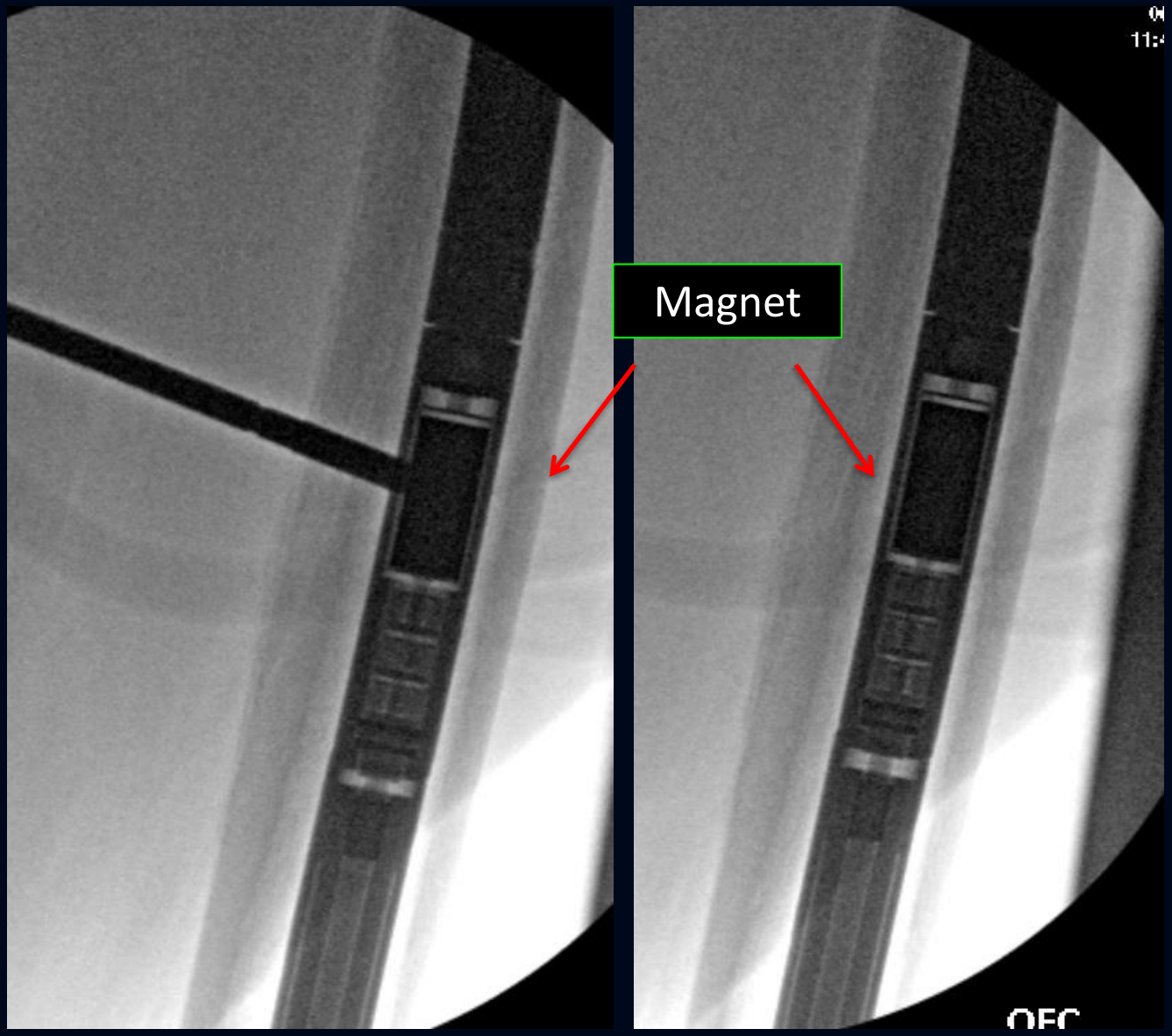

Post-Operative Radiograph

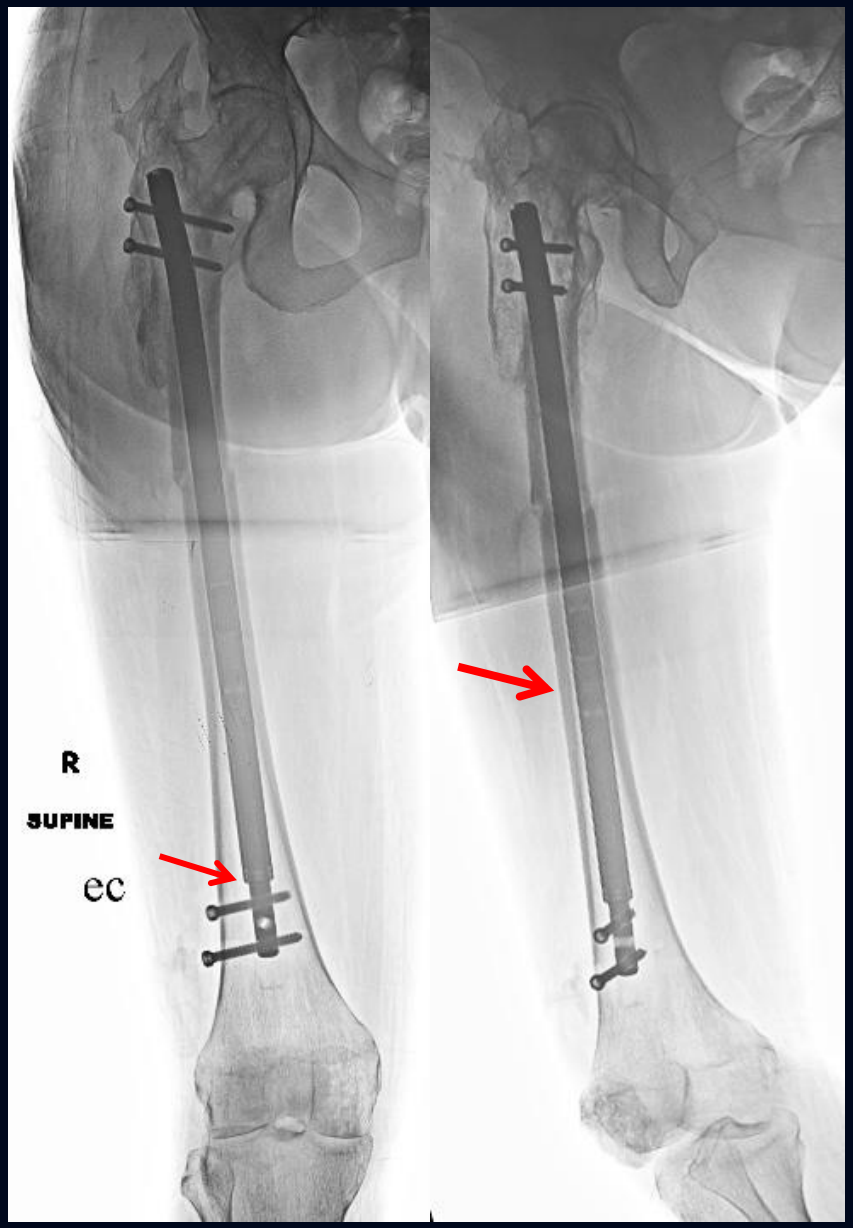

Lengthening 0.75 mm/day

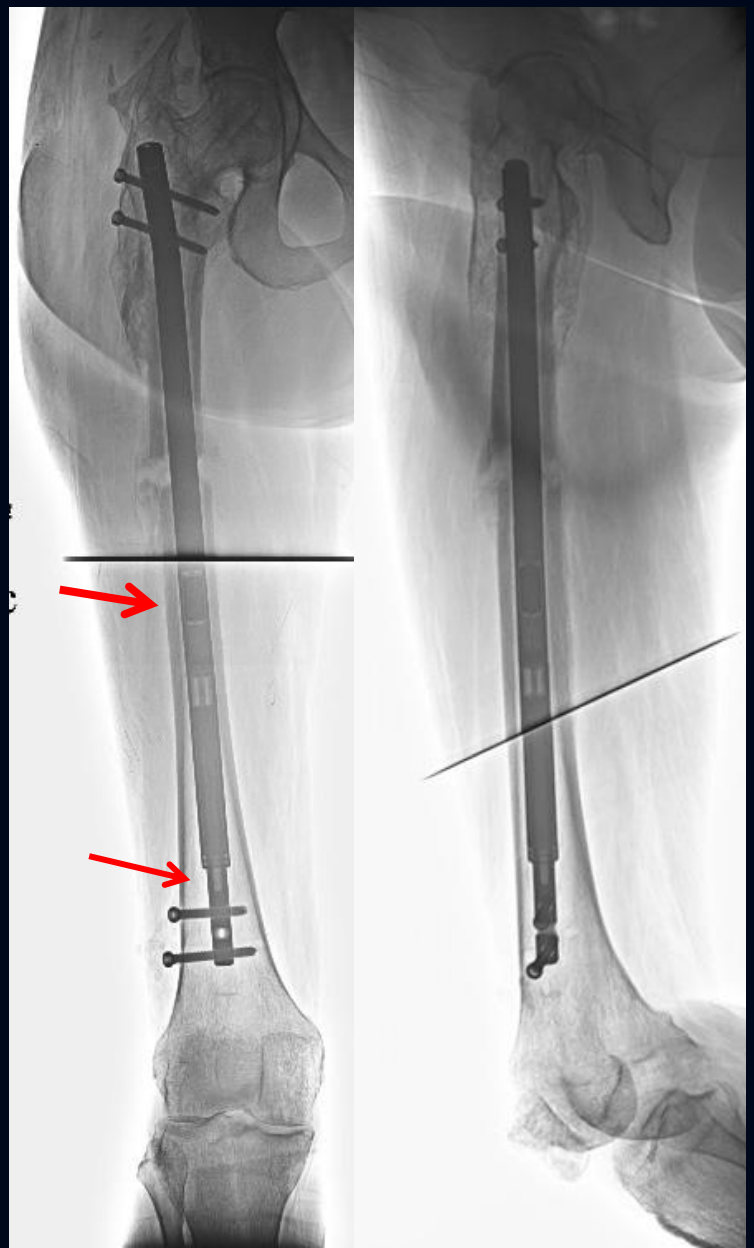

Computer Programmed Magnet For Lengthening

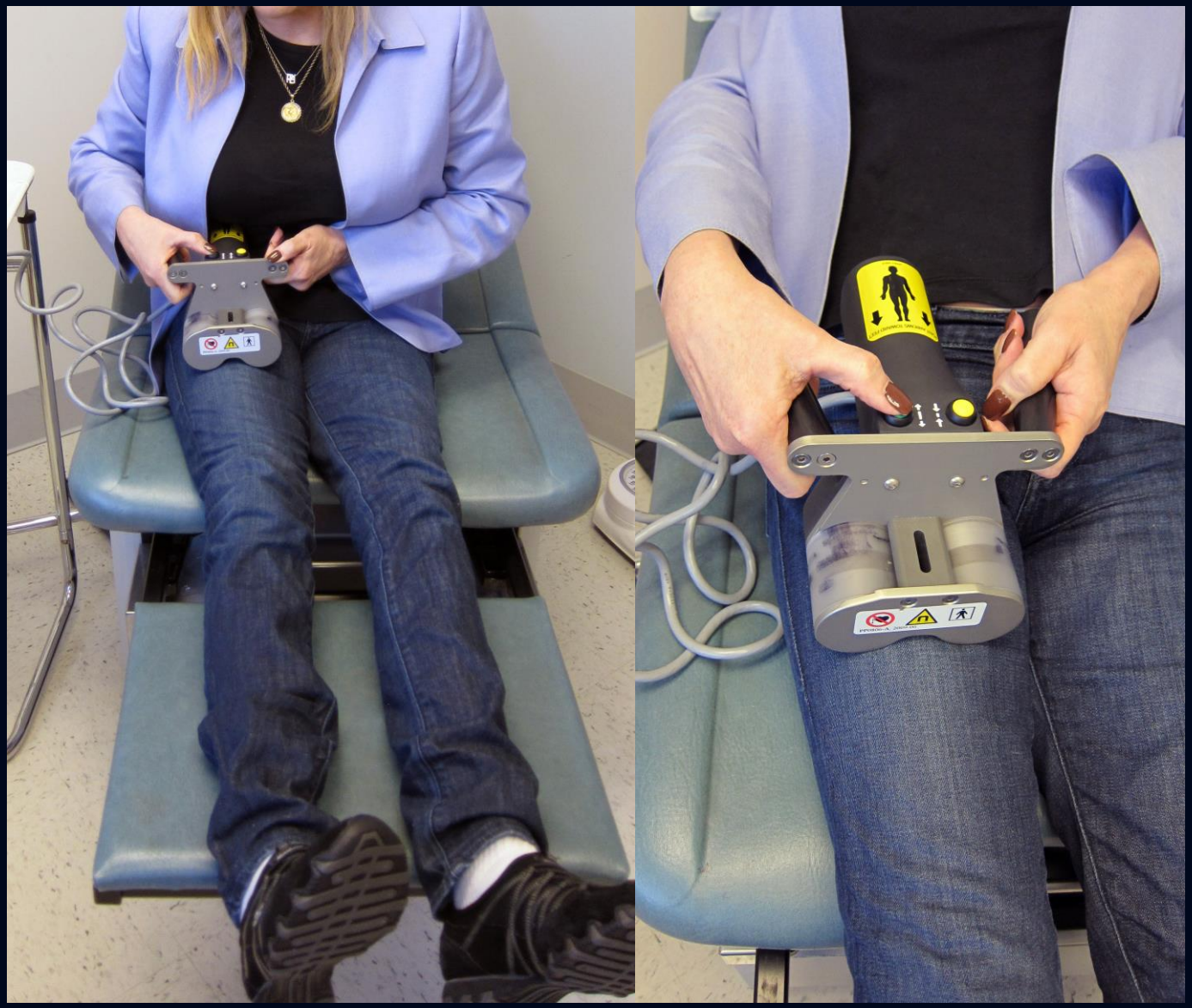

2.5 cm Lengthening

4.O cm Lengthening

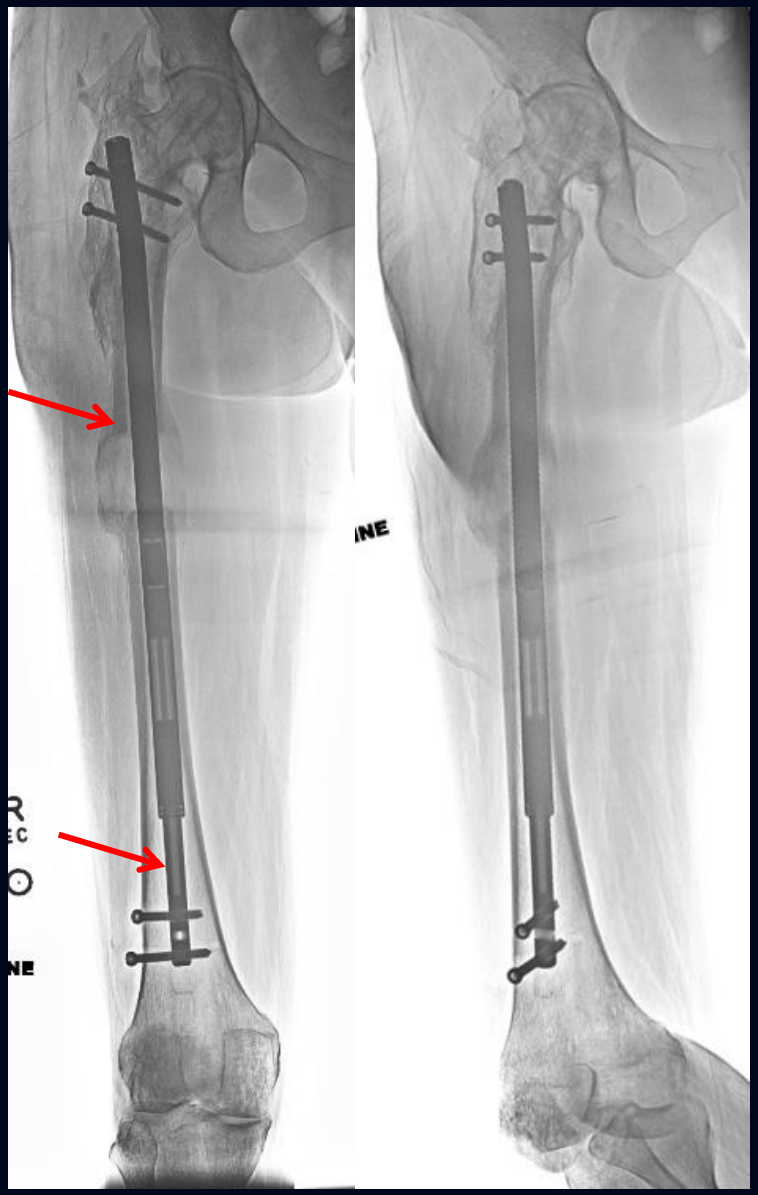

4.7 cm Lengthening

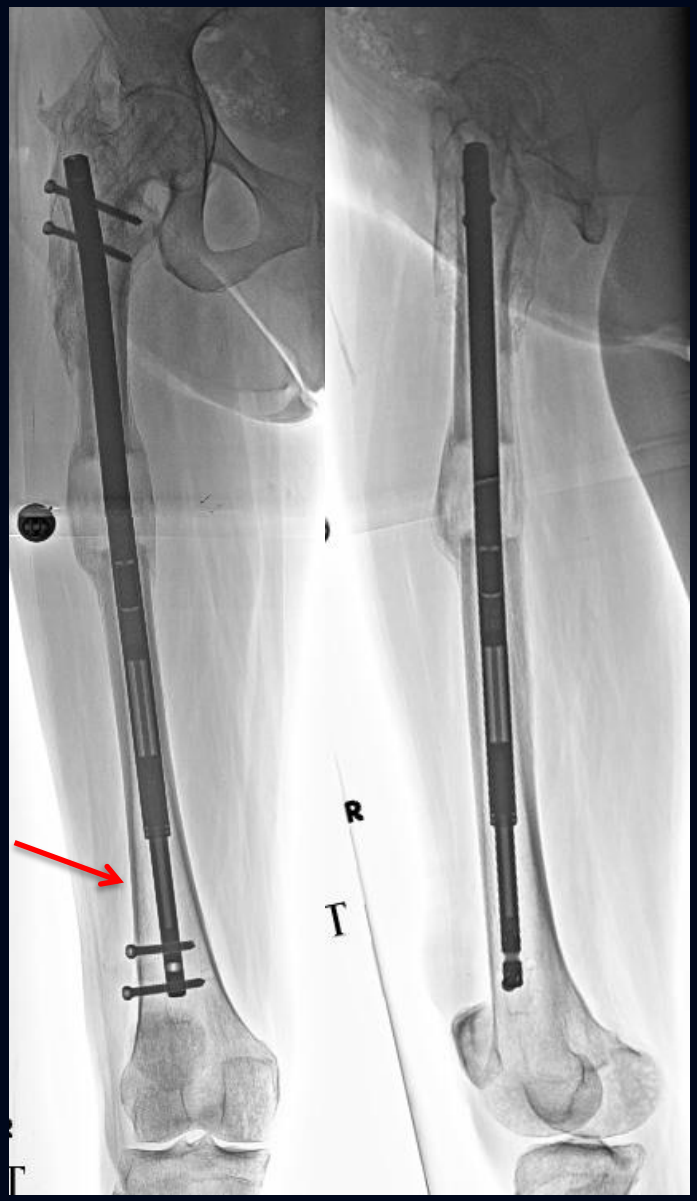

Healed Leg Lengths Equal

Follow-Up At 2 Years; Healed With Bridging Cortical Bone

59 Yr Male With A Complex Mal-Union Of The Proximal Femur

Extreme Lateral Entry Point Leading To A Varus Deformity With A Neck Shaft Angle Of 118 Degrees, Nailed 4 Cm Short

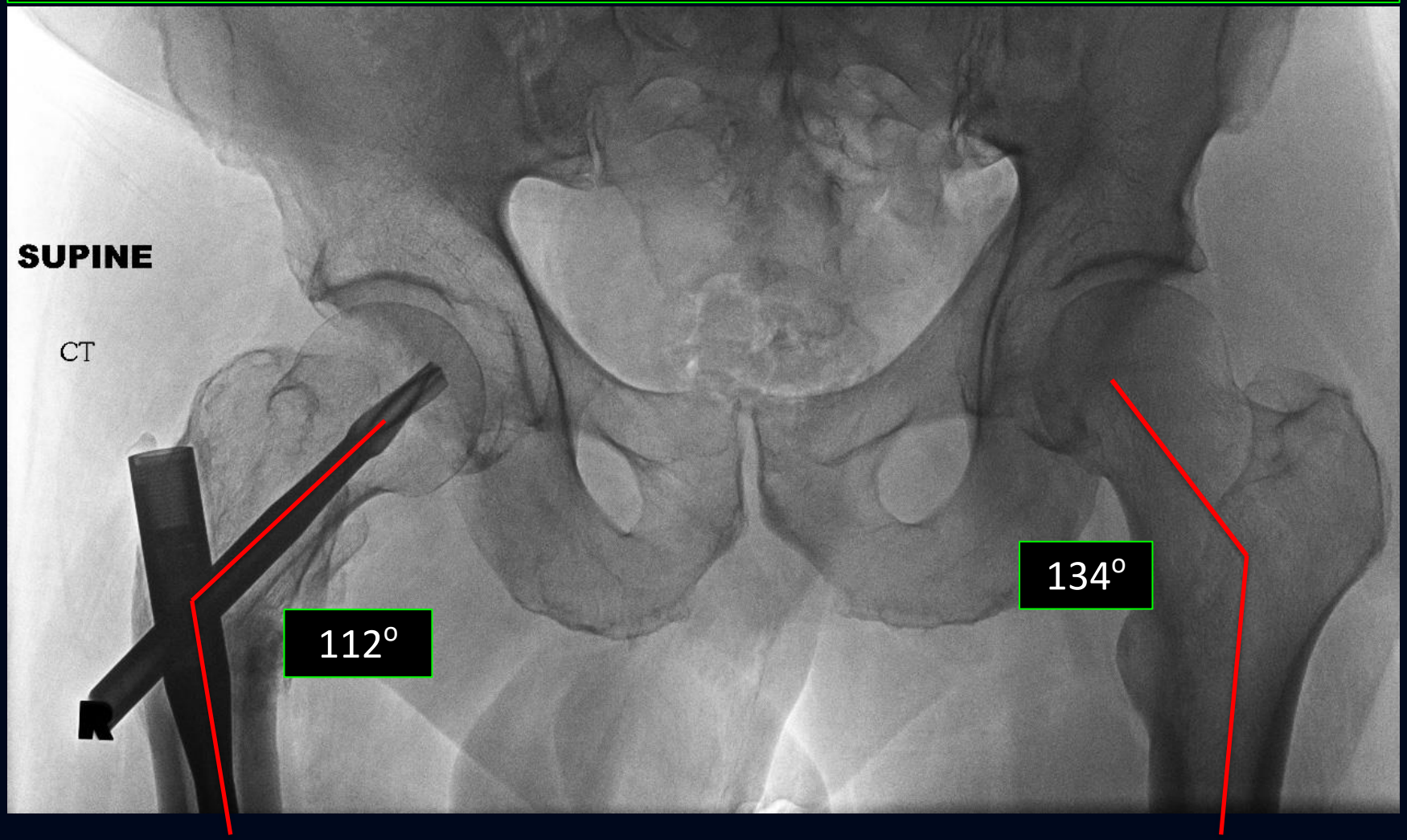

20 Degree Closing Wedge Osteotomy & Insertion Of Blade Plate

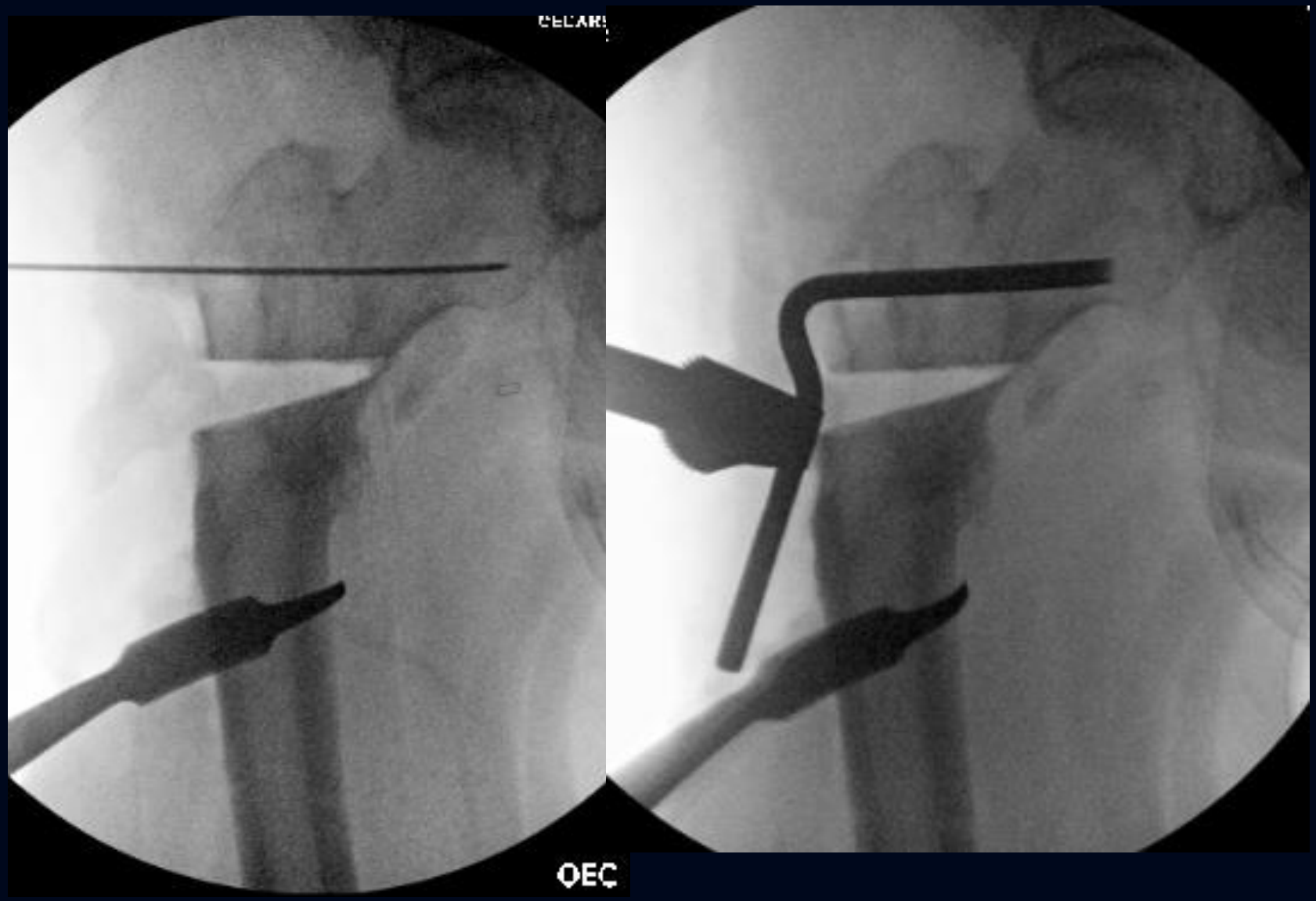

Deformity Correction & Compression Of The Osteotomy

Final Fixation Construct

12 Months Post-Operative; Healed

Scanogram At One Year Shows A

3.5 Cm Residual Limb Shortening

And A 25° Internal Rotation

Deformity. Wearing A 3 cm Shoe

Lift. Planned 2nd Stage Leg

Lengthening Procedure

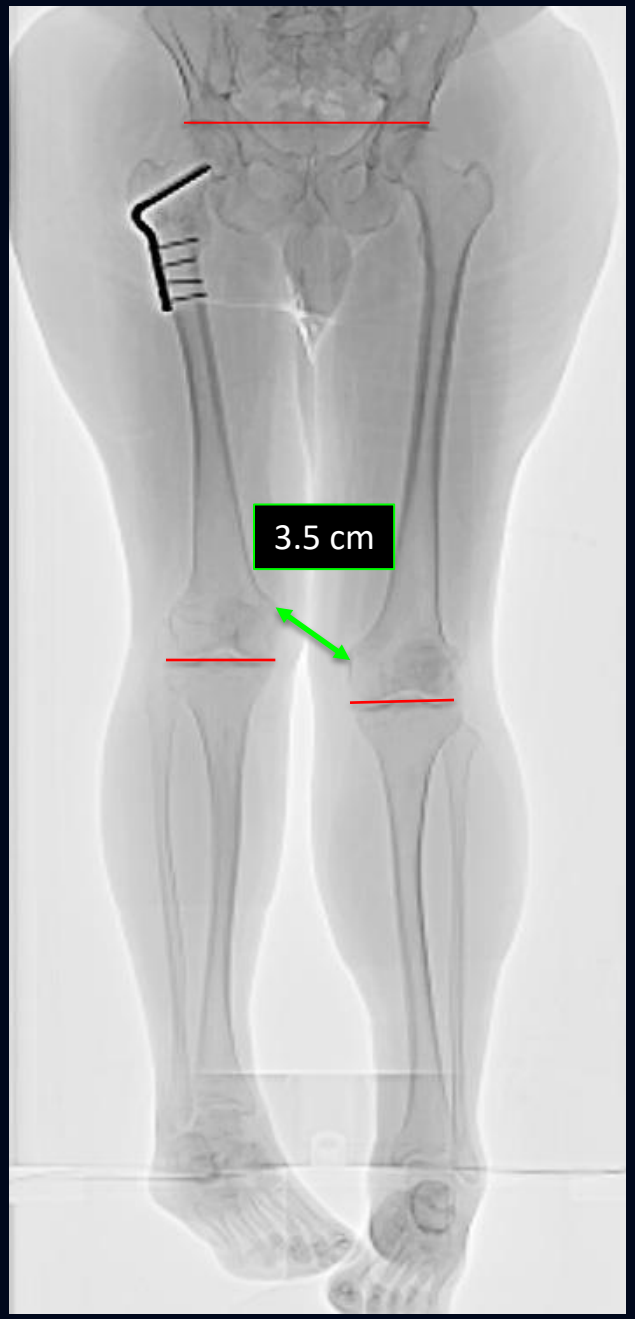

Removal Blade Plate & Closed Intra-Medullary Osteotomy

Femoral Nail & Computer Directed Lengthening Magnet

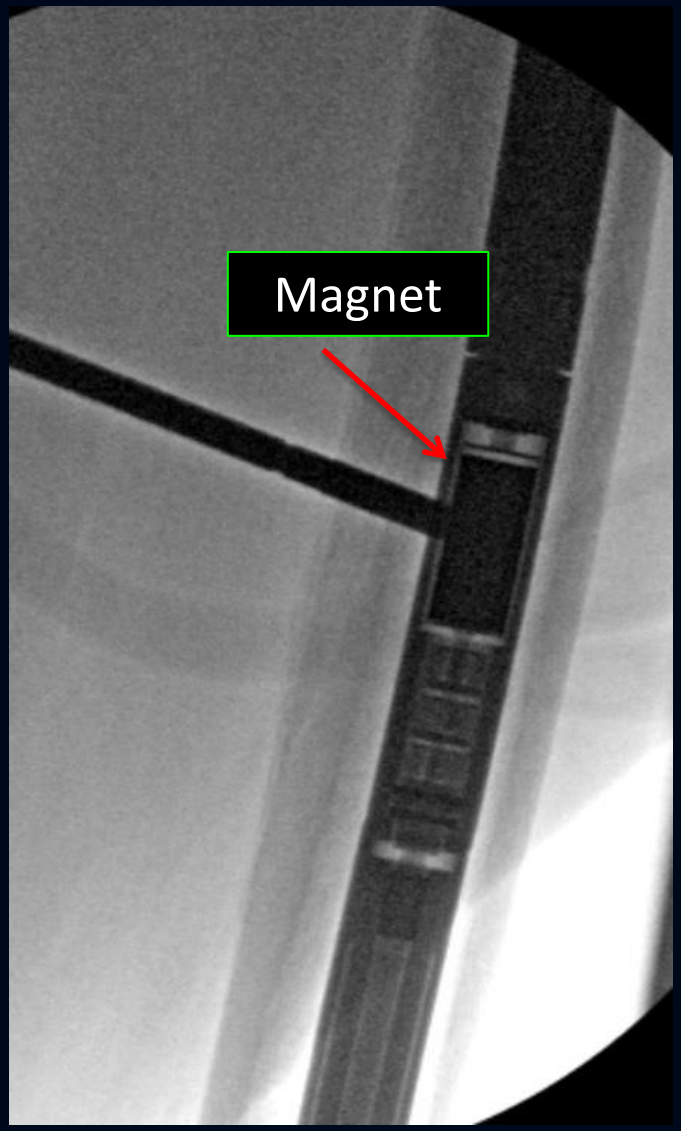

Closed Intra-Medullary Osteotomy & Lengthening Nail

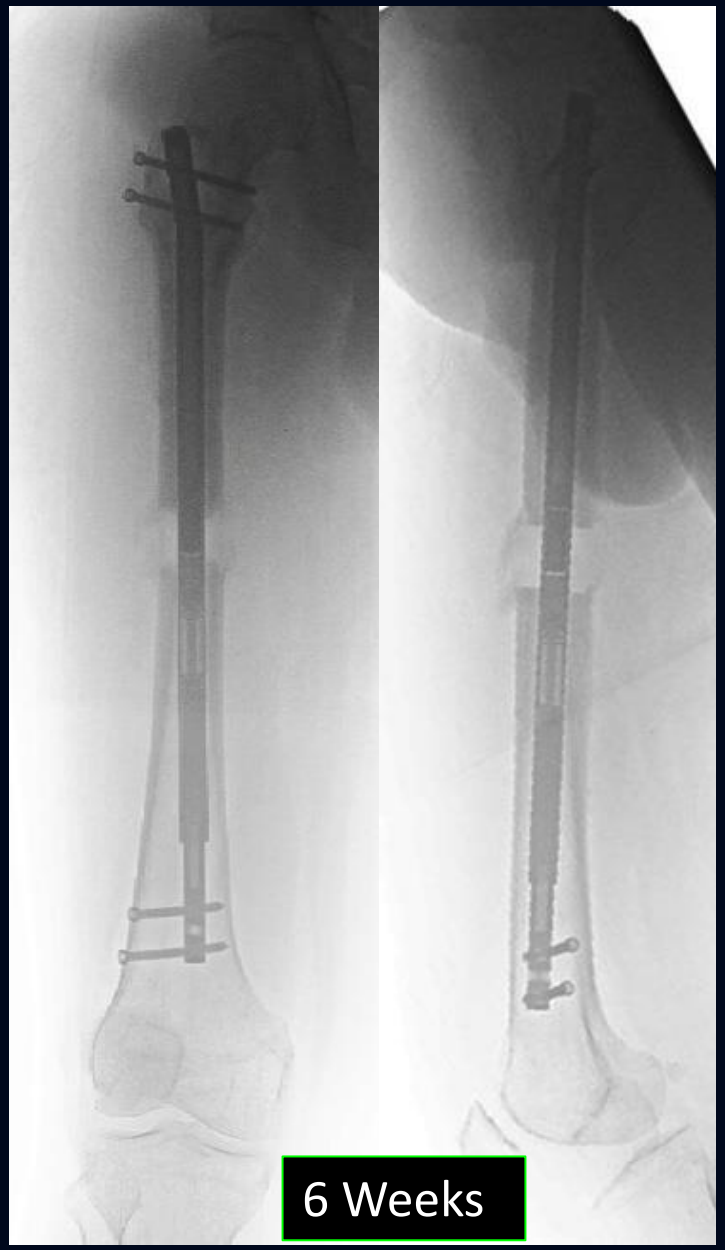

10 Weeks Of Lengthening

14 Weeks Of Lengthening

Mission Accomplished 3.5cm

4 Months S/P Lengthening

6 Months S/P Lengthening

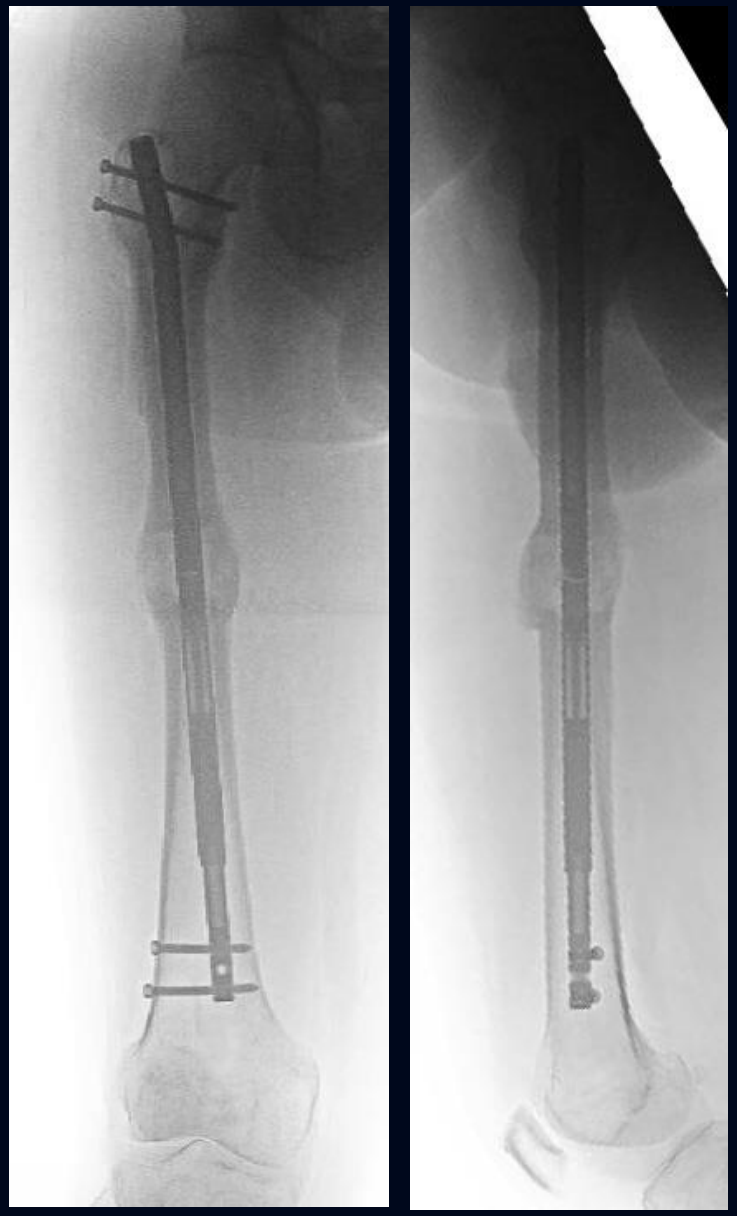

Final Follow-Up At 10

Months; Working &

Playing Golf


EXIT

57 Yr Male S/P Motorcycle Accident

Grade IIIA Open Supracondylar Femur Fx

Treated At Outside Hospital

I & D And ORIF With Antibiotic Spacer

Referred At 9 Weeks With These X-Rays

Large Anterior Distal Wound Healed.

ROM Knee 10 – 60 Degrees

At 10 Weeks I Removed Spacer With Contralateral RIA Bone Graft

4 Months Post Bone Graft

8 Months Healed ROM 0-90

At 1 Year Persistent Pain & A Limp

3.0 cm Short

25 Degrees Externally Rotated

Patient Is Unhappy With Shoe Lift

Planned 2nd Stage Limb Lengthening

Pre-Op AP & Lateral Femur

Note Translational Deformity

Of The Distal Fragment On

Lateral Radiograph

Closed Intra-Medullary Osteotomy For Leg Lengthening and Rotational Correction

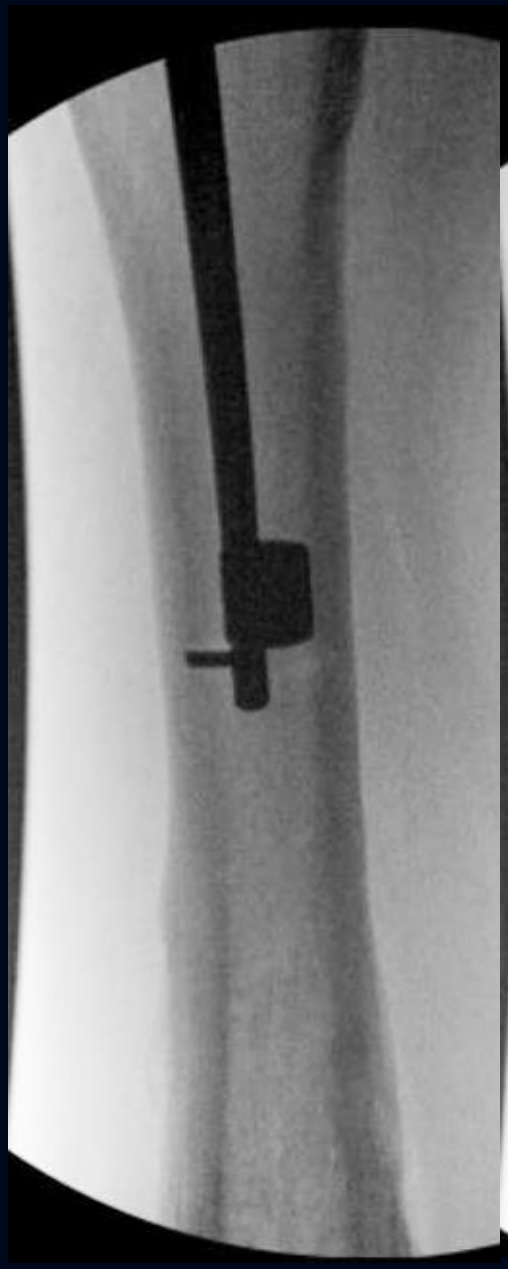

Deformity Correction, Lengthening Nail; Could Not Advance Nail Due To Deformity

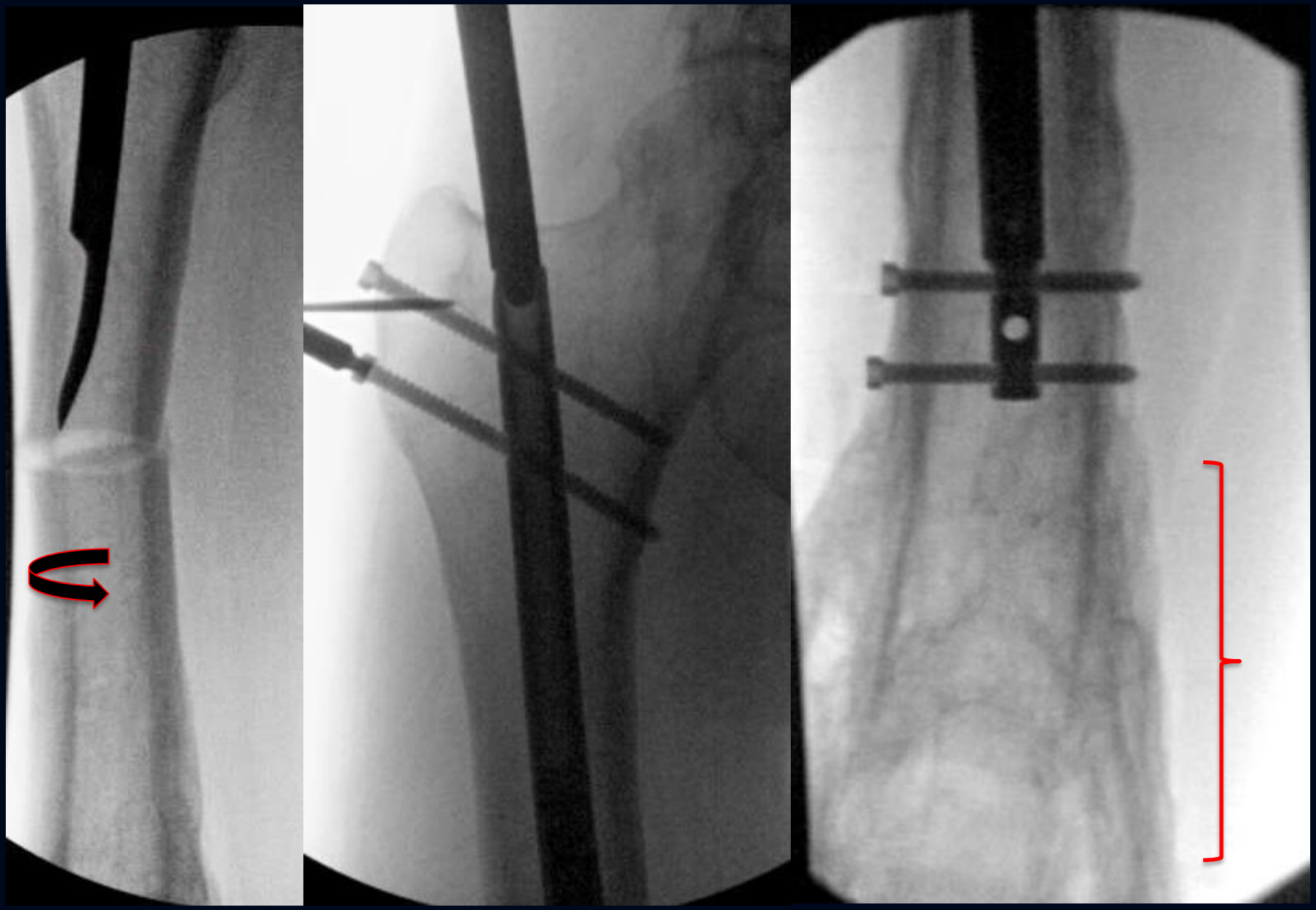

Post-Op Radiographs

Radiographs At 7 Weeks

Radiographs At 4 Months

Radiographs At 8 Months

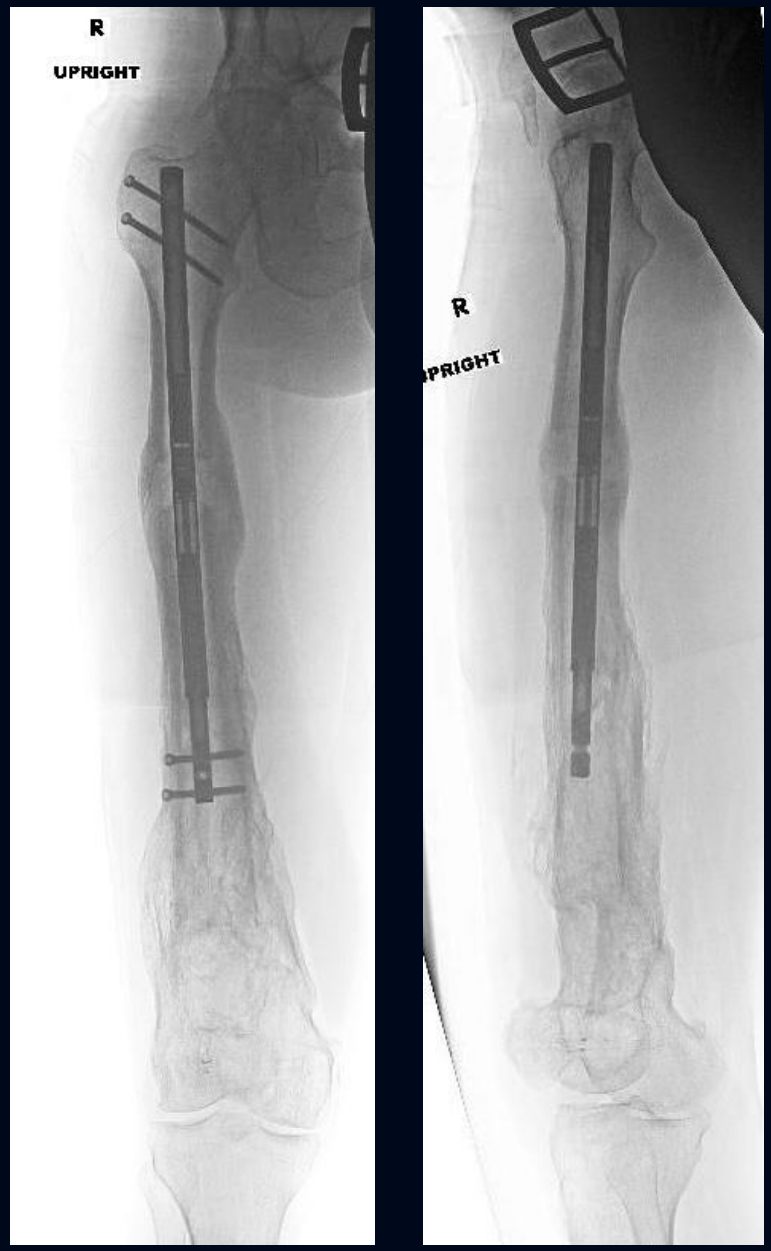

12 Month Follow-Up Healed And Working

18 Month Follow-Up Drives A Truck

18 Month Follow-Up Walking In The Clinic



34 Yr Old Male Google Executive.

Femur Fracture Age 15 Managed in

Austraila With Traction & Spica Cast.

Presents With Leg Length Discrepancy

And Inability To Participate In Sports

CT Scanogram Shows 5.0 cm Shortening Of Affected Femur

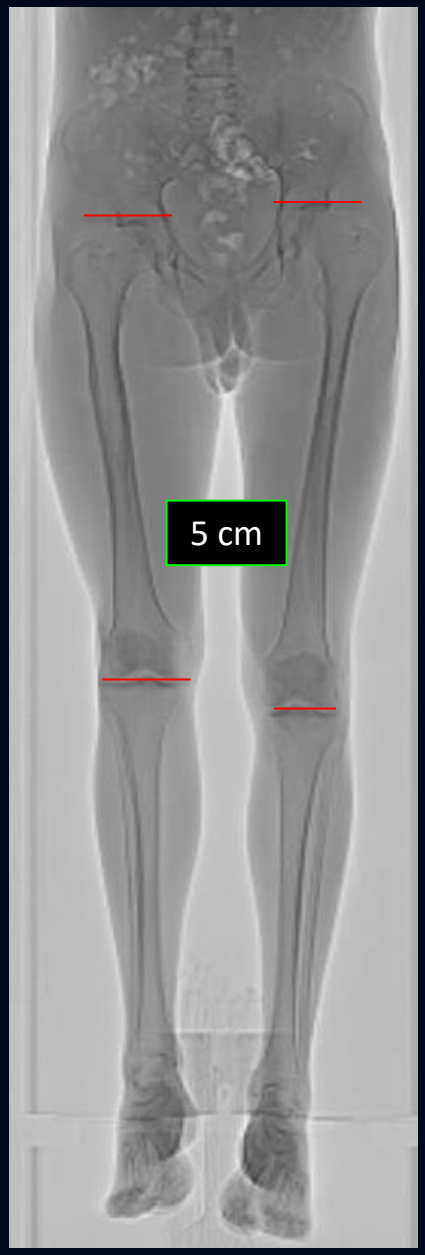

Lateral Decubitus On A Fracture Table. Piriformis Entry

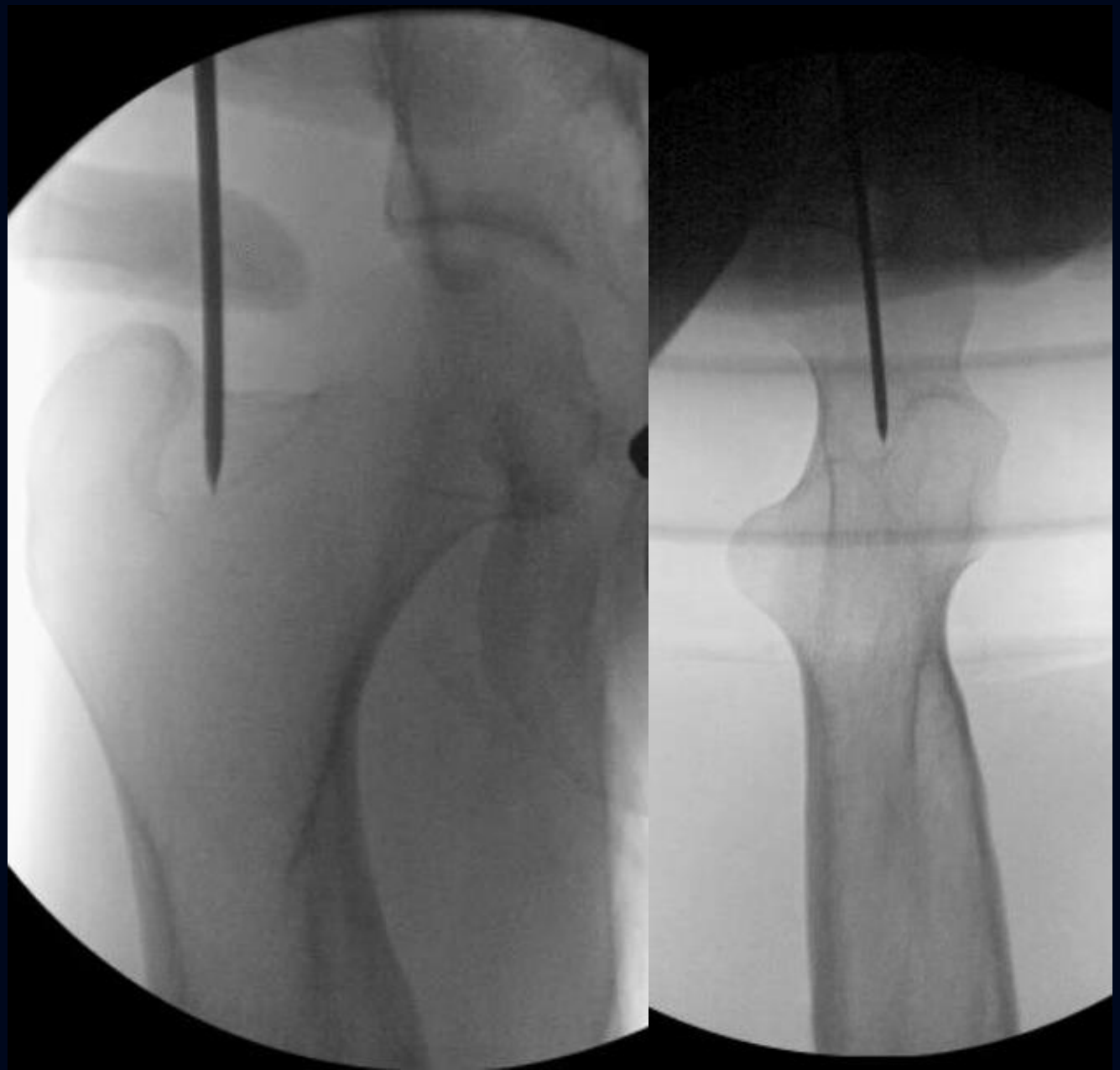

Osteotomy; Blocking Drill Bits To Improve Position Of The Guide Wire

Post-Op Radiographs

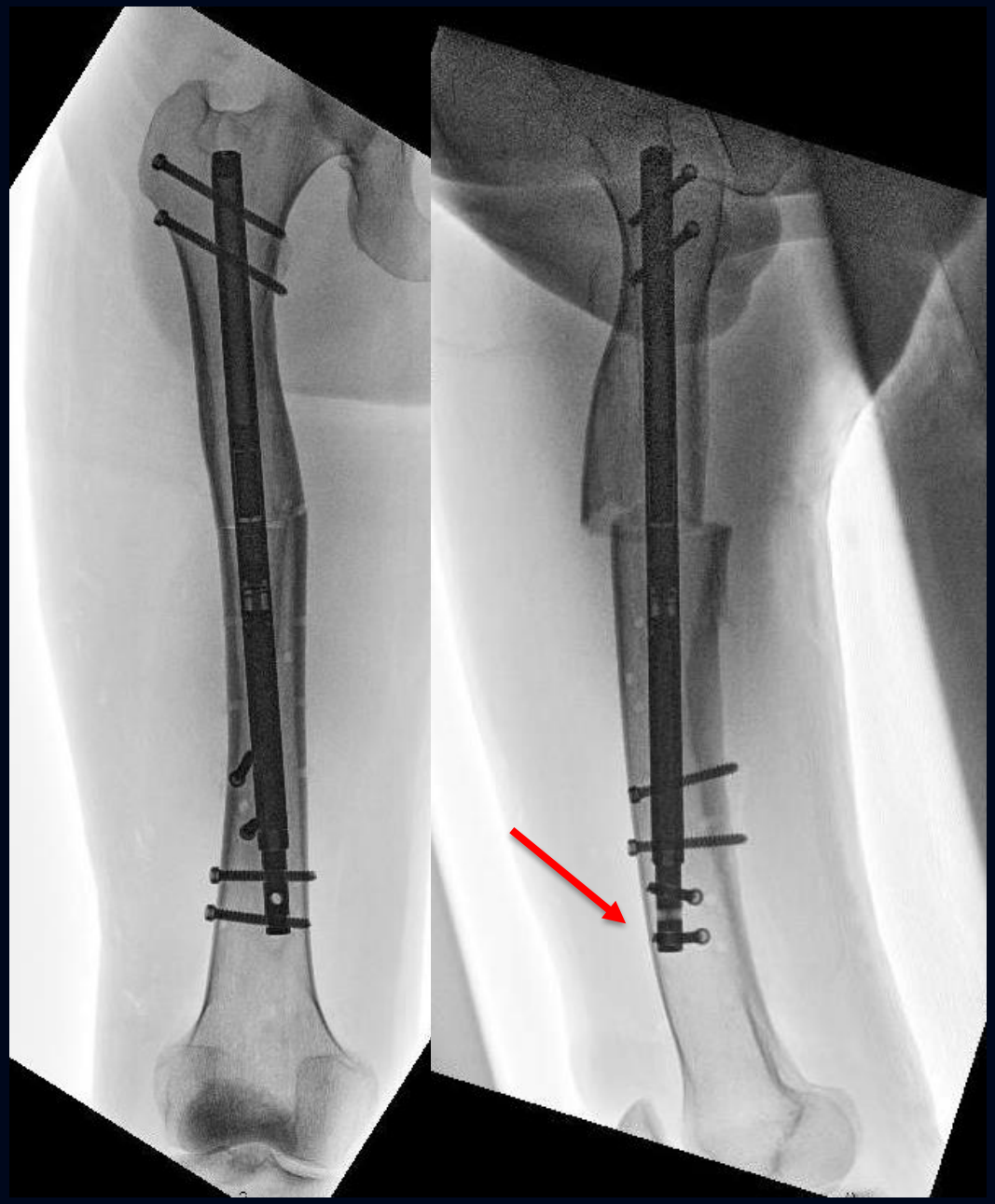

Radiographs At 6 Weeks

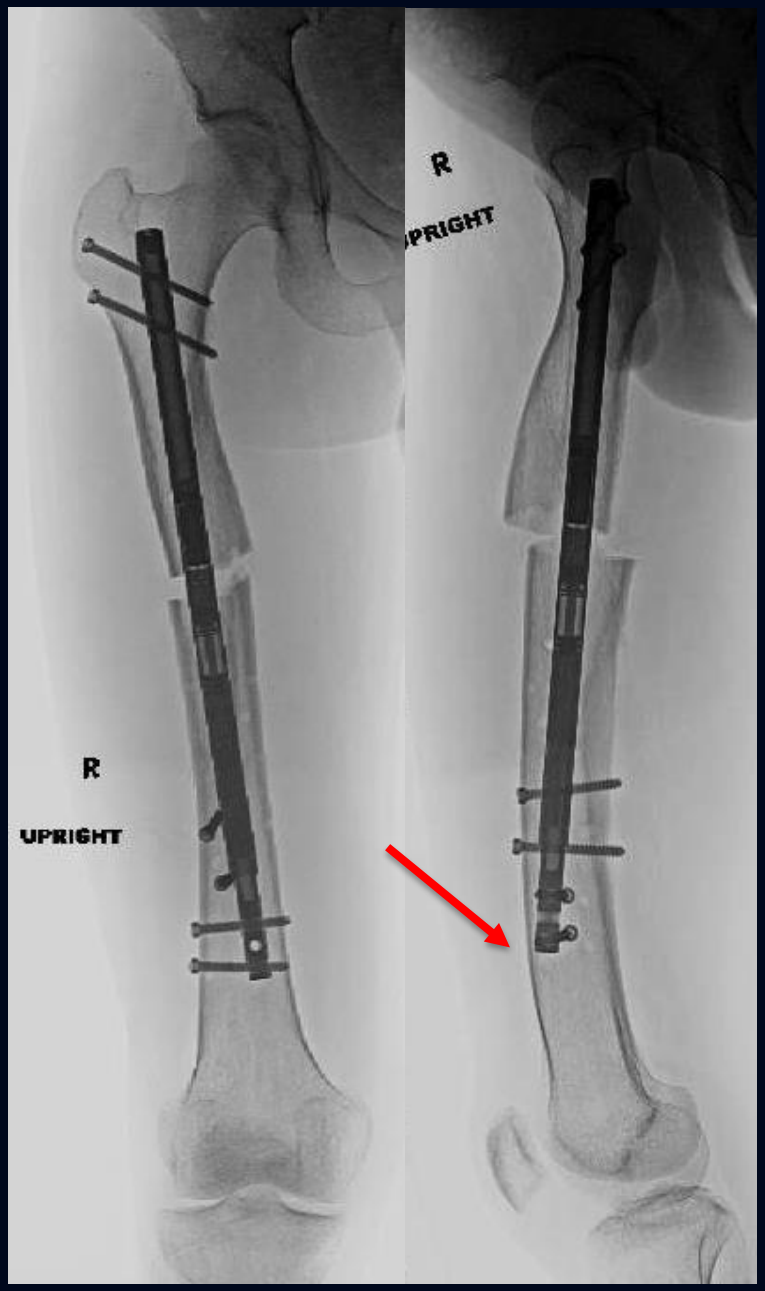

Radiographs At 4 Months

Radiographs At 6 Months

Radiographs At 9 Months Healed

Clinical External Rotation Deformity

CT Scanogram

Documents A 25 Degree

External Rotational

Deformity. Now What?

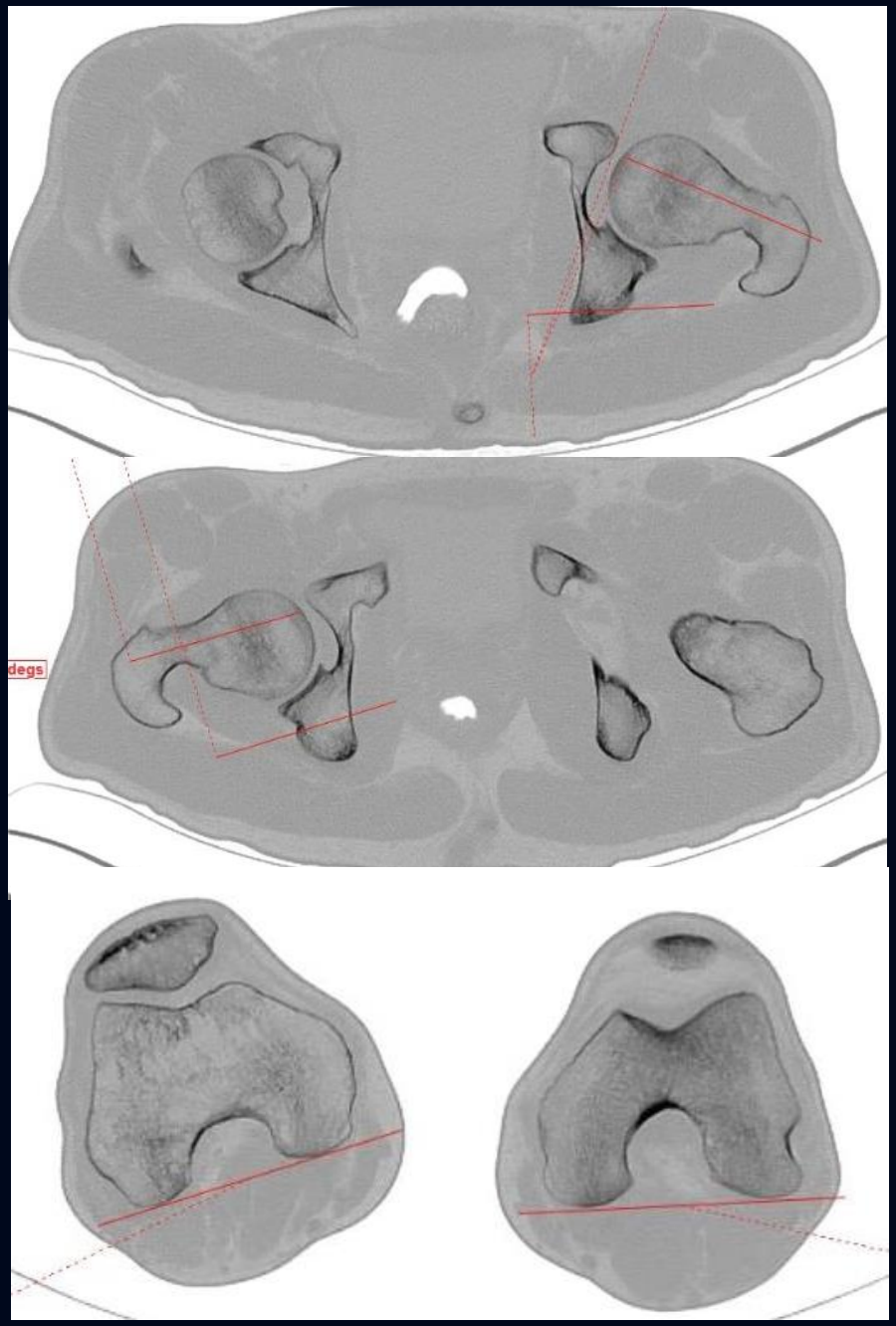

Removal Lengthing Nail

Osteotomy Distal Femur

Rotational Deformity Correction

Insertion Full Length

Conventional Locking Nail

6 Weeks Post-Op

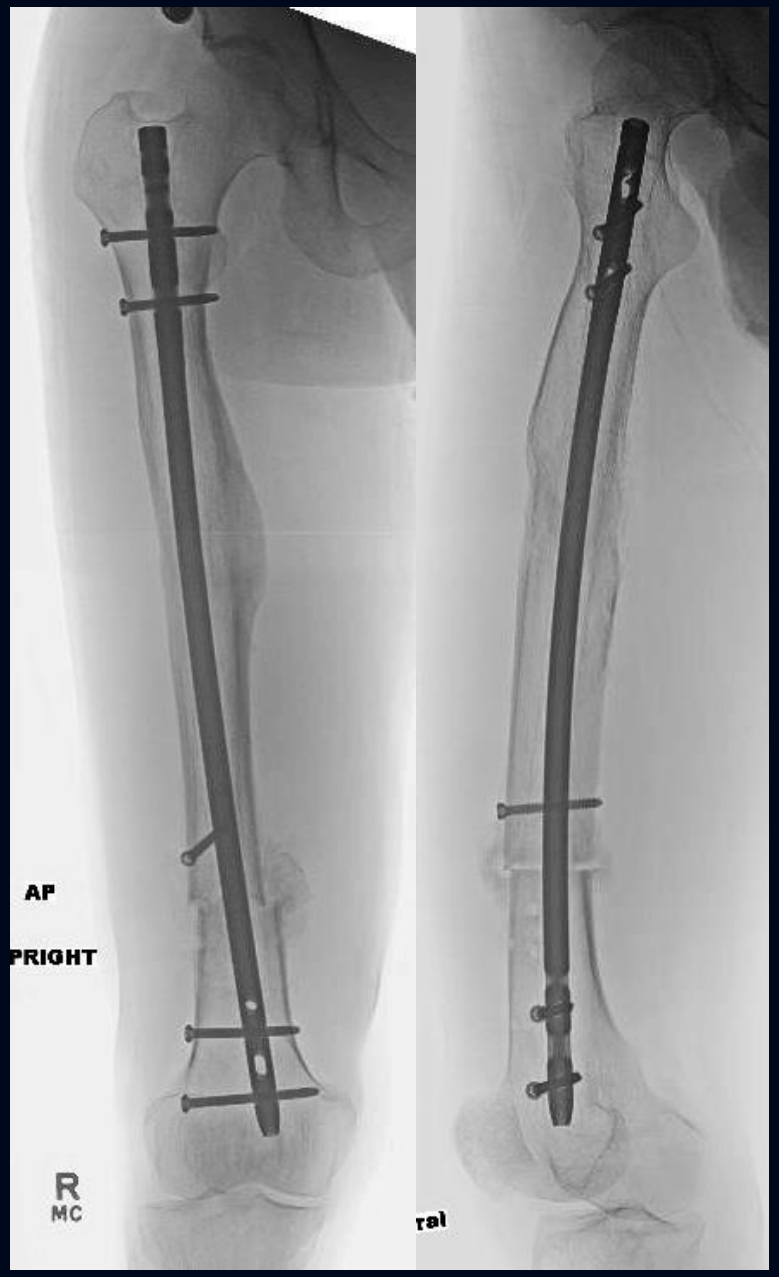

Follow-Up Shows Complete Healing; Length & Rotation Perfect

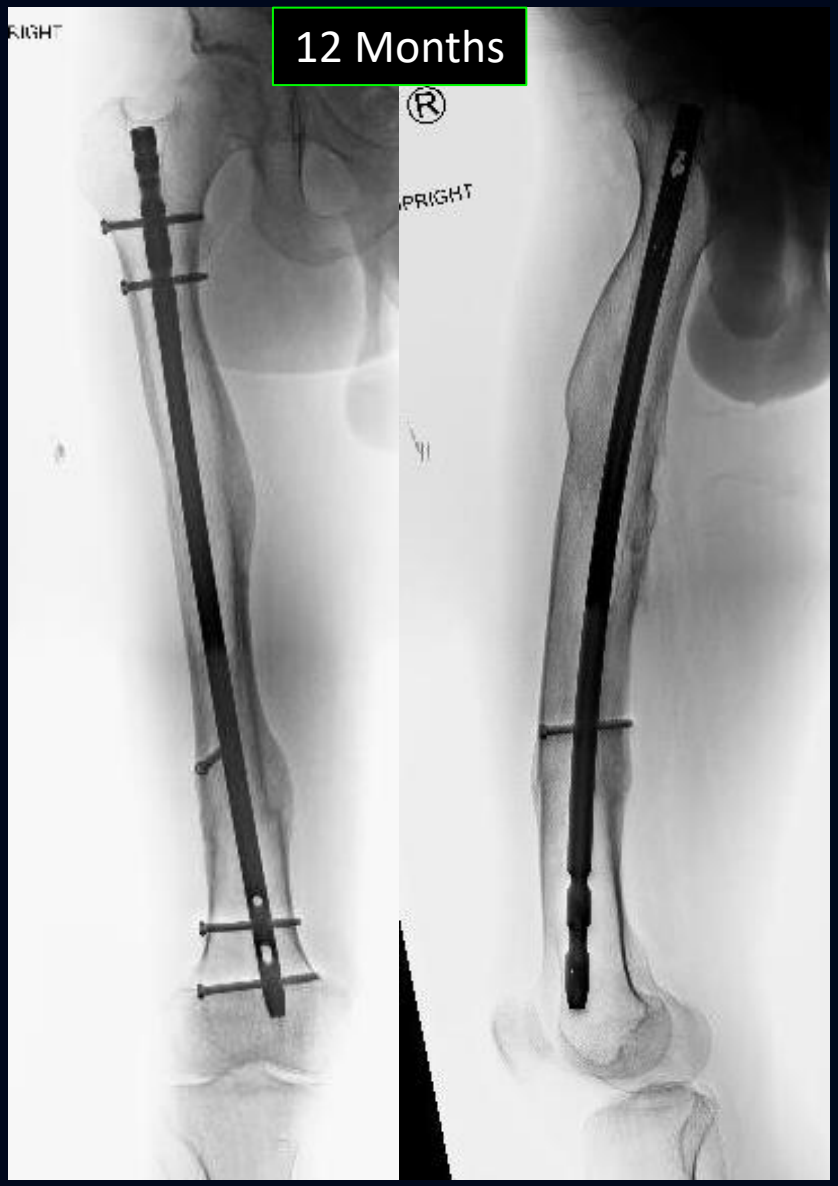


EXIT

Post-Traumatic Deformity & Limb Shortening Treatment With A Magnetic Lengthening Nail

- Technically Demanding Procedure
- Defined Indications For Lengthening
- Real Advance In Patient Care
- Often Done As A 2nd Stage Procedure
- Safe & Effective

Thank You From Beautiful Southern California