

Anterior and Posterior Approaches to the Acetabulum

Amir Matityahu, MD

Professor of Orthopaedic Surgery UCSF Department of
Orthopaedic Surgery

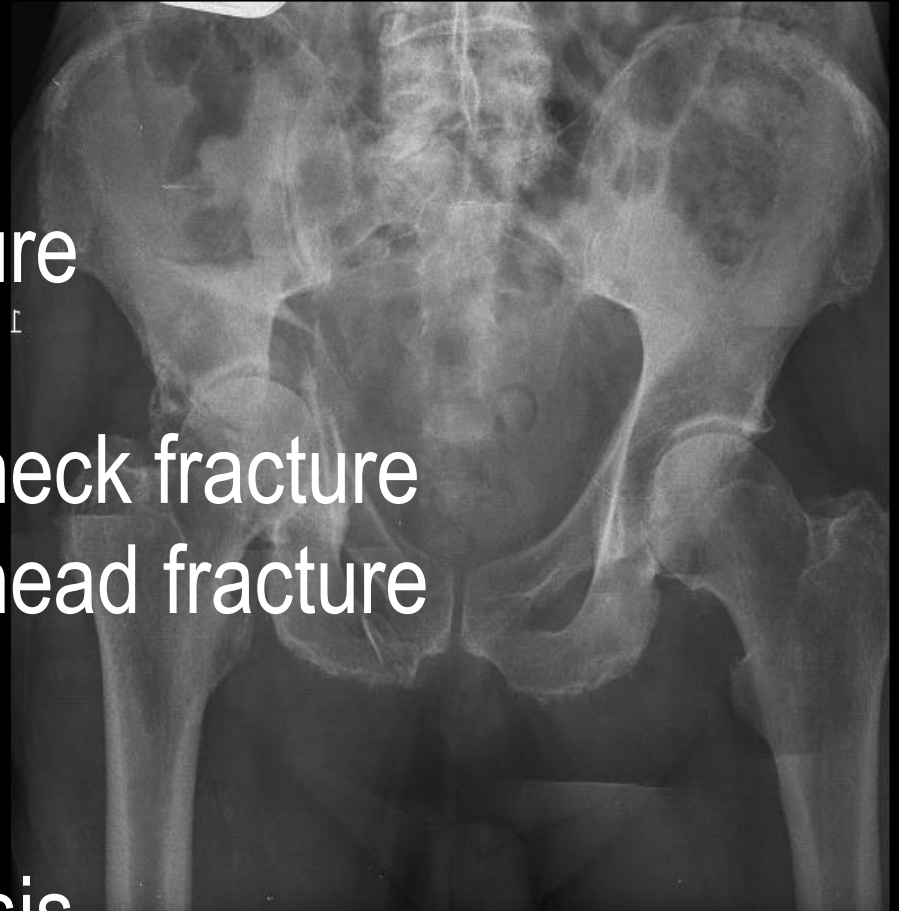Vice President of the Medical Staff, Chairman of Surgery, Chief of
Orthopaedics and Director of Orthopaedic Trauma
Regional Medical Center of San Jose

Common Approaches

- | **Anterior**
 - Stoppa
 - Ilioinguinal
- | Iliac Crest – Lateral Window
- | Kocher Langenbeck
- | Smith Peterson

Impediments to an Anatomical Reduction

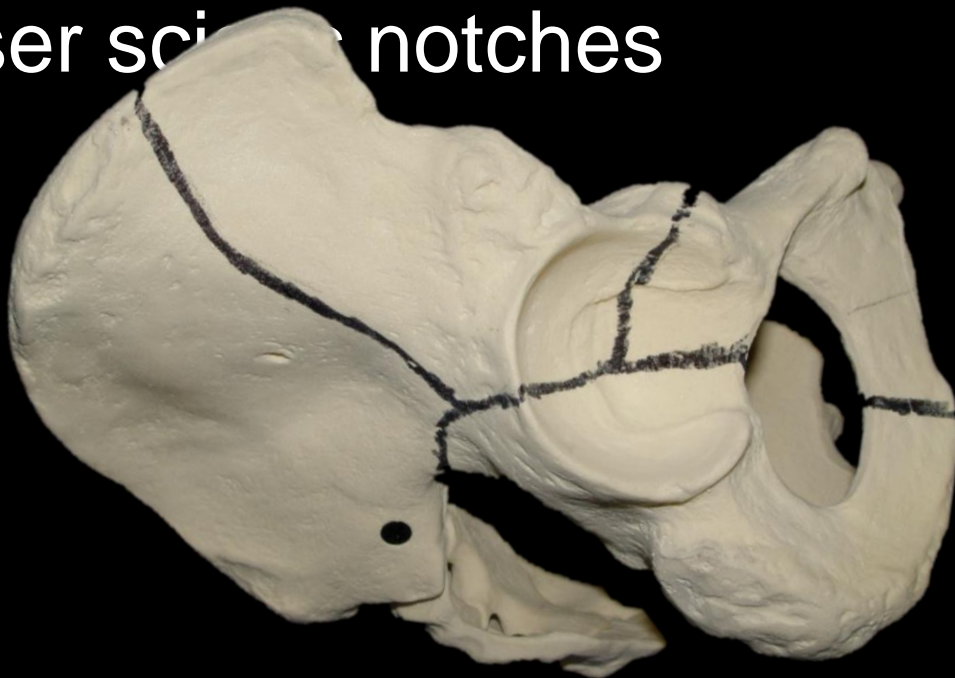
- Osteopenia
- Comminution
- Posterior Wall Fracture
- Dome Impaction
- Associated femoral neck fracture
- Associated femoral head fracture
- Delayed Surgery
- Morbid Obesity
- Previous Hip Arthrosis



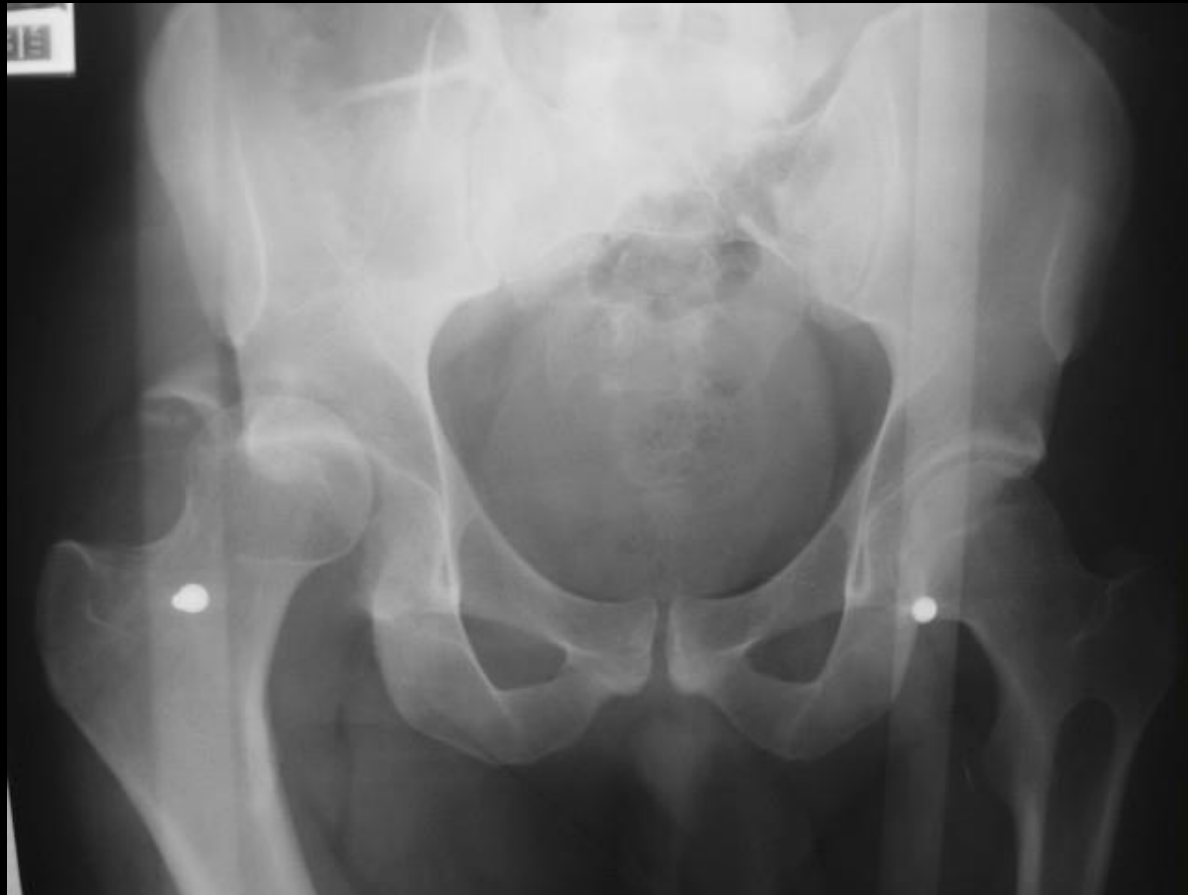Kocher Langenbeck Approach

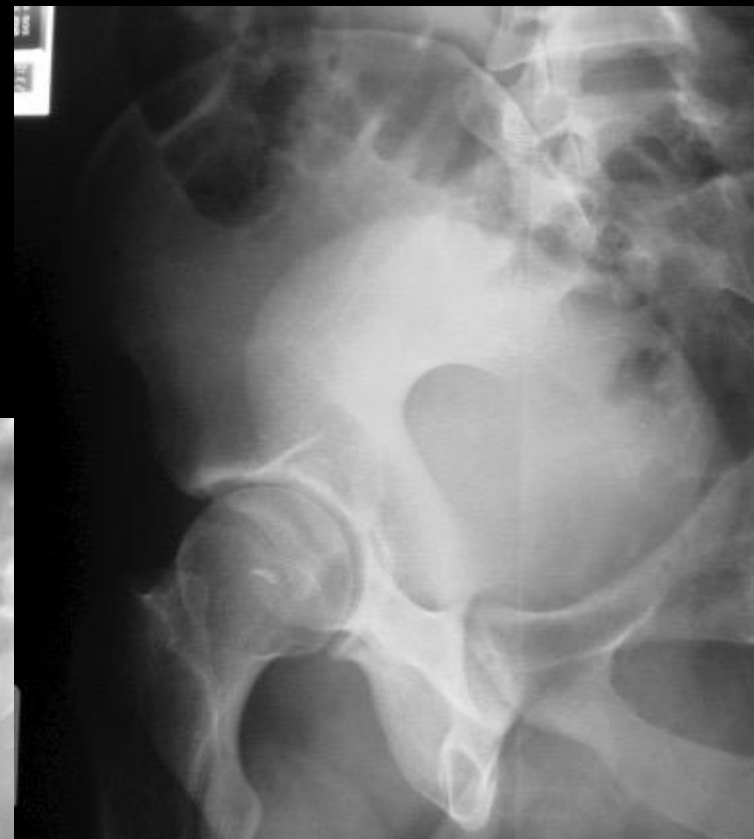
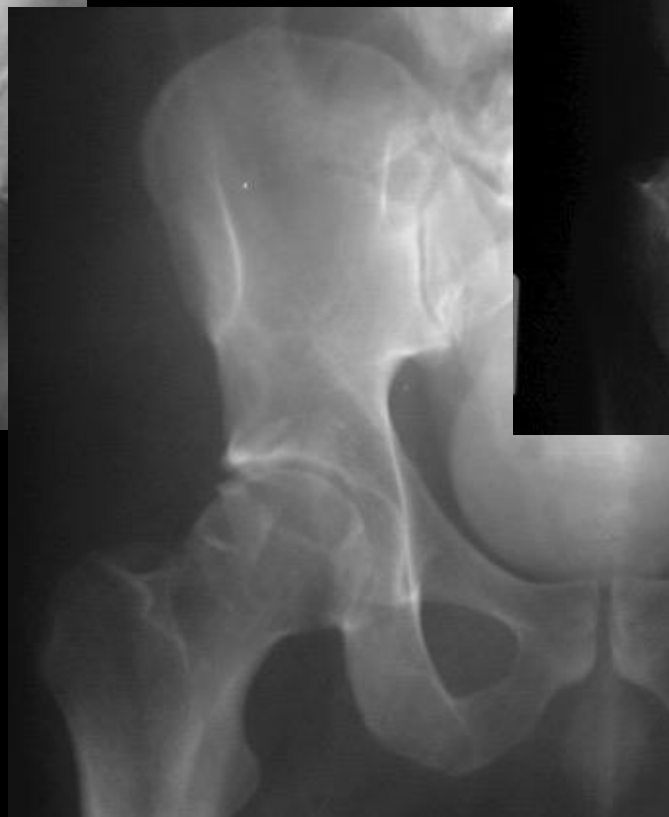
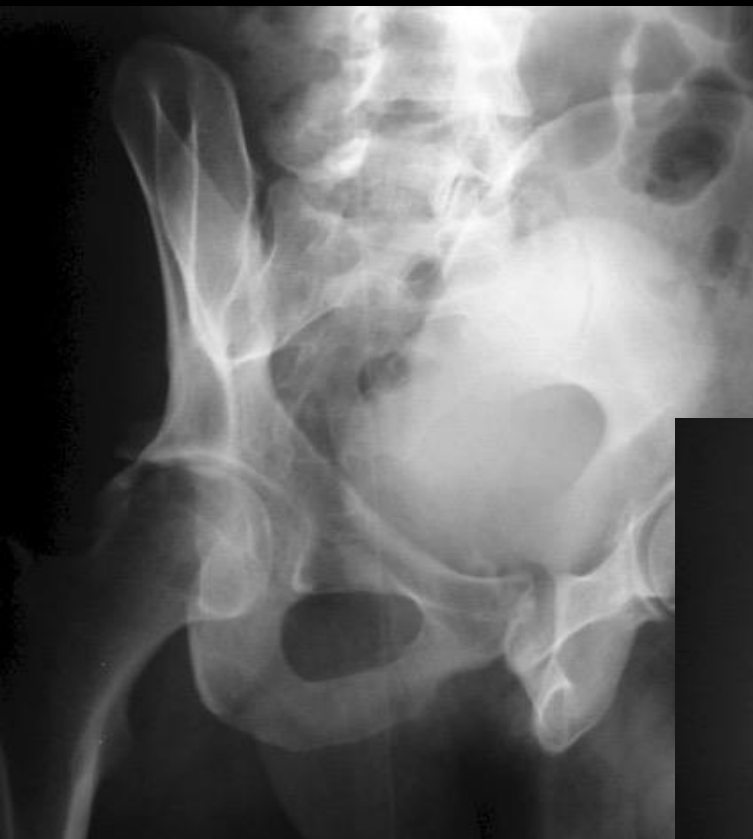Nonextensile approach to posterior acetabular column.

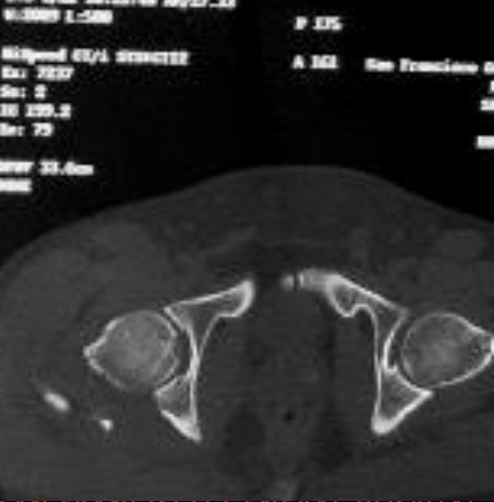
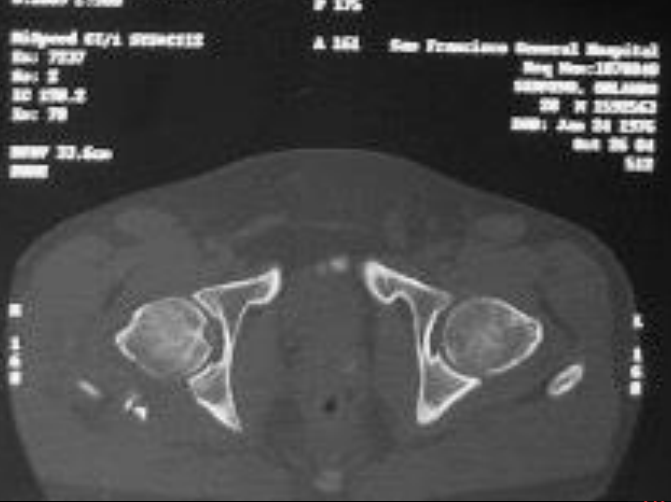
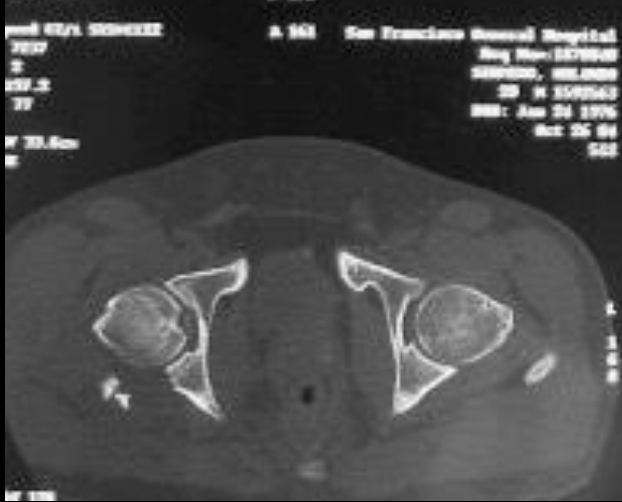
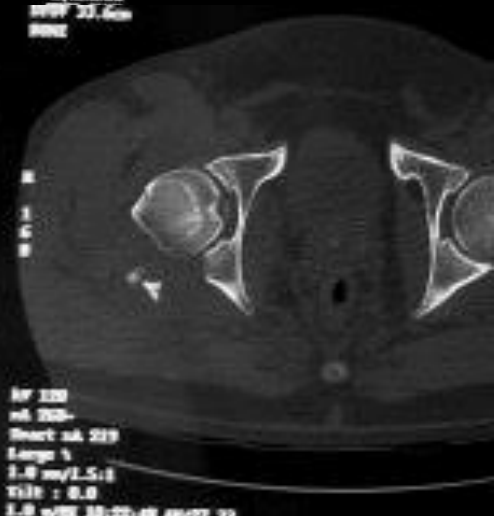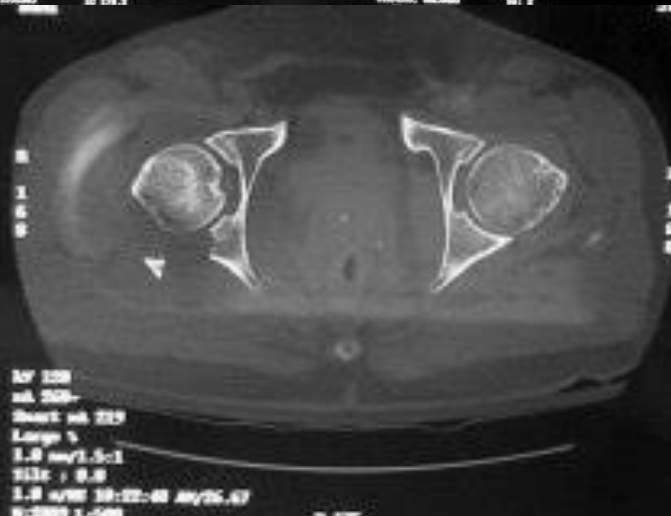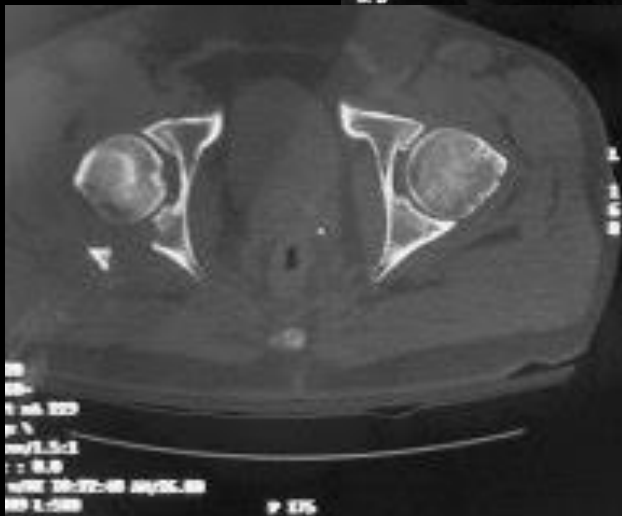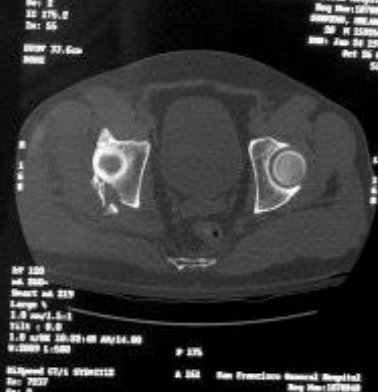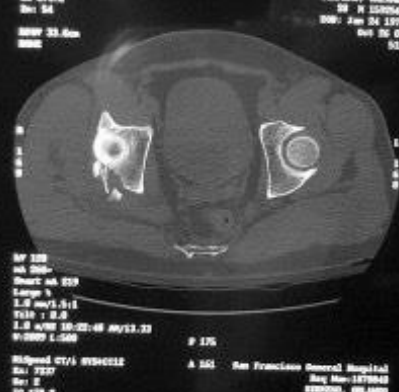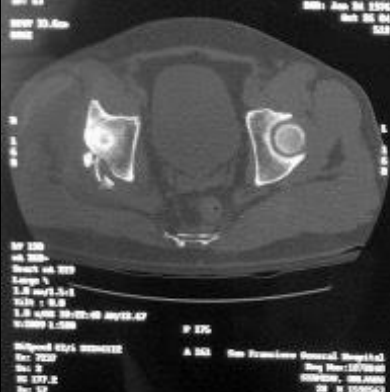Direct visualization of the acetabular articular surface, femoral head, posterior wall, posterior column, ischium, and greater and lesser sciatic notches

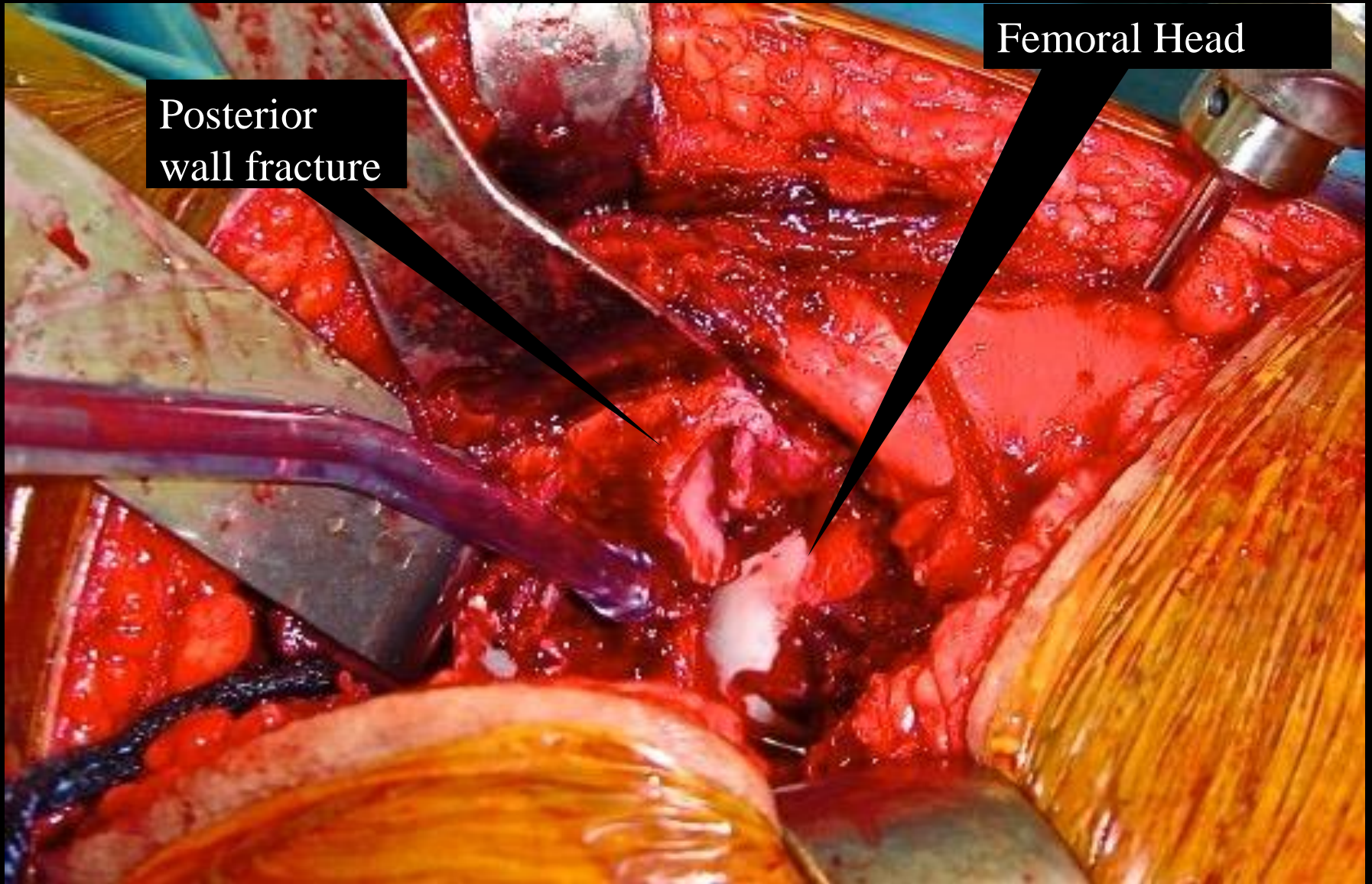


Comminuted Posterior Wall



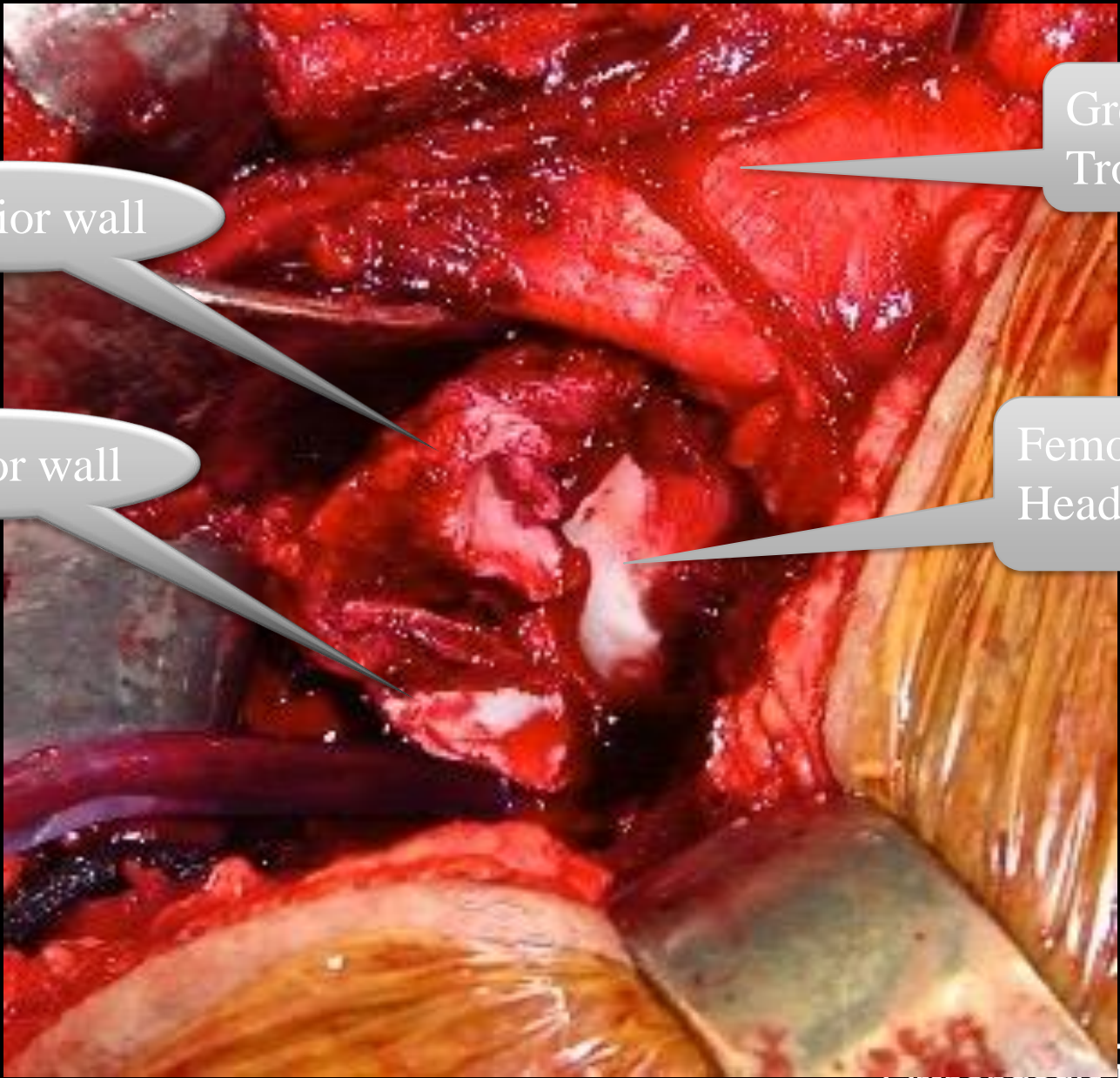






Femoral Head

Posterior wall fracture

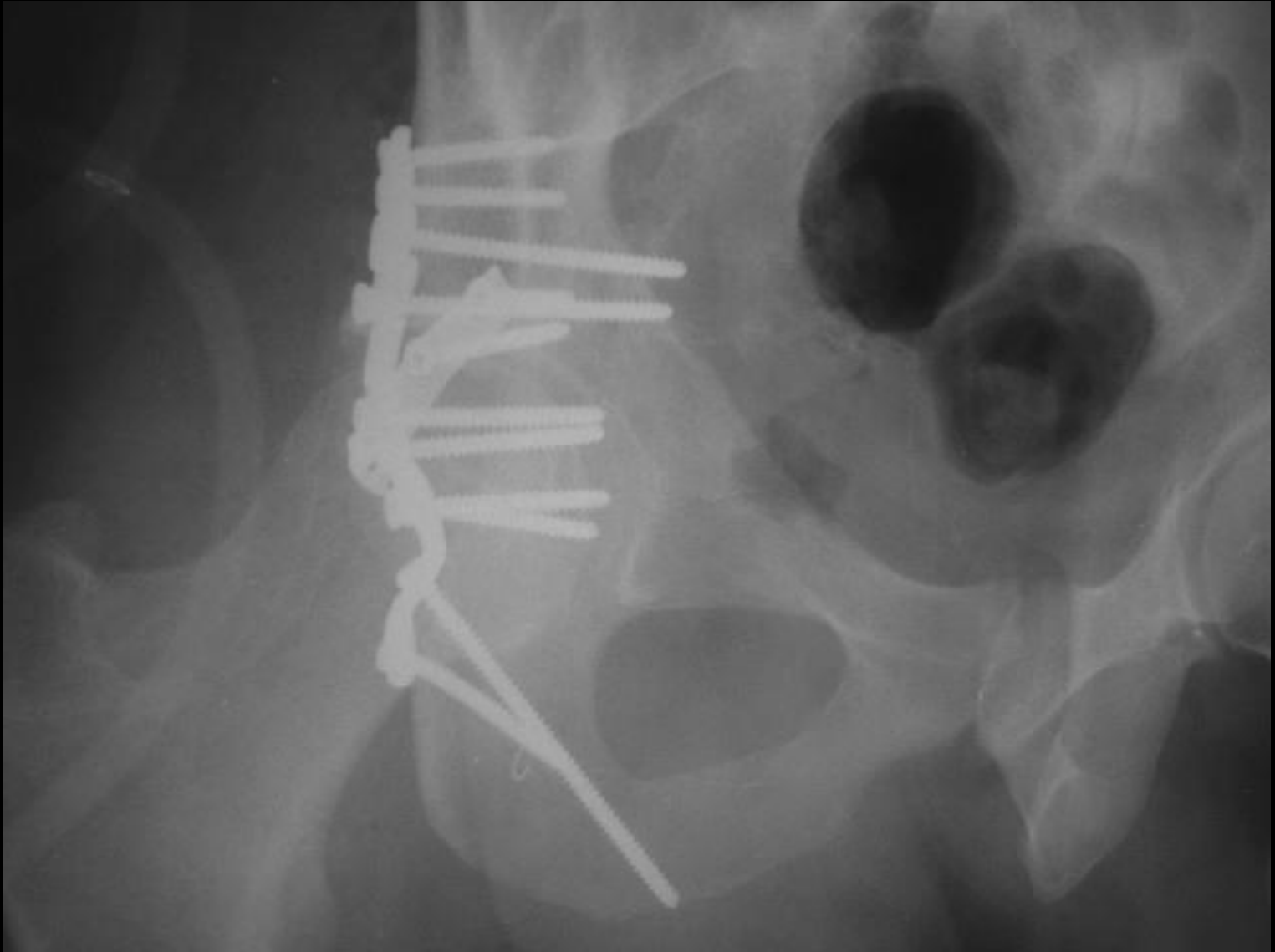


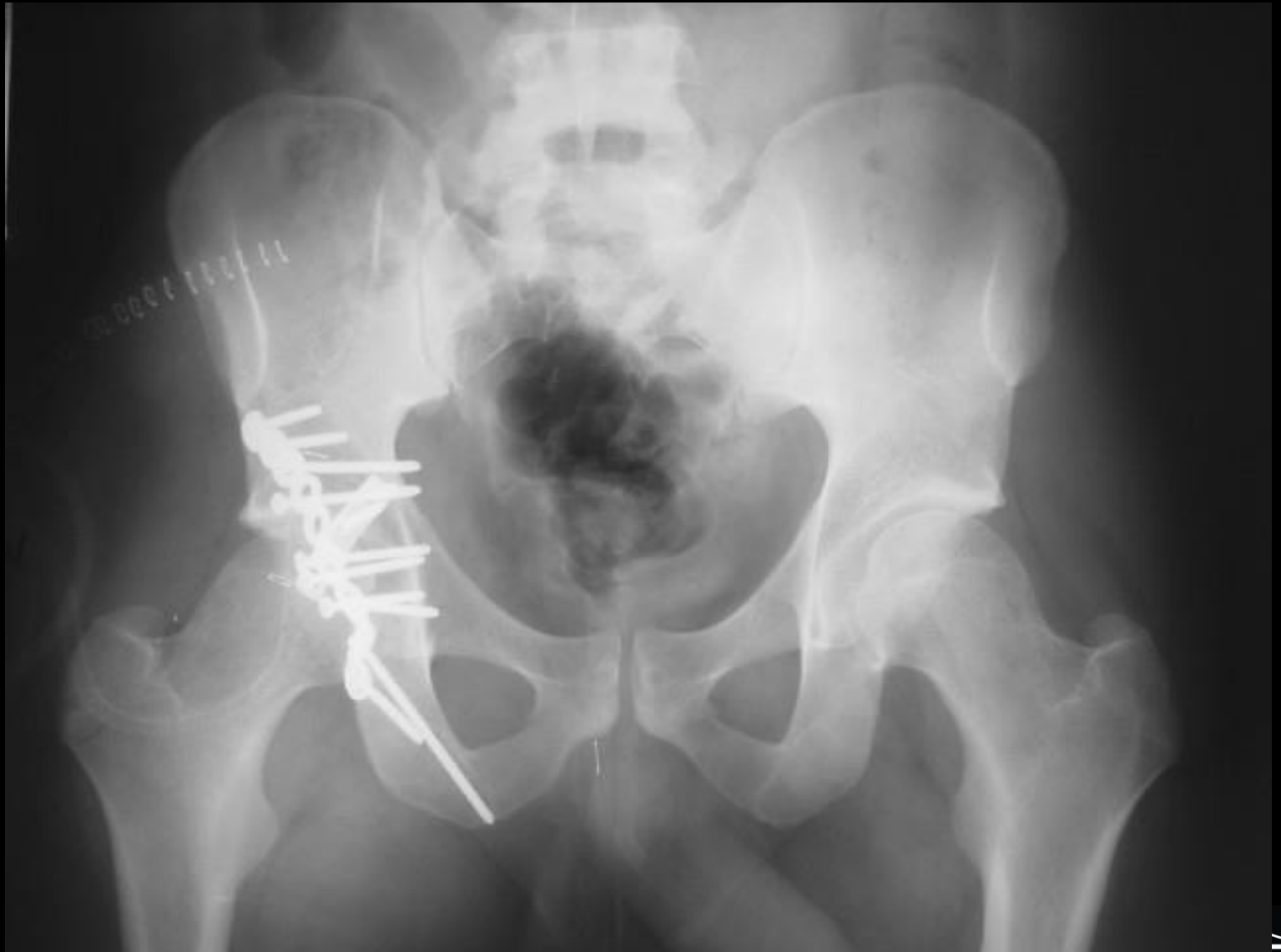Greater Trochanter

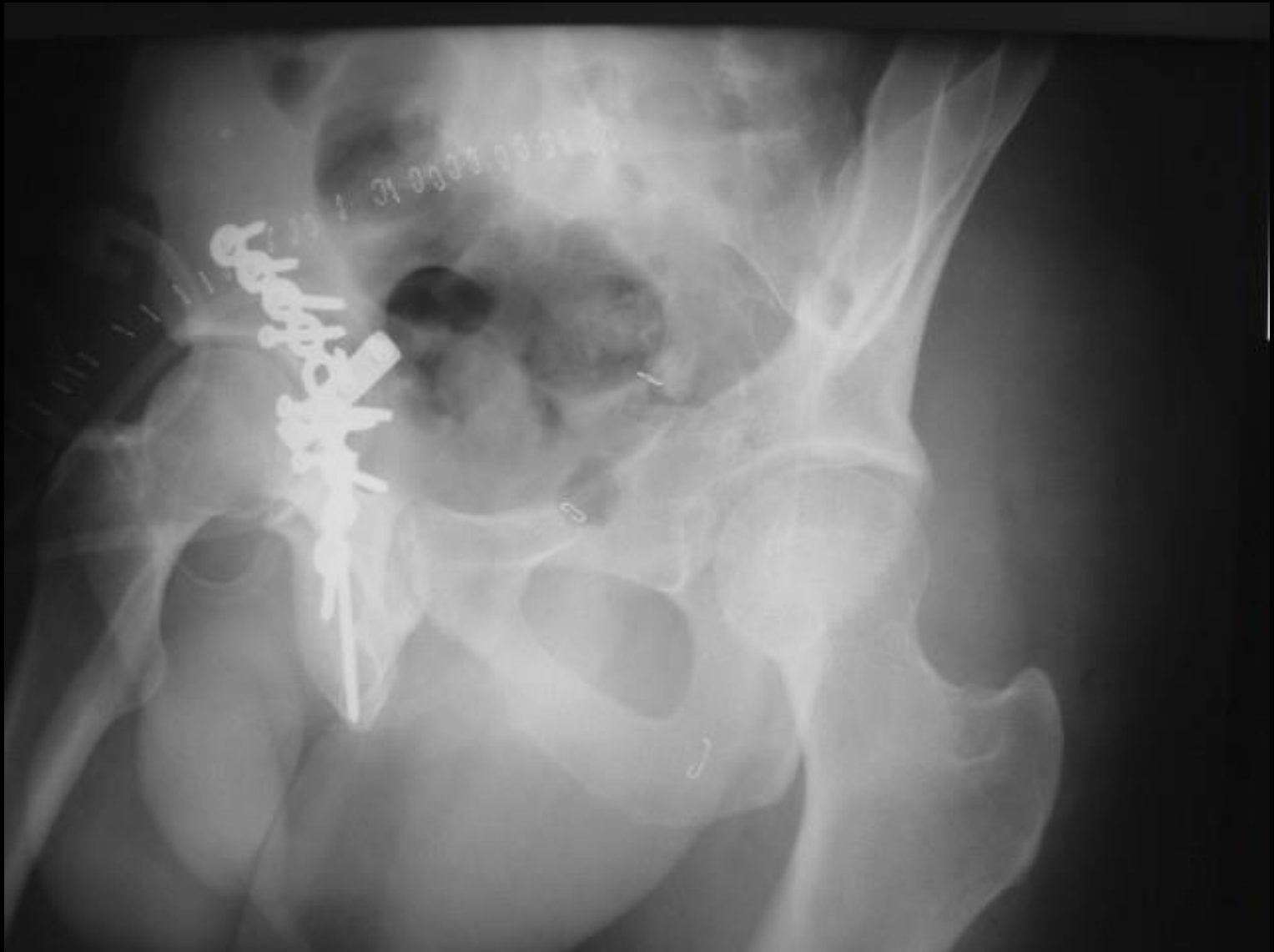Femoral Head

Posterior wall

Posterior wall





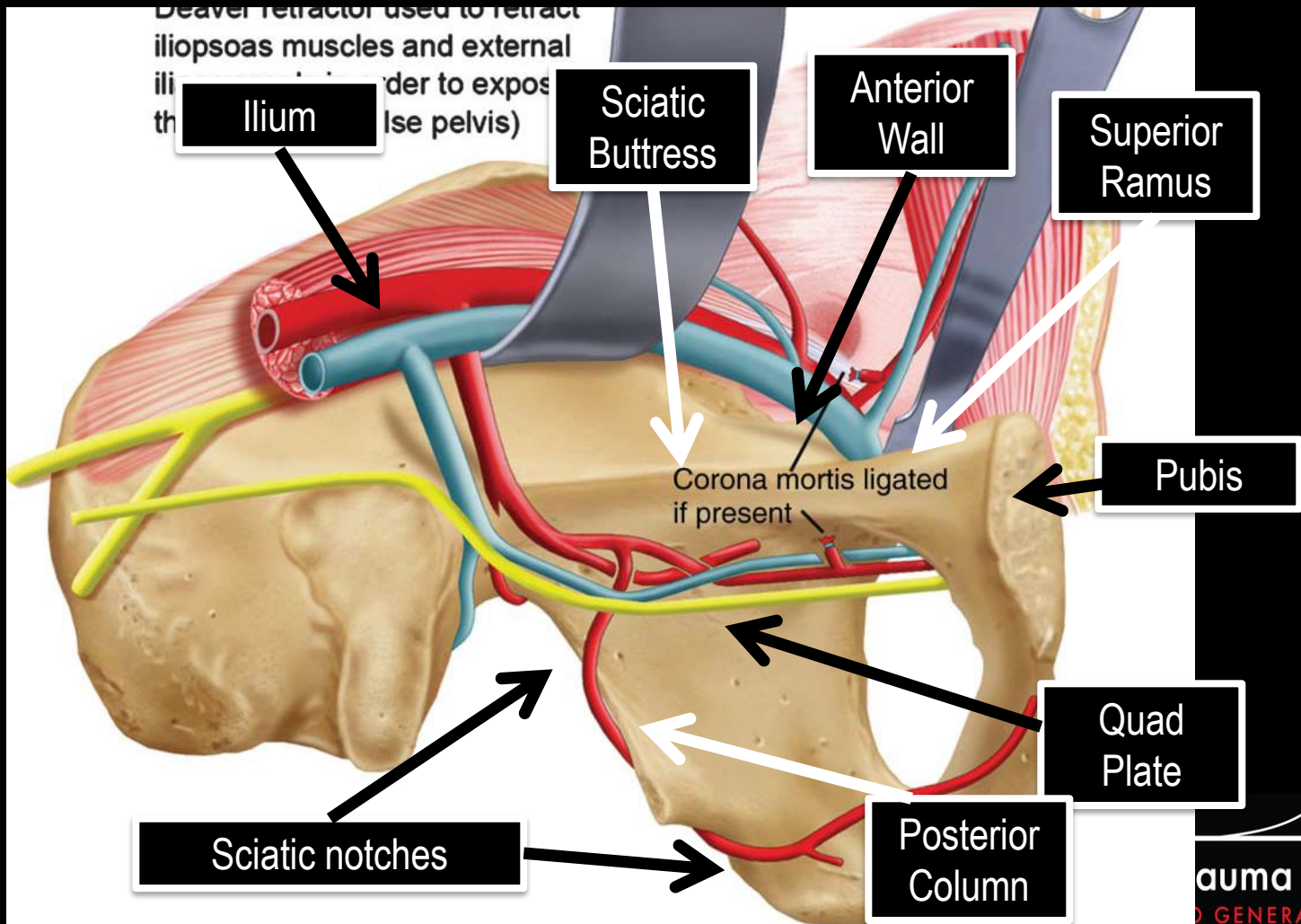


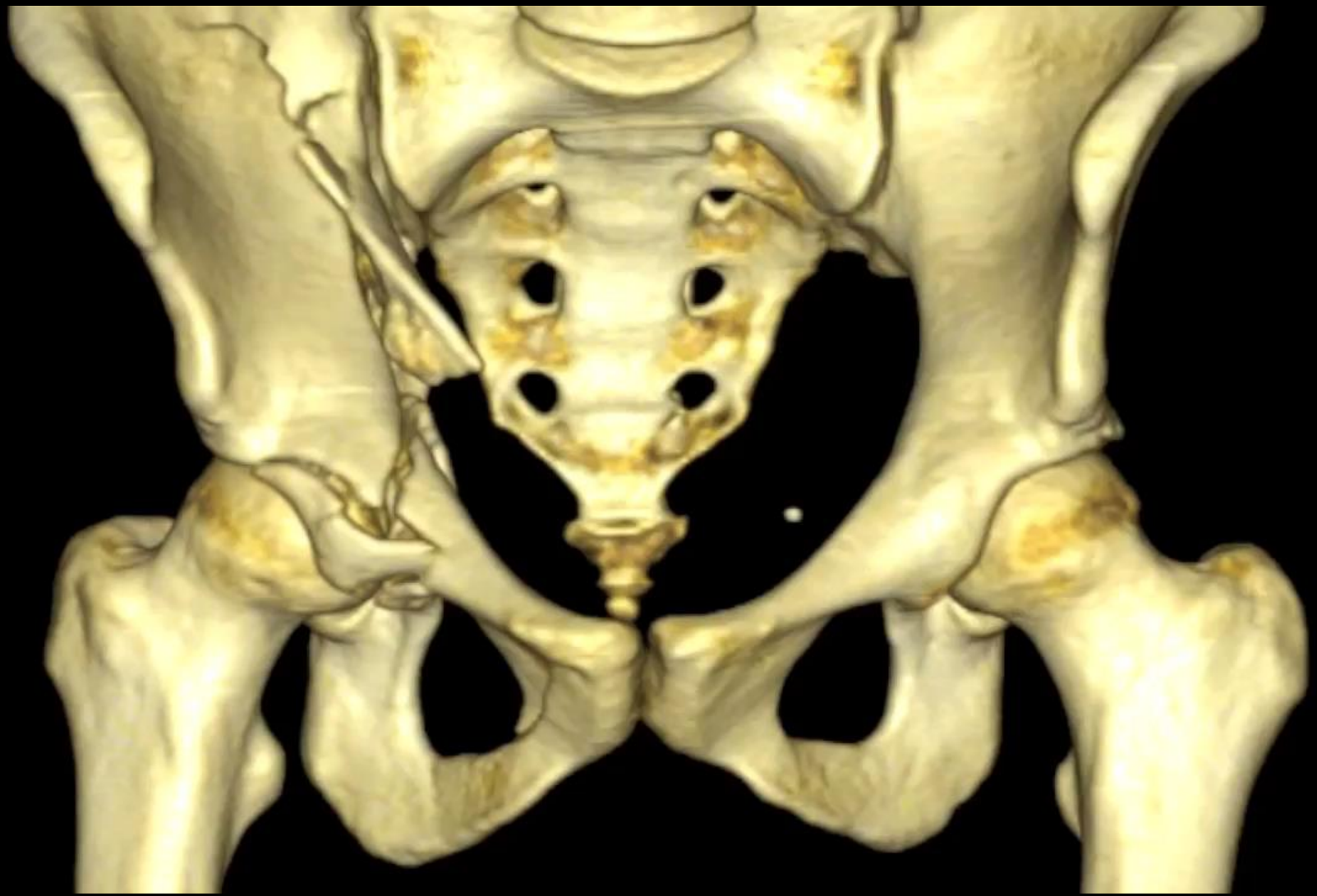
Stoppa

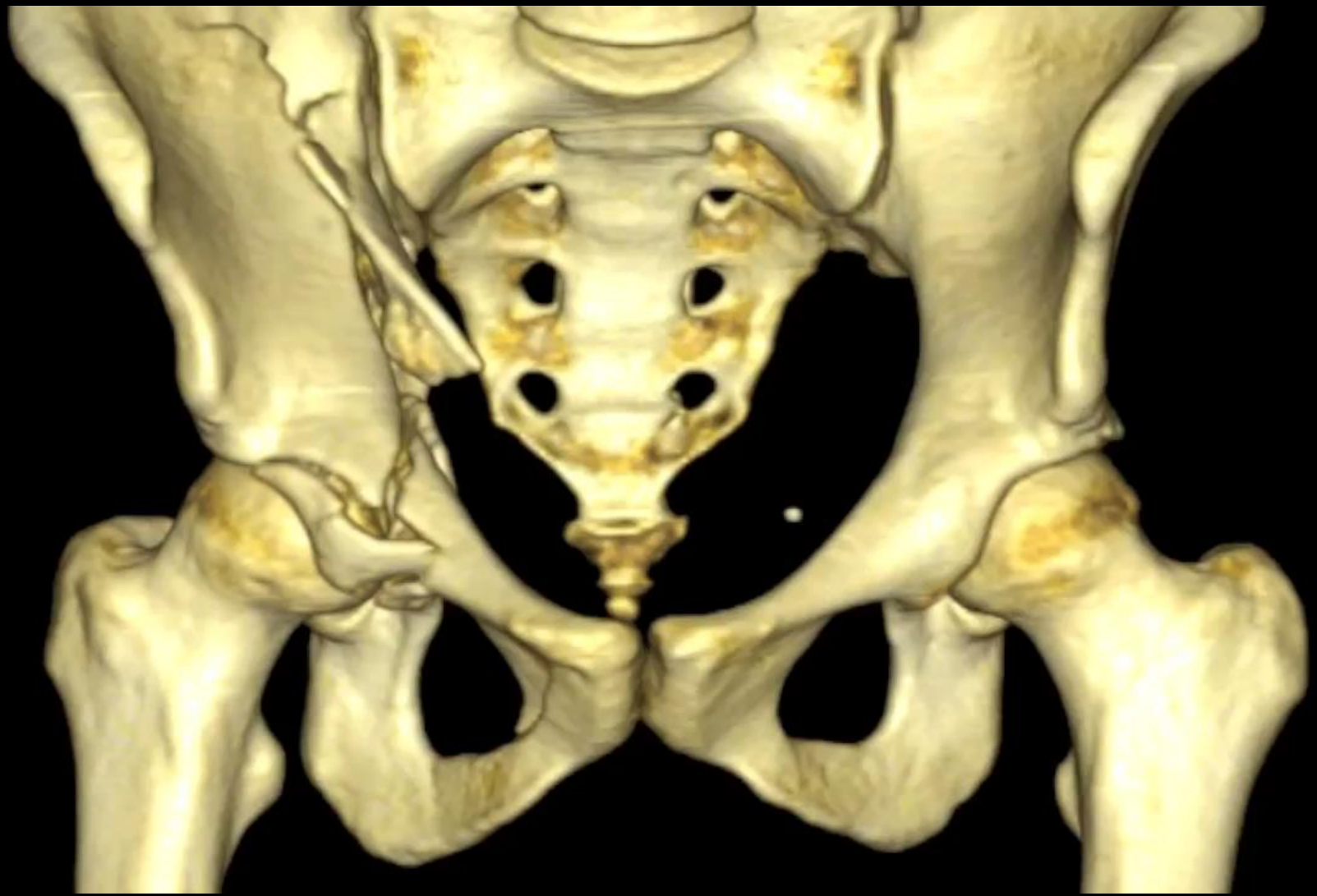
- | What can you see?
 - Pubis
 - Superior pubic ramus
 - Pubic root
 - Ilium
 - Quadrilateral plate
 - Medial aspect of posterior column
 - Sciatic buttress
 - Anterior SI joint

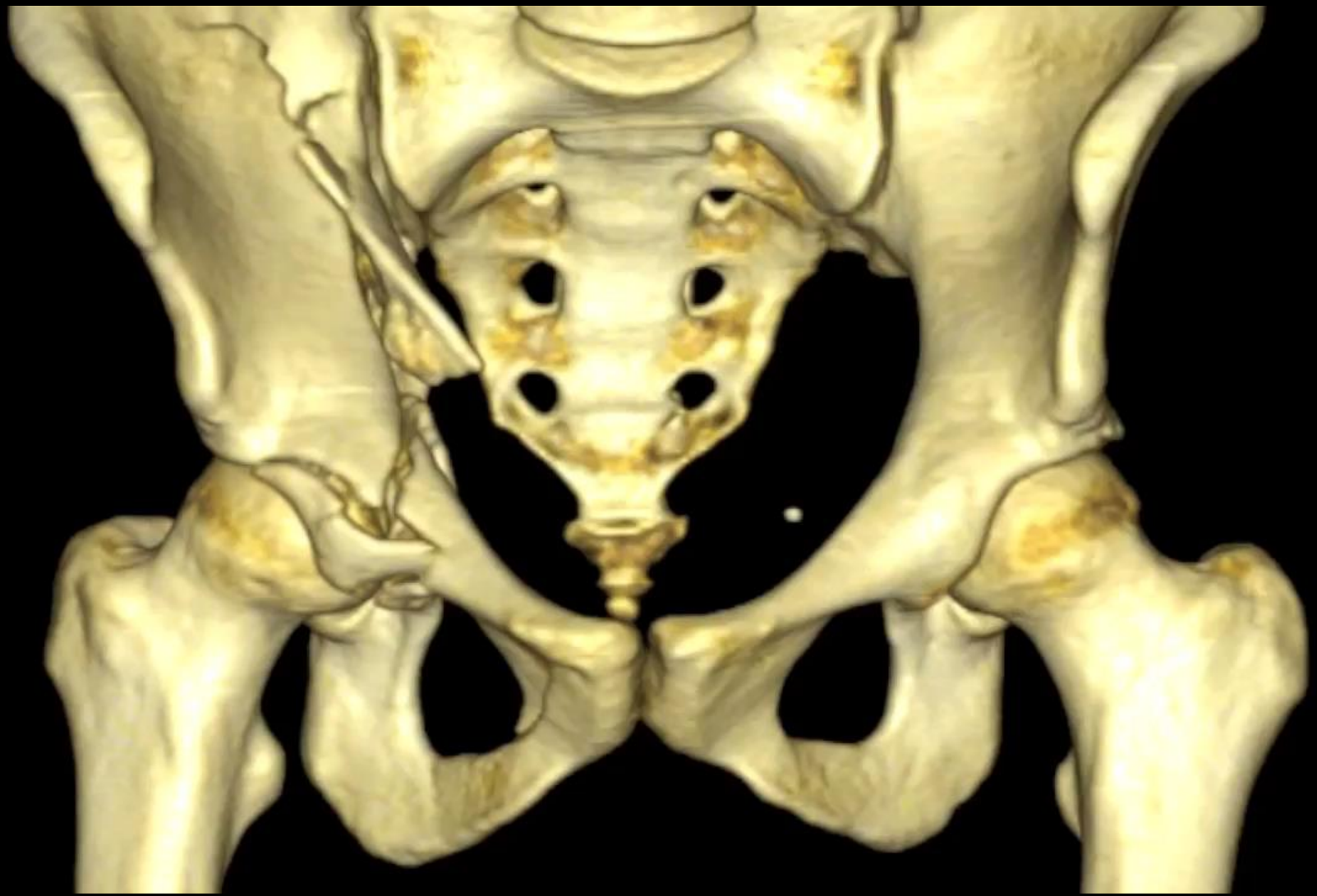
Anatomy

Anterior Abdominal Wall









Thank you

