



The Department of Orthopaedic Surgery  
University of California San Francisco School of Medicine



# UCSF Arthroplasty for the Modern Surgeon: Hip, Knee and Health Innovation Technology in Sonoma

Thursday - Friday

**September 15-16, 2022**

Fairmont Sonoma Mission Inn • Sonoma, CA

## PRIMARY TKA Case Review

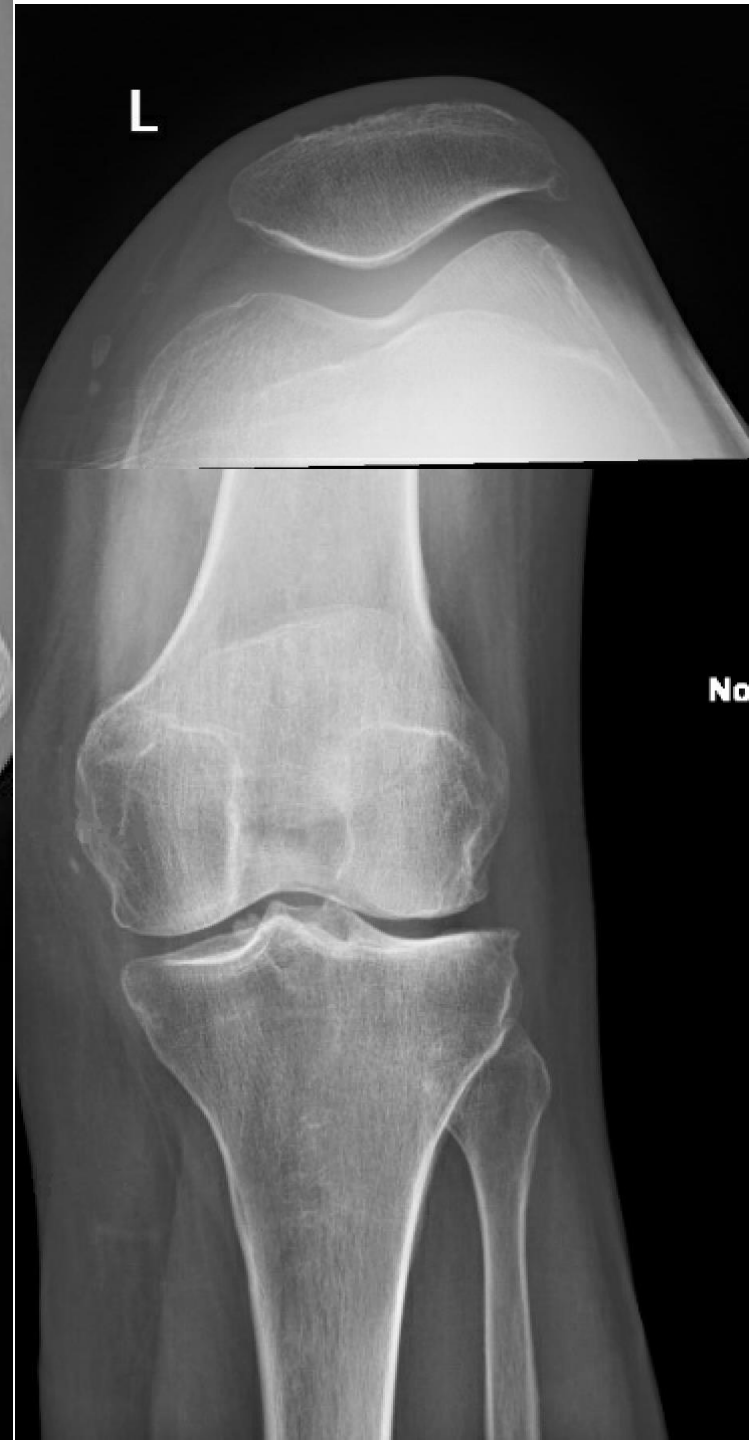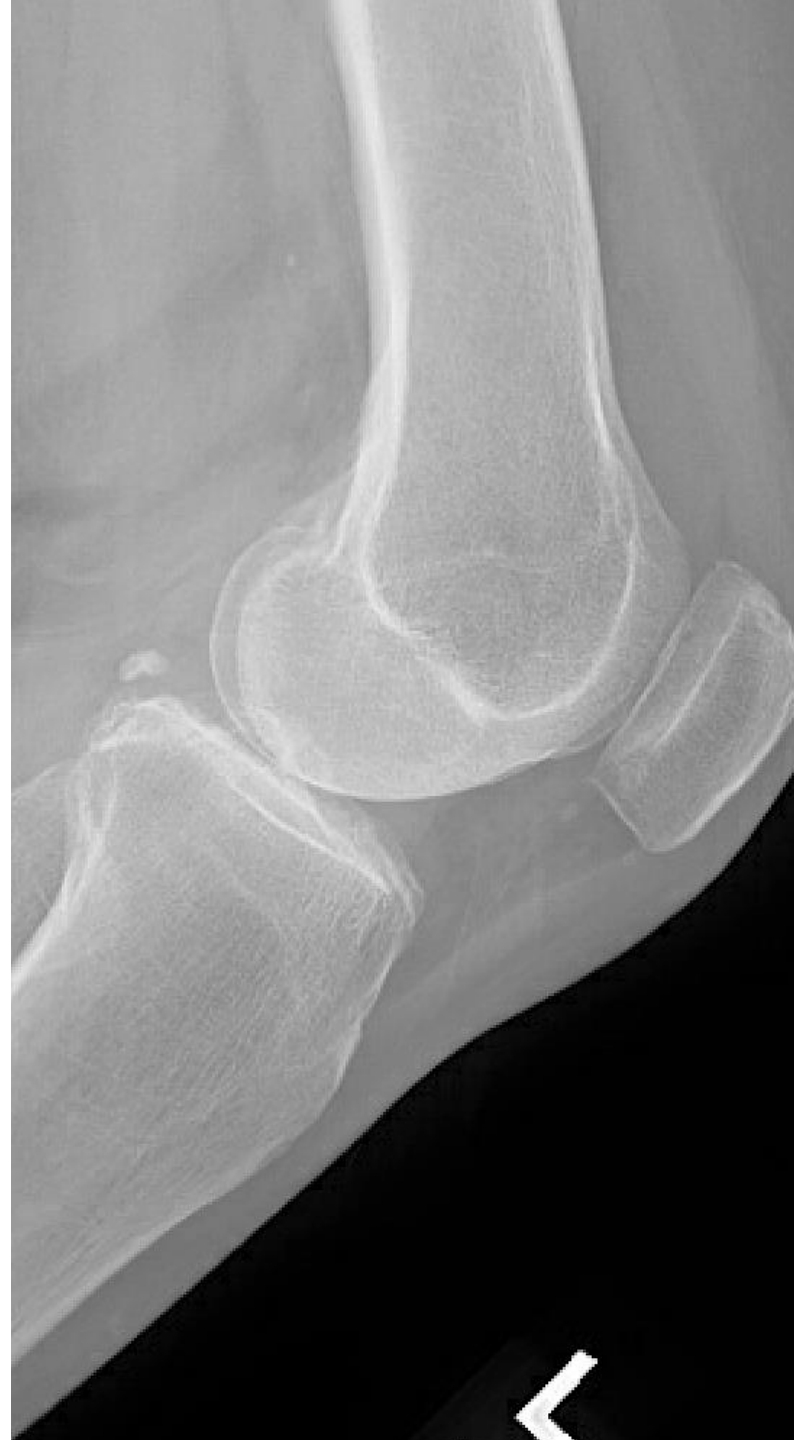[Register Now!](#)

Stefano Bini MD

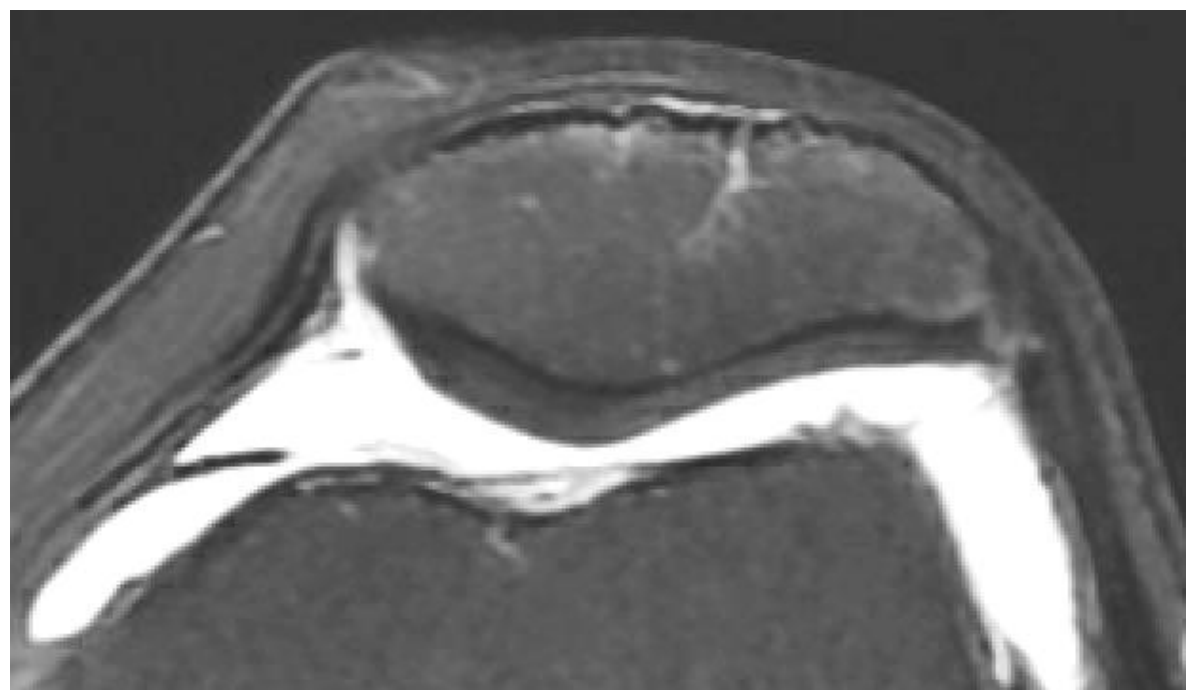
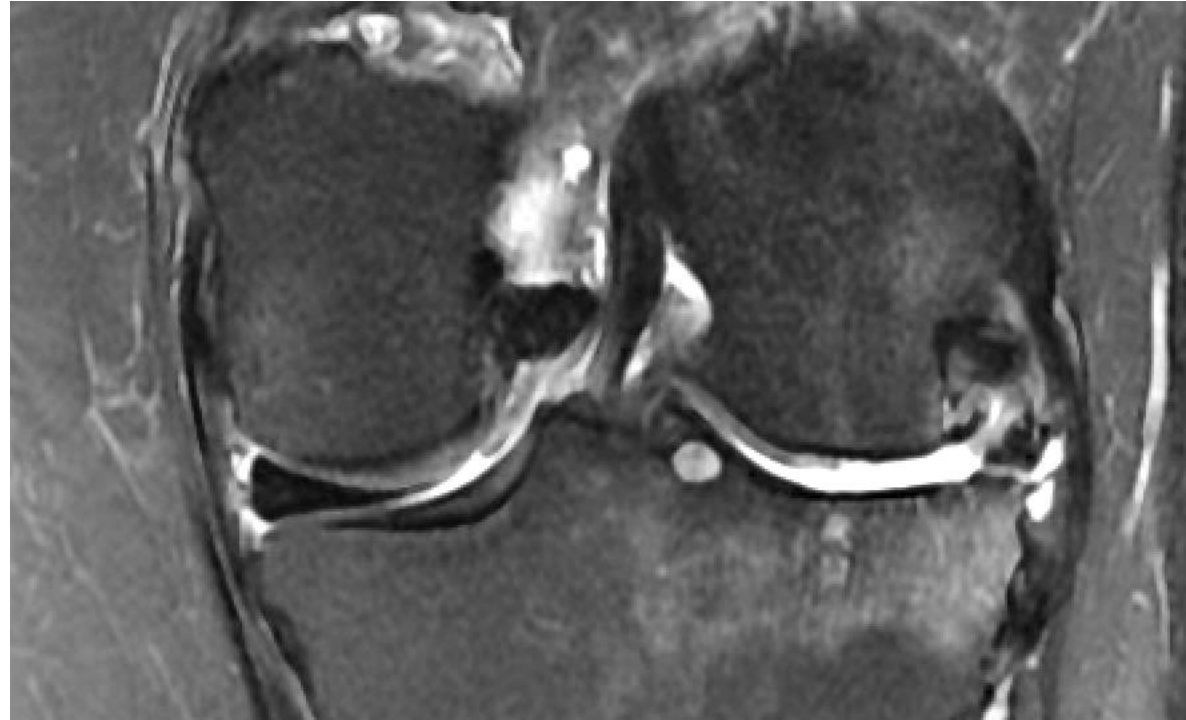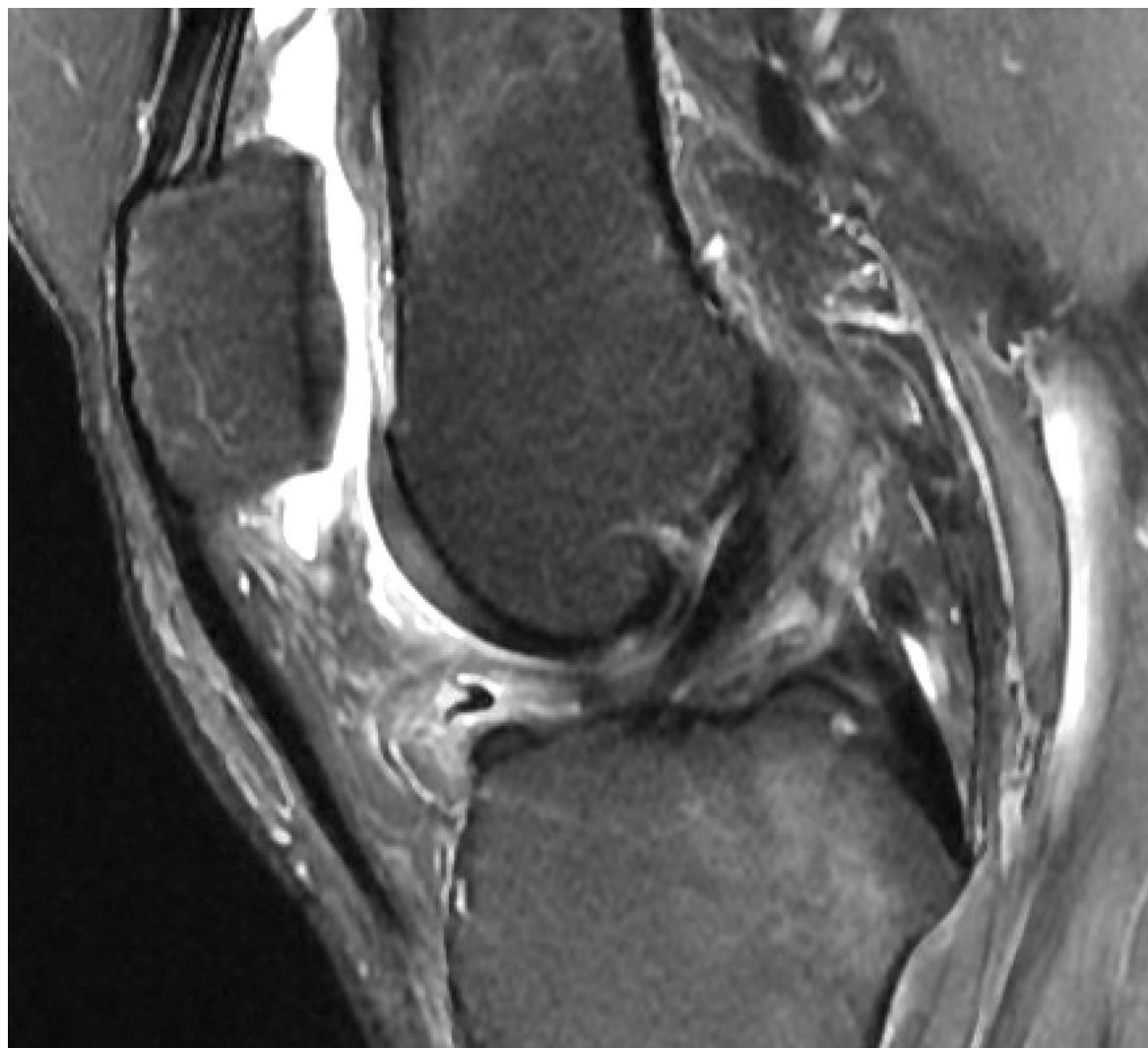
Sonoma 2022

UCSF Arthroplasty for the Modern Surgeon: Hip, Knee and Health Innovation  
Technology in Sonoma

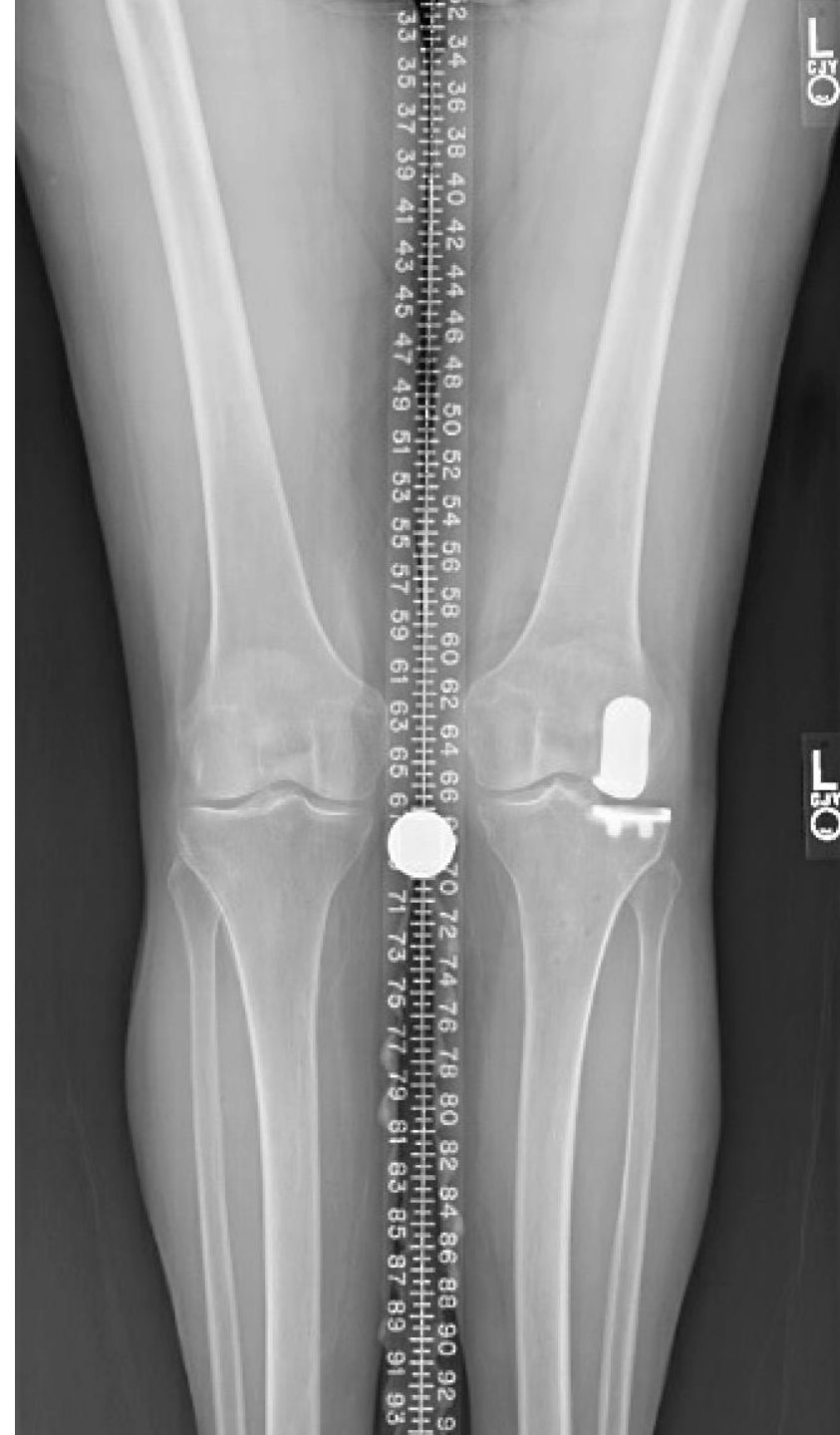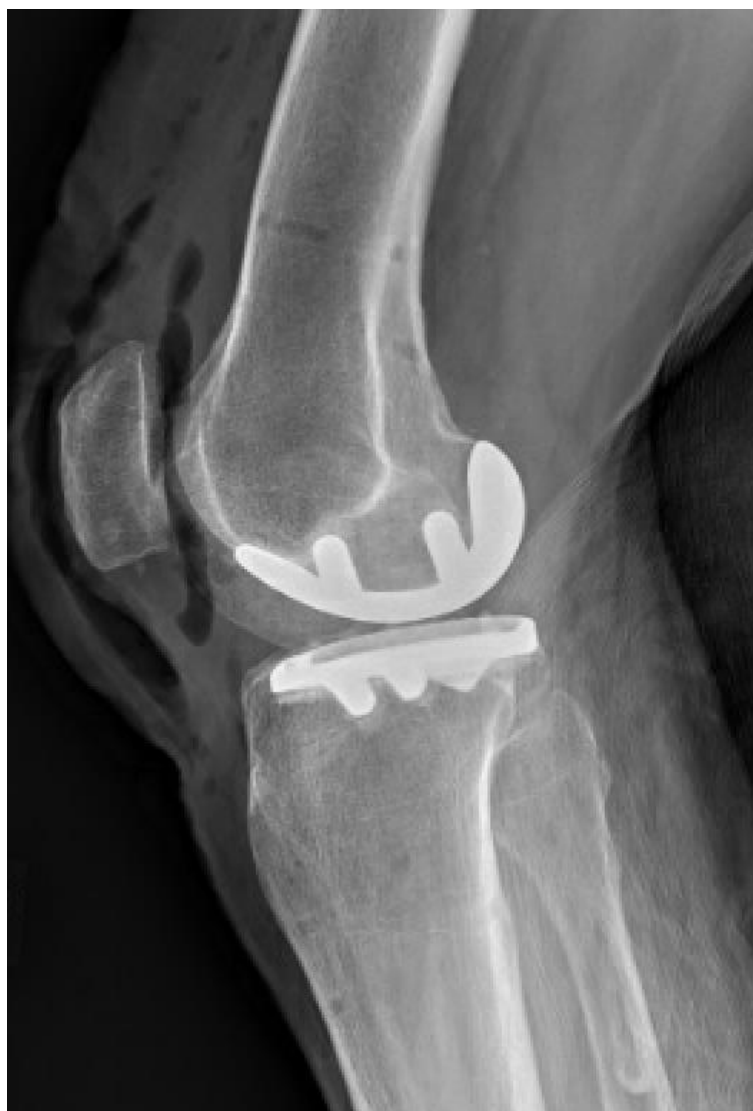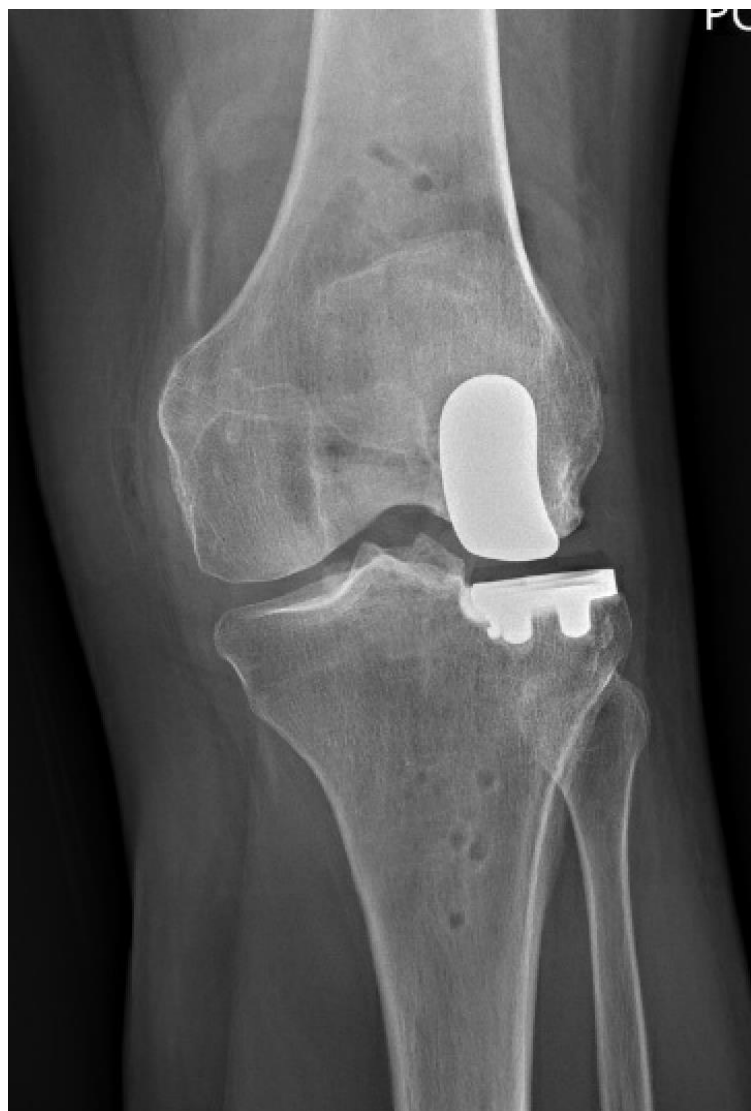74 yo Lateral  
Knee pain.  
HIV+  
Duragesic  
Patch for  
Neuropathy  
10 mg  
Prednisone  
Had injections



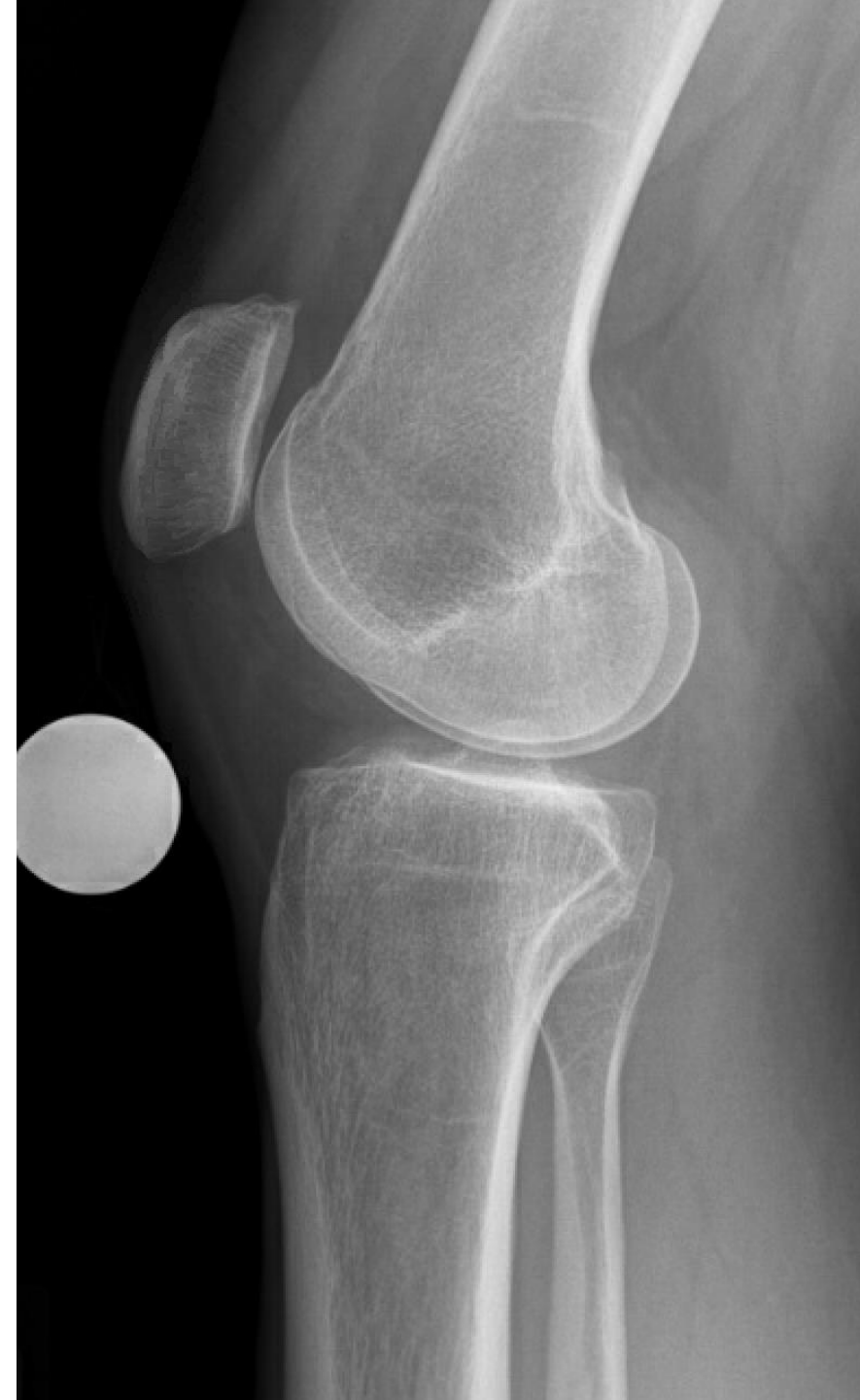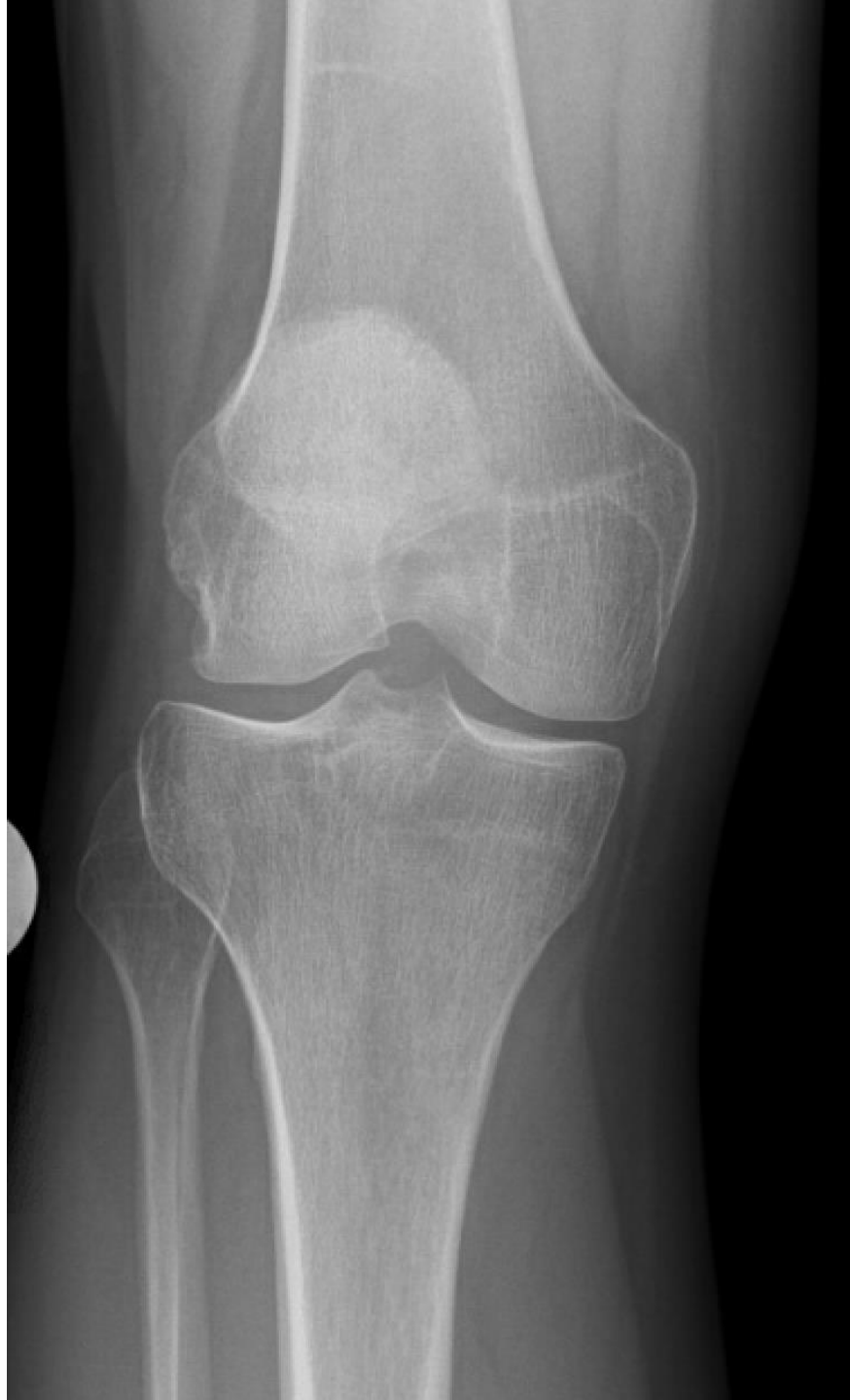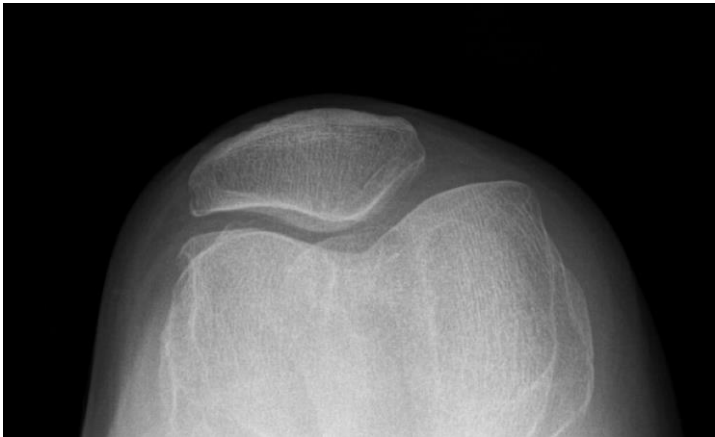
# MRI



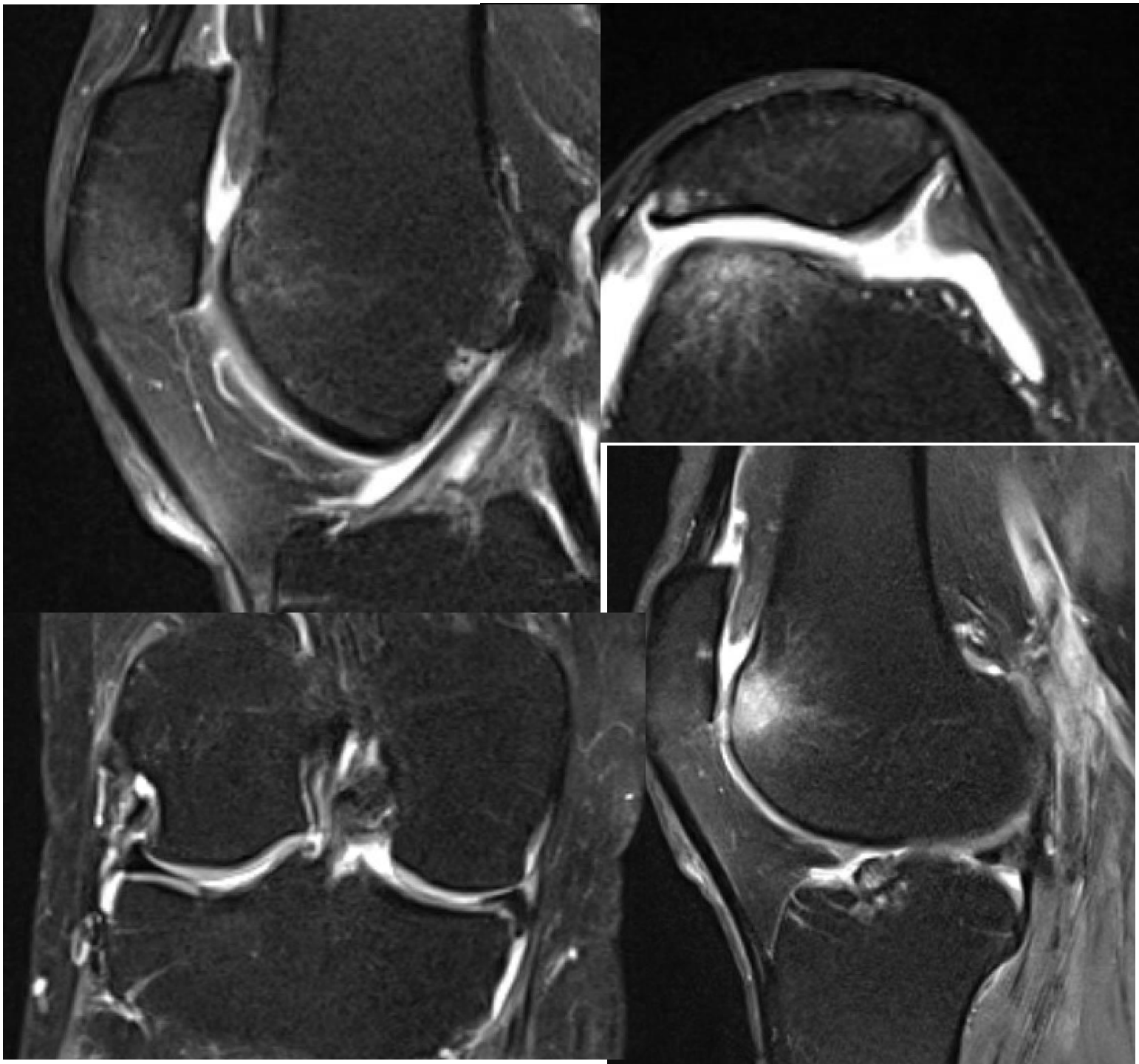
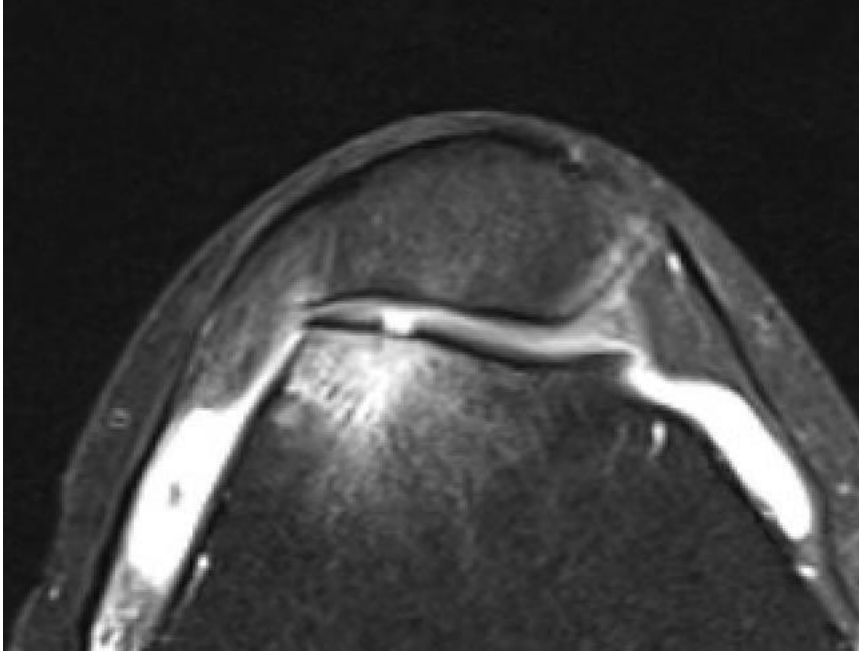
# Lateral UKA



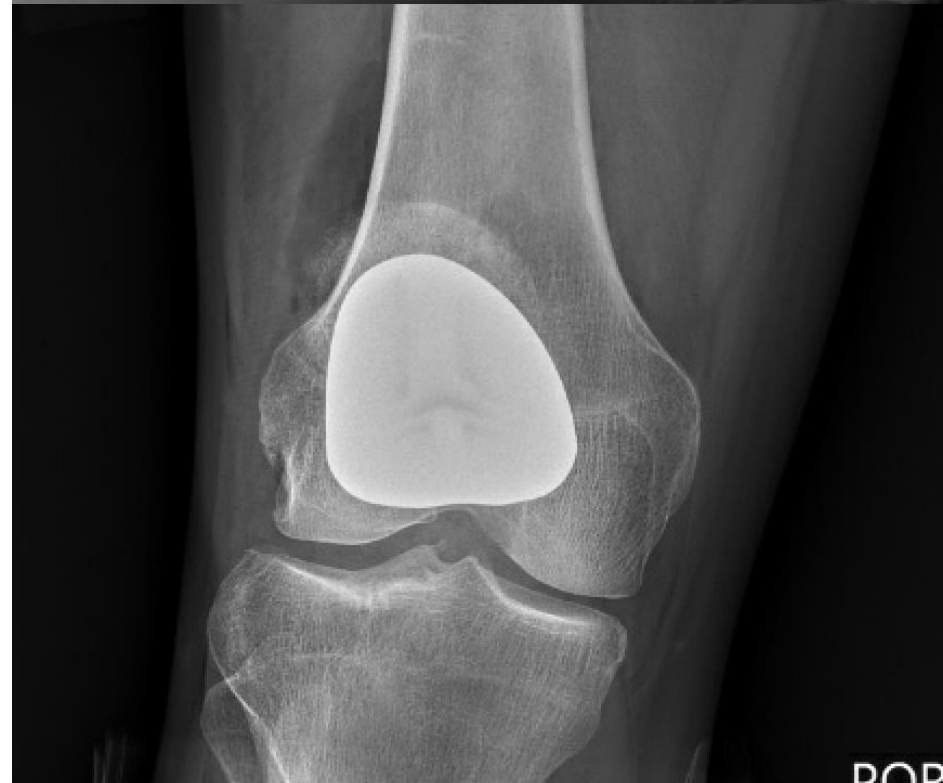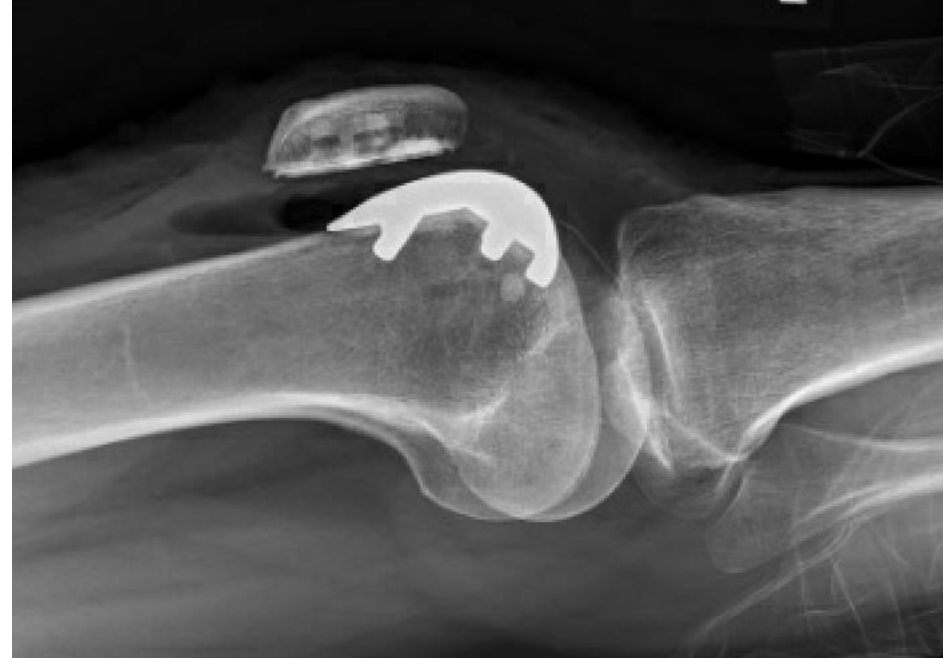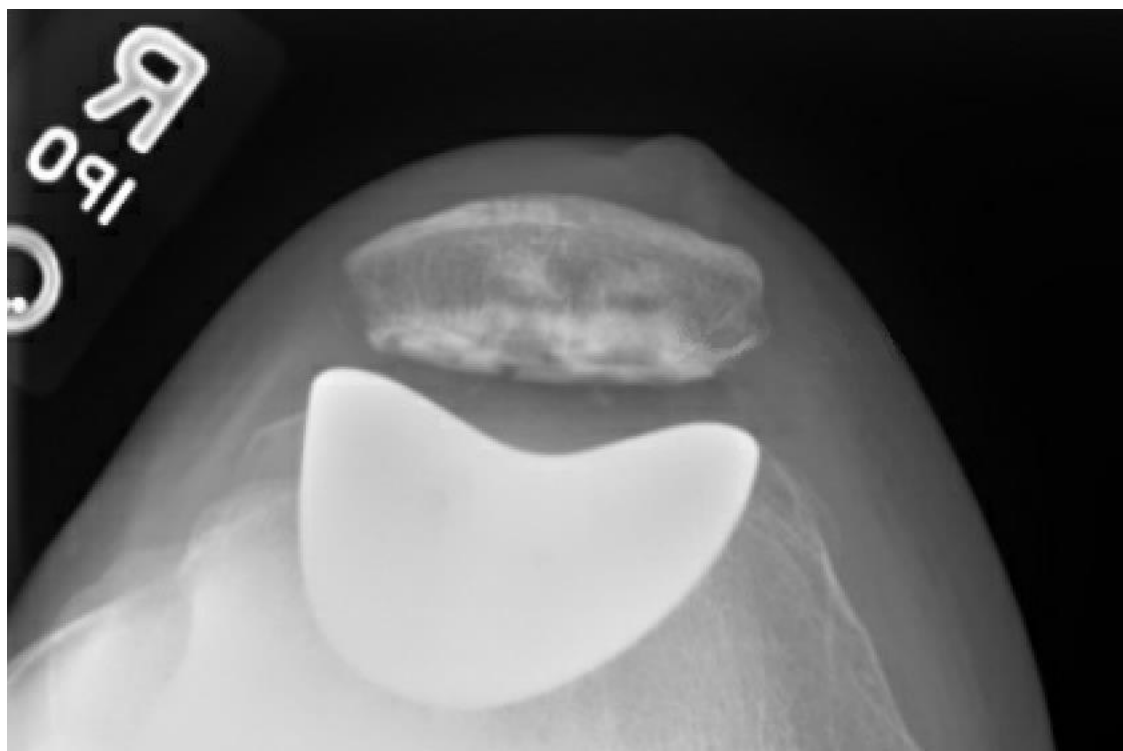
47 yo Female  
trouble  
climbing, hills,  
stairs. Failed  
PT, some relief  
from steroids



47 yo Knee pain



PFA



67 yo female

- Limp: yes
- Anti-inflammatory medication tried: Yes
- Home exercise/activities: walking
- Ambulatory capacity: 1-3 blocks
- Assistive devices: not using a cane or other assistive device
- Physical therapy tried: Yes
- Weight gain/loss: has been stable
- Corticosteroid injections and/or viscosupplementation tried: No

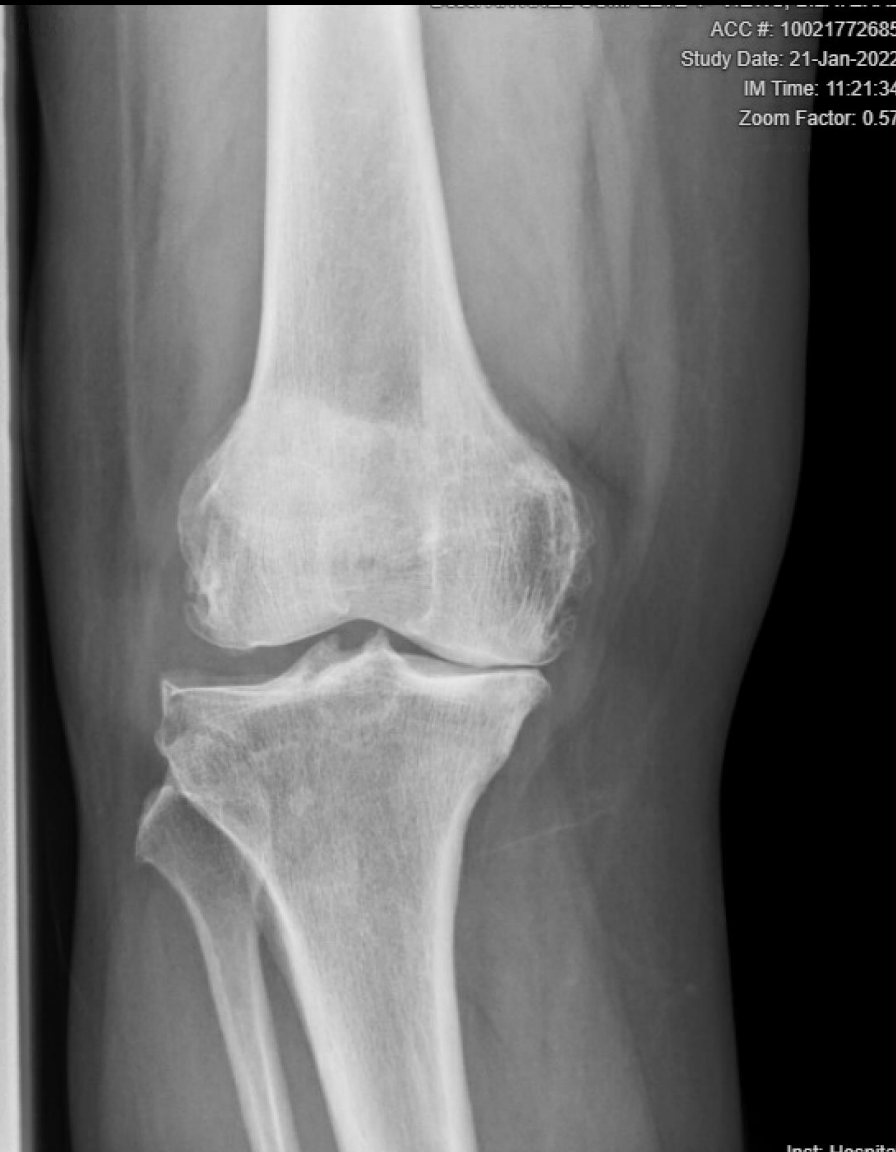

R TKA

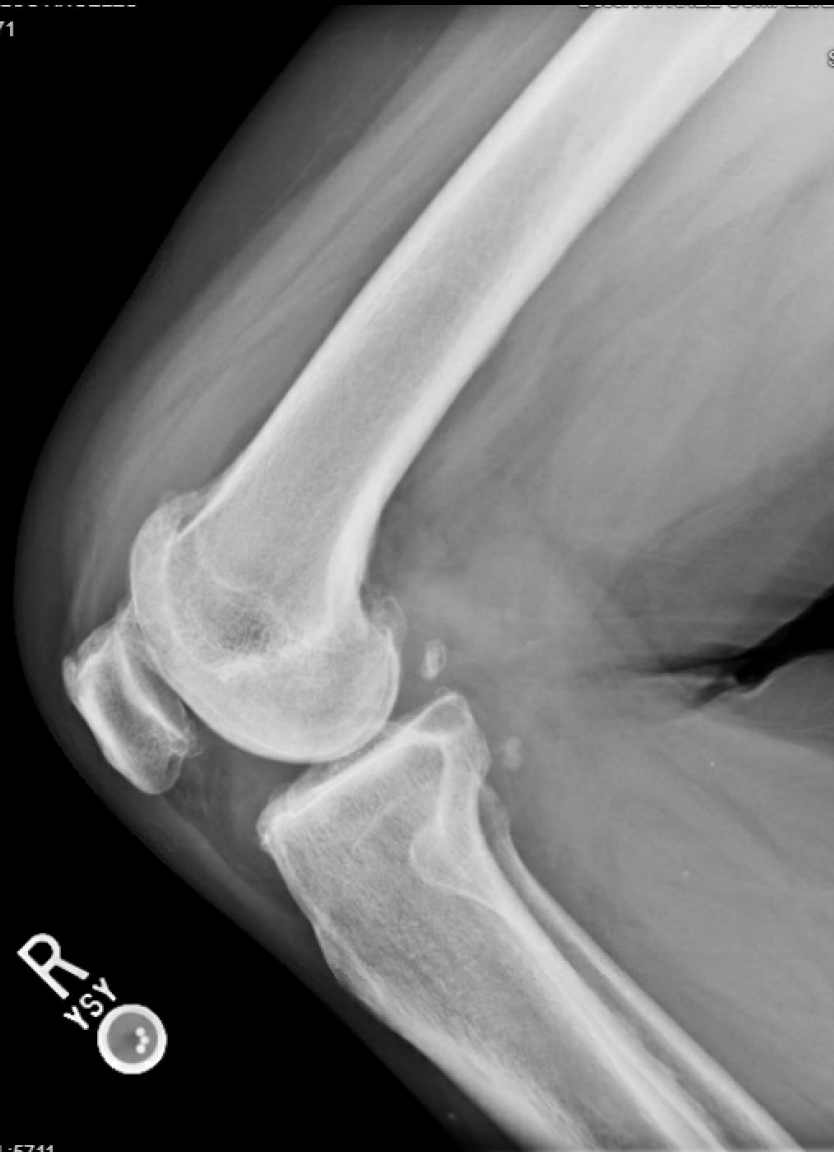PMH: Palpitations, BL carotid artery stenosis, HLD, hypothyroidism, HTN

PSH: None

ALL: NKDA DVT: ASA

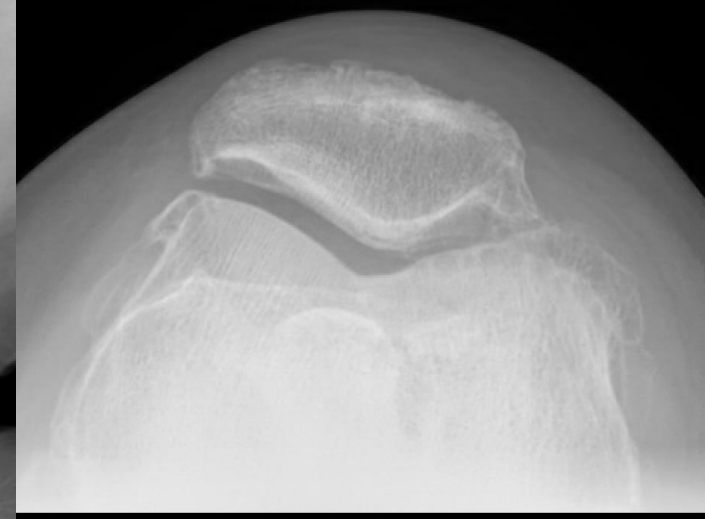


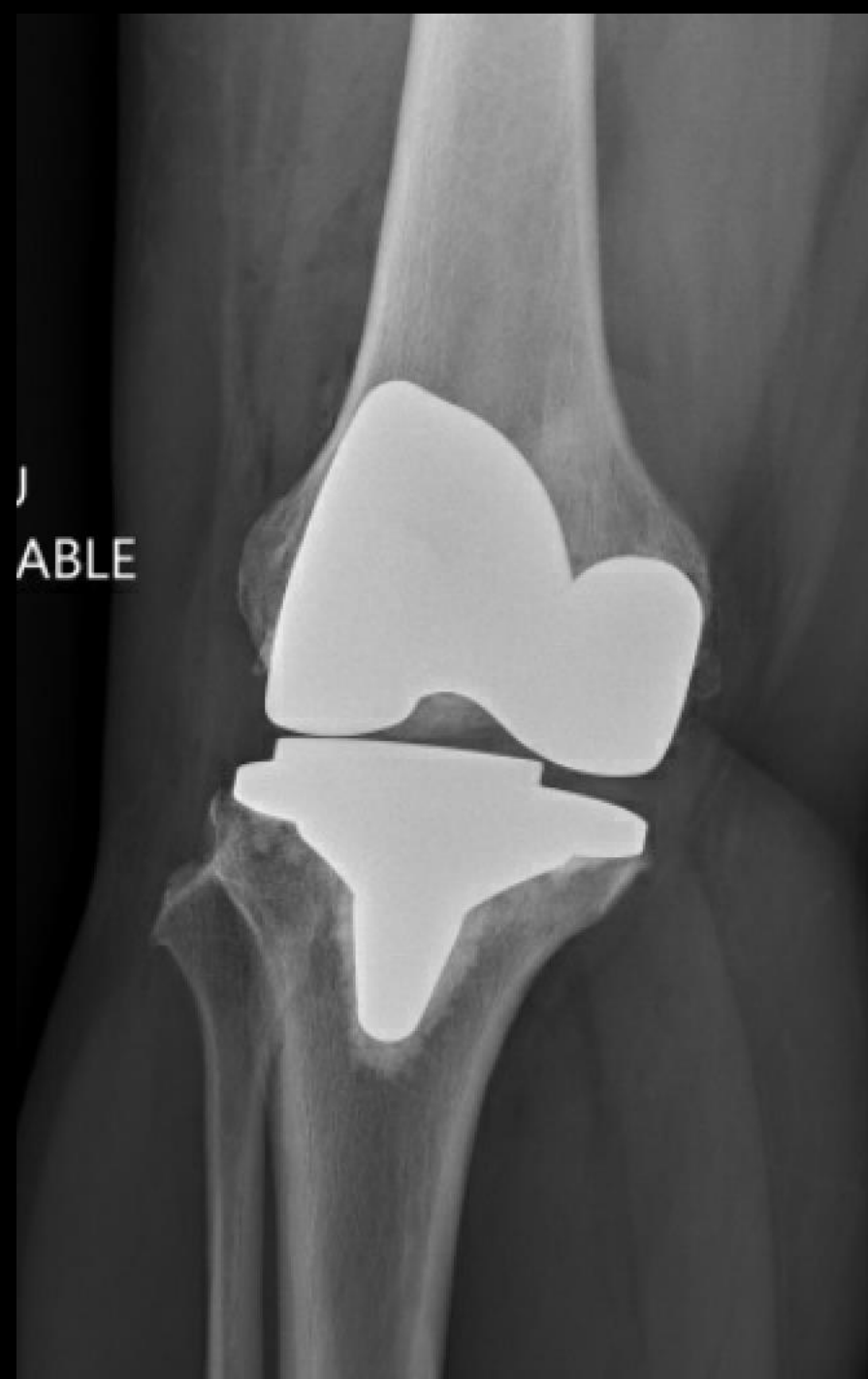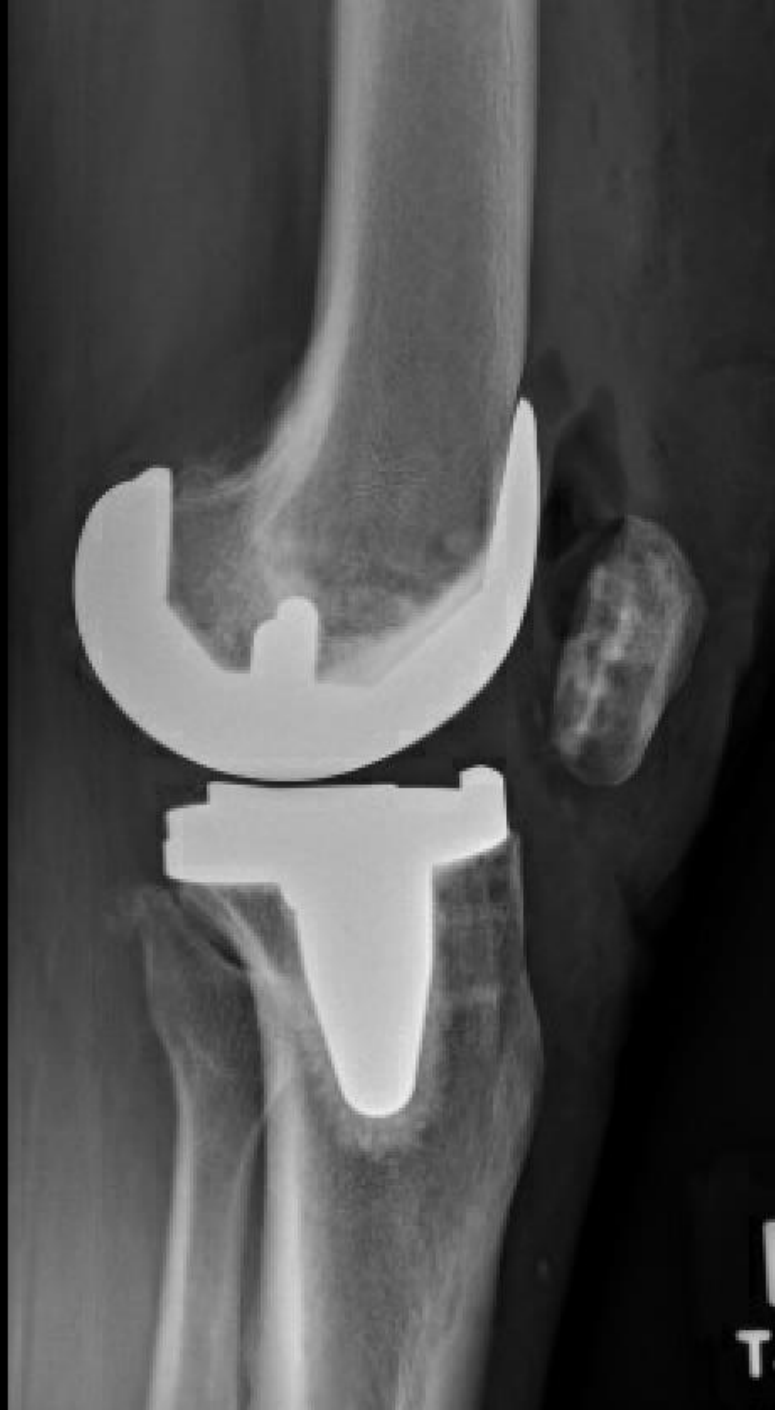ACC #: 10021772685 MRN: 45879771  
Study Date: 21-Jan-2022 Age:  
IM Time: 11:21:34 Sex: F  
Zoom Factor: 0.57



R  
YSY  
O

1/1  
IM #: 5  
SE #: 6556-4





# Post ACL TKA 68 YO Female

- 68 y.o. female has right knee post-traumatic OA with valgus deformity associated with prior ACL allograft
- Anti-inflammatory medication history: None
- Home exercise/activities: swimming, walking, hiking and golf - pilates
- Ambulatory capacity: 0.5 miles with discomfort
- Assistive devices: not using a cane or other assistive device
- Stair climbing: one foot at a time, with one hand support
- Physical therapy: Yes
- Weight gain/loss: has been stable

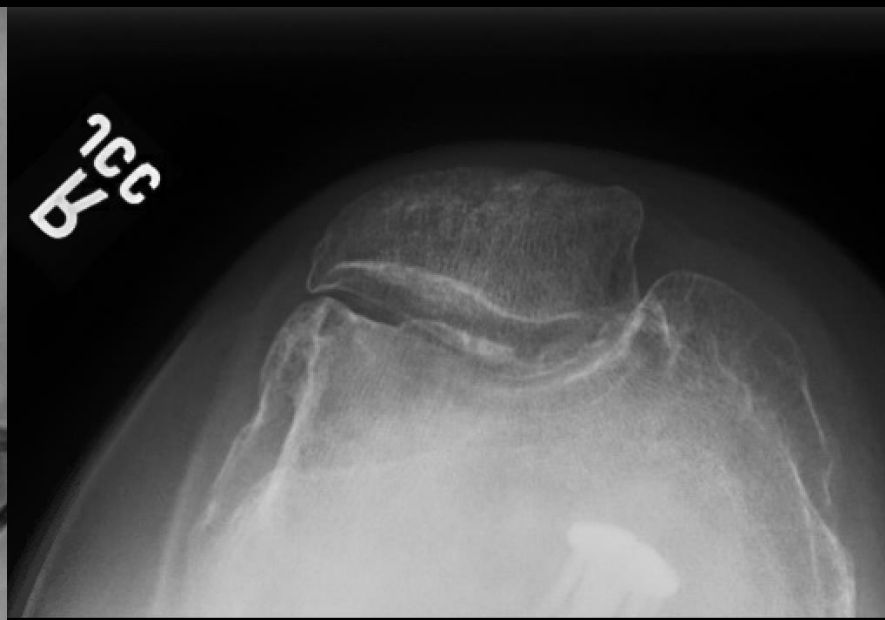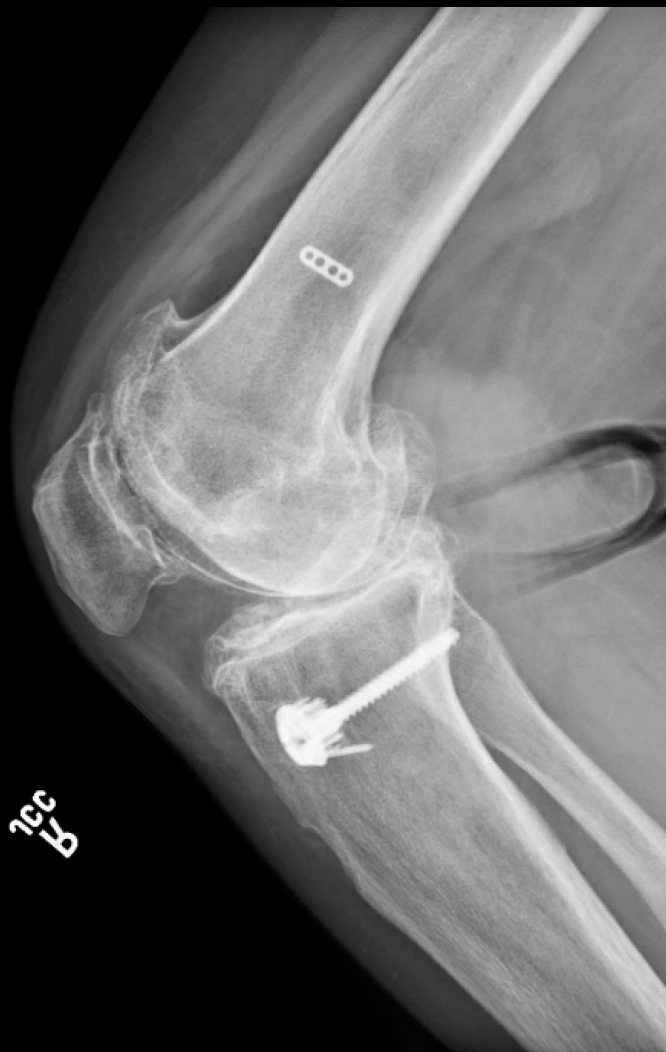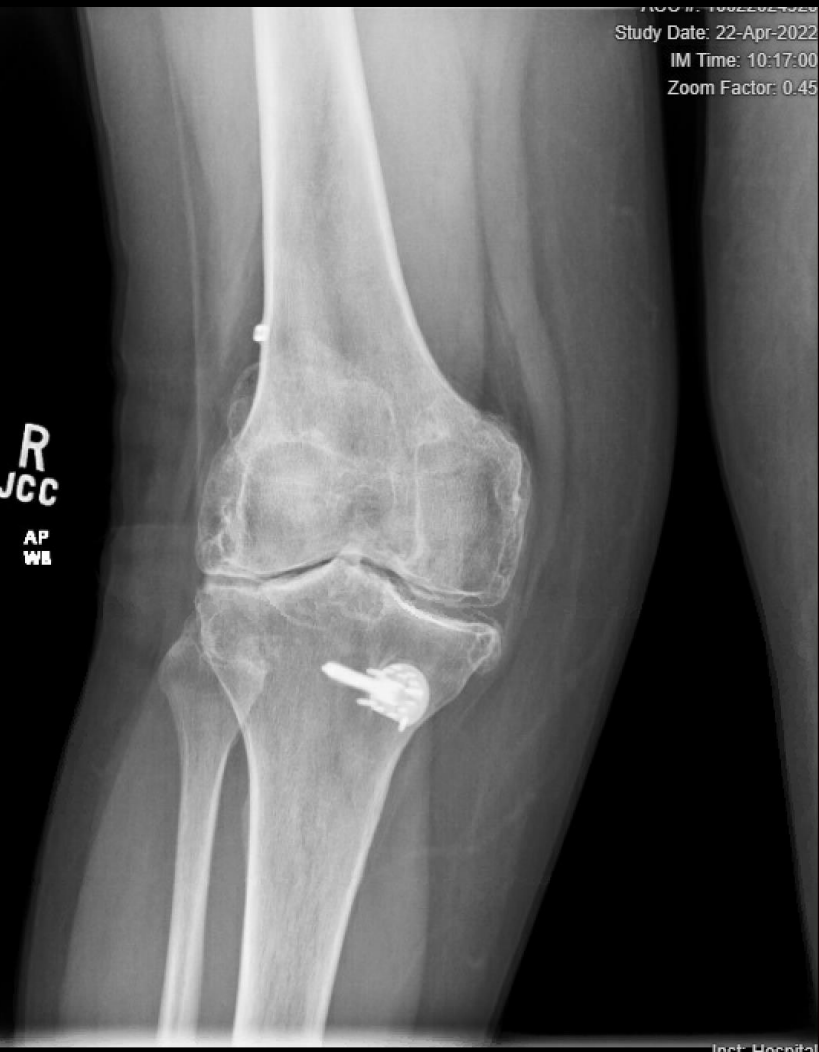R TKA

PMH: none

PSH: R ACLR 1998

ALL: NKDA DVT: ASA

Study Date: 22-Apr-2022 Age:  
IM Time: 10:17:00 Sex: F  
Zoom Factor: 0.45

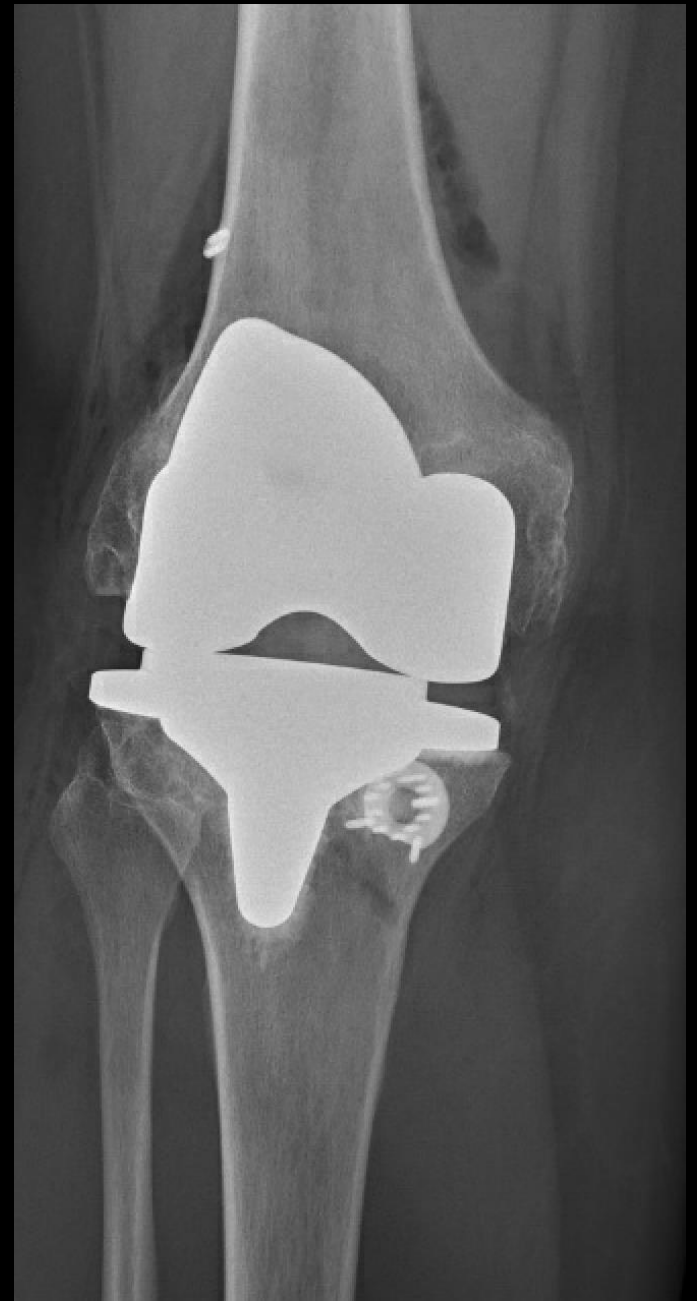
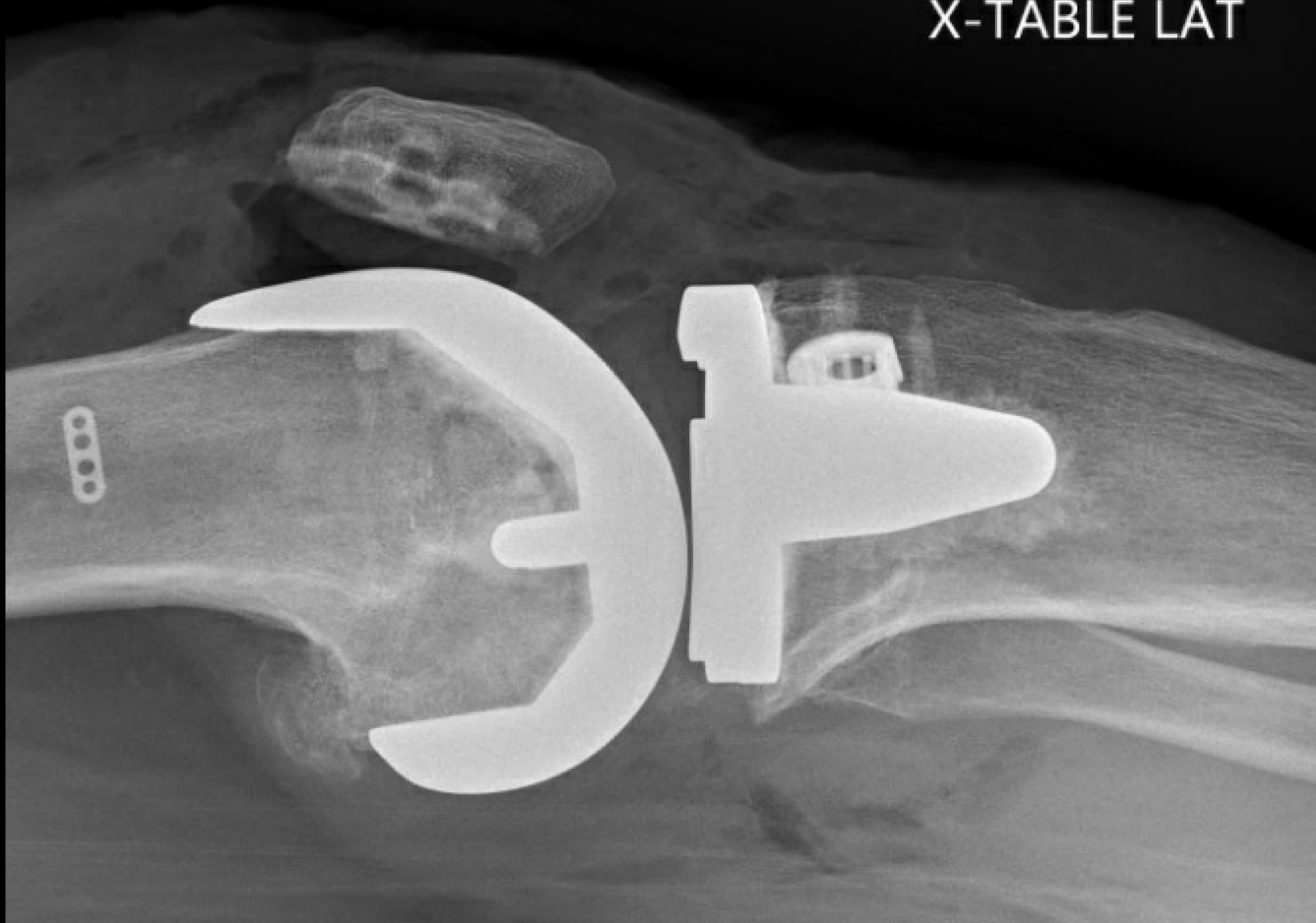
1/1  
IM #: 5  
SE #: 9112-5

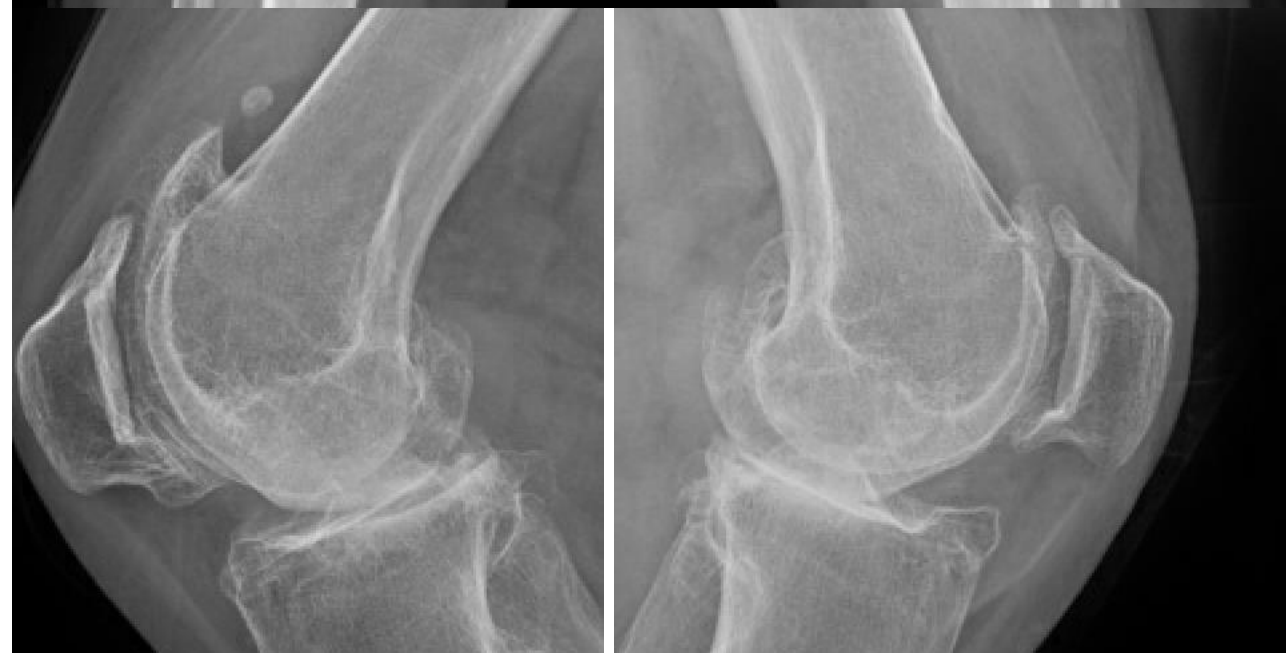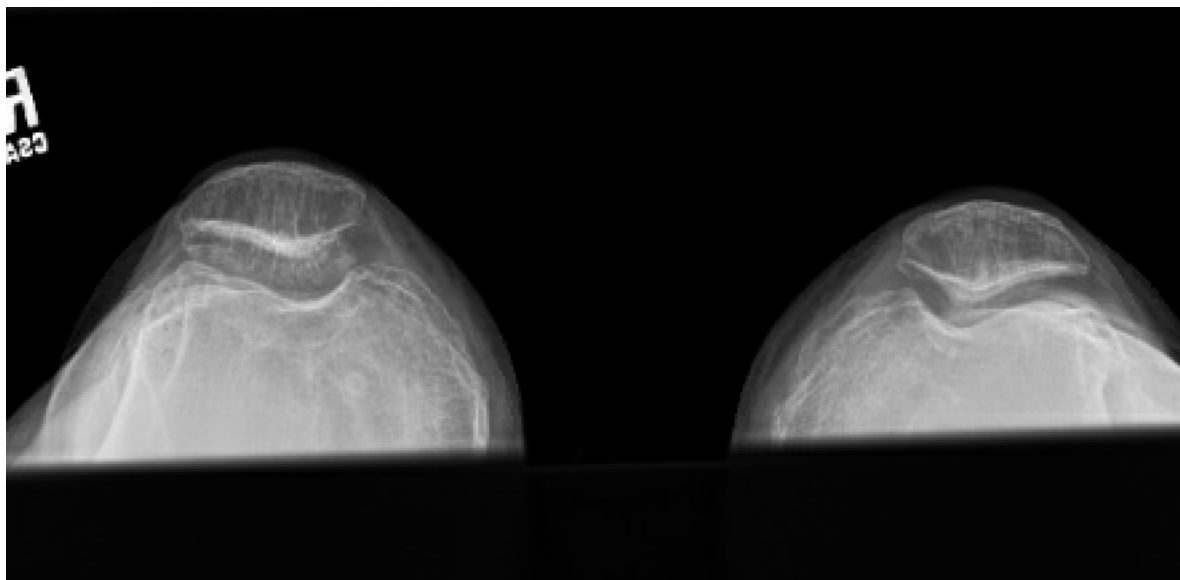
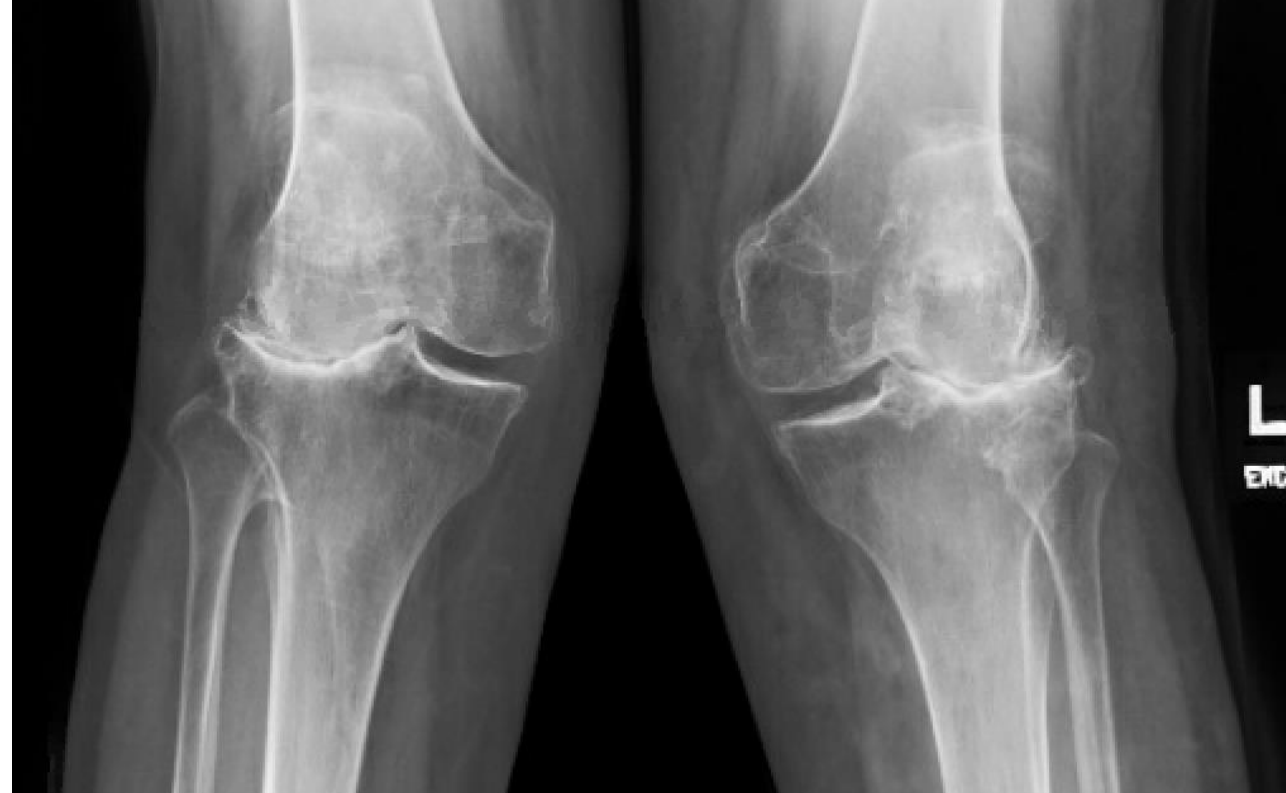
Inst: Hospital UMI - W-112441-7070

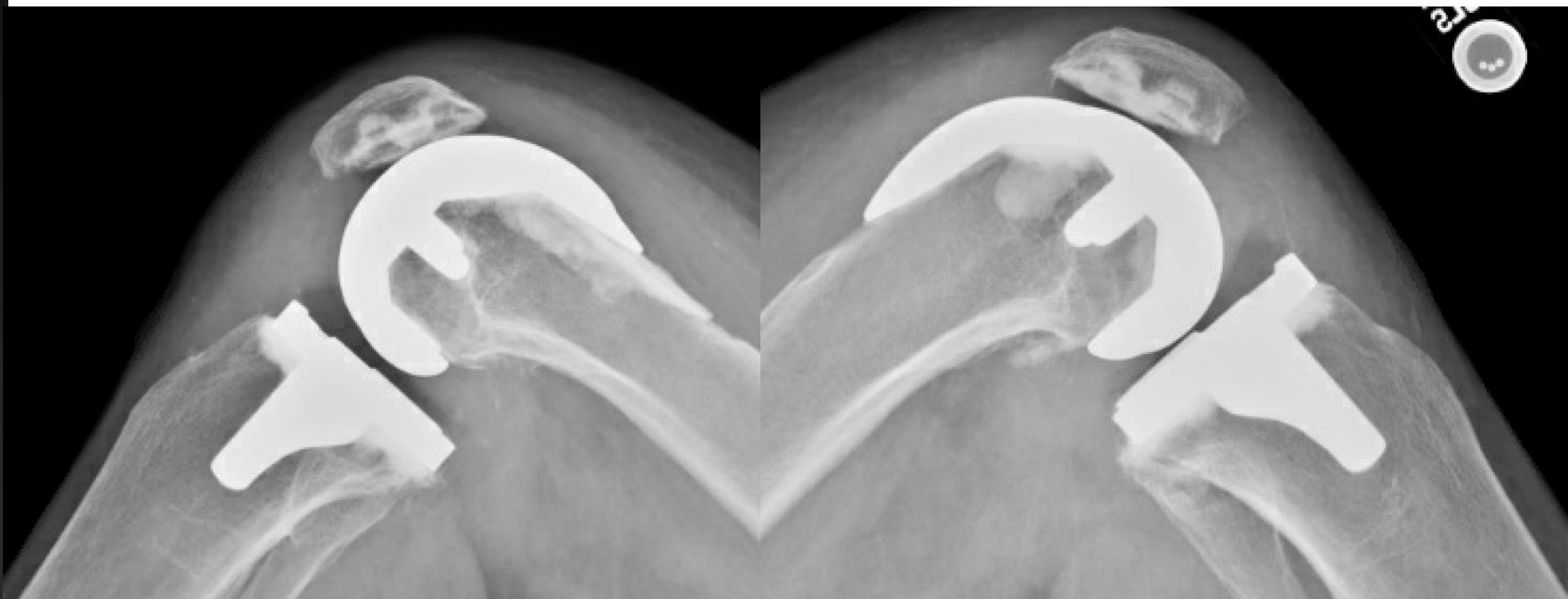
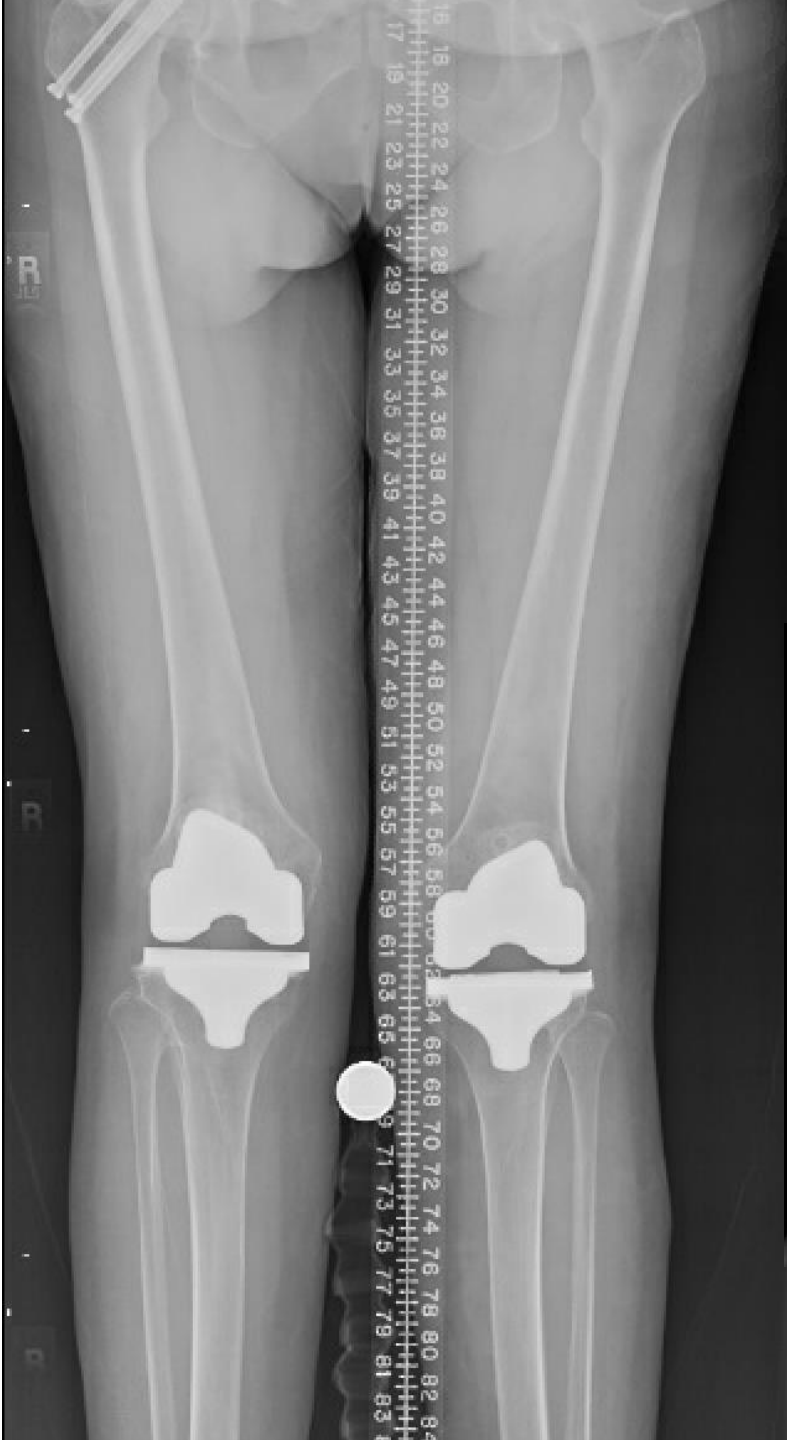
Inst: Ucnit

PACU  
X-TABLE LAT

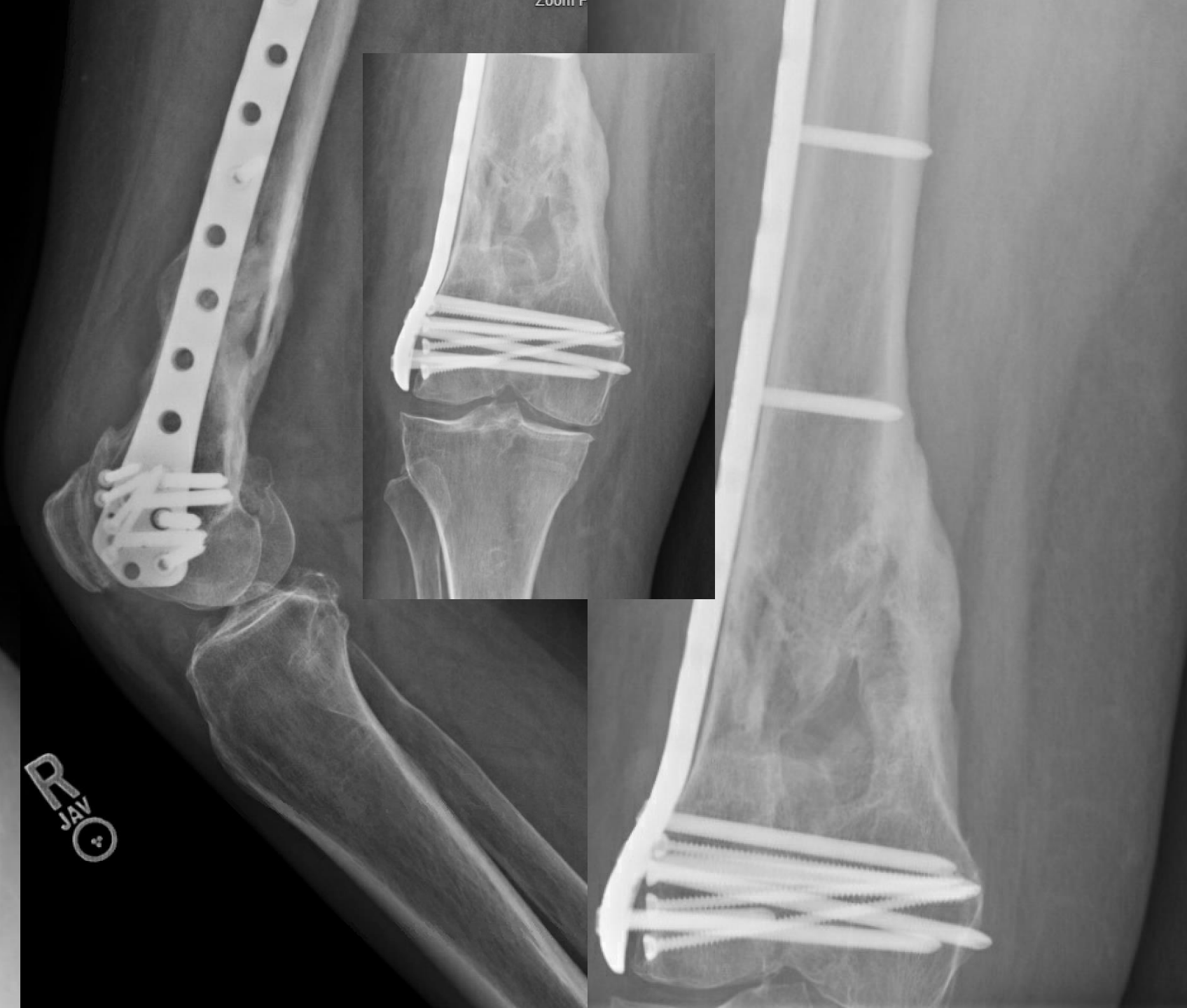
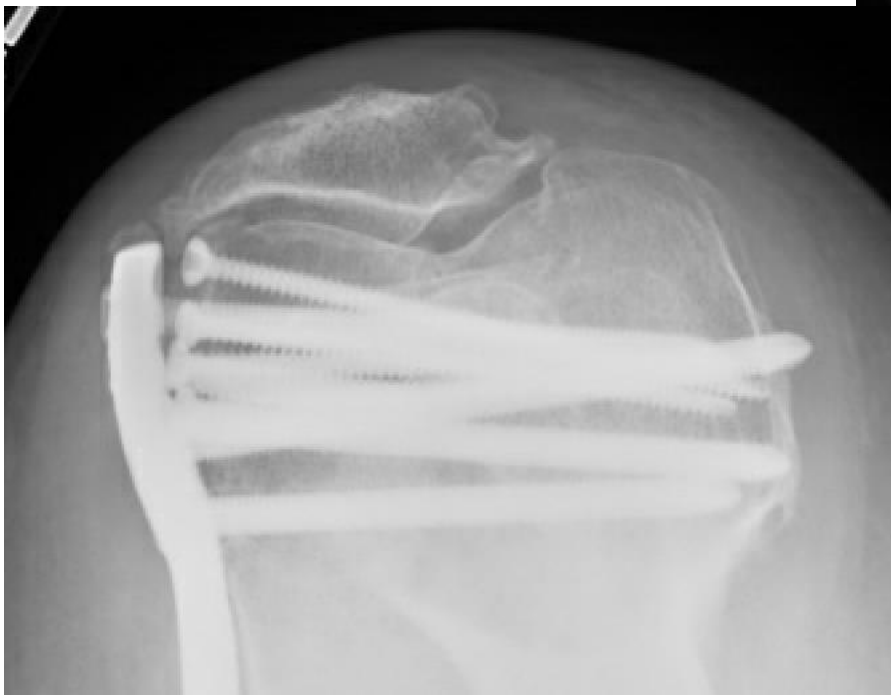
75 yo bilateral  
knee pain TKA  
15 deg flex,  
limited flexion  
cx,HTN

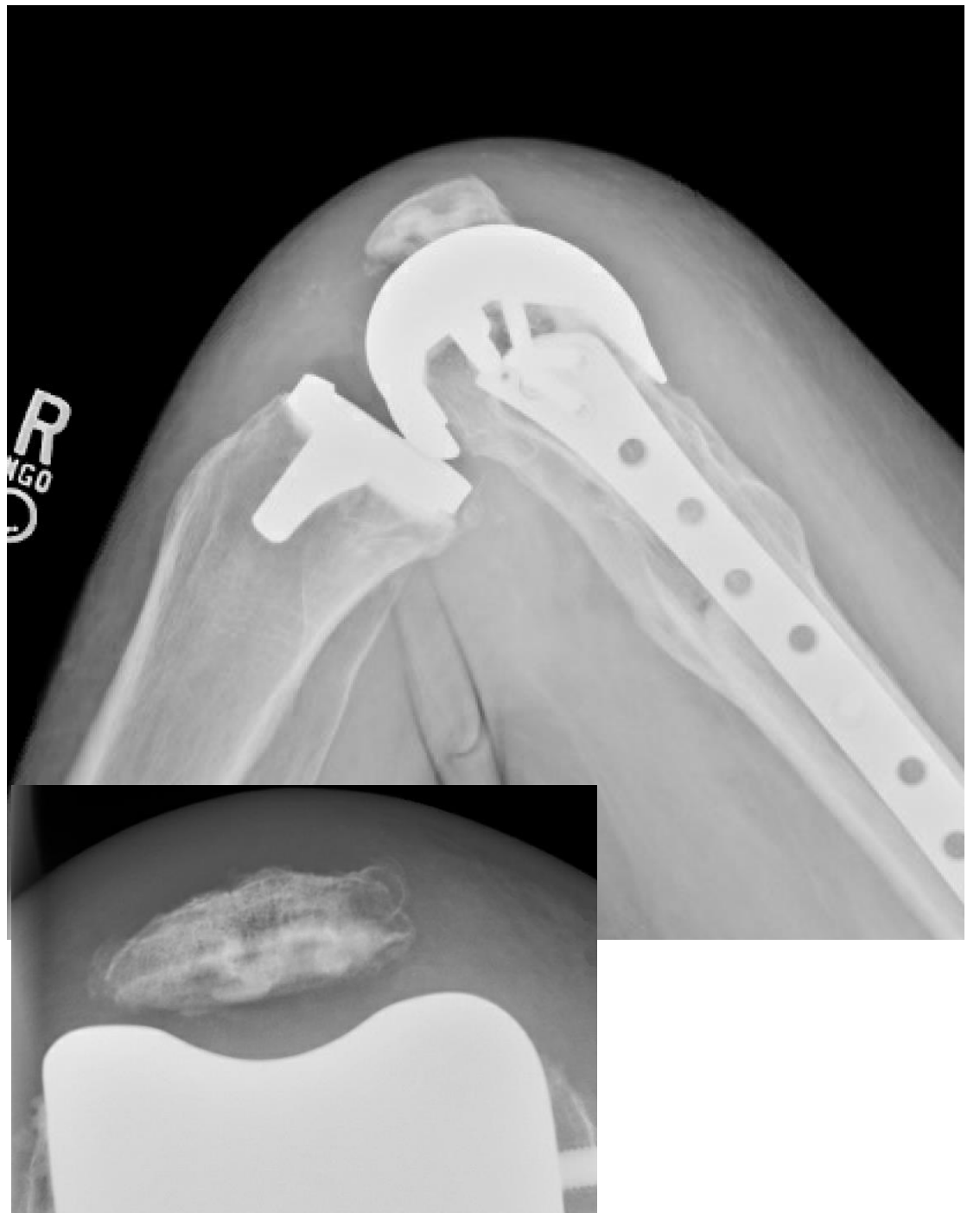
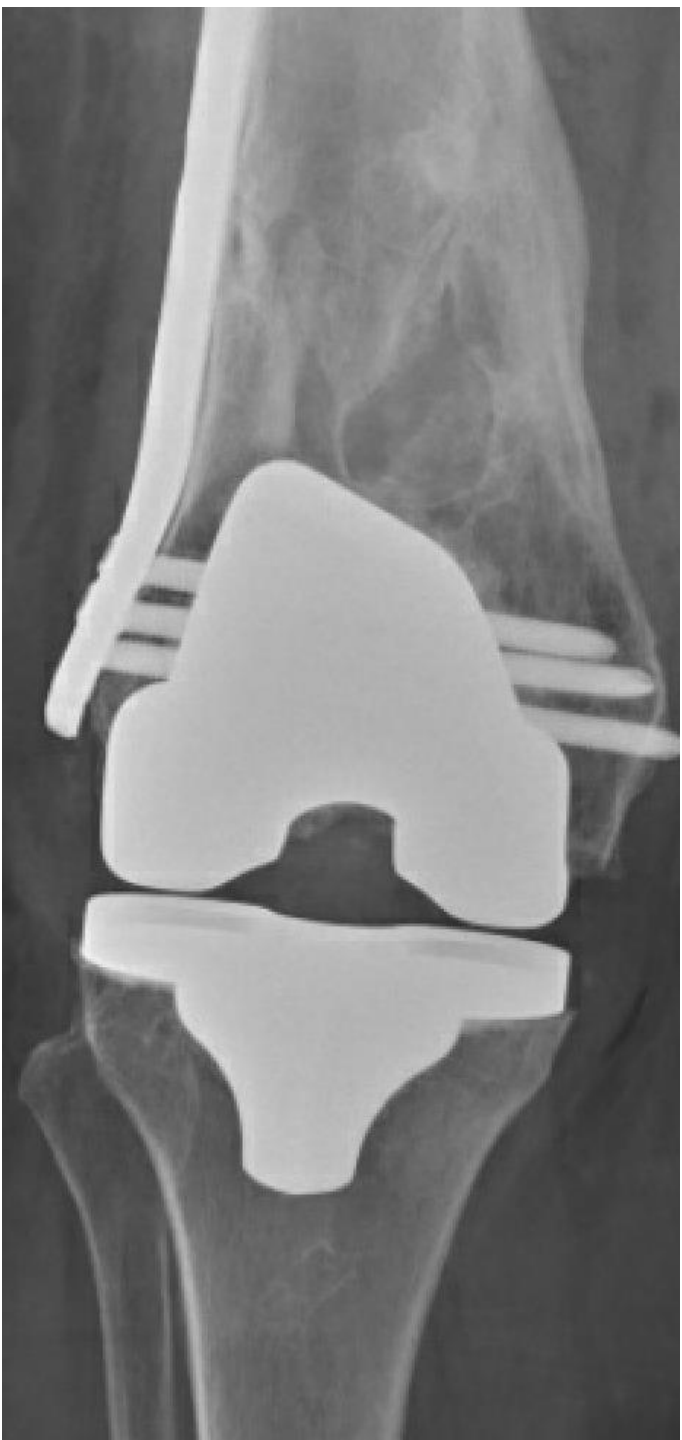
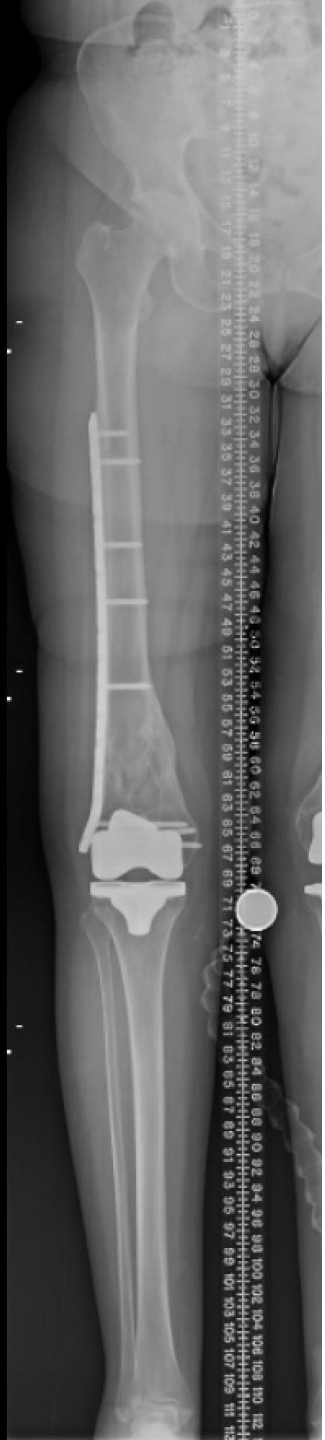

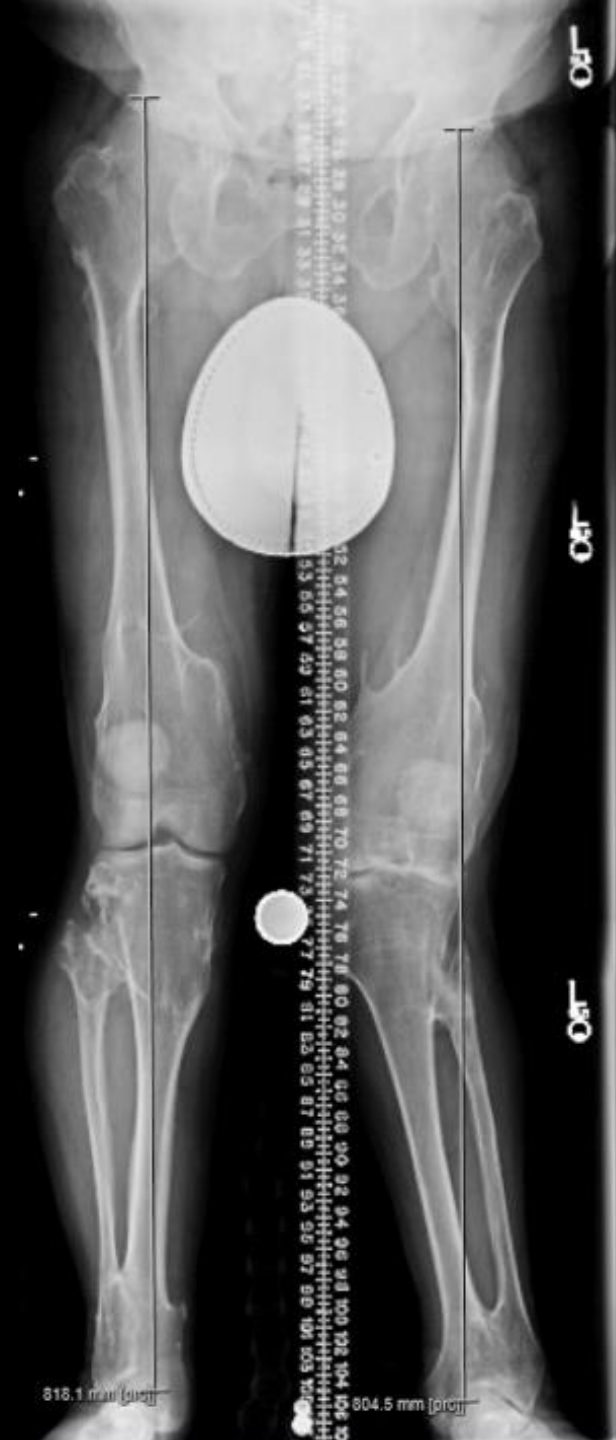65 yo female  
BMI 24  
Post traumatic  
TKA  
3 years post  
ORIF  
No infection



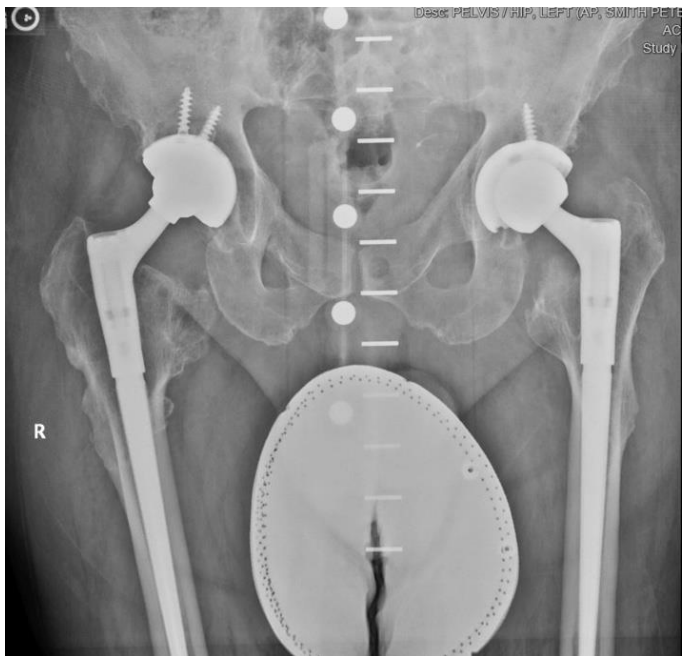
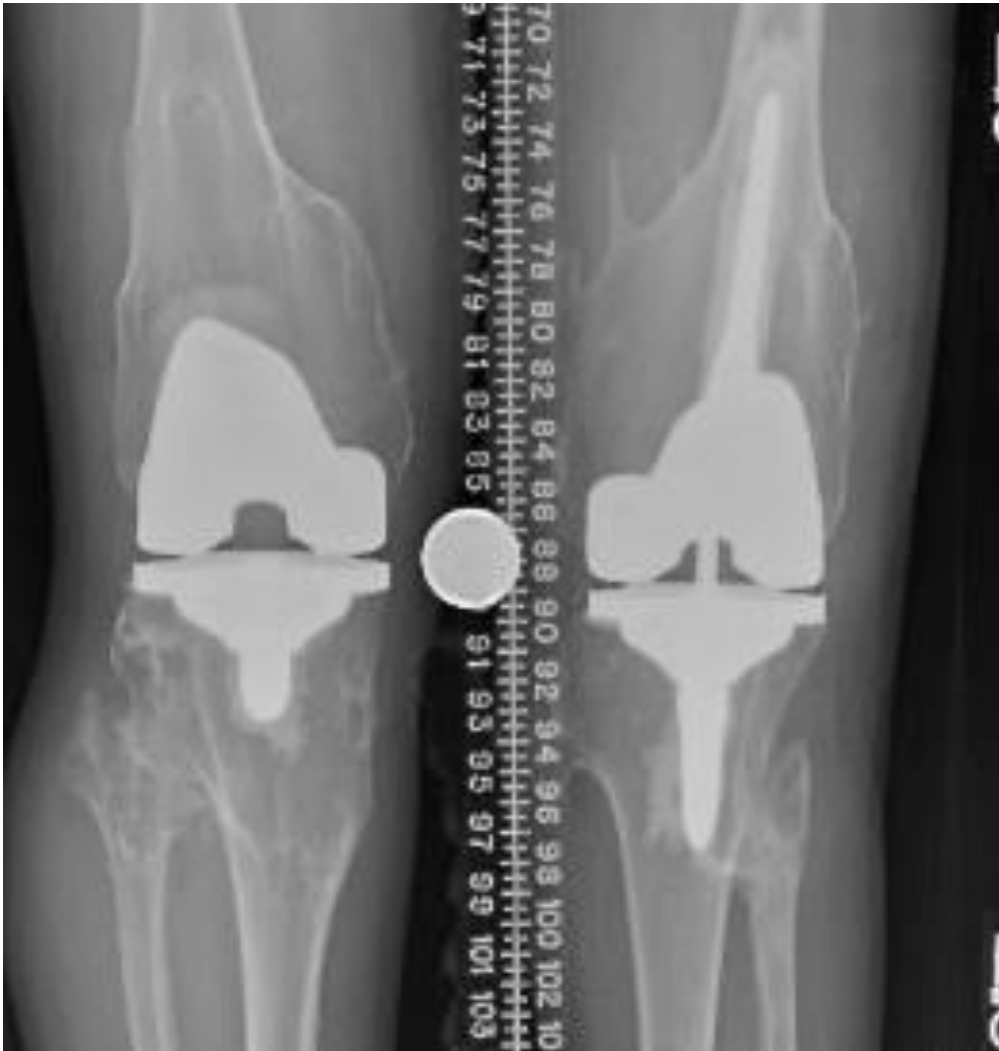
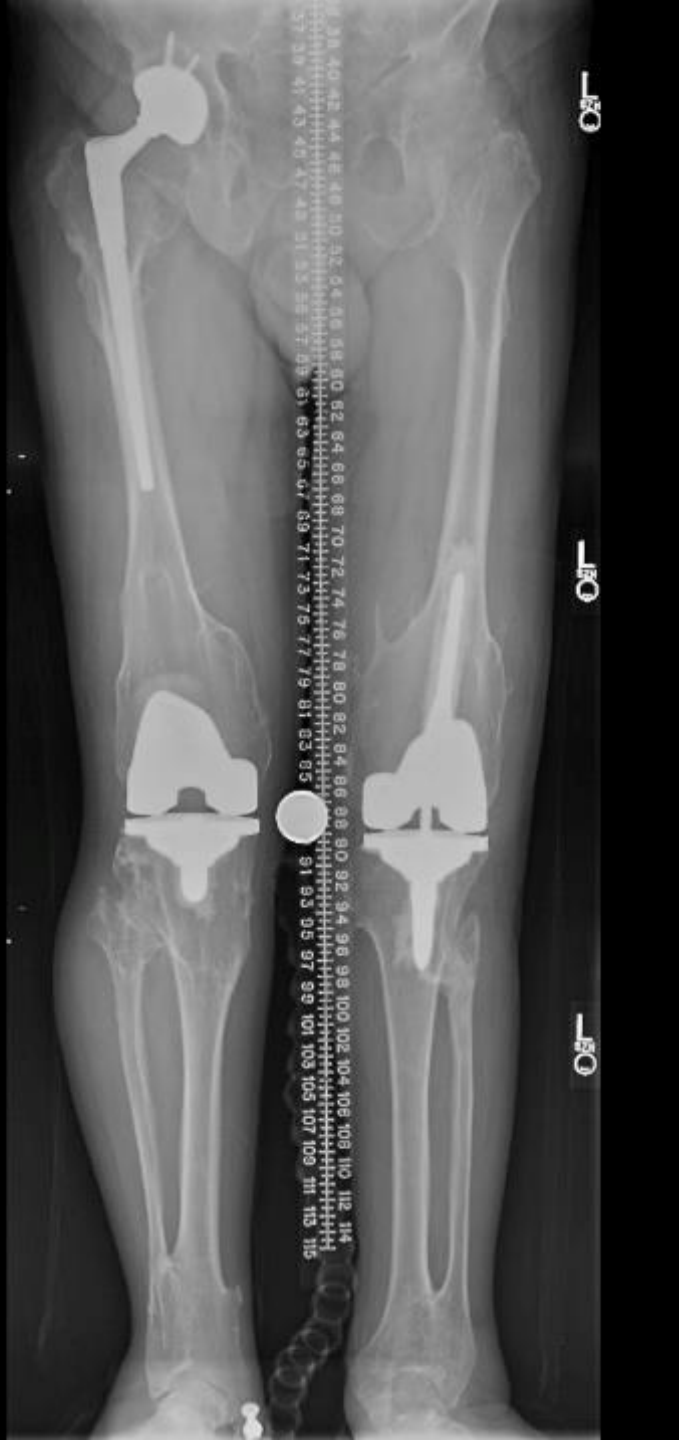



Des

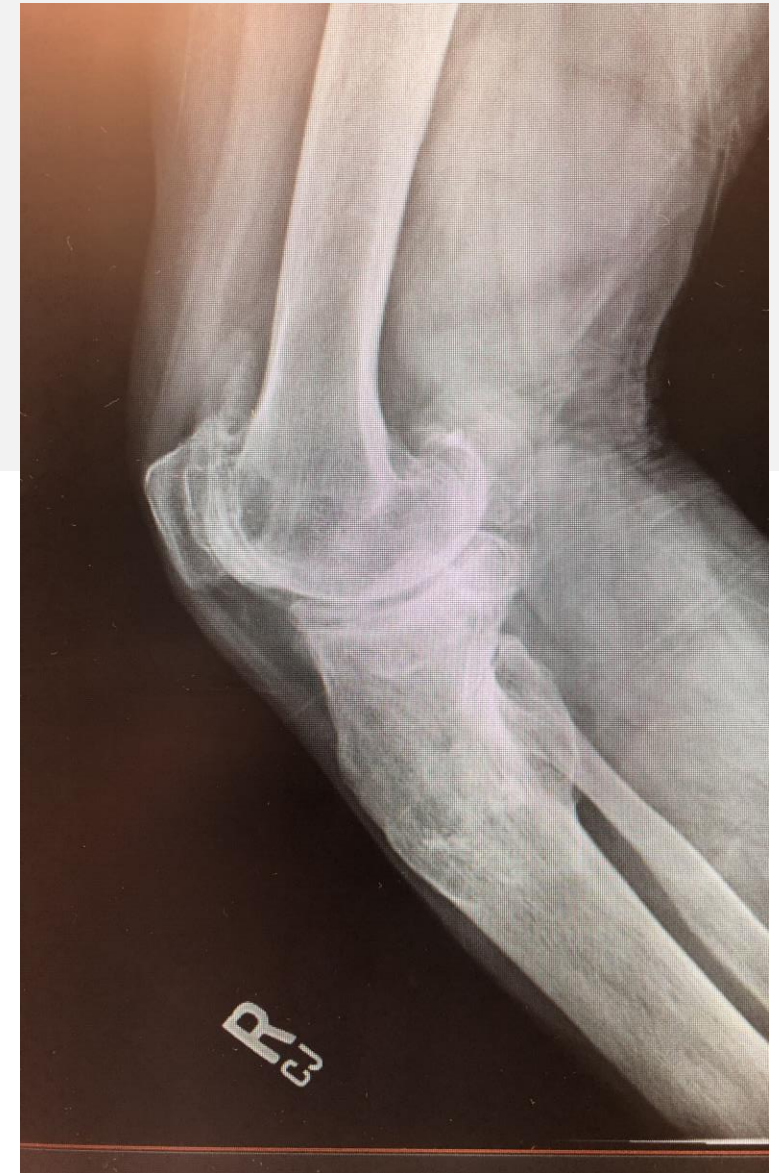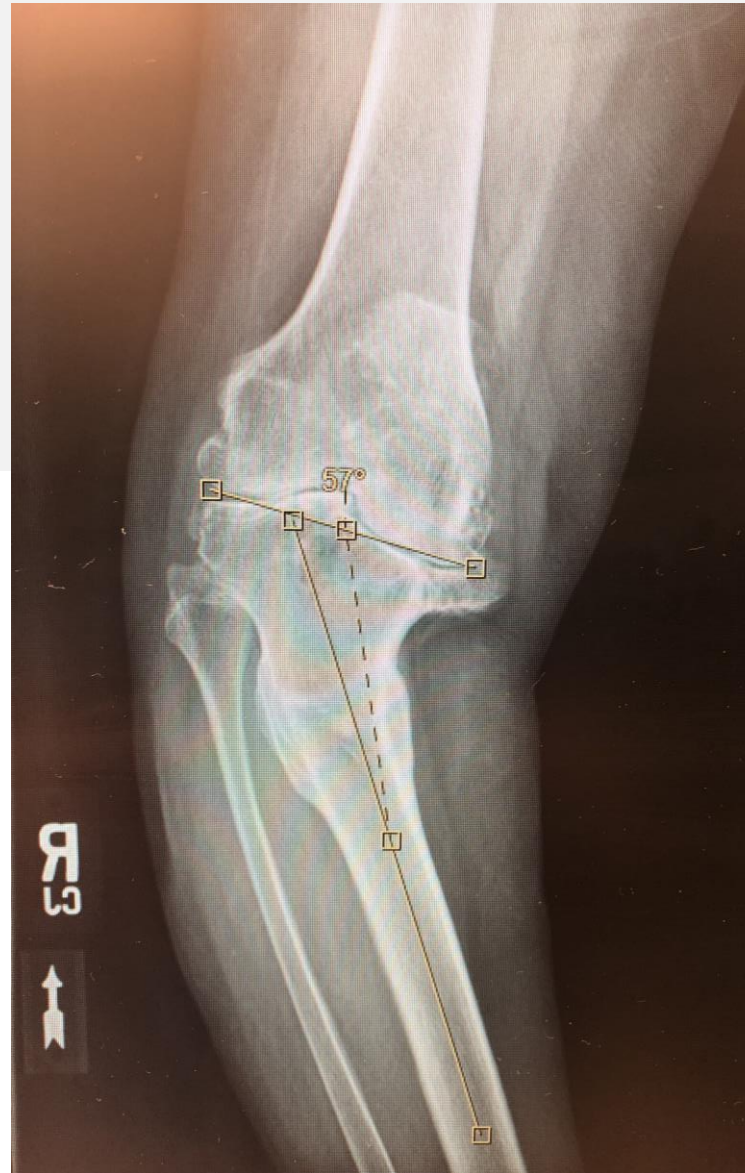MHE

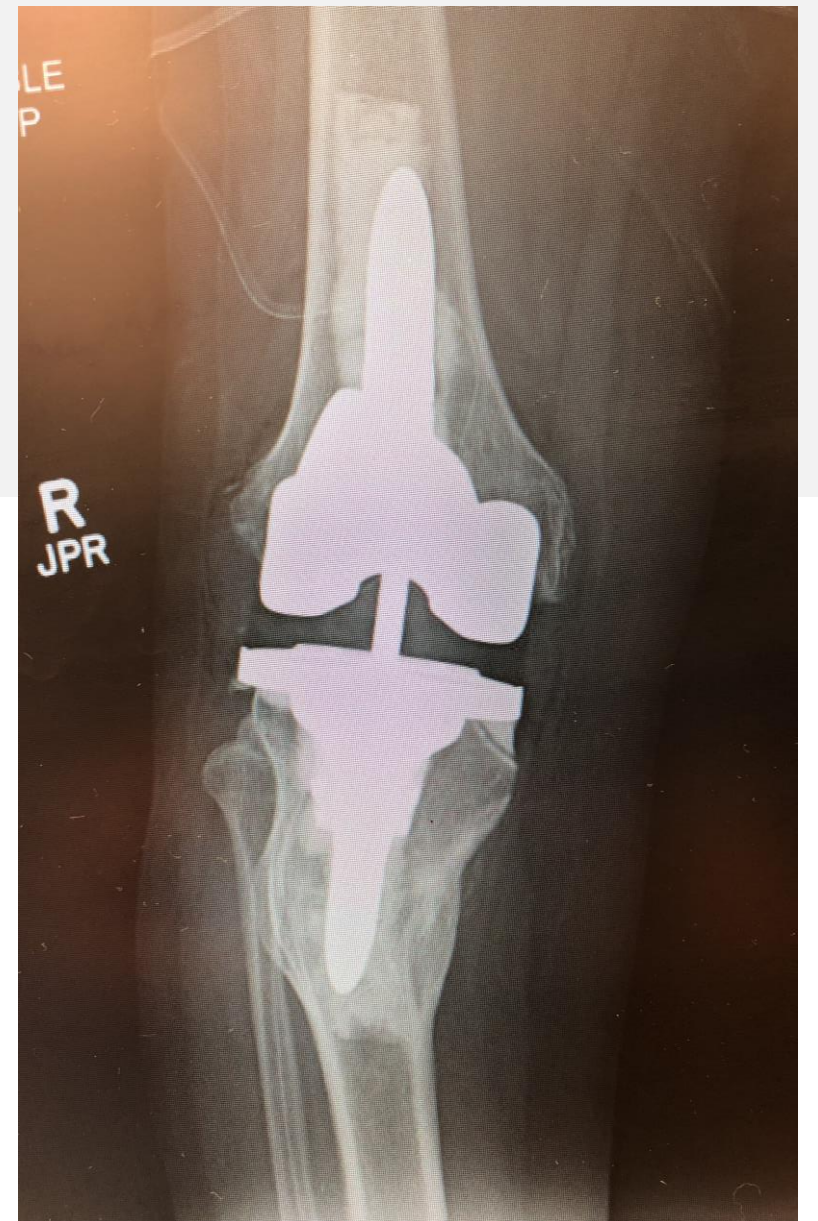
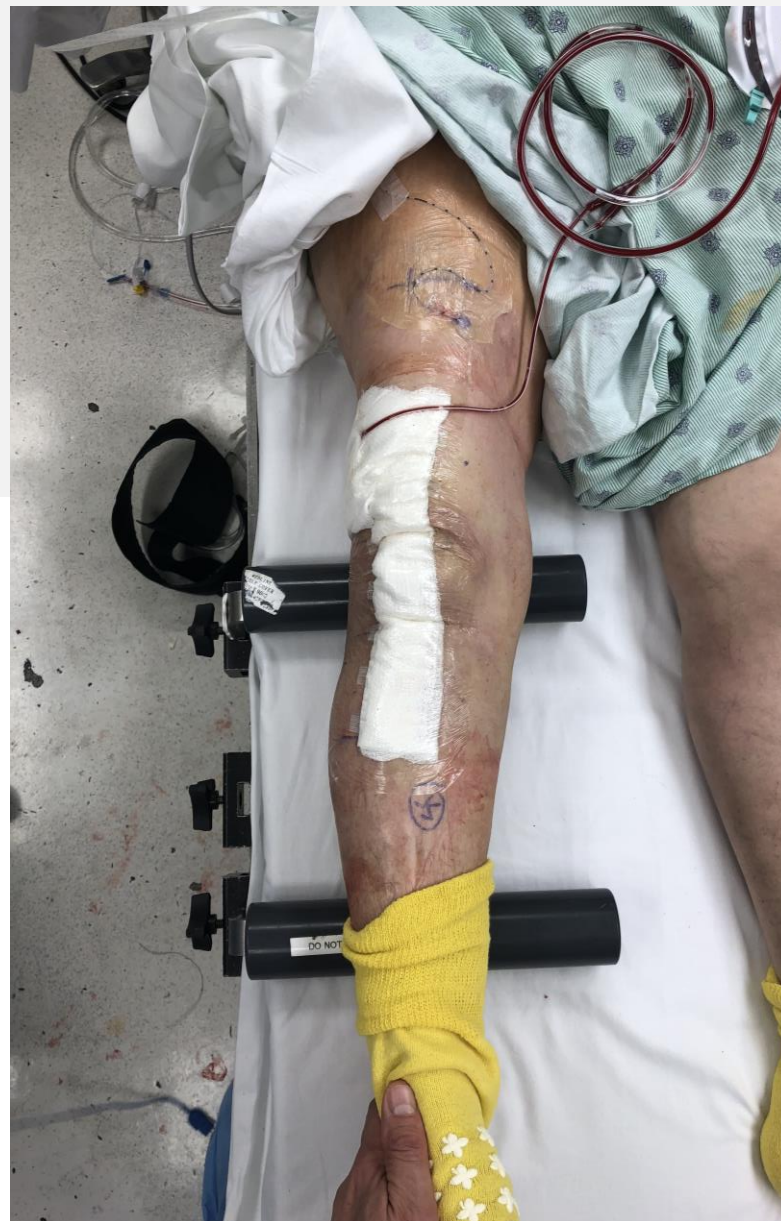
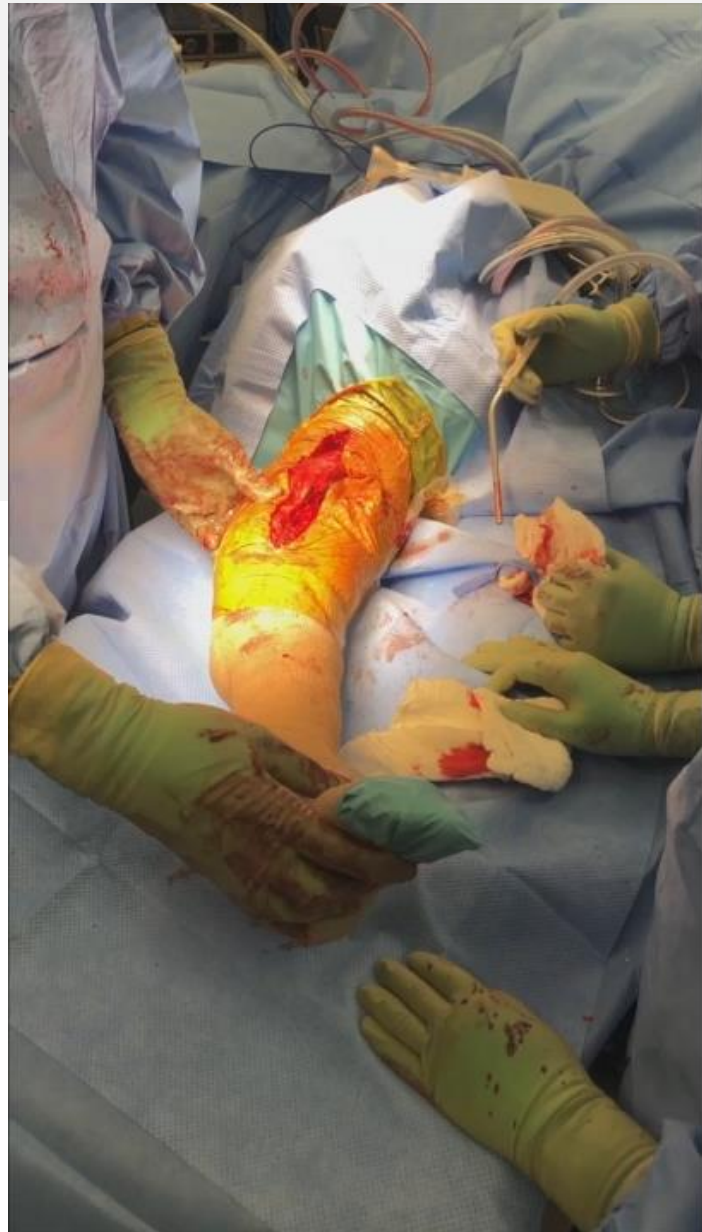


# Severe post traumatic Deformity

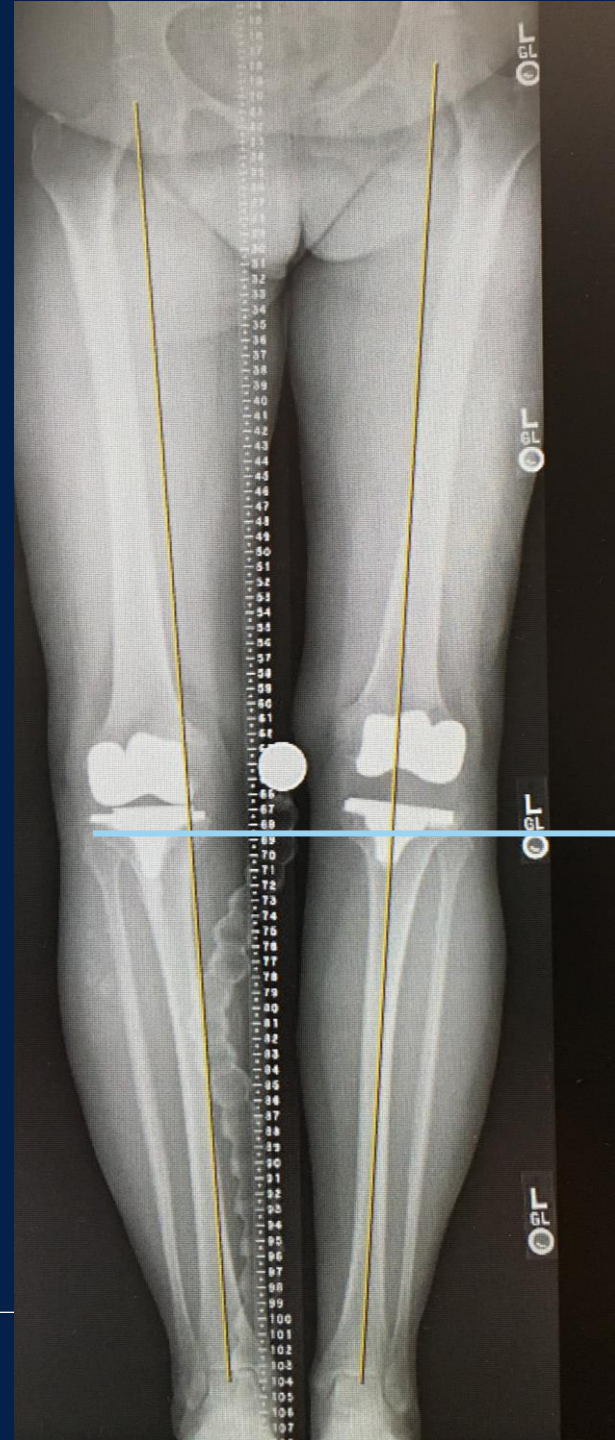
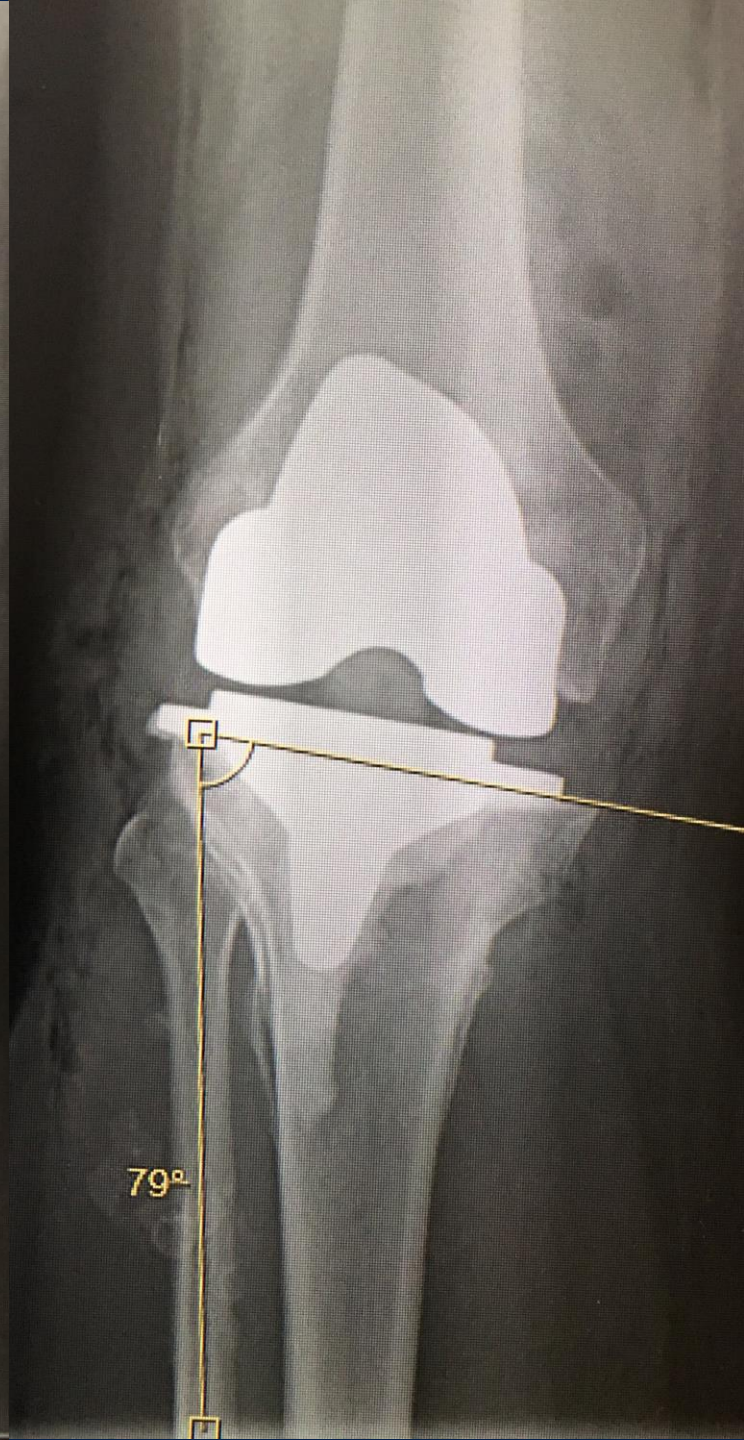
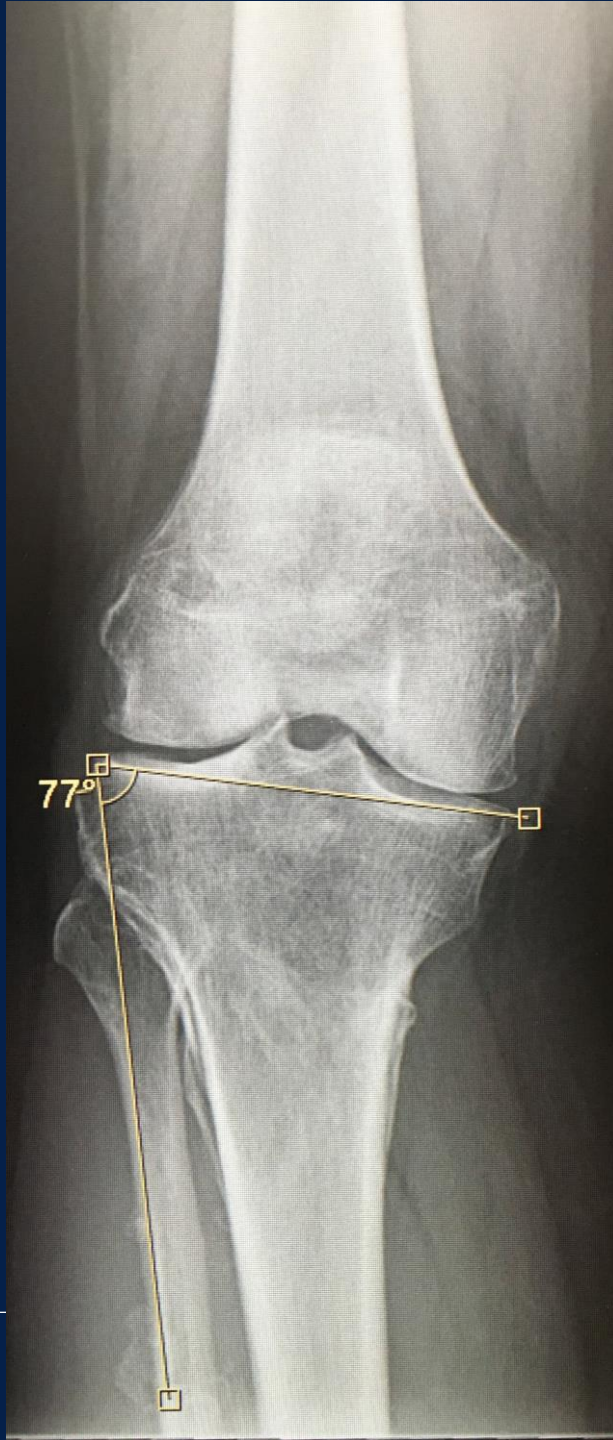
- 72 yo Hispanic woman with RA, memory issues, bilateral knee OA, R>L, R s/p post traumatic deformity x 35 years
- 4' 11" 140 lbs BMI 29
- 0-40 arc of motion
- Pain 7/10, walker, 2 rails for stairs
- Left TKA 5/2018
- Right TKA 10/2018





# Follow up

- DOS
- 4 week follow up (11/07/18)
- Doing well, very pleased, minimal pain, Tylenol
- 0-90 arc of motion R knee
- Minimal assistance needed ambulating (uses a walker for balance, walking outside of home)
- Never came back to ortho clinic
- Underwent LEFT ankle fusion at UCSF Dr Thuillier 5/2019 no notes of issues with R knee or L knee

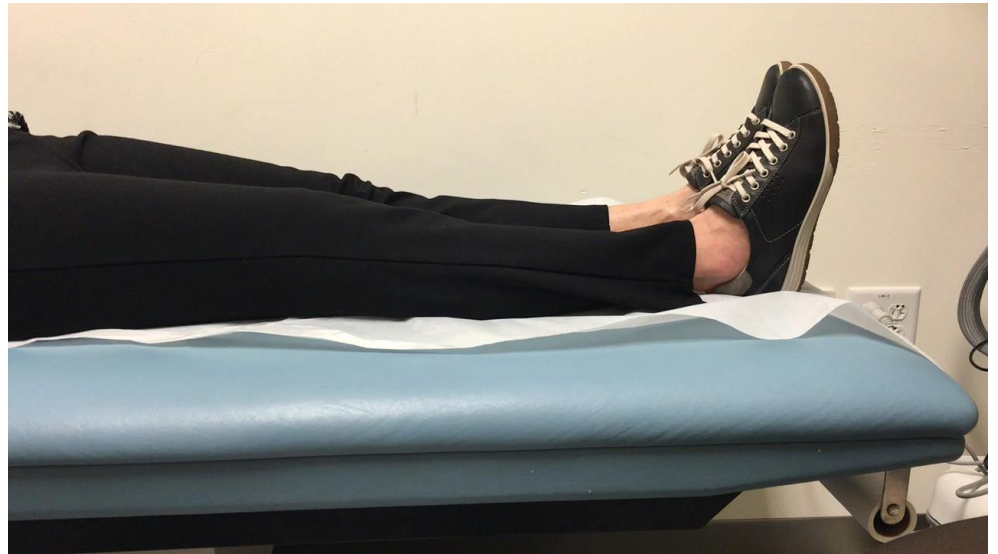
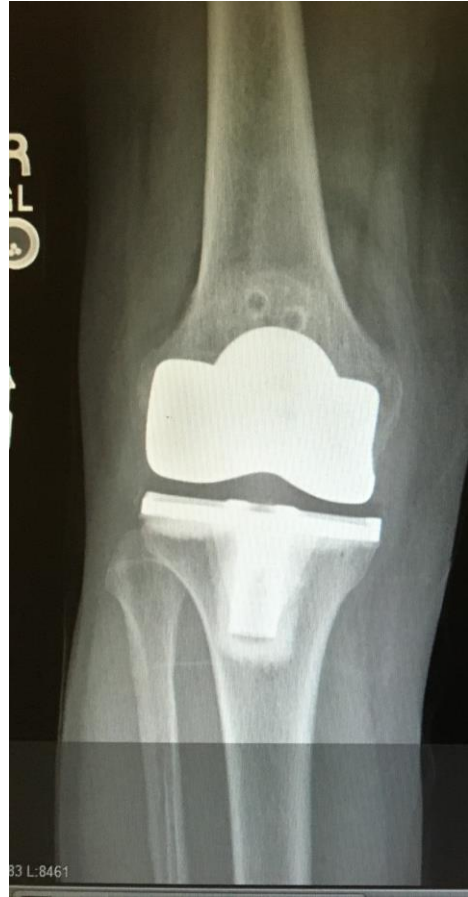
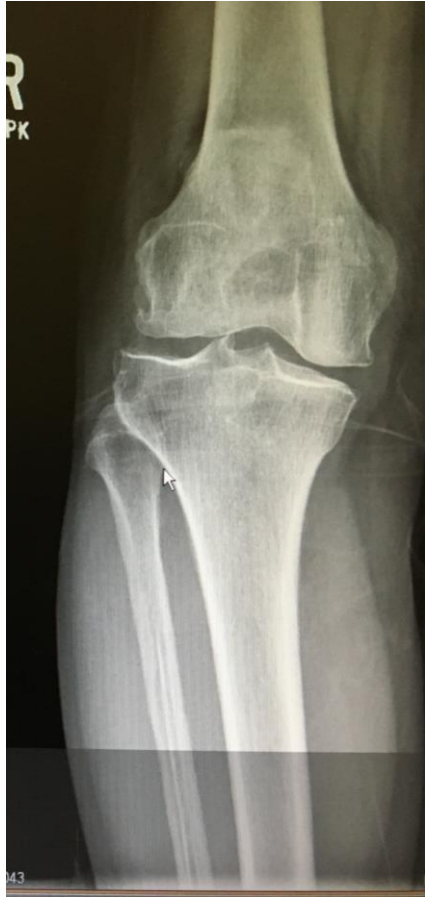


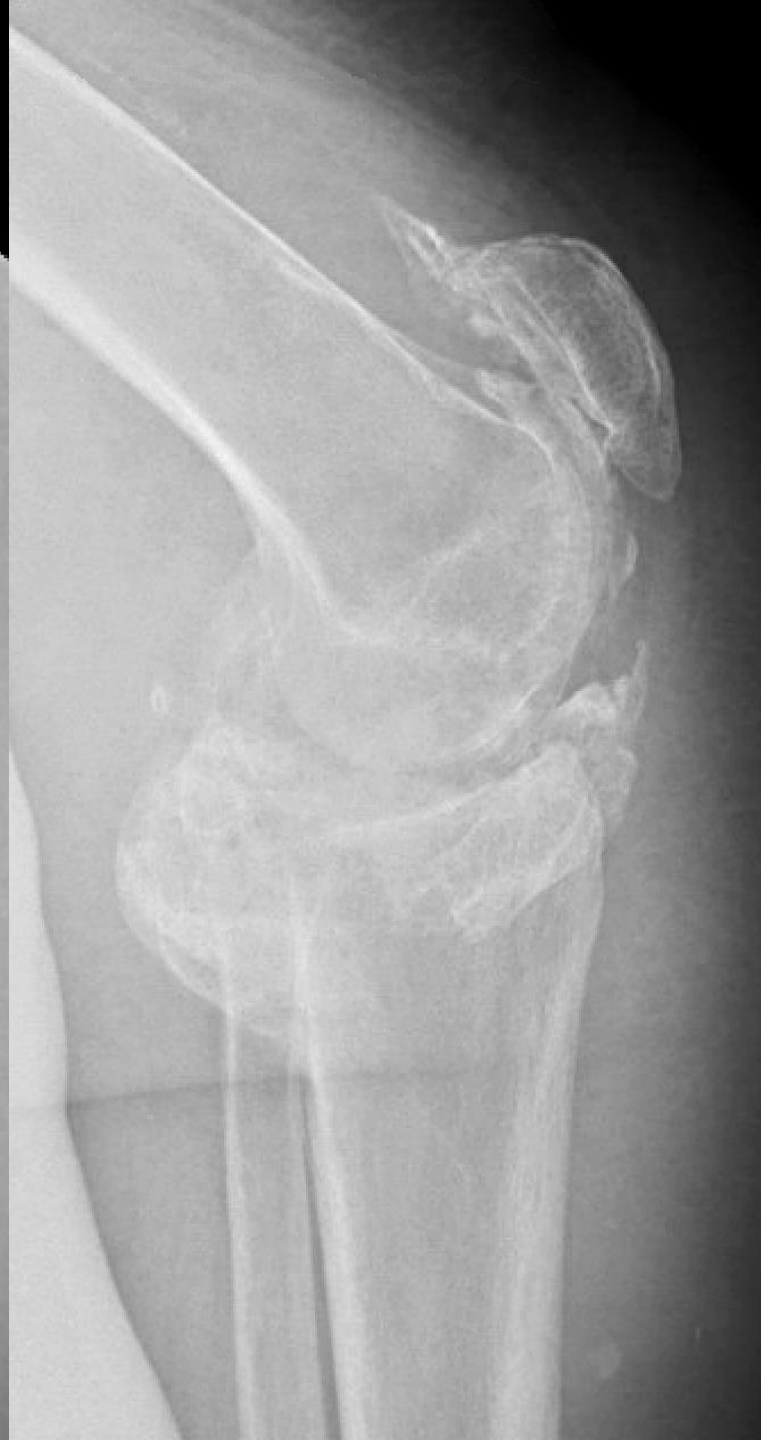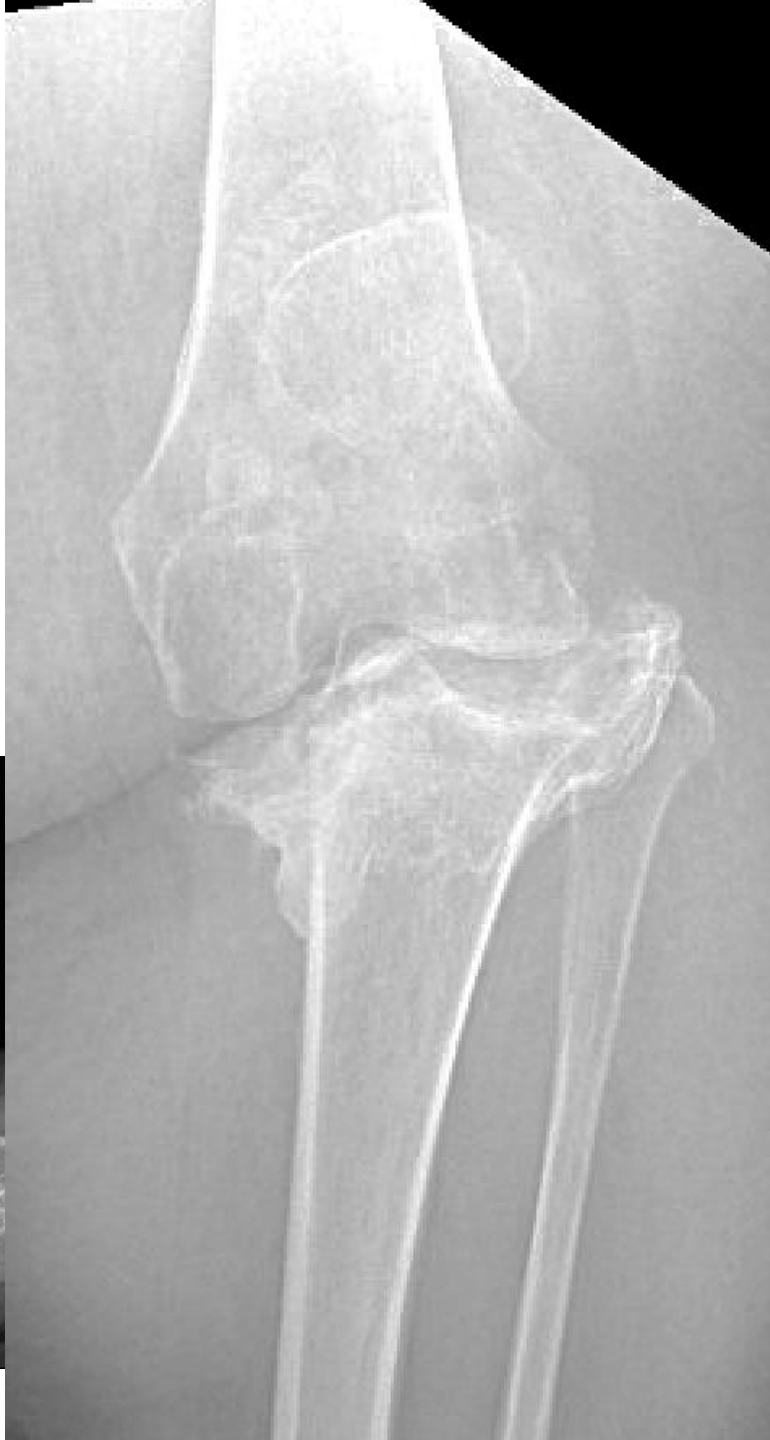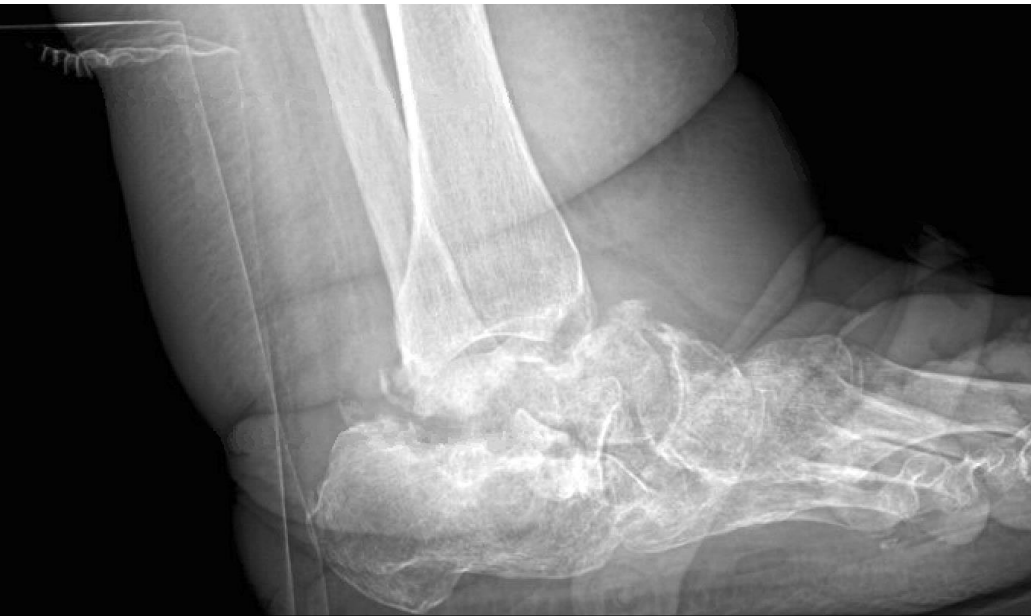77°

0.130  
0.120  
0.097  
0.087  
0.077  
0.067  
0.057  
0.047  
0.037  
0.027  
0.017

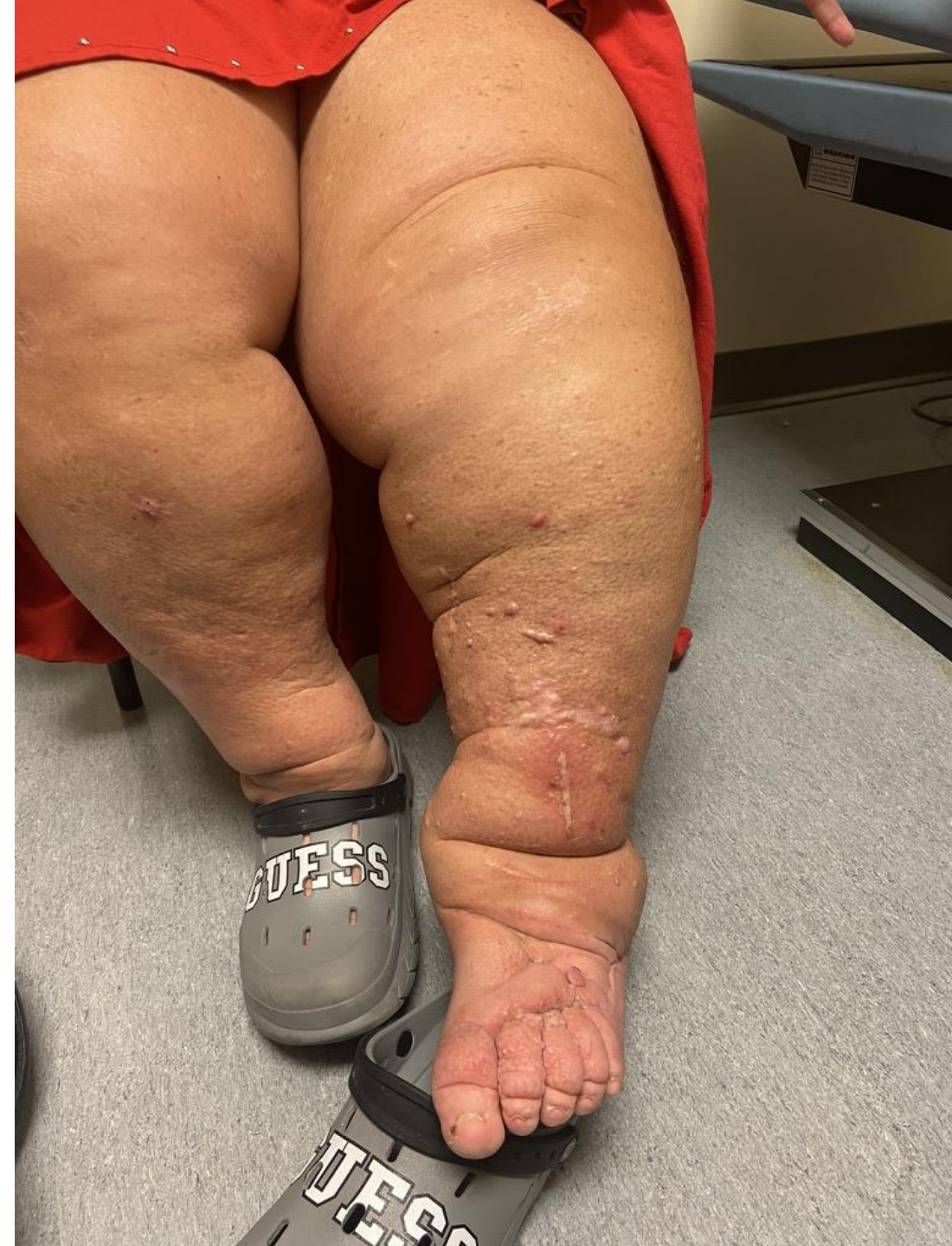

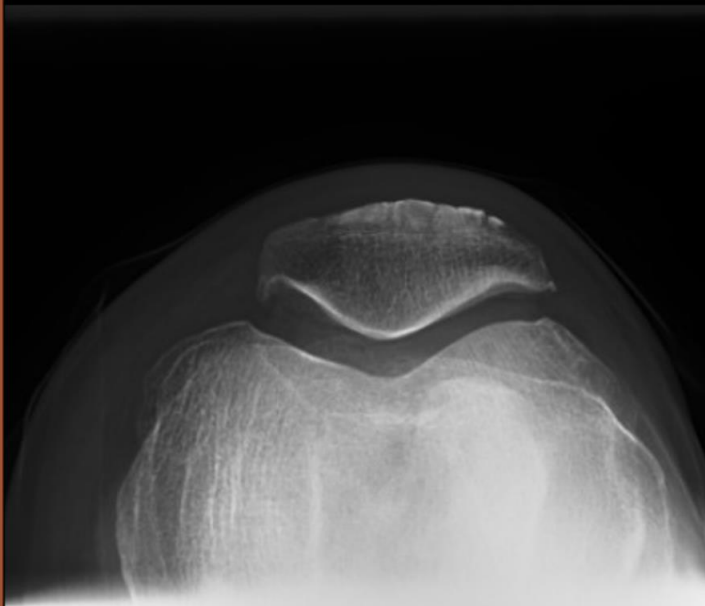

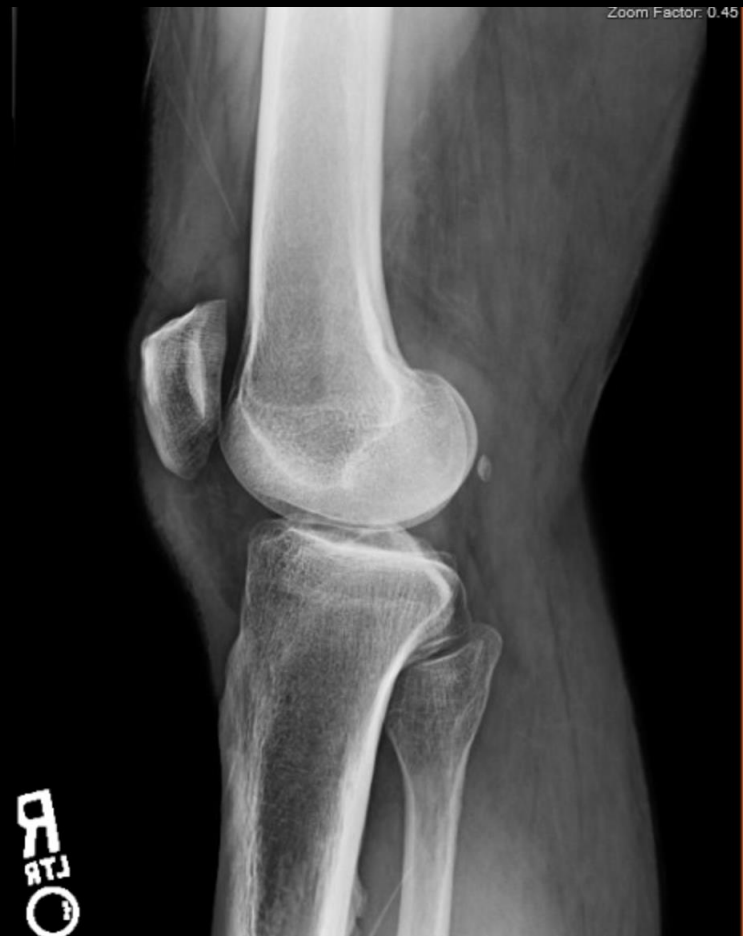
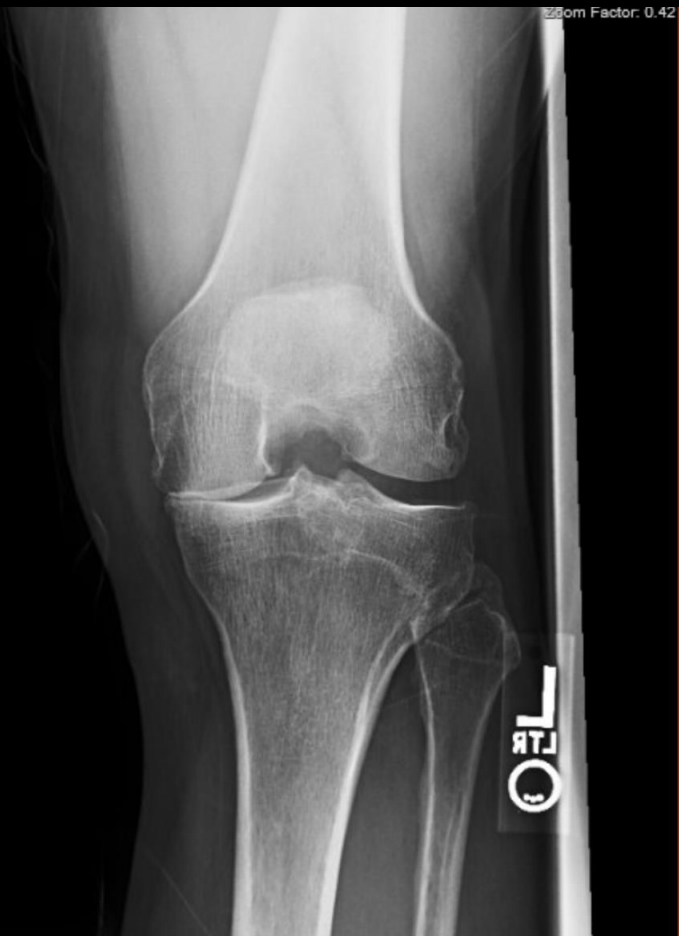66 yo female  
congenital  
lymphedema  
(Milroy's), hx of PE,  
COPD, CA, PTSD

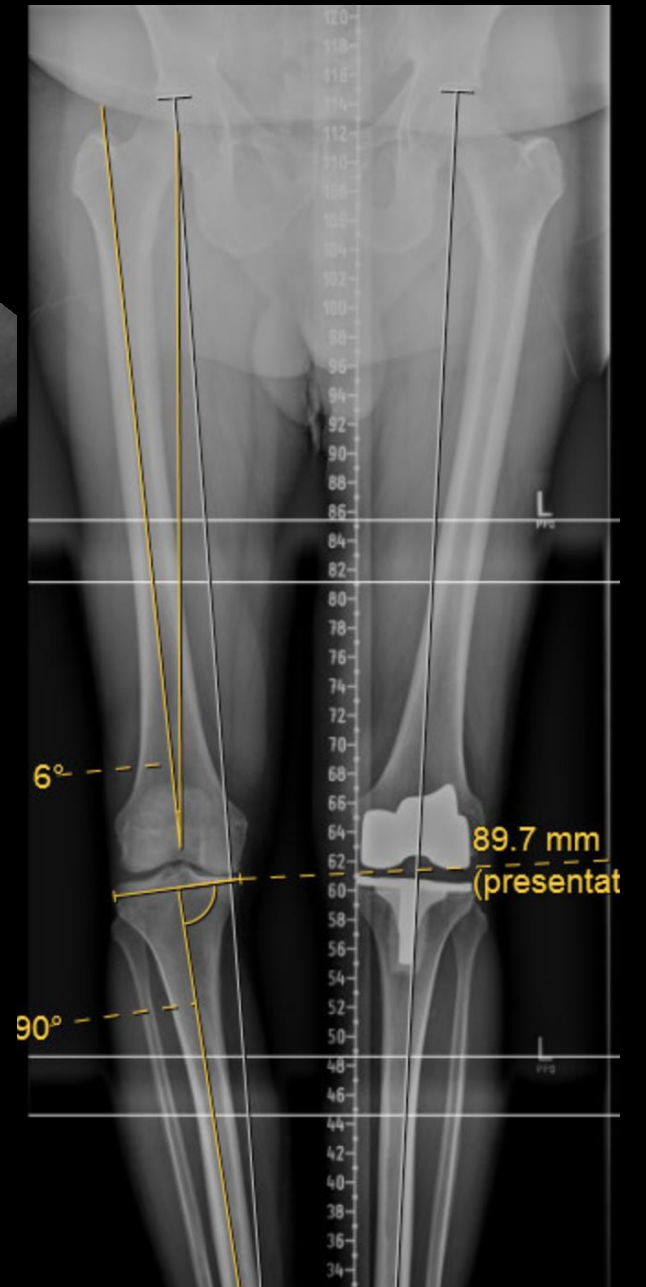
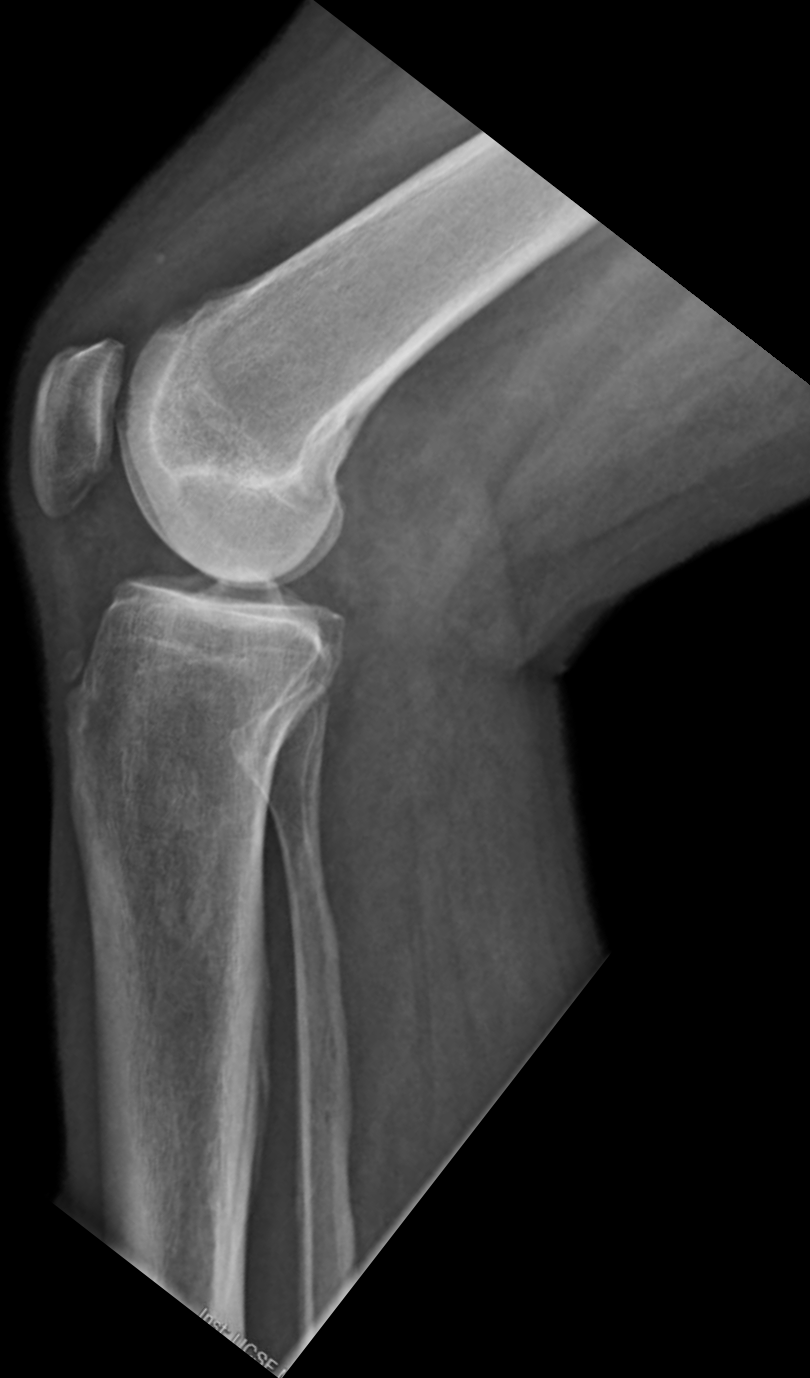
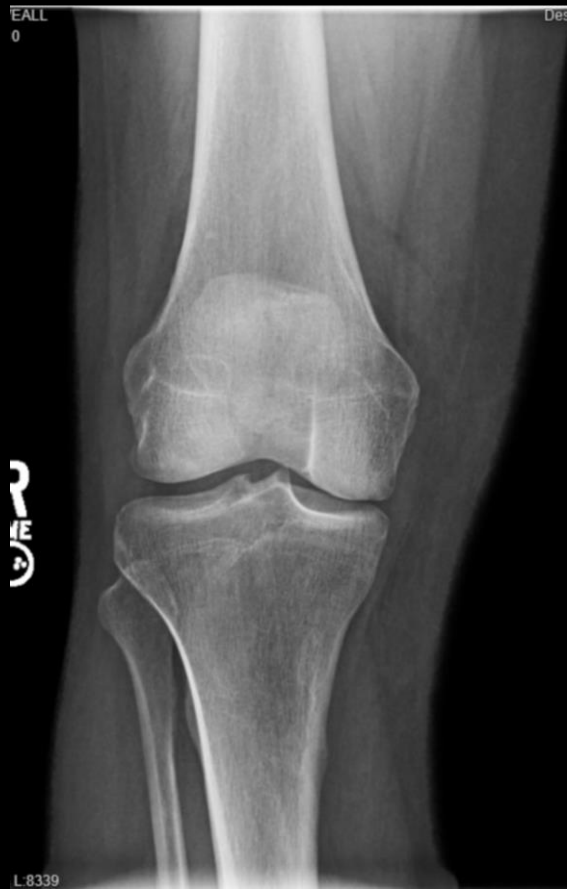
- Surgical Indications
- Surgical Management
- Post operative care

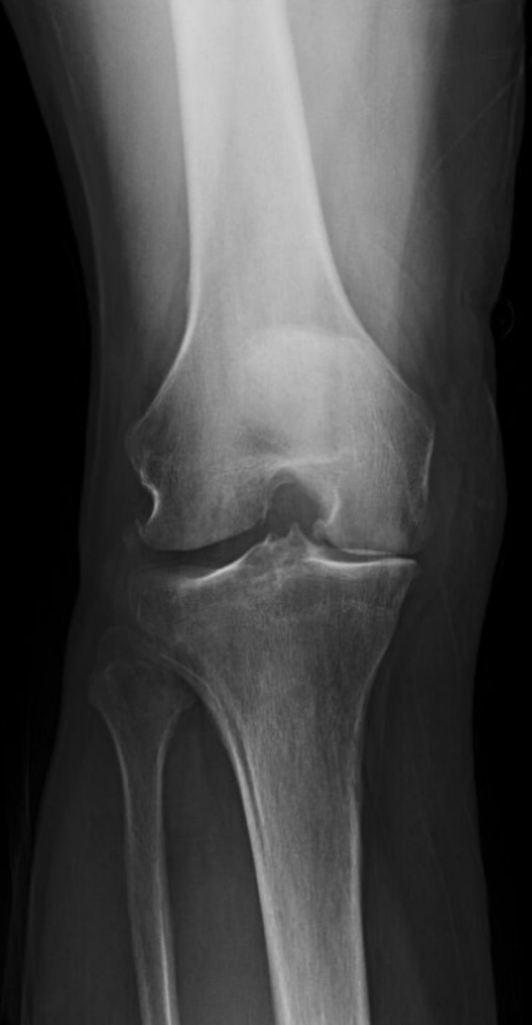



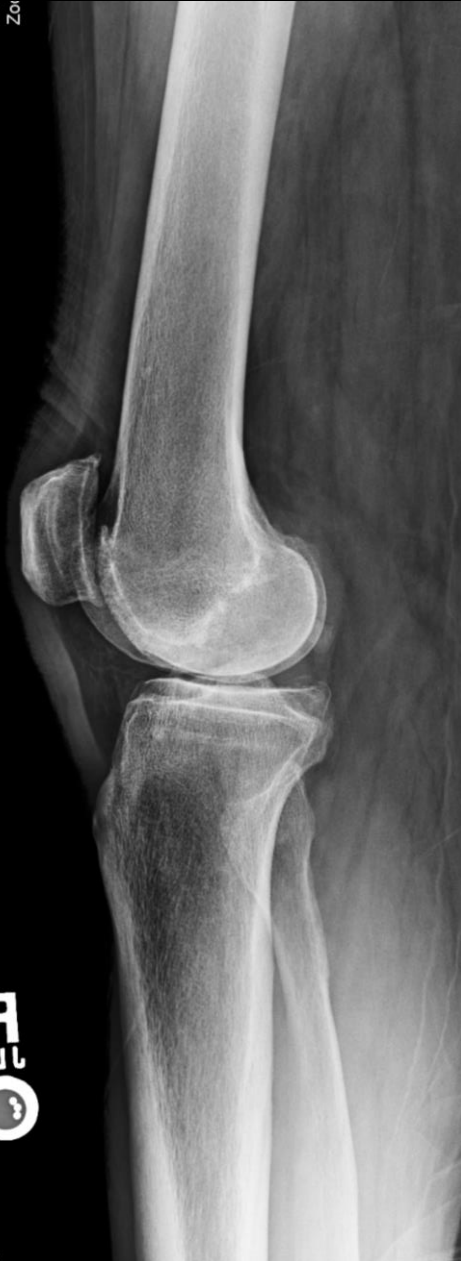(MRN: 66233820)  
63M L knee med OA -> L UKA  
PMHx: none  
All: nkda  
DVT: ASA  
ID/Abx: ancef



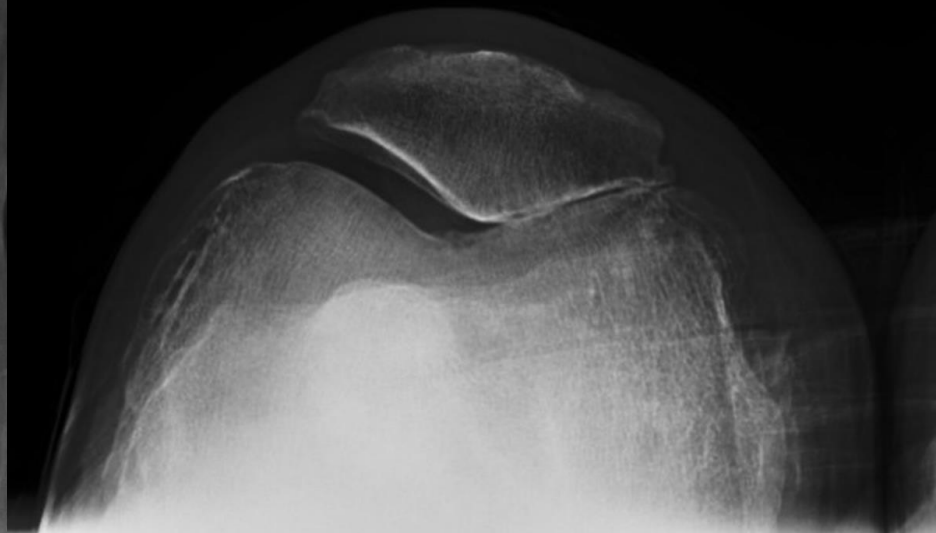
(MRN: 68511810)  
64M R knee OA-> R TKA  
PMHx: HTN, GERD  
All: NKDA  
DVT: ASA  
ID/Abx: ancef



AC  
Study Dat  
IM  
Zoi



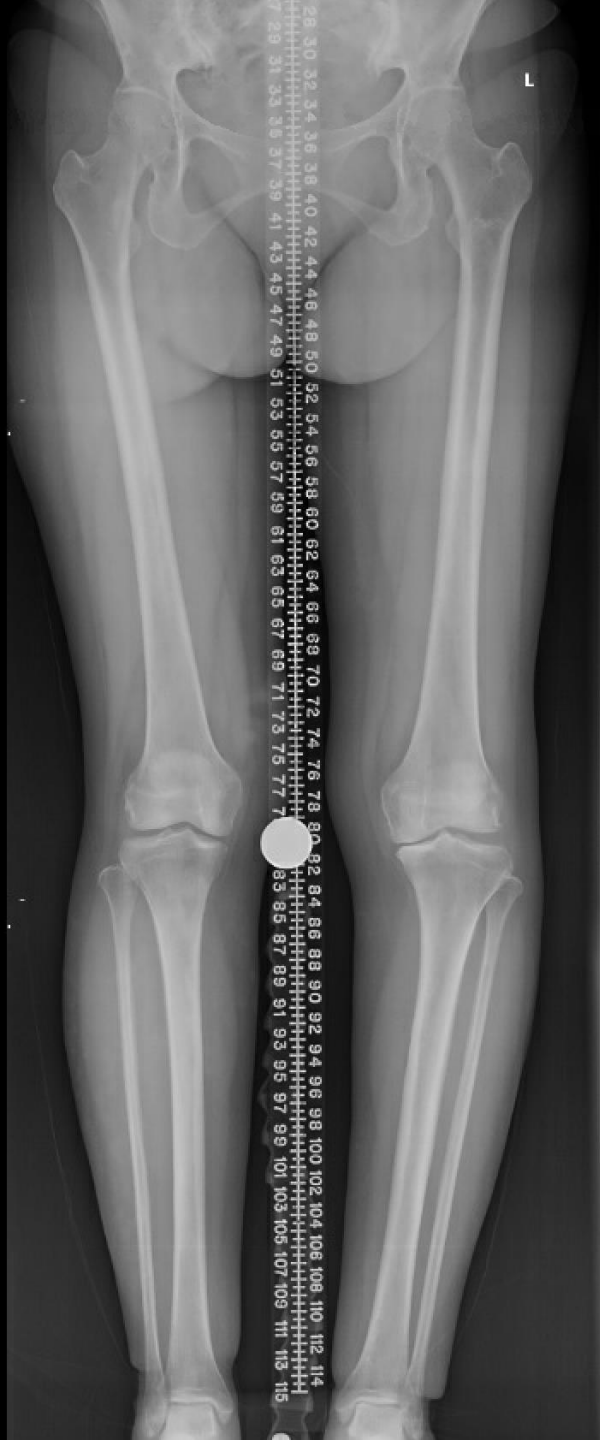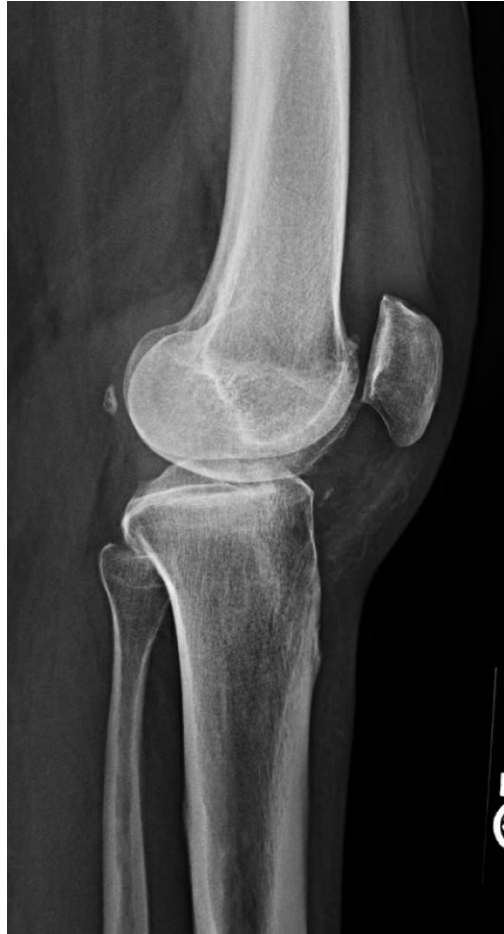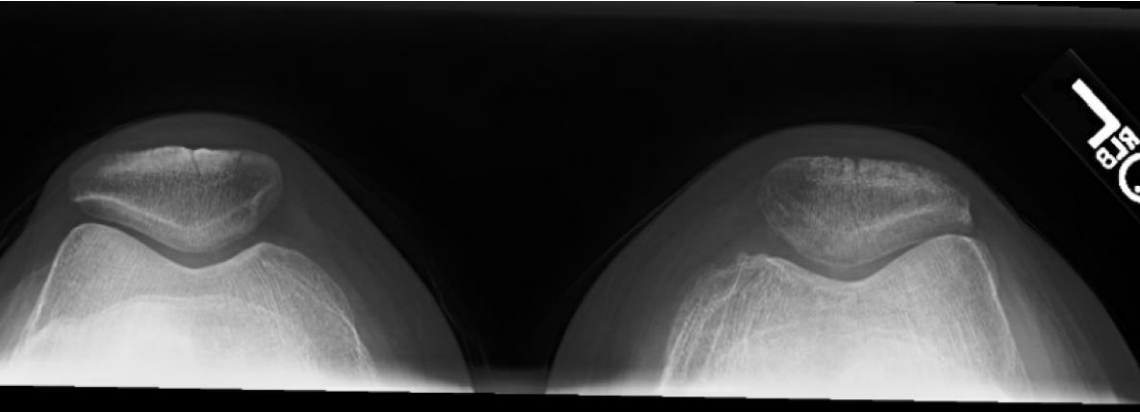
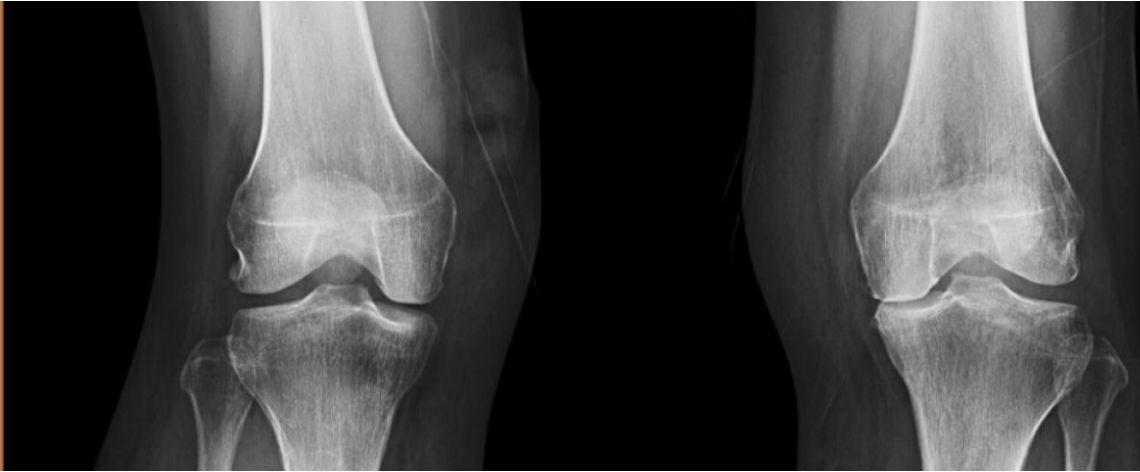
05574315  
072Y  
M



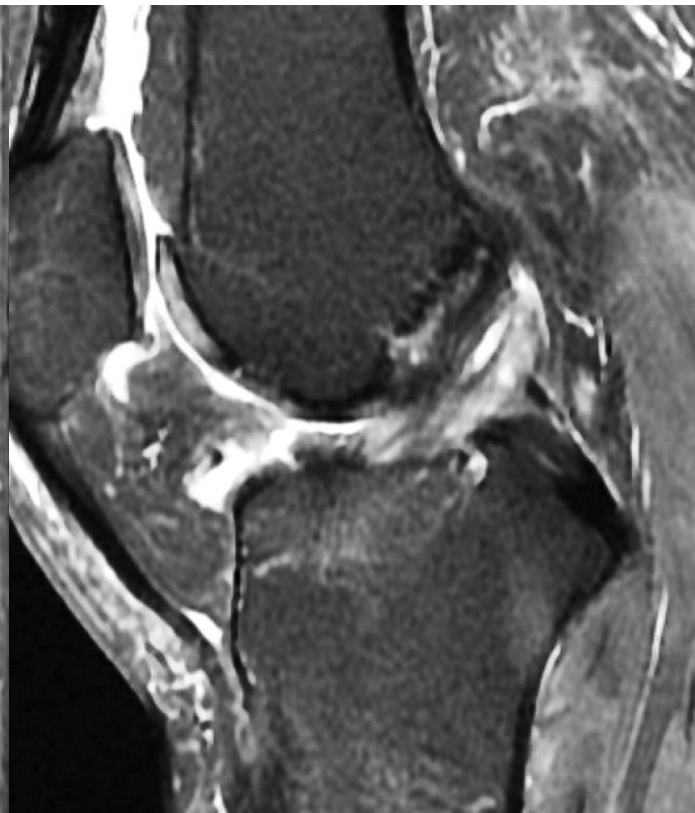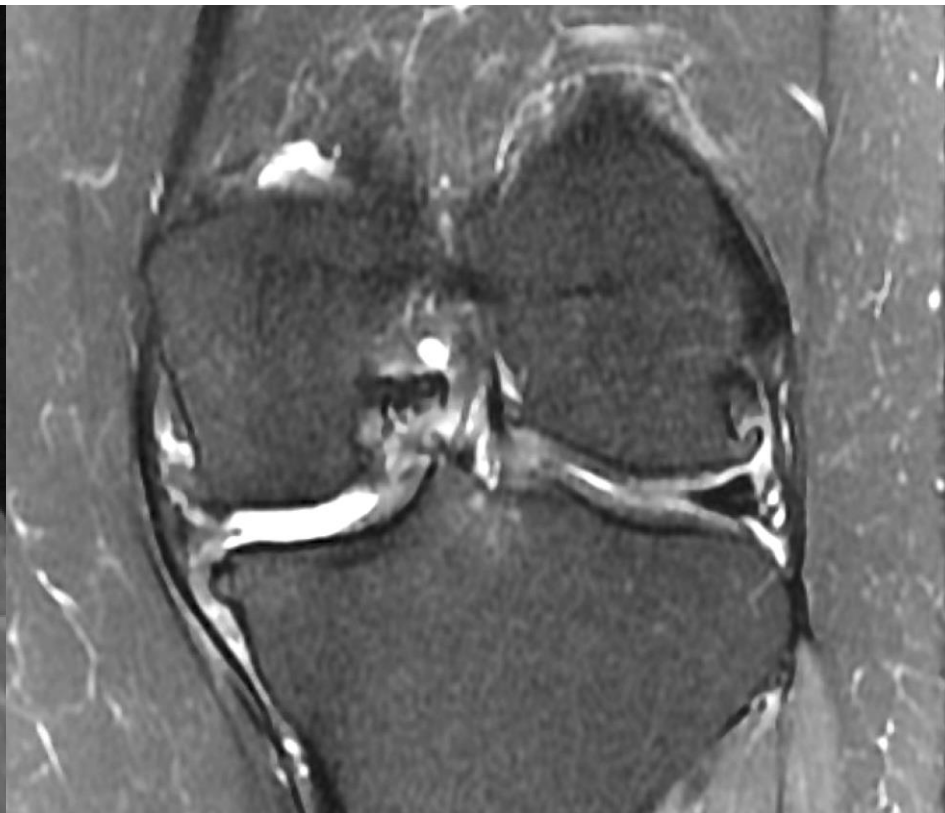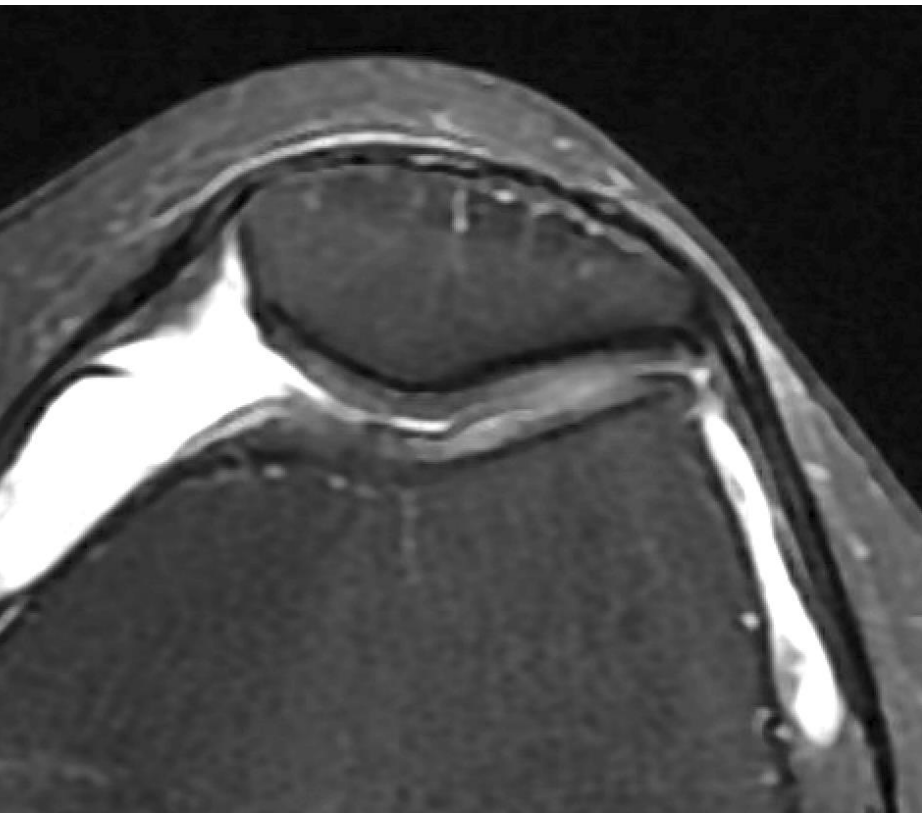
MD (MRN: 05574315)  
72M R knee OA-> R TKA  
PMHx: HLD, GERD, chronic back pain, RLS, ocular  
migraine  
DVT: ASA  
ID/Abx: ancef x1

\*\*\*No scannogram in PACS

58 yo asian female left med. knee pain

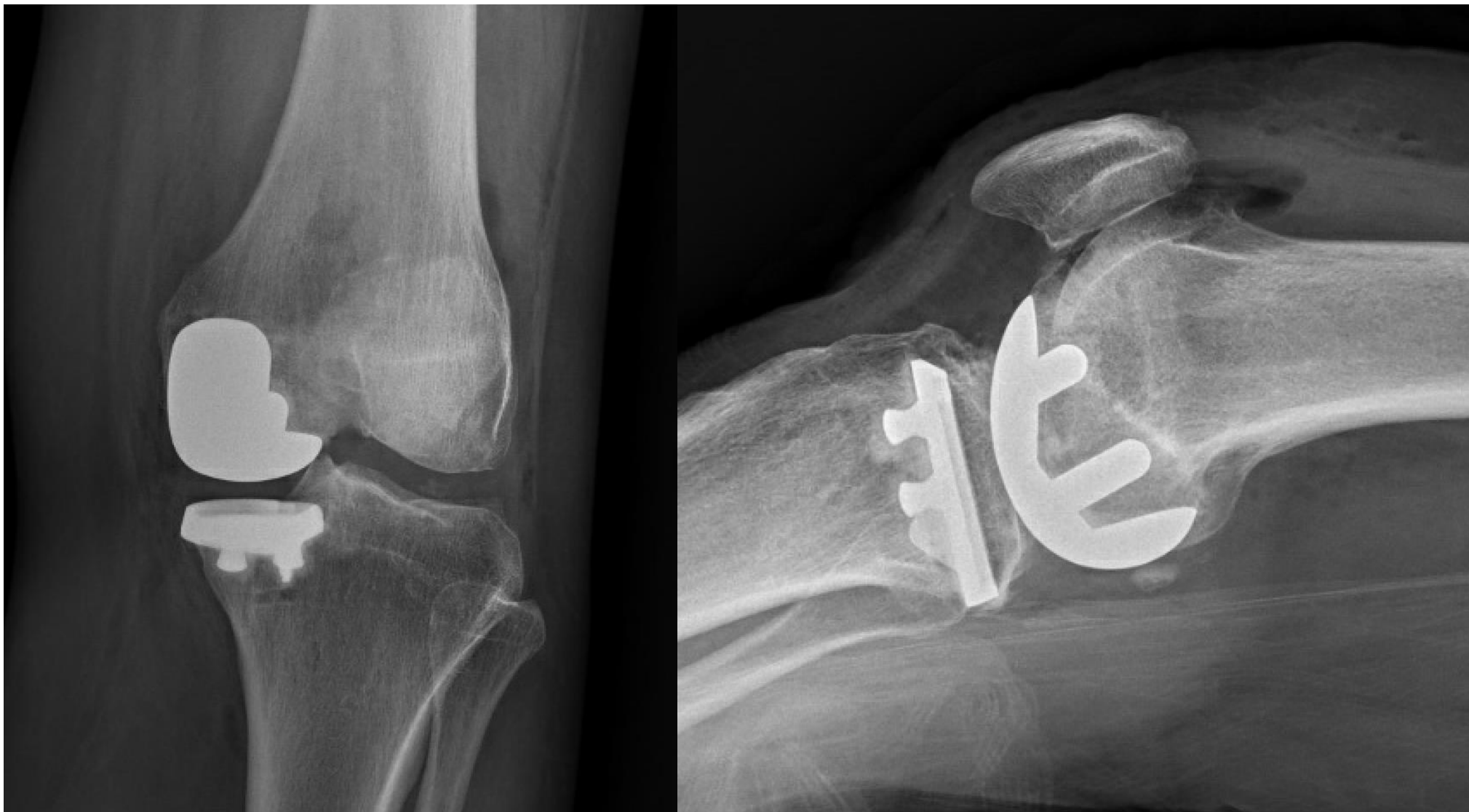

# MRI LEFT KNEE





26 may



22 June, 29 August, 15 September

