

SPORTS

Background.....	169	Knee	176
Physis	169	Meniscus Tear	176
Maturation	169	Discoid Meniscus	176
Gender	170	Patellar Instability.....	177
Thermoregulation	170	Osteochondritis Dissecans.....	178
Obesity	170	Ligament Tear	179
Genetics	170	Shoulder	180
Epidemiology	171	Traumatic Instability	180
Injury Prevention	171	Atraumatic Instability	180
The Disabled Child	171	Little Leaguer’s Shoulder	180
Type of Injury.....	172	Impingement	181
Ligament	172	Elbow.....	181
Muscle.....	172	Medial Little Leaguer’s Elbow	181
Physis	172	Lateral Little Leaguer’s Elbow	182
Fibrocartilage.....	172	Other	182
Bone.....	172	Exertional Compartment Syndrome	182
Concussion	173	Plica.....	183
Strength Training.....	173	Reflex Neurovascular Dystrophy	183
Ankle	174		
Ankle Sprain	174		
Osteochondral Lesion of Talus.....	175		

BACKGROUND

Participation in sports is on an inexorable rise in Western culture. At play in this trend are the societal prioritization of physical fitness; a zeal for competition; the building of character, for example, confidence, self-image, discipline, and teamwork; a recognition that occupying a child’s time with sports is diverting from other allurements of youth, for example, the “screen–refrigerator” complex; and the financial incentives for sports industry and participant, for example, the promise of remuneration in college and beyond. Fueling the frenzy is the presumption that enjoyment is not enough: excellence and success are the driving goals, which may be achieved only by means of early adoption and specialization, for example, preschool, and long hours.

This chapter focuses on the distinctive aspects of sports in the immature skeleton, in contrast with the late teenager, who blends with the adult.

Physis

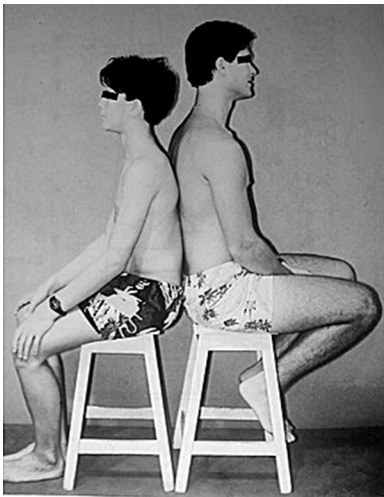
This provides the single sharpest contrast between children and adults with regard to injury and treatment (*cf.* Trauma chapter).

Maturation

Age is a stricter defining criterion in children than in adults, for example, 1 year separates middle school from high school, yet an ocean separates them socially, psychologically, and physically. Children mature at different rates, whereas adults are mature by definition. Differences are amplified by the growth acceleration of puberty, which correlates with the peak of serious injuries presenting to an emergency facility. The principal stratifier in sports participation during childhood is chronologic age. These factors account for unanticipated psychic and physical risks to children finding their place in sports. A method of stratification based upon assessment of biologic maturity, including such factors as Tanner stage, is more appropriate and safer.

Numbers	Comment
3%	High-school participants in soccer, basketball and American football who go on to play in division I or II
1%	Obtain a college scholarship for athletics
\$10,000	Average scholarship
1/5000	Play at the professional level

A Success in youth sports The average scholarship covers half the cost of a state school and <1/4 the cost of a private institution. This must be balanced against the costs of lessons, camps, and time raising the elite athlete.



B Differential maturation Even though both are the same age, a boy sits next to a man. This has far-reaching implications on sports participation and performance [Blount].

Age	70's	00's
Preschool	5%	10%
Prepuberty	4%	15%
Adolescents	6%	15%

Food	Cost 1990 → 2007
Energy dense	Cola: ↓ 35%
	Fast food: ↓ 10%
Vegetables	↑ 10%

C Childhood obesity Childhood obesity was stable until the early 1970s. Its rise coincides with the crossing of child *per diem* consumption of milk (decline) and cola (increase). It has doubled or tripled in a generation. Reductions in the price of food account for 1/3 of the rise in body mass index in children and young adults. There is no evidence that family income impacts obesity. However, maternal employment does (e.g., less time, more prepared food), correlating with a 10% to 33% rise in obesity of children in upper socioeconomic strata.

Gender

Vigorous physical activity delays menarche. A practical outcome is elimination of this as a measure of maturity in the management of conditions affected by growth, for example, scoliosis. Beware of the triad of amenorrhœa, eating disorder, and osteoporosis, which puts the female athlete at increased risk of overuse injuries or stress fractures. Maturation has a narrower window in girls than in boys, in whom it has a long tail, for example, running performance plateaus after puberty in girls whereas it continues to increase in boys.

Thermoregulation

Children’s capacity to regulate body temperature is less developed compared with that of adults. A greater surface area to body mass means greater heat absorption from the environment. A growing body produces more metabolic heat *per* mass unit during physical activity. Children sweat less, reducing heat dissipation by evaporation. They have a duller thirst response and so replenish fluid loss later than adults. These characteristics increase the risk of heat-related illness.

Obesity

Childhood obesity is multifactorial and in tumultuous evolution. Obesity may be defined as body mass index >95th percentile. Risk factors include urban residence, which highlights the effects of a sedentary lifestyle with greater access to food, uterine exposure to maternal diabetes and adiposity, and genetic factors in association with certain diseases, for example, Prader-Willi. Musculoskeletal complications include accelerated maturation, lower limb deformity such as Blount disease and slipped capital femoral epiphysis, and increased musculoskeletal complaints such as back pain, all of which may limit activity.

Even though input, for example, eating, and all the forces that influence it, including the economics of food, are ultimately more influential than is output, for example, exercise, sports are intimately intertwined and integral to abatement of the obesity epidemic.

Genetics

The type of sport in which a child participates is determined by interest (of child and parent), social environment, and continual competitive selection. The genetic basis for physical ability and psychological aptitude has remained veiled except for the most rudimentary characteristics such as height for basketball or weight for wrestling. An expanding body of research is uncovering gene polymorphisms that will allow a much more sophisticated understanding. For example, polymorphism in the gene encoding actin-binding protein α -actinin-3, a highly conserved component of fast-twitch skeletal muscle fibers, may separate power and speed athletes from endurance athletes. A recognition that genetics is an immutable component of the performance phenotype may decompress the family when the child does not meet expectations. Genetic testing to identify child aptitude, and the development of sports profiles, will enable more informed and rational decision making.

EPIDEMIOLOGY

Reporting (e.g., in sports that place a premium on toughness) and definitions (e.g., by a coach vs. trainer vs. physician) introduce imprecision in statistical analysis of sports injuries.

Two million children *per annum* are seen in an emergency setting for a sports-related injury. Another 2 million receive nonemergency medical care. Total cost of management of paediatric sports injuries is \$2 billion *per annum*. Most injuries are benign [A]. American football is most injurious [B] and most dangerous, having a 10 times greater rate of catastrophic event, such as permanent nerve deficit, than do other sports. Annual attrition from organized sports is 1/3, while total attrition by adolescence is 3/4. Boys sustain more injuries than do girls, whose rate is increasing more steeply due to more rapid increase in sports participation. Fractures and physial overuse injuries predominate in preteens, whereas ligamentous injuries come to the forefront in teenagers.

Injury Prevention

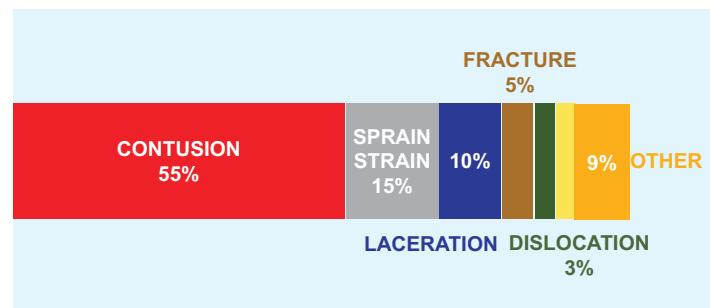
Sports and play injuries are unique in that exposure is elective, recurrence is not unusual, and prevention is possible. There are several strategies that may be taken to make these activities safer for children [C]. Three-fourths of school playground fractures involve the upper limb, of which >1/2 are supracondylar humerus fractures (*cf.* Trauma chapter).

THE DISABLED CHILD

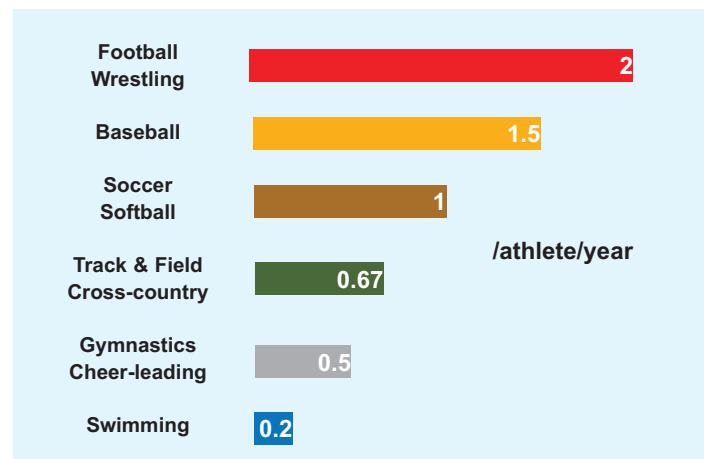
The International Wheelchair Games were hosted by Dr. Ludwig Guttmann (German-born refugee to England) on the opening day of the 1948 Summer Olympics in London, for World War II veterans with spinal cord injury. The first Paralympic (Greek παρά: “beside”) Games took place in Rome in 1960. There are six categories of disability: limited mobility or wheelchair, amputation, blindness, cerebral palsy, intellectual impairment, and other. The disabled realize the same benefits of sports as able-bodied children. Because they are less active at baseline, sports and strength training are essential for the disabled, including to control obesity, reduce contractures, increase muscle strength, build bone mass, and integrate into the society around them.

In children with Down syndrome, a requirement for participation in Special Olympics is no evidence of instability on lateral flexion–extension röntgenogrammes of the cervical spine. Special considerations for patients with spina bifida relate to vulnerability of skin to breakdown, including from brace wear; fractures, which restrict them from high-contact sports; and wheelchair use. For cerebral palsy, seizure control is essential.

Wheelchair injuries are primarily soft tissue. This ranges from blisters on the hand to decubitus ulcer, due to the design that raises the knees above the pelvis. Overuse injuries are common, in particular of the shoulders.



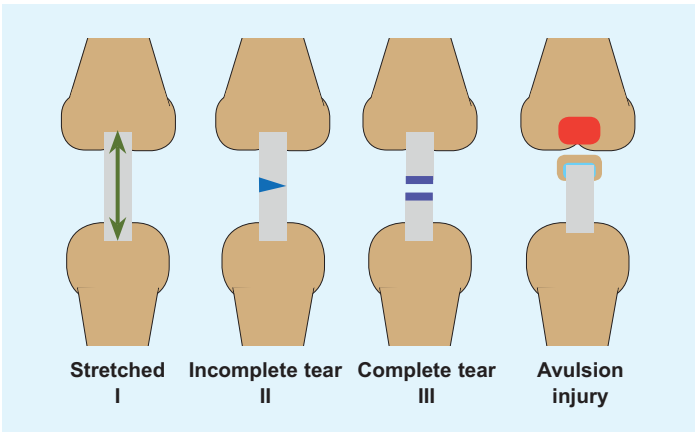
A Sports injuries in children Most are benign. Yellow represents concussion at 3%, which will command a larger proportion as focus is brought upon it.



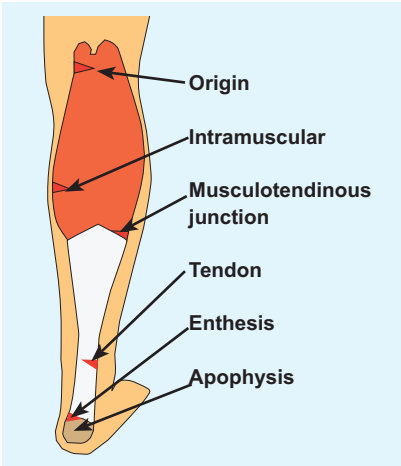
B Injuries brought to medical attention by sport American football leads, followed closely by wrestling. Categories are simplified: in each, the upper has a slightly greater rate. For bigender sports, there are no significant differences. Softball approximates soccer rather than baseball.

PLAYGROUND	
Surface	Soft: shredded rubber, sand, ? wood chips Hard: grass, soil, cement
Fall zone	9 ft between equipment
Height	1 ft/year age up to 6 ft
Entrapment	6" between bars to avoid entrapment of limb or head No open hooks that may catch clothing
PRACTICE & GAME	
Athlete	Fitness Strength training Rest Hydration Protective clothing
Coach	Use and maintenance of correct equipment Education, e.g., first aid, CPR, injury protocols Enforcement of safety rules Reporting of injury Multiple sports with no specialization
Community	Pre-participation assessment Funding, e.g., facilities, monitoring, medical care Evidence based rules and regulations Behavior modification

C Injury prevention in youth sports Recommendations in an evolving landscape. Some are straightforward, others nebulous. An example of the latter is behavior modification, yet 1/3 of athletes who quit include negative interactions with a coach or parent as a reason. Softness of wood chips is debated.



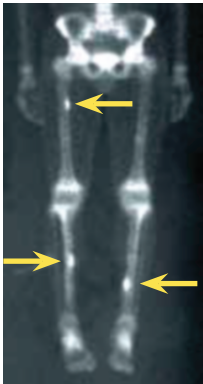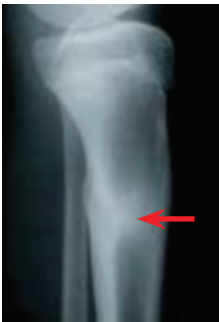A Grading of ligamentous injury In type I, there is injury and pain but no instability. In type II, there is more motion but a clear endpoint on manual testing. Type III is characterized by instability, is associated with capsular injury, and lacks an endpoint. Avulsion is a reflection that ligament is stronger than bone in the immature child. The quintessential example is fracture of the intercondylar eminence of tibia.



B Triceps surae injury Different levels of injury present a constellation: muscle strain; tendinitis, including in association with retrocalcaneal bursitis; enthesitis, for example, associated with ankylosing spondylitis; and apophysitis (Sever).

Common Sites	Sport
Medial epicondyle	Throwing, (e.g., baseball)
Iliac spine	Kicking, (e.g., soccer)
Ischial apophysis	Jumping and landing, (e.g., gymnastics)
Apex of patella	Jumping, (e.g., basketball)
Tibial tubercle	Jumping, (e.g., basketball)
Calcaneal apophysis	Running and jumping, (e.g., soccer)

C Apophysal injury These result from traction during activities exemplified by the most common sports with which they are associated. The knee dominates in frequency.



D Stress fracture Multiple may occur, as in this cross-country runner. Röntgenogramme shows hyperostosis (red). Scintigramme reveals involvement of both tibia and femur (yellow).

TYPE OF INJURY

Sports injuries may be acute or chronic, which may be described as overuse. Overuse injury results from repetitive submaximal loading, leading to microtrauma that may be reversed by rest. In the absence of rest, cumulative microtrauma results in stress injury. It is a diagnosis of exclusion:

- Pain is intermittent, punctuated by periods of normal function. It does not awaken the child from sleep, even though it may delay falling asleep and require the comfort of a parent. It is not localized, for example, child cups the patella with the hand.
- There are no objective signs of macroinjury, such as joint effusion or other inflammatory sign, deformity, instability, or atrophy.

While initially more benign than acute injury, overuse may take longer to heal; requires active involvement of the child for recovery and future prevention, for example, stretching program and other behavior modifications; and may result in more time away from sports. Rest is simple and cheap and effective, yet may be the most vexing prescription to child and family.

Sports injuries may be divided anatomically into ligament, muscle, physis, fibrocartilage and bone.

Ligament

Ligaments fail suddenly in most cases, by contrast with physal injuries, which tend to result from repetitive stress. Ligament injuries may be classified [A]. Ligament injuries are most common around the ankle and knee. They may coexist with bony injuries, as seen in tibial spine fractures.

Muscle

Injuries may be of muscle belly, tendon, or enthesis [B].

Physis

In addition to acute fracture (*cf.* Trauma chapter), children involved in sports may present with chronic repetitive stress injuries, for example, Little League shoulder (*q.v.*). Unlike acute fracture, the physis becomes widened, irregular, and tender, but not grossly unstable. One type of injury may usher in the other, for example, Osgood-Schlatter condition preceding fracture of the tibial apophysis. Certain synchondrosis disruptions are classified separately, for example, accessory navicular (*cf.* Foot chapter).

Fibrocartilage

This consists of meniscus and labrum. In the knee, the medial meniscus is more constrained (2-3 mm excursion) compared with the lateral meniscus (10 mm). The medial meniscus is more susceptible to trauma, leading to tear, while the lateral meniscus is more susceptible to reactive hypertrophy, as in the genesis of the discoid form. In the shoulder, the labrum is essential to stability, while in the hip the rôle of the labrum is less clear (*cf.* Hip chapter).

Bone

Acute fractures are discussed in Trauma. Chronic injuries may result from traction [C] or compression, for example, stress fracture and osteochondritis dissecans.

Stress fractures occur most frequently in the tibia (*cf.* Trauma chapter), metatarsal bones, and femur, for example, in runners [D], and the distal radius and at the pars interarticularis, producing spondylolysis, for example, in gymnasts (*cf.* Spine chapter).

Osteochondritis dissecans represents segmental avascular necrosis of subchondral bone with injury to overlying cartilage. Causes include repetitive microtrauma and a genetic predisposition to localized juxta-articular ischaemia. A subgroup of patients may have been given this diagnosis for disordered epiphysal maturation. It is classified based upon the geographic extent of injury, as determined by injury and at time of operation [E]. Cartilage and stability guide treatment.

- Stage I. Cartilage is intact and fragment is stable. Manage closed.
- Stage II. Cartilage is partially disrupted but fragment is stable. Manage closed or open.

- Stage III. Cartilage is completely disrupted. Fragment remains in place but is loose and at risk for displacement. Manage open, and include fixation.
- Stage IV. Osteochondral fragment has displaced. In the acute setting, it may be returned to the donor site and fixed, with the expectation that it will heal. In the chronic setting, the fragment becomes eroded such that it cannot be put back. Reconstruct the donor site.

CONCUSSION

This also may be referred to as mild traumatic brain injury. Rapid short-duration neural impairment results from biomechanical force applied or transmitted to the head. The pathophysiology includes force resulting in ion dysregulation and vasoconstriction that lead to an energy crisis in the brain. Grading is retrospective, with severity determinable only after recovery. By definition, brain imaging is negative. It is impossible to estimate the scope of the problem because definition, classification, and diagnosis are in flux; however, there is universal agreement that concussion has been underestimated and is increasing.

Preparticipation screening is essential to establish a child's baseline cognitive function. Concussion varies by sport [A]. Symptoms and signs may not appear until hours after the inciting event [B]. Loss of consciousness is rare, and if it lasts more than 30 seconds, should raise concern for a significant intracranial lesion. Assess an athlete away from the field in an environment that will be used for follow-up, such as a quiet room. Any evidence of a structural brain injury is an indication for brain imaging. Postconcussive symptoms and signs typically resolve after a week.

Remove a concussed athlete from the game, from physical exertion, and from school, for a period of "cognitive rest." Allow a return to sports after resolution of signs and symptoms, but not sooner than a week. Because most repeat concussions occur within the first 2 weeks after injury, this may be regarded as a window of vulnerability and a guide for return to sports [C]. Recurrence of symptoms after exertion indicates incomplete recovery. There is no consensus on retirement of an athlete from a sport. This may be considered for the athlete who sustains three concussions in the same season or in whom postconcussive symptoms and signs persist beyond 3 months.

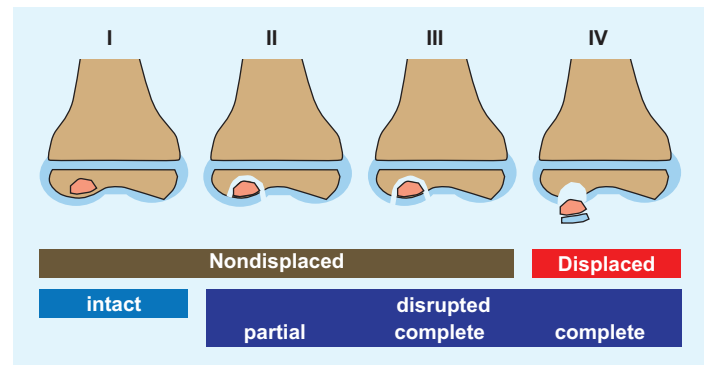
STRENGTH TRAINING

This also is known as resistance or weight training. Strength training enhances muscle power (by resistance) and endurance (by repetition). Strength training differs from body building, which is occupied with aesthetics and stands on its own as a competitive sport. Goals of strength training include both improved performance and reduced injury.

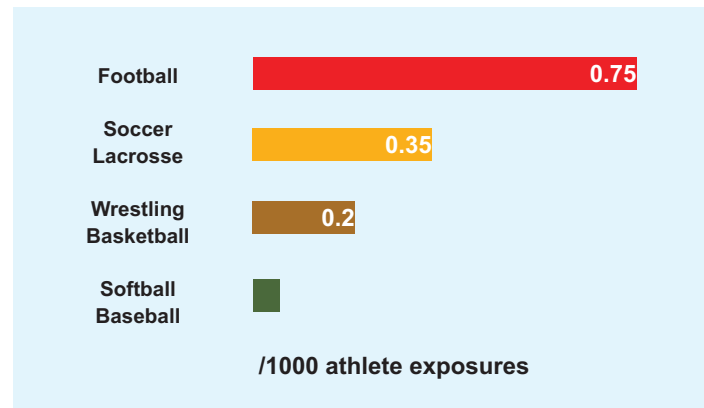
Weights may be free, for example, dumbbell, or static, for example, machine. By requiring control of a limb in space, free weight improves coordination and balance as well as strength. Static weight, in a supported position, is safer. Closed chain exercises are performed with the hand or foot stabilized. A free hand or foot opens the chain. Isotonic exercise maintains a fixed resistance while muscle length varies. In isometric exercise, a muscle contracts without changing its length, for example, in an immobilized limb. Muscle contraction may be concentric, in which length decreases, or eccentric, characterized by lengthening of the muscle during resistance. The latter may accelerate power acquisition at the expense of an increase in injury rate. Alternating concentric and eccentric contraction in rapid succession forms the basis of plyometrics, or jump training, which may reduce the rate of anterior cruciate ligament tears in female athletes.

Strength training in prepubertal children is effective without muscle hypertrophy by recruitment of motor neurons for a given muscle mass.

Begin strength training after 7 years of age, by when a child has developed adult balance and posture control. A schedule of 2 to 3 times/week for 3 months will yield significant results safely. Start with large muscle groups and transition to small. Maintain high repetitions (10) and titrate resistance in 10% increments. Perform 1 to 3 sets with 1 to 3 minutes of



E Classification of osteochondritis dissecans I: Osteonecrosis. II: Dead bone has become separated from surrounding bone, as evidenced by a "halo." Cartilage (blue) is partially injured. III: Overlying cartilage is completely broken. Fragment remains in place but is loose and at risk for displacement. IV: Osteochondral fragment has separated or become "dissected" (König) to become a mobile body. There is no desiccation, or "drying."



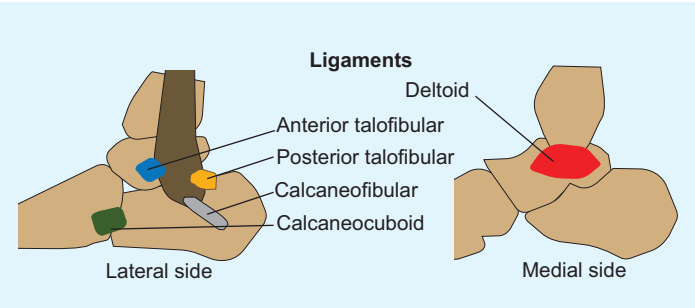
A Concussion by sport American football leads. Data for certain high-risk sports, for example, ice hockey, are limited.

Physical	Cognitive	Emotional	Sleep
Headache	'Foggy'	Irritable	Drowsy
Nausea	Difficult concentration	Sad	Altered pattern
Vomiting	Amnesia	Nervous	
Balance			
Visual			
Fatigue			
Sensory hypersensitivity			

B Symptoms and signs of concussion Balance may be tested by three positions: standing on both feet with hands on iliac crests with open and shut eyes and standing on the nondominant foot.

Concussion rehabilitation
No physical activity + cognitive rest
Light aerobic exercise
Sports-specific exercise
Noncontact drills
Full-contact practice
Game

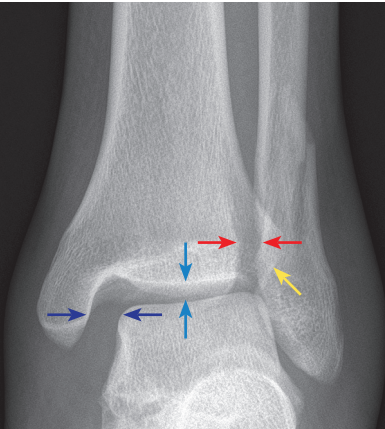
C Concussion rehabilitation Return to sports is gradual. Once symptoms and signs have resolved, the athlete may progress through each stage no faster than every 24 hours.



A Ankle ligaments The anterior talofibular ligament, extending from anterior margin of the fibular malleolus to the talus distal to its lateral articular facet, is most frequently injured. The calcaneofibular ligament, the longest, is a rounded cord that courses from fibular malleolus to a tubercle on the lateral surface of the calcaneus, where the peronei longus and brevis run over it. The posterior talofibular ligament, the strongest of the lateral complex, runs from fibular malleolus to a tubercle on the posterior surface of the talus lateral to the groove for flexor hallucis longus. The deltoid drapes over the tibial malleolus and has two laminae. Superficial consists of tibionavicular, calcaneotibial, and posterior talotibial. Deep consists of anterior talotibial fibers.

Attenuation	Mild swelling and tenderness
Partial tear	Moderate swelling, unable to bear weight
Complete tear	Marked swelling, bleeding, instability, and disability

B Grading of ankle sprains.



C Deltoid disruption The ankle of this mature teenager was stepped on, resulting in an acceptably displaced distal fibula fracture. The force emerged through the deltoid ligament, widening the medial joint (*navy*) compared with the superior tibiotalar distance (*blue*). Normal clear space is <6 mm (*red*) and normal overlap of fibula and tibia is >1 mm (*yellow*) on mortise view.

rest between them. Book end each session with a 10-minute period of warm up, including stretching, and a 10-minute cool down. “Detraining,” or loss of strength, occurs at 5% to 10%/week. There is no deleterious effect on growth. With proper technique and supervision at no lower than 1:10 instructor:student ratio, there is no increase in injury.

ANKLE

The ankle accounts for the largest number of orthopaedic complaints in the child athlete. Sports as a stress test may awaken silent conditions, such as tarsal coalition, or turn normal into abnormal, such as irritation of the calcaneal apophysis.

Ankle Sprain

This represents tear of one or more ankle ligaments, which may be divided into medial and lateral [A]. The medial is termed deltoid, after its resemblance to an upside-down Greek letter delta, Δ . The lateral group consists of three independently named ligaments. Ankle sprains may be classified by severity [B]. With increasing severity, more of the ligamentous complex is torn, bearing with it more pain and instability. The peak incidence of ankle sprain is in latter teenage years. Basketball is the most abundant source (25%), followed by soccer (20%) and American football (15%).

Ankle sprains may be recurrent, due to excessive force in the coronal plane transmitted to the ankle by a tarsal coalition that limits subtalar motion. Also in the differential diagnosis are peroneal retinacular tear and traction on an accessory os subfibulare.

Most ankle sprains are produced by an inversion mechanism. Eversion (1%) produces the high ankle sprain, in which there is disruption of the tibiofibular syndesmosis. Direct force to the lateral leg results in a valgus moment on the knee and external rotation of the ankle.

Evaluation Ask about the mechanism of injury, such as “rolling” the ankle. Swelling may be focal, for example, anterolateral at the anterior talofibular ligament, or diffuse, suggesting a more complete injury that includes the entire lateral ligamentous complex. The deltoid ligament is injured rarely in children. Cutaneous change, for example, ecchymosis, may track beyond the ankle, marking the extent of soft tissue disruption. Look for foot deformity, and range the subtalar joint, to rule out tarsal coalition. Percussion, which will transmit force to bone while minimizing stretch to injured soft tissues, above the tip of fibula may reveal physal injury; immediately beyond the tip, it may reveal os fibulare avulsion.

Examination of motion is not feasible in the acute setting. In the chronic setting, talar tilt or inversion of the ankle tests the anterior talofibular and calcaneofibular ligaments. The anterior drawer manoeuvre also stresses the anterior talofibular ligament. External rotation with valgus tests the deltoid ligament. External rotation and maximal ankle flexion test the syndesmosis, which also may be stressed by manually compressing tibia and fibula.

For eversion testing, ask a patient to stand and rotate the pelvis away from the affected side, reproducing the mechanism of injury. A single limb calf raise will hurt.

IMAGING For a child who is unable to bear weight, or for clinical suspicion of an osseous injury, röntgenogrammes are indicated. Check the trochlea of talus for osteochondral fracture. MRI is the imaging modality of choice to evaluate ligamentous injury, although this rarely is necessary.

Management Ankle sprains are the most undertreated sports injury and have the highest rate of recurrence. Do not hesitate to place a child in a cast to immobilize the ankle enough for the torn ligament(s) to heal. Stiffness is not a concern. Most difficult to achieve is behavior modification: support and rest the ankle and stay out of sports until clinically healed. For a cooperative older child, a cam walker worn full-time for up to 6 weeks suffices. No walking until no pain; no jumping and no running. Healing is evidenced by no swelling, no tenderness, full motion, and unfettered ability to bear weight, which may be assessed by observing no limp, single limb calf raise, hopping, squatting, and “duck walking.”

For a syndesmosis injury, as evidenced by widening of the medial joint or tibiofibular clear space, treat with a syndesmotic screw or suture button or both. Remove the screw in 3 months if you don't want it to break.

Osteochondral Lesion of Talus

Anterolateral lesions of the trochlea are more often associated with a recognized traumatic event than posteromedial lesions, which are the product of repeated microtrauma [A]. Mechanism for the former is compression in ankle flexion (dorsiflexion) and eversion, as when an athlete pivots on a planted foot. For the latter, the ankle is extended (plantar flexed) and inverted, as in push off during running. There is no gender predilection. Peak incidence is in the second decade.

Evaluation There may be a history of trauma. The patient complains of ankle pain, which is associated with effusion and stiffness. The patient may sense a mobile body. Chronic ankle pain or persistent ankle pain after there has been sufficient time for an acute injury to heal should raise suspicion for this diagnosis.

IMAGING Obtain roöntgenogrammes in ankle flexion and extension to view the anterior and posterior margins of trochlea [B]. Roöntgenogrammes may not identify stage I lesions, which will be detected on scintigramme. Cartilage is best seen on MRI, which permits classification and guides management.

Management Prognosis for healing of lesions when they present in the first decade is better than second decade. Acute lesions have a higher healing rate than chronic lesions, of which half heal by closed methods. Stable lesions may be managed closed. Unstable lesions require operative treatment.

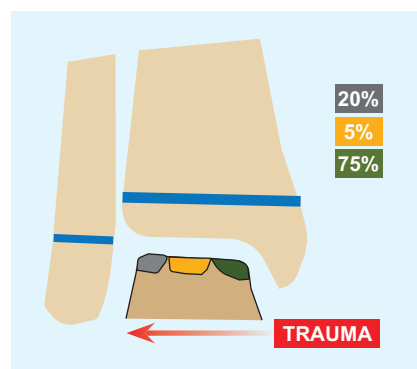
STAGE I AND II Cast for 6 weeks with touchdown weight bearing. The lesion is stable, and the cartilage remains partially intact. If the lesion does not heal, operative treatment is indicated. The necrotic bone may be drilled retrograde through the lateral body of talus [C]. Use an image intensifier or an arthroscope to make sure the overlying cartilage is not disturbed. Harvest autogenous bone graft from calcaneus or distal tibia and pack through the drilled tunnel to support the cartilage surface. Alternatively, the lesion may be opened like a book arthroscopically, hinging on the intact cartilage. The bed is débrided of necrotic tissue and drilled or fractured with an awl to stimulate bleeding and healing of the bone. Because opening the lesion may destabilize it, add fixation.

Small lesions and those that are difficult to access may be excised, although there is no consensus on size or location.

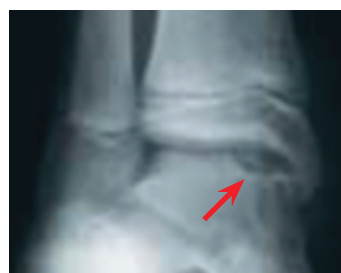STAGE III Treat as an unhealed stage II. Add fixation because the lesion is unstable.

STAGE IV If the fragment is viable and has a reasonable osseous component for union, treat as a stage III. Sculpt the donor site to match the fragment. Otherwise, remove the mobile body. If the defect is small, excise, débride, and drill. If large, reconstruct, which requires open access. Lateral lesions may be accessed by an oblique fibular osteotomy emerging distal to the syndesmosis or ligament and capsular release with subluxation of the talus anteriorward. Posteromedial lesions may require osteotomy of the tibial malleolus [D]. Reconstruction options include osteochondral allo- or autograft transfer and autogenous chondrocyte implantation. The latter has the disadvantage that it requires two stages. The first consists of harvest of full-thickness cartilage with superficial layer of subchondral bone from the knee or retrieval of the osteochondral lesion from the talus. The chondrocytes are isolated and grown in laboratory. In the second stage, the lesion is débrided and oversewn with a periosteal flap obtained from the distal tibial, after which the chondrocyte suspension is injected. Advantages of autogenous chondrocyte implantation include ability to treat large and rim lesions, obviating concerns about shape matching.

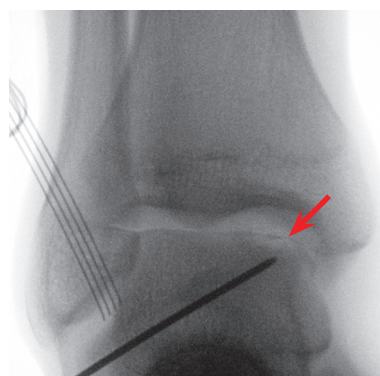
Outcomes Prognosis for healing of lesions when they present in the first decade is better than second decade. Acute lesions have a higher healing rate than chronic lesions, of which half heal by closed methods. Stable lesions heal more reliably and by closed methods. The fate of lesions requiring open reconstruction is unclear.



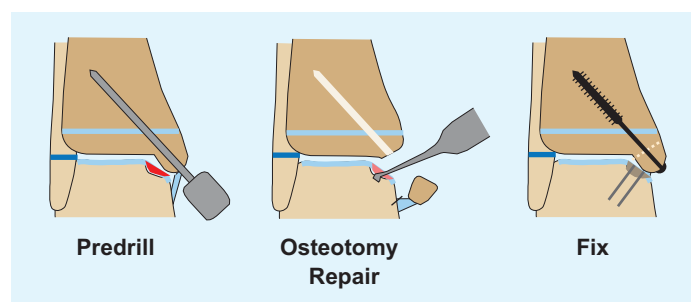
A Location of osteochondritis dissecans of the talus Lateral lesions tend to be due to acute trauma.




B Roöntgenographic appearance of osteochondritis dissecans There is sclerosis of the trochlea and a halo surrounding the lesion (red).



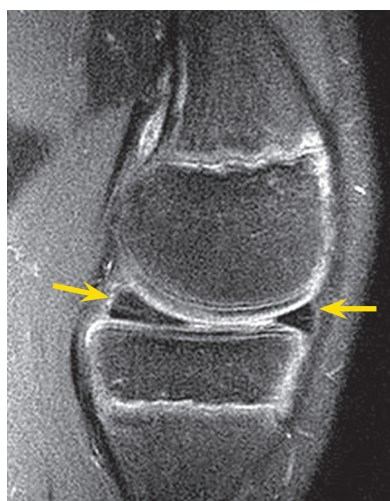
C Retrograde drilling of osteochondritis dissecans A guidewire is passed through the lateral body of talus into the lesion (red). An image intensifier confirms that the wire is centered on the lesion in all planes. An arthroscope monitors the cartilage to make sure it is not disturbed. The guidewire is overdrilled to break up the necrotic bed. The drill tunnel is curetted and irrigated. Bone graft is tamped through the tunnel to support the overlying cartilage until the lucency is filled.



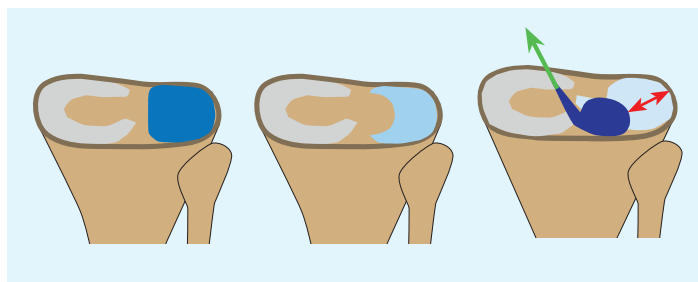
D Osteotomy for exposure This aids orthogonal approach to a posteromedial lesions.



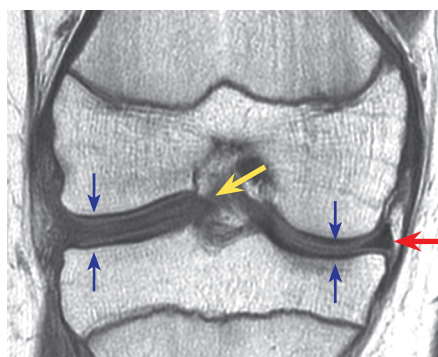
A Patterns of meniscal tears Tears may occur in every direction and in every plane. Medial displacement of the longitudinal tear is likened to a bucket handle (green). Displacement may also produce a flap (blue). Radial tears start in the avascular zone (red). Complex tears combine fundamental patterns.



B Meniscal vascularity Posterior horn shows vascular ingrowth from periphery into center of healthy meniscus (yellow). The articular surface of meniscus is intact, arguing against tear.



C Classification of discoid meniscus tear Two-thirds are complete (blue), covering the entire lateral tibial articular surface, and 1/3 are incomplete (light blue), covering <80%. One-fourth of these demonstrate rim detachment and instability, 50% at the anterior horn, followed by 40% posterior horn and 10% in the middle third. A variant (navy) is degenerative and lacks meniscocapsular ligaments to anchor to the lateral capsule, detaching it from the tibia (red). Its only attachment (green) is the meniscofemoral ligament of Wrisberg, which travels posterior to posterior cruciate ligament to reach femur.



D Discoid meniscus Lateral discoid meniscus appears rectangular on cross section (yellow) as opposed to the typical triangular shape (red). The complete fullness separates and flattens the lateral condyles, an increased distance and morphology that raises suspicion on röntgenogramme. The discoid meniscus extends into the intercondylar notch.

KNEE

The knee accounts for the greatest burden of surgical care in the paediatric athlete.

Meniscus Tear

This is a second-decade injury. Mechanism is twisting and compression, without or with coronal plane deflection. They may be longitudinal or radial, described according to the surface of the meniscus, incomplete or complete, based upon the depth of tear. Longitudinal tears may be intra-substance, which may displace as a bucket handle. They may be break through one horn, where displacement creates a flap. There are other patterns, including horizontal cleavage and complex combinations.

The adolescent meniscus may be divided into outer third, described as red because it is well perfused by a blood supply that enters from synovial membrane into the outer margin, middle third, or red-white, and inner third, which is white and avascular. At birth, the entire meniscus has a vascular network, which retreats to the adult state by the second decade.

Evaluation There may be a history of sudden onset pain without or with hearing a noise from, or feeling a click in, the knee. Presentation includes knee pain, often around the joint line, mechanical signs such as locking and crepitus, and effusion, which is a sign of instability. Provocative testing, including twisting in and out in single limb stance on a partially flexed knee (Thessaly) and maximal flexion, elicits pain.

IMAGING Röntgenogrammes are negative except in a discoid meniscus (*q.v.*). MRI is the modality of choice, but exercise caution. Do not interpret blood vessels coursing through the meniscus, visible on MRI in particular in the prepubescent child, as a tear. A tear requires an interruption in the articular surface of the meniscus. On the other hand, MRI may underestimate lateral meniscal injuries.

Management Most meniscal tears in children are longitudinal in the peripheral red zone, which heal well with repair. Reserve débridement only for untidy or unstable tears or those in the central avascular region, repairing any extension into the red zone. Reduction in meniscal surface area will increase joint pressure, accelerating degeneration of the knee. Meniscal débridement in children has greater consequence than in adults, because they have longer to walk on the knee.

Discoid Meniscus

The term describes resemblance of the meniscus to a disc rather than a crescent (Greek *μήνη* “moon,” Latin *luna*, hence the alternate term semi-lunar cartilage) due to preservation of its central portion. The majority are lateral. They are rarely bilateral. Cause is unknown. Incidence is 4%. A disorganized collagen fiber scaffold makes them vulnerable to tear, at twice the rate of normal menisci. Classification is based upon shape and stability [C].

Evaluation Most discoid menisci escape detection in childhood because they are stable and not torn. An unstable discoid meniscus may shift into the intercondylar fossa with extension, presenting as a snapping knee: there is audible crepitus, a palpable shift, and a visible bulge at the anterior lateral joint line. This is intermittent and activity related. Absent instability, the patient may present with pain due to a tear.

IMAGING Röntgenogrammes may show widening of the lateral joint width associated with squaring of the condyles, suggesting an interposed block of tissue. MRI is the modality of choice [D]. Three or more body segments will be visible on sequential images. Continuity between meniscal horns gives the appearance of a “bow tie.”

Management Observe discoid menisci identified incidentally. Even though they are more prone to tear, there is no evidence that prophylactic treatment reduces this rate. Symptomatic discoid menisci are saucerized, in which the central portion is arthroscopically débrided leaving a 6- to 8-mm rim. Repair or débride associated tear. Repair rim detachment to the capsule. Counsel the patient and family that what you leave behind is not a normal but a better meniscus.

Patellar Instability

Habitual instability or dislocation differs from the congenital dislocation, which is irreducible (*cf.* Lower Limb chapter). Peak incidence is puberty. Redislocation rate is 20% after index event, which in more than half of cases occurs during sports. Girls are affected more than are boys. There are several predisposing factors.

- **Soft tissue.** This includes generalized ligamentous laxity, contracture of lateral patellar retinaculum, and attenuation of the medial patellofemoral ligament, which is a static stabilizer of the patella. This courses from the superomedial margin of patella to the medial femoral epicondyle between adductor tubercle and attachment of tibial collateral ligament, adjacent physis.
- **Muscular weakness,** in particular vastus medialis obliquus and core muscles, which act as dynamic stabilizers of the patella.
- **Osseous.** A patella supera is displaced out of the trochlea. A dysplastic trochlea does not retain the patella. How much this is a primary factor, or one that develops due to erosion by an instable patella, is unknown. Genu valgum increases the lateral force vector, as does lateral torsion of tibia along with tibial tubercle, and medial torsion of femur.

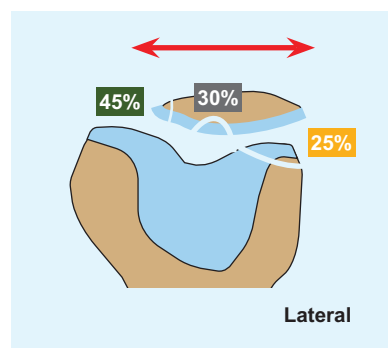
In knee extension, the patella is not engaged in the trochlea, held in place by dynamic and static soft tissue stabilizers. By 30 degrees of flexion, the patella is fully seated in the trochlea, which takes over as the osseous restraint.

Evaluation Ask about the inciting event, to assess likelihood of an associated fracture in the event of significant trauma. Medial patellofemoral ligament injury occurs in 2/3 of traumatic dislocations, and fracture in 1/3 [E]. Ask about the number of recurrent events, which may include pain and giving way in routine activities such as changing direction. Pain is associated with swelling in the acute setting. Note the position of the patella in knee extension, and track it during flexion. Manipulate the patella for laxity. Check apprehension in extension and during knee flexion, which is more reliable. Measure intermalleolar distance for genu valgum. Determine the rotational profile of the lower limbs.

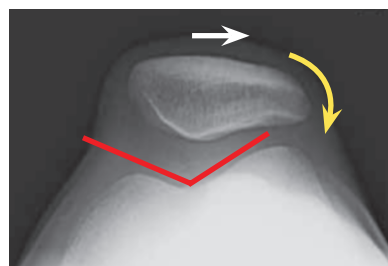
IMAGING Full-length standing anteroposterior view röntgenogrammes allow calculation of genu valgum and quadriceps angle. Lateral view may demonstrate patella supera, as well as the sclerotic line of a trochlea *en profil* crossing the condyles anterior to the anterior femoral cortex, which is a sign of trochlear dysplasia. Merchant view shows patellar tilt and translation and allows calculation of the sulcus angle [F]. The sulcus angle may be underestimated on a single view röntgenogramme. MRI in habitual dislocators may show that the trochlea is flattened by overlying articular cartilage despite an osseous groove. Calculate the tibial tubercle–trochlea distance, which is a measure of lateral torsion: abnormal is >20 mm. Trace the medial patellofemoral ligament, and look for an avulsion fracture or bone bruising.

Management Nonoperative management focuses on strengthening of vastus medialis obliquus, gluteal, and core muscles. This is successful in most first time dislocators but only half of second time dislocators, who are manifesting intrinsic patellofemoral disease. Similarly, family history is a risk factor for failure of nonoperative management. This highlights the importance of static restraints, both soft tissue and bony.

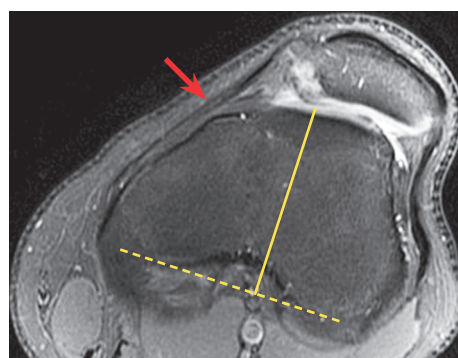
- Correct genua valga by growth modulation (*cf.* Lower Limb chapter).
- Correct medial torsion of femur by derotational osteotomy.
- Lateral retinacular release is indicated for lateral patellar tilt without significant translation. This is not a stand-alone procedure but is combined with more complete reconstruction.
- Proximal realignment includes advancement of vastus medialis obliquus and nonanatomic medial soft tissue imbrication.
- Distal realignment is indicated for tibial tubercle–trochlea distance >20 mm. In the immature, consider medialization of the lateral half of ligamentum patellae to periosteum or sartorius (Roux-Goldthwaite). This may be augmented by transfer of semitendinosus to patella (Galeazzi). For the mature adolescent, perform a tibial tubercle medial transfer.



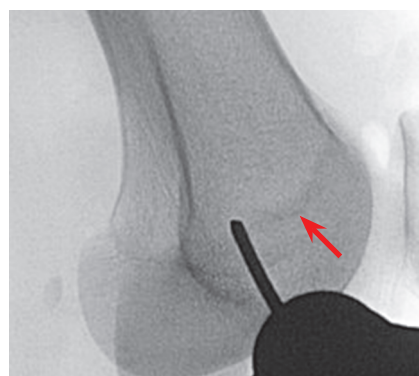
E Fracture after traumatic dislocation The lateral condyle or the articular surface of patella may be fractured as the patella dislocates. The medial margin may be fractured as the patella relocates or as an avulsion by the medial patellofemoral ligament.



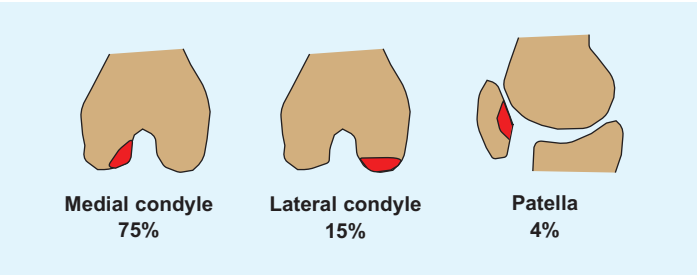
F Merchant view The sulcus angle (*red*) measures depth of trochlea: dysplasia is >145 degrees. The patella is tilted (*yellow*) and translated (*white*): abnormal is >10 mm. Note that Greek τροχίλεια means “pulley, groove, trochlea.”



G Trochlear dysplasia The trochlea is flat and does not restrain patella from lateral displacement. The medial patellofemoral ligament (*red*) is attenuated. The position of trochlea is determined by a perpendicular (*yellow*) to the posterior condylar margin (*dashed*). This is compared with a perpendicular to the tibia tubercle by overlapping axial images to measure the tibial tubercle–trochlea distance.



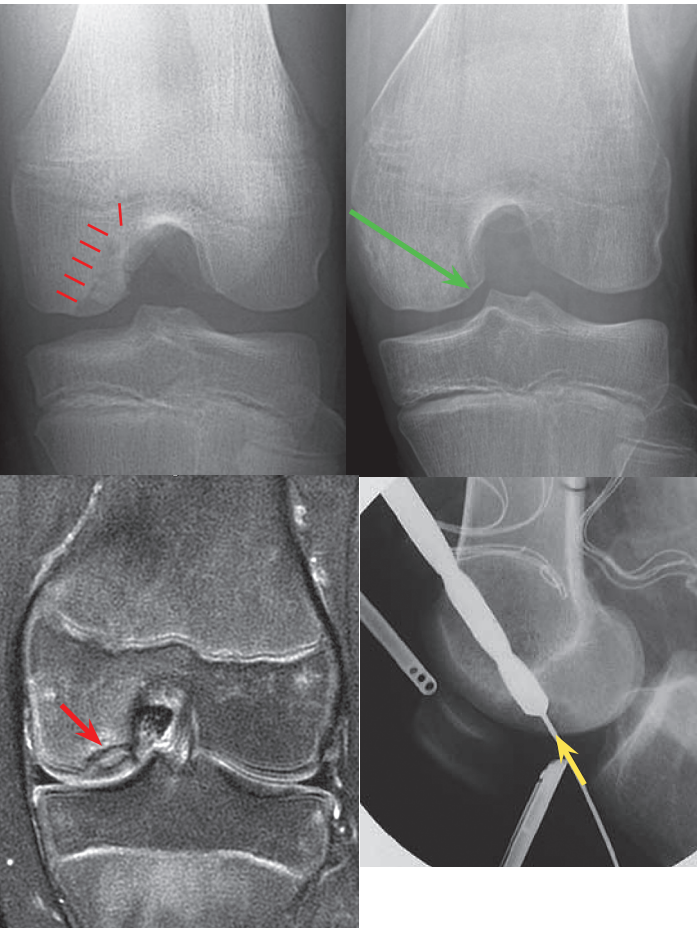
H Medial patellofemoral ligament The isometric femoral tunnel site is immediately proximal to the distal physis of femur (*red*) and anterior to the posterior cortex extension line.



I Distribution of osteochondritis dissecans of the knee Other lesions that have been reported include of trochlea and tibial condyle.

CHARACTERISTIC	POOR PROGNOSIS
Stability	Halo or mobile body
Size	> 400 mm ²
Age	2nd decade
Location	Atypical

J Prognostic factors in osteochondritis dissecans of the knee.



K Drilling of osteochondritis dissecans of the knee The lesion is seen on notch view röntgenogrammes and MRI (red). It was drilled antegrade (green) through epiphysis away from physis. Most of the lesion was healed by 6 months after operation. The technique may be facilitated by inserting the guidewire through the center of the lesion as viewed and probed at arthroscopy (yellow).

- For patella supra, a distal transfer of tibial tubercle is indicated in the mature adolescent.
- Just like muscle strengthening harnesses dynamic stabilizers to compensate for static stabilizers, medial patellofemoral ligament reconstruction relies on a static soft tissue restraint to compensate for loss of static osseous restraint. Tendon graft is more durable than primary repair or medial soft tissue imbrication for the repeat dislocator. A medial strip of quadriceps may be sewn to the femoral attachment site, or a strip of adductor may be sewn to the patellar attachment site. Tension the graft at 30 degrees of knee flexion such that it allows 25% of lateral patellar displacement. These techniques avoid the distal physis of femur [H]. For the mature child, autogenous gracilis tendon or allograft may be secured by drill holes in patella and tensioned through a tunnel in femur.
- Trochleoplasty may deepen the trochlea by elevating the lateral condylar surface or depressing the center. Concerns about alteration of the articular surface, and the consequences of patellofemoral arthritis, have slowed acceptance of this procedure.

Osteochondritis Dissecans

Incidence is 1%, peaking at puberty and affecting boys twice as often as girls. Most lesions occur on the lateral aspect of the medial condyle of femur [I]. Up to ¼ are bilateral.

Evaluation There may be a history of trauma. The patient complains of knee pain, which is associated with effusion and stiffness. The patient may sense a mobile body. Gait may be characterized by lateral rotation of tibia, to move the intercondylar eminence away from a medial condylar lesion. This may be tested by extending the knee while medially rotating the tibia, which elicits pain that is relieved by lateral rotation (Wilson test). In terminal knee flexion, a condylar lesion may be tender directly.

IMAGING A condylar lesion may be obscured on anteroposterior projection röntgenogramme. It may be exposed by a 45-degree “notch view,” which brings the beam tangent to the lesion. A “halo” of sclerosis may surround the lesion. Scintigraphy may have value in predicting healing: “hot” lesions, like an acute fracture, may heal by nonoperative means, whereas “cold” lesions, like a nonunion, will not. Cartilage is best seen on MRI, which permits classification (*cf.* Type of Injury). Dissection of fluid on T2-weighted pulse sequence to form a “halo” indicates a breach of overlying cartilage and instability. The size of the lesion may be measured on MRI: >400 mm² have a poor prognosis [J].

Management Prognosis for healing of lesions when they present in the first decade is better than second decade. Nonoperative treatment focuses on symptoms. The benefits of activity modification, limited weight bearing, casting or bracing, and physiotherapy are unproven.

Indications for operation include presence of a “halo,” which on röntgenogramme indicates that the lesion has been walled off by the rest of the bone and represents a nonunion, large lesions >400 mm² in size, and mobile body. For stable but large lesions, or lesions surrounded by sclerosis, drill the bone to break up the wall and stimulate ingrowth. Drilling may be arthroscopic through the articular surface with a pin. Alternatively, an antegrade approach through the epiphysis beyond the physis with a cannulated drill may be utilized, using an image intensified to center the pin tip in the lesion and an arthroscope to ensure that the articular surface is not violated [K]. Graft the lesion through the drill tunnel. Unstable lesions and mobile bodies are treated as for the talus (*q.v.*).

Ligament Tear

Ligaments are at once unyielding and pliant. Posttraumatic knee instability is discussed in the Hippocratic Corpus. Knee ligaments may be divided into intra- and extra-articular. The former were termed cruciate by Galen after the manner in which they “cross” the joint (Latin *crux*: “cross”). They are distinguished as anterior and posterior based upon their site of attachment on the tibia. The latter are termed collateral and are named according to their site of distal attachment as tibial and fibular or after their location medial and lateral.

Injured collateral ligaments heal with closed methods. A posterior cruciate ligament tear can heal primarily by closed or by surgical methods. An anterior cruciate ligament does not heal primarily and is treated by replacement. Potential reasons for higher anterior cruciate ligament injury rates in girls include a narrower intercondylar fossa, a smaller cross-sectional diameter, differences in strength, flexibility and neuromuscular control, and hormonal profile. The anterior cruciate ligament consists of anteromedial bundle, the predominant constraint against translation, and a more horizontal posterolateral bundle, which predominates against rotation (pivot shift).

Evaluation Ask about the mechanism, such as valgus blow to the knee with the foot planted. The child may remember a noise from the knee and giving way. Was there swelling? A traumatic hæmarthrosis is associated with an anterior cruciate ligament tear in half or more of cases [L]. Are there repeated episodes of instability and effusion? When the knee is not inflamed and the patient does not guard, perform varus/valgus tests in 30 degrees of flexion, a posterior drawer at 90 degrees of flexion, an anterior drawer at 30 degrees of flexion (Lachman), and a pivot shift test. Check for concomitant meniscal injury, including palpation of the joint line and maximum flexion. Estimate the maturity of the child clinically.

IMAGING Röntgenogrammes screen the knee for fracture, such as of the intercondylar eminence (*cf.* Trauma chapter), or other lesion, and provide an assessment of the physis. MRI shows the ligaments [M], as well as associated articular lesions such as meniscus tear.

Management Partial anterior cruciate ligament tears may be treated nonoperatively if the physical examination shows no significant instability, in particular if the posterolateral bundle is preserved.

The natural history of a complete anterior cruciate ligament tear in a child is poor, because recurrent instability leads to articular injury, in particular irreparable medial meniscal tear and chondral injury.

PHYSIAL SPARING In the extra- and intra-articular technique, the iliotibial tract is harvested leaving its distal attachment intact, wrapped around the lateral femoral condyle (where it is fixed), passed through the knee, under the intermeniscal ligament, and sewn to the periosteum over the anterior margin of the medial tibial condyle [N]. This may overconstrain the knee in rotation. Alternatively, the semitendinosus and gracilis may be harvested leaving their insertion intact, tunneled through the tibial epiphysis, secured to the femoral footprint by a staple, and looped back through the tibial tunnel.

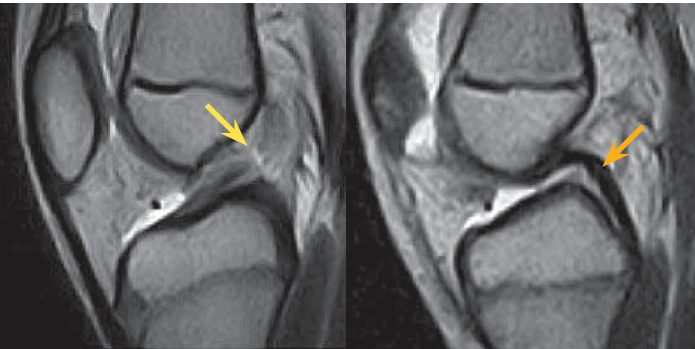
The physis may be spared by staying intraepiphyseal. Advocates reserve this for the “prepubescent.” The femoral physis may be spared, or the tibial physis, or both [O].

TRANSPHYSIAL This is indicated for any child. It is isometric and well established. Autogenous semitendinosus and gracilis grafts traverse, but are fixed remote from, the physis. Do not place bone (e.g., ligamentum patellæ) across the physis, where it will produce a bridge. Do not insert an implant across the physis, which eventually will stop growing. Remember that the treatment of a physal bridge is resection with soft tissue interposition. Keep tunnels <7% of the cross-sectional area or <10 mm. Anatomic femoral tunnel placement increases the percentage of physal removal, which argues for single bundle technique.

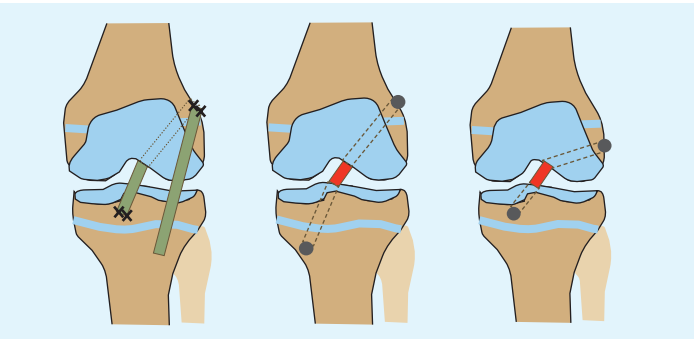
Posterior cruciate ligament injury is rare in children. Avulsion from the tibia is more likely than intrasubstance tear. This may be repaired arthroscopically, which allows evaluation of the knee for associated injury, or open, by a direct popliteal fossa approach.

HÆMARTHROSIS	Pre-puberty	Adolescent
ACL tear	45%	65%
Meniscal tear	45%	45%
Fracture	15%	5%

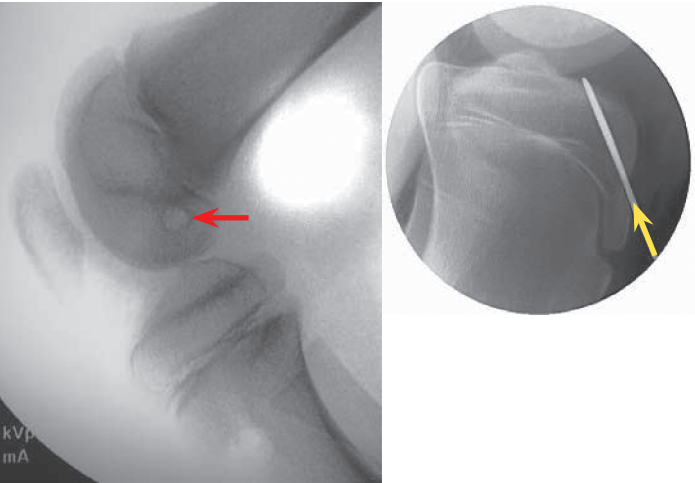
L Lesions associated with hæmarthrosis of the knee Prepubescent is defined as Tanner stage 1 or 2, <12 years for boys and <11 years for girls.



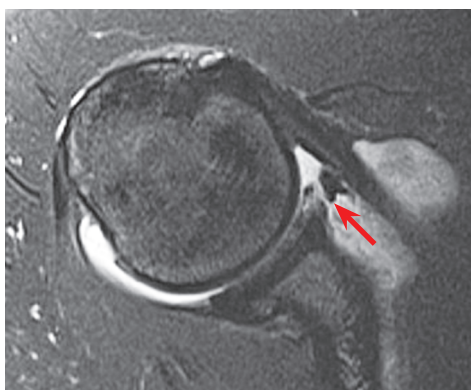
M MRI of the knee The anterior cruciate ligament is torn, as evidenced by discontinuity and fraying at the femur in contrast with the tibial stump that appears cord-like (yellow). The posterior cruciate ligament is dense and preserved (orange).



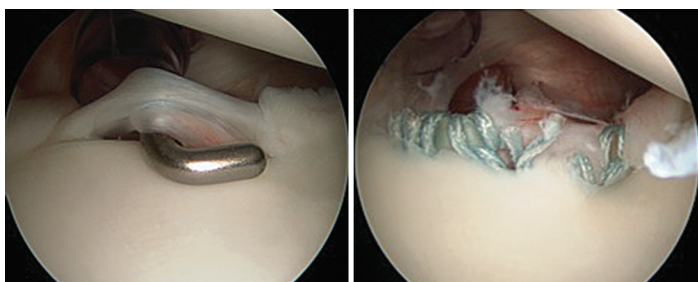
N Techniques for anterior cruciate ligament reconstruction The iliotibial tract (green) may be looped around the lateral femoral condyle, drawn through the knee under intermeniscal ligament, and sewn over the anterior tibial margin. Transphysal (middle) hamstring graft reconstruction is isometric. Intraepiphyseal (right) hamstring graft reconstruction seeks isometry while avoiding the physis.



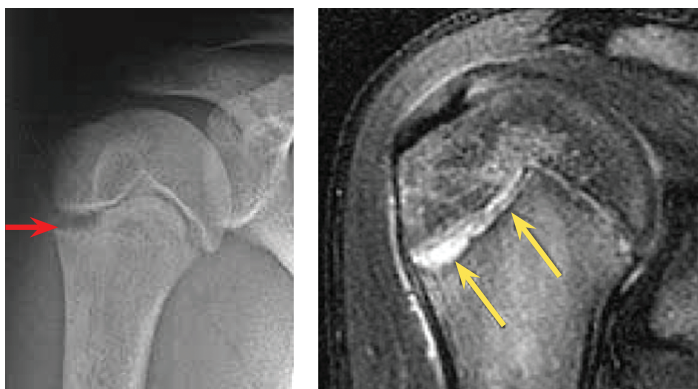
O Physeal-sparing anterior cruciate ligament reconstruction The distal physis of femur may be spared by drilling a transverse tunnel in the distal femoral epiphysis (red). The proximal tibial physis may be spared by staying within the proximal tibial epiphysis (yellow).



A Bankart lesion Labral avulsion from anterior glenoid cavity is seen on MRI (red).



B Bankart lesion A tear in the glenoid labrum, through which the probe is advanced, is repaired arthroscopically.



C Imaging of Little Leaguer's shoulder Anteroposterior view röntgenogram, taken in external rotation, shows widening of the lateral proximal physis of humerus. This is confirmed on MRI.

SHOULDER

The proximal physis gives 80% of longitudinal growth to the humerus. Three secondary ossification centers, for head and tubercles, coalesce by 7 years. The proximal physis fuses in the late teens. Peri-omal muscles—rotator cuff, deltoid, biceps brachii, scapular—dynamically stabilize the glenohumeral joint by concavity compression during motion. The glenohumeral capsule and ligaments are recruited as static stabilizers at the extremes of motion. The other static stabilizer is the labrum, which deepens the glenoid cavity.

Traumatic Instability

A third of acute traumatic shoulder dislocations occur in children. One half will recur, the rate being inversely correlated with age. The majority are anterior. The mechanism is a direct blow or forced abduction, lateral rotation, and extension. Most chronic instability also is anterior. Laxity develops from repetitive microtrauma, sustained during overhead sports.

Evaluation Ask about type of activity, for example, a contact sport such as ice hockey or overhead sport such as pitching. Determine the direction of instability. Is there anterior apprehension with shoulder abduction and external rotation? Is this improved with anterior pressure applied by the palm? Is there apprehension with posterior force applied through the humerus with the shoulder flexed, adducted, and internally rotated? Is there inferior instability, as evidenced by a sulcus sign with distraction? Can the head of the humerus be subluxated manually in the glenoid cavity?

IMAGING Röntgenogrammes, including axillary view, may show associated fracture, such as a Hill-Sachs lesion. MRI, without or with arthrography, determines the presence of a labral or glenoid rim avulsion (Bankart) as well as other soft tissue injury [A].

Management Most chronic instability is managed successfully by directed physiotherapy. If symptoms and signs persist beyond 6 months, consider surgical treatment, which may include imbrication of attenuated capsule and ligaments.

For anterior traumatic instability, in the absence of a Bankart lesion, immobilize for 3 weeks, after which begin dynamic shoulder stabilization under the guidance of a physiotherapist.

A Bankart lesion, as well as age at dislocation, are associated with recurrence in 3/4 of patients with nonoperative care. In addition, delayed has a higher recurrence than early operative repair. Less dissection is necessary by arthroscopy, in particular of subscapularis, which permits more rapid rehabilitation. Recurrence after operation is 10%.

Atraumatic Instability

This is multidirectional. Causes include ligamentous laxity and repetitive overhead activity.

Evaluation Patients complain of anterior shoulder pain with abduction and external rotation. Posterior pain may be elicited in the flexed and adducted position, such as when pushing in front of an object. Inferior instability may be felt when carrying a heavy load. Examine both shoulders, because the condition usually is bilateral. The sulcus sign is readily produced. The head of the humerus may be subluxated with ease. Look for other signs of ligamentous laxity, such as hyperextension of elbows, knees, metacarpophalangeal joints, and thumb on volar forearm.

IMAGING MRI may show capsular redundancy.

Management This resembles traumatic instability. Postoperative rehabilitation is slower, as this is a laxity and not a stiffness problem.

Little Leaguer's Shoulder

This is named after the inciting sport, namely, pitching a baseball. It represents an overuse proximal humeral physiolysis [C]. It may be exacerbated by rotator cuff weakness for the demands put upon it.

Evaluation The patient complains of diffuse upper arm and shoulder pain of insidious onset. Rule out shoulder instability. Ask about activity, including pitch count and rest periods between pitching.

IMAGING Röntgenogrammes show widening of the proximal physis of humerus. Contralateral images show no widening of the nondominant upper limb. MRI, obtained if presentation is atypical, confirms physiolyis [C].

Management This is nonoperative. Stop throwing. Strengthen the rotator cuff. Begin throwing in a monitored training program after 6 weeks. Return to a game after 3 months if pain has resolved. Do not exceed 600 pitches/season, which increases risk of this injury.

Impingement

This is the most common cause of posterior shoulder pain in adolescents who are involved in overhead sports, such as baseball pitchers, swimmers, and tennis players. In external rotation and abduction, supra- and infraspinatus abut against the posterosuperior labrum, leading to tear, partial articular supraspinatus tendon avulsions, and stretching of the anteroinferior capsuloligamentous complex. This is exacerbated by subtle instability.

Evaluation Provocative manoeuvres for impingement are positive, such as internal rotation with the shoulder flexed to 90 degrees, which elicits pain when supraspinatus impinges upon coracoacromial ligament and anterior acromion (Hawkins). Resisted abduction by supraspinatus in the plane of the scapula is painful with internal rotation (empty can) as the greater tubercle approaches the acromion, where the tendon may be squeezed. There may be an associated glenohumeral internal rotation deficit.

IMAGING Röntgenogrammes are normal. MRI will show increased T2-weighted signal intensity in the rotator cuff and subacromial space. Rotator cuff tear is rare.

Management Physiotherapy to strengthen the rotator cuff, in order to decrease risk of tear, and scapular stabilizers, as well as posterior capsular stretching, are effective in most patients. Refractory pain may be addressed arthroscopically, with subacromial bursectomy, labral repair, posterior capsular release, and capsular plication for associated instability as indicated.

ELBOW

The elbow is more often injured than the shoulder, with fractures accounting for the lion's share (*cf.* Trauma chapter). Sports injuries combine poor mechanics and more enthusiasm than skill. The mechanisms are similar for both joints, including overhead activity such as pitching a baseball, and involvement of the dominant upper limb. The flexor-pronator mass provides dynamic valgus stability to the elbow, while the static stabilizers are the ulnar collateral ligament and the radiocapitular joint.

Medial Little Leaguer's Elbow

This represents a traction apophysitis of the medial epicondyle of humerus, from which originate the flexor-pronator muscles of the forearm. The mechanism is excessive valgus loading of the elbow at cocking and initiation of acceleration [E], which is exacerbated by flexor-pronator contraction to flex the wrist during ball release. This is the more common injury—half of baseball pitchers will complain of this at least once—and the one for which the appellation was conceived. Force travels through the weaker medial epicondylar physis in the child, protecting the ulnar collateral ligament, which would be injured in the late teenager or adult.

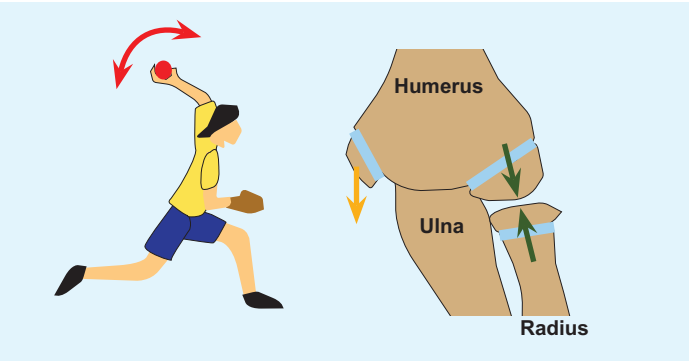
Evaluation The patient complains of medial elbow pain associated with the offending sports activity. There is tenderness and swelling of the medial epicondyle. Terminal extension may be lost.

IMAGING Röntgenogrammes may be normal or show epicondylar fragmentation or overgrowth (Hueter-Volkmann principle). It also may show separation of the epicondyle (*cf.* Trauma chapter).

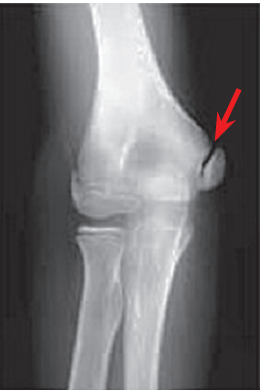Management Absent a fracture, treatment resembles that of Little League shoulder. It may be challenging to counsel patient and family, invested in playing, about nonoperative care for protracted symptoms.

Age (years)	Pitches per game	Games per week
8-10	52 ± 15	2 ± 0.6
11-12	68 ± 18	2 ± 0.6
13-14	76 ± 16	2 ± 0.4
15-16	91 ± 16	2 ± 0.6
17-18	106 ± 16	2 ± 0.6

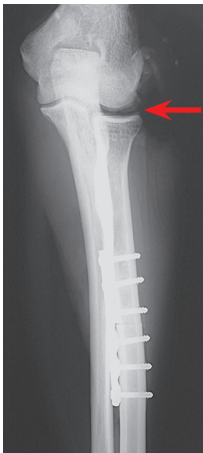
D Maximum pitches These guidelines were developed by the American Academy of Orthopaedic Surgeons to protect the shoulder of the paediatric athlete.



E Overhead sports Overhead acceleration against resistance, for example, pitching a baseball or striking a tennis ball, produces a valgus load that distracts the medial side (*orange*) and compresses the lateral side (*green*) of the elbow.



F Little Leaguer's elbow
Röntgenogrammes show physiolyis (*red*).



G Decompression of the radiocapitular joint In a cadaveric model, the radius was shortened the width of a saw blade (1 to 2 mm) and compression plated. The head of radius was thereby drawn away from capitulum (red), which reduces force and contact area across their articulation.

Time (after exercise)	Compartment Pressure
Rest	≥ 15 mm Hg
1 minute	≥ 30 mm Hg
5 minutes	≥ 20 mm Hg

A Pressure in exertional compartment syndrome These guidelines aid diagnosis.

Lateral Little Leaguer’s Elbow

Excessive valgus loading of the elbow results in compression of the radiocapitular articulation. The capitulum is more vulnerable to osteochondritis dissecans than the head of radius. Osteochondritis dissecans, which affects pubertal and older adolescents, differs from Panner disease, which is an osteochondrosis in prepubescent children that involves the entire capitulum and resolves spontaneously without sequelae (akin to Köhler disease of the tarsal navicular).

Evaluation The patient complains of activity-related lateral elbow pain. There may be mechanical symptoms such as catching or locking. There often is an associated flexion contracture. Pain is exacerbated by extension and valgus stress.

IMAGING The first röntgenographic sign is subchondral flattening. MRI allows measurement of size and classification and determines if there is a mobile body, all of which guide treatment.

Management This follows the general protocol for osteochondritis dissecans (*q.v.*). Stable lesions, characterized by open physis, flattening, and no contracture, heal with nonoperative treatment. Unstable lesions, in which physis is closed, capitulum is fragmented, and there is an associated contracture, benefit from operation. Surgical treatment includes anterior elbow capsulectomy for contracture >20 degrees.

A unique aspect is the role of decompression. This follows the experience of shortening osteotomy for Kienböck disease of the lunate. Shortening of the radius significantly reduces mean force, contact area, and pressure across the radiocapitular articulation. Alternatively, a lateral column shortening of the distal humerus may translate the capitulum proximalward and achieve the same effect; however, this may carry a higher risk, including osteonecrosis from injury to the posterior nonanastomotic blood supply of the capitulum.

OTHER

Exertional Compartment Syndrome

This first was described as march gangrene, after a mechanism and the ultimate outcome. It was named anterior tibial syndrome after the compartment most affected, although it also has been reported in lateral crural compartment, arm, forearm, hand, thigh, and gluteals. Adolescents are affected. While characterized by elevated muscular compartment pressures, the condition differs from its acute counterpart:

- Less pain.
- An intermittent course. It resolves with rest and is not progressive.
- Onset follows lower-energy trauma, for example, following running.
- Delayed presentation, typically 24 to 48 hours after inciting event.
- Chronic patients have increased intramuscular pressure at rest and a greater increase in this pressure with exercise.

Evaluation The patient complains of pain in the affected compartment that is brought on by exercise, which is stopped as a result. There may be associated neural findings such as paræsthesias. Pain resolves with rest without residuum. More than half have bilateral symptoms. Physical examination at rest is normal; after exercise, the compartment is tense.

TESTING Compartment pressures after exercise have been characterized [A], although such measurements are invasive. Near-infrared spectroscopy measures reduced oxygen saturation of muscle. Increased T2-weighted signal intensity is seen on MRI after exercise. Thallium 201 single photon emission CT, which is superior to electrocardiogram in detection of ischaemic muscle from coronary artery disease, is effective and accurate for exertional compartment syndrome.

Management Many patients will accommodate to pain. Fasciotomy is indicated for patient in whom pain is unacceptable and prevents exercise. This may be open *via* a single incision according to compartment involved or endoscopically assisted *via* two smaller incisions. Proceed with caution, because the morbidity of surgical treatment is not insignificant, including scar, infection, neural injury, and chronic pain.

Plica

Plica synovialis represents a normal “fold” (Latin *plica*, whence “*plication*”) of synovial membrane remnant from joint tricompartimentalization during fetal development. Locations are suprapatellar; medial parapatellar, which is most symptomatic; infrapatellar; and rarely lateral. Trauma incites inflammation, which hurts.

Evaluation There often is no history of a specific traumatic event. Presentation is in adolescence, including intermittent mechanical anterior knee pain, clicking with activity, catching or giving way, and palpable, tender crepitus with movement of the knee.

IMAGING This is a clinical diagnosis of exclusion. Röntgenogrammes are negative; MRI is variable.

Management Most patients respond to rest, activity modification, patellar taping, as well as quadriceps and core strengthening. Pain persistent for more than 6 months may be addressed arthroscopically. Surgical findings include hypertrophy, injection, cord or ledge morphology, bowstringing and snapping over, and erosion of femoral condyle or patella [B].

Reflex Neurovascular Dystrophy

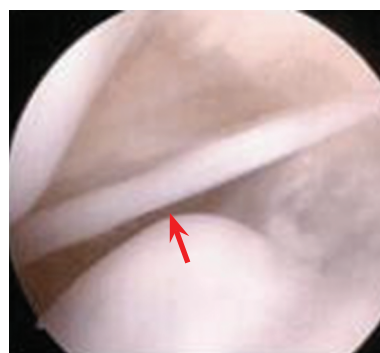This is the childhood equivalent of complex regional pain syndrome in adults. The concept has evolved since the original description from the American Civil War (Mitchell). The name described loss of descending pain inhibition at the spinal cord that sets up a vicious cycle of vascular constriction, hypo-oxygenation, and hyperacidosis, followed by more pain. Girls outnumber boys 3:1. The lower limb is affected twice as often as the upper limb.

Evaluation There is a history of trauma, for example, articular fracture of the knee. The child complains of amplified or disproportionate pain after healing has been demonstrated by objective measures. Pain does not follow an anatomic or dermatomal pattern. Associated findings include limp, stiffness, hyperaesthesia, atrophy of disuse, and cutaneous change in temperature and color.

IMAGING This confirms healed injury. Röntgenogrammes may show osteopenia. Scintigramme may show asymmetric uptake due to dysautonomia [C].

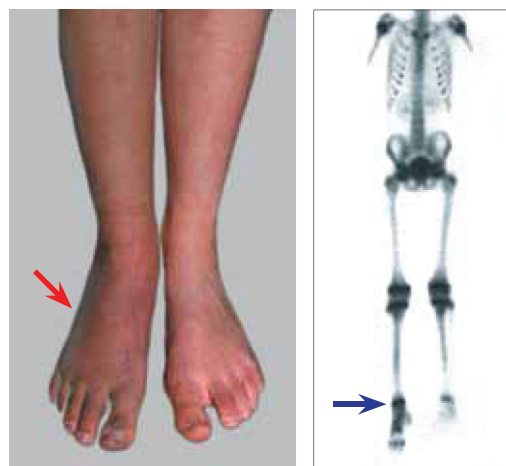
Management This is a diagnosis of exclusion, which requires at once confidence and sensitivity to establish and accept. Delay in diagnosis is typical. Take time to educate and assure patient and family. Vigorous physiotherapy is the cornerstone, even through pain: do not immobilize or otherwise support that the child is vulnerable. Do not operate, for example, arthroscopy to lyse adhesions: this is an additional trauma that exacerbates the problem. Enlist a psychologist to explore other stressors in the child’s life, both at school and in the home. A 2- to 3-week hospitalization may be beneficial in fulminant cases. The objectives are to ensure compliance with physiotherapy, up to 5 hours daily, and to control the environment, including sequestration from parents. The role of vitamin C as prophylaxis, administered daily starting at the time of injury or in the emergency setting, is not well defined.

Most patients recover completely or are significantly improved. Five percent develop chronic pain. Up to 15% may relapse.



B Symptomatic plica synovialis

This normal structure is bowstrung across the femoral condyle.



C Reflex neurovascular dystrophy after severe ankle sprain The leg and foot have diffuse soft swelling and discoloration (*red*), which corresponds with increased signal on scintigramme (*blue*).

GENERAL

- Blount WP. *Fractures in Children*. Baltimore, MD: Williams & Wilkins Co.; 1954.
- Cawley J. The economics of childhood obesity. *Health Aff.* 29(3):364–371, 2010.
- Faigenbaum AD, Myer GD. Resistance training among young athletes: safety, efficacy and injury prevention effects. *Br. J. Sports. Med.* 44(1):56–63, 2010.
- König F. Veber freie körper in der gehenken. *Dtsch. Z. Chir.* 27:90–109, 1888.
- Halstead ME, Kevin D, Walter KD, Council on Sports Medicine and Fitness. Clinical report: sport-related concussion in children and adolescents. *Pediatrics* 126(3):597–615, 2010.
- Lippi G, Longo UG, Maffulli N. Genetics and sports. *Br. Med. Bull.* 93(1):27–47, 2010.
- Norton C, Nixon J, Sibert J. Playground injuries to children. *Arch. Dis. Child.* 89(2):103–108, 2004.
- Wilt F, Yessis M. *Soviet Theory, Technique and Training for Running and Hurdling*. Ames, Iowa: Vol. 1. Championship Books, 1984.

ANKLE

- Berndt AL, Harty M. Transchondral fractures (osteochondritis dissecans) of the talus. *J. Bone Joint Surg.* 41-A:988–1020, 1959.
- Flick AB, Gould N. Osteochondritis dissecans of the talus (transchondral fractures of the talus): review of the literature and a new surgical approach for medial dome lesions. *Foot Ankle* 5(4):165–185, 1985.
- Tol JL, Struijs PAA, Bossuyt PMM, Verhagen RAW, van Dijk CN. Treatment strategies in osteochondral defects of the talar dome: a systematic review. *Foot Ankle Int.* 21(2):119–126, 2000.

KNEE

- Kennedy A, Coughlin DG, Metzger MF, Tang R, Pearle AD, Lotz JC, Feeley BT. Biomechanical evaluation of pediatric anterior cruciate ligament reconstruction techniques. *Am. J. Sports Med.* 39(5):964–971, 2011.
- Hefti F, Beguiristain J, Krauspe R. Osteochondritis dissecans: a multicenter study of the European Pediatric Orthopedic Society. *J. Pediatr. Orthop.* 8(4)-B:231–245, 1999.
- Hui C, Roe J, Ferguson D, Waller A, Salmon L, Pinczewski L. Outcome of anatomic transphyseal anterior cruciate

ligament reconstruction in Tanner stage 1 and 2 patients with open physes. *Am. J. Sports Med.* 40(5):1093–2008, 2012.

- Joo SY, Park KB, Kim BR, Park HW, Kim HW. The ‘four-in-one’ procedure for habitual dislocation of the patella in children: early results in patients with severe generalised ligamentous laxity and aplasia of the trochlear groove. *J. Bone Joint Surg.* 89(12)-B:1645–1649, 2007.
- Kocher MS, DiCanzio J, Zurakowski D, Micheli LJ. Diagnostic performance of clinical examination and selective magnetic resonance imaging in the evaluation of intra-articular knee disorders in children and adolescents. *Am. J. Sports Med.* 29(3):292–296, 2001.
- Lawrence JT, Argawal N, Ganley TJ. Degeneration of the knee joint in skeletally immature patients with a diagnosis of an anterior cruciate ligament tear: is there harm in delay of treatment? *Am. J. Sports Med.* 39(12):2582–2587, 2011.
- MacIntosh DL, Darby TA. Lateral substitution reconstruction. *J. Bone Joint Surg.* 58-B:142–146, 1976.
- MacNab I. Recurrent dislocation of the patella. *J. Bone Joint Surg.* 34(4)-A:957–967, 1952.
- Nelitz M, Dornacher D, Dreyhaupt J, Reichel H, Lippacher S. The relation of the distal femoral physis and the medial patellofemoral ligament. *Knee Surg. Sports Traumatol. Arthrosc.* 19(12):2067–2071, 2011.
- Rohren E, Kosarek FJ, Helms CA. Discoid lateral meniscus and the frequency of meniscal tears. *Skeletal Radiol.* 30(6):316–320, 2001.
- Stanitski CL, Harvell JC, Fu F. Observations on acute knee hemarthrosis in children and adolescents. *J. Pediatr. Orthop.* 13(4):506–510, 1993.
- Vavken P, Murray MM. Treating anterior cruciate ligament tears in skeletally immature patients. *Arthroscopy* 27(5):704–716, 2011.
- Wilson JN. A diagnostic sign in osteochondritis dissecans of the knee. *J. Bone Joint Surg.* 49(3)-A:477–480, 1967.
- Young R. The external semilunar cartilage as a complete disc. In: Cleland J, Mackey JY, Young RB, eds. *Memoirs and Memoranda in Anatomy*. London, UK: Williams and Norgate; 1987:179–187.

SHOULDER

- Bottoni CR, Smith EL, Berkowitz MJ, Towle RB, Moore JH. Arthroscopic versus open shoulder stabilization for

- recurrent anterior instability. A prospective randomized clinical trial. *Am. J. Sports Med.* 34(11):1730–1737, 2006.
- Dotter WE. Little leaguer’s shoulder—fracture of the proximal humeral epiphyseal cartilage due to baseball pitching. *Guthrie Clin. Bull.* 23(1):68–72, 1953.
- Hovelius L, Augustini BG, Fredin H, Johansson O, Norlin R, Thorling J. Primary anterior dislocation of the shoulder in young patients. A ten-year prospective study. *J. Bone Joint Surg.* 78(11)-A:1677–1684, 1996.
- Pasque CB, McGinnis DW, Griffin LY. Shoulder. In: Sullivan JA, Anderson ST, eds. *Care of the Young Athlete*. Rosemont, IL: American Academy of Orthopaedic Surgeons, and Elk Grove Village, IL: American Academy of Pediatrics; 2000.

ELBOW

- Bennett GE. Shoulder and elbow lesions distinctive of baseball players. *Ann. Surg.* 126(1):107–110, 1947.
- Diab M, Poston JM, Huber P, Tencer AF. The biomechanical effect of radial shortening on the radiocapitellar articulation. *J. Bone Joint Surg.* 87(6)-B:879–883, 2005.
- Takahara M, Mura N, Sasaki J, Harada M, Ogino T. Classification, treatment, and outcome of osteochondritis dissecans of the humeral capitellum. *J. Bone Joint Surg.* 89(6)-A:1205–1214, 2007.

OTHER

- Goldschneider KR. Complex regional pain syndrome in children: asking the right questions. *Pain Res. Manag.* 17(6):386–390, 2012.
- Johnson DP, Eastwood DM, Witherow PJ. Symptomatic synovial plicae of the knee. *J. Bone Joint Surg.* 75(10)-A:1485–1496, 1993.
- Mavor GE. The anterior tibial syndrome. *J. Bone Joint Surg.* 38(2)-B:513–517, 1956.
- Mitchell SW, Morehouse GR, Kean WW. *Gunshot Wounds and Other Injuries of Nerves*. New York: Lippincott, 1864.
- Nallamothu N, Pancholy SB, Lee KR, Heo J, Iskandrian AS. Impact on exercise single-photon emission computed tomographic thallium imaging on patient management and outcome. *J. Nucl. Cardiol.* 2(4):334–338, 1995.
- Pedowitz RA, Hargens AR, Mubarak SJ, Gershuni DH. Modified criteria for the objective diagnosis of chronic compartment syndrome of the leg. *Am. J. Sports Med.* 18(1):35–40, 1990.